

METHODS FOR QUANTITATIVE ASSESSMENT OF FEMORAL ANTROPOSCOPIC LANDMARKS USING HAND-HELD LASER SCANNER

Pavel Timonov¹, Stefan Sivkov², Tsvetanka Petleshkova²

¹*Department of Pathological Anatomy and Forensic Medicine,
Medical University of Plovdiv*

²*Department of Anatomy, Histology and Embryology, Medical University of Plovdiv*

ABSTRACT

PURPOSE: This study is focused on an innovative approach to the numerical assessment of gluteal tuberosity through 3D visualization and its use as sex discriminant.

MATERIALS AND METHODS: The study was based on an aggregate of 40 right femora, male and female in equal proportion. The surface of tuberositas glutea femoris is captured in a 3D image, using a Hand-held Laser Scanner (FastSCAN). Afterwards, the assessment contains three ways. Firstly, the result is a 3D shape comprising two tetrahedrons with common base. Therefore, the volume of the roughness is approximately equal to the total of the volumes of these two tetrahedrons (volume). Secondly, several points /markers/ are placed on the surface of the roughness of the 3D image. After that we create two-dimensional shape which is a function of the three-dimensional one. The area of the formed shape is measured (area) as well as its greatest elevation (elevation). Thirdly, we assess the position angle of gluteal tuberosity (angle C). The results were processed with SPSS 17.0 using Discriminant Function Analysis.

RESULTS: If the predictors (volume, area, elevation and angle) are included in the model, than the percentage of cases classified correctly is 95%.

CONCLUSION: This score coincides with world results based on various anthropometric indices of the femur.

Key words: *gluteal tuberosity, sex determination, femoral bone, Hand-held Laser Scanner*

INTRODUCTION

Each forensic anthropology examination of human skeletal remains is based on determining “the great four”: sex, age, stature and race. When the whole

skeleton, including pelvis and skull, is available, the accuracy rate of sex determination reaches up to 95%. In case of a single bone available, except for a femur, sex determination is seriously impeded.

The significant sexual dimorphism of the femur is based on several facts:

1. Men are relatively physically stronger than women and they use their muscles more actively.
2. Men's axial skeleton is heavier than women's and this weight is normally distributed in the upper end of the two femora.
3. Due to its reproductive function the female pelvis differs in shape from male's, which is

Address for correspondence:

Pavel Timonov

*Department of Pathological Anatomy and Forensic Medicine
Medical University of Plovdiv*

Plovdiv 4001, bul. Vassil Aprilov 15a

0888409590

e-mail: antoaneta_ioan@yahoo.com

Received: January 25, 2013

Accepted: February 11, 2013

expected to result in a change in the upper part of the femora, forming the pelvic bones (3).

This study aims to demonstrate a contemporary and innovative method for quantitative assessment of tuberositas glutea femoris through 3D visualization. The said method allows for its accurate mathematical estimation and can be use as a sex discriminant or as an additional predictor in models for the purpose of sex determination of the femur. Furthermore, it could be useful in the assessment of other osteoscopic landmarks.

MATERIALS

The study was based on an aggregate of 40 right femora, male and female in equal proportion. They had been subject of forensic examination, and the sex of one part of said femora was known, while that of the others was determined through pelvic bones analysis. Bones included in this study fulfill the following criteria: 1 - show no anomalies, deformations or abrasions, 2 - have sustained no fractures previously, 3 - have reached skeletal maturity. The average age of the known male bones is $48,4 \pm 13,44$ years, and of the female ones $72,6 \pm 13,97$ years /Mean \pm SD/.

Tuberositas glutea femoris is the subject of scanning due to the following features:

1. the strongest extensor muscle, gluteus maximus, in the human body is inserted in it.
2. due to the fact that the effect of muscle action is more powerful on the point of insertion than on the point of origin (3,4).
3. gluteus maximus stabilizes the hip joint, which in its turn shows great sexual dimorphism.
4. the activity and function of gluteus maximus are continuous and daily, for instance, 60% of the movements for taking a single stride when walking are performed by gluteus maximus along with gluteus medius (5).
5. muscle activity is higher in men than in women (5,6,8).

On the grounds of these features the following conclusion may be drawn in advance, this antroposcopic landmark will differ considerably in men and women in its size and impression and will be successfully used as a sex discriminant.

METHODS

Firstly, the surface of tuberositas glutea femoris is captured in a 3D image, using a Hand-held Laser Scanner (FastSCAN) (10,11,12). Afterwards, the following points (markers) are placed on the surface of the 3D image obtained. They are placed as follows – on the uppermost point, on the roughness – femoral surface margin (point a), on the lowest point of the roughness – femoral surface margin or on the margin where it meets labium laterale (point d), on the most medial point, on the roughness – femoral surface margin (point b), on the most lateral point, on the roughness – femoral surface margin (point f) and the uppermost point is empirically selected on the roughness itself (point 2). Each of these points is defined by certain x, y, and z values. The result is a 3D shape comprising two tetrahedrons(abf2 and dbf2) with common base (bf2). Therefore, the volume of the roughness is approximately equal to the total of the volumes of thesetwo tetrahedrons and it is the first predictor: $V = V_{abf2} + V_{dbf2}$. The measurement unit is in mm³.

This method of calculation of volumes of descriptive characteristics by creation of geometrical figures similar in size and shape to the studied objects and their use as sex discriminants is applied, for example, in morphological assessment of lips and external nose in facial reconstruction (10,11) (Fig. 1).

Secondly, on the roughness itself some uppermost projecting points, as well as lowest points, are selected /points 1,2,3,4,5 and 6, the bigger the

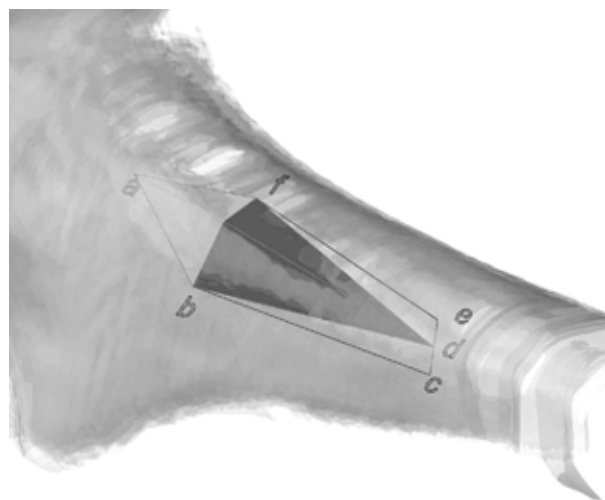


Fig. 1.

number of these points, the more precise the method is, as the impression of the roughness is more accurately described/. Also, each point marked is defined by x, y, and z values.

Afterwards the following stages are performed:

1. Finding the sectioning point of the straight line bf (**point g**).
2. Creating three planes – the first one **A** is determined by points a, g and d, the second one **B** – by points a, f and d and the third one **C** – by a, b and d, so that the straight line bf lies simultaneously on the three planes created.
3. Points 1,2,3,4,5 and 6 are transposed to the formed plane A, as the elevations at which they are positioned are respectively above planes B and C and are, respectively, equal to their elevations over the straight line ad in plane A.

This results in the formation of a 2D polygonal shape, defined within the following points a, g, d and transposed 1,2,3,4,5 and 6.

The newly created two-dimensional shape is a function of the three-dimensional one. The area of the formed shape is measured (**area**) as well as its greatest elevation (elevation), which are other predictors. The measurement units are in mm² and mm.

Why have we selected the above points?

1. **Points a, d, b and f characterize the size of the point of insertion and the function of gluteus maximus, respectively, extension, external rotation, abduction and adduction!**

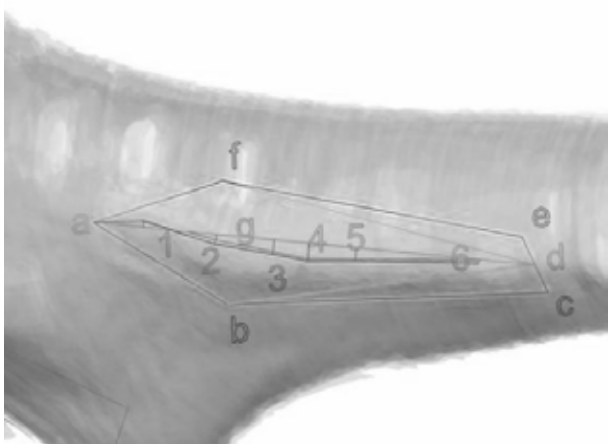


Fig. 2.

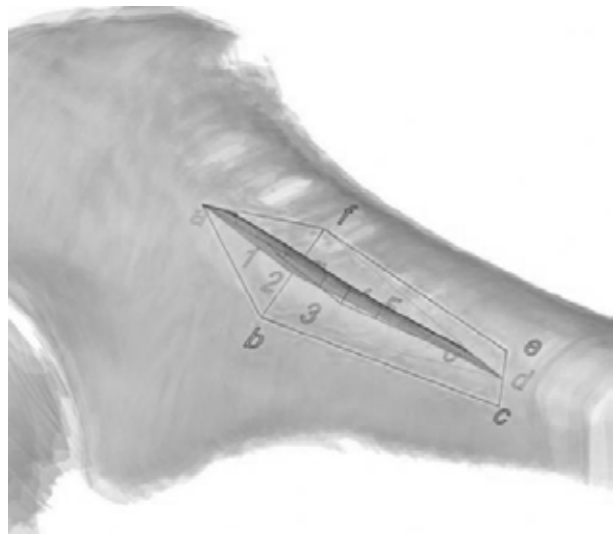


Fig.3.

2. **Points 1,2,3,4,5 and 6 characterize the impression of the point of insertion!**
3. **Point g /the middle of the line bf/ also characterizes the functional activity of the muscle, especially the external rotation of the hip, the wider the roughness, the lower the position of point g under straight line ad, and the area of the 2D polygonal shape will be larger and vice versa!**

In women the point of insertion of the muscle in the bone is smaller in size and has less distinctive impression [3,4]. Based on the above data, it could be concluded that the variables of the shape obtained will be indicative of sex differences.

RESULTS

Statistics - SPSS 17,0 is used The means of the three independent variables /volume, area of the 2D shape and its greatest elevation /for both sexes/ are shown in Table 1.

By applying the Kolmogorov-Smirnov Test it was established that the following variables - area /p=0,218/, elevation /p=0,656/ and volume /p=0,60/ are normally distributed. The Independent Samples Test indicates significant difference in the variables between the two sexes /p<0,05/, which makes them suitable as successful sex discriminants /Table 2/, i.e., male indices exceed female ones.

Tabl. 1.

Sex	N	%	Area (A)		Volume (V)		Elevation (E)	
			Mean	SD	Mean	SD	Mean	SD
M	20	50	1,32	0,16	0,72	0,09	0,43	0,07
F	20	50	1,11	0,16	0,59	0,14	0,25	0,07

The acquired data is subjected to Discriminant Analysis and the three discriminants are simultaneously involved as independent variables.

F= 1,665 x Area + 11,427 x Elevation - 5,927. In cases of F>0 we accept that the bone is male and vice versa. As a result of this function the accuracy of sex determination is: Male - 95%, Female - 90%, Total - 92,5%.

DISCUSSION AND CONCLUSION

The yielded result of correct sex determination - 92,5% coincides with world results based on various anthropometric indices of the femur, both as independent variables and in combination with other variables, for instance, vertical and horizontal diameter of the head, circumference of the head,

superior - inferior diameter of the femoral neck, width of the distal epiphysis, circumference in the middle of the diaphysis, dimensions of Purkait's triangle, etc. They give results within the range of about 82% to 95% (1,2,7,8,9).

Muscle activity is higher in men than in women. This, in its turn, results in difference in both the anthropometric and antroposcopic landmarks, in favour of the male sex. This study demonstrates innovative method for objective evaluation of the muscles' points of insertion which can be used successfully for sex determination, especially in case of highly fragmented bones that impede anthropometric analyses.

The present study was based on research project 02/25 from 20.12.2010 financed by the Ministry of Education and Science: "Cephalometric investigation and 3D virtual modelling of the face for the construction and visualization of 3D facial statistics and the establishment of a cephalometric database".

Tabl. 2.

Sex	M	F	t	P
N	20	20		
A mean±SD	1,32±0,16	1,11±0,16	4,682	<0,001
E mean±SD	0,43± 0,07	0,25±0,07	7,318	<0,001
V mean±SD	0,72 ± 0,09	0,59 ± 0,14	3,416	=0,02

Tabl. 3.

Functions and variables	Raw coefficient	Standart coefficient	Structure coefficient	Sectioning point
Area	1,905	0,272	0,591	0
Elevation	14,724	1,123	0,924	
Volume	-3,842	-0,459	0,431	
Constant	-4,805			

REFERENCES

1. Alunni-Perret, V., P. Staccini, G. Quatrehomme. Reexamination of a Measurement for Sexual Determination Using the Supero-Inferior Femoral Neck Diameter in a Modern European Population.- *Forensic Sci.*, **48**, 2003, No 3.
2. Black, T. A new method for assessing the sex of fragmentary skeletal remains: femoral shaft circumference.- *Am. J. Phys. Anthropol.*, **48**, 1978, 227-231.
3. Breathnach, A. Frazer's Anatomy of Human Skeleton, 5th ed. J.A. Churchill Ltd., London, 1958.
4. France, D. Osteometry at muscle origin and insertion in sex determination.- *Am. J. Phys. Anthropol.*, **76**, 1988, 515-526.

5. Hamill, J., K. Knutzen. *Biomechanical Basis of Human Movement*, 3rd Edition, Copyright 2009, Lippincott Williams & Wilkins.
6. Hennessy, R., S. McLearn, A. Kinsella, J. Waddington. Facial Shape and Asymmetry by Three-Dimensional Laser Surface Scanning Covary With Cognition in a Sexually Dimorphic Manner.- *J. Neuropsychiatry Clin. Neurosci.*, **18**, 2006, 73-80.
7. Işcan, M., S. Ding. Sexual dimorphism in the Chinese femur.- *Forensic Sci. Int.*, **74**, 1995, 79-87.
8. Purkait, R. Triangle identified at the proximal end of femur: a new sex determinant.- *Forensic Sci. Int.*, **147**, 2005, 135–139.
9. Robinson, M., M. Bidmos. An assessment of the accuracy of discriminant function equations for sex determination of the femur and tibia from a South African population.- *Forensic Sci. Int.*, **206**, 2011, 210- 212.
10. Sforza, G., G. Grandi, M. Binelli, C. Dolci, M. De Menezes, V. Ferrario. Age- and sex-related changes in three-dimensional lip morphology.- *Forensic Sci. Int.*, **200**, 2010, 182.e1–182.e7.
11. Sforza, C., G. Grandi, M. De Menezes, G. Tartaglia, V. Ferrario. Age- and sex-related changes in the normal human external nose.- *Forensic Sci. Int.*, **204**, 2010, 205.e1–205.e9.
12. www.fastscan3d.com