

# PSEUDOMYXOMA PERITONEI – A REPORT OF TWO CASES AND A REVIEW OF THE LITERATURE

Daniel Stefanov<sup>1</sup>, Ventsislav Mutafchiyski<sup>2</sup>, Georgi Popivanov<sup>2</sup>, Kirien Kjossev<sup>1</sup>,  
Petko Dimov<sup>1</sup>, Dimitar Dimitrov<sup>1</sup>

<sup>1</sup>*Clinic of Abdominal Surgery, Military Medical Academy, Sofia*

<sup>2</sup>*Clinic of Endoscopic, Endocrine surgery and Coloproctology,  
Military Medical Academy, Sofia*

## ABSTRACT

**INTRODUCTION:** PMP is a rare disease with a slow but progressive course leading to death. According to the literature PMP encompass wide variety of conditions. To avoid the confusion and to facilitate the treatment and comparison of the results several authors suggested that the term “PMP” should include only the cases with appendiceal origin.

**CASE REPORT:** We report two cases with low-grade pseudomyxoma peritonei. The first case was managed by debulking surgery alone with survival 2 years. The second case underwent complete cytoreduction plus HIPEC and 3 years later is still alive and free of disease. There was one patient with a benign appendiceal mucocele treated by appendectomy, who is free of disease 3 years later.

**CONCLUSION:** Despite the high complication rate, cytoreductive surgery with HIPEC remains the gold standard in the treatment of pseudomyxoma peritonei. The tumor grade and completeness of cytoreduction are the main prognostic factors. Due to the rarity of the condition most of the surgeons are not experienced enough to manage these patients. Additionally, the incomplete cytoreduction is associated with poorer prognosis and significantly hampers the subsequent interventions. Thus, in the cases when it is found incidentally, the best strategy is the taking of biopsy, appendectomy and subsequent referral to a specialized center for a treatment by multidisciplinary team.

**Keywords:** *pseudomyxoma peritonei, debulking; cytoreductive surgery, HIPEC, long-term survival*

---

### Address for correspondence:

Georgi Popivanov, MD  
Clinic of Endoscopic, Endocrine surgery and Coloproctology  
Military Medical Academy  
“Georgi Sofiiski” Str. 3  
Sofia, 1606  
Bulgaria  
+359 885 521 241  
+359 2 952 65 36 (Fax)  
e-mail: [gerasimpopivanov@rocketmail.com](mailto:gerasimpopivanov@rocketmail.com)

**Received:** June 16, 2015

**Accepted:** September 12, 2015

## INTRODUCTION

Pseudomyxoma peritonei (PMP), known also as “jelly belly”, is a rare and still poorly understood disease. It is associated with a slow, but progressive accumulation of mucinous ascites with a scant cellular component within the peritoneal cavity. PMP includes a wide variety of conditions, from mucinous ascites due to ruptured cystadenoma of the appendix to a disseminated peritoneal mucinous adenocarcinoma. Irrespectively of the pathological type, it eventually leads to a progressive abdominal disten-

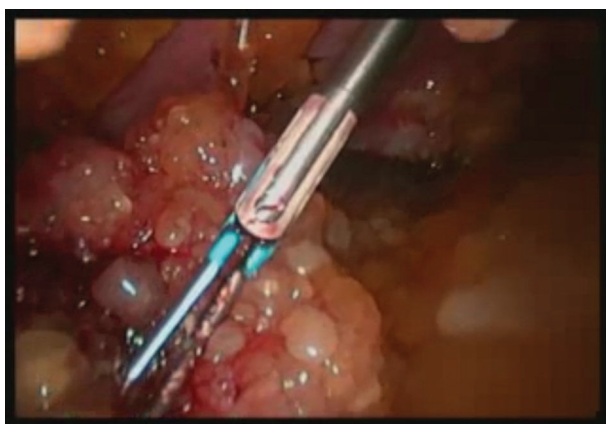
sion and a lethal outcome due to abdominal compartment syndrome.

Most of the cases are unexpectedly diagnosed during laparotomy or at imaging during an investigation of another disease. This, together with its rarity and the lack of consensus about the definition and management, is a source of significant diagnostic and treatment challenges. The aim of the present work is to report two cases along with a brief review of the literature in order to shed more light on this rare entity.

## CASE PRESENTATION

### Case 1

A 57-year-old man complaining of weight loss and increased abdominal girth. CT examination revealed only a large amount of ascites. CEA and CA 19-9 were 282 U/l and 188 ng/l, respectively. The laparoscopy found gelatinous ascites throughout the entire abdomen and multiple peritoneal lesions (Fig. 1, 2). Microscopic examination revealed mucin lakes with a scant cellular component with a characteristic of low grade carcinoma. The patient underwent 6 courses of XELOX with subsequent debulking surgery. Unfortunately, 2 months later the disease recurred and he underwent only exploratory laparotomy. The overall survival was 2 years.



firm fibrous capsule and whitish gelatinous content along with multiple lesions affecting great omentum, uterus and adnexa. She underwent tumor removal with right hemicolectomy, omentectomy, cholecystectomy, hysterectomy and adnexectomy. Thus complete cytoreduction was achieved. Pathological examination revealed low grade mucinous adenocarcinoma. Due to lack of equipment for HIPEC it was performed later in Germany. Three year later she is still alive and free of recurrence.

## DISCUSSION

The incidence of PMP is 1-2 cases per million. There is a slight preponderance of females (0.6-1.9 vs. 0.4-1 in men) (1). According to 10-year nationwide study from the Netherlands, the appendiceal tumors occur in 0.9%. Only 9% of them developed PMP [2].

The primary origin of PMP has been a subject of debate for a long time. Rokitansky first reported a case of the benign appendiceal mucocele in 1842, whereas Cruveilhé in 1848 described “maladie gélatineuse du pèritoine”. In 1884, Werth coined the term “PMP” and related it to ovarian neoplasm. Subsequently, Frankel considered PMP as a consequence of peritoneal spreading of benign, whereas Woodruff and McDonald, of malignant appendiceal mucocele.

Although in most of the cases PMP originates from the appendix, several authors include the cas-

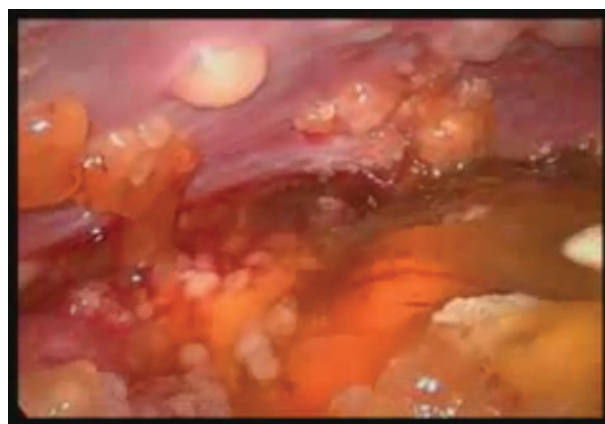


Fig. 1, 2. Laparoscopic view of case 1

### Case 2

A 58-year-old woman admitted with CT and MRT evidence for a large tumor mass located between the right kidney and the pelvis. Intra-operatively, it was found to originate from a cecum with

es in which the primary tumor (benign or malignant) arises from different organs (ovary, stomach, small intestine, gallbladder, urinary bladder, lung) (3). However, this wide spectrum of conditions have different prognosis and the patients might not re-

ceive the appropriate treatment. Additionally, it significantly hampers the comparison of the results of the treatment and prognosis. In this light, Sugarbaker et al. suggested that the term “PMP” should be applied only to the cases in which the primary tumor is appendiceal cystadenoma or adenocarcinoma (4,5). Thus, mucinous ascites from other malignancies should not be included.

Several studies support the appendiceal origin of PMP (6-8). All cases are positive for CK-20 and CEA, whereas ovarian tumors express CK-7 and HAM-56 (6).

The primary event is a rupture of the appendix, which is often occult. It leads to a slow intraperitoneal spreading of mucin and mucin-producing cells, which accumulate at specific sites such as diaphragm domes, liver surface, omentum, pelvis and the fixed parts of gastrointestinal tract (antrum and pylorus, ileocecal region, rectosigmoid area and upper rectum). A pathognomonic feature is the lack of deposits on the small bowel due to lack of adhesion molecules on the tumor cells and the normal peristalsis.

The pathological classification of PMP is very important in relation to the prognosis. According to Ronnet et al. there are 3 types – disseminated peritoneal adenomucinosis (DPAM), peritoneal mucinous carcinomatosis (PMCA) and peritoneal mucinous carcinomatosis with intermediate or discordant features (PMCA-I/D) (9). To overcome the possible sources of bias, the WHO classification from 2010 considers PMP as a malignant disease with two main subtypes – low and high grade (10).

Most frequently, the PMP is clinically manifested by abdominal distension (23-50%), suspicion of acute appendicitis (27%), a new onset inguinal hernia (14%) and ovarian mass in women (39%). An increasing number of cases are diagnosed incidentally through a CT examination during another investigation, especially in women. The best diagnostic modality is CT scan, which reveals free peritoneal fluid with areas of low and higher attenuation. The “scalloping” of liver and spleen and “omental cake” distinguish mucinous from fluid ascites (11). CEA and CA 19-9 are elevated in 75% and 58% of the cases (12).

The surgical treatment is the central component of the therapy with two approaches available. Debulking surgery includes the removal of most of

the mucinous material and appendectomy without taking excessive surgical risks. This approach is associated with frequent and more difficult reoperations due to adhesions and fibrous separation of the mucin. The 5-year survival is significantly lower than after cytoreductive surgery (40% vs 74%) although some authors reported similar prognosis (1).

The current standard of care is cytoreductive surgery or so-called Sugarbaker’s procedure combined with hyperthermic intraperitoneal chemotherapy (HIPEC). It includes the stripping of the peritoneum from the diaphragmatic domes, liver surface and pelvis, cholecystectomy, antrectomy and removal of lesser and greater omentum, uterus and ovaries, splenectomy and rectosigmoidectomy. The whole operation usually takes 6-13 hours, but in practice the simultaneous removal of all organs is rarely indicated. The abdominal cavity is divided into 12 regions given in Table 1. The operative report should be made according to the Extent of Surgery Score (ESS), introduced by Sugarbaker et al. (table 2). The completeness of cytoreduction (CCR) includes 4 degrees: 0 – no residual tumor, 1 – no residual nodule > 2.5 mm, 2 – no residual nodule > 25 mm and 3 – residu-

*Table 1. The abdominal regions according to Sugarbaker*

N	Region	N	Region
0	Central	7	Right lower
1	Right upper	8	Right flank
2	Epigastrium	9	Upper jejunum
3	Left upper	10	Lower jejunum
4	Left flank	11	Upper ileum
5	Left lower	12	Lower ileum
6	Pelvis		

*Table 2. Extent Surgery Score (ESS)*

ESS	Description
0	Biopsy only
1	Exploratory laparotomy with cytoreduction, 1-2 regions
2	Exploratory laparotomy with cytoreduction and resection, 2-5 regions
3	Extensive cytoreduction, > 5 regions

al nodules > 25 mm.

Currently, HIPEC should be attempted in all cases because it significantly influences the overall survival rate even in the cases with incomplete cytoreduction (59 vs. 33 months) (13). It was initiated in Washington Hospital Center in 1992 and consisted of intraperitoneal delivery of Mitomycin C heated to 41-42°C for 90 min. before the completion of anastomoses (14). More recently, Elias et al. introduced a new regimen with Oxaliplatin alone or with Irinotecan for 30 min. at 43°C, which might be combined or not with intravenous administration of 5-FU (15,16).

The results of CRS and HIPEC are summarized in Table 3. Recently, Lord et al. reported 5-year sur-

The main favorable prognostic factors are low grade tumors and completeness of cytoreduction, which is demonstrated in Table 4.

The study of Chua et al. deserves a special attention (30). It includes overall 2 298 patients from 16 centers treated from 1993 to 2011. Approximately 31% of the cases were with high-grade tumors. Complete CRS was achieved in 51%, whereas HIPEC was performed in 89%. The overall 5-, 10- and 15-year survival was 74%, 63% and 59%, whereas the median survival was 16.3 years. The study clearly demonstrated the survival benefit of low vs. high grade tumors, HIPEC vs. no HIPEC and complete vs. incom-

Table 3. Survival rates after Sugarbaker's procedure and HIPEC

Author	Year	N	5 -year, %	10-year, %	High grade, %
Smith (17)	1992	17	75	60	NA
Gough (18)	1994	56	53	32	†66
Sugarbaker (19)	1999	385	50	-	NA
Piso (20)	2001	16	*75	-	100
Van Ruth (21)	2003	62	70	-	NA
Misdraji (22)	2003	107	86/44	45	18
Guner (23)	2005	28	43	-	NA
Baratti (24)	2008	89	78	-	29
Vaira (25)	2009	60	94	85	NA
Elias (26)	2010	301	79	-	22
Youssef (27)	2011	456	87	74	NA
Andreasson (28)	2012	152	74	-	46
Sorensen (29)	2012	93	-	69	39
Chua (30)	2012	2 298	75	63	30.5
Iversen (31)	2013	29	73	-	14
Kuijpers (32)	2013	300	65	-	16
Jarvinen (1)	2014	87	69	-	NA

NA – non addressed, †52% appendiceal and 36% ovarian cancer, \*4-year survival

vival for the patients without recurrence, those with re-done surgery and with recurrence 91%, 79% and 65% respectively (33).

To our knowledge there is only one study reporting long-term results after surgical treatment without HIPEC (34). Complete CRS was performed in 21/25 patients with 5-year survival 92% for adenomucinosis and 33% for adenocarcinoma.

plete CRS or debulking surgery and younger vs. older age.

The complications of CRS/HIPEC are frequent and vary between 16% and 45% with mortality of 2-4% (1,3,18,25,30,34). EES-3 operations are associated with higher complication rate (38% vs. 16%) (34). Major surgical complications include stomach or bowel perforation (22%), enteric fistulas (13-29%),



*Table 4. Influence of tumor grade and completeness of cytoreduction on 5-year survival*

Author	Low grade, %	High grade, %	Author	Complete CRS	Incomplete CRS
Sugarbaker (19)	80	28	Piso (20)	92	40
Wheeler (33)	92	33	Miner (35)	12.8 ys	4.2 ys
Miner (35)	12.8 ys	4 ys	Sugarbaker (19)	86	20
Baratti (24)	80	30	Glehen (13)	-	15
Misdraji (22)	86	44	Andreasson (29)	94	28
†Glehen (13)	2.5 ys	1.3 ys	Chua (30)	91	33
Chua (30)	82	50			

†This series includes only cases with incomplete cytoreduction

anastomotic leak (19%), compartment syndrome (19%), bleeding (18%). Prolonged bowel paresis occurs in almost all patients. Re-operation rates for complications range from 11% to 21% with mortality rates 0-14% (3). The anastomotic leak is the most common cause of death (32). Systemic complications include pulmonary embolism, cardiovascular, neurological, hematological and gastrointestinal toxicity (13).

## CONCLUSIONS

PMP is a rare disease with a slow but progressive course leading to death. According to the literature PMP encompasses a wide variety of conditions. To avoid the confusion and to facilitate the treatment and comparison of the results several authors suggested that the term "PMP" should include only the cases with an appendiceal origin. The tumor grade and the completeness of cytoreduction are the main prognostic factors.

Despite the high complication rate, the cytoreductive surgery with HIPEC remains the optimal treatment. Due to the rarity of the condition most of the surgeons are not experienced enough to manage these patients. Additionally, the incomplete cytoreduction is associated with poorer prognosis and significantly hampers the subsequent interventions. Thus, in the cases when it is found incidentally, the best strategy is the taking of biopsy, appendectomy and subsequent referral to a specialized center for a treatment by multidisciplinary team.

## ACKNOWLEDGMENTS

*This work is devoted to the memory of Dr. Angel Stefanov who succumbed to this disease.*

## CONSENT

*Written informed consent was obtained from the patient for publication of this case report and any accompanying images. For the patient who died written consent was obtained from his son, who is the first author of this manuscript.*

## DISCLOSURE

*The present work will be presented at 20<sup>th</sup> Congress of Balkan Military Committee held in Thessaloniki, Greece on 8-11 June, 2015.*

## CONFLICT OF INTEREST

*The authors report no conflict of interest.*

## REFERENCES

1. Jarvinen P. Diagnosis and treatment of pseudomyxoma peritonei. PhD Thesis, 2014, Helsinki, Finland.
2. Smeenk RM, van Velthuisen ML, Verwaal VJ, Zoetmulder FA. Appendiceal neoplasms and pseudomyxoma peritonei: a population based study. *Eur. J. Surg. Oncol.* 2008; 34(2):196-201.
3. Bevan K, Mohamed F, Moran B. Pseudomyxoma peritonei. *World J. Gastrointest. Oncol.* 201; 2(1):44-50.
4. Ronnett BM, Yan H, Kurman RJ, Shmookler BM, Wu L, Sugarbaker PH. Patients with pseudomyxoma peritonei associated with disseminated peritoneal adenomucinosis have a significantly more favourable prognosis than patients with peritoneal mucinosis carcinomatosis. *Cancer* 2001; 92:85-91.

5. Sugarbaker PH. Appendiceal epithelial neoplasms and pseudomyxoma peritonei, a distinct clinical entity with distinct treatments. *Polski Przegląd Chir.* 2007; 79(9):618-28.
6. Ronnet BM, Kurman RJ, Zahn CM, Shmookler BM, Jablonski KA, Kass ME, Sugarbaker PH. Pseudomyxoma peritonei in women: a clinicopathologic analysis of 30 cases with emphasis on site of origin, prognosis, and relationship to ovarian mucinous tumors of low malignant potential. *Hum. Pathol.* 1995; 26:509-24.
7. Szych C, Staebler A, Connolly D, Wu R, Cho KR, Ronnett BM. Molecular genetic evidence supporting the clonality and appendiceal origin of Pseudomyxoma peritonei in women. *The Am. J. Pathol.* 1999; 154(6):1849-55.
8. Mukherjee A, Parvaiz A, Cecil T, Moran B. Pseudomyxoma peritonei usually originates from the appendix: a review of the evidence. *Eur. J. Gynecol. Oncol.* 2004; 25(4):411-14.
9. Ronnet BM, Zahn CM, Kurman RJ, Sugarbaker PH, Shmookler BM. Disseminated peritoneal adenomucinosis and peritoneal mucinous carcinomatosis. A clinicopathologic analysis of 109 cases with emphasis on distinguishing pathologic features, site of origin, prognosis, and relationship to 'pseudomyxoma peritonei'. *Am. J. Surg. Pathol.* 1995; 19:1390-1408.
10. Carr N. In: WHO Classification of Tumours of the Digestive System. 4<sup>th</sup> Edn; 2010:122-124.
11. Sulkin T, O'Neill H, Amin A, Moran B. CT in pseudomyxoma peritonei: a review of 17 cases. *Clin. Radiol.* 2002; 57:608-13.
12. Van Ruth S, Hart AA, Bonfrer JM, Verwaal VJ, Zoetmulder FA. Prognostic value of baseline and serial carcinoembryonic antigen and carbohydrate antigen, 19.9 measurements in patients with pseudomyxoma peritonei treated with cytoreduction and hyperthermic intraperitoneal chemotherapy. *Ann. Surg. Oncol.* 2002; 9:961-7.
13. Glehen O, Mohamed F, Sugarbaker P. Incomplete cytoreduction in 174 patients with peritoneal carcinomatosis from appendiceal malignancy. *Ann. Surg.* 2004; 240:278-85.
14. Stephens A, Alderman R, Chang D, et al. Morbidity and mortality analysis of 200 treatments with cytoreductive surgery and hyperthermic intraoperative intraperitoneal chemotherapy using the coliseum technique. *Ann. Surg. Oncol.* 1999; 6(8):790-6.
15. Elias D, Bonnay M, Puizillou J, et al. Heat-ed intraoperative intraperitoneal oxaliplatin after complete resection of peritoneal carcinomatosis: pharmacokinetics and tissue distribution. *Ann. Oncol.* 2002; 13(2):267-72.
16. Elias D, Honore C, Ciuchendea R, et al. Peritoneal pseudomyxoma: results of a systematic policy of complete cytoreductive surgery and hyperthermic intraperitoneal chemotherapy. *Br. J. Surg.* 2008. 95(9):1164-71.
17. Smith J, Kemeny N, Caldwell C, Banner P, Sigurdson E, Huvos A. Pseudomyxoma peritonei of appendiceal origin. The Memorial Sloan-Kettering Cancer Center experience. *Cancer* 1992; 70:396-401.
18. Gough D, Donohue J, Schutt A, Gonchoroff N, Goeliner JR, Wilson TO, et al. Pseudomyxoma peritonei. Long-term patient survival with an aggressive regional approach. *Ann. Surg.* 1994; 219(2):112-9.
19. Sugarbaker P, Chang D: Results of treatment of 385 patients with peritoneal surface spread of appendiceal malignancy. *Ann. Surg. Oncol.* 1999; 6:727-31.
20. Piso P, Bektas H, Werner U, Schlitt HJ, Kubicka S, Bornscheuer A, et al. Improved prognosis following peritonectomy procedures and hyperthermic intraperitoneal chemotherapy for peritoneal carcinomatosis from appendiceal carcinoma. *EJSO* 2001; 27:286-90.
21. van Ruth S, Acherman Y, van de Vijver M, Hart AA, Verwaal VJ, Zoetmulder FA. Pseudomyxoma peritonei: a review of 62 cases. *Eur. J. Surg. Oncol.* 2003; 29:682-8.
22. Misdraji J, Yantiss R, Graeme-Cook F, Graeme-Cook FM, Balis UJ, Young RH. Appendiceal mucinous neoplasms: a clinicopathologic analysis of 107 cases. *Am. J. Surg. Pathol.* 2003; 27:1089-103.
23. Guner Z, Schmidt U, Dahlke M, Schlitt HJ, Klempnauer J, Piso P. Cytoreductive surgery and intraperitoneal chemotherapy for pseudomyxoma peritonei. *Int. J. Colorectal Dis.* 2005; 20(2):155-60.
24. Baratti D, Kusamura S, Nonaka D, Langer M, Andreola S, Favaro M, et al. Pseudomyxoma peritonei: clinical pathological and biological prognostic factors in patients treated with cytoreductive surgery and hyperthermic intraperitoneal chemotherapy (HIPEC). *Ann. Surg. Oncol.* 2007; 15(2):526-34.

25. Vaira M, Cioppa T, de Marco G, Bing C, D'Amico S, D'Alessandro M, et al. Management of pseudomyxoma peritonei by Cytoreduction+HIPEC (Hyperthermic Intraperitoneal Chemotherapy): results analysis of a twelve-year experience. *In vivo* 2009; 23:639-44.
26. Elias D, Gilly F, Quenet F, Bereder JM, Sideris L, Mansvelt B, et al. Pseudomyxoma peritonei: a French multicentric study of 301 patients treated with cytoreductive surgery and intraperitoneal chemotherapy. *Eur. J. Surg. Oncol.* 2010; 36(5):456-62.
27. Youssef H, Newman C, Chandrakumaran K, Mohamed F, Cecil TD, Moran BJ. Operative findings, early complications, and long-term survival in 456 patients with pseudomyxoma peritonei syndrome of appendiceal origin. *Dis. Col. Rectum* 2011; 54(3):293-99.
28. Andreasson H, Graf W, Nygren P, Glimelius B, Mahteme H. Outcome difference between debulking surgery and cytoreductive surgery in patients with pseudomyxoma peritonei. *Eur. J. Surg. Oncol.* 2012; 38(10):962-968.
29. Sorensen O, Flatmark K, Reed W, Wiig JN, Dueland S, Giercksky KE, et al. Evaluation of complete cytoreductive surgery and two intraperitoneal chemotherapy techniques in pseudomyxoma peritonei. *Eur. J. Surg. Oncol.* 2012; 38(10):969-76.
30. Chua T, Moran B, Sugarbaker P, Levien EA, Glehen O, Gilly FN, et al. Early- and long-term outcome data of patients with pseudomyxoma peritonei from appendiceal origin treated by a strategy of cytoreductive surgery and hyperthermic intraperitoneal chemotherapy. *J. Clin. Oncol.* 2012; 30(20):2449-56.
31. Iversen L, Rasmussen P, Hageman-Madsen R, Laurberg S. Cytoreductive surgery and hyperthermic intraperitoneal chemotherapy for peritoneal carcinomatosis: the Danish experience. *Colorectal Dis.* 2013; 15(7):365-72.
32. Kuijpers A, Mirck B, Aalbers A, Nienhuijs SW, de Hingh I, Wiezer M, et al. Cytoreduction and HIPEC in the Netherlands: Nationwide Long-term Outcome Following Dutch Protocol. *Ann. Surg. Oncol.* 2013; 20:4224-30.
33. Lord AC, Shihab O, Chandrakumaran K, Mohamed F, Cecil TD, Moran BJ. Recurrence and outcome after complete tumour removal and hyperthermic intraperitoneal chemotherapy in 612 patients with pseudomyxoma peritonei from perforated appendiceal mucinous tumours. *Eur. J. Surg. Oncol.* 2015; 41(3):396-9.
34. Wheeler B, Reddy S, Kenwright D, Keating JP. Treating pseudomyxoma peritonei without heated intraperitoneal chemoradiotherapy – a first look in New Zealand. *NZMJ* 2014; 127(1389):31-39.
35. Miner T, Shia J, Jaques D, Klimstra D, Brennan M, Coit D. Long-term survival following treatment of pseudomyxoma peritonei. *Ann. Surg.* 2005; 241:300-8.