

CLINICAL, INSTRUMENTAL AND IMMUNOLOGICAL FOLLOW-UP OF PATIENTS WITH BRAIN TUMORS

A. Kaprelyan, N. Deleva, N. Dimitrov¹, K. Metodiev²

Clinic of Neurology, ¹Clinic of Neurosurgery, ²Department of Microbiology, Prof. Paraskev Stoyanov Medical University of Varna

ABSTRACT

Dynamic assessment of 66 patients with different brain tumours was carried out. The clinical, immunological and instrumental (electrophysiological and neuroimaging) follow-up included three groups of cases with stable clinical course, tumour progression and recurrence. Our results confirm that the changes in the functional and immune status of the patients with cerebral neoplasms as well as the alterations in the cerebral function and structure reflect the tumour development and the corresponding therapeutic behaviour. Monitoring of patients status and tumour growth provides opportunity for better disease control and prognosis.

Key words: brain tumours, clinical performance score, brain imaging, electrophysiology, immune status

According to modern epidemiological data brain tumours are characterized with increasing rate of morbidity and relatively insufficient therapeutic efficacy, especially concerning the most malignant forms (13). Their clinical picture presents with continuous progression of signs and symptoms as a result of local compression, destruction and dislocation of brain tissue and development of intracranial hypertension (2). The expansive or infiltrative tumour growth induces not only CNS structural and functional disorders (4,5,15) but also abnormalities in immune and performance status of the patients (1,3,6,11). This is the reason the combined clinical, instrumental (computed tomography - CT, electroencephalography - EEG, and brain mapping - BM) and immunological follow-up through the course of tumour progression to become a necessary condition for the early prediction of recurrence, progression or malignization and the corresponding adequate treatment (8,10,14).

The aim of the study was to dynamically assess the clinical, instrumental and immunological characteristics of patients with brain tumours in relation to the various clinical course of the disease.

MATERIAL AND METHODS

A total of 66 patients with different brain tumours diagnosed and followed-up in the Clinics of Neurology and Neurosurgery of Prof. Paraskev Stoyanov Medical University of Varna were studied from 1995 to 2003. All cases were divided into 3 groups: I - 25 with meningiomas, II - 14 with low-grade gliomas (astrocytomas gr. I-II), and III - 27

Address for correspondence:

A. Kaprelyan, Dept. of Neurology, Prof. Paraskev Stoyanov Medical University of Varna, BG-9002 Varna, 55 Marin Drinov St., Bulgaria
E-mail: arakapri@techno-link.com

with high-grade gliomas (astrocytomas gr. III and glioblastomas). Histopathological verification confirmed the diagnosis in all cases. Tumour classification and gradation was carried out according to the recommendations of the World Health Organization (7). Preoperative and postoperative (on 2, 6, 12, 18 and 24 months) follow-up included: evaluation of patient's functional status by Karnofsky index of performance status (KFS) (score from 0 to 100); electrophysiological (EEG and BM) and CT studies and assessment of immunological status (lysozyme activity in serum by Zucker-Elliot, macrophage activity by NBT test, leukocyte count, B-lymphocyte and T-lymphocyte counts, T-h and T-s by Shore, T-h/T-s index and mitochondrial enzymes SDH and α -GPDH). All these immunological indices were compared to the values of 30 healthy controls. The correlative analysis between each patient brain maps and the maps of controls was performed by means of programmed Z score.

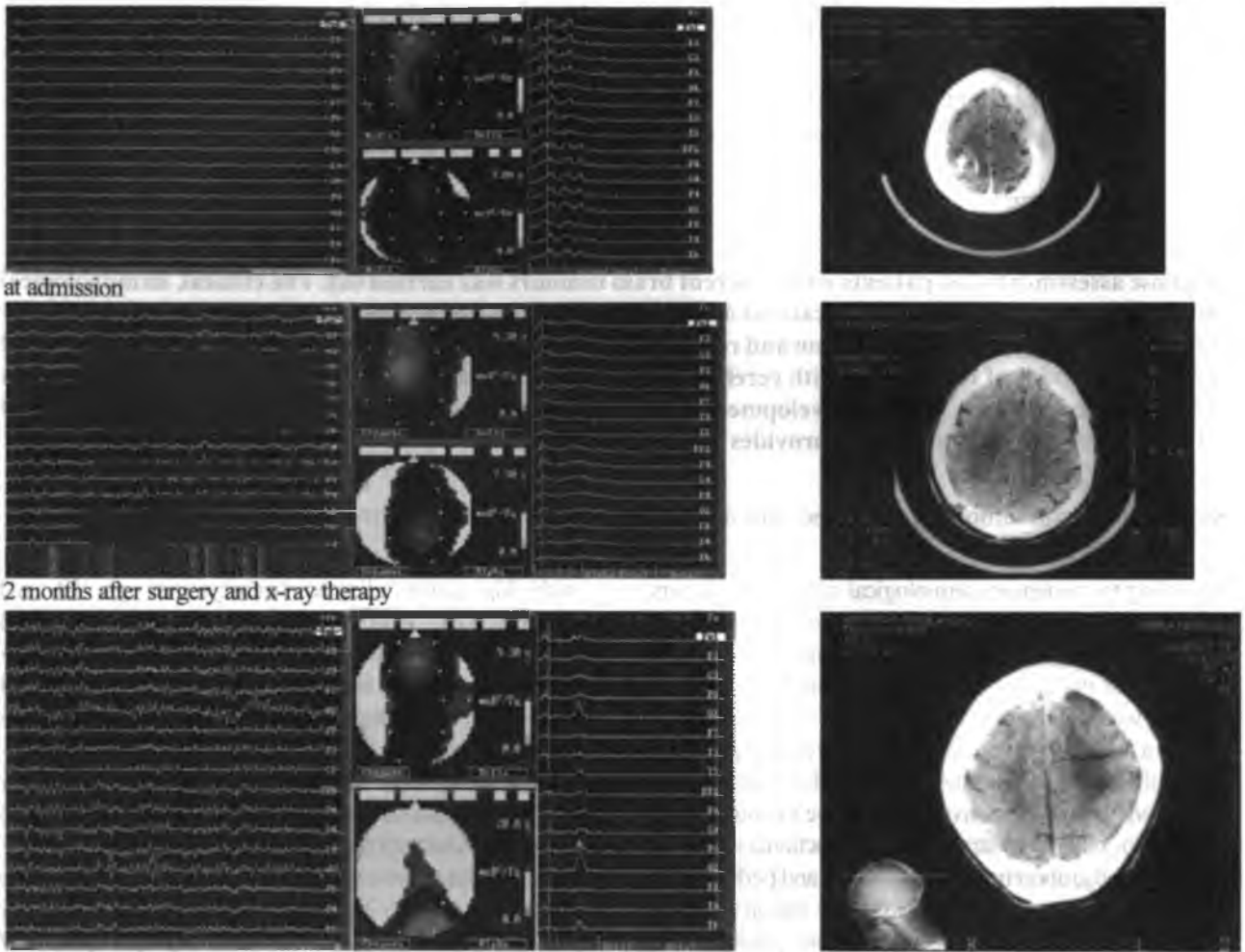
RESULTS AND DISCUSSION

In all the cases without recurrence and tumour progression (24 patients from group I and group II) the dynamic clinical examination showed reduction of focal and common cerebral neurological deficit in the postoperative period (2 and 6 months) and elevation of the initial values of KPS index. The parallel postoperative CT, EEG, and BM studies confirmed the reduction of tumour mass and cerebral edema presenting on EEG records with decrease in slow-wave activity and appearance of focal limited delta and theta fluctuations over the zone of the pathological process. The postoperative assessment of immune status after 2 and 6 months outlined a gradual normalization of the examined immunological parameters. Patients' follow-up expressed on 24 month the same tendencies: elevation of Karnofsky score

(up to 70) in correlation to the recovery of neurological deficit, normalization of the immunological parameters, CT

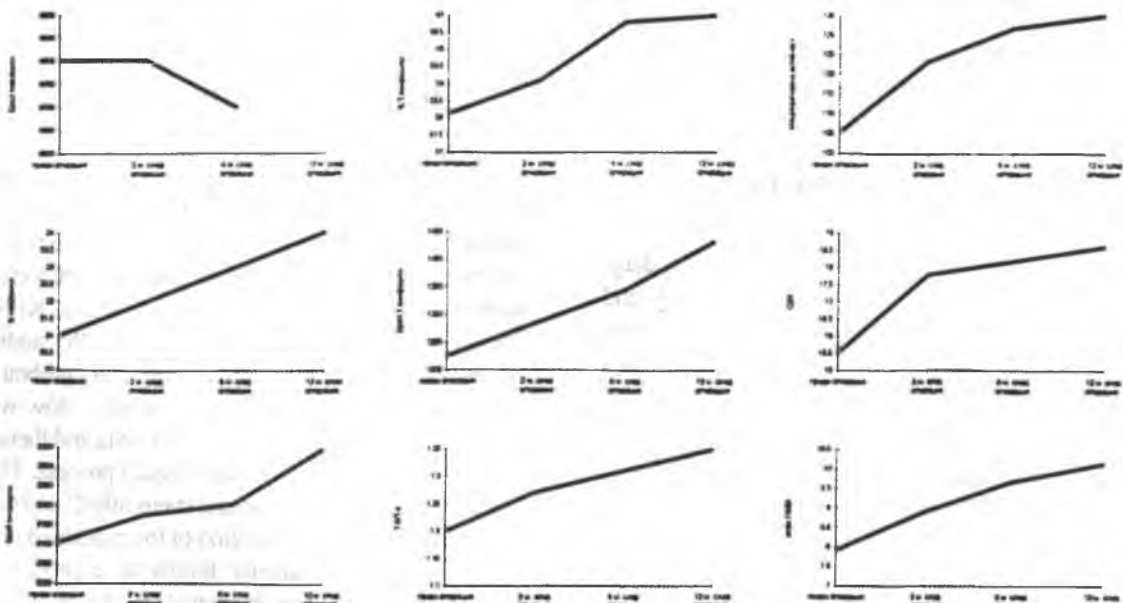
data confirming the clinical course of the disease (lack of tumour relapse and progression) and normalization of

Case 1. Low grade astrocytoma. Pre- and postoperative CT, EEG and BM study

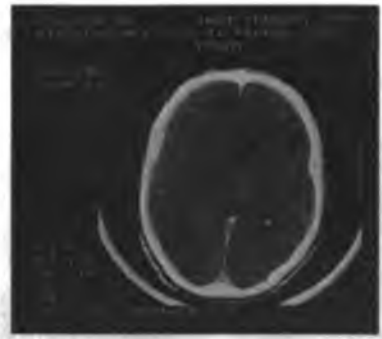
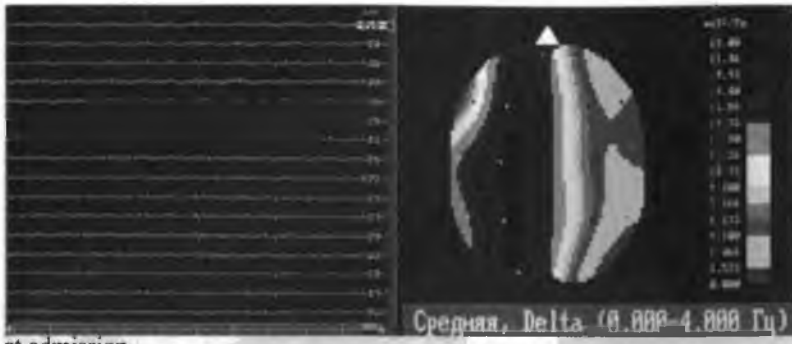
12 months after surgery and x-ray therapy

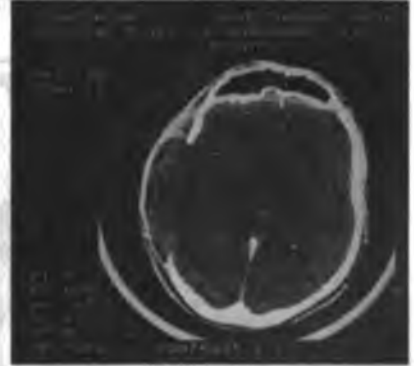
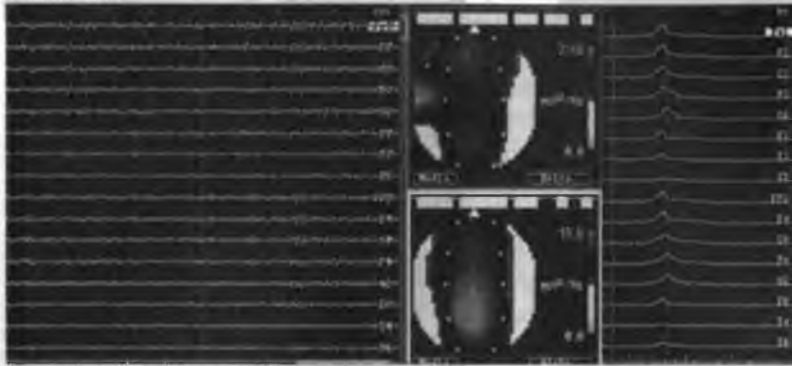
Immunological monitoring of leukocytes, T-lymphocytes, T-h/Ts ratio, macrophage activity and mitochondrial enzyme activity (SDH, alpha- GPDH)



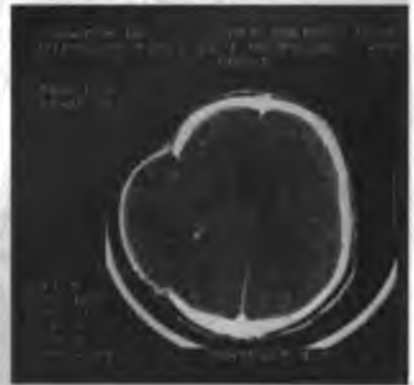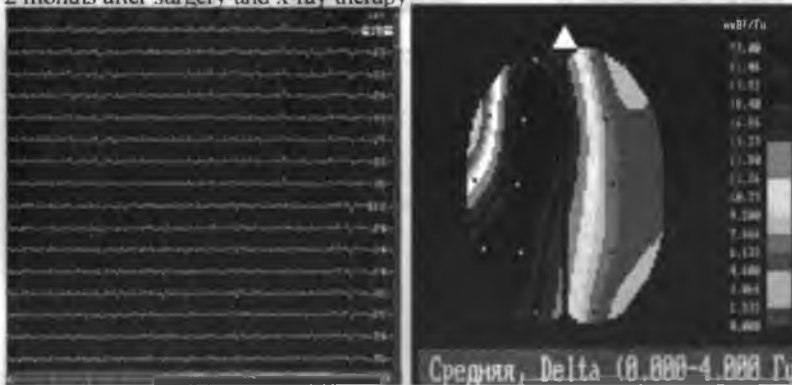
Case 2. Anaplastic astrocytoma. Pre- and postoperative CT, EEG and BM study.



at admission




2 months after surgery and x-ray therapy

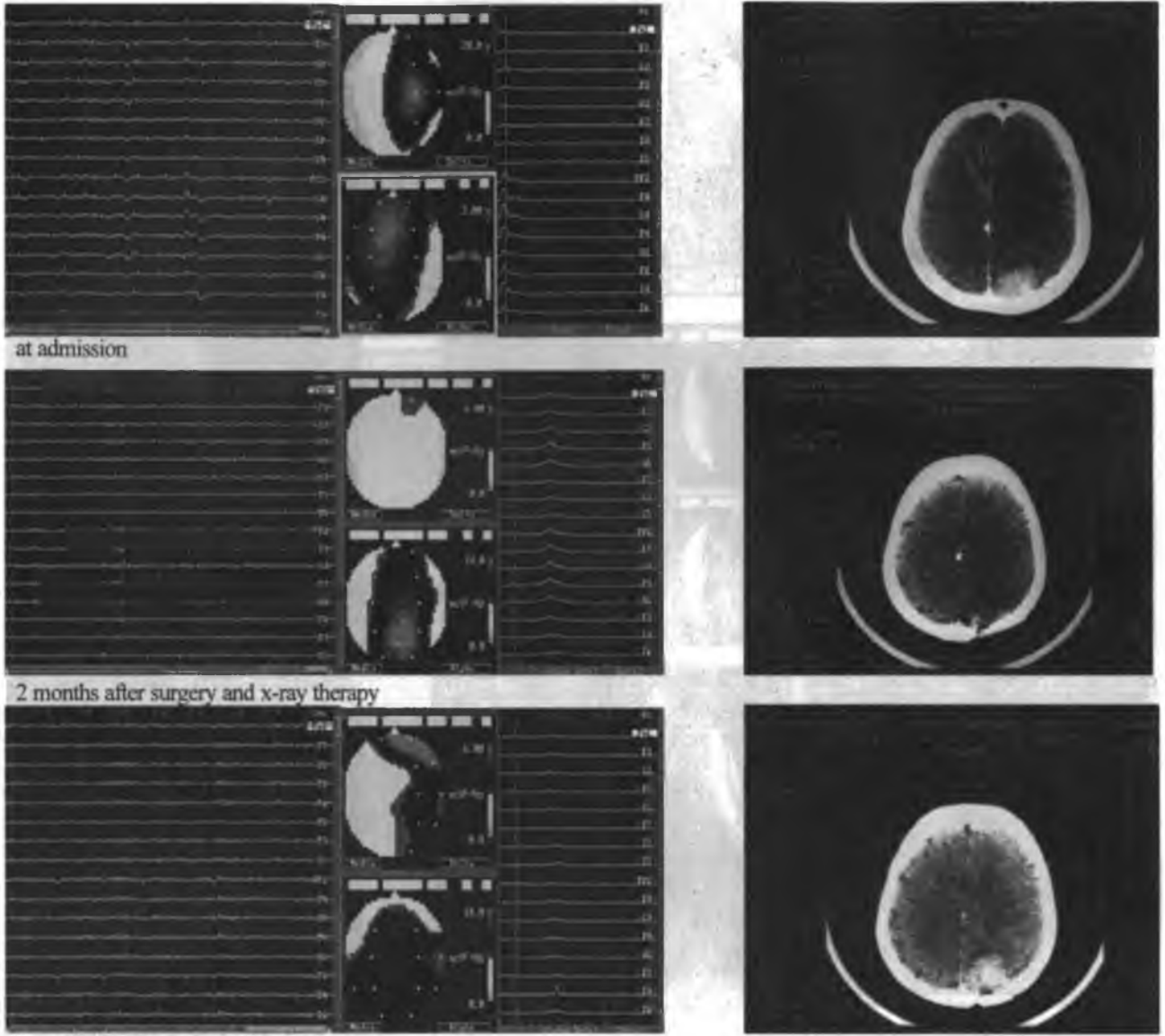


12 months after surgery and x-ray therapy

Immunological monitoring of leukocytes, T-lymphocytes, T-h/Ts ratio, macrophage activity and mitochondrial enzyme activity (SDH, alpha-GPDH)




Case 3. Recurrent meningioma. Pre- and postoperative CT, EEG and BM study



12 months after surgery and x-ray therapy

Immunological monitoring of leukocytes, T-lymphocytes, T-h/Ts ratio, macrophage activity and mitochondrial enzyme activity (SDH, alpha- GPDH)



bioelectrical cerebral activity on the control EEG records (Clinical case 1).

The early postoperative period of patients with tumour progression (a total of 23 cases from group III) presented with slight elevation of KPS as a result of tumour mass and edema reduction and values of immune indices closer to the initial ones. The control CT scans showed partial reduction of tumour burden, brain edema and dislocation phenomena. EEG registered decrease of the diffuse slow-wave activity. The follow-up of patients with tumour progression demonstrated tendencies of decreasing Karnofsky score (under 40), data of continuing intensifying immunosuppression, CT images confirming tumour and edema progression and EEG records presenting with elevation of diffuse slow-wave activity (Clinical case 2).

Patients with recurrent tumours (6 cases from group I, 5 from group II and 8 from group III) demonstrated initial postoperative improvement of KPS and the immune status indices. CT and EEG (reduction of the common cerebral disorders with underlining of the focal slow-wave activity) data reflected the primary tumour resection and the decrease of brain edema. The consequent worsening of the neurological deficit with decrease of Karnofsky score and EEG records expressing a well defined pathological focus showed coincidence with the CT scans presenting tumour recurrence and the indices of repeated immune suppression (Clinical case 3).

It is known that cerebral neoplasms with infiltrative or expansive growth can cause different focal and common clinical signs, produce cerebral edema, destruction and dislocation phenomena and provoke a broad immune suppression (2,4,5,6,15). According to the literature available (8,10,14) the isolated or combined clinical, instrumental and immunological follow-up of patients with different brain neoplasms provides evidence that reflects the clinical course of tumour development (stable, progressive, or recurrent). Patients with stable clinical course present with improvement of functional and immune status as well as with CT and EEG data confirming the tumour and edema reduction. The cases with progression of the disease show further worsening of the functional status and continuing immune suppression (1) parallelly to the electrophysiological (9,14) and neuroimaging data of tumour progression. The postoperative control of the patients with recurrent tumours demonstrates initial improvement of their status followed by repeated worsening of the clinical, immunological, CT and EEG parameters as a result of a new neoplasm growth. All these results (3,8,10,14) present evidence that the dynamic assessment of clinical and immune status of the patients along with the detection of functional and structural cerebral damages may be an important tool enabling the precise diagnosis and the correct therapeutic behaviour in the different phases of the neoplastic process.

CONCLUSION

Our study demonstrates the possible clinical benefit of the complex clinical, instrumental and immunological monitoring as a real opportunity for a dynamic assessment of patients with brain tumours in relation to the disease control and prognosis.

REFERENCES

1. Руденко В. А., Н. И. Лисяный, А. А. Радзиевский. Субпопуляции лимфоцитов и их функциональная активность у больных с опухолями головного мозга.- *Врач. дело*, 1990, № 9, 91-94.
2. Adams, R., V. Maurice. Intracranial neoplasms.- In: *Principles of Neurology*. 5. ed. R. Adams, V. Maurice, eds. McGraw-Hill, 1993, 554-597.
3. Dauch, W. A., D. Krex, J. Heymanns, B. Zeithammer, P. L. Bauer. Peri-operative changes of cellular and humoral components of immunity with brain tumour surgery.- *Acta Neurochir. (Wien)*, 126, 1994, No 2-4, 93-101.
4. Dolisi, C., G. Suisse, E. Delpont. Quantitative EEG abnormalities and asymmetries in patients with intracranial tumors.- *Electroencephalogr. Clin. Neurophysiol.*, 76, 1990, No 1, 13-18.
5. Harmony, T., A. Fernandez-Bouzas, E. Marosi, T. Fernandez, J. Bernal, M. Rodrigues, A. Reyes, J. Silva, G. Casian. Correlation between computed tomography and voltage and current source density spectral EEG parameters in patients with brain lesions.- *Electroencephalogr. Clin. Neurophysiol.*, 87, 1993, No 4, 196-205.
6. Karnofsky, D. A. Karnofsky Index of Performance Status (KPS).- *Cancer*, 1, 1948, 634.
7. Kleihues, P., P. C. Burger, B. W. Scheithauer. The new WHO classification of brain tumors.- *Brain Pathol.*, 3, 1993, No 3, 255-268.
8. Lillehei, K. O., D. H. Mitchell, S. D. Johnson, E. L. McCleary, C. A. Cruse. Long-term follow-up of patients with recurrent malignant gliomas treated with adjuvant adoptive immunotherapy.- *Neurosurgery*, 28, 1991, No 1, 16-23.
9. Logar, C., W. Freidi, H. Lechner. A comparison of EEG mapping with and without visual artifact control in focal cerebral lesions.- *EEG EMG Z Electroencephalogr., Electromyogr. Verwandte Geb.*, 23, 1992, No 2, 101-104.
10. Loisean, H. Prognosis of gliomas.- *Rev. Neurol.*, 152, 1996, No 2, 84-102.
11. Matsuhisa, T. Subset analysis of tumor infiltrating lymphocytes and peripheral blood lymphocytes in malignant glioma patients.- *No To Shinkei*, 47, 1995, No 5, 466-473.
12. Newer, M. R. Quantitative EEG. II. Frequency analysis and topographic mapping in clinical settings.- *J. Clin. Neurophysiol.*, 5, 1988, 63-65.
13. Preston-Martin, S. Epidemiology of primary CNS neoplasms.- *Neurol. Clin.*, 14, 1996, No 2, 273-290.

14. Szuwart, U., S. A. Qaiyumi, H. Bennefeld, M. Weinel. Follow-up EEG analysis as a diagnostic instrument in the after-care of patients with astrocytoma.- *Nervenarzt*, **60**, 1989, No 1, 55-60.

15. Wendt, U., F. Hentschel. Correlation of morphologic findings (CT) with clinical and relevant EEG findings in adult epileptics.- *Psychiatr. Neurol. med. Psychol.*, **42**, 1990, No 7, 418-425.