

## DIAGNOSTIC PROBLEMS AND THERAPEUTIC BEHAVIOUR IN CHILDREN WITH NEUROBLASTOMA

V. Kaleva, S. Kertikova, V. Tzaneva, D. Radeva

**Key-words:** neuroblastoma — diagnosis — treatment — prognosis — children

Neuroblastoma is an embryonal tumour originating from stem cells of the sympathetic nervous system and adrenal medulla. That is why it is numbered among neoplasms of the nervous and endocrine system as well. It is the most frequent solid malignant tumour in childhood and presents at the average 6 — 10 per cent of all the malignant neoplasms in children (2, 6, 8). Recently, its increasing incidence rate as well as difficulties for early diagnosis and timely treatment pose the problem of this neoplastic process in the centre of the attention of all the oncohaematological departments in our country and in the world.

The aim of the present work is to systematize our own experience with the clinical specificity, diagnostic problem and therapeutic behaviour in children with neuroblastoma.

### Material and methods

Case records of 21 children hospitalized in the Pediatric Clinic, Higher Institute of Medicine, Varna, for a 10-year period with a diagnosis of neuroblastoma were retrospectively analyzed. Patients' distribution according to sex is almost equal: 11 girls (52 per cent) towards 10 boys (48 per cent). 14 children are in the age group up to 4 years (67 per cent), 2 ones are in the age group between 5 and 8 years (10 per cent) and 5 ones (23 per cent) are 5 years old. Cases with intraabdominal localization predominate — a total of 17 children. Neuroblastoma originates from the right adrenal gland in 8 cases (38 per cent), from the left one in 2 (9 per cent), from paravertebral ganglia in 3 (15 per cent) but its localization is not specified in 4 cases (20 per cent). Two cases (9 per cent) are of mediastinal origin and another two (9 per cent) with unspecified localization.

Children's distribution according to clinical stages is done after the classification of Evans et al. (1971). All the children were admitted to hospital in an advanced phase of the disease: 16 children (76 per cent) were in the fourth and 5 ones (24 per cent) in the third phase. Histological biopsies (intraoperatively or post-mortem) were performed in 13 patients. Neuroblastoma was the only one histological result (in 100 per cent of the cases).

### Results and discussion

Clinical symptomatics is determined by localization and size of primary tumour and by metastatic dissemination. Anemia dominates in the clinical picture in all the cases. Anemic syndrom is persistent and precedes the rest

symptoms of the illness for a long period of time. Febrility is observed in 18 children, abdominal pain with intraabdominal localization — in 15, appetite loss — in 15, polyadenopathia — in 14, palpebral oedema with haematoma — in 9 (fig. 1, 2); hepatomegalia — in 9, headache, diarrhoe and bone pains — in 7 each, exophthalmus 6 (fig. 1, 2), subcutaneous lesions (fig. 2), palpable tu-

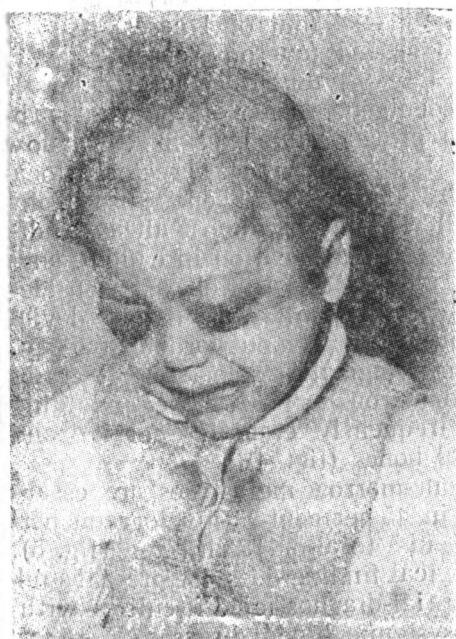

Fig. 1. Palpebral oedema with haematoma, exophthalmus.

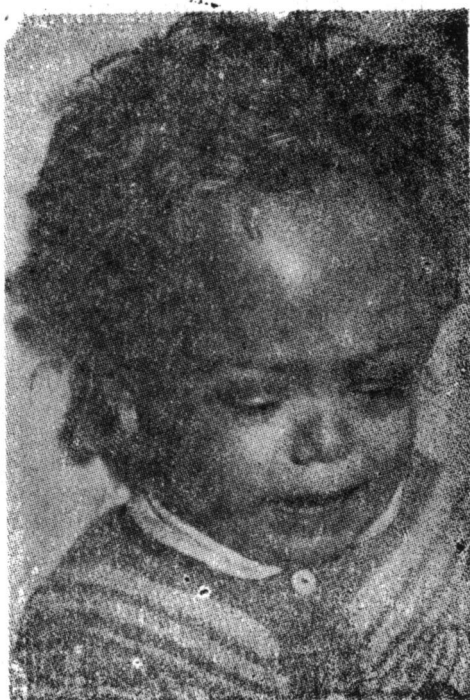

Fig. 2. Subcutaneous metastatic lesion.

meur in the abdomen — in 4 each, syndrome of radiculitis — in 3, exanthema — in 2, pareses, obstipation and icterus — in one case each.

Concerning routine laboratory examinations, it stresses that there is a persistent anemia of hypochromic type as well as ESR elevation. Biochemical and other examinations of the peripheral and venous blood did not indicate any significant abnormalities. We present the number of positive results from the examinations by means of all the methods applied in our study of different number of patients in order to reveal the diagnostic possibilities for every single method:

**Roentgenologic examination:**

mediastinum	— 1
whole abdomen	— 2
bone metastases	— 6 (out of 17 cases)
venous urography	— 12 (out of 17 cases)
<b>Echoscropy of the abdomen:</b>	
tumour	— 10 (out of 17 cases)

liver and lymph node metastases	— 9
Urinary metabolites (vanillo-mandellic acid and homo-vanillic acid)	— 3
Myelogram:	
metastases	— 8
reactive changes	— 10
Fine-needle aspiration biopsy:	
lymph nodes	— 2 (out of 5 cases)
subcutaneous lesion	— 4 (out of 4 cases)
liver	— 1 (out of 1 case)
bone lesion	— 1 (out of 1 case).

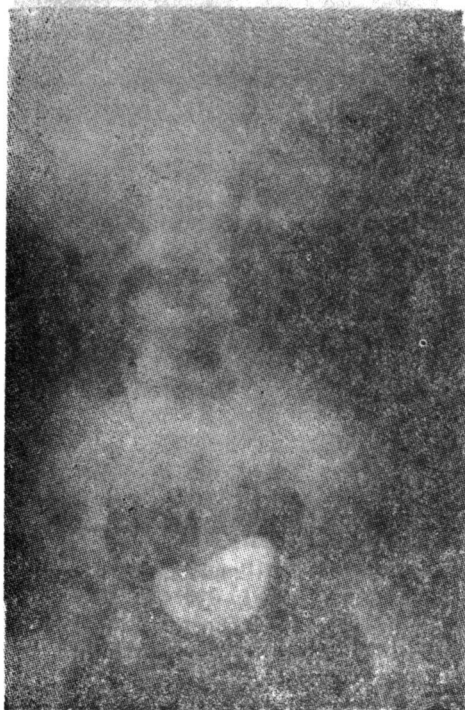

Fig. 3. Venous urography — the right kidney is dislocated in external and caudal direction by neuroblastoma originating from the corresponding adrenal gland.

Roentgenography of the whole abdomen proves seldom a tumour shadow which is later on more precisely localized by echoscopy and venous urography (fig. 3). The latter almost always indicates a renal dislocation in caudal and lateral direction as well as a considerable deformation, rotation and deviation of ureters with outwards convexity. Roentgenologically, bone metastases show numerous osteolytic foci involving most frequently cranial, pelvic and femoral bones (fig. 4).

Bone-marrow metastases are established in 45 per cent of myelograms performed in a total of 18 children (fig. 5). Cytological finding does not present and differential-diagnostic difficulties with other systemic blood diseases.

Fine-needle aspiration biopsy has been introduced as a routine method for examination of peripheral lesions and enlarged lymph nodes since 1987. Despite the small number of investigations the results obtained confirm its diagnostic importance and role for clinical stage determination (fig. 6) (9, 10).

A complex treatment: surgical elimination of the tumour, radiation therapy and chemotherapy is carried out in 4 patients only. Three of them are in the

third and one in the fourth stage of the illness. Only chemotherapy is administered in 5 children in the fourth stage but combination of chemotherapy and radiation therapy in 2 children in the third and 10 children in the fourth stage. Therapeutic behaviour is conformed to the clinical stage at the first place as well as to the age of the child, primary tumour size and localization and metastases (4, 7). A triple combination of cyclophosphamide (at a doses of 10 mg/kg b. w.), vincristine (1.5 mg/m<sup>2</sup>) and adriamycine (60 mg/m<sup>2</sup>) was applied. A total radiation dosage of 15 — 60 Gry was realized.

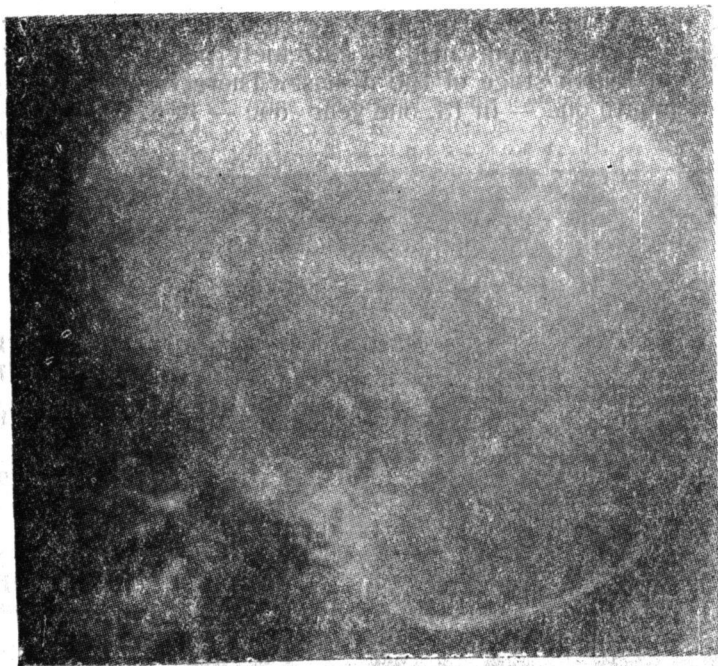

Fig. 4. Cranial metastases of osteolytic type.

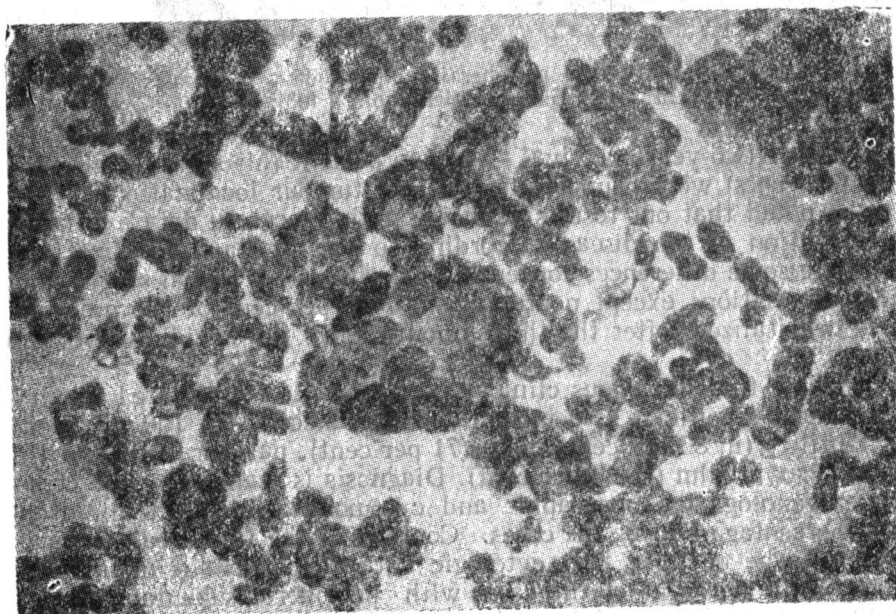


Fig. 5. Myelogram — metastasis of well-differentiated neuroblastoma with rosette-like structure (Stain after Giemsa, Microphoto x 400).

Prognosis depending mainly on the clinical stage, age, primary tumour localization and histological result is confirmed as extremely poor concerning the patients in the third and fourth stage of the disease. There is a 3-month survival in 19 children, a 6-month one — in 13, one year — in 8, 18-month

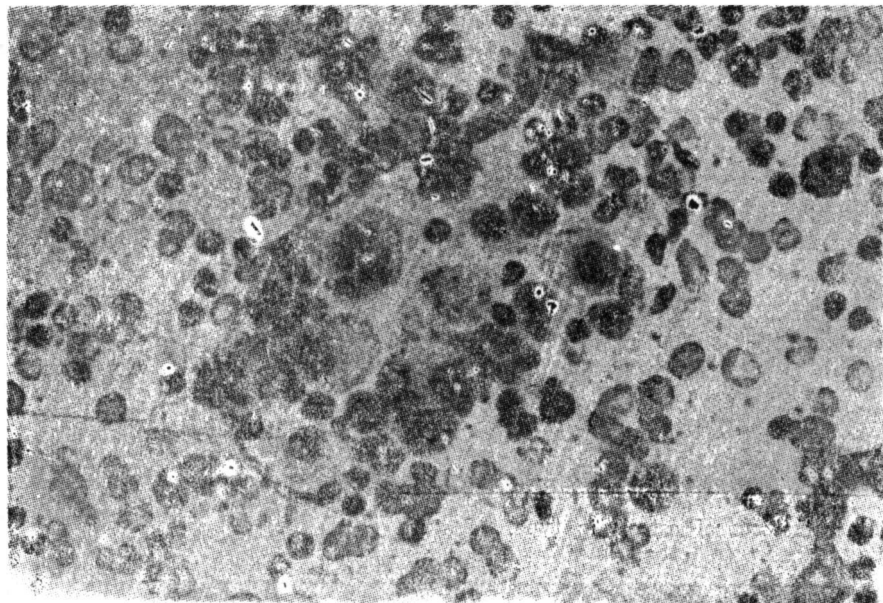


Fig. 6. Fine-needle aspiration biopsy of a peripheral lymph node — metastasis of well-differentiated neuroblastoma (Stain after Giemsa Microphoto x 400).

one — in 4, and over two-years survival — in one patient (his survival already is longer than 10 years) with primary mediastinal tumour localization.

It has to be noted that our results coincide with literature data available about the distribution of the disease according to sex, age and localization. However, there are some differences concerning the absence of initial stages and other histological variations except neuroblastoma. 90 per cent of the patients are rather late hospitalized (after the third month since the initial symptoms) (1 — 3, 5).

We can conclude that analogous clinical symptomatology is presented in any patients. The highest specificity is demonstrated by: anemia (in 100 per cent of the cases), febrility (in 85 per cent), pain (71 per cent), palpebral oedema (in 43 per cent) and exophthalm (in 28 per cent). Diagnosis is realized by the combination of roentgenological, sonographic and cytomorphological examination in the greatest percentage (75) of the cases. Concerning the fine-needle aspiration biopsy it is to be outlined that cytologic data about distant metastases are established in 100 per cent of the cases with peripheral subcutaneous lesions and in 40 per cent of the peripheral lymph nodes. Combination of chemotherapy and radiation therapy is the most frequently used therapeutic approach (in 55 per cent of the cases) in conformity with the clinical stage of the disease.

## REFERENCES

1. Бобев, Д., М. Каменова, И. Христовова, Р. Савова, Ш. Ниньо. *Педиатрия*, 1984, № 4, 11—16.
2. Дончева, Н. Докт. дис. София, 1979.
3. Митров, Г. (ред.) Злокачественные новообразования. София, Медицина и физкультура, 1983.
4. Русева, Ц. Канд. дис. София, 1980.
5. Христовова, И. Канд. дисс. Москва, 1983.
6. Христовова, И. *Педиатрия*, 1988, № 2, 4—7.
7. Христовова, И. *Педиатрия*, 1988, № 2, 1—4.
8. Evans, A. E., G. J. D'Angio, J. Randolph. *Cancer*, 27, 1971, No 2, 374—378.
9. Miller, T. R., K. Bottles, J. S. Abele, J. H. Beckstead. *Acta Cytol.*, 29, 1985, 461—468.
10. Perikala, V., Kumar., *Acta Cytol.*, 31, 1987, No 5, 583—586.

### ДИАГНОСТИЧЕСКИЕ ПРОБЛЕМЫ И ТЕРАПЕВТИЧЕСКОЕ ПОВЕДЕНИЕ ПРИ ЛЕЧЕНИИ ДЕТЕЙ С НЕЙРОБЛАСТОМой

В. Калев, С. Курткова, В. Цанева, Д. Радева

#### РЕЗЮМЕ

Изучаются начальные проявления, клинические особенности, диагностические проблемы и терапевтическое поведение при лечении двадцати одного ребенка, лечившихся в Детской клинике при Высшем медицинском институте в Варне в течение десяти лет с диагнозом: нейробластома.

У всех детей установлена аналогическая начальная симптоматика. Клинический полиморфизм обусловлен преимущественно злокачественными метастазами, находящимися в четвертой стадии в 75% случаев, что ограничивает комплексный подход при лечении.

Диагностические проблемы связаны на первом месте с установлением первичной локализации опухоли. Обсуждается диагностическая ценность тонкоигольной аспирационной биопсии и экоскопии с целью определения клинического стадия заболевания.