

# MORPHOLOGICAL CHANGES IN THE RAT AORTA ENDOTHELIUM AT THE CLAMPING SITES AFTER SURGICAL ANASTOMOSIS

Lazar Jelev<sup>1,2</sup>, Roman Romansky<sup>3</sup>, Kouzman Guirov<sup>2</sup>, Minko Minkov<sup>4</sup>,  
Wladimir Ovtsharoff<sup>1</sup>

<sup>1</sup>*Department of Anatomy, Histology and Embryology, Medical University of Sofia*

<sup>2</sup>*Clinic of Vascular Surgery and Angiology, Military Medical Academy*

<sup>3</sup>*Department of Plastic and Reconstructive Surgery,  
Alexandrovska University Hospital, Sofia*

<sup>4</sup>*Department of Anatomy, Histology and Embryology, Medical University of Varna*

## ABSTRACT

This study aimed to investigate on en face preparations the morphological changes in the rat aorta endothelium at the clamping sites while performing surgical anastomosis.

Adult male Wistar rats (14-18-month-old, 390-420g) were used for the experiments. Under surgical anesthesia, the postrenal part of the abdominal aorta was dissected, clamped proximally and distally, cut and restored microsurgically using 10-0 suture. The clamping time was 30-40 min. At different days after surgery the animals were sacrificed, their aortas fixed and removed from the body and preparations for en face observation were made.

*En face* preparations, obtained at the first postoperative day, showed complete denudation of the clamping sites. The most interesting endothelial cell population was noted at the borders of the clamping sites on the 3rd day after surgery – a large number of small endothelial cells and also few endothelial cells having very large size. At the later stages, the endothelial cell layer advanced rapidly to the denuded areas, as the complete restoration was observed after day 14.

**Key words:** *endothelium, aorta, clamping injury, reendothelization, rat*

## INTRODUCTION

The healing process of the vessel wall after surgical incision and following suturing has

been well investigated in different experimental animals (1,8,11,12). In many of these studies the reendothelization of the incision line and the intraluminal part of the sutures were analyzed (1,5,8,11,12). During routine vascular operations, however, the vessel incision can be preceded by applying special clamps proximal and distal to the site of incision. This step can also damage the endothelial covering (2-4,8-10).

This study aimed to investigate on special *en face* preparations the morphological changes in the rat aorta endothelium at the clamping sites while performing surgical anastomosis.

---

### Address for correspondence:

Lazar Jelev

Department of Anatomy, Histology and Embryology

Medical University of Sofia

blvd. Sv. Georgi Sofiisky 1

BG-1431 Sofia, Bulgaria

tel.: +359-2-91-72-636

fax: +359-2-851-87-83

e-mail: [ljelev@abv.bg](mailto:ljelev@abv.bg)

**Received:** February 08, 2013

**Accepted:** February 25, 2013

## MATERIAL AND METHODS

Fifteen male Wistar rats (14-18-month-old, 390-420 g) were used for this study. The animals were maintained in accordance with the recommendations of the *Guide for the Care and Use of Laboratory Animals* (Washington D.C., National Academy Press, 1996) and guidelines of the Animal Care Committee of the Medical University of Sofia, Bulgaria. Under surgical anesthesia (i.p. Ketamine 45 mg/kg and Xylazine 5 mg/kg), through a midline laparotomy the postrenal part of the abdominal aorta was dissected free and microvascular steel clamps applied proximally and distally for approximately 30-40 min. The aorta was cut transversely and next anastomosed "end-to-end" microsurgically. Three animals were sacrificed at 1<sup>st</sup>, 3<sup>rd</sup>, 7<sup>th</sup>, 14<sup>th</sup>, 21<sup>st</sup> day after surgery by an overdose of Thiopental. Prefixation silver impregnation of the aortic endothelial cells was done (7). The aorta was perfusion fixed with half-strength Karnovsky solution and *en face* preparations were made (6).

## RESULTS

*En face* preparations, obtained at the first postoperative day (Fig. 1a), showed complete denudation of the clamping sites with abundant

polymorphonuclear cells infiltration and fibrin deposits (Fig. 1a).

The most interesting endothelial cell population was noted at the borders of the clamping sites on the 3<sup>rd</sup> day after surgery (Fig. 1b,c). There was a large number of small elongated endothelial cells advancing to the denuded areas now cleared away from polymorphonuclear cells and fibrin deposits. A rare finding was endothelia cells in some stages of mitotic cell division. Among the smaller cell population, few endothelial cells of very large size and multiple nuclei were also observed.

At day 7 after surgery, a population of small elongated endothelial cells nearly covered the clamped sites, but still some differences between the cells of uninjured and reendothelialized areas can be found (Fig. 2a,b). At later days, the endothelial cell gradually enlarged and become indistinguishable from the neighboring endothelial covering (Fig. 2c).

## DISCUSSION

In the literature, there are some studies investigating the vascular clamp injuries by means of arteriographic and ultrasonic evaluation (3). Several other studies paid attention on the intimal changes of the clamped vessel found under scanning electron




Fig. 1. Microphotographs of the *en face* preparations from the rat aorta. (a) Day 1 after surgery. Polymorphonuclear cells infiltration (arrows) and fibrin deposits (asterisks) at the clamping site. (b) Day 3 after surgery. Denuded clamp site (asterisks). (c) Clamp site border. Giant endothelia cell (large arrow). Small endothelia cells in mitotic cell division (small arrows). Size bars: (a) -50  $\mu\text{m}$ ; (b) - 200  $\mu\text{m}$ ; (c) - 50  $\mu\text{m}$

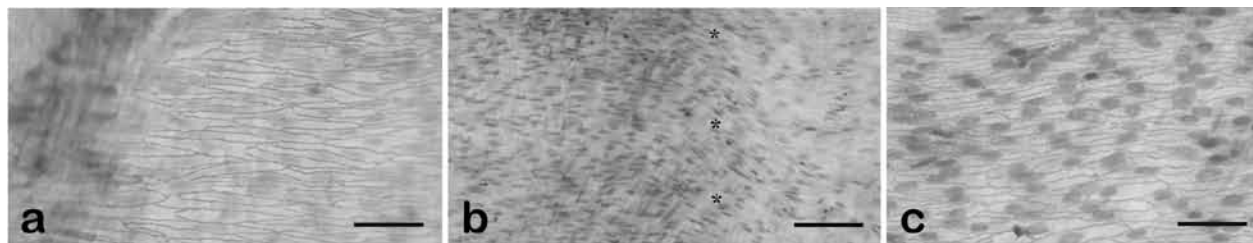


Fig. 2. Microphotographs of the *en face* preparations from the rat aorta. (a) and (b) Day 7 after surgery. Layer of small elongated endothelial cells. Asterisks show the clamp site border in (b). (c) Day 14 after surgery. Nearly normal endothelial covering of the clamping site. Size bars: (a) -50  $\mu\text{m}$ ; (b) - 100  $\mu\text{m}$ ; (c) - 50  $\mu\text{m}$

microscopy but on relatively small areas of the vessel intima (9). The process of endothelial regeneration on larger intimal areas after experimental clamping injury can be better examined on flat (*en face*) preparations from the rat aortas.

Our results showed the dynamics and mechanism of endothelial regeneration over larger denuded areas. At first, the injured clamp sites have been infiltrated with polymorphonuclear cells representing the acute inflammation phase of the process. In the next two days, the injured endothelial cells are completely removed from the intimal surface, and reendothelialization process started. There is an advancing front of endothelial cells, smaller than normal, showing signs of mitotic cell division. Among them, as a rare finding, giant multinucleated cells can also be observed. After the first week, the clamp sites are nearly completely reendothelialized but with the major population of smaller endothelial cells. For the next weeks these cells grow fast and become indistinguishable from the neighboring normal endothelial covering.

The detailed studies on the vessel wall after application of vascular clamps (2-4,8-10), including our results, have showed the potential injurious effect on the intimal layer. This intimal injury is directly proportional to the amount of pressure by a given clamp and also the application time (10). Some endothelial injury during surgical procedures can induce thrombus formation with further devastating consequences (4). Therefore, vascular clamps must be applied with extreme care bearing in mind the fragility of the endothelial layer.

## REFERENCES

1. Becquemin JP, Deleuze P, Léandri J, Lautier A, Mellièrre D. Influence of the type of arterial anastomosis on the development of endothelial hyperplasia. - *J Mal Vasc*. **9**, 1984, No 2, 90-94.
2. Bunt TJ, Manship L, Moore W. Iatrogenic vascular injury during peripheral revascularization. - *J Vasc Surg*. **2**, 1985, No 3, 491-498.
3. Coelho JC, Sigel B, Flanigan DP, Schuler JJ, Justin J, Machi J. Arteriographic and ultrasonic evaluation of vascular clamp injuries using an in vitro human experimental model. - *Surg Gynecol Obstet*. **155**, 1982, No 4, 506-512.
4. Folts J. An in vivo model of experimental arterial stenosis, intimal damage, and periodic thrombosis. - *Circulation*. **83**, 1991, No 6, IV3-14.
5. Jeleu L, Romansky R, Nachev G, Ovtsharoff W. Regeneration of the endothelium of the rat aorta after microsurgical anastomosis studied on *en face* preparations. - *Comptes rendus de l'Académie bulgare des Sciences* **62**, 2009, No 12, 1621-1624.
6. Jeleu L, Surchev L. A novel simple technique for *en face* endothelial observations using water-soluble media - 'thinned-wall' preparations. - *J Anat*. **212**, 2008, No 2, 192-197.
7. Jones GT, Martin BJ, Stehbens WE. Endothelium and elastic tears in the afferent arteries of experimental arteriovenous fistulae in rabbits. - *Int J Exp Pathol*. **73**, 1992, No 4, 405-416.
8. Mattox DE. Microvascular anastomosis: a scanning electron microscopic study. - *Otolaryngol Head Neck Surg*, **88**, 1980, 252-256.
9. Pabst TS 3<sup>rd</sup>, Flanigan DP, Buchbinder D. Reduced intimal injury to canine arteries with controlled application of vessel loops. - *J Surg Res.*, **47**, 1989, No 3, 235-241.
10. Slayback JB, Bowen WW, Hinshaw DB. Intimal injury from arterial clamps. - *Am J Surg*. **132**, 1976, No 2, 183-188.
11. Wieslander JB, Mecklenburg CV, Aberg M. Endothelialization following end-to-end and end-in-end (sleeve) microarterial anastomoses. A scanning electron microscopic study. - *Scand J Plast Reconstr Surg*, **18**, 1984, 193-199.
12. Zeebregts C, van den Dungen J, Buikema H, van der Want J, van Schilfgaarde R. Preservation of endothelial integrity and function in experimental vascular anastomosis with non-penetrating clips. - *Br J Surg*. **88**, 2001, No 9, 1201-1208.