



Indian Journal of Traditional Knowledge  
Vol 19(4), October 2020, pp 708-713



## *Kadukkai maathirai* (a polyherbal traditional siddha formulation) prevents D-galactosamine induced hepatic necrosis in rats

M Shetty<sup>a</sup>, S Shenoy<sup>b</sup>, N Kumar<sup>c,\*†</sup>, V Devi<sup>a</sup>, A Amuthan<sup>a</sup>, G Shenoy K<sup>a</sup> & P Pavithra<sup>d</sup>

<sup>a</sup>Department of Pharmacology, Melaka Manipal Medical College, Manipal Academy of Higher Education, Manipal, Karnataka, India, 576 104

<sup>b</sup>Department of Pharmacology, Kasturba Medical College, Manipal, Manipal Academy of Higher Education, Manipal, Karnataka, India, 576 104

<sup>c</sup>Department of Pharmacology and Toxicology, National Institute of Pharmaceutical Education and Research, Hajipur (NIPER-H)- 844 102, Vaishali, Bihar India

<sup>d</sup>Department of Pathology, Melaka Manipal Medical College, Manipal Academy of Higher Education, Manipal, Karnataka, India, 576 104.

\*E-mail: <sup>†</sup> niteshkumar43@gmail.com

Received 21 May 2019; revised 11 March 2020

This study evaluated the prophylactic effect of *Kadukkai maathirai* in D-galactosamine (D-gal) induced hepatotoxicity in rats. D-galactosamine (D-gal) 400 mg/kg intraperitoneally was used to induce liver damage in rats. To assess the hepatoprotective effect of KM, three different doses of KM (36, 72 and 144 mg/kg body weight) were used. The hepatoprotective effect of KM was compared with standard drug silymarin (50 mg/kg). The biochemical parameters such as AST, ALT, ALP and total bilirubin were estimated. The livers were dissected out to look for histological changes. KM 144 mg/kg and silymarin showed a significant decrease in AST, ALP and total bilirubin. Both KM and silymarin significantly prevented decrease in liver weight. In KM treated groups, the liver did not show necrosis of hepatocytes, and apoptotic bodies with mild to moderate inflammatory infiltrate in the lobules and portal tracts. Hence, the results of this study confirms the hepatoprotective effect KM in rats.

**Keywords:** D-galactosamine, Hepatoprotective, *Kadukkai maathirai*

**IPC Code:** Int. Cl.<sup>20</sup>: A61K 31/7008, A61P 1/16

Fulminant hepatitis can be caused by various factors including viruses, alcohol and chemicals. This disease is associated with a high mortality rate as there are no effective prophylaxis or treatment. Liver transplantation is the only option in case of fulminant hepatitis which is very expensive. Hence newer agents need to be developed to treat various liver ailments. Extensive research is ongoing around the world to understand the pathogenesis of fulminant hepatitis. Different animal models are being used to test new chemical entities and herbal drugs. One of the models commonly used to mimic fulminant hepatitis in rats is D-galactosamine (D-gal) induced acute liver injury<sup>1</sup>.

Hepatic injury by D-galactosamine (D-gal) resembles human viral hepatitis in its morphological and functional features<sup>2</sup>. The intermediary toxic metabolites (UDP-galactosamine and UDP-

glucosamine) of D-gal trap uracil nucleotides required for the biosynthesis of nucleic acids and proteins<sup>3</sup>. Subsequently, necrosis of hepatocytes occurs. Galactosamine induces activated mast cells to release histamine leading to increase in the permeability of the gut. Damage by D-galactosamine is also due to release of tumor necrosis factor-alpha (TNF- $\alpha$ ) from Kupffer cells which causes cell death by oxidative stress and by triggering inflammation<sup>4-6</sup>. Administration of galactosamine causes inhibition of the synthesis of macromolecules in hepatocytes, and an increase in the sensitivity to TNF- $\alpha$ -mediated events<sup>7</sup>.

Many Indian traditional medicines have been used in the treatment of liver disease, and there are plenty of reports demonstrating hepatoprotective effects of various herbs<sup>8</sup>. Among the traditional Indian medicines, the Siddha system of medicine is practiced mainly in South Indian states and other South East

\*Corresponding author

Asian countries. *Kadukkai maathirai* (KM), one of the polyherbal Siddha preparation is often used to prevent and treat liver diseases<sup>9,10</sup>.

KM consists of four herbs namely *Terminalia chebula* (Retz.), *Piper nigrum* (Linn.), *Ecliptaalba* (Linn.), *Citrus limon* (Linn.), and ferrous sulfate<sup>11</sup>. Each herb contained in KM has been proved to exhibit hepatoprotective effect individually against different hepatotoxin induced liver disease animal models like -isoniazid, rifampicin, and pyrazinamide-induced liver toxicity; carbon tetrachloride as well as thioacetamide-induced liver toxicity. Studies with KM alone has been shown to have hepatoprotective effect in CCl<sub>4</sub>-as well as alcohol induced liver toxicity in rats<sup>12-18</sup>.

The current experiment was undertaken to investigate whether *Kadukkai maathirai* could protect against D-galactosamine induced hepatotoxicity.

## Material and Methods

### Animals and reagents

Adult female Sprague Dawley rats weighing about 150-200 g were used in this study. They were housed individually in polypropylene cages at 27 ± 3°C, humidity of 60 ± 10%- and 12-hours' light /dark cycle. The study was in accordance with standards laid down by Committee for the Purpose of Control and Supervision of Experiments on Animals (CPCSEA) guidelines following clearance from the Institutional Animal Ethics Committee, Manipal. (IAEC/KMC/19/2016 dated 16.03.2016).

D-galactosamine was procured from TCI, chemicals industry, Co.Ltd, Tokyo, Japan. All other chemicals were obtained from SPINREACT chemicals, Spain. Silymarin (standard drug) was procured from a local pharmacy. *Kadukkai maathirai* was procured from SKM Siddha and Ayurveda Company (India) Ltd, Saminathapuram, Modakkurichi, Erode District- 638 104, Tamilnadu, a GMP certified company.

### Experiment design

Nine groups with six rats in each was taken for the study. D-galactosamine was used to induce liver damage. Group I received the vehicle (2% gum acacia) and served as control. Groups II, III, IV test drug control, received KM 36, 72, 144 mg/kg, respectively. Group V was kept as toxic (D-gal) control and received 2% gum acacia. Groups VI, VII, VIII received *Kadukkai maathirai* (36 mg/kg, 72 mg/kg and 144 mg/kg, respectively) along with D-gal.

Group IX received standard drug silymarin (50 mg/kg) with D-gal. Drugs, other than D-gal, were given by oral gavage upto day seven. On day eight, D-galactosamine 400 mg/kg was injected intraperitoneally in rats of groups V, VI, VII, VIII, IX. On the 9th day, body weight was measured, and blood was collected by retro-orbital puncture and the serum was separated in sterile centrifuge tubes. The following serum enzymes were analyzed in serum using commercial assay kits obtained from Agappe Diagnostics Ltd: aspartate amino transferase (AST), alanine amino transferase (ALT), alkaline phosphatase (ALP) and total bilirubin. The estimation of biochemical parameters was done by standard procedures using kits. Rats were sacrificed by high dose pentobarbitone, and the liver was weighed and fixed in 10% formalin solution for microscopic examination using hematoxylin-eosin stain.

### Statistics

The statistical program SPSS 16.0 was used. Data were expressed as mean and standard deviation. One-way ANOVA followed by post hoc Tukey's test was used. Statistical significance was set at p<0.05.

## Results

### Biochemical estimation in serum

Administration of D-galactosamine showed a significant (p<0.05) rise in serum AST and ALT, ALP, total bilirubin levels than normal control. Prophylaxis with KM at 36, 72, 144 mg/kg significantly (p<0.05) prevented D-galactosamine induced rise in AST and ALT, ALP, total bilirubin levels versus those who were administered D-galactosamine alone (Table 1). Serum ALT level was significantly (p<0.05) lower in rats treated with silymarin than the group which received KM-144 mg/kg (p<0.05). Alteration in weight of rats was not significant between groups. The weight of the liver in D-galactosamine group was significantly reduced whereas three different doses KM at 36, 72, 144 mg/kg and silymarin significantly prevented decrease in weight of liver when given prophylactically.

### Histopathology

Histopathological findings of the liver sections of normal and test drug treated groups are shown in Figure 1.

Figures 1a-100x, 1b-400x show the liver section of group I (normal) rats where hepatic parenchyma with

Table 1 — Effect of *Kadukkai maathirai* on liver enzymes and bilirubin in D-galactosamine induced liver damage in Sprague Dawley rats

Group	AST(units/L)	ALT(units/L)	ALP(units/L)	Total bilirubin (µmol/L)
Group I (Normal control)	148.40 ± 7.7	76.20 ± 4.7	334.20 ± 95.1	0.24 ± 0.04
Group II (KM 36 mg/kg)	165.00±16.2	102.00±4.4	287.00±82.3	0.26 ± 0.07
Group III (KM 72 mg/kg)	192.00±18.2	115.40±12.1	310.00±33.2	0.27±0.08
Group IV (KM 144 mg/kg)	189.00 ± 33.1	94.00 ± 37.8	269.60 ± 60.0	0.24 ± 0.05
Group V (D-galactosamine control)	878.60±56.4*	1061.00±119.7*	633.20±113.6*	0.40±0.07*
Group VI (KM 36 mg/kg+ D-gal)	328.40±68.8**	415.40±51.4**	350.20±26.9**	0.26±0.05**
Group VII (KM 72 mg/kg+ D-gal)	264.80±45.13**	233.40±68.4**, <sup>§</sup>	370.00 ± 77.8**	0.24±0.05**
Group VIII (KM 144 mg/kg+ D-gal)	173.20±45.0**, <sup>§</sup>	348.60±95.3**	284.60±68.5**	0.24 ± 0.05**
Group IX(Silymarin+D-gal)	194.40 ± 34.7**, <sup>§</sup>	201.60 ± 33.7**, <sup>§,£</sup>	344.80 ± 77.7**	0.26 ± 0.05**

\*P< 0.05 versus control; \*\*P< 0.05 versus D-galactosamine;

<sup>§</sup>P< 0.05 versus group VI; <sup>£</sup> P< 0.05 versus group VIII;

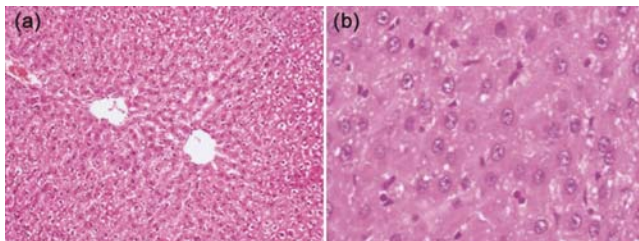


Fig. 1 — Histopathological findings of the liver in control group

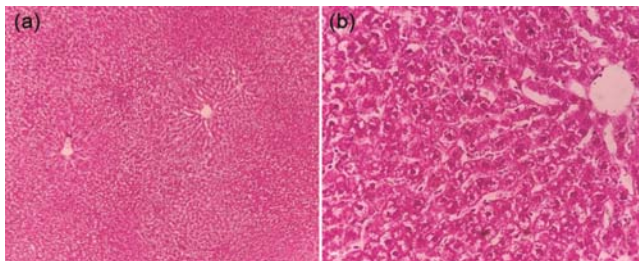


Fig. 2 — (a) Photomicrograph of liver tissue of group II (KM in 36 mg/ kg body weight) showing normal hepatic parenchyma with hepatic lobules and occasional cytoplasmic vacuolation; low power view (10x), H&E stain; & (b) - Photomicrograph of liver tissue of group II (KM in 36 mg/ kg body weight) showing normal hepatic parenchyma with hepatic lobules and occasional cytoplasmic vacuolation; high power view (40x), H&E stain

normal lobular architecture and cell structure. Figures 2a, 2b; 3a, 3b; 4a, 4b- 10× and 40× show liver tissue of groups II, III, IV (KM in 36, 72, 144 mg/ kg body weight) where normal hepatic parenchyma with hepatic lobules and occasional cytoplasmic vacuolation. Figures 5a, 5b-10×, 40× show group V (D-galactosamine) where there were extremely pronounced focal necrosis of hepatocytes, occasional apoptotic bodies, and also showed partially effaced architecture with small clusters of lymphocytes within the lobules and portal tracts. In groups VI, VII, VIII (KM 36, 72, 144 mg/kg along

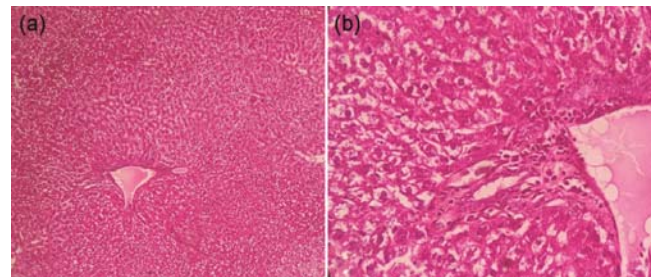


Fig. 3 — (a) 10x Photomicrograph of liver tissue of group III (KM in 72 mg/ kg body weight) showing normal hepatic parenchyma with hepatic lobules and occasional cytoplasmic vacuolation; low power view (10x), H&E stain; & (b) Photomicrograph of liver tissue of group III (KM in 72 mg/ kg body weight) showing normal hepatic parenchyma with hepatic lobules and occasional cytoplasmic vacuolation; high power view (40x)

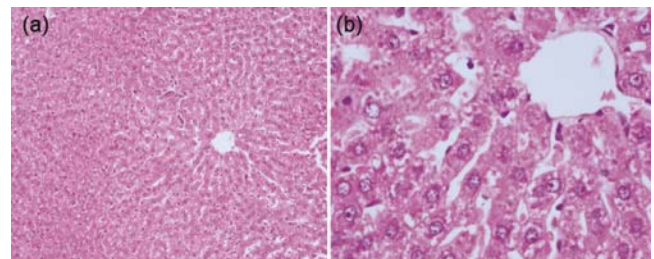


Fig. 4 — (a) Photomicrograph of liver tissue of group IV (KM in 144 mg/ kg body weight) showing normal hepatic parenchyma with hepatic lobules and occasional cytoplasmic vacuolation; low power view (10x), H&E stain; & (b) Photomicrograph of liver tissue of group IV (KM in 144 mg/ kg body weight) showing normal hepatic parenchyma with hepatic lobules and occasional cytoplasmic vacuolation; high power view (40x), H&E stain

with D-gal) there was better structural appearance of the liver without necrosis of hepatocytes, and apoptotic bodies with mild to moderate inflammatory infiltrate in the lobules and portal tracts (Fig. 6a-10×, 6b-40×; 7a-10×, 7b-40×; 8a-10×, 8b-40×) as compared to group IX (Fig 9a-10×, 9b-40×).

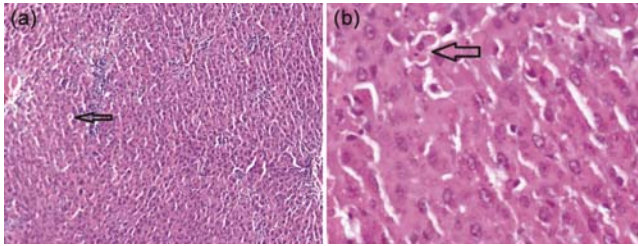


Fig. 5 — (a) Liver tissue of group V(D-galactosamine) showed extremely pronounced focal necrosis of hepatocytes, occasional apoptotic bodies, and also showed partially effaced architecture with small clusters of lymphocytes within the lobules and portal tracts; low power view (10x), H&E stain; & (b) Photomicrograph of liver tissue of group V(D-galactosamine) showed extremely pronounced focal necrosis of hepatocytes, occasional apoptotic bodies, and also showed partially effaced architecture with small clusters of lymphocytes within the lobules and portal tracts; high power view (40x), H&E stain

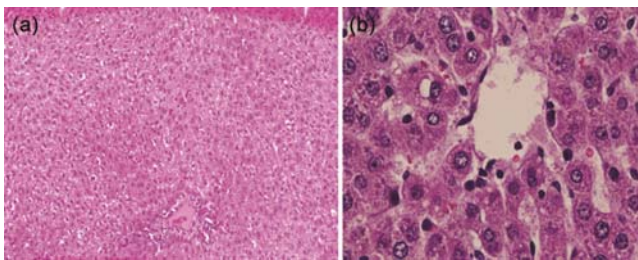


Fig. 6 — (a) Photomicrograph of liver tissue showing of group VI(KM 36 mg/kg along with D-gal ) better structural appearance of the liver without necrosis of hepatocytes, and apoptotic bodies with mild to moderate inflammatory infiltrate in the lobules and portal tracts; low power view (10x), H&E stain; & (b) Photomicrograph of liver tissue showing of group VI(KM 36 mg/kg along with D-gal) better structural appearance of the liver without necrosis of hepatocytes, and apoptotic bodies with mild to moderate inflammatory infiltrate in the lobules and portal tracts; high power view (40x), H&E stain

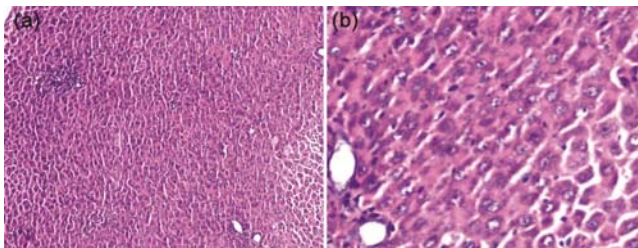


Fig. — 7 (a) Photomicrograph of liver tissue showing of group VII(KM 72 mg/kg along with D-gal )better structural appearance of the liver without necrosis of hepatocytes, and apoptotic bodies with mild to moderate inflammatory infiltrate in the lobules and portal tracts; low power view (10x), H&E stain; & (b) Photomicrograph of liver tissue showing of group VII(KM 72 mg/kg along with D-gal )better structural appearance of the liver without necrosis of hepatocytes, and apoptotic bodies with mild to moderate inflammatory infiltrate in the lobules and portal tracts; high power view (40x), H&E stain

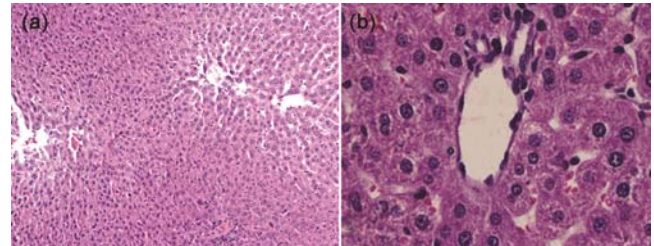


Fig. 8 — (a) Photomicrograph of liver tissue showing of group VIII(KM 144 mg/kg along with D-gal )better structural appearance of the liver without necrosis of hepatocytes, and apoptotic bodies with mild to moderate inflammatory infiltrate in the lobules and portal tracts; low power view (10x), H&E stain; & (b) Photomicrograph of liver tissue showing of group VIII(KM 144 mg/kg along with D-gal )better structural appearance of the liver without necrosis of hepatocytes, and apoptotic bodies with mild to moderate inflammatory infiltrate in the lobules and portal tracts; high power view (40x), H&E stain

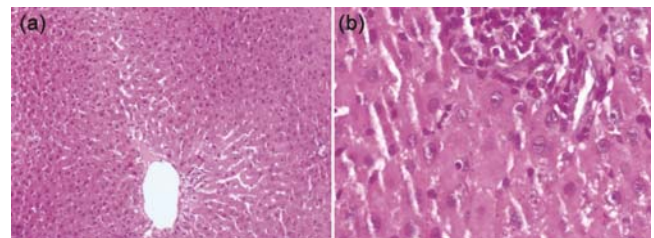


Fig. 9 — (a) Photomicrograph of liver tissue showing of group IX(Silymarin along with D-gal ) ; low power view (10x), H&E stain; & (b) Liver tissue showing of group IX(Silymarin along with D-gal ); high power view (40x), H&E stain

## Discussion

D-galactosamine-induced liver injury model is commonly used to screen the hepatoprotective effects of new chemical entities and also various herbal drugs. The changes seen in liver pathology with D-galactosamine induced liver damage resembles acute viral hepatitis in human beings<sup>19,20</sup>. Hence, this model was chosen in the current study. D-galactosamine makes the liver more susceptible to oxidative stress as it alters antioxidant status<sup>20</sup>. Various studies in the past have shown that D-galactosamine causes a drastic rise in AST, ALT and ALP. D-galactosamine causes fulminant hepatitis by blocking hepatic protein synthesis, and this could be attributed to liver weight loss observed in this study<sup>21</sup>. D-galactosamine-induced liver injury is associated with the exhaustion of uracil nucleotides leading to inhibition of synthesis of RNA and protein which causes necrosis of liver cells<sup>22</sup>. Administration of D-galactosamine in a dose of 400 mg/kg body weight *i.p.* produced extensive liver damage within 24 hours. As a result, the typical architecture of the

liver changed to partially affected architecture with small clusters of lymphocytes within the lobules and portal tracts, focal necrosis of hepatocytes along with occasional apoptotic bodies. Subsequently, hepatic enzymes seeped into the plasma which resulted in a significant ( $p < 0.05$ ) rise in serum levels of AST, ALT and ALP in D-gal treated rats.

Silymarin was used as a standard hepatoprotective compound in this study as it is known to protect the plasma membrane of liver cells<sup>23</sup>. Silymarin acts by reduction of free radicals. It also hinders the entry of toxic substances into the liver cells. Also, it promotes protein synthesis<sup>24</sup>.

In the present study, KM at 36, 72, 144 mg/kg significantly ( $p < 0.05$ ) prevented the D-galactosamine induced rise in AST and ALT levels. This was comparable with standard drug silymarin (Table 2). KM drug alone (36, 72, 144 mg/kg) showed a slight elevation in liver enzymes without any structural damage. This elevation might be because of presence of certain minerals or metals in KM as it is a polyherbal preparation. The absence of structural damage was confirmed by histopathological findings. In this study we have not evaluated whether it is self-limiting or spontaneously reversible. However, in future studies this can be evaluated.

Clinically, AST, ALT, ALP and bilirubin levels are elevated in acute hepatitis, and their levels return to normal when the healing process starts<sup>23</sup>. KM consists of herbs such as *T. chebula*, *P. nigrum*, *E. alba*, and *C. limon*<sup>11</sup>. *C. limon* has antioxidants such as Vitamin C and flavonoids which target the free radicals<sup>25</sup>. *P. nigrum* exerts antioxidant effect which could be mediated by flavonoids and phenolic constituents. It has been shown to inhibit lipid peroxidation, and generation of superoxide free radicals<sup>26,27</sup>. Gallic acid

and chebulic acid are essential constituents of *T. chebula*. Gallic acid has antioxidant and anti-inflammatory properties. Chebulic acid is known to be an antioxidant and hepatoprotective agent<sup>28-31</sup>. Coumestans, present in *E. alba*, has been shown to exert a protective effect in liver disorders and stimulate liver cell regeneration. KM treatment showed significant restoration of the altered liver enzymes and bilirubin levels towards normal in D-galactosamine intoxicated rats. The hepatoprotective effect of KM at the dose of 144 mg/kg and the standard drug silymarin were comparable which was further confirmed by histopathological findings.

### Conclusions

The Siddha preparation, *Kadukkai maathirai* exhibited hepatoprotective activity in D-galactosamine induced liver damage in rats. Hence, this study could be a piece of scientific evidence for traditional medicine practitioners. The hepatoprotective effect exhibited by KM could be attributed to its anti-inflammatory and antioxidant properties reported earlier.

### Acknowledgment

Authors thank SKM Siddha and Ayurveda (GMP certified) Company (India) Ltd, Tamilnadu for providing *Kadukkai maathirai* for the study.

### Conflicts of Interest

Authors declare no conflict of interest

### Author Contributions

Conceptualization: MS, SS; Data curation: MS, NK; Formal analysis: VD, PP; Methodology: GS, AA; Project administration: MS; Writing—original draft: MS; Writing—review and editing: MS, GS, SS.

Table 2 — Effect of *Kadukkai maathirai* on body and liver weight in D-galactosamine induced liver damage in Sprague Dawley rats.

Groups	Body Weight(g)	Liver weight (g)
Group I (Normal control)	241.6 ± 14.1	6.3 ± 0.9
Group II (KM 36 mg/kg)	237 ± 17.1	6.2 ± 0.7
Group III (KM 72 mg/kg)	239 ± 17.1	6.2 ± 0.8
Group IV (KM 144 mg/kg)	230.3 ± 17.1	6.2 ± 0.6
Group V (D-galactosamine control)	235.0 ± 24.7	3.6 ± 0.6*
Group VI (KM 36 mg/kg + D-gal)	237.6 ± 12.1	5.6 ± 0.3**
Group VII (KM 72 mg/kg + D-gal)	265.3 ± 41.0	5.7 ± 0.7**
Group VIII (KM 144 mg/kg + D-gal)	258.0 ± 20.0	5.5 ± 0.7**
Group IX (Silymarin + D-gal)	229.6 ± 30.8	5.5 ± 0.9**

\*P < 0.05 versus control; \*\*P < 0.05 versus D-galactosamine

### References

- 1 Decker K & Keppler D, Galactosamine induced liver injury, *Prog Liver Dis*, 4 1972 183–99.
- 2 Macdonald J R, Gandolfi A J, & Sipes I G, Hepatic cysteamine and non-protein sulfhydryl levels following cysteamine or cysteamine treatment of galactosamine-poisoned rats, *Drug Chem Toxicol*, 8 (6) (1985) 483-494.
- 3 Keppler D, Lesch R, Reutter W, & Decker K, Experimental hepatitis induced by d-galactosamine, *Exp Mol Pathol*, 9 (2) 1968 279-90.
- 4 Bates S H, Jones R B, & Bailey C J, Insulin-like effect of pinitol, *Br J Pharmacol*, 130 (8) (2000) 1944-1948.
- 5 Sun F, Hamagawa E, Tsutsui C, Sakaguchi N, Kakuta Y, *et al.*, Evaluation of oxidative stress during apoptosis and necrosis

- caused by D-galactosamine in rat liver, *Biochem Pharmacol*, 65 (1) (2003) 101-107.
- 6 Halliwell B G J M C, *Free Radicals in Biology and Medicine*, 3rd ed., (Oxford University Press, New York), 1999.
  - 7 Kasravi F B, Wang L, Wang X, Molin G, Bengmark S, *et al.*, Bacterial translocation in acute liver injury induced by D- galactosamine, *Hepatology*, 1996.
  - 8 Kim S-H, Kim YS, Kang SS, Bae K, Hung TM, *et al.*, Anti-apoptotic and Hepatoprotective Effects of Gomisin A on Fulminant Hepatic Failure Induced by D-Galactosamine and Lipopolysaccharide in Mice, *J Pharmacol Sci*, 106 (2) 2008 225–233.
  - 9 Muriel P & Rivera-Espinoza Y, Beneficial drugs for liver diseases, *J Appl Toxicol*, 2008.
  - 10 Anon, *Therapeutic Index Siddha Hospital Pharmacopoeia*, 1st ed., (Chennai), 2010.
  - 11 Amuthan A, Physico-chemical evaluation of kadukkai maathirai and its tablet formulation , a Siddha iron preparation used in anemia, 1 (1) 2012 3–8.
  - 12 Nirwane AM & Bapat AR, Effect of methanolic extract of Piper nigrum fruits in Ethanol-CCl4 induced hepatotoxicity in Wistar rats, *Der Pharm Lett*, 2012.
  - 13 Bai X, Zhang W, Chen W, Zong W, Guo Z, *et al.*, Anti-hepatotoxic and anti-oxidant effects of extracts from piper nigrum L. root, *African J Biotechnol*, 2011.
  - 14 Bhavsar SK, Joshi P, Shah MB, & Santani DD, Investigation into hepatoprotective activity of Citrus limon, *Pharm Biol*, 2007.
  - 15 Saxena AK, Singh B, & Anand KK, Hepatoprotective effects of Eclipta alba on subcellular levels in rats, *J Ethnopharmacol*, 23 (1) (1993) 97-103.
  - 16 Thirumalai T, David E, Therasa V, & Elumalai E K, Restorative effect of Eclipta alba in CCl 4 induced hepatotoxicity in male albino rats, *Asian Pacific J Trop Dis*, 1 (4) (2011) 304-307.
  - 17 Amuthan A, Hepatoprotective activity of Kadukkai Maathirai (a Siddha polyherbal formulation) against carbon tetrachloride induced liver damage in rat, 1 (4) (2012) 17–21.
  - 18 Shetty M, Shenoy S, Devi V, Kumar N, Amuthan A, *et al.*, protective effect of kadukkai maathirai (Terminalis chebula-based polyherbal siddha formulation) in ethanol-induced liver disease in rats, *Asian J Pharm Clin Res*, 11 (11) (2018) 368.
  - 19 Chaung S S, Lin C C, Lin J, Yu K H, Hsu Y F, *et al.*, The hepatoprotective effects of *Limonium sinense* against carbon tetrachloride and  $\beta$ -D-galactosamine intoxication in rats, *Phyther Res*, 17 (7) (2003) 784-791.
  - 20 Nakagiri R, Hashizume E, Kayahashi S, Sakai Y, & Kamiya T, Suppression by Hydrangeae Dulcis Folium of D-galactosamine-induced liver injury in vitro and in vivo, *Biosci Biotechnol Biochem*, 67 (12) (2003) 2641-2643.
  - 21 Tang X-H, Gao L, Gao J, Fan Y-M, Xu L-Z, *et al.*, Mechanisms of hepatoprotection of Terminalia catappa L. extract on D-galactosamine-induced liver damage, *Am J Chin Med*, 32 (4) (2004). <https://doi.org/10.1142/S0192415X04002156>
  - 22 Decker K & Keppler D, Galactosamine hepatitis: key role of the nucleotide deficiency period in the pathogenesis of cell injury and cell death, *Rev Physiol Biochem Pharmacol*, 1974.
  - 23 Ramellini G & Meldolesi J, Liver protection by silymarin: in vitro effect on dissociated rat hepatocytes, *Arzneimittel-Forschung/Drug Res*, 71 (1976) 77-106.
  - 24 AbouZid S, Natural flavonolignans from milk thistle, In: *Phytochemicals - A Global Perspective of Their Role in Nutrition and Health*, edited by V Rao, IntechOpen, 2012. DOI: 10.5772/26027
  - 25 Jaiswal S K, Gupta V K, Siddiqi N J, Pandey R S, & Sharma B, Hepatoprotective effect of *Citrus limon* fruit extract against carbofuran induced toxicity in wistar rats, *Chinese J Biol*, 2015 (2015) 1–10.
  - 26 Vijayakumar R S, Surya D, & Nalini N, Antioxidant efficacy of black pepper (Piper nigrum L.) and piperine in rats with high fat diet induced oxidative stress, *Redox Rep*, 9 (2) (2004) 105-110.
  - 27 Selvendiran K & Sakthisekaran D, Chemopreventive effect of piperine on modulating lipid peroxidation and membrane bound enzymes in benzo(a)pyrene induced lung carcinogenesis, *Biomed Pharmacother*, 58 (4) (2004) 264-267.
  - 28 Juang L J, Sheu S J, & Lin T C, Determination of hydrolyzable tannins in the fruit of Terminalia chebula Retz. by high-performance liquid chromatography and capillary electrophoresis, *J Sep Sci*, 27 (9) (2004) 718-724.
  - 29 Panunto W, Jaijoy K, Lerdvuthisophon N, Lertprasertsuke N, Jiruntanat N, *et al.*, Acute and chronic toxicity studies of the water extract from dried fruits of *Terminalia chebula* Retz. in rats, *Int J Appl Res Nat Prod*, 10 (2) (2010) 223-31.
  - 30 Lee H S, Jung S H, Yun B S, & Lee K W, Isolation of chebulic acid from Terminalia chebula Retz. and its antioxidant effect in isolated rat hepatocytes, *Arch Toxicol*, 81 (3) (2007) 211-218.
  - 31 Lee S I, Hyun P M, Kim S H, Kim K S, Lee S K, *et al.*, Suppression of the onset and progression of collagen-induced arthritis by chebulagic acid screened from a natural product library, *Arthritis Rheum*, 52 (1) (2005) 345-353.