



A Fatal Pneumonia due to Coinfection of *Pseudomonas putida* and *Staphylococcus pseudintermedius* in a Laboratory Beagle Dog

Min Hong¹, Liping Wei¹, Yan Chen², Yongchang Qin², Xin Wang², Yaqun Zhang², Yan Chang¹ & Hua Li¹

ABSTRACT

Background: *Pseudomonas putida* (*P. putida*) is widely distributed in the environment, and sometimes caused nosocomial infections in human beings, but no case of infection has been reported in beagle dogs. *Staphylococcus pseudintermedius* (*S. pseudintermedius*) is a natural cutaneous bacterium in dogs and occasionally causes purulent infections of the skin yet rarely causes pneumonia. Both bacteria are opportunistic pathogens. Dogs, even well-controlled laboratory beagle dogs, maybe infected by the bacterium in certain conditions like this report. In order to provide information and give suggestion to veterinarians involved in dogs study, a complete profile of the coinfection was drawn in this report.

Case: It is presented a case of an 8-month-old beagle dog, weighing 6 kg that suffered from coinfection of *P. putida* and *S. pseudintermedius* during a treatment of chemotherapy. The animal was confirmed as normal by appearance, physical examination and laboratory tests before arrival according to the applicable guidelines. After 14-day acclimation period, the animal was administrated with a tyrosinase inhibitor once daily via oral gavage. From Day 8, coughing, decreased activity, hyporeflexia, squinting, shortness of breath (abdominal breathing), and discharge around the nose as well as crackles in the lung and rapid heart rate were noted. Since the poor conditions progressed quickly and have not been improved by treatment of ceftriaxone and dexamethasone. On Day 9, the animal was euthanized for humanitarian reasons. To define the pathogen, hilar lymph node and thoracic swab were collected for bacteria isolation and purification in special mediums, and at last characterized by Gram staining and 16s rRNA gene sequence analysis and positive PCR-restriction fragment length polymorphism. In clinical pathological examination, an increase in WBC, neutrophils, lymphocytes, monocytes, cholesterol, triglyceride, total protein, globulin, and lactate dehydrogenase, as well as a decrease in RBC, hemoglobin, hematocrit, platelets, sodium ion, chloride ion, and albumin were noted. At necropsy, dark red and enlarged lymph nodes were noted in the hilum of lung, multiple abscesses with yellow pus and multifocal hemorrhage were noted in the lung, and a large amount of frothy yellow fluid were noted in the trachea. In pathological examinations, severe neutrophilic inflammation, diffuse and moderate macrophage aggregation, mild hemorrhage, and moderate alveolar emphysema were noted in the lung, and severe sinusoidal stasis were noted in portal lymph nodes.

Discussion: The current case presented a profile of the appearance, treatment, hematological examination, coagulation examination, clinical chemistry, macroscopic and histological changes in the lung. Multiple purulent abscesses, infiltration of neutrophils, macrophage, and hemorrhage, were correlated to the increase in WBC, neutrophils, lymphocytes, and monocytes, and the decrease in RBC, hemoglobin, hematocrit, and platelets. In the coagulation examination, an increase in Fbg concentration was noted. This change may be induced by the coagulase effect of the *S. pseudintermedius*, yet no effect on PT or APTT was noted, indicating the coagulation function has not been affected. In the clinical chemistry, the increase of creatine kinase and lactate dehydrogenase may indicate tissue cell damages. Significant increase of globulin may be caused by the inflammatory status. In conclusion, the findings in this case indicate that both *Pseudomonas putida* and *Staphylococcus pseudintermedius* can induce infections in laboratory beagle dogs under certain conditions, and might result in a fatal pneumonia which could progress very fast within several days.

Keywords: *Pseudomonas putida*, *Staphylococcus pseudintermedius*, pneumonia, beagle dog.

DOI: 10.22456/1679-9216.107684

Received: 6 October 2020

Accepted: 18 January 2021

Published: 27 March 2021

¹Shanghai Innostar Bio-tech Co. Ltd., Shanghai, Shanghai, China. ²Innostar Bio-tech Haimen Site, Nantong, Jiangsu, China. CORRESPONDENCE: H. Li [lihua_innostar@protonmail.com]. Shanghai Innostar Bio-tech Co. Ltd. 199 Guoshoujing Road, Shanghai, China.

INTRODUCTION

In laboratory beagle dogs, various pathogens should be monitored and controlled according to Federation of European Laboratory Animal Science Associations (FELASA) recommendations [11] and “Laboratory animal - Microbiological standards and monitoring” (Standard No. GB14922.2-2011). However, opportunistic pathogens such as *Pseudomonas putida* (*P. putida*) and *Staphylococcus pseudintermedius* (*S. pseudintermedius*), are not included in either of these guidelines.

P. putida is a gram-negative, aerobic pseudomonad that is widely distributed in the environment, and is regarded as part of the normal flora in the human oropharynx [2]. It sometimes caused nosocomial infections in immunocompromised patients [18]. A few cases of *P. putida* have been reported in animals such as mice [8], catfish [15], and monkeys [10]. However, no case of infection has been reported in beagle dogs by now. *Staphylococcus pseudintermedius* is a gram-positive, DNase-positive, coagulase coccus bacteria that has been firstly characterized in 2005 [4]. The bacteria is regarded as a natural cutaneous bacterium in dogs and occasionally causes purulent infections of the skin [3,13]. However, the infection of the lung that causes pneumonia in dogs, especially in laboratory beagle dogs, is rarely reported.

Both opportunistic pathogens are well-controlled in normal laboratory beagle dogs. However, in animals with immunocompromised condition, the pathogens may cause severe disease. In this report, we present a case of fatal pneumonia caused by coinfection of *Pseudomonas putida* and *Staphylococcus pseudintermedius* in an 8-month-old beagle dog, weighing 6 kg after several days of chemotherapy.

CASE

A total of 40 animals were brought by Shanghai Innostar Bio-tech Co. Ltd. for conducting a GLP (Good Laboratory Practice) complaint toxicology study, which complied with all applicable local, national, and international guidelines, and was monitored and approved by the IACUC of the company, an AAA-LAC-accredited facility. Before arrival, all animals were confirmed as normal by appearance, physical examination, and laboratory tests of various viruses, *Salmonella*, *Brucella*, fungus, ectoparasite, and *Toxoplasma* according to the applicable guidelines. After

arrival, the animals were still healthy according to the results of in-home observation, physical examination, hematological analysis, parasite examination, electrocardiograph, and clinical pathological examinations in a 14-day acclimation or quarantine period.

All 40 dogs received TI-001¹, a tyrosinase inhibitor used for chemotherapy, once daily via oral gavage in a standard GLP toxicology study. No abnormality was noted until Day 8, when one animal was observed with coughing, decreased activity, and hyporeflexia. Besides, crackles in the lung and rapid heart rate (approximately 150 bpm) were noted via auscultation by a staff veterinarian. Then the animal was treated with 1g of ceftriaxone² and 0.01 mg/kg of dexamethasone³ via intramuscular injection. However, the conditions of the animal had not been improved by the treatment. On day 9, additional abnormalities such as squinting, shortness of breath (abdominal breathing), and discharge around the nose were noted in the animal. Since the disease progressed rapidly without any effective antibiotic therapy, the animal was euthanized for humanitarian reasons.

In order to define the pathogens of this fatal infection, a hilar lymph node near the lesion was quickly removed by sterile surgery, and the fluid on the thoracic wall was collected by sterile swabbing. The lymph node tissue and thoracic swabs were shipped carefully to VRL Laboratories (Suzhou, China) for a pathogen test. According to the local SOPs, the samples were firstly inoculated on blood Agar and selective mediums of nalidixic acid ceftrimide agar and deoxycholate-hydrogen-sulfide-lactose agar⁴. Dominant colonies or potential pathogenic bacteria colonies were isolated and purified via repeated plate streaking. Then the purified colonies were subjected to Gram staining⁴, 16s rRNA gene sequence analysis and positive PCR-restriction fragment length polymorphism for pathogenic bacteria determination according to standard procedures as described in the past literature [5,6,16]. The test report indicated that *P. putida* was noted in the thoracic swabs, while both *P. putida* and *S. pseudintermedius* were detected in the hilar lymph node.

With the objective of characterize the profile of the infection, firstly, a detailed macroscopic examination was conducted, as shown in Figure 1. The result showed dark red and enlarged lymph nodes in the hilum of lung, multiple abscesses with yellow

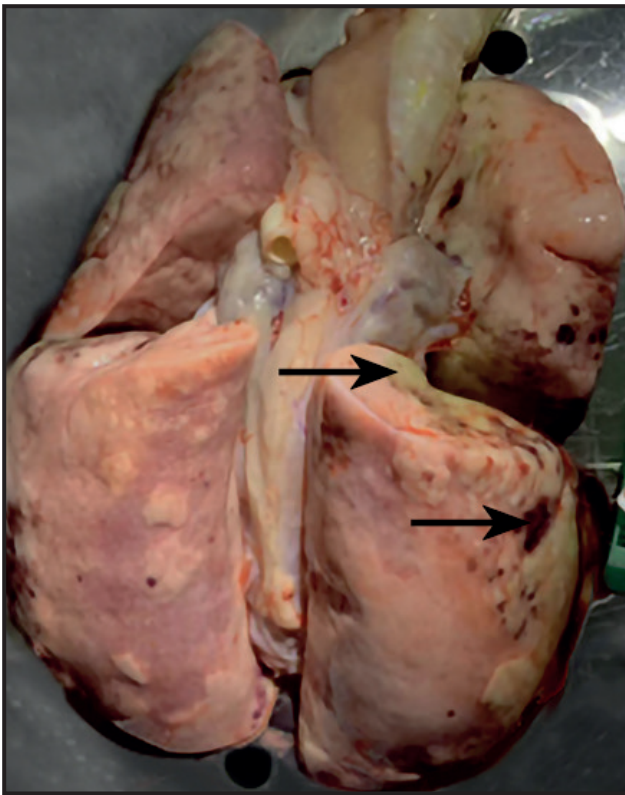


Figure 1. Macroscopic findings in the co-infected lung of the beagle dog. The photo was taken freshly at necropsy, after the animal was exsanguinated under deep anesthesia. The upper arrow points to the abscesses with yellow pus in the lung; the lower arrow points to a hemorrhage focus.

pus and multifocal hemorrhage in the lung, and a large amount of frothy yellow fluid in the trachea. No abnormality was observed in other tissues or organs. Under a microscopy, as shown in Figure 2B when compared to Figure 2A (from a concurrent negative control animal in the study), abnormalities of severe

neutrophilic inflammation, diffuse and moderate macrophage aggregation, mild hemorrhage, and moderate alveolar emphysema were noted in the lung, and severe sinusoidal stasis in portal lymph nodes. No other abnormalities were noted except for mild lymphopenia in the spleen, mild hypertrophy in the adrenal cortex, and mild atrophy in the thymic cortex. Hematological examination using ADVIA 2120 Automated Hematology Analyzer⁵ showed an increase in WBC (71.02×10^3 cell/ μL , baseline value of 12.4×10^3 cell/ μL), neutrophils (54.37×10^3 cell/ μL , baseline value of 7.35×10^3 cell/ μL), lymphocytes (8.77×10^3 cell/ μL , baseline value of 3.99×10^3 cell/ μL), and monocytes (4.01×10^3 cell/ μL , baseline value of 0.56×10^3 cell/ μL), and a decrease in RBC (3.38×10^3 cell/ μL , baseline value of 6.13×10^3 cell/ μL), hemoglobin (7.5 g/dL, baseline value of 13.1 g/dL), hematocrit (25.2%, baseline value of 41.4%), and platelets (113×10^3 cell/ μL , baseline value of 461×10^3 cell/ μL). Coagulation examination using CA-1500 Automated Coagulation Analyzer⁶ showed an increase in fibrinogen (7.44 g/L, baseline value of 1.47 g/L) but not in prothrombin time (PT) or activated partial thromboplastin time (APTT). Clinical chemistry using 7180 Automatic Clinical Analyzer⁷ showed an increase in cholesterol (11.64 mmol/L, baseline value of 3.32 mmol/L), triglyceride (1.22 mmol/L, baseline value of 0.22 mmol/L), total protein (61.9 g/L, baseline value of 50.8 g/L), globulin (37.0 g/L, baseline value of 20.7 g/L), and lactate dehydrogenase (302 U/L, baseline value of 150 U/L), and a decrease in sodium ion (142.6 mmol/L, baseline value of 147.2 mmol/L), chloride ion (104.6 mmol/L, baseline

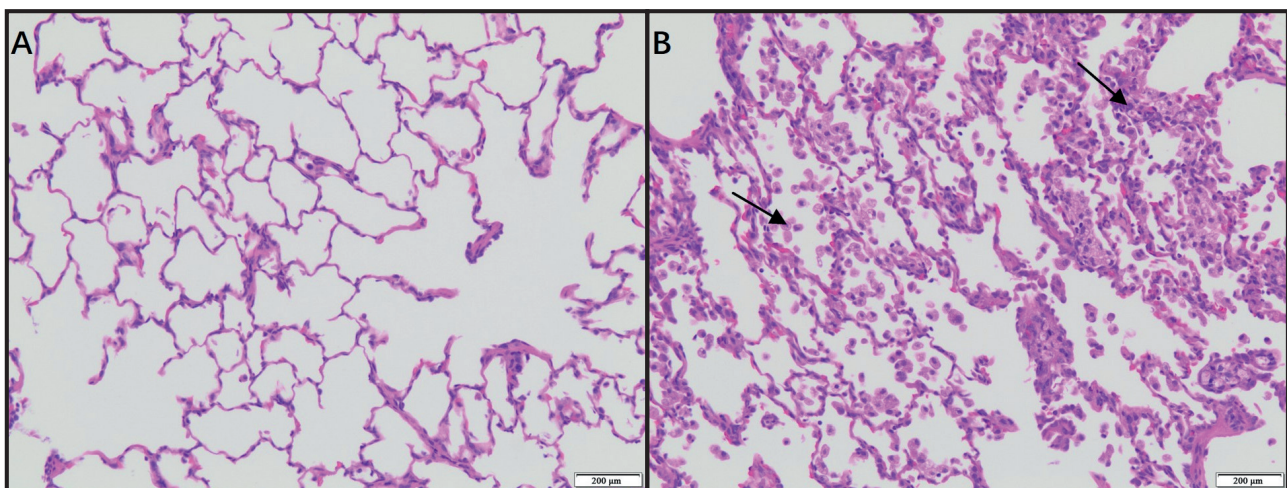


Figure 2. Histological examination after H-E staining of lung slides. The lungs were fixed with 10% neutral formalin and subjected to paraffin embedding, sectioning, hematoxylin-eosin staining, and histopathological examination. A- A normal slide of lung from a concurrent control beagle dog. B- Image from the co-infected animal. The left arrow indicates macrophage aggregation and the right arrow indicates neutrophilic inflammation.

Table 1. Changes of clinical pathological parameters in the co-infected beagle dog.

Parameter	At euthanasia*	Baseline	Reference values
Red Blood cell (x10 ⁶ /uL)	3.38↓	6.13	4.76 to 7.19
Hemoglobin (g/dL)	7.5↓	13.1	10.64 to 16.52
Hematocrit (%)	25.2↓	41.4	31.54 to 49.74
Mean Corpuscular Hemoglobin Concentration (g/dL)	29.6↓	31.6	31.39 to 35.40
Platelet (x10 ³ /uL)	113↓	461	166.18 to 441.79
White blood cell (x10 ³ /uL)	71.02↑	12.42	5.98 to 17.22
Neutrophil (x10 ³ /uL)	54.37↑	7.35	3.08 to 10.34
Lymphocyte (x10 ³ /uL)	8.77↑	3.99	1.74 to 5.68
Monocyte(x10 ³ /uL)	4.01↑	0.56	0.24 to 1.05
Fibrinogen (g/L)	7.44↑	1.47	1.05 to 2.34
Creatine Kinase (U/L)	940↑	359	76.01 to 498.35
Cholesterol (mmol/L)	11.64↑	3.32	2.65 to 6.17
Triglyceride (mmol/L)	1.220↑	0.22	0.16 to 0.71
Sodium ion (mmol/L)	142.6↓	147.2	144.89 to 151.81
Chloride ion (mmol/L)	104.6↓	110.3	109.57 to 117.64
Total protein (g/L)	61.9↑	50.8	48.49 to 60.42
Albumin (g/L)	24.9↓	30.1	25.82 to 33.94
Globulin (g/L)	37.0↑	20.7	19.27 to 29.36
A/G	0.67↓	1.5	0.90 to 1.57
Lactate dehydrogenase (U/L)	302↑	150	14.85 to 215.36

*↑/↓: Increase/decrease of value compared to either baseline or in-home reference value. Other parameters such as eosinophils, basophils, prothrombin time, activated partial thromboplastin time, alanine aminotransferase, aspartate aminotransferase, alkaline phosphatase, gamma-glutamyl transpeptidase, total bilirubin, direct bilirubin, glucose, BUN, CREA, Ca, P, and K were examined but not listed here because of no difference compared with the baseline value or within the reference value.

value of 110.3 mmol/L), and albumin (24.9 g/L, baseline value of 30.1 g/L).

DISCUSSION

Laboratory beagle dogs are widely used in non-clinical studies of drug development, and animal health is an important factor that may confuse the interpretation of study results. Generally, the microorganisms, especially certain pathogens, are well controlled according to applicable guidelines. However, in some studies or conditions where the animals are immunocompromised, opportunistic pathogens may cause infection in the animals. In the present study, the authors reported the first case of coinfection of *P. putida* and *S. pseudintermedius* in a beagle dog. Pathogens were isolated by various mediums and confirmed by the 16s rRNA gene sequence analysis and positive

PCR-restriction fragment length polymorphism. The authors present a profile of the appearance, treatment, hematological examination, coagulation examination, clinical chemistry, macroscopic and histological examination for a whole panel of tissues and organs.

Pseudomonas putida is a normal inhabitant of soil, water, and plants, and has emerged as a nosocomial bacterial pathogen in human beings. Various investigations indicated that the pathogen may release endotoxin, causing soft tissue infection, urinary tract infections, pneumonia, septicemia, wound infections, meningitis, and peritonitis [9,17]. The *P. putida* induced pneumonia in human beings was observed with relatively higher heart rate and respiratory rate, and an increase in leukocyte count, neutrophils, lymphocytes, monocytes and eosinophils [7]. *Staphylococcus pseudintermedius* is part of the commensal bacterium in

dogs and cats' skin [1]. The opportunistic infections caused by this bacterium mainly appear as skin purulent damage [14]. A few cases of the lung infection that caused pneumonia were reported in human beings [12] and in a dog [19]. In the case of the dog, *S. pseudintermedius*, which was observed in the canine milk samples, vaginal swabs, and skin swabs, caused interstitial pneumonia and multifocal acute myocardial necrosis. The dog died within three days due to the rapid development of symptoms [19].

The infection in this study was limited to the lung, and no infection or inflammatory was noted in other tissues or organs. Although mild lymphopenia in the spleen, mild hypertrophy in the adrenal cortex, and mild atrophy in the thymic cortex were noted, they are regarded as secondary changes due to stress. Changes in the lung, such as the bacterium caused multiple purulent abscesses via macroscopic examination, infiltration of neutrophils, macrophage and hemorrhage via histological examination, are correlated to the increase in WBC, neutrophils, lymphocytes, and monocytes, and the decrease in RBC, hemoglobin, hematocrit, and platelets, consisting with report results as above mentioned. In the coagulation examination, an increase in Fbg concentration was noted. This change may be induced by the coagulase effect of the *S. pseudintermedius*, yet no effect on PT or APTT was noted, indicating the coagulation function has not been affected. In the clinical chemistry, the increase of creatine kinase and

lactate dehydrogenase may indicate tissue cell damages. Significant globulin increase may be caused by the inflammatory status, and secondarily resulted in the albumin decrease in order to balance the plasma osmolality. An increase in cholesterol and triglyceride may indicate a dysfunction of the metabolic system. A decrease in sodium ion and chloride ion may due to loss of the tissue fluid.

The findings in this case indicate that both *Pseudomonas putida* and *Staphylococcus pseudintermedius* can induce infections in laboratory beagle dogs under certain conditions, and might promote a fatal pneumonia which could progress very fast within several days. The report recommends that beagle dogs receiving immunosuppressive therapy should be monitored for the development of opportunistic infections.

MANUFACTURERS

¹Gateway Co. Ltd. Shanghai, China.

²Xinya pharmaceutical Co. Ltd. Shanghai, China.

³Zhuofeng pharmaceutical Co. Ltd. Zhengzhou, China.

⁴VRL Laboratories. Suzhou, China.

⁵Bayer Pharmaceuticals. Leverkusen, Germany.

⁶Sysmex Corporation. Kobe, Japan.

⁷Hitachi Ltd. Tokyo, Japan.

Acknowledgments. This work was supported by the Major Projects Foundation of the National Health Commission of the People's Republic of China (Grant Number: 2018ZX09201017-008).

Declaration of interest. The authors report no conflicts of interest. The authors alone are responsible for the content and writing of paper.

REFERENCES

- 1 Bardiau M., Yamazaki K., Ote I., Misawa N. & Mainil J.G. 2013. Characterization of methicillin-resistant *Staphylococcus pseudintermedius* isolated from dogs & cats. *Microbiology and Immunology*. 57(7): 496-501.
- 2 Carlson D., McKeen E., Mitchell M., Torres B., Parad R., Comeau A.M. & O'Sullivan B.P. 2009. Oropharyngeal flora in healthy infants: observations and implications for cystic fibrosis care. *Pediatric Pulmonology*. 44(5): 497-502.
- 3 Carneiro L.E., Vanz A.C. & Barcellos H.H.A. 2018. Tratamento prévio com trilostano e levotiroxina em subdose dificultam diagnóstico de hipotireoidismo canino. *Acta Scientiae Veterinariae*. 46(1): 304.
- 4 Christie I.C., Price J., Edwards L., Muldoon M., Meltzer C.C. & Jennings J.R. 2008. Alcohol consumption and cerebral blood flow among older adults. *Alcohol*. 42(4): 269-275.
- 5 Chrobak D., Kizerwetter-Swida M., Rzewuska M., Moodley A., Guardabassi L. & Binek M. 2011. Molecular characterization of *Staphylococcus pseudintermedius* strains isolated from clinical samples of animal origin. *Folia Microbiologica*. 56(5): 415-422.
- 6 Chuang C.Y., Yang Y.L., Hsueh P.R. & Lee P.I. 2010. Catheter-related bacteremia caused by *Staphylococcus pseudintermedius* refractory to antibiotic-lock therapy in a hemophilic child with dog exposure. *Journal of Clinical Microbiology*. 48(4): 1497-1498.
- 7 Fujita J., Negayama K., Ohara M., Hojo S., Obayashi Y., Miyawaki H., Yamaji Y. & Takahara J. 1998. Pneumonia caused by *Pseudomonas putida* with a mucoid phenotype. *Respiratory Medicine*. 92(4): 693-695.

- 8 **George S.E. 2009.** Survival of Environmental Microbial Agents in CD-1 Mice Following Oral Exposure. *Microbial Ecology in Health and Disease*. 12(2): 92-98.
- 9 **Lombardi G., Luzzaro F., Docquier J.D., Riccio M.L., Perilli M., Coli A., Amicosante G., Rossolini G.M. & Toniolo A. 2002.** Nosocomial infections caused by multidrug-resistant isolates of *Pseudomonas putida* producing VIM-1 metallo-beta-lactamase. *Journal of Clinical Microbiology*. 40(11): 4051-4055.
- 10 **Matchett C.A., Dillehay D.L., Goodman M.M. & Pullium J.K. 2003.** Postanesthesia death and suspected peracute endotoxic shock due to *Pseudomonas putida* in a cynomolgous macaque (*Macaca fascicularis*). *Comparative Medicine*. 53(3): 309-312.
- 11 **Rehbinder C., Baneux P., Forbes D., van Herck H., Nicklas W., Rugaya Z. & Winkler G. 1998.** FELASA recommendations for the health monitoring of breeding colonies and experimental units of cats, dogs and pigs. Report of the Federation of European Laboratory Animal Science Associations (FELASA) Working Group on Animal Health. *Laboratory Animals*. 32(1): 1-17.
- 12 **Stegmann R., Burnens A., Maranta C.A. & Perreten V. 2010.** Human infection associated with methicillin-resistant *Staphylococcus pseudintermedius* ST71. *The Journal of Antimicrobial Chemotherapy*. 65(9): 2047-2048.
- 13 **Wan J. 2014.** A case of methicillin-resistant *Staphylococcus pseudintermedius* (MRSP) pyoderma in a Labrador retriever dog. *The Canadian Veterinary Journal*. 55(11): 1100-1101.
- 14 **Weese J.S., Faires M., Brisson B.A. & Slavic D. 2009.** Infection with methicillin-resistant *Staphylococcus pseudintermedius* masquerading as ceftiofur susceptible in a dog. *Journal of the American Veterinary Medical Association*. 235(9): 1064-1066.
- 15 **Ya-Jiao D., Xiao-Li H., Gui-Ran Z., Wei F., Jing D., Yi-Lin Z., Yong-Qiang D., Yi G., De-Fang C. & Kai-Yu W. 2017.** Isolation, identification and pathological lesions of *Pseudomonas putida* from hybrid catfish. *Acta Hydrobiologica Sinica*. 41(2): 371-378.
- 16 **Yamamoto S. & Harayama S. 1998.** Phylogenetic relationships of *Pseudomonas putida* strains deduced from the nucleotide sequences of gyrB, rpoD and 16S rRNA genes. *International Journal Systematic Bacteriology*. 48(3): 813-819.
- 17 **Yang C.H., Young T., Peng M.Y. & Weng M.C. 1996.** Clinical spectrum of *Pseudomonas putida* infection. *Journal of the Formosan Medical Association = Taiwan yi zhi*. 95(10): 754-761.
- 18 **Yoshino Y., Kitazawa T., Kamimura M., Tatsuno K., Ota Y. & Yotsuyanagi H. 2011.** *Pseudomonas putida* bacteremia in adult patients: five case reports and a review of the literature. *Journal of Infection and Chemotherapy: Official Journal of the Japan Society of Chemotherapy*. 17(2): 278-282.
- 19 **Zakosek Pipan M., Svava T., Zdovc I., Papic B., Avbersek J., Kusar D. & Mrkun J. 2019.** *Staphylococcus pseudintermedius* septicemia in puppies after elective cesarean section: confirmed transmission via dam's milk. *BMC Veterinary Research*. 15(1): 41.