



THE AGA KHAN UNIVERSITY

eCommons@AKU

---

Section of Otolaryngology, Head & Neck Surgery

Department of Surgery

---

2-1-2020

## Management of laryngotracheal trauma: A review of current trends and future directions

Muhammad Wasif

Rahim Dhanani

Shayan Khalid

Mohammad Sohail Awan

Muhammad Hassan Danish

*See next page for additional authors*

Follow this and additional works at: [https://ecommons.aku.edu/pakistan\\_fhs\\_mc\\_surg\\_otolaryngol\\_head\\_neck](https://ecommons.aku.edu/pakistan_fhs_mc_surg_otolaryngol_head_neck)

 Part of the [Otolaryngology Commons](#), [Otorhinolaryngologic Diseases Commons](#), [Surgery Commons](#), and the [Trauma Commons](#)

---

---

**Authors**

Muhammad Wasif, Rahim Dhanani, Shayan Khalid, Mohammad Sohail Awan, Muhammad Hassan Danish, Huzafa Moiz, and Hamdan Ahmed Pasha

---

## NARRATIVE REVIEW

## Management of Laryngotracheal trauma: A review of current trends and future directions

Muhammad Wasif, Rahim Dhanani, Shayan Khalid Ghaloo, Muhammad Sohail Awan, Muhammad Hassan Danish, Huzaifa Moiz Hussain, Hamdan Ahmed Pasha

### Abstract

Laryngotracheal trauma is rare but can pose serious threats to one's life. Presenting symptoms vary according to the severity of injury. Immediate Airway control is first step in the management, intubation should be considered by a senior member of the trauma team if the injury is minor while tracheostomy should be reserved for more severe injuries. Evaluation by a fibre-optic laryngoscopy and CT scan should be done whenever possible. Reconstruction is done according to the site involved using suture, titanium miniplates and stents. Tissue engineering has added a new horizon in this management but up till now complete laryngotracheal regeneration is very far-fetched, but tissue regeneration at individual sites have shown some positive results. More work needs to be done in this less explored field including laryngeal transplantation.

**Keywords:** Larynx, Trachea, Trauma, Management.

### Introduction

Laryngotracheal trauma is rare but can pose serious threats to one's life. Incidence is only 1 in 30,000 patients coming to the emergency room.<sup>1</sup> This rarity is potentially due to positioning of the laryngotracheal framework in the body which is superiorly secured by the mandible, inferiorly by sternum, posteriorly by vertebral column and multiple muscles and tendons in the neck.<sup>2</sup> Although these are rare but overall mortality for patients of cervical tracheal trauma is reported to be 14%.<sup>3</sup> Due to rarity these injuries are frequently missed during evaluation of trauma patients therefore a high level of suspicion should be practiced.<sup>4</sup> Immediate intervention is highly recommended in cases with major injuries in order to achieve favourable outcomes.<sup>5</sup>

**Presentation:** Presenting symptoms vary according to the severity of injury, the may included dysphonia, dysphagia, haemoptysis, dyspnoea or stridor. Examination may reveal tenderness on the neck region, cyanosis and

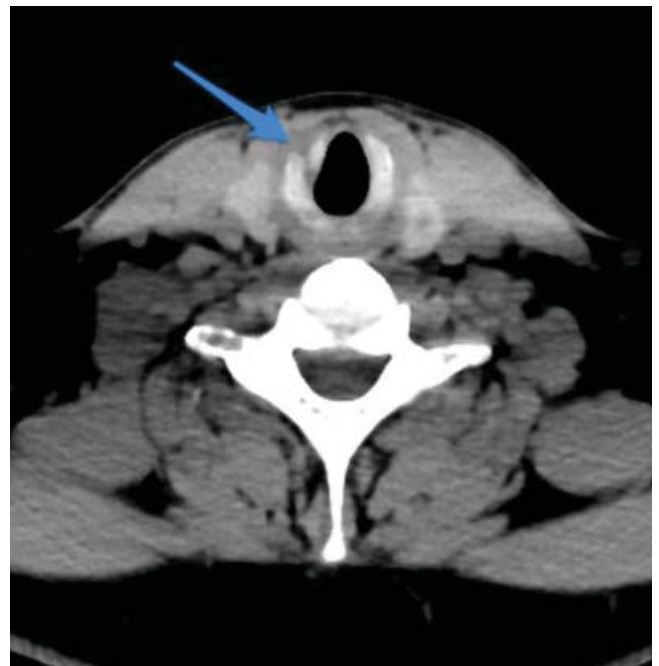.....  
Department of Surgery, Aga Khan University Hospital, Karachi, Pakistan.

**Correspondence:** Rahim Dhanani. Email: dr.rahimghanani@gmail.com

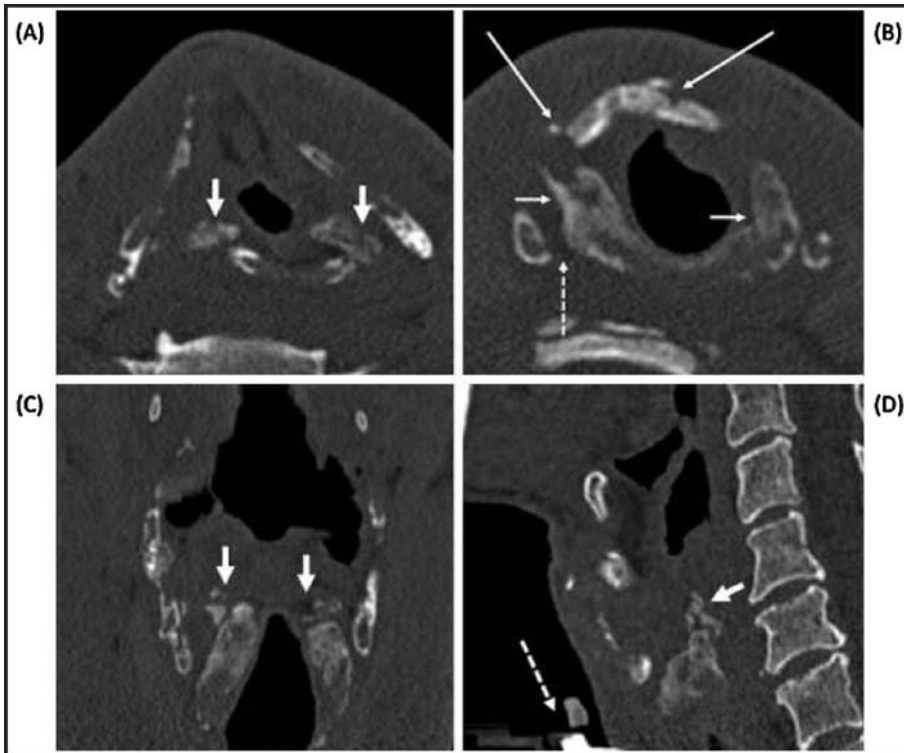
subcutaneous emphysema.

**Evaluation:** After establishment of airway full trauma assessment is needed to gauge the degree of injury and to look for injuries of other organs as the possibility of associated injuries with laryngeal trauma is very high.<sup>2</sup> A chest X-ray is the initial radiological modality to rule out pneumothorax, pneumomediastinum, subcutaneous emphysema or deviation of trachea.<sup>6</sup>

CT scan can help to identify the underlying laryngeal and pharyngeal injuries including fractures, dislocations and other associated injuries. Oesophagus is the most commonly involved adjacent organ in laryngotracheal trauma. CT scan helps in differentiating between the patients who would require surgical interventions to those who can be managed conservatively (Figure-1 & 2).<sup>7,8</sup> CT scan may not be indicated in case of open wound with obvious fracture where surgical exploration and repair is ultimate choice of treatment. CT angiogram can also be considered in case of suspected vascular injury.



**Figure-1:** Arrow showing Fracture of right anterior half of cricoids.



**Figure-2:** Multiple cartilage fractures. Axial bone window images at the glottic (A) and subglottic level (B), (C) and (D) showing coronal and sagittal windows.

Carotid artery is reported in the literature as the most commonly injured vessel associated with laryngotracheal trauma.<sup>9</sup>

Direct visualization of the airway on bedside with flexible fiber optic laryngoscopy should always be performed as it is very important in diagnosing airway injury at any level.<sup>6</sup> Rigid bronchoscopy is usually not needed. In cases where oesophageal injuries are suspected, oesophagoscopy and barium swallow are the options that should be obtained. Currently, MRI and MRA do not have any added advantage in the evaluation of laryngotracheal trauma.<sup>7</sup>

**Management:** The emergent measures that are needed to be taken without any significant delay include preservation of the airway, haemostasis, and stabilization of the spine.<sup>10</sup> However, because of the rarity of laryngeal injuries, they often go unrecognized. Various treatment modalities have been discussed in the literature. They may include observation with symptomatic treatment, fixation of the laryngeal fractures, or if the injury is significant then reconstruction of airway, be it tracheal or laryngeal, may be required. The first and foremost objective in case of laryngotracheal trauma is securing the airway and reconstructing it. Restoration of voice and swallowing are the long term goals that may be achieved

later in the order of management. The factors that decide the overall management include the site and mechanism of the injury. One must take in account the associated injuries when outlining the management. Table-1 shows non-operative management of laryngotracheal trauma. Table-2 shows Schaefer's classification<sup>10</sup> management of laryngotracheal trauma according to severity. Individual fractures can be managed individually as follow:

**Hyoid bone:** The fractures of hyoid bone are commonly witnessed as a result of road vehicle accidents, sports (martial arts, hockey, football and basket ball) and strangulations. Ramchand et al. did a review on 46 patients by who suffered fractures of the hyoid bone, surgical repair was only performed in five patients. Rest of the patients were treated symptomatically with analgesia, diet modifications and voice rest.<sup>11</sup>

The most common method of treatment of a fractured hyoid bone is nonsurgical management.<sup>12</sup>

**Thyroid cartilage:** Thyroid cartilage is known to ossify in early childhood. Ossification of thyroid and cricoid cartilage can impact the pattern of injury to it. An ossified thyroid cartilage can suffer multiple fractures. However, in a younger person, where the larynx is more elastic, it usually gets fractured at a single site. The thyroid cartilage, at the time of trauma, is forcefully impacted against the cervical spine posteriorly. On its impaction, thyroid cartilage suffers from a linear fracture anteriorly.<sup>12</sup>

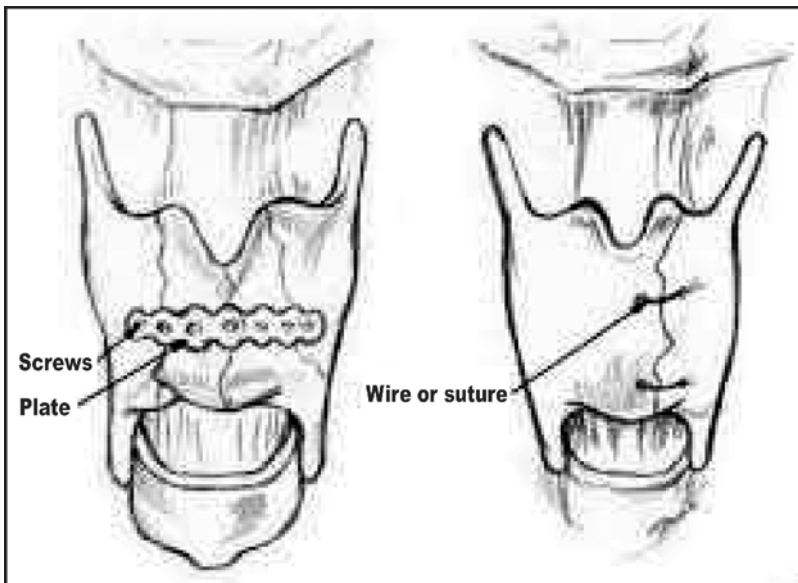
If the endoscopic examination of non-displaced fracture of the thyroid cartilage shows no signs of internal injuries,

**Table-1:** Non-operative management of laryngotracheal trauma.

Intervention	Purpose
Head of bed Elevation	May help to decrease laryngeal oedema and manage secretions
Voice rest	Minimizes exacerbation of laryngeal oedema
Cool humidified Air	Decreases ciliary paralysis to improve management of secretions
Steroids	No supporting data, however may help to reduce oedema
Anti-reflux medication	Prevents laryngeal inflammation from acid Reflux

**Table-2:** Evaluation and management based on the Schaefer Classification System (10).

Severity	Evaluation	Management
Minor endolaryngeal haematomas or lacerations without detectable fractures More severe oedema, haematoma, minor mucosal disruption without exposed cartilage, or non-displaced fractures	Flexible fiber-optic laryngoscopy  Direct laryngoscopy and oesophagoscopy	Medical management only, including: steroids, antibiotics, humidification, voice rest Serial examinations, since the injuries may worsen over time. These injuries infrequently require a tracheostomy. Helpful adjunctive medical treatments as described above
Massive oedema, large mucosal lacerations, exposed cartilage, displaced fractures or vocal cord immobility	Direct laryngoscopy and oesophagoscopy performed in the operating room	Tracheostomy and surgical repair are often required. Injuries requiring surgical repair include: disruption of the anterior commissure, major endolaryngeal lacerations, vocal cord tear, immobile vocal cord, cartilage exposure, displaced cartilage fractures
Same as group 3, but more severe with disruption of anterior larynx, unstable fractures, two or more fracture lines, or severe mucosal injuries Complete laryngotracheal separation	Direct laryngoscopy and esophagoscopy performed in the operating room  These patients present in severe respiratory distress and therefore endoscopic evaluation is delayed until an airway is secured	Tracheostomy is always required Surgical repair requires stent placement to maintain the integrity of the larynx Disruption of the airway usually occurs above or below the cricoid cartilage, either at the cricothyroid membrane or cricotracheal junction. The airway is usually temporarily established using an endotracheal tube inserted through the neck directly into trachea distal to the site of transection. A complex laryngotracheal repair is then performed through a low cervical incision.



**Figure-3:** Showing application of miniplates and suture on fractured thyroid cartilage.

such fracture should only be treated with supportive measures like keeping the head of bed elevated, voice rest and anti-reflux medications.

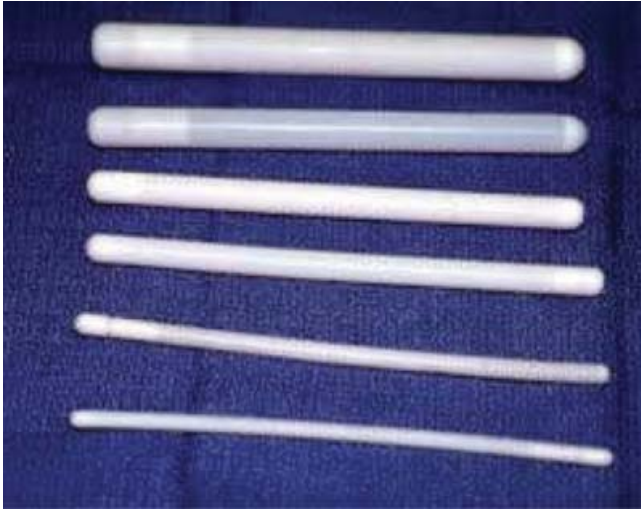Whenever the thyroid cartilage suffers an injury leading to a displaced fracture, it must undergo open reduction and fixation. Realignment can be done with various

substances, including a miniplate, a non-absorbable suture or a wire.

Fixation with a miniplate, because it promotes complete cartilaginous union, is known to be superior to a non-absorbable suture or a wire. Defects limited to the mucosa only can be repaired well by using absorbable sutures.<sup>13</sup> Figure-3 showing application of sutures and miniplates on a fractured thyroid cartilage.

**Stents:** Stents are used to prevent the adhesions of the raw mucosal surfaces formed as a result of extensive endolaryngeal injuries, or when there is disruption of the anterior commissure. Placing a stent in anterior commissure disruption helps to restrain the development of anterior glottis webs and it also has a role to keep the commissure in proper alignment. Stent placement can lead to certain complications like formation of granulation tissue or scar at the site of placement, infection and pressure necrosis. Pressure necrosis usually results when the stents used are larger than the airway. Commonly used are metal, silicone and hybrid. The appropriate choice of stent remains controversial and is usually surgeon-dependent, however the preferred stent is the silicone stent Figure-4 shows





**Figure-4:** Showing silicone stents of different sizes.

silicone stents of different size. The stent removal time, on average, is 2 weeks. Removal of the stent is carried out in the operating room.<sup>1</sup>

**Cricoid cartilage:** The cricoid cartilage is often injured in association with the fracture of thyroid cartilage. The fractures in which cricoid cartilage is non-displaced or are stable fractures, no surgical intervention is required and can be managed conservatively. Wire fixation and stent placement can be done for about four to six weeks if the fractured segments are displaced and unstable. Patients landing in emergency room with crush injury to cricoid ring should be managed with a tracheostomy to provide a safe airway. Later, once the edema has resolved, excision of the cricoid cartilage should be done. In the procedure of cricoid excision, only the anterior half of the cartilage is excised. The excised part can be reconstructed with the help of a graft taken either from a hyoid bone or rib cartilage.<sup>6</sup>

**Controversies:** There are four major controversial areas in the management of laryngo-tracheal trauma (i) management of airway initially (ii) diagnostic modality (iii) operative indication and timings and (iv) operative technique.<sup>14</sup>

Initial airway management is crucial in any laryngeal trauma. It can be achieved either by intubation or through emergency tracheostomy. Many authors prefer immediate tracheostomy over intubation rationalizing that intubation may cause further trauma to already tenuous trachea. Intubation too is difficult in such situation with presence of blood and edema in the upper airway. Proponents of intubation argue that tracheostomy in an already severed neck would be a potential for further

damage to other surrounding structures.<sup>15</sup> Schaefer, recommended following guidelines before intubation (i) The airway should be visible to direct inspection (ii) The larynx and trachea should be intact (iii) intubation shall be performed by a highly experienced physician.<sup>16</sup>

Evaluation of laryngotracheal structure is also a topic of controversy, Schafer recommended that in an obvious open injury where operative exploration is unavoidable, Laryngoscope or Bronchoscope should be preferred over CT scan. Subsequently if there is a history of blunt trauma and airway is not threatened then CT scan is a good imaging modality to review internal injuries. In selected cases it can help in avoiding any operative procedure at all.<sup>14,16</sup>

The timings of the operative procedure is debatable too, Nahum, Olson and Miles concluded that a waiting period of 4 to 5 days should be maintained to give time for laryngeal oedema to settle down.<sup>17,18</sup> however recent studies suggest that a delay of more than 24 hours causes poor outcomes in terms of increased difficulty in procedure, complication rate and poorer voice quality and airway post-surgery.<sup>19,20</sup>

The decision of open versus closed approach is greatly steered by the outcome. As reported by Leopold in his review that voice and airway outcomes were better with closed technique rather than open one.<sup>21</sup> When there is severe laryngotracheal injury open technique is preferred as it provides good exposure. Stenting and keel placement are other options for repairing of laryngotracheal trauma. In last few decades the use of stents has refined and with its reduced placement time, softer material, and synthetic fixing material it now plays a great role in restoring myoelastic aerodynamic properties of the larynx.<sup>16</sup>

**Latest advancements:** Laryngotracheal reconstruction (LTR) is a complex and challenging procedure. In past two decades much work has been done in this field ranging from simple grafting to reconstruction to tissue engineering. Up till now complete laryngotracheal regeneration is very far-fetched, but tissue regeneration at individual sites have shown some positive results.

**This concept is based upon three factors:** cell therapy, scaffolding therapy and growth factor therapy also known as tissue engineering triad. The cells for cell therapy can be procured endogenously by controlling behaviour of already present stem cells and exogenously induced adipose tissue-derived stromal cells (ASCs), human embryonic stem cells (hESCs), and bone marrow-derived mesenchymal stromal cells (BM-MSCs) among which latter two are more popular.

Scaffolding material provides a suitable environment for cell infiltration, proliferation and regeneration which is essential for tissue restoration. Scaffolding material has to be biocompatible as well as biodegradable. Hyaluronic acid and Atelocollagen are commonly used as regenerative scaffold. Basic fibroblast growth (bFGF) factor and hepatocyte growth factor (HGF) are the more popular and more successful of the regulatory factors. They have strong anti-fibrotic and restorative effects.

These options are well suited for muscular and mucosal regeneration but cartilaginous regeneration is yet to be achieved. In trauma where there is total destruction of larynx and trachea laryngo-tracheal transplant can be considered. Laryngo-tracheal transplant apart from restoring the physiological function of larynx also provides great improvement in quality of life.<sup>22</sup>

A laryngotracheal transplant was performed by Dr. Farwell which produced successful results. The laryngeal framework along with the adjacent thyroid and parathyroid glands and the feeding vessels were harvested from the donor. After 2 weeks of surgery the patient

was able to use her vocal cords, was able to swallow and with physiotherapy was able to speak again.<sup>23</sup>

## Conclusion

Laryngotracheal trauma is rare but can pose serious threats to one's life. High level of suspicion should be practiced and immediate care should be provided to prevent complications. Recent advances in tissue regeneration have added a new horizon in the management of laryngotracheal trauma. More work needs to be done in this less explored field including laryngeal transplantation.

**Acknowledgements:** None.

**Conflict of Interest:** None.

**Disclosure:** None.

## References

1. Lee WT, Eliashar R, Eliachar I. Acute external laryngotracheal trauma: diagnosis and management. *Ear Nose Throat J* 2006;85:179-84.
2. Moonsamy P, Sachdeva UM, Morse CR. Management of laryngotracheal trauma. *Ann Cardiothorac Surg* 2018;7:210-216. doi: 10.21037/acs.2018.03.03.
3. Kelly JP, Webb WR, Moulder PV, Moustouakas NM, Lirtzman M. Management of airway trauma. II: Combined injuries of the trachea and esophagus. *Ann Thorac Surg* 1987;43:160-3.
4. Minto DG, Ratliff W, Legan Z. Laryngeal fractures-diagnosis and management. *J Oral Maxillofac Surg* 2016;74:e91.
5. Akhtar S, Awan S. Laryngotracheal trauma: its management and sequelae. *J Pak Med Assoc* 2008;58:241-3.
6. Bhojani RA, Rosenbaum DH, Dikmen E, Paul M, Atkins BZ, Zonies D, et al. Contemporary assessment of laryngotracheal trauma. *J Thorac Cardiovasc Surg* 2005;130:426-32.
7. Parida PK, Kalaiarasi R, Alexander A. Management of Laryngotracheal Trauma: A Five-Year Single Institution Experience. *Iran J Otorhinolaryngol* 2018;30:283-290.
8. Becker M, Leuchter I, Platon A, Becker CD, Dulguerov P, Varoquaux A. Imaging of laryngeal trauma. *Eur J Radiol* 2014;83:142-54. doi: 10.1016/j.ejrad.2013.10.021.
9. van Roozendaal LM, van Gool MH, Sprooten RTM, Maesen BAE, Poeze M, Hulsewé KWE, et al. Surgical treatment of bronchial rupture in blunt chest trauma: a review of literature. *J Thorac Dis* 2018;10:5576-5583. doi: 10.21037/jtd.2018.08.22.
10. Schaefer SD, Close LG. Acute management of laryngeal trauma. Update. *Ann Otol Rhinol Laryngol* 1989;98:98-104.
11. Ramchand T, Choudhry OJ, Shukla PA, Tomovic S, Kuperan AB, Eloy JA. Management of hyoid bone fractures: a systematic review. *Otolaryngol Head Neck Surg* 2012;147:204-8. doi: 10.1177/0194599812451409.
12. Gluckman JL, Mangal AK. Laryngeal trauma. In: Paparella MM, Shumrick DA, Gluckman JL, Meyerhoff WL, eds. *Otolaryngology: Head and neck 3rd ed.* Philadelphia, USA: Saunders, 1991; pp 223.
13. Sniezek JC, Thomas RW. Laryngeal Trauma. In: *Resident Manual of Trauma to the Face, Head and Neck, 1st ed.* Alexandria, VA: American Academy of Otolaryngology, 2012; pp 177-87.
14. Gussack GS, Jurkovich GJ. Treatment dilemmas in laryngotracheal trauma. *J Trauma* 1988;28:1439-44.
15. Hwang SY, Yeak SC. Management dilemmas in laryngeal trauma. *J Laryngol Otol* 2004;118:325-8.
16. Schaefer SD. Management of acute blunt and penetrating external laryngeal trauma. *Laryngoscope* 2014;124:233-44. doi: 10.1002/lary.24068.
17. Nahum AM. Immediate care of acute blunt laryngeal trauma. *J Trauma* 1969;9:112-25.
18. Olson NR, Miles WK. Treatment of acute blunt laryngeal injuries. *Ann Otol Rhinol Laryngol* 1971;80:704-9.
19. Gussack GS, Jurkovich GJ, Luteran A. Laryngotracheal trauma: a protocol approach to a rare injury. *Laryngoscope* 1986;96:660-5.
20. Downey WL, Owen RC, Ward PH. Traumatic laryngeal injury--its management and sequelae. *South Med J* 1967;60:756-61.
21. Leopold DA. Laryngeal trauma. A historical comparison of treatment methods. *Arch Otolaryngol* 1983;109:106-12.
22. Farwell DG, Birchall MA, Macchiarini P, Luu QC, de Mattos AM, Gallay BJ, et al. Laryngotracheal transplantation: technical modifications and functional outcomes. *Laryngoscope* 2013;123:2502-8. doi: 10.1002/lary.24053.
23. Etienne H, Fabre D, Gomez Caro A, Kolb F, Mussot S, Mercier O, et al. Tracheal replacement. *Eur Respir J* 2018;51:e1702211. doi: 10.1183/13993003.02211-2017.