



THE AGA KHAN UNIVERSITY

eCommons@AKU

Section of Orthopaedic Surgery

Department of Surgery

2-1-2020

A comprehensive basic understanding of pelvis and acetabular fractures after high-energy trauma with associated injuries: Narrative review of targeted literature


Muhammad Atif

Obada Hussein Hasan

Naveed Baloch

Masood Umer

Follow this and additional works at: https://ecommons.aku.edu/pakistan_fhs_mc_surg_orthop

 Part of the [Musculoskeletal Diseases Commons](#), [Orthopedics Commons](#), [Surgery Commons](#), and the [Trauma Commons](#)

NARRATIVE REVIEW

A comprehensive basic understanding of pelvis and acetabular fractures after high-energy trauma with associated injuries: Narrative review of targeted literature

Muhammad Atif, Obada Hasan, Naveed Baloch, Masood Umer

Abstract

Acetabular fractures are caused by energy trauma which is high enough to cause such a fracture with incidence of 3 patients / 100000. In older individuals, most common mechanism of injury is fall and, in younger individuals, road traffic accidents. Acetabular fractures are usually associated with visceral injuries and other musculoskeletal injuries (about 50% of patient). In this narrative review of targeted English literature from all level of evidences, which is written and supervised by experienced specialized orthopedic and trauma surgeons who were among the pioneers of conducting pelvis fracture management workshops in the country, we aim to describe the mechanism of injury, assessment principles and associated injuries, decision-making and preoperative planning and indications of non-operative managements.

Keywords: Acetabular fracture, Pelvic trauma, Review, Narrative.

Introduction

Acetabular fractures are caused by high energy trauma with incidence of 3 patients / 100000. In older patients (>60 years), most common mechanism of injury is a fall while in younger patients, it is mostly secondary to a road traffic accident.¹ Impaction of femoral head with articular surface of acetabulum results in a fracture.² Direction of force which damages head passes either through greater trochanter or along the axis of the femoral shaft. Fracture of acetabulum depends upon direction, location and position of the hip at the time of impaction. Hence in external rotation anterior fracture will be produced by a force traversing femoral neck on the other hand; internal rotation will produce posterior fracture. Acetabular fractures are usually associated with visceral injuries and other musculoskeletal injuries³ in about 50% of patients.⁴ Studies by Matta reveal that 35 percent of acetabular fractures are associated with extremity injury, 19% having

head injuries, chest injuries are found in 18 percent, nerve palsy in 13 percent, 8% with abdominal injuries, genitourinary involve 6 percent and spine injuries are the cause in 4 percent patients.³ In one study, it was observed that most common injury was of the lower extremity (36%) followed by lung, retroperitoneal and upper extremity (21% to 26%). However 2% to 16% injuries include bowel, kidney, bladder, liver, spleen, brain, spine and vascular injuries.⁵ As these fractures are associated with other systemic injuries, careful assessment should be made. Studies have reported that even isolated injuries required blood transfusion in 35% of patients.⁶ Standard guideline and ATLS protocol should be followed to rule out fatal injuries.⁷⁻⁹ Usually Operative treatment of acetabulum is not performed as an emergency case unless it is associated with irreducible dislocation of hip to prevent osteonecrosis of head or open fracture. In this narrative review of targeted literature, which is written and supervised by experienced specialized orthopaedic and trauma surgeons who were among the pioneers of conducting pelvis fracture management workshops in the country, we aim to describe the mechanism of injury, assessment principles and associated injuries, decision-making and preoperative planning and indications of non-operative managements.

Discussion

Anatomy of acetabulum: Acetabulum is a three dimensional structure. Accurate knowledge of anatomy is essential for proper assessment of fracture pattern and for making plan of how to fix it with excellent acceptable outcomes. Acetabulum is an incomplete hemispherical socket having horse shoe shaped articular surface with non-articular surface called cotyloid fossa. Socket of acetabulum is supported by two column of bone in inverted Y.^{2,10} These two columns are called anterior and posterior column. Anterior column consists of anterior half iliac crest, iliac spines, anterior half of acetabulum and pubis. Posterior column has ischium, ischial spine, posterior half of acetabulum and dense bone forming sciatic notch. Sciatic buttress connects these columns to sacroiliac articulation. Column concept is used to classify acetabular fractures. Roof or dome of acetabulum is

.....
Department of Surgery, Section of orthopedics, Aga Khan University Hospital, Karachi, Pakistan.

Correspondence: Obada Hasan. Email: obada.husseinali@gmail.com

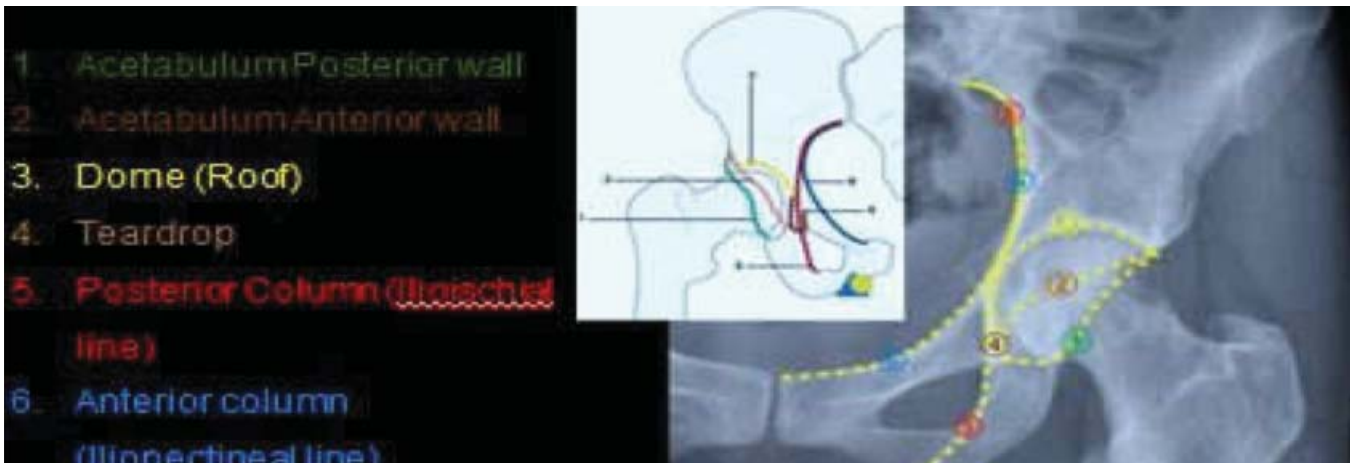

Figure-1: Anatomy and radiological lines on antero-posterior plain radiograph of pelvis.

weight bearing area of the acetabulum. Anatomic restoration of dome with concentric reduction of femoralhead is the ultimate goal of operative and non-operative treatment. Quadrilateral surface forms lateral border of true pelvis.² Radiological anatomy is equally important in evaluating these critical patients (Figure-1).

Presentation of patient: Patient with acetabular fracture usually presents with high energy trauma with associated injuries as described above. However in elderly patients ground level fall is a common presentation. Mechanism of injury determines the pattern of fracture like fall from height, direct blow injury, driver having road traffic accident while driving and pedestrian struck by vehicle. Patient may complain of pain at knee due to knee injury (bony or ligamentous). In osteoporotic bone, low energy trauma (history of fall) is usual cause of fracture. It is crucial to investigate possible reason of fall in these patients. They may have underlying medical condition involving cardiac or neurologic component. Patients with history of trauma must be evaluated with ATLS protocol to find out immediate life threatening or limb threatening conditions. In general orthopedic examinations include careful examination of whole musculoskeletal and^{11,12} peripheral neurovascular examination with documentation. In polytrauma patients and patients with head injury, should be evaluated carefully to prevent missed injuries. Such patients usually are found to have skeletal injuries which were not identified at initial presentation. Morel-Lavalle lesion¹³ is a deep local closed soft tissue injury with internal degloving around the inguinal region and flanks which may become infected leading to wound infection, sepsis and septicaemia. In such cases, delayed wound closure and fracture fixation is required.

Neurological examination is important for patient

prognosis. Fracture of posterior acetabular wall or column with dislocation is commonly found to be associated with sciatic nerve injury, which most of the time involve peroneal division.^{14,15} Injury may vary with either isolated sensory or motor component or loss of individual muscle. So it is important to examine active ankle and toe dorsiflexion and planter flexion individually. Hip adductors and quadriceps femoris muscle help in evaluating obturator and femoral nerves respectively. Limb shortening is an important finding for hip dislocation or posterior acetabular all fracture and should be evaluated.¹⁴

Radiological assessment: Letournel and Judet described that anteroposterior pelvis and Judet views (two 45 degree oblique views) are used to determine radiographic anatomy of acetabulum. Radiographic classification of acetabular fracture is based on work of Letournel and Judet by using three different radiographic views (anteroposterior pelvis, obturator (45-degree internal Judet view) oblique view or iliac (45-degree external Judet) oblique view). There are six basic landmarks on AP view of pelvis. These are the ilioischial, iliopectineal, tear drop, the roof of acetabulum, anterior and posterior rim of acetabulum. Acetabular fractures are classified in view of disruption of these landmarks. For example, fracture that disrupts iliopectineal line will produce

Table-1: Letournel Classification of Acetabular Fractures.³⁹

Elementary Fracture Patterns	Associated Fracture Patterns
Posterior wall	Posterior column and posterior wall
Posterior column	Transverse and posterior wall
Anterior wall	Anterior column(or wall) and posterior hemitransverse
Anterior column	T-shaped
Transverse	Both column

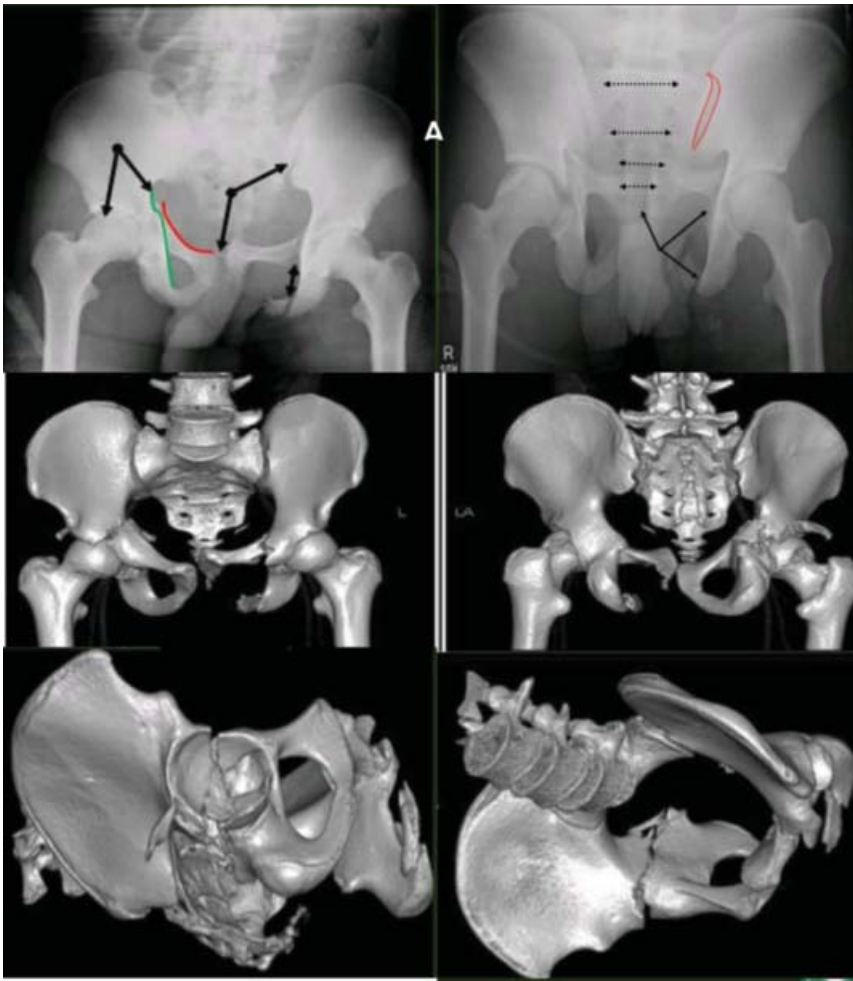


Figure-2: A 17 Years old boy presented to Emergency Department after a run over injury by truck, vitals, abdominal and rectal examination was unremarkable. He was catheterized and no hematuria was present. Trauma team cleared the patient for surgery. A: Preoperative radiographs showing right acetabulum transverse comminuted fracture, anterior column disruption, left pubic rami fracture and sacroiliac joint disruption. B: CT scan of pelvis with 3D reconstruction confirming the findings and helping in preoperative planning.

anteriorcolumn fracture while posterior column fracture is produced by disruption of ilioischialline. These lines are also helpful and used as a guide in operating room for restoring fracture anatomy in acetabular fractures.

CT scan is helpful in delineating anatomy of pelvis but it has not replaced the radiograph. Axial cuts should be taken in a thin interval of 3mm. The CT scan of entire pelvis is mandatory to identify missed injury and it is helpful in comparison with opposite side. Better assessment of fracture configuration, intra-articular fragments and impaction can be done on CT scan^{14,16} (Figure-2, 3).

Treatment

Non-operative treatment: Concentrically reduced stable

hip that does not have superior acetabulum dome as a part of fracture can be managed non-operatively.¹⁷⁻²⁰ It comprises of non-displaced or minimally displaced fracture and patients with secondary congruence (displaced both column fracture), medical contraindication to surgery,^{21,22} Other indications include low anterior column, low transverse, low T-shape fractures, wall fracture without compromising stability and severe osteoporosis. These patients should be followed weekly with radiographs to make sure adequate reduction. Patients need bed rest in the acute phase of injury to progress to hip range of motion and partial weight bearing. It usually takes 6 to 12 weeks for the fracture to heal. Later the patient is mobilized for full weight bearing.²³

Prognosis of acetabular fracture strongly depends on involvement of acetabulum dome.²³ Upper third of acetabulum weight bearing area is called Roof of acetabulum (superior dome). Osion and Matta observed axial CT sections and proposed that upper 10mm articular surface is equivalent to acetabulum dome. It is helpful in demonstrating whether the acetabulum line passes through this region. Non-operative treatment is more favoured as it has a displacement less than two mm (<2mm).^{10,18,19}

Roof-arc angle is measured by Matta to determine whether remaining acetabulum is sufficient to maintain stable and congruous relationship with the head of the femur. Decision of operative vs. non-operative treatment can be decided on measuring angle.¹⁸ It is calculated by using all three radiographic films without traction. Medial, Anterior and Posterior roof-arc is measured on radiograph by using AP, Obturator and iliac oblique views respectively. To measure this angle, a vertical line is placed through the centre of head of femur and a second line is traced from centre of femoral head to articular surface fracture of acetabulum at particular view. Both column fracture and posterior wall fracture are exempted from these calculations. It is recommended that fracture having medial roof-arc angle greater than 45 degrees, anterior angle of greater than 25 degrees and posterior angle of greater than 70 degrees is considered for non-operative management.

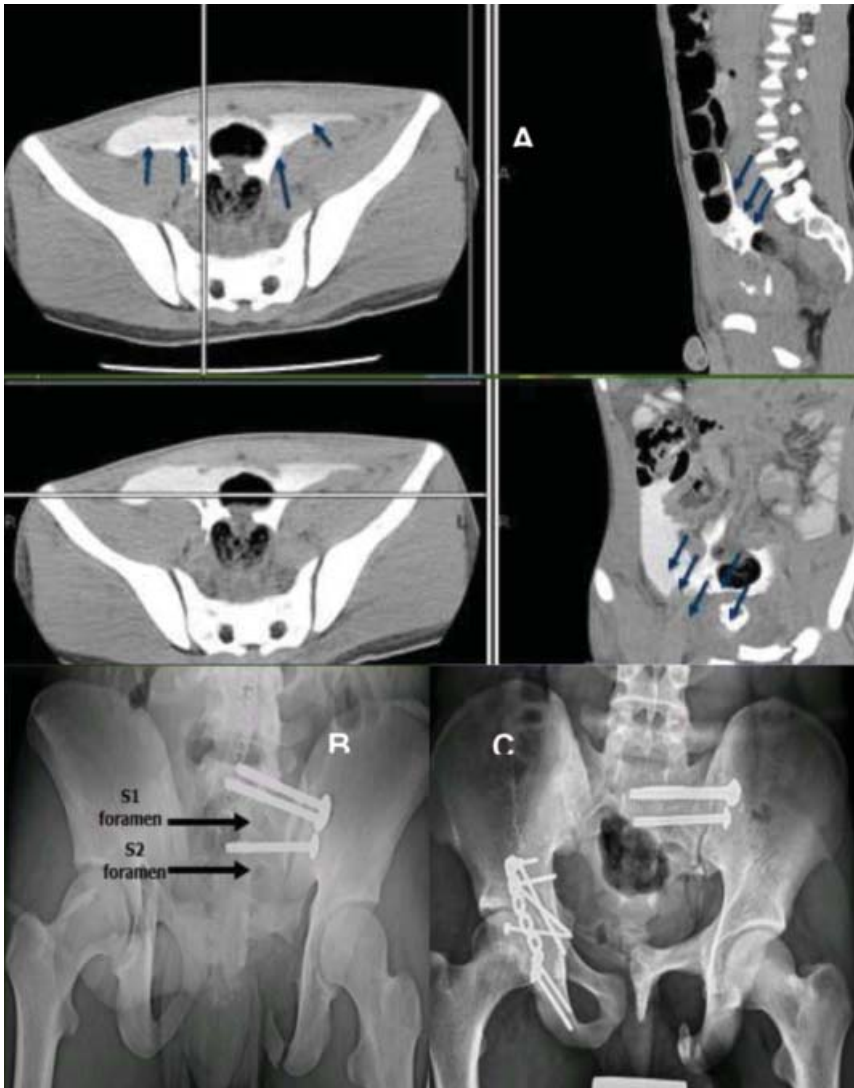


Figure-3: Same patient in figure 1. He had a fever spikes and abdominal tenderness while admitted in the special care unit. A: CT scan showing intraperitoneal extravasation of contrast and peritonitis due to ruptured bladder which was missed at time of presentation. This was controlled surgically followed by left sacroiliac joint and then acetabulum fixation as in the pelvis outlet view in B. C: Two years follow-up radiographs showing union of the fracture with preserved hip joint and head of femur.

Operative Management: All acetabular fractures with joint instability and/or incongruity are amenable to operative fixation regardless of classification type. In general acetabular fracture is not treated on emergent basis. Three to five days delay is usually acceptable for proper preoperative planning, further evaluation of patient associated injuries and optimization of the patient.^{24,26} Radiological and clinical outcome are dependant on time to surgery, in elementary fractures, surgery should not be delayed more than 15 days and with associated injuries, not more than 10 days.²⁷ Recurrent hip dislocation despite of reduction,

irreducible hip dislocation, progressive sciatic nerve deficit, open fracture, associated vascular injury and ipsilateral femoral neck fracture are emergency indications for acetabular fracture fixation.²⁸

Selection of Proper Surgical Approach:

It is a crucial aspect of pre-operative fracture fixation planning. However, fracture configuration, delay in primary surgery and fracture displacement are main factors contributing in decision making. Judet et al has effectively demonstrated various surgical approaches including Kocher-Langenbeck, Iliofemoral, ilioinguinal and extended iliofemoral.¹⁸ These approaches give exposure to one column and you have to reduce the opposite column indirectly. However extended iliofemoral approaches gives access to all aspects of acetabulum and are commonly employed in delayed surgical management of associated fractures. Various other approaches have been added in literature including modified Gibson approach, the modified Stoppa approach,²⁹ Trochanteric flip osteotomy and combined anterior and posterior approaches. We are not addressing the details of surgical approaches and technique and method of fracture fixation. Figure-4 demonstrates the patient's prone position to fix the posterior column and posterior wall fracture, pelvis model is on the table beside the surgeon to guide the 3D structure of the pelvis and acetabulum.

Complications

Arthritis after acetabular fracture is a common complication.³⁰ Adequate reduction is required to prevent complications. Studies showed better long-term outcomes in fracture reduction to within 1 mm of displacement. Patient may need replacement in advance arthritis.^{31,32} There is 5% infection rate in patients with acetabular fracture,³⁶ which increased with soft tissue injury,³⁰ open fracture, gastrointestinal and urological injuries. Embolization of pelvic arteries increases risk of infection after open reduction and internal fixation.^{33,34} Obesity increases complications and hospital stay³⁵ and adds 5% increased risk of infection as compared to a normal patient.

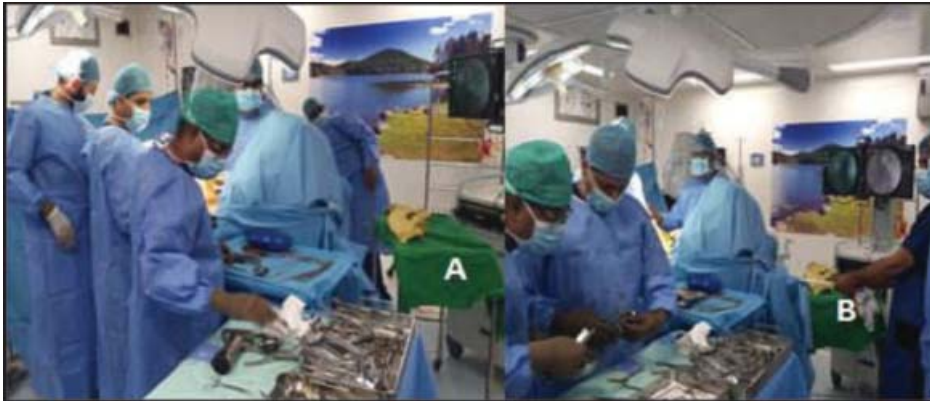

Figure-4: The operation Theatre setting. Note in (A) The pelvis model is beside the surgeon to help guide in screws and plate fixation as a 3D- model. Moreover as in (B) the assistant who is doing traction which is connected to skeletal traction in distal femur.

If infection involves the joint, results are bad with complete joint destruction. This usually occurs in conditions where the joint has been exposed (Kocher-Lahgenbeck or extended approach). In ilioinguinal approach, results are better because of indirect joint reduction and decreased soft tissue dissection, hence preserving local blood supply. Management of infection is same as musculoskeletal infection in the rest of the body.

Iatrogenic nerve injury can occur to superior and inferior gluteal nerve, obturator femoral nerve. The most common nerve injury is sciatic nerve injury.³⁶ These injuries may occur in extended approaches. Preventive measures with careful patient positioning, shifting and dissection can minimize this injury. Recovery of functions is variable; it may take three years for recovery. Management of sciatic nerve injury includes ankle-foot orthosis, physical therapy, observation and neurogenic pain medications. Release of nerve from heterotrophic bone and scar tissue is helpful. In case of femoral nerve, ambulation is difficult and may need bracing.

Venous thromboembolism is common with acetabular fracture (either post-traumatic or postoperative). In one study, 13(2.6%) deaths were reported after surgery of which 4 were due to massive pulmonary embolism.¹⁰

Incidence of heterotrophic ossification is high about 90% (ranges 18% to 90%) of patients. Loss of 20% of hip movements is considered as severe heterotrophic ossification. Excision is needed after maturation. Post-operative radiotherapy or indomethacin are used for post-excision prophylaxis.^{37,38}

Conclusion

Acetabular fractures are complicated fractures and associated with multiple visceral injuries, which if missed

at presentation, can become catastrophic and fatal. These patients should be assessed according to ATLS protocol and then referred to specialist trauma and orthopaedic surgeons. Radiological studies are very important in classification and decision-making. Needless to say, thorough understanding of anatomy is the key for successful fixation.

Strengths, Limitations and Future Study Recommendations

This is a narrative review of targeted literature simplifying this complex topic from its different angles. This work was done and supervised by experienced specialized orthopaedic and trauma surgeons who were among the pioneers of conducting pelvis fracture management workshops in the country in the last decade. Among main limitation of the study, is that we did not conduct a systematic review of all present literature. We recommend systematic reviews and meta-analyses focusing on the management of such injuries and including, but not limited to, associated injuries and the long term outcomes of surgical Vs conservative management.

Disclaimer: None.

Financial Support and Sponsorship: Nil.

Conflicts of Interest: There are no conflicts of interest.

Guarantor: All authors listed take full responsibility.

ERC Requirement: Exempted as it is a narrative review article.

References

1. Laird A, Keating JF. Acetabular fractures: a 16-year prospective epidemiological study. *The Journal of bone and joint surgery British volume.* 2005;87(7):969-73.
2. Judet R, Judet J, Letournel E. FRACTURES OF THE ACETABULUM: CLASSIFICATION AND SURGICAL APPROACHES FOR OPEN REDUCTION. PRELIMINARY REPORT. *The Journal of bone and joint surgery American volume.* 1964;46:1615-46.
3. Matta JMJOTD. Fracture of the acetabulum: accuracy of reduction and clinical results in patients managed operatively within three weeks after the injury. *The Journal of bone and joint surgery American volume.* 2011;9(02):31-6.
4. Kregor PJ, Templeman D. Associated injuries complicating the management of acetabular fractures: review and case studies. *The Orthopedic clinics of North America.* 2002;33(1):73-95, viii.
5. Porter SE, Schroeder AC, Dzigan SS, Graves ML, Zhang L, Russell GV. Acetabular fracture patterns and their associated injuries.

- Journal of orthopaedic trauma. 2008;22(3):165-70.
6. Ebraheim NA, Savolaine ER, Hoeflinger MJ, Jackson WT. Radiological diagnosis of screw penetration of the hip joint in acetabular fracture reconstruction. *Journal of orthopaedic trauma*. 1989;3(3):196-201.
 7. Stahel PF, Moore EE. *Modern Strategies for the Management of High-Energy Pelvic Fractures in the Twenty-First Century. Operative Techniques and Recent Advances in Acute Care and Emergency Surgery*; Springer; 2019. p. 261-71.
 8. Stahel PF, Burlew CC, Moore EE. Current trends in the management of hemodynamically unstable pelvic ring injuries. *Current opinion in critical care*. 2017;23(6):511-9.
 9. Kortbeek JB, Al Turki SA, Ali J, Antoine JA, Bouillon B, Brasel K, et al. *Advanced trauma life support, 8th edition, the evidence for change*. *The Journal of trauma*. 2008;64(6):1638-50.
 10. Letournel E, Judet R. *Fractures of the acetabulum*: Springer Science & Business Media; 2012.
 11. Blum L, Hake ME, Charles R, Conlan T, Rojas D, Martin MT, et al. Vertical shear pelvic injury: evaluation, management, and fixation strategies. *International orthopaedics*. 2018;42(11):2663-74.
 12. Barcellos ALL, da Rocha VM, Guimaraes JAM. Current concepts in spondylopelvic dissociation. *Injury*. 2017;48 Suppl 6:S5-s11.
 13. Hak DJ, Olson SA, Matta JM. Diagnosis and management of closed internal degloving injuries associated with pelvic and acetabular fractures: the Morel-Lavallee lesion. *The Journal of trauma*. 1997;42(6):1046-51.
 14. Moed BR, WillsonCarr SE, Watson JT. Results of operative treatment of fractures of the posterior wall of the acetabulum. *The Journal of bone and joint surgery American volume*. 2002;84(5):752-8.
 15. Helfet DL, Schmeling GJ. Somatosensory evoked potential monitoring in the surgical treatment of acute, displaced acetabular fractures. Results of a prospective study. *Clinical orthopaedics and related research*. 1994(301):213-20.
 16. Tile M, Helfet D, Kellam J. *Fractures of the pelvis and acetabulum*: Lippincott Williams & Wilkins; 2003.
 17. Makhni MC, Makhni EC, Swart EF, Day CS. *Acetabular Fractures. Orthopedic Emergencies*: Springer; 2017. p. 245-9.
 18. Heeg M, Otter N, Klasen HJ. Anterior column fractures of the acetabulum. *The Journal of bone and joint surgery British volume*. 1992;74(4):554-7.
 19. Olson SA, Matta JM. The computerized tomography subchondral arc: a new method of assessing acetabular articular continuity after fracture (a preliminary report). *Journal of orthopaedic trauma*. 1993;7(5):402-13.
 20. Mears DC, Velyvis JH, Chang CP. Displaced acetabular fractures managed operatively: indicators of outcome. *Clinical orthopaedics and related research*. 2003(407):173-86.
 21. Johnson EE, Matta JM, Mast JW, Letournel E. Delayed reconstruction of acetabular fractures 21-120 days following injury. *Clinical orthopaedics and related research*. 1994(305):20-30.
 22. Gorczyca JT, Powell JN, Tile M. Lateral extension of the ilioinguinal incision in the operative treatment of acetabulum fractures. *Injury*. 1995;26(3):207-12.
 23. Templeman DC, Olson S, Moed BR, Duwelius P, Matta JM. Surgical treatment of acetabular fractures. *Instructional course lectures*. 1999;48:481-96.
 24. Tosounidis TH, Giannoudis VP, Kanakaris NK, Giannoudis PV. The Kocher-Langenbeck Approach: State of the Art. *JBJS essential surgical techniques*. 2018;8(2):e18.
 25. Starr AJ, Watson JT, Reinert CM, Jones AL, Whitlock S, Griffin DR, et al. Complications following the "T extensile" approach: a modified extensile approach for acetabular fracture surgery-report of forty-three patients. *Journal of orthopaedic trauma*. 2002;16(8):535-42.
 26. Vailas JC, Hurwitz S, Wiesel SW. Posterior acetabular fracture-dislocations: fragment size, joint capsule, and stability. *The Journal of trauma*. 1989;29(11):1494-6.
 27. Wright R, Barrett K, Christie MJ, Johnson KD. Acetabular fractures: long-term follow-up of open reduction and internal fixation. *Journal of orthopaedic trauma*. 1994;8(5):397-403.
 28. Halawi MJ. Pelvic ring injuries: Surgical management and long-term outcomes. *Journal of clinical orthopaedics and trauma*. 2016;7(1):1-6.
 29. Verbeek DO, Ponsen KJ, van Heijl M, Goslings JC. Modified Stoppa approach for operative treatment of acetabular fractures: 10-year experience and mid-term follow-up. *Injury*. 2018;49(6):1137-40.
 30. Mayo KA. Open reduction and internal fixation of fractures of the acetabulum. Results in 163 fractures. *Clinical orthopaedics and related research*. 1994(305):31-7.
 31. Minhas MS. Traumatic hip dislocations in children. *JPMA The Journal of the Pakistan Medical Association*. 2010;60(12):1019-22.
 32. Rollmann MF, Holstein JH, Pohlemann T, Herath SC, Histing T, Braun BJ, et al. Predictors for secondary hip osteoarthritis after acetabular fractures-a pelvic registry study. *International orthopaedics*. 2019;43(9):2167-73.
 33. Manson TT, Perdue PW, Pollak AN, O'Toole RV. Embolization of pelvic arterial injury is a risk factor for deep infection after acetabular fracture surgery. *Journal of orthopaedic trauma*. 2013;27(1):11-5.
 34. Sagi HC, Dziadosz D, Mir H, Virani N, Olson C. Obesity, leukocytosis, embolization, and injury severity increase the risk for deep postoperative wound infection after pelvic and acetabular surgery. *Journal of orthopaedic trauma*. 2013;27(1):6-10.
 35. Carson JT, Shah SG, Ortega G, Thamyongkit S, Hasenboehler EA, Shafiq B. Complications of pelvic and acetabular fractures in 1331 morbidly obese patients (BMI \geq 40): a retrospective observational study from the National Trauma Data Bank. *Patient safety in surgery*. 2018;12:26.
 36. Tidermark J, Blomfeldt R, Ponzer S, Soderqvist A, Tornkvist H. Primary total hip arthroplasty with a Burch-Schneider antiprotusion cage and autologous bone grafting for acetabular fractures in elderly patients. *Journal of orthopaedic trauma*. 2003;17(3):193-7.
 37. Bosse MJ, Poka A, Reinert CM, Ellwanger F, Slawson R, McDevitt ER. Heterotopic ossification as a complication of acetabular fracture. Prophylaxis with low-dose irradiation. *The Journal of bone and joint surgery American volume*. 1988;70(8):1231-7.
 38. Nauth A, Giles E, Potter BK, Nesti LJ, O'Brien F P, Bosse MJ, et al. Heterotopic ossification in orthopaedic trauma. *Journal of orthopaedic trauma*. 2012;26(12):684-8.
 39. Butler BA, Lawton CD, Hashmi SZ, Stover MD. The Relevance of the Judet and Letournel Acetabular Fracture Classification System in the Modern Era: A Review. *Journal of orthopaedic trauma*. 2019;33 Suppl 2:S3-s7.