



Universiteit
Leiden
The Netherlands

IDH1 and IDH2 mutations are frequent events in central chondrosarcoma and central and periosteal chondromas but not in other mesenchymal tumours

Amary, M.F.; Bacsı, K.; Maggiani, F.; Damato, S.; Halai, D.; Berisha, F.; ... ; Flanagan, A.M.

Citation

Amary, M. F., Bacsı, K., Maggiani, F., Damato, S., Halai, D., Berisha, F., ... Flanagan, A. M. (2011). IDH1 and IDH2 mutations are frequent events in central chondrosarcoma and central and periosteal chondromas but not in other mesenchymal tumours. *The Journal Of Pathology*, 224(3), 334-343. doi:10.1002/path.2913

Version: Not Applicable (or Unknown)

License: [Licensed under Article 25fa Copyright Act/Law \(Amendment Taverne\)](#)

Downloaded from: <https://hdl.handle.net/1887/108488>

Note: To cite this publication please use the final published version (if applicable).

IDH1 and IDH2 mutations are frequent events in central chondrosarcoma and central and periosteal chondromas but not in other mesenchymal tumours

M Fernanda Amary,¹ Krisztian Bacsi,^{1#} Francesca Maggiani,^{1#} Stephen Damato,¹ Dina Halai,¹ Fitim Berisha,¹ Robin Pollock,² Paul O'Donnell,³ Anita Grigoriadis,⁴ Tim Diss,⁵ Malihe Eskandarpour,⁶ Nadège Presneau,⁶ Pancras CW Hogendoorn,⁷ Andrew Futreal,⁸ Roberto Tirabosco¹ and Adrienne M Flanagan^{1,6*}

¹ Department of Histopathology, Royal National Orthopaedic Hospital NHS Trust, Stanmore, UK

² Bone Tumour Unit, Royal National Orthopaedic Hospital NHS Trust, Stanmore, UK

³ Department of Radiology, Royal National Orthopaedic Hospital NHS Trust, Stanmore, UK

⁴ Breakthrough Breast Cancer Research Unit, Guy's Hospital, King's Health Partners Academic Health Science Centres, London, UK

⁵ Department of Cellular Pathology University College London Hospital Foundation Trust, London, UK

⁶ UCL Cancer Institute, London, UK

⁷ Leiden University Medical Centre, The Netherlands

⁸ Wellcome Trust Sanger Institute, Hinxton, UK

*Correspondence to: Adrienne M Flanagan, Institute of Orthopaedics and Musculoskeletal Science, UCL, The Royal National Orthopaedic Hospital, Brockley Hill, Stanmore, Middlesex HA7 4LP, UK. e-mail: a.flanagan@ucl.ac.uk

#These authors contributed equally to this study.

Abstract

Somatic mutations in isocitrate dehydrogenase 1 (*IDH1*) and *IDH2* occur in gliomas and acute myeloid leukaemia (AML). Since patients with multiple enchondromas have occasionally been reported to have these conditions, we hypothesized that the same mutations would occur in cartilaginous neoplasms. Approximately 1200 mesenchymal tumours, including 220 cartilaginous tumours, 222 osteosarcomas and another ~750 bone and soft tissue tumours, were screened for *IDH1* R132 mutations, using Sequenom[®] mass spectrometry. Cartilaginous tumours and chondroblastic osteosarcomas, wild-type for *IDH1* R132, were analysed for *IDH2* (R172, R140) mutations. Validation was performed by capillary sequencing and restriction enzyme digestion. Heterozygous somatic *IDH1/IDH2* mutations, which result in the production of a potential oncometabolite, 2-hydroxyglutarate, were only detected in central and periosteal cartilaginous tumours, and were found in at least 56% of these, ~40% of which were represented by R132C. *IDH1* R132H mutations were confirmed by immunoreactivity for this mutant allele. The ratio of *IDH1:IDH2* mutation was 10.6:1. No *IDH2* R140 mutations were detected. Mutations were detected in enchondromas through to conventional central and dedifferentiated chondrosarcomas, in patients with both solitary and multiple neoplasms. No germline mutations were detected. No mutations were detected in peripheral chondrosarcomas and osteochondromas. In conclusion, *IDH1* and *IDH2* mutations represent the first common genetic abnormalities to be identified in conventional central and periosteal cartilaginous tumours. As in gliomas and AML, the mutations appear to occur early in tumourigenesis. We speculate that a mosaic pattern of *IDH*-mutation-bearing cells explains the reports of diverse tumours (gliomas, AML, multiple cartilaginous neoplasms, haemangiomas) occurring in the same patient.

Copyright © 2011 Pathological Society of Great Britain and Ireland. Published by John Wiley & Sons, Ltd.

Keywords: IDH1; IDH2; mutation; enchondroma; chondrosarcoma; Ollier disease; sarcoma; mosaic

Received 18 March 2011; Revised 30 March 2011; Accepted 31 March 2011

No conflicts of interest were declared.

Introduction

Recurrent somatic mutations in the isocitrate dehydrogenase 1 (*IDH1*) gene have been described in secondary glioblastomas and in gliomas [1]. A smaller number of mutations involving mitochondrial isocitrate dehydrogenase 2 (*IDH2*) have also been detected in these neoplasms [1]. In contrast, these mutations are rarely present in the primary form of glioblastoma [2].

Subsequently, similar *IDH1* and *IDH2* mutations were detected in acute myeloid leukaemia (AML) [3–7], and myelodysplastic disorders [8]. These mutations have been reported rarely in other tumours, including thyroid [9], prostate, B cell lymphoma and colorectal carcinomas (for review, see [10]). To date no *IDH1/IDH2* mutations have been identified in mesenchymal tumours.

Heterozygous *IDH1* and *IDH2* mutations detected in gliomas/glioblastomas and AML result in specific amino acid changes near or in the active sites of the enzyme. Only single copies of the gene have been found to be mutated in tumours [11]. *IDH1* mutations usually result in substitutions at R132, whereas *IDH2* mutations affect either R172, the residue that is analogous to *IDH1* R132, and R140. A small number of other *IDH1/IDH2* mutations have been described [10]. The mutant enzyme loses the ability to convert isocitrate to α -ketoglutarate [12], in addition to which the enzyme gains a new function that leads to the accumulation of δ -2-hydroxyglutarate, the levels of which strongly correlate with tumorigenesis [13]. These findings support the concept of δ -2-hydroxyglutarate, which has been referred to as an oncometabolite, exerting tumour-inducing actions [13].

Cartilaginous neoplasms, when benign and malignant forms are combined, represent the most common primary bone tumour [14]. They are referred to as conventional when the microscopic appearance bears a close resemblance to non-neoplastic cartilage as opposed to the rare mesenchymal, clear cell and dedifferentiated chondrosarcomas that have specific histological and clinical features. Dedifferentiated chondrosarcoma is considered to represent transformation from conventional chondrosarcoma [14]. A second classification is based on the relationship of the cartilaginous tumour to the anatomy of the bone on which it has arisen, i.e. central (intramedullary) or surface. There are two types of surface neoplasm, the most common being the osteochondroma, which can transform into the so-called 'secondary'/peripheral chondrosarcoma, the molecular pathology of which is well described [15]. This is a cartilage-capped exophytic lesion, the stalk of which connects directly with the medullary cavity of the underlying bone. The second is the rare periosteal cartilaginous tumour that has no connection with the underlying marrow. There is a benign and malignant variant but the pathogenesis of periosteal tumours is largely unknown [14].

Central conventional cartilaginous tumours represent a spectrum of disease spanning from benign to high-grade malignant disease. The benign tumour (enchondroma) can transform into chondrosarcoma grade I (together referred to as low-grade cartilaginous tumours) and subsequently into chondrosarcoma grades II and III (high-grade disease). There is poor inter-observer reproducibility when it comes to distinguishing enchondroma and grade I chondrosarcoma, but this is not considered clinically relevant as these tumours can generally be cured by curettage in conjunction with local adjuvant cryosurgery or phenol application [16]. However, distinguishing low-grade from high-grade disease is important, as wide margins of excision are required to treat the latter because of the difficulty of local disease control of these tumours.

Enchondromas generally occur as non-familial solitary tumours, with up to 50% occurring in the small

bones of the hands and feet. The polyostotic form of the disease, Ollier disease/multiple enchondromas, is rarely inherited [17] and has a variable phenotype, but classically there is unilateral involvement of the short and long tubular bones of the limbs, with one side being affected more severely than the other. Patients with Maffucci syndrome have multiple enchondromas associated with soft tissue vascular lesions [14,18]. There is no recurrent mutation associated with the solitary conventional central cartilaginous tumour or the multiple neoplasms occurring in Ollier disease and Maffucci syndrome [19,20], although involvement of parathyroid-related protein (PTHrP) has been suggested [18,21]. However, frequent loss of heterozygosity of the 9p21 region involving the *INK4a/INK4A-ARF* locus and the associated loss of expression of p16 is seen, predominantly in high-grade tumours [22].

Patients with Ollier disease and Maffucci syndrome have a significant risk of developing a second unrelated cancer [17], the most common of which is glioma [23–33]. Although less common, there are also reports of patients with Ollier disease who develop acute myeloid leukaemia (AML) [34–36]. It is also of interest that an *IDH1* R132C mutation has recently been detected at the Wellcome Trust Sanger Institute in the HT1080 cell line, described originally as deriving from a fibrosarcoma of bone [37]. Armed with this information, we decided to screen cartilaginous tumours and osteosarcomas for the previously reported *IDH1/IDH2* mutations. Approximately 1000 other mesenchymal tumours of various histological types were also included in this study for the purpose of studying the lineage specificity of *IDH1/IDH2* mutations.

Materials and methods

The tumour samples were largely obtained from the Royal National Orthopaedic Hospital, with a number of osteosarcomas contributed from Leiden University Medical Centre (see Supporting information, Tables S1, S2). Ethical committee approval was given for this study. The pathology slides were reviewed, diagnosed and graded according to WHO guidelines [14].

DNA was extracted from paraffin-embedded tumours, which was at least 60% tumour-rich, and paired non-neoplastic tissue when available [38]. The majority of the bone tumour samples had been decalcified in EDTA, a minority in formic acid. All bone and soft tissue tumours apart from osteochondromas were analysed for *IDH1* R132 mutations using the Sequenom[®] high-throughput MassARRAY platform. The presence of wild-type *IDH1* R132 DNA detected by MassARRAY analysis was confirmed in 27 tumours by capillary sequencing and or enzyme-specific restriction digestion (see Supporting information, Table S2). The MassARRAY assay was designed manually and performed at

Sequenom® (Hamburg, Germany). A cut-off of 10% of allelic frequency was generally used, as below this there is a high risk of false-positive calls due to noise or adducts. Cases analysed by the MassARRAY platform were classified as harbouring an *IDH1* mutation when the genetic variant was validated by capillary sequencing and/or enzyme-specific restriction digestion. Capillary sequencing was employed for screening *IDH2* R172 and R140 mutations, and for analysis of *IDH1* mutations in osteochondromas (for oligonucleotide primer sequences, see Supporting information, Tables S3, S4).

A tissue microarray was constructed using a manual arrayer (Beecher Instruments, WI, USA). Two 1 mm cores were taken from each of the 184 cartilaginous tumours. Cores of liver, lymph node, placenta, glioblastomas and fat were included as controls. Immunohistochemistry was performed using the Leica Bond-Max™ Autostainer (Leica Microsystems, Wetzlar, Germany) with the antibody targeting *IDH1* R132H (clone H09; 1:100 dilution, 20 min citrate buffer pretreatment; Dianova, Hamburg, Germany) [39]. The immunohistochemistry was scored as positive or negative as assessed by the presence and absence of chondrocyte cytoplasmic and nuclear immunoreactivity. The microscopists were blinded to the sequencing data when scoring the immunohistochemistry.

The clinical notes and imaging, where available, from patients with cartilaginous neoplasms, were reviewed.

The *IDH1* and *IDH2* mutation data were combined for the purpose of statistical analysis, as the seven tumours with *IDH2* mutations were insufficient to analyse independently. Fisher's exact test and the Welch *t*-test for age comparison were employed. All analyses were performed within R language. $p < 0.05$ was considered statistically significant.

Results

Cartilaginous tumours

Tumour and germline mutation data

Informative validated DNA sequences were obtained by at least two techniques from 145 cartilaginous tumours. These comprised 137 central and eight periosteal cartilaginous tumour samples, 81 of which (56%) harboured a mutation. Seventy-four of the mutations were found in *IDH1* R132 and the remaining seven mutations were found in *IDH2* R172. No mutations were detected in *IDH2* R140. Seventy-five of the mutations were found in central tumours, 68 of which were accounted for by *IDH1* and seven by *IDH2*. The six mutations identified in the eight periosteal tumours were all *IDH1* mutations (Tables 1, 2; Figure 1).

Neither *IDH1* nor *IDH2* mutations were detected in 24 informative peripheral chondrosarcomas or in

Table 1. Results of analysis of 81 mutation-positive cartilaginous tumours analysed by MassArray and validated by PCR enzyme-specific restriction digestion or direct sequencing

Gene	Mutation	Base change	Mutations analysed by MassArray and confirmed by RD and/or sequencing [n (%)] of mutation-positive cases]
<i>IDH1</i>	R132C	CGT > TGT	32 (39.5)
<i>IDH1</i>	R132G	CGT > GGT	16 (19.7)
<i>IDH1</i>	R132H	CGT > CAT	14 (17.3)
<i>IDH1</i>	R132L	CGT > CTT	6 (7.4)
<i>IDH1</i>	R132S	CGT > AGT	6 (7.4)
<i>IDH2</i>	R172S	AGG > AGT	7 (8.6)

n, number; RD, restriction digestion.

an additional 18 osteochondromas (see Supporting information, Tables S1, S2).

Non-neoplastic tissue (skeletal muscle/bone marrow/blood) was available from 30 patients whose tumours harboured a mutation (*IDH1* = 23; *IDH2* = 7). Analysis of this material by restriction digestion, and DNA sequencing failed to reveal any *IDH1*/*IDH2* mutations. Four of these samples were obtained from patients with Ollier disease.

Review of the histology failed to reveal any morphological features which correlated with the presence or absence of *IDH1*/*IDH2* mutations; 54.3% of the mutations were detected in the low-grade cartilaginous tumours (enchondroma/chondrosarcoma grade I) and the remaining 45.7% were found in high-grade disease, which included grade II, grade III and dedifferentiated chondrosarcomas ($p = 0.6$). Although there is inter-observation variation in distinguishing enchondroma from chondrosarcoma [16], when a tumour is composed of hyaline matrix, is paucicellular, shows no entrapment of host lamellar bone, and the chondrocytes show a closed chromatin pattern together with no erosion of the cortical bone on imaging, it is generally accepted as representing an enchondroma [14]. Using these criteria in cases where imaging was available, 14 of the low-grade tumours in long bones of the appendicular skeleton were classified confidently as enchondromas and four of these harboured a mutation (Figure 2A). Twenty-three of the 137 central cartilaginous tumours contained a dedifferentiated component, 13 (56.5%) of which harboured a mutation (12 *IDH1* and one *IDH2*). Of the four cases in which both components (grade I and dedifferentiated) were analysed, the same mutation was detected in both elements. Eleven of the 23 dedifferentiated chondrosarcomas showed osteosarcomatous differentiation and eight (72.7%) of these contained a mutation.

Mutation-positive central and periosteal cartilaginous tumours occurred more frequently in the tubular bones of the hands and feet than at other anatomical locations ($p < 0.001$) (Table 2); 90% (26 of 29) of the acral-based tumours revealed a mutation, compared to 53.2% (42 of 79) of tumours in the long bones of the appendicular skeleton, and 35.1% (13 of 37) of those in the flat bones (Table 2).

Table 2. Correlation of subtype, grade and site of central and periosteal, genetically informative, cartilaginous tumours with IDH1 and IDH2 mutation type

Tumour subtype/grade (n)	Number with mutation (%)	Mutation type n (%)	Site (total number)/number with mutation (%)
Central low-grade cartilaginous tumours (75)	39 (52.0)	R132C	Femur (14)/5 (35.7)
		14 (35.9)	
		R132G	Fibula (2)/2 (100)
		8 (20.5)	
		R132H	Foot (4)/3 (75)
		11 (28.2)	
		R132L	Hand (22)/20 (90.9)
		1 (2.6)	
		R132S	Humerus (14)/5 (35.7)
		4 (10.3)	
		R172S	Pelvis (4)/1 (25)
		1 (2.6)	
		Rib (4)/0 (0)	
		Scapula (2)/1 (50)	
		Tibia (6)/1 (16.7)	
		Ulna (1)/0 (0)	
		Vertebra (1)/0 (0)	
	36 (58.0)		
Central high-grade: chondrosarcomas GII and GIII (39)	23 (58.9)	R132C	Femur (22)/18 (81.8)
		10 (43.5)	
		R132G	Hand (2)/2 (100)
		5 (21.7)	
		R132L	Humerus (9)/3 (33.3)
		3 (13.0)	
		R172S	Pelvis (17)/11 (64.7)
4 (17.4)			
R172T	Rib (3)/0 (0)		
1 (4.3)			
Central high-grade: dedifferentiated chondrosarcoma (23)	13 (56.5)	R132C	Scapula (3)/0 (0)
		4 (30.7)	
		R132G	Tibia (3)/2 (67.7)
		3 (23.1)	
		R132H	Vertebra (3)/0 (0)
		3 (23.1)	
		R132L	
2 (15.4)			
R172S			
1 (7.7)			
Periosteal chondromas (7)	5 (71.43)	R132C	Femur (2)/1 (50)
		3 (60.0)	
		R132S	Fibula (1)/1 (100)
		2 (40.00)	
		Foot (1)/1 (100)	
		Humerus (2)/2 (100)	
		Radius (1)/0 (0)	
		Femur (1)/1(0)	
Periosteal chondrosarcoma (1)	1 (100)	R132C	
		1 (100)	

WT, wild-type; n, number of genetically informative samples; G, grade. Secondary peripheral chondrosarcomas (n = 24) were excluded from this analysis.

Of 137 cartilaginous tumours, 15 (11%) had been removed from patients diagnosed as having multiple central cartilaginous tumours by a variety of imaging techniques. Twelve of these tumour samples (one from each patient) harboured a mutation. Analysis of a second neoplasm was possible in only one patient: this showed the same IDH1 R132C mutation in both tumours.

Immunohistochemistry for the IDH1 R132H mutation was performed on all of the cartilaginous tumours included in this study [central, periosteal cartilaginous

tumours, peripheral chondrosarcoma and the osteochondromas (n = 202)]. All 14 central tumours identified as harbouring a R132H mutation assessed by MassARRAY and DNA sequencing showed strong and diffuse cytoplasmic and nuclear immunoreactivity (Figure 2B). All but five of the other 188 cases showed absence of immunoreactivity. The immunoreactivity observed in these five cases was confirmed on full tissue sections. Of note was that an IDH1 R132H mutation had been detected by MassARRAY in three of these. However, as these results were not validated

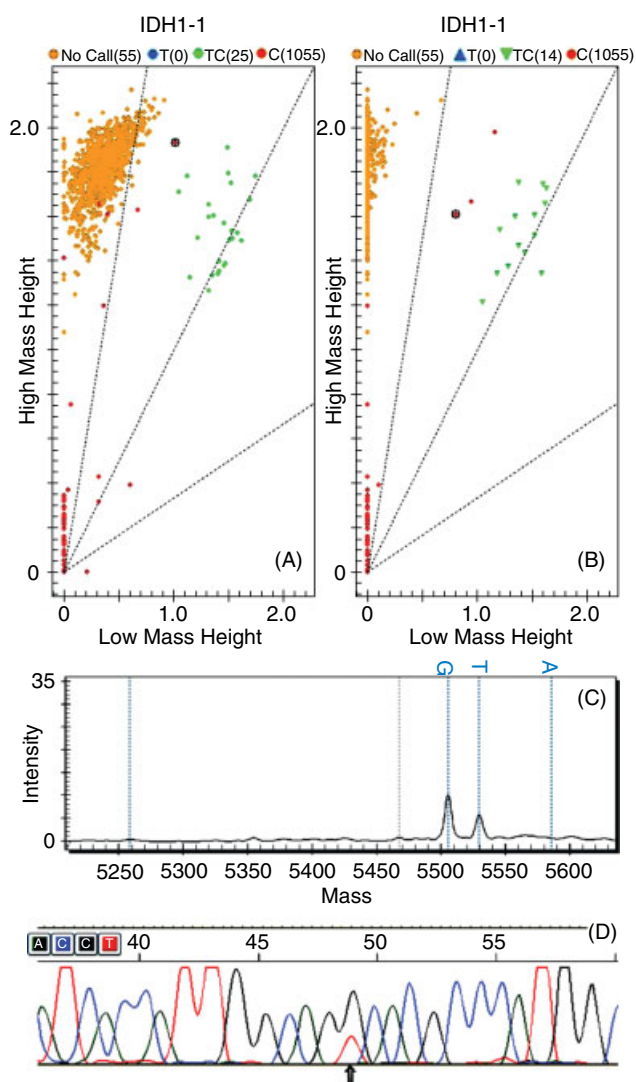


Figure 1. MassArray cluster plots for *IDH1* mutations: (A) cluster plots of 1035 samples from cartilaginous tumours showing *IDH1* R132C in 25 samples and (B) *IDH1* R132G in 14 samples; (C) spectra for one R172S sample; (D) which was confirmed by direct sequencing.

by DNA sequencing and/or restriction enzyme digestion, they were not included in the validated tumour set. The remaining two cases were found to be wild-type by DNA MassArray, and capillary sequencing and restriction digestion failed to reveal an *IDH2* mutation. Review of haematoxylin and eosin (H&E)-stained sections, representing the tissue from which the DNA had been extracted from these two cases, revealed that in addition to the presence of low-grade cartilaginous tumour there were also cellular foci of haemopoietic marrow. Hence, the failure to detect the mutations in these two cases is likely to be accounted for by dilution of the mutated cell population.

Clinical information and follow-up

The 145 informative central and periosteal tumours were surgically removed from 85 male and 60 female patients: the numbers of male and female patients

harbouring a mutation were 42 and 39, respectively. There was no significant difference with respect to the distribution of tumours in male and female patients (see Supporting information, Supplementary materials and methods). The mean age of patients presenting with central/periosteal cartilaginous tumours harbouring either an *IDH1* or an *IDH2* mutation was not significantly different from that of patients whose tumours did not have a mutation (see Supporting information, Supplementary materials and methods).

None of the patients with cartilaginous tumours revealed evidence of a family history of this disease and/or personal or family history of AML or brain tumour. Follow-up information was available from 108 of 145 patients with central/periosteal cartilaginous tumours, from whom there were informative validated genetic data. Follow-up data were available from 58 (63.4%) patients with central/periosteal low-grade cartilaginous tumours (range 1–169 months, mean 15.8), all of whom were alive without metastatic disease, with only one patient having persistent clinical disease. Tumour had recurred on one occasion in four individuals (two with and two without mutation). Of the 50 patients (79.4%) with high-grade chondrosarcomas (49 central and one periosteal), the follow-up period was in the range 2–158 months (mean 33.0 months) (Table 3). The survival period of the 50 patients with high-grade chondrosarcomas with and without a mutation was not significantly different ($p = 0.25$). Twenty-four (48%) of these patients died of their disease 2–158 (average 26) months from the time of diagnosis, 11 were alive with disease and 15 were alive without evidence of disease: ~60% of the patients in all three groups harboured an *IDH1/IDH2* mutation (Table 3).

Non-cartilaginous neoplasms

Osteosarcoma samples from 222 patients, 19 osteosarcoma cell lines and one chordoma cell line were tested for *IDH1* mutations using the high-throughput MassARRAY platform: 64.4% (143 samples) of these were also analysed for *IDH2* mutations, including all chondroblastic osteosarcomas (20.44% of osteosarcomas) (see Supporting information, Tables S1, S5). No mutations were detected in any of these samples (98.6% informative).

An *IDH1* mutation was not detected in 655 soft tissue mesenchymal neoplasms, 106 bone sarcomas [including 79 chordomas (all immunoreactive for brachyury), 25 PNET/Ewing sarcoma, one fibrosarcoma of bone and one clear cell chondrosarcoma], 96.3% of which were genetically informative (see Supporting information, Table S1).

Discussion

This is the first report of *IDH1* (R132) and *IDH2* (R172) heterozygous mutations in conventional central and periosteal cartilaginous tumours. Of note is that the

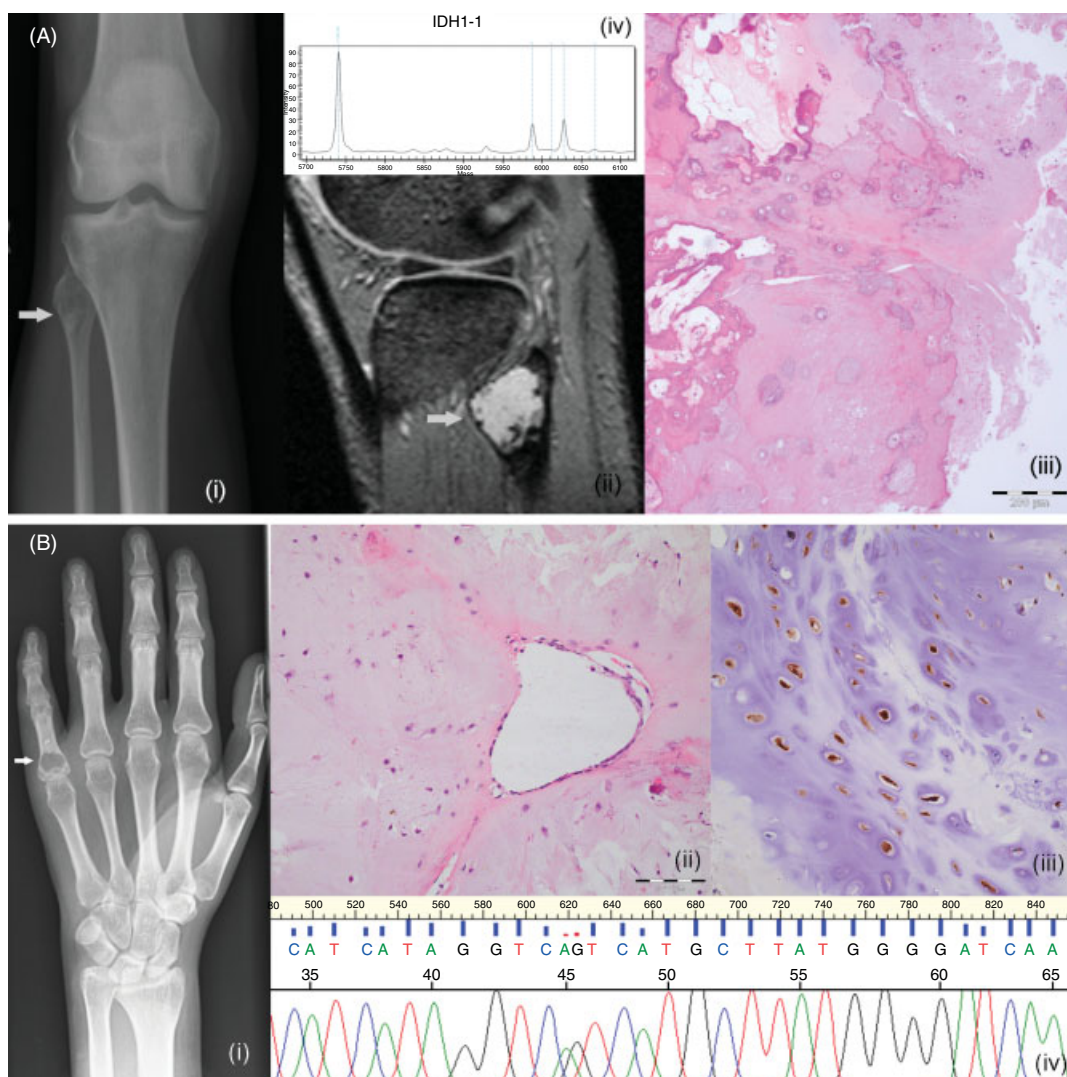


Figure 2. Imaging and histological appearances of two cartilaginous tumours with an *IDH1* mutation: (Ai) plain radiograph; (Aii) magnetic resonance image; (Aiii) an enchondroma of the fibula, which is shown in the photomicrograph; (Aiv) MassArray spectra (R132G) of DNA from the enchondroma; (Bi) Plain radiograph with the arrow pointing to the central enchondroma in the 5th proximal phalanx; which is shown in a photomicrograph (Bii) of a H&E-stained section; (Biii) the *IDH1* R132H immunoreactivity supports the (Biv) capillary sequencing, which shows a heterozygous R132H mutant allele of the enchondroma.

Table 3. Clinical outcome of 50 patients with high-grade* central or periosteal tumours genetically informative for *IDH1* or *IDH2* mutations

	Patients <i>n</i>	Mutation-positive tumours <i>n</i> (%)
Dead of disease	24	15 (62.5)
Alive with disease	11	7 (63.6)
Alive without disease	15	9 (60)
Total	50	31 (62)
One or more recurrences	19	9 (47.4)
Recorded metastatic disease	23	12 (52.2)

n, number. *High-grade includes grades II and III and dedifferentiated chondrosarcomas.

mutations are restricted to these specific subtypes of cartilaginous tumours, and furthermore were not found in a wide variety of an additional ~1000 other connective tissue neoplasms, including 222 osteosarcomas. The finding that conventional secondary peripheral chondrosarcomas and osteochondromas, characterized

by mutations in *EXT1* and *EXT2*, do not harbour *IDH1/IDH2* mutations supports the current evidence that these neoplastic subgroups represent distinct neoplastic entities [40].

Although the overall frequency of *IDH1/IDH2* mutations in conventional central and periosteal cartilaginous neoplasms was found to be 56%, it is striking that the distribution of mutation-positive tumours in the bones of the hand and feet was significantly greater than at extra-acral sites, with 90% of the acral-based tumours harbouring a mutation compared to 53.2% of tumours in the long bones of the appendicular skeleton and 35.1% of those in the flat bones. However, considering that two low-grade cartilaginous tumours in the long bones (humerus, femur) were classified as wild-type when analysed by capillary DNA sequencing yet found to be immunoreactive for R132H, the frequency of *IDH1/IDH2* mutations detected by DNA sequencing may well be an underestimate. This discrepancy

can be explained by failure to detect mutations in low-grade paucicellular tumours because of the presence of populations of contaminating non-neoplastic cells. Unfortunately the R132H antibody, which is a highly specific and sensitive marker for this mutant allele, is the only one available against *IDH1/IDH2* mutants [39]. Hence, when the immunohistochemistry finding for R132H mutations is extrapolated to other *IDH1/IDH2* mutation types in our 145 validated samples, the overall mutation frequency would be predicted to be closer to 70%. Nevertheless, even when taking into account the potential false-negative results, there appears to be a significant number of cases that do not harbour a common *IDH1/IDH2* mutation in central/periosteal cartilaginous tumours.

In contrast to gliomas, in which 88% of *IDH1* mutations involve histidine at codon 132 (R132H), R132C represents the most common *IDH1* mutation in cartilaginous tumours (40%), with the R132H variant constituting 17%. In contrast, *IDH2* mutations are the most common in AML and occur most frequently at residue R140 [41], whereas no *IDH2* R140 mutations are detected in gliomas [1] or in our cartilaginous tumours. The biological importance of these different mutations remains unknown.

There is a consensus that the multiple enchondromas in Ollier disease and Maffucci syndrome are the consequence of a post-zygotic germline mutation resulting in a mosaic distribution of mutant cells [19]. However, to date the culprit gene(s) has remained elusive [20], apart from ~10% which are associated with *PTHR1* mutations [21,42]. As *IDH1/IDH2* mutations were detected in both apparently solitary cartilaginous tumours and in those excised from patients with multiple lesions (Ollier disease/Maffucci syndrome), it is interesting to speculate, particularly in view of the reports of patients with Ollier disease developing gliomas and AML, many of which harbour *IDH1/IDH2* mutations, that these mutations represent early post-zygotic genetic events and account for initiation of the disease process. Definitive evidence for this would be provided by detection of the same *IDH1/IDH2* mutations in somatic tissues from the same patient but at a lower frequency. However, we have been unable to demonstrate mutations in non-lesional tissue in our cohort, but others have also found this to be difficult in patients with mosaic conditions. Specifically, in McCune Albright syndrome, the archetypal mosaic disorder, mutation detection was highly variable (in the range 8–48%) and was found to depend on the disease burden [43].

There is accumulating evidence that *IDH1/IDH2* mutations are implicated in the early stages of tumour development of both AML and gliomas and that this is brought about by the accumulation D-2-hydroxylglutarate [11]. Recent studies show that *IDH1/IDH2* mutations in AML mediate their effects through blocking the catalytic effect of TET2, an α -ketoglutarate-dependent demethylase enzyme, the consequence of which is global hypermethylation,

resulting in reduced haemopoietic cellular differentiation and loss of markers related to proliferation [44]. Although we have not had the opportunity to demonstrate the presence D-2-hydroxylglutarate in cartilaginous tumours harbouring the mutations, the report of 'enchondroma-like' nodules in patients with D-2-hydroxylglutarate aciduria, a neurometabolic disorder that is associated with inherited *IDH2* mutations, provides evidence that D-2-hydroxylglutarate is also involved in the early stages of cartilage tumourigenesis, or at least abnormal cellular proliferation of chondrocytes, thereby providing evidence for its role in tumourigenesis [45–47]. Since mutations that result in loss of function of TET2 in AML have the same neoplastic effects as the *IDH1/IDH2* mutations, it will be interesting to see whether *TET2* mutations are found in the *IDH1/IDH2* mutation-negative cartilaginous tumours [44]. Additional candidates include other genes encoding mitochondrial metabolic enzymes, such as fumarate hydratase and succinate dehydrogenase or others, which have previously been implicated in carcinogenesis in other tumours and would exert the same functional consequence [10].

There is also evidence that *IDH1/IDH2* mutations result in elevated levels of HIF-1 α and the associated transcriptional activity of its target genes, and that these effects are mediated through low levels of α -ketoglutarate [12]. These genes are important in adaptation of cells to low oxygen tension and are involved in glucose metabolism, angiogenesis, cell motility and invasion functions that are important for tumour growth/progression. It is therefore noteworthy that high levels of HIF-1 α are detected in chondrosarcomas, and that an increase in glycolysis-associated genes has been reported in high-grade chondrosarcomas compared with the low-grade counterpart in a comparative cDNA study [48,49]. It will be of interest to determine whether these findings are related to the *IDH1/IDH2* mutations in cartilaginous tumours, and also to correlate the *IDH1/IDH2* mutation status with other genetics alterations, such as loss of p16 and p53, which are known to occur in chondrosarcomas. Such information may reveal the sequence of genetic events that are involved in the process of cartilaginous tumour development [22].

In terms of connective tissue neoplasms, *IDH1* R132 and *IDH2* R172 mutations appear to be restricted to conventional central and periosteal cartilaginous tumours, as the mutations were not detected in ~1000 other bone ($n = 328$) and soft tissue neoplasms. This information has the potential to make a clinically valuable contribution to three challenging areas of diagnostic surgical pathology: first, the detection of *IDH1/IDH2* mutations distinguishes chondroblastic osteosarcomas from central chondrosarcomas; second, the detection of an *IDH1/IDH2* mutation appears to distinguish a dedifferentiated chondrosarcoma with osteosarcomatous differentiation from an osteosarcoma which arises *de novo* [14]; finally, the presence of an *IDH1/IDH2* mutation is mutually exclusive with

the expression of brachyury in chordomas, thereby providing additional criteria for distinguishing these neoplasms [50].

The only non-cartilaginous connective tissue tumour in which *IDH1/IDH2* mutations has been detected is the HT1080 cell line, which derives from a primary fibrosarcoma of bone in a 35 year-old man without documented features of Ollier disease [37]. Hence, we consider that this tumour cell line represents a dedifferentiated chondrosarcoma.

Conventional cartilaginous tumours comprise a variety of lesions, which are classified as distinct entities on the basis of their clinical/radiological and morphological features. The most common of these is osteochondroma/secondary peripheral chondrosarcoma, the majority of which harbour mutations in *EXT1/EXT2*. The other major group comprises central and periosteal tumours, a significant proportion of which we now know harbour *IDH1/IDH2* mutations. However, there are also rarer subtypes of conventional cartilaginous tumours, for example metachondromatosis and spondyloenchondrodysplasia, which develop as multiple lesions, a number of which have recently been linked to specific genetic alterations, including *PTPN11*, which encodes protein tyrosine phosphatase, non-receptor type 11, and *ACP5*, which encodes tartrate-resistant acid phosphatase [51–53]. As these disease entities may have overlapping phenotypes, recognition of these mutations will allow robust disease classification that can be exploited for patient diagnosis and treatment. Nevertheless, it is striking that, despite the morphological similarities of these tumours, the genes implicated in their development represent a heterogeneous group which have different functions, and there is no obvious close relationship in terms of their signalling pathways. This highlights how little of the basic biology of cartilaginous tissue is understood, and suggests that a systems biology approach will be required to unravel the full story.

Acknowledgment

We are grateful to all the patients for donating their tissue for research and to all of the clinicians and support staff in the London Sarcoma Service who were involved in caring for the patients involved in this study. The research was generously funded by Skeletal Cancer Action Trust (SCAT) UK and The Wellcome Trust, WT077012. SD received funding from The Pathological Society of Great Britain and Ireland. The project was made possible by the existence of the RNOH Musculoskeletal Research Programme and Biobank, and support was received from UCLH/UCL Comprehensive Biomedicine Cancer Theme.

Author contributions

Review of the pathology was undertaken by histopathologists FM, RT, SD, MFA and AMF. Preparation

of the DNA was performed by DH, KB, FM and FB. PCWH provided some osteosarcoma samples and the osteosarcoma cell lines. AF analysed the cell lines and contributed along with PA and AMF to the concept of the paper. The experimental design was performed by MFA and AMF. Validation of the MassARRAY results was performed by MFA, DH, FB, TD, SD and NP. Immunohistochemistry was performed by FB; the TMAs were built by SD. Analysis of the data was performed by MFA, DH, FB, TD and AMF. Radiology was reviewed by PO'D. Surgical input was provided by RP. Statistical analysis was performed by AG. The MS was written by AMF, MFA and reviewed by PCWH and AF.

References

1. Yan H, Parsons DW, Jin G, *et al.* *IDH1* and *IDH2* mutations in gliomas. *N Engl J Med* 2009; **360**: 765–773.
2. van den Bent MJ, Dubbink HJ, Marie Y, *et al.* *IDH1* and *IDH2* mutations are prognostic but not predictive for outcome in anaplastic oligodendroglial tumors: a report of the European Organization for Research and Treatment of Cancer Brain Tumor Group. *Clin Cancer Res* 2010; **16**: 1597–1604.
3. Abbas S, Lugthart S, Kavelaars FG, *et al.* Acquired mutations in the genes encoding *IDH1* and *IDH2* both are recurrent aberrations in acute myeloid leukemia (AML): prevalence and prognostic value. *Blood* 2010; **116**: 2122–2126.
4. Green A, Beer P. Somatic mutations of *IDH1* and *IDH2* in the leukemic transformation of myeloproliferative neoplasms. *N Engl J Med* 2010; **362**: 369–370.
5. Ho PA, Alonzo TA, Kopecky KJ, *et al.* Molecular alterations of the *IDH1* gene in AML: a Children's Oncology Group and Southwest Oncology Group study. *Leukemia* 2010; **24**: 909–913.
6. Kosmider O, Gelsi-Boyer V, Slama L, *et al.* Mutations of *IDH1* and *IDH2* genes in early and accelerated phases of myelodysplastic syndromes and MDS/myeloproliferative neoplasms. *Leukemia* 2010; **24**: 1094–1096.
7. Ward PS, Patel J, Wise DR, *et al.* The common feature of leukemia-associated *IDH1* and *IDH2* mutations is a neomorphic enzyme activity converting α -ketoglutarate to 2-hydroxyglutarate. *Cancer Cell* 2010; **17**: 225–234.
8. Abdel-Wahab O, Manshour T, Patel J, *et al.* Genetic analysis of transforming events that convert chronic myeloproliferative neoplasms to leukemias. *Cancer Res* 2010; **70**: 447–452.
9. Murugan AK, Bojdani E, Xing M. Identification and functional characterization of isocitrate dehydrogenase 1 (*IDH1*) mutations in thyroid cancer. *Biochem Biophys Res Commun* 2010; **393**: 555–559.
10. Yen KE, Bittinger MA, Su SM, *et al.* Cancer-associated *IDH* mutations: biomarker and therapeutic opportunities. *Oncogene* 2010; **29**: 6409–6417.
11. Dang L, Jin S, Su SM. *IDH* mutations in glioma and acute myeloid leukemia. *Trends Mol Med* 2010; **16**: 387–397.
12. Zhao S, Lin Y, Xu W, *et al.* Glioma-derived mutations in *IDH1* dominantly inhibit *IDH1* catalytic activity and induce HIF-1 α . *Science* 2009; **324**: 261–265.
13. Dang L, White DW, Gross S, *et al.* Cancer-associated *IDH1* mutations produce 2-hydroxyglutarate. *Nature* 2009; **462**: 739–744.
14. Fletcher CDM, Unni KK, Mertens F. Cartilage tumours. In *World Health Organization Classification of Tumours Pathology and Genetics of Tumours of Soft Tissue and Bone*. Kleihues P, Sobin LH (eds). International Agency for Research on Cancer (IARC): Lyon, 2002; 233–257.

15. Bovee JV, Hogendoorn PC, Wunder JS, *et al*. Cartilage tumours and bone development: molecular pathology and possible therapeutic targets. *Nat Rev Cancer* 2010; **10**: 481–488.
16. Eefting D, Schrage YM, Geirnaerd MJ, *et al*. Assessment of inter-observer variability and histologic parameters to improve reliability in classification and grading of central cartilaginous tumors. *Am J Surg Pathol* 2009; **33**: 50–57.
17. Pansuriya TC, Kroon HM, Bovee JV. Enchondromatosis: insights on the different subtypes. *Int J Clin Exp Pathol* 2010; **3**: 557–569.
18. Rozeman LB, Sangiorgi L, Briaire-de Bruijn IH, *et al*. Enchondromatosis (Ollier disease, Maffucci syndrome) is not caused by the *PTHRI* mutation p.R150C. *Hum Mutat* 2004; **24**: 466–473.
19. Erickson RP. Somatic gene mutation and human disease other than cancer: an update. *Mutat Res* 2010; **705**: 96–106.
20. Pansuriya TC, Oosting J, Krenacs T, *et al*. Genome-wide analysis of Ollier disease: is it all in the genes? *Orphanet J Rare Dis* 2011; **6**: 2.
21. Hopyan S, Gokgoz N, Poon R, *et al*. A mutant PTH/PTHrP type I receptor in enchondromatosis. *Nat Genet* 2002; **30**: 306–310.
22. van Beerendonk HM, Rozeman LB, Taminiou AH, *et al*. Molecular analysis of the *INK4A/INK4A-ARF* gene locus in conventional (central) chondrosarcomas and enchondromas: indication of an important gene for tumour progression. *J Pathol* 2004; **202**: 359–366.
23. Bendel CJ, Gelmers HJ. Multiple enchondromatosis (Ollier's disease) complicated by malignant astrocytoma. *Eur J Radiol* 1991; **12**: 135–137.
24. Chang S, Prados MD. Identical twins with Ollier's disease and intracranial gliomas: case report. *Neurosurgery* 1994; **34**: 903–906; discussion, 906.
25. Frappaz D, Ricci AC, Kohler R, *et al*. Diffuse brain stem tumor in an adolescent with multiple enchondromatosis (Ollier's disease). *Childs Nerv Syst* 1999; **15**: 222–225.
26. Hofman S, Heeg M, Klein JP, *et al*. Simultaneous occurrence of a supra- and an infratentorial glioma in a patient with Ollier's disease: more evidence for non-mesodermal tumor predisposition in multiple enchondromatosis. *Skel Radiol* 1998; **27**: 688–691.
27. Jirattanaphochai K, Jitpimolmard S. Maffucci's syndrome with frontal lobe astrocytoma. *J Med Assoc Thai* 1990; **73**: 288–293.
28. Mahafza WS. Multiple enchondromatosis Ollier's disease with two primary brain tumors. *Saudi Med J* 2004; **25**: 1261–1263.
29. Mellon CD, Carter JE, Owen DB. Ollier's disease and Maffucci's syndrome: distinct entities or a continuum. Case report: enchondromatosis complicated by an intracranial glioma. *J Neurol* 1988; **235**: 376–378.
30. Ranger A, Szymczak A. Do intracranial neoplasms differ in Ollier disease and Maffucci syndrome? An in-depth analysis of the literature. *Neurosurgery* 2009; **65**: 1106–1113; discussion, 1113–1105.
31. Rawlings CE III, Bullard DE, Burger PC, *et al*. A case of Ollier's disease associated with two intracranial gliomas. *Neurosurgery* 1987; **21**: 400–403.
32. van Nielen KM, de Jong BM. A case of Ollier's disease associated with two intracerebral low-grade gliomas. *Clin Neurol Neurosurg* 1999; **101**: 106–110.
33. Walid MS, Troup EC. Cerebellar anaplastic astrocytoma in a teenager with Ollier disease. *J Neurooncol* 2008; **89**: 59–62.
34. Lawson JP, Scott G. Case report 602: Spindle cell hemangioperithelioma (SCH) and enchondromatosis (a form of Maffucci syndrome) in a patient with acute myelocytic leukemia (AML). *Skel Radiol* 1990; **19**: 158–162.
35. Rector JT, Gray CL, Sharpe RW, *et al*. Acute lymphoid leukemia associated with Maffucci's syndrome. *Am J Pediatr Hematol Oncol* 1993; **15**: 427–429.
36. White MS, Martin PL, McLean TW. Acute myelogenous leukemia associated with Ollier disease. *Pediatr Blood Cancer* 2008; **50**: 645–646.
37. Rasheed S, Nelson-Rees WA, Toth EM, *et al*. Characterization of a newly derived human sarcoma cell line (HT-1080). *Cancer* 1974; **33**: 1027–1033.
38. Presneau N, Shalaby A, Idowu B, *et al*. Potential therapeutic targets for chordoma: PI3K/AKT/TSC1/TSC2/mTOR pathway. *Br J Cancer* 2009; **100**: 1406–1414.
39. Capper D, Weissert S, Balss J, *et al*. Characterization of R132H mutation-specific IDH1 antibody binding in brain tumors. *Brain Pathol* 2010; **20**: 245–254.
40. Szuhai K, Jennes I, de Jong D, *et al*. Tiling resolution array-CGH shows that somatic mosaic deletion of the *EXT* gene is causative in *EXT* gene mutation-negative multiple osteochondromas patients. *Hum Mutat* 2011; **32**: E2036–2049.
41. Thol F, Damm F, Wagner K, *et al*. Prognostic impact of *IDH2* mutations in cytogenetically normal acute myeloid leukemia. *Blood* 2010; **116**: 614–616.
42. Couvineau A, Wouters V, Bertrand G, *et al*. *PTHRI* mutations associated with Ollier disease result in receptor loss of function. *Hum Mol Genet* 2008; **17**: 2766–2775.
43. Lumbroso S, Paris F, Sultan C. Activating *Gsa* mutations: analysis of 113 patients with signs of McCune–Albright syndrome—a European collaborative study. *J Clin Endocrinol Metab* 2004; **89**: 2107–2113.
44. Figueroa ME, Abdel-Wahab O, Lu C, *et al*. Leukemic *IDH1* and *IDH2* mutations result in a hypermethylation phenotype, disrupt TET2 function, and impair hematopoietic differentiation. *Cancer Cell* 2010; **14**: 553–567.
45. Honey EM, van Rensburg M, Knoll DP, *et al*. Spondyloenchondromatosis with D-2-hydroxyglutarate aciduria: a report of a second patient with this unusual combination. *Clin Dysmorphol* 2003; **12**: 95–99.
46. Kranendijk M, Struys EA, van Schaftingen E, *et al*. *IDH2* mutations in patients with D-2-hydroxyglutaric aciduria. *Science* 2010; **330**: 336.
47. Talkhani IS, Saklatvala J, Dwyer J. D-2-hydroxyglutaric aciduria in association with spondyloenchondromatosis. *Skel Radiol* 2000; **29**: 289–292.
48. Chen C, Zhou H, Wei F, *et al*. Increased levels of hypoxia-inducible factor-1 α are associated with Bcl-xL expression, tumor apoptosis, and clinical outcome in chondrosarcoma. *J Orthop Res* 2011; **29**: 143–151.
49. Rozeman LB, Hameetman L, van Wezel T, *et al*. cDNA expression profiling of chondrosarcomas: Ollier disease resembles solitary tumours and alteration in genes coding for components of energy metabolism occurs with increasing grade. *J Pathol* 2005; **207**: 61–71.
50. Vujovic S, Henderson S, Presneau N, *et al*. Brachyury, a crucial regulator of notochordal development, is a novel biomarker for chordomas. *J Pathol* 2006; **209**: 157–165.
51. Briggs TA, Rice GI, Daly S, *et al*. Tartrate-resistant acid phosphatase deficiency causes a bone dysplasia with autoimmunity and a type I interferon expression signature. *Nat Genet* 2011; **43**: 127–131.
52. Lausch E, Janecke A, Bros M, *et al*. Genetic deficiency of tartrate-resistant acid phosphatase associated with skeletal dysplasia, cerebral calcifications and autoimmunity. *Nat Genet* 2011; **43**: 132–137.
53. Sobreira NL, Cirulli ET, Avramopoulos D, *et al*. Whole-genome sequencing of a single proband together with linkage analysis identifies a Mendelian disease gene. *PLoS Genet* 2010; **6**: e1000991.

SUPPORTING INFORMATION ON THE INTERNET

The following supporting information may be found in the online version of this article:

Supplementary materials and methods

Table S1. All cartilaginous and non-cartilaginous mesenchymal tumours and cell lines analysed for *IDH1* and *IDH2* mutations.

Table S2. Clinical details and molecular results of 184 cartilaginous tumours (159 central and periosteal and 25 peripheral).

Table S3. Oligonucleotide primer sequences used in the MassArray assay.

Table S4. Oligonucleotide primers and enzymes for restriction enzyme digestion (A) and oligonucleotide primers for sequencing (B).

Table S5. Osteosarcoma and chordoma lines with *IDH1* mutation status.