

Early Magnetic Resonance Imaging and Cognitive Markers of Hereditary Cerebral Amyloid Angiopathy

Sanneke van Rooden, PhD; Anna M. van Opstal, MSc; Gerda Labadie, BSc;
Gisela M. Terwindt, MD, PhD; Marieke J.H. Wermer, MD, PhD; Andrew G. Webb, PhD;
Huub A.M. Middelkoop, PhD; Steven M. Greenberg, MD, PhD; Jeroen van der Grond, PhD;
Mark A. van Buchem, MD, PhD

Background and Purpose—Early markers for cerebral amyloid angiopathy are largely unknown. We aimed to identify which magnetic resonance imaging (MRI) (performed at 7 and 3T) and cognitive markers are an early sign in (pre) symptomatic subjects with hereditary cerebral hemorrhage with amyloidosis-Dutch type.

Methods—Twenty-seven DNA-proven Dutch-type mutation carriers (15 symptomatic and 12 presymptomatic) (mean age of 45.9 years) and 33 controls (mean age of 45.6 years) were included. 7T and 3T MRI was performed, cerebral amyloid angiopathy and small-vessel disease type MRI markers were estimated, and cognitive performance was assessed. Univariate general linear modeling analysis was used to assess the association between MRI markers and cognitive performance on the one hand and on the other, mutation status, adjusted for age, sex, and education.

Results—In symptomatic patients, all established cerebral amyloid angiopathy MRI markers (microbleeds, intracerebral hemorrhages, subarachnoid hemorrhages, superficial siderosis, microinfarcts, volume of white matter hyperintensities, and dilated perivascular spaces in centrum semiovale) were increased compared with controls ($P < 0.05$). In presymptomatic subjects, the prevalence of microinfarcts and median volume of white matter hyperintensities were increased in comparison to controls ($P < 0.05$). Symptomatic patients performed worse on all cognitive domains, whereas presymptomatic subjects did not show differences in comparison with controls ($P < 0.05$).

Conclusions—White matter hyperintensities and microinfarcts are more prevalent among presymptomatic subjects and precede cognitive and neuropsychiatric symptoms and intracerebral hemorrhages. (*Stroke*. 2016;47:3041-3044. DOI: 10.1161/STROKEAHA.116.014418.)

Key Words: cerebral amyloid angiopathy ■ cognition ■ hemorrhage ■ magnetic resonance imaging ■ siderosis

A major problem in diagnosing sporadic cerebral amyloid angiopathy (sCAA) is the absence of reliable, non-invasive diagnostic tests. Hereditary cerebral hemorrhage with amyloidosis-Dutch type (HCHWA-D) is an autosomal dominant disease, and the chemical composition and underlying pathology of the amyloid deposits is similar to that in sCAA.¹ Clinically, the symptomatic stage of both sCAA and HCHWA-D is characterized by recurrent hemorrhagic strokes and cognitive impairment,² and common radiological manifestations are microbleeds, intracerebral hemorrhages, superficial siderosis, convexity subarachnoid hemorrhages,³ greater volumes of white matter hyperintensities (WMHs),^{4,5} and microinfarcts.⁶ Because sCAA and HCHWA-D are subtypes of small-vessel disease, other small-vessel disease markers such as lacunar infarcts and dilated perivascular spaces might also be more prevalent in sCAA and HCHWA-D. Previous

studies suggested that in patients with sCAA and HCHWA-D, cognitive impairment may also be an early disease marker, preceding stroke or any other brain lesion.^{2,7} The goal of our study is to identify which markers are an early sign of HCHWA-D using the most sensitive magnetic resonance imaging (MRI) techniques at 3T and 7T and to assess whether cognitive decline and neuropsychiatric abnormalities are an early sign of the disease.

Materials and Methods

HCHWA-D and control subjects were recruited via the HCHWA-D patient association in Katwijk (the Netherlands) and outpatient clinic of the Department of Neurology of the Leiden University Medical Center. Twenty-seven DNA-proven HCHWA-D mutation carriers and 33 controls were included (symptomatic [$n=15$] and presymptomatic [$n=12$] mutation carriers). Subjects were considered symptomatic when they had experienced signs of the disease reported to a general

Received July 4, 2016; final revision received August 23, 2016; accepted September 28, 2016.

From the C.J. Gorter Center for High-Field MRI (S.v.R., A.M.v.O., A.G.W., J.v.d.G., M.A.v.B.), Department of Radiology (S.v.R., A.M.v.O., G.L., A.G.W., J.v.d.G., M.A.v.B.), and Department of Neurology (G.M.T., M.J.H.W., H.A.M.M.), Leiden University Medical Center, The Netherlands; and Department of Neurology, Massachusetts General Hospital, Boston (S.M.G.).

The online-only Data Supplement is available with this article at <http://stroke.ahajournals.org/lookup/suppl/doi:10.1161/STROKEAHA.116.014418/-/DC1>.

Correspondence to Jeroen van der Grond, PhD, Department of Radiology, C3-Q, Leiden University Medical Center, PO Box 9600, 2300 RC Leiden, The Netherlands. E-mail j.van_der_Grond@lumc.nl

© 2016 American Heart Association, Inc.

Stroke is available at <http://stroke.ahajournals.org>

DOI: 10.1161/STROKEAHA.116.014418

Table 1. MRI Markers in Presymptomatic and Symptomatic Mutation Carriers Versus Controls

MRI Markers	Controls (n=33)		Presymptomatic Carriers (n=12)		Symptomatic Carriers (n=15)	
	Prevalence	Median (25th–75th Percentile)	Prevalence	Median (25th–75th Percentile)	Prevalence	Median (25th–75th Percentile)
Microbleeds	6.7% (2/30)	0 (0–0)	18.2% (2/11)	0 (0–0)	100% (15/15)*	49 (28–118)*
ICHs	0% (0/30)	0 (0–0)	9.1% (1/11)	0 (0–0)	100% (14/14)*	13 (5–27)*
Convexity SAHs	0% (0/30)	0 (0–0)	18.2% (2/11)	0 (0–0)	50% (7/14)*	0.5 (0–2.3)*
Siderosis (%)	0% (0/30)	...	9.1% (1/11)	...	93.3% (14/15)*	...
Cortical microinfarcts (mean, range)	13.8% (4/29)	0.2 (0–2)	30.0% (3/10)†	0.8 (0–6)	100% (12/12)*	5 (2–13)*
WMHs volume (cm ³)	...	0.6 (0.2–2.2)	...	1.4 (0.4–6.0)*	...	82.4 (50.7–133.0)*
DPVS-CSO	...	3 (2–3)	...	3 (2–4)	...	4 (3–4)†
DPVS-BG	...	2 (2–2)	...	2 (2–2)	...	2 (2–2)
Lacunar infarcts	32.3% (10/31)	0 (0–1)	27.3% (3/11)	0 (0–1)	13.3% (2/15)*	0 (0–0)

BG indicates basal ganglia; CSO, centrum semiovale; DPVS, dilated perivascular spaces; ICH, intracerebral hemorrhage; MRI, magnetic resonance imaging; and SAH, subarachnoid hemorrhage.

* $P < 0.001$, controls vs presymptomatic carriers and controls vs symptomatic carriers.

† $P < 0.05$, controls vs presymptomatic carriers and controls vs symptomatic carriers.

practitioner. At 7T, T_2^* -weighted gradient-echo scans and fluid-attenuated inversion recovery sequences were performed. At 3T, fluid-attenuated inversion recovery, T1-weighted images, and T2-weighted images were acquired. Microbleeds, intracerebral hemorrhages, superficial siderosis, and convexity subarachnoid hemorrhages were assessed at 7T T_2^* -weighted sequences. Cortical microinfarcts were scored as previously described.⁸ Because counting microinfarcts is a relatively new technique, these lesions were scored by 2 independent experienced raters, and inter-rater reliability was calculated. At 3T, WMHs, dilated perivascular spaces in the basal ganglia and centrum semiovale, and lacunar infarcts were assessed. A battery of neuropsychological and neuropsychiatric tests was performed ([online-only Data Supplement](#)).

Statistics

Mann–Whitney U testing was used to assess differences in age between groups, univariate general linear modeling analysis was used to assess differences in blood pressure measurements, adjusted

for age and sex, and χ^2 tests were used to assess differences in sex, educational level, and percentage cardiovascular risk factors between groups. For assessment of microinfarcts, interobserver variability was calculated. Univariate general linear modeling analysis was used to assess the association between MRI markers and cognitive performance on the one hand and on the other, mutation status, adjusted for age, sex, and education ([online-only Data Supplement](#)).

Results

The characteristics of the presymptomatic mutation carriers and symptomatic mutation carriers versus controls are shown in Table 1 in the [online-only Data Supplement](#). All symptomatic patients clinically experienced one or multiple strokes as first symptomatic sign of the disease. None of the symptomatic patients experienced objective cognitive impairment as first sign of the disease. None of the presymptomatic mutation

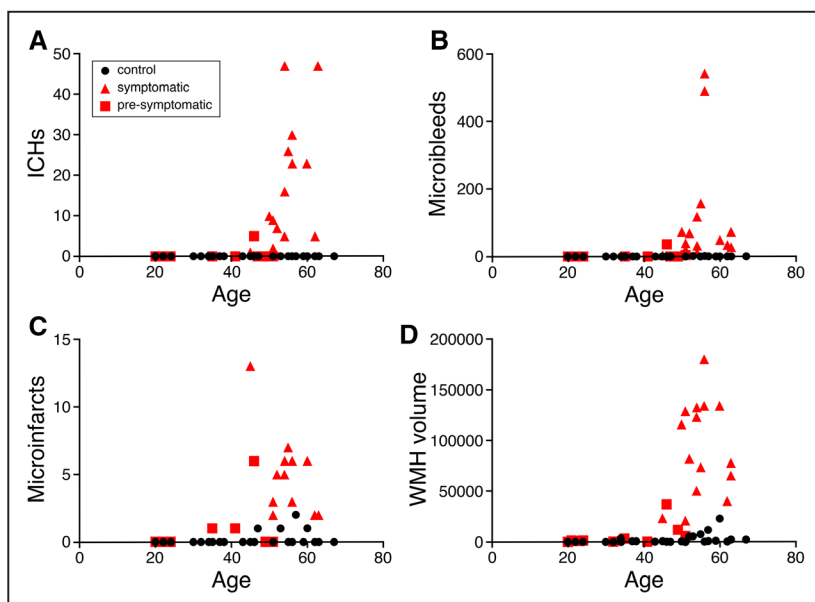


Figure. Graphs of (A) intracerebral hemorrhages (ICHs), (B) microbleeds, (C) microinfarcts, and (D) white matter hyperintensity (WMH) volume against age in the 3 different groups.

Table 2. Cognitive and Neuropsychiatric Markers in Presymptomatic and Symptomatic Mutation Carriers Versus Controls

Cognitive Domain	Cognitive Tests	Controls (n=33) (SD; Range)	Presymptomatic Mutation Carriers (n=12) (SD; Range)	Symptomatic Mutation Carriers (n=15) (SD; Range)
Global cognitive function	MMSE (mean points)	29.4 (0.7; 27–30)	29.8 (0.6; 28–30)	26.7 (3.8; 16–30)*
Memory	WMS (mean memory quotient)	124.9 (10.8; 105–143)	121.6 (11.5; 103–137)	110.5 (24.9; 72–143)†
	HVLT immediate recall	28.2 (4.3; 16–35)	28.0 (2.8; 24–32)	21.4 (7.5; 7–31)†
	HVLT delayed recall	10.4 (2.3; 6–19)	9.8 (1.7; 7–12)	6.8 (3.7; 0–12)*
Psychomotor speed	TMT A (mean s)	30.3 (10.7; 15–53)	26.6 (8.8; 16–44)	54.8 (21.7; 29–96)*
Executive function	TMT B (mean s)	59.9 (22.5; 30–105)	54.5 (13.4; 39–85)	161.2 (127.1; 67–540)*
	DSST (mean nr of correct symbols)	77.1 (15.5; 46–110)	84.0 (11.8; 62–101)	47.3 (17.3; 18–79)*
	Clock drawing (median points)	3.0 (0.2; 2–3)	3.0 (0.5; 2–3)	2.0 (0.6; 1–3)*
Language	Letter fluency (mean nr of correct words)	33.9 (9.1; 13–50)	32.9 (11.8; 19–54)	23.5 (7.9; 12–38)†
	Category fluency (mean nr of correct words)	22.2 (5.6; 14–40)	23.0 (6.0; 14–32)	15.3 (5.5; 3–23)†
	BNT (mean nr of correct items)	28.6 (1.0; 27–30)	28.3 (1.1; 26–30)	23.0 (6.6; 4–29)*
Apathy	Apathy scale of Starkstein (mean points)	9.4 (3.7; 2–15)	8.9 (5.2; 2–20)	8.9 (4.9; 2–18)
Anxiety	HADS subscale anxiety (mean points)	3.5 (2.7; 0–10)	4.0 (2.8; 0–9)	5.5 (3.8; 0–13)†
Depression	HADS subscale depression (mean points)	1.9 (2.3; 0–9)	1.8 (3.0; 0–10)	4.1 (3.2; 0–11)†

BNT indicates Boston Naming Test; DSST, Defense Activity for Non-Traditional Education Support (DANTES) Subject Standardized Test; HADS, Hospital Anxiety and Depression Scale; HVLT, Hopkins Verbal Learning Test; MMSE, Mini-Mental State Examination; nr, number; TMT, Trail Making Test; and WMS, Wechsler Memory Scale.

* $P < 0.001$, controls vs presymptomatic carriers and controls vs symptomatic carriers.

† $P < 0.05$, controls vs presymptomatic carriers and controls vs symptomatic carriers.

carriers reported cognitive complaints or showed objective cognitive impairment.

The κ value for interobserver agreement was almost perfect for detecting presence of cortical microinfarcts, $\kappa = 0.88$ ($P < 0.001$). The prevalence and median count of microbleeds, intracerebral hemorrhages, convexity subarachnoid hemorrhages, superficial siderosis, microinfarcts, median volume of WMHs, and dilated perivascular spaces-centrum semiovale are significantly higher in the symptomatic mutation carriers than in controls, adjusted for age and sex ($P < 0.05$; Table 1). In presymptomatic mutation carriers, the prevalence of microinfarcts ($P = 0.044$) and median volume of WMHs ($P = 0.000$) is significantly increased compared with controls adjusted for age and sex. As illustrated in Figure, our cross-sectional data suggest that patients start developing changes on MRI at ≈ 5 years before developing their first symptoms (at age of 45 years).

All cognitive tests were performed significantly worse by symptomatic mutation carriers than controls, adjusted for age, sex, and education ($P < 0.05$). They also showed a higher score on the Hospital Anxiety and Depression Scale (HADS) anxiety and depression scale ($P < 0.05$). Presymptomatic mutation carriers did not show any significant differences compared with controls on the cognitive and neuropsychiatric tests (Table 2).

Discussion

Of all sCAA markers, WMHs and cortical microinfarcts (ischemic manifestations of CAA) are more prevalent among presymptomatic subjects and precede cognitive and neuropsychiatric symptoms and intracerebral hemorrhages, whereas other sCAA MRI-related markers are only more prevalent in symptomatic patients. Microinfarcts are a new finding likely

related to the fact that 7T MRI was not available in previous studies. Although it has been suggested that in sCAA amyloid- β deposition alone could cause cognitive impairment⁷ and that in HCHWA-D mutation carriers cognitive deterioration can precede the first clinical stroke,² we showed that cognitive abnormalities are not present in presymptomatic subjects with HCHWA-D. The generalizability of these findings to sCAA remains to be established because it occurs in older individuals in whom there is a closer association with amyloid plaques and the clinical features of Alzheimer disease. Using the most sensitive MRI techniques for all lesions, we found several abnormal MRI characteristics in the presymptomatic phase but no cognitive deficits suggesting that HCHWA-D starts with abnormalities in the brain caused by amyloid- β deposition, which then causes cognitive deficits.

Sources of Funding

This work was supported by NIH (R01 NS070834).

Disclosures

None.

References

- Zhang-Nunes SX, Maat-Schieman ML, van Duinen SG, Roos RA, Frosch MP, Greenberg SM. The cerebral beta-amyloid angiopathies: hereditary and sporadic. *Brain Pathol*. 2006;16:30–39.
- Bornebroek M, Van Buchem MA, Haan J, Brand R, Lanser JB, de Bruine FT, et al. Hereditary cerebral hemorrhage with amyloidosis-Dutch type: better correlation of cognitive deterioration with advancing age than with number of focal lesions or white matter hyperintensities. *Alzheimer Dis Assoc Disord*. 1996;10:224–231.
- Linn J, Herms J, Dichgans M, Brückmann H, Fesl G, Freilinger T, et al. Subarachnoid hemosiderosis and superficial cortical hemosiderosis

- in cerebral amyloid angiopathy. *AJNR Am J Neuroradiol*. 2008;29:184–186. doi: 10.3174/ajnr.A0783.
4. Chen YW, Gurol ME, Rosand J, Viswanathan A, Rakich SM, Groover TR, et al. Progression of white matter lesions and hemorrhages in cerebral amyloid angiopathy. *Neurology*. 2006;67:83–87. doi: 10.1212/01.wnl.0000223613.57229.24.
 5. Haan J, Algra PR, Roos RA. Hereditary cerebral hemorrhage with amyloidosis–Dutch type. Clinical and computed tomographic analysis of 24 cases. *Arch Neurol*. 1990;47:649–653.
 6. Charidimou A, Gang Q, Werring DJ. Sporadic cerebral amyloid angiopathy revisited: recent insights into pathophysiology and clinical spectrum. *J Neurol Neurosurg Psychiatry*. 2012;83:124–137. doi: 10.1136/jnnp-2011-301308.
 7. Xu D, Yang C, Wang L. Cerebral amyloid angiopathy in aged Chinese: a clinico-neuropathological study. *Acta Neuropathol*. 2003;106:89–91. doi: 10.1007/s00401-003-0706-1.
 8. van Veluw SJ, Biessels GJ, Luijten PR, Zwanenburg JJ. Assessing cortical cerebral microinfarcts on high resolution MR images. *J Vis Exp*. 2015;105:e53125. doi: 10.3791/53125.

Early Magnetic Resonance Imaging and Cognitive Markers of Hereditary Cerebral Amyloid Angiopathy

Sanneke van Rooden, Anna M. van Opstal, Gerda Labadie, Gisela M. Terwindt, Marieke J.H. Wermer, Andrew G. Webb, Huub A.M. Middelkoop, Steven M. Greenberg, Jeroen van der Grond and Mark A. van Buchem

Stroke. 2016;47:3041-3044; originally published online November 10, 2016;
doi: 10.1161/STROKEAHA.116.014418

Stroke is published by the American Heart Association, 7272 Greenville Avenue, Dallas, TX 75231
Copyright © 2016 American Heart Association, Inc. All rights reserved.
Print ISSN: 0039-2499. Online ISSN: 1524-4628

The online version of this article, along with updated information and services, is located on the World Wide Web at:

<http://stroke.ahajournals.org/content/47/12/3041>

Data Supplement (unedited) at:

<http://stroke.ahajournals.org/content/suppl/2016/11/15/STROKEAHA.116.014418.DC1>

Permissions: Requests for permissions to reproduce figures, tables, or portions of articles originally published in *Stroke* can be obtained via RightsLink, a service of the Copyright Clearance Center, not the Editorial Office. Once the online version of the published article for which permission is being requested is located, click Request Permissions in the middle column of the Web page under Services. Further information about this process is available in the [Permissions and Rights Question and Answer](#) document.

Reprints: Information about reprints can be found online at:
<http://www.lww.com/reprints>

Subscriptions: Information about subscribing to *Stroke* is online at:
<http://stroke.ahajournals.org/subscriptions/>

ONLINE SUPPLEMENT

Early MRI and cognitive markers of hereditary cerebral amyloid angiopathy

Sanneke van Rooden, PhD^{1,2}

Anna M. van Opstal, MSc^{1,2}

Gerda Labadie, BSc²

Gisela M. Terwindt, MD, PhD³

Marieke J.H. Wermer, MD, PhD³

Andrew G. Webb, PhD^{1,2}

Huub A.M. Middelkoop, PhD³

Steven M. Greenberg, MD, PhD⁴

Jeroen van der Grond, PhD^{1,2}

Mark A. van Buchem, MD, PhD^{1,2}

From the C.J. Gorter center for high-field MRI¹, departments of Radiology² and Neurology³, Leiden University Medical Center, Leiden, The Netherlands. From the department of Neurology⁴, Massachusetts General Hospital, Boston, U.S.A.

Corresponding author:

J. van der Grond

Dept. of Radiology, C3-Q, Leiden University Medical Center

PO Box 9600, 2300 RC Leiden, the Netherlands

Phone: +31-71-5264376

Fax: +31-71-5248256

E-mail: J.van_der_Grond@lumc.nl

Supplemental Methods

Participants

Subjects were selected via the HCHWA-D patient association in Katwijk (the Netherlands) and the outpatient clinic of the Department of Neurology of the Leiden University Medical Center based on DNA analysis for confirmation of codon 693 mutation in the amyloid- β precursor protein (A β PP) gene. Twenty-seven DNA-proven HCHWA-D mutation carriers were included in the present study. These subjects had a mean age of 45.9 years (25th -75th percentile 35 to 55 years). Seventeen of them were female (mean age 44.4 years, 25th -75th percentile 33 to 53 years) and ten male (mean age of 48.4 years, 25th -75th percentile 34 to 58 years). Both symptomatic (n=15) and pre-symptomatic (n=12) mutation carriers were included. Subjects were considered symptomatic when they had experienced signs of the disease reported to a general practitioner. Control subjects were recruited from individuals at risk for HCHWA-D (one of the parents has HCHWA-D) but who tested genetically negative and from subject spouses, family or friends, who also underwent genetic testing for inclusion. All controls were ascertained to be both stroke-free as well as negative genetic tested. Thirty-three controls were included in the present study. These subjects had a mean age of 45.6 years (25th -75th percentile 34 to 57 years). Twenty of them were female (mean age 41.9 years, 25th -75th percentile 32 to 52 years) and thirteen male (mean age of 51.3 years, 25th -75th percentile 41 to 61 years). The ethics committee of our institution approved the study, and written informed consent was obtained from all subjects.

MRI

Image acquisition

All participants underwent a 7T and 3T MRI scan. 7T MRI was performed on a whole body human MRI system (Philips Healthcare, Best, the Netherlands) using a quadrature transmit and 32-channel receive head coil. 2D flow-compensated transverse T₂*-weighted gradient-echo scan was performed with repetition time (TR)/echo time (TE) 794/25 ms, flip angle 45°, slice thickness 1.0 mm with a 0.1 mm interslice gap, 50 slices and coverage of 10 cm, 240 x 180 x 22 mm field of view (FOV), 1000 x 1024 matrix size – spatial resolution of 0.24 x 0.24 mm² ~ scan duration 20 minutes.¹ 3D magnetization prepared sagittal fluid attenuated inversion recovery (FLAIR) sequence was performed with TR/TE/inversion time (TI) 8000/300/2200 ms, flip angle 100°, slice thickness 1 mm, with 1 mm³ isotropic voxels, scan duration ~ 8 minutes.² At 3T FLAIR scans were performed with: TR/TE: 11.0s/125ms, flip angle 90°, slices 25, FOV 252x179.76x250mm, matrix size 224x224, scan duration ~ 5 minutes. 3D T1-weighted images were acquired with: TR/TE 9/4.6ms, flip angle 8°, FOV = 224x177x168mm, scan duration ~5 minutes. T2-weighted images were acquired with: TR/TE: 4.2s/ 80ms, flip angle 90°, 40 slices, FOV 224x180x144 mm, slice thickness 3.6 mm, matrix size 448x320 and scan duration ~3 minutes.

Image analysis

To be as sensitive and precise as possible for all lesions scored in this study, two different field strengths (7T and 3T) and the best validated methods were used per lesion. The detection of hemorrhagic lesions (microbleeds, ICHs, convexity SAHs and superficial siderosis) was evaluated at 7T T₂*-weighted sequences as this field strength and sequence is

most sensitive for these lesions. Lobar microbleeds (location as described by the Boston criteria³) were defined and scored as previously described.⁴ Only remote, resorbed ICHs were observed and they were defined as parenchymal defects with evidence of hemosiderin in their wall. The number and presence of convexity SAHs was assessed described as a subarachnoid bleeding localized to the convexities of the brain.⁵ The presence of superficial siderosis was assessed described as linear residues of blood in the superficial layers of the cortex.⁶ The number and presence of cortical microinfarcts were scored on 7T FLAIR images as previously described, as these lesions are visualized best using this field strength and sequence.⁷ Since counting microinfarcts is a relatively new technique, these lesions were scored by two independent experienced raters and interrater reliability was calculated. WMHs are defined and analysed using 3T FLAIR images as described earlier using a semi-automated and validated method.⁸ DPVS were evaluated and assessed in the basal ganglia (BG) and centrum semiovale (CSO) on 3T T2-weighted and T1-weighted images. DPVS are defined and rated according to a 4-point semi-quantitative score.⁹ Presence of lacunar infarcts was assessed using 3T T2-weighted and FLAIR images as described earlier.¹⁰

Cognitive and neuropsychiatric function

A battery of neuropsychological tests measuring global cognitive functioning (Mini mental state examination (MMSE)¹¹), memory (Wechsler Memory Scale (WMS)¹² and Hopkins Verbal Learning Test (HVLT)¹³), psychomotor speed (Trailmaking test (TMT) part A), executive function (TMT part B (cognitive flexibility)¹⁴, Digit symbol substitution test (DSST) of the WAIS III¹⁵ and Clock drawing), and language (letter and animal naming (letter and category fluency)¹⁶ and Boston naming test (BNT)¹⁷) were performed. Also neuropsychiatric tests were performed measuring apathy (Apathy scale of Starkstein)¹⁸, anxiety (hospital anxiety and depression scale (HADS)¹⁹) and depression (HADS).

Statistics

Mann-Whitney U-testing was used to assess differences in age between groups, univariate general linear modeling analysis was used to assess differences in blood pressure measurements between groups, adjusted for age and sex, and chi-square tests were used to assess differences in sex, educational level and percentage cardiovascular risk factors between groups. For counting microinfarcts, the interobserver variability (kappa value) was calculated and the grading of interobserver agreement was performed according to the recommendations of Landis and Koch.²⁰ Univariate general linear modeling analysis was used to assess the association between the prevalence and median of MRI markers (for MRI markers (except cortical microinfarcts) natural log transformation was used because of a non-normal distribution) and mutation status, adjusted for age and sex. Univariate general linear modeling analysis was also used to assess the association between cognitive and neuropsychiatric tests and mutation status, adjusted for age, sex and. All statistical analyses were performed with the Statistical Package of Social Sciences (SPSS, version 20.0; SPSS, Chicago, Ill).

Supplemental Tables

Table I: Baseline characteristics of pre-symptomatic and symptomatic mutation carriers versus controls

	Controls (SD; 25 th -75 th percentile) (N=33)	Pre-symptomatic carriers (SD; 25 th - 75 th percentile) (N=12))	Symptomatic carriers (SD; 25 th -75 th percentile) (N=15)
Age (years)	45.6 (14.1; 34-57)	34.3 (12.1; 23-47)*	55.1 (5.2; 51-60)*
Sex (male/female)	13/20	3/9	7/8
Education (median)	Associate's degree	Bachelor's degree	Associate's degree
Systolic blood pressure	130.6 (26.1; 109 - 142)	125.2 (14.4; 112 - 133)	144.2 (19.8; 129 - 168)
Diastolic blood pressure	81.5 (12.2; 72 - 87)	80.4 (9.4; 73 - 87)	89.1 (10.4; 78 - 96)
Mean arterial pressure	97.6 (15.9; 86 - 107)	95.3 (9.4; 88 - 102)	107.5 (12.4; 95 - 117)
Pulse pressure	49.1 (18.4; 36 - 60)	44.8 (13.2; 33 - 50)	55.1 (14.7; 43 - 69)
Hypertension (%)	18.2	0	40
Hyperlipidemia (%)	6.1	0	33.3*
Diabetes Mellitus (%)	0	8.3	6.7
Cardiovascular disease (%)	0	0	6.7

Supplemental References

1. van Rooden S, Versluis MJ, Liem MK, Milles J, Maier AB, Oleksik AM, et al. Cortical phase changes in alzheimer's disease at 7t mri: A novel imaging marker. *Alzheimers. Dement.* **2014;10:e19-26**
2. van Rooden S, Goos JD, van Opstal AM, Versluis MJ, Webb AG, Blauw GJ, et al. Increased number of microinfarcts in alzheimer disease at 7-t mr imaging. *Radiology.* 2014;270:205-211
3. Greenberg SM. Cerebral amyloid angiopathy: Prospects for clinical diagnosis and treatment. *Neurology.* 1998;51:690-694
4. Greenberg SM, Vernooij MW, Cordonnier C, Viswanathan A, Al-Shahi SR, Warach S, et al. Cerebral microbleeds: A guide to detection and interpretation. *Lancet Neurol.* 2009;8:165-174
5. Kumar S, Goddeau RP, Jr., Selim MH, Thomas A, Schlaug G, Alhazzani A, et al. Atraumatic convexal subarachnoid hemorrhage: Clinical presentation, imaging patterns, and etiologies. *Neurology.* 2010;74:893-899
6. Linn J, Herms J, Dichgans M, Bruckmann H, Fesl G, Freilinger T, et al. Subarachnoid hemosiderosis and superficial cortical hemosiderosis in cerebral amyloid angiopathy. *AJNR Am. J. Neuroradiol.* 2008;29:184-186
7. van Veluw SJ, Biessels GJ, Luijten PR, Zwanenburg JJ. Assessing cortical cerebral microinfarcts on high resolution mr images. *J. Vis. Exp.* 2015; doi: **10.3791/53125**
8. Hafkemeijer A, Altmann-Schneider I, de Craen AJ, Slagboom PE, van der Grond J, Rombouts SA. Associations between age and gray matter volume in anatomical brain networks in middle-aged to older adults. *Aging Cell.* 2014;13:1068-1074
9. Zhu YC, Tzourio C, Soumare A, Mazoyer B, Dufouil C, Chabriat H. Severity of dilated virchow-robin spaces is associated with age, blood pressure, and mri markers of small vessel disease: A population-based study. *Stroke.* 2010;41:2483-2490
10. Klarenbeek P, van Oostenbrugge RJ, Rouhl RP, Knottnerus IL, Staals J. Ambulatory blood pressure in patients with lacunar stroke: Association with total mri burden of cerebral small vessel disease. *Stroke.* 2013;44:2995-2999
11. Folstein MF, Folstein SE, McHugh PR. "Mini-mental state". A practical method for grading the cognitive state of patients for the clinician. *J. Psychiatr. Res.* 1975;12:189-198
12. Wechsler DA. A standardized memory scale for clinical use. *Journal of Psychology.* 1945;19:87-95
13. Brandt J. The hopkins verbal learning test: Development of a new memory test with six equivalent forms. *The Clinical Neuropsychologist.* 1991;5:125-142
14. Reitan RM. Validity of the trail making test as an indication of organic brain damage. *Percept Mot Skills.* 1958;8:271-276
15. Wechsler D. *Wechsler adult intelligence scale-third edition.* London: The Psychological Corporation Limited; 1997.
16. Lezak MD. *Neuropsychological assessment.*: Oxford [Oxfordshire]: Oxford University Press.; 1995.
17. Kaplan, Goodglass, Harold, Weintraub, Sandra. *Boston naming test.* Philadelphia: Lea & Febiger; 1983.
18. Starkstein SE, Petracca G, Chemerinski E, Kremer J. Syndromic validity of apathy in alzheimer's disease. *Am. J. Psychiatry.* 2001;158:872-877
19. Zigmond AS, Snaith RP. The hospital anxiety and depression scale. *Acta Psychiatr. Scand.* 1983;67:361-370

20. Landis JR, Koch GG. The measurement of observer agreement for categorical data. *Biometrics*. 1977;33:159-174