

Genetics

The Common *ABCA4* Variant p.Asn1868Ile Shows Nonpenetrance and Variable Expression of Stargardt Disease When Present in *trans* With Severe Variants

Esmee H. Runhart,^{1,2} Riccardo Sangermano,²⁻⁴ Stéphanie S. Cornelis,^{2,3} Joke B. G. M. Verheij,⁵ Astrid S. Plomp,⁶ Camiel J. F. Boon,^{7,8} Dorien Lugtenberg,³ Susanne Roosing,^{2,3} Nathalie M. Bax,¹ Ellen A. W. Blokland,³ Marlie H. M. Jacobs-Camps,³ Saskia D. van der Velde-Visser,³ Jan-Willem R. Pott,⁹ Klaus Rohrschneider,¹⁰ Alberta A. H. J. Thiadens,^{11,12} Caroline C. W. Klaver,^{1,11,12} L. Ingeborgh van den Born,¹³ Carel B. Hoyng,¹ and Frans P. M. Cremers^{2,3}

¹Department of Ophthalmology, Radboud University Medical Center, Nijmegen, The Netherlands

²Donders Institute for Brain, Cognition and Behaviour, Radboud University Medical Center, Nijmegen, The Netherlands

³Department of Human Genetics, Radboud University Medical Center, Nijmegen, The Netherlands

⁴Radboud Institute of Molecular Life Sciences, Radboud University Medical Center, Nijmegen, The Netherlands

⁵Department of Medical Genetics, University Medical Center Groningen, University of Groningen, Groningen, The Netherlands

⁶Department of Clinical Genetics, Academic Medical Center, Amsterdam, The Netherlands

⁷Department of Ophthalmology, Leiden University Medical Center, Leiden, The Netherlands

⁸Department of Ophthalmology, Academic Medical Center, Amsterdam, The Netherlands

⁹Department of Ophthalmology, University Medical Center Groningen, University of Groningen, Groningen, The Netherlands

¹⁰Universitätsaugenklinik, Ruprecht-Karls-Universität, Heidelberg, Heidelberg, Germany

¹¹Department of Ophthalmology, Erasmus Medical Center, Rotterdam, The Netherlands

¹²Department of Epidemiology, Erasmus Medical Center, Rotterdam, The Netherlands

¹³The Rotterdam Eye Hospital and the Rotterdam Ophthalmic Institute, Rotterdam, The Netherlands

Correspondence: Frans P. M. Cremers, Department of Human Genetics, Radboud University Medical Center, P.O. Box 9101, 6500 HB, Nijmegen, The Netherlands; Frans.Cremers@radboudumc.nl

EHR and RS contributed equally to the work presented here and should therefore be regarded as equivalent authors.

LIvdB, CBH, and FPMC contributed equally to the work presented here and should therefore be regarded as equivalent authors.

Submitted: January 17, 2018
Accepted: May 15, 2018

Citation: Runhart EH, Sangermano R, Cornelis SS, et al. The common *ABCA4* variant p.Asn1868Ile shows nonpenetrance and variable expression of Stargardt disease when present in *trans* with severe variants. *Invest Ophthalmol Vis Sci.* 2018;59:3220-3231. <https://doi.org/10.1167/iovs.18-23881>

PURPOSE. To assess the occurrence and the disease expression of the common p.Asn1868Ile variant in patients with Stargardt disease (STGD1) harboring known, monoallelic causal *ABCA4* variants.

METHODS. The coding and noncoding regions of *ABCA4* were sequenced in 67 and 63 STGD1 probands respectively, harboring monoallelic *ABCA4* variants. In case p.Asn1868Ile was detected, segregation analysis was performed whenever possible. Probands and affected siblings harboring p.Asn1868Ile without additional variants in *cis* were clinically evaluated retrospectively. Two asymptomatic siblings carrying the same *ABCA4* variants as their probands were clinically examined. The penetrance of p.Asn1868Ile was calculated using allele frequency data of *ABCA4* variants in non-Finnish European individuals.

RESULTS. The p.Asn1868Ile variant was found in *cis* with known variants in 14/67 probands. In 27/67 probands, we identified p.Asn1868Ile without additional variants in *cis*, in combination with known, mainly severe *ABCA4* variants. In 23/27 probands, the *trans* configuration was established. Among 27 probands and 6/7 STGD1 siblings carrying p.Asn1868Ile, 42% manifested late-onset disease (>44 years). We additionally identified four asymptomatic relatives carrying a combination of a severe variant and p.Asn1868Ile; ophthalmologic examination in two persons did not reveal STGD1. Based on *ABCA4* allele frequency data, we conservatively estimated the penetrance of p.Asn1868Ile, when present in *trans* with a severe variant, to be below 5%.

CONCLUSIONS. A significant fraction of genetically unexplained STGD1 cases carries p.Asn1868Ile as a second variant. Our findings suggest exceptional differences in disease expression or even nonpenetrance of this *ABCA4* variant, pointing toward an important role for genetic or environmental modifiers in STGD1.

Keywords: *ABCA4* protein, nonpenetrance, modifiers, Stargardt disease, retinal dystrophy

Autosomal recessive Stargardt disease (STGD1; Mendelian Inheritance in Man [MIM] 248200) represents the most common hereditary macular dystrophy (estimated prevalence, 1:10,000)¹ and is funduscopically characterized by lipofuscin deposits in the retinal pigment epithelium (RPE), presenting as

yellow-white flecks and progressive atrophy of the macular RPE.^{2,3} STGD1 is caused by sequence variants in the transmembrane ATP-binding cassette transporter type A4 (*ABCA4*; MIM 601691).⁴ Different combinations of *ABCA4* variants give rise to several phenotypes, which can partly be



attributed to differences in the residual activity of the *ABCA4* protein.⁵⁻¹⁰ A combination of disease-causing *ABCA4* alleles may, therefore, result in a severe, early-onset STGD1 phenotype (i.e., onset ≤ 10 years of age),^{11,12} which is often observed as rapidly progressive cone-rod dystrophy,^{5,13} in classical STGD1,¹⁰ or in late-onset STGD1.¹⁴⁻¹⁶ In about half of the patients with late-onset STGD1 (onset >44 years of age), only one disease-causing allele was identified, despite the sequence analysis of all coding variants.¹⁶

In carriers of monoallelic *ABCA4* variants, the second variant can reside in introns, outside of splice sites, not detected by standard sequencing methods.¹⁷⁻²⁰ A very small fraction of these unidentified defects comprise copy number variants that elude detection by PCR-based sequencing techniques.^{18,21-23} Identification of disease-causing alleles and insight into their associations with differences in disease presentation and severity are essential for the counseling of patients and become increasingly important, as research on therapeutic approaches is rapidly evolving.

Recently, a frequent *ABCA4* coding variant, c.5603A>T (p.As1868Ile), which thus far was considered benign due to its high minor allele frequency (AF) of 6.6% in the non-Finnish European population,²⁴ was associated with STGD1.^{25,26} This variant was found to be phenotypically expressed only when in *trans* with a deleterious mutation (i.e., presence of the variants on different alleles) and explained $>50\%$ of all monoallelic cases and $\sim 80\%$ of late-onset cases in a US cohort.²⁶ In addition, the c.2588G>C (p.[Gly863Ala, Gly863del]) variant was proposed to act as a mild pathogenic variant only when in *cis* with p.As1868Ile (i.e., presence of the variants on the same allele).

In this study, we investigated STGD1 probands with a single disease-causing *ABCA4* allele for the presence of the p.As1868Ile variant, performed segregation analysis through the inclusion of unaffected family members to assess the configuration of the identified *ABCA4* variants (i.e., in *cis* or in *trans*), and performed ophthalmologic studies to evaluate the full spectrum of phenotypes associated with the single-variant allele p.As1868Ile (i.e., no *ABCA4* variants identified in *cis*). In addition, we calculated the penetrance for the p.As1868Ile variant by using allele frequencies of severe *ABCA4* variants.

METHODS

Study Population and Genetic Analysis

We ascertained 67 clinically suspected STGD1 patients in whom only one disease-causing variant in the *ABCA4* gene had been identified, from eight ophthalmic centers in The Netherlands ($n = 64$) and one center in Germany ($n = 3$). Between 1998 and 2017, these subjects were screened for disease-causing variants in the coding regions and flanking splice sites of *ABCA4*, and, recently, for 63 subjects, $\sim 95\%$ of the entire *ABCA4* gene (exons and introns) was further sequenced by using a custom Haloplex Target Enrichment kit (Agilent, Santa Clara, CA, USA) as described previously.²⁷ All variants identified by Haloplex-based *ABCA4* sequencing were confirmed using Sanger sequencing. We investigated probands harboring monoallelic variants for the presence of the p.As1868Ile variant and rare (minor AF <0.005) deep-intronic variants. Four DNA samples were analyzed using non-Haloplex-based alternative techniques (Supplementary Methods S1).

The segregation of the sequence variants identified in the probands was studied by sequencing the corresponding genomic DNA fragments in relatives (Supplementary Table S1). Participants gave informed consent after an explanation of

the nature of the study. The study procedures were performed according to approval of the medical ethics committee of the Radboud University Medical Center and the tenets of the Declaration of Helsinki.

Clinical Evaluation

Probands and affected siblings carrying the single-variant allele p.As1868Ile were clinically evaluated. Medical records were reviewed and available clinical data were collected, comprising age at onset and initial symptoms, age at diagnosis, best-corrected visual acuity (BCVA), and findings on ophthalmoscopy. Age of onset was defined as the age at which the initial symptoms were noted by the patient. In asymptomatic subjects and in cases where age at onset was not noted in the patient file, we used the age at which macular abnormalities were first diagnosed by an ophthalmologist.

Furthermore, we examined available data acquired by fundus photography, fundus autofluorescence (FAF) imaging using a confocal scanning laser ophthalmoscope (Spectralis; Heidelberg Engineering, Heidelberg, Germany), spectral domain-optical coherence tomography (OCT; Spectralis), or time-domain OCT (Stratus; Carl Zeiss Meditec, Dublin, CA, USA), fluorescein angiography, and full-field electroretinography, according to the International Society for Clinical Electrophysiology of Vision standards. We assessed presence of foveal sparing, which we defined as RPE atrophy encircling a structurally and functionally (BCVA, $\geq 20/200$) preserved fovea by $\geq 180^\circ$,¹⁵ by evaluation of FAF and/or OCT.

Two asymptomatic siblings who carried the same combination of *ABCA4* variants as the respective probands were clinically examined by measurement of BCVA and performance of fundus photography, FAF, and OCT.

ABCA4 Allele Frequency Calculations and p.As1868Ile Penetrance Estimates

To assess the penetrance of the common variant p.As1868Ile when present in *trans* with a severe *ABCA4* variant, we used AF data in $\sim 33,000$ non-Finnish European control subjects in Exome Aggregation Consortium²⁴ (available at: <http://exac.broadinstitute.org>; accessed September 01, 2017), as at least 24/27 patients belong to this population. First, because we did not know all *ABCA4* variants that are in linkage disequilibrium with p.As1868Ile, we estimated the frequency of the single-variant allele p.As1868Ile. Zernant et al.²⁶ indicated that 10% of c.2588G>C alleles carry c.5603A>T (p.As1868Ile) in *cis* and that this allele, containing both variants, probably acts as a fully penetrant mild allele if present in a compound heterozygous state with a severe *ABCA4* variant. In the same study, consistent with our data, the frequent noncanonical splice site variant c.5461-10T>C was always found in *cis* with c.5603A>T (p.As1868Ile). Therefore, the AF of the single-variant allele p.As1868Ile was calculated based on its total AF minus the AF of c.5461-10T>C and 10% of the AF of c.2588G>C. Other variants have been found in *cis* with p.As1868Ile, but their cumulative non-Finnish European AF is likely negligible and was not taken into account.

Second, we calculated a cumulative AF of severe *ABCA4* variants. We determined the sum AF of all protein-truncating variants (i.e., stop mutations, frameshift mutations) and canonical splice site variants that, in the majority of cases, result in exon skipping and likely in the absence of *ABCA4* activity, and added the AF of noncanonical splice site variants (i.e., RNA splice variants outside the conserved intronic

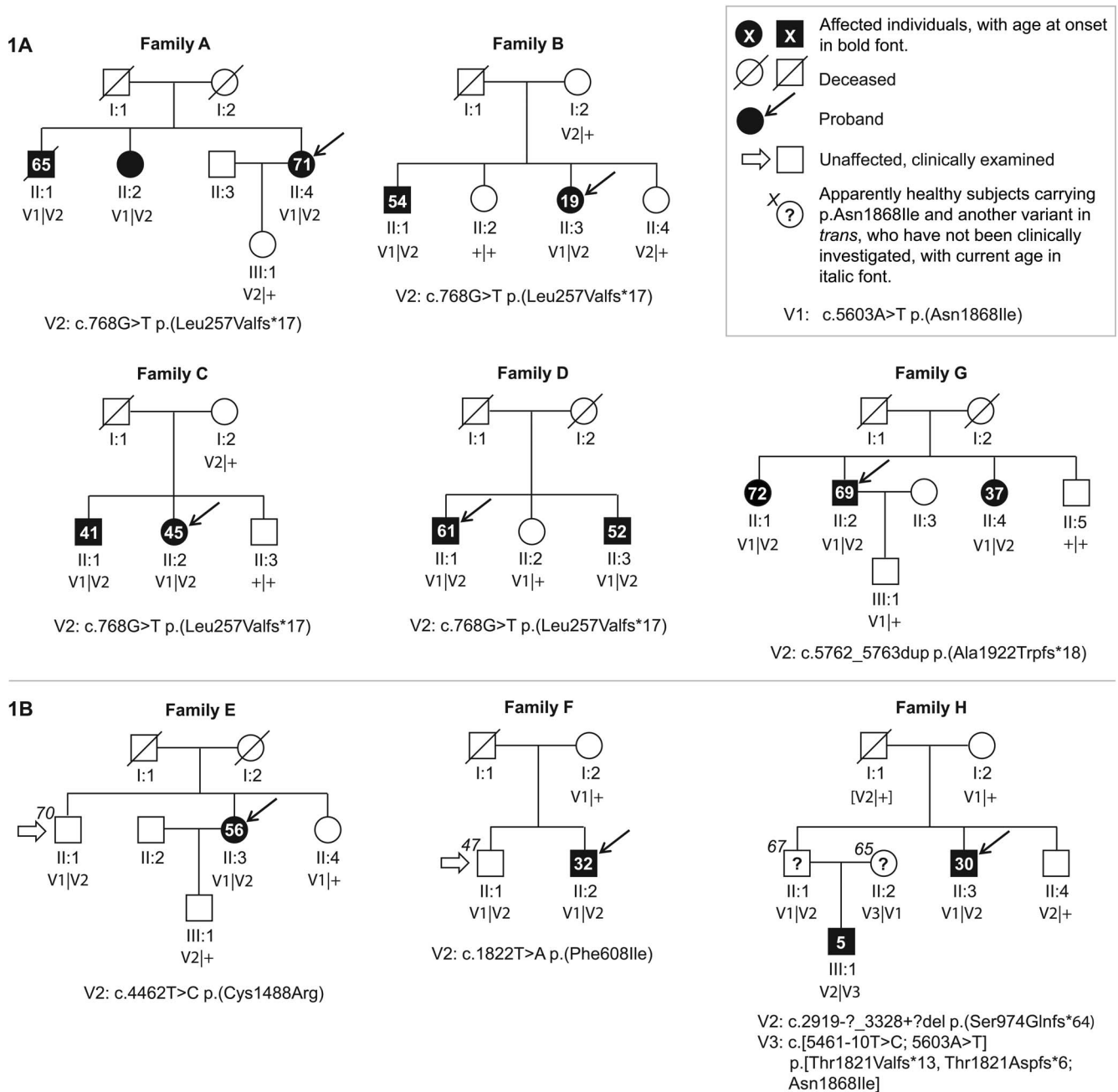


FIGURE 1. *ABCA4* variant c.5603A>T (V1) is associated with variable age at onset and putative nonpenetrance of Stargardt disease. (A) Segregation analysis of *ABCA4* variants in STGD1 families A–D, and G, with multiple affected individuals, showed that V1 in combination with a severe variant segregated with the disease. As expected for an autosomal recessive-inherited Mendelian trait, all affected and genetically tested individuals in families A–D, and G carry two *ABCA4* variants in *trans*, whereas unaffected individuals carry one or no variant. (B) In families E, F, and H, reduced penetrance or even nonpenetrance occurs. Family H is part of a previously described multigeneration pedigree.^{13,20} Proband H-II:3 and the unaffected sibling H-II:1 carry V1 and c.2919-?_3328+?del, whereas the unaffected individual H-II:2, the spouse of H-II:1, is compound heterozygous for V1 and c.[5461-10T>C; 5603A>T]. For H-I:1, the variants were deduced by haplotype analysis.

dinucleotides at the ends of introns) that resulted in less than 25% of normally spliced *ABCA4*.²⁸

Finally, given an estimated prevalence of STGD1 of 1 in 10,000 individuals¹ and a population in The Netherlands of 17,150,000 people, the expected and observed number of STGD1 patients due to the combination of the single-variant allele p.Asn1868Ile and a severe variant in The Netherlands were compared.

RESULTS

Genetic Analysis

In 14/67 probands, we found p.Asn1868Ile to be in *cis* with causal protein-coding or splice site variants, that is c.5461-10T>C ($n = 9$), c.2588G>C ($n = 3$), c.4469G>A ($n = 1$), and c.818G>A ($n = 1$). We excluded these patients from clinical evaluation.

TABLE. Clinical and Genetic Characteristics of STGD1 Patients Carrying c.5603A>T (p.Asn1868Ile)

Subject / Sex / Age Latest Visit, y‡	Age at Onset, y	Latest Visual Acuity		Fundus and Imaging Features	Dark Choroid on Fluorescein Angiography	Full-Field ERG†		Genotype: ABCA4 Variant(s) in <i>Trans</i>		
		RE	LE			Light Adapted (RE/LE)	Dark Adapted (RE/LE)	cDNA Variant	Protein Variant	Functional Effect
A-II:4 / F / 75 ^{a,b}	71	20/25	20/20	Yellow-white pisciform flecks throughout the posterior pole, no atrophy	Yes	N	N	c.768G>T	p.(Leu257Valfs*17)§	S
B-II:1 / M / 63 ^{a,b,c}	54	20/200	20/200	Yellow-white pisciform flecks throughout the posterior pole and midperiphery with chorioretinal atrophy in macula	Yes	SR	SR	c.768G>T	p.(Leu257Valfs*17)§	S
B-II:3 / F / 60	19	CF	20/400	Extensive chorioretinal atrophy and pigmentary changes in macula with yellow-gray pisciform flecks throughout posterior pole and midperiphery. Additionally, temporal and inferior peripheral in RE chorioretinal scars of Coats-like lesions and laser therapy.	Yes	NP	NP	c.768G>T	p.(Leu257Valfs*17)§	S
C-II:1 / M / 49	41	20/20	20/20	Yellow-white pisciform flecks throughout the posterior pole and midperiphery with parafoveal chorioretinal atrophy in the left eye with foveal sparing	NP	N (45 y)	N (45 y)	c.768G>T	p.(Leu257Valfs*17)§	S
C-II:2 / F / 55	45	20/50	20/20	Yellow-white pisciform flecks throughout the posterior pole and extensive chorioretinal atrophy with foveal sparing	NP	NP	NP	c.768G>T	p.(Leu257Valfs*17)§	S
D-II:1 / M / 68	61	CF	20/130	62 y: yellow-white pisciform flecks throughout the posterior pole and parafoveal chorioretinal atrophy with foveal sparing 68 y: chorioretinal atrophy in macula with a few surrounding pisciform yellow-white flecks	Yes	N (63 y)	NP (63 y)	c.768G>T	p.(Leu257Valfs*17)§	S
D-II:3 / M / 58	52	20/20	20/22	Predominantly perimacular pisciform yellow-white flecks and mottled decreased FAF in macula with foveal sparing	NP	NP	NP	c.768G>T	p.(Leu257Valfs*17)§	S
E-II:3 / F / 64 ^{a,b,c}	56	20/400	20/400	Foveal changes with perimacular and peripapillary irregular yellow-white flecks and mottled decreased FAF in macula (Fig. 3D-F)	Yes	N	N	c.4462T>C	p.(Cys1488Arg)	NA
F-II:2 / M / 41	32	20/66	20/66	Foveal changes with perimacular and peripapillary irregular yellow-white flecks and mottled decreased FAF in macula (Figs. 3J-I)	Yes	N	N	c.1822T>A	p.(Phe608Ile)	S

TABLE. Continued

Subject / Sex / Age Latest Visit, y#	Age at Onset, y	Latest Visual Acuity		Fundus and Imaging Features	Dark Choroid on Fluorescein Angiography	Full-Field ERG†		Genotype: ABCA4 Variant(s) in Trans		Functional Effect
		RE	LE			Light Adapted (RE/LE)	Dark Adapted (RE/LE)	cDNA Variant	Protein Variant	
G-II:1 / F / 76	72	20/25	20/32	Parafoveal pigmentary changes RE, and chorioretinal atrophy with foveal sparing and hyper- and hypoautofluorescent flecks throughout posterior pole on FAF	NP	NP	NP	c.5762_5763dup	p.(Ala1922Trpfs*18)	S
G-II:2 / M / 75 ^c	69	20/25	20/40	Chorioretinal atrophy with foveal sparing and hyper- and hypoautofluorescent flecks throughout posterior pole and midperiphery on FAF (Figs. 2A-C)	NP	N	N/MR	c.5762_5763dup	p.(Ala1922Trpfs*18)	S
G-II:4 / F / 70	37	CF	CF	Extensive chorioretinal atrophy and pigmentary changes in posterior pole and hyper- and hypoautofluorescent flecks throughout posterior pole and midperiphery on FAF	NP	NP	NP	c.5762_5763dup	p.(Ala1922Trpfs*18)	S
H-II:3 / M / 38 ^d	30	20/125	HM¶	Perimacular irregular yellow-white flecks and beaten bronze atrophy in macula (no OCT/FAF)	Yes	N	N	c.2919-?_3328+?del	p.(Ser974Glnfs*64)	S
H-II:3 / F / 29 ^c	18	20/50	20/33	Parafoveal pigmentary changes with yellow-white pisciform flecks throughout the posterior pole and mild atrophy in macula (no OCT/FAF)	No	N	N	c.768G>T	p.(Leu257Valfs*17)§	S
J-II:2 / M / 57	56	20/32	20/330	Pigmentary changes in macula, perimacular yellow-white flecks, and chorioretinal atrophy with in RE foveal sparing, in both eyes surrounded by an area of increased background FAF	NP	NP	NP	c.[5461-10T>C; 5603A>T]	p.[Thr1821Valfs*13, Thr1821Aspfs*6; Asn1868Ile]§	S
K-II:1 / F / 29	23	20/200	20/125	Foveal changes and perimacular yellow-white flecks (no OCT/FAF)	Yes	NP	NP	c.5914G>A***	p.(Gly1972Arg)	NA
L-II:1 / F / 46	31	20/200	20/200	Foveal changes with perimacular yellow-white irregular flecks and mottled decreased FAF in macula	Yes	N (31 y)	N (31 y)	c.768G>T	p.(Leu257Valfs*17)§	S
M-II:1 / F / 69	53	20/50	20/100	Foveal changes with yellow-white pisciform flecks throughout the posterior pole and midperiphery and chorioretinal atrophy with foveal sparing; Attenuated arterioles	Yes	MR (53 y)	N (53 y)	c.6155del	p.(Asn2052Thrfs*9)	S

TABLE. Continued

Subject / Sex / Age Latest Visit, y‡	Latest Visual Acuity			Fundus and Imaging Features	Dark Choroid on Fluorescein Angiography	Full-Field ERG†		Genotype: ABCA4 Variant(s) in <i>Trans</i>		
	RE	LE	Age at Onset, y			Light Adapted (RE/LE)	Dark Adapted (RE/LE)	cDNA Variant	Protein Variant	Functional Effect
N-II:1 / F / 71 ^{a,b,c,f}	CF	20/20	45	45 y: yellow-white pisciform flecks throughout the posterior pole 71 y: extensive chorioretinal atrophy in macula of RE after years of foveal sparing, chorioretinal atrophy with foveal sparing in LE	Yes	SR	SR	c.3874C>T#	p.(Gln1292 [*])	S
O-II:1 / F / 39	20/22	20/20	32	Foveal changes with perimacular yellow-white irregular flecks and mottled FAF in macula with foveal sparing	NP	NP	NP	c.768G>T	p.(Leu257Valfs*17)§	S
P-II:1 / F / 35 ^c	20/50	20/100	32	Foveal changes with perimacular yellow-white irregular flecks and mottled decreased FAF in macula surrounded by a zone of increased background FAF	NP	N	N	c.6428T>G	p.(Met2143Arg)	NA
Q-II:1 / F / 46	20/30	20/32	42	Foveal changes with perimacular yellow-white irregular flecks and mottled decreased FAF in macula	Yes	NP	NP	c.5714+5G>A	p.[-, Glu1863Leufs*33)§	Mo
R-II:1 / M / 30	20/28	20/22	30	Perimacular ring of increased FAF around a zone of mottled decreased FAF with foveal sparing and normal fovea reflex; A few mild hyperfluorescent flecks in posterior pole	NP	N	N	c.5917delG#	p.(Val1973 [*])	S
S-II:1 / F / 30	20/200	20/50	26	Foveal changes with perimacular yellow-white irregular flecks and mottled decreased FAF in macula	Yes	N	N	c.1822T>A	p.(Phe608Ile)	S
T-II:1 / M / 45 ^c	20/66	CF	36	Foveal pigmentary changes and yellow-white pisciform flecks throughout the posterior pole and midperiphery with chorioretinal atrophy in macula	NP	NP	NP	c.3259G>A	p.(Glu1087Lys)	NA
U-II:1 / F / 40	20/40	20/66	37	Perimacular yellow-white pisciform flecks and mottled decreased FAF in macula with foveal sparing	NP	N (37 y)	NP (37 y)	c.1938-1G>A	p.(C)	S
V-II:1 / F / 31	CF	20/100	27	Perimacular yellow-white pisciform flecks and mottled decreased FAF in macula, surrounded by a zone of increased background FAF; initially with foveal sparing	NP	SR (27 y)	N (27 y)	c.5882G>A	p.(Gly1961Glu)	M

TABLE. Continued

Subject / Sex / Age Latest Visit, y#	Latest Visual Acuity		Fundus and Imaging Features	Dark Choroid on Fluorescein Angiography	Full-Field ERG†		Genotype: <i>ABCA4</i> Variant(s) in <i>Trans</i>		
	RE	LE			Light Adapted (RE/LE)	Dark Adapted (RE/LE)	cDNA Variant	Protein Variant	Functional Effect
W-II:1 / F / 55	20/130	20/200	Perimacular yellow-white irregular flecks and a zone of increased background FAF in macula with foveal mottled decreased EAF	NP	N (42 y)	N (42 y)	c.768G>T	p.(Leu257Valfs*17)§	S
X-II:1 / F / 32 ^c	20/200	20/125	Perimacular yellow-white irregular flecks with chorioretinal atrophy in macula	No	N	N	c.4506C>A	p.(Cys1502*)	S
Y-II:1 / F / 53	20/25	20/20	Perimacular yellow-white irregular flecks; Parafoveal chorioretinal atrophy with foveal sparing in RE, and mottled decreased FAF with foveal sparing in LE	Yes	NP	NP	c.[5461-10T>C; 5603A>T]	p.[Thr1821Valfs*13, Thr1821Aspfs*6; Asn1868Ile]§	S
Z-II:1 / F / 44	CF	CF	22 y: Abnormal foveal reflex with macular pigmentary changes 44 y: Perimacular yellow-white irregular flecks and chorioretinal atrophy in macula	NP	N/NP (20 y)	N/NP (20 y)	c.4234C>T#	p.(Gln1412*)	S
AA-II:1 / M / 58	20/20	20/20	Yellow-white pisciform flecks throughout the posterior pole, no atrophy	NP	N	N	c.[4469G>A; 5603A>T]	p.[Cys1490Glufs*12; Asn1868Ile]§	S

CF, counting fingers; ERG, electroretinography; fs, frameshift; HM, hand motion; LE, left eye; M, mild effect; Mo, moderately severe effect; NA, not applicable; NP, not performed; RE, right eye; S, severe effect; N, normal amplitude (equal to or above the lower 5% of the range for a normal population); MR, moderately reduced amplitude (1%-5% of normal range); SR, severely reduced amplitude (<1% of normal range).

* Stop codon.

† ERG results at latest visit, unless stated otherwise.

Previously mentioned cases: (a) Ref. 16, (b) Ref. 33, (c) Ref. 34, (d) Refs. 13, 20, (e) Ref. 35, and (f) Ref. 15.

§ Based on in vitro splice assays.^{27,28}

|| Age at diagnosis.

¶ Amblyopic eye.

trans configuration could not be established by segregation analysis or homozygosity.

** Also *CNGB3* c.1148delC heterozygous.

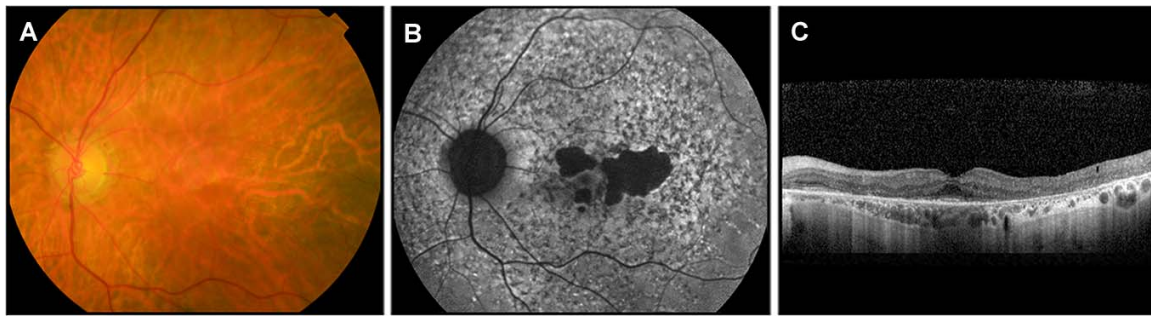

FIGURE 2. Retinal imaging of a patient with a very late onset of STGD1. (A) Fundus photography showed no signs of flecks in patient G-II:2 at the age of 72, 3 years after disease onset. (B, C) FAF performed in the same patient, at the same time, showed widespread hypo- and hyperautofluorescent lesions. FAF and OCT showed perifoveal chorioretinal atrophy with foveal sparing.

In 27/67 probands, we detected the single-variant allele p.As1868Ile; in 23 patients, we could establish the *trans* configuration of the identified variants (Figs. 1A, 1B; Supplementary Figs. S1, S2), either due to segregation analysis ($n = 21$) or because the p.As1868Ile variant was found in a homozygous state (Y-II:1 and AA-II:1). In the remaining four probands (K-II:1, N-II:1, R-II:1, and Z-II:1), segregation analysis could not be completed due to the absence of DNA of relatives (Table, footnote #; Supplementary Fig. S2). Additionally, in probands I-II:3, J-II:2, Y-II:1, and AA-II:1, we could not exclude the presence of intronic variants in *cis* with p.As1868Ile, as the noncoding regions of *ABCA4* in these individuals were not sequenced.

Among the 27 probands harboring the single-variant allele p.As1868Ile, 19 carried p.As1868Ile together with a protein-truncating mutation due to a stop ($n = 4$), a frameshift ($n = 4$), a canonical splice site variant ($n = 1$), or because of noncanonical splice site variants elsewhere shown to result in protein truncations ($n = 10$) (Table).^{27,28} The remaining eight probands harbored seven unique variants: six missense variants and one noncanonical splice site variant (c.5714+5G>A) that has a moderately severe effect on splicing.²⁸ Among these missense variants, p.Gly1961Glu in the vast majority of STGD1 cases acts as a mild variant,^{26,29,30} whereas p.Phe608Ile is considered a severe variant.³¹ For the remaining missense variants (p.Glu1087Lys, p.Cys1488Arg, p.Gly1972Arg, and p.Met2143Arg), the effect on protein function is unclear.

Segregation analysis in 10 siblings affected by STGD1 identified 7 individuals who harbored the same causal variants as the respective probands (Fig. 1A). In two families, we found affected siblings carrying different combinations of disease-causing *ABCA4* alleles (Supplementary Fig. S1).

Clinical Evaluation

Thirty-four STGD1 patients (27 probands and 7 siblings) that harbor p.As1868Ile in combination with a known causal variant were identified, 12 of whom were male and 22 were female. Detailed clinical characteristics of 32/34 subjects carrying p.As1868Ile are depicted in the Table. For two individuals, detailed clinical data were not available (A-II:2 and, besides age at onset, A-II:1; Figure 1A).

None of the subjects manifested early-onset STGD1 (age at onset, ≤ 10 years). Fourteen patients showed late-onset STGD1 (age at onset, >44 years), and 19 subjects manifested classical STGD1 (age at onset, 11–44 years). The mean age of onset was 42 years (SD, 16 years), with the majority of patients presenting with decreased visual acuity. Other initial symptoms included scotoma and metamorphopsia. Patients D-II:3, R-II:1, and U-II:1 did not experience visual symptoms at the time of

diagnosis at the age of 52, 30, and 37 years, respectively; all three manifested few flecks, largely confined to the macular region, and a perifoveal ring of RPE atrophy with a relatively spared fovea.

Classical STGD1, in the majority of patients (14/19), was characterized by early involvement of the macula featuring flecks, beaten bronze atrophy, and/or mottled decreased FAF, all largely confined to the macular and perimacular region. In the minority of patients (5/19), flecks throughout the posterior pole were observed, accompanied by pronounced atrophy in the posterior pole and midperiphery in 4/5 patients. The latter combination of fundus characteristics might represent a later disease stage, because available data of the first decade(s) after disease onset for the four patients manifesting atrophy (B-II:3, I-II:3, G-II:4, and T-II:1) were insufficient to assess fundus characteristics early in the disease. However, in 1/5 patients (C-II:1, with an age at onset of 41 years), flecks throughout the posterior pole and midperiphery with parafoveal atrophy were observed in the year after he first experienced symptoms, suggesting either slowly progressive disease that the patient himself had long been unaware of, or a different subphenotype. Foveal sparing in the classical STGD1 group was observed in 5/19 patients (age at onset, 27–41 years) (Table).

Late-onset STGD1, in the majority of clinically evaluated patients (8/13), was characterized by flecks throughout the posterior pole and midperiphery, often followed by sharply demarcated atrophy. Yet, three patients (E-II:3, J-II:2, and Y-II:1, with an age at onset of 56, 56, and 47, respectively) showed early exclusive involvement of the macula with perimacular flecks and macular beaten bronze atrophy and/or macular mottled decreased FAF, which are characteristics that were observed in the majority of the classical STGD1 patients. The remaining two patients showed both flecks throughout the posterior pole and midperiphery as well as mottled, decreased FAF in the macula at first presentation. RPE atrophy in a foveal sparing pattern was observed in 9/13 subjects, whereas 2/13 patients did not show macular atrophy yet.

In two late-onset STGD1 patients (G-II:1 and G-II:2), who were initially diagnosed with age-related macular degeneration (AMD) at the age of 72 and 69, respectively, flecks appeared absent, as assessed by ophthalmoscopy and fundus photography. Yet, they did exhibit widespread hypo- and hyperautofluorescent flecks on FAF (Fig. 2), highlighting the clinical value of FAF in the differentiation between AMD and late-onset STGD1.

Variable Age at Onset and Incomplete Penetrance

When comparing affected siblings who harbor p.As1868Ile (Fig. 1A), we observed fairly constant ages at onset in families A, C, and D, whereas in family B, the age at onset between

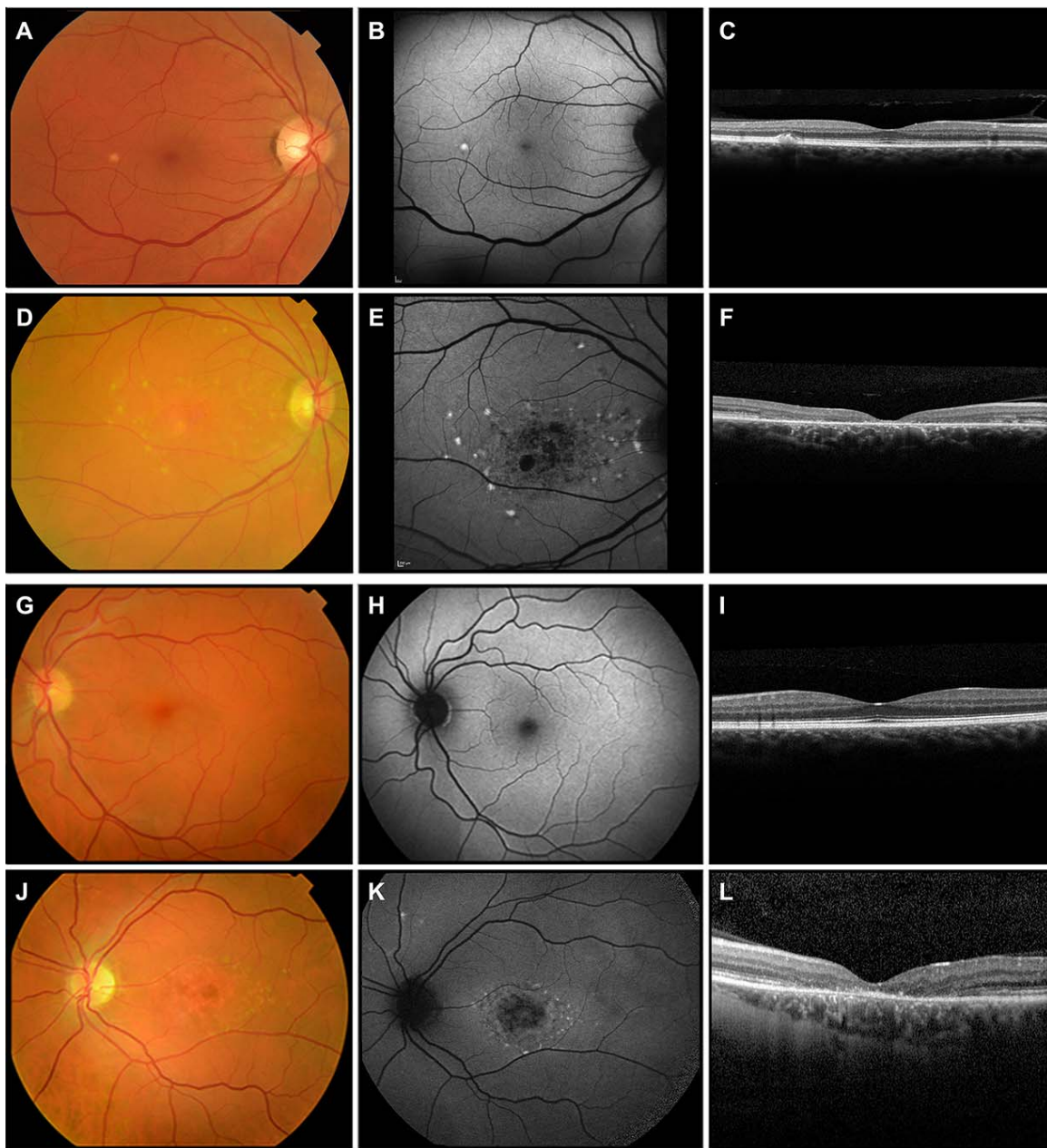


FIGURE 3. Retinal imaging of two sibling pairs in which an affected and an unaffected sibling harbor the same combination of *ABCA4* variants. (A–C) Asymptomatic sibling E-II:1 does not manifest STGD1 as assessed by fundus photography, FAF, and OCT at the age of 70 years. Fundus photography shows one small yellow-white, round lesion, which appears hyperautofluorescent on FAF and is visible as a single subretinal deposit on OCT. (D–F) Patient E-II:3 shows perimacular and peripapillary irregular yellow-white flecks on fundus photography at the age of 64. FAF reveals hyperautofluorescent lesions corresponding with the flecks and mottled decreased autofluorescence in the macula. OCT shows macular RPE atrophy. (G–I) Asymptomatic sibling F-II:1 shows no abnormalities on fundus photography, FAF, and OCT at the age of 47 years. (J–L) Patient F-II:2 shows foveal changes with perimacular and peripapillary irregular yellow-white flecks, mottled decreased FAF in the macula, and central RPE atrophy at the age of 41 years, 9 years after disease onset.

affected siblings varied tremendously (19 and 54 years of age). In addition to STGD1, B-II:3 suffered from Coats-like exudative vasculopathy, but this was first observed at the age of 57 and affected only the right eye.

Surprisingly, we found three asymptomatic male siblings (E-II:1, F-II:1, and H-II:1) in three STGD1 families that carried the same compound heterozygous variants as their probands (Fig. 1B). Also, unaffected person H-II:2 carried an *ABCA4* allele with a severe variant (c.[5461-10T>C; 5603A>T]) and c.5603A>T (p.Asn1868Ile) on the other allele. For asymptomatic siblings E-II:1 and H-II:1, in view of the large gap between

their current age and the age at onset of the proband, it is plausible that they remain unaffected and can be considered nonpenetrant. Moreover, current manifestation of STGD1 in E-II:1 was excluded during ophthalmologic examination: fundus photography, FAF, and OCT of E-II:1 showed no STGD1 phenotype at the age of 70, when his BCVA was 20/25 in the right eye and 20/20 in the left eye (Figs. 3A–C). His sibling E-II:3 reported initial symptoms at the age of 56 and was diagnosed with STGD1 at the age of 59 (Figs. 3D–F). Although the third asymptomatic sibling F-II:1 may develop STGD1 later in life considering his current age and the age of onset of the

A. Allele frequencies c.5603A>T

c.5603A>T	0.06573
c.[5641-10T>C; 5603A>T]*	0.00039
c.[2588G>C; 5603A>T]†	0.00081
Single-variant allele c.5603A>T (p)	0.06453

B. Sum allele frequency of severe ABCA4 variants

ABCA4 protein-truncating and canonical splice site variants	0.00188
ABCA4 severe non-canonical splice site variants‡	0.00083
Severe ABCA4 variants (q)	0.00271

C. Theoretical number of STGD1 cases with severe variant and c.5603A>T

Frequency of STGD1 cases with severe variant and c.5603A>T (2pq)	0.000349
Number of STGD1 cases in The Netherlands with severe variant and c.5603A>T	5,991

D. Observed number of STGD1 cases with severe variant and c.5603A>T

Total STGD1 prevalence	0.0001
Proportion STGD1 cases in Nijmegen carrying severe variant and c.5603A>T	0.0833
Prevalence STGD1 cases in The Netherlands with severe variant and c.5603A>T	0.00000833
Number of STGD1 cases in The Netherlands with severe variant and c.5603A>T	143

E. Penetrance of c.5603A>T in combination with a severe variant (observed/theoretical number of STGD1 cases)**0.0239**

FIGURE 4. Penetrance calculation for c.5603A>T when in *trans* with severe ABCA4 variants. *Assuming complete linkage disequilibrium between c.5603A>T and c.5641-10T>C based on this study and a previously published report.²⁶ †Based on the observation that in an AMD cohort, 10% of individuals with c.2588G>C also carry c.5603A>T.²⁶ ‡Based on in vitro splice assays of non-canonical splice site variants.²⁸

proband, he also underwent ophthalmologic examination, which excluded current manifestations of STGD1. His fundus photography, FAF, and OCT showed no abnormalities at the age of 47, and BCVA was 20/20 in both eyes (Figs. 3G–I). His sibling F-II:2 reported initial symptoms at the age of 32 and was diagnosed with STGD1 at the age of 38 (Figs. 3J–L). The asymptomatic cases in family H were not clinically examined, so current manifestations of mild STGD1 phenotypes could not be excluded.

Individuals harboring an ABCA4 variant that had been designated as severe did not show STGD1 phenotypes more often or more severe compared to individuals who harbored a variant with mild, moderately severe, or unknown effect (Table), with regard to age at onset or occurrence of foveal sparing.

p.As1868Ile Shows a Very Low Penetrance in the Caucasian Population

Based on previous findings²⁶ and the results of this study, we can conclude that p.As1868Ile represents a mild ABCA4 variant that in the majority of cases only results in STGD1 when present in *trans* with a severe ABCA4 variant.

First, the maximum AF of the single-variant allele p.As1868Ile among ~66,000 non-Finnish European control alleles, based on its total AF minus the AF of c.5461-10T>C and 10% of the AF of c.2588G>C, was 0.0645 (Fig. 4A).

Second, the total AF of severe ABCA4 variants (protein-truncating variants and noncanonical splice site variants determined to have a severe effect²⁸) was 0.00271 (Fig. 4B),

which yielded an estimated prevalence of individuals with one severe ABCA4 variant and p.As1868Ile of 0.000349 (Fig. 4C). Given a total population in the Netherlands of 17,150,000 persons, the theoretical number of STGD1 cases with a severe variant and p.As1868Ile thereby is 5991.

Third, the prevalence of STGD1 is estimated at 1 in 10,000 individuals,¹ and in the Nijmegen STGD1 cohort, STGD1 due to a severe ABCA4 variant and p.As1868Ile was observed in 25/300 (8.3%) probands (Fig. 4D). Given a total population in The Netherlands of 17,150,000 people, STGD1 due to this combination of variants was expected in ~143 persons. If the non-Finnish European AF are comparable to those in The Netherlands, we concluded that the penetrance of the single-variant allele p.As1868Ile, when present in combination with a severe ABCA4 variant, was 2.4% (Fig. 4E).

As these calculations were based on a few assumptions, we also calculated the penetrance based on alternative assumptions regarding the prevalence of STGD1 and the frequency of severe ABCA4 variants (Supplementary Results S2). When uncertainties in these factors of the calculation were taken into account and in the unlikely situation that the alternative assumptions would act in concert, the penetrance of p.As1868Ile ranged between 0.24% and 9.54%.

DISCUSSION

By combining ABCA4 sequence analysis and segregation analysis of the identified variants, we detected the common variant p.As1868Ile as the second allele in 40% of cases carrying monoallelic variants in our genetically unexplained

STGD1 cohort. In the majority of the cases, p.Asn1868Ile was found in *trans* with severe *ABCA4* variants, thus pointing toward the mild nature of this exonic variant in STGD1. In agreement with a previous study,²⁶ we found that a high proportion of these p.Asn1868Ile carriers manifest the late-onset STGD1 phenotype. However, among our cases, age at onset was highly variable. Strikingly, we identified one asymptomatic sibling and two unaffected siblings, all of whom carried the same combination of *ABCA4* variants as the respective probands. The very low calculated penetrance of p.Asn1868Ile of 2.4% in addition to the observed variability in age at onset and phenotypes among individuals carrying the same combinations of *ABCA4* variants, lead us to hypothesize that *cis*- or *trans*-acting genetic modifiers or environmental factors greatly influence *ABCA4* gene expression and, thereby, the clinical presentation of STGD1.

As yet, very little is known about the potential nature, role, and mechanisms of modifiers in STGD1. One group studied gene expression variation in the human retina and found that *ABCA4* showed 1.5-fold higher expression in males compared to females.³² Males carrying a high-expressed mild *ABCA4* allele, thereby, may be less prone to develop STGD1. In our study, we also observed an overrepresentation of females (22/34, 65%) among patients carrying p.Asn1868Ile (one-sample one-sided binomial test, $P = 0.0615$). Furthermore, all three putative nonpenetrant siblings are male. Further research is needed to identify possible modifiers, explain the mechanisms whereby they modify gene expression, and, most interestingly, explore their potential as therapeutic targets.

Clinical overlap with other macular diseases, along with inconclusive results of genetic analyses, can make the diagnosis of late-onset STGD1 particularly challenging, as illustrated by cases G-II:1 and G-II:2 who first experienced symptoms at the age of 72 and 69, respectively. FAF and genetic analysis in these cases were valuable in distinguishing late-onset STGD1 from AMD. The identification of the second disease-causing allele, whereby a significant fraction of late-onset STGD1 cases is now genetically explained, strengthens the assumption that late-onset STGD1 represents a distinct disease entity that should not be confused with AMD.²⁶ An accurate diagnosis is essential for appropriate counseling of patients regarding prognosis and heritability, and is relevant for putative therapies, for example either recommendation or dissuading of vitamin A supplement use in AMD and STGD1, respectively. Moreover, several therapeutic trials in STGD1 patients are ongoing (<http://www.clinicaltrials.gov>, last accessed 21-03-2018), requiring identification of both disease-causing *ABCA4* alleles.

The assessment of nonpenetrance has a few limitations. First, this study showed that age at onset, which constitutes a rather subjective measure, can vary tremendously even among siblings carrying the same *ABCA4* variants. Therefore, nonpenetrance cannot easily be confirmed by clinical examination of unaffected persons carrying bi-allelic disease-causing *ABCA4* variants. Regardless of whether the currently unaffected subjects develop STGD1 later in life, a highly variable disease expression was observed that raises new questions about the disease mechanisms.

Second, although we have experimentally proven the veracity of a nonpenetrance phenomenon, we are conscious of the fact that nonpenetrance estimates cannot be considered as definitive. Most importantly, late-onset STGD1 currently may be underdiagnosed or misdiagnosed due to the clinical overlap with AMD. In an AMD cohort ($n = 698$) from the Radboudumc, The Netherlands, we however did not observe persons with a combination of a severe *ABCA4* variant and p.Asn1868Ile, suggesting that misdiagnosis cannot be a major factor in centers of clinical expertise on STGD1. Moreover, because several nontruncating *ABCA4* variants might also behave like

severe variants, our estimate of the cumulative AF of severe variants in the population may in fact be higher, which would make the resultant penetrance estimate (2.4%) even lower.

CONCLUSIONS

Identification of genetic variants underlying STGD1 is essential to provide accurate counseling to patients and relatives and to drive therapeutic approaches. A significant proportion of STGD1 patients carries p.Asn1868Ile, which is associated with late-onset STGD1 and a variable disease expression. In line with these findings, we calculated an exceptionally low penetrance of the p.Asn1868Ile variant, which may be explained by the action of *cis*- or *trans*-acting genetic modifiers or nongenetic factors in STGD1.

Acknowledgments

The authors thank H.Y. Kroes for ascertaining STGD1 patients, M.J. Geerlens for her analysis of *ABCA4* variants in the AMD cohort, and J.N. Hermens for his expertise in electroretinography.

Supported by the FP7-PEOPLE-2012-ITN programme EyeTN, agreement 317472 (FPMC), the Macula Vision Research Foundation (FPMC), the Rotterdamse Stichting Blindenbelangen, the Stichting Blindenhulp, and the Stichting tot Verbetering van het Lot der Blinden (FPMC), and by the Landelijke Stichting voor Blinden en Slechtzienden, Macula Degeneratie fonds, and the Stichting Blinden-Penning that contributed through Uitzicht 2016-12 (FPMC). This work was also supported by the Foundation Fighting Blindness USA, grant no. PPA-0517-0717-RAD (FPMC, SR, and CBH) and Foundation Fighting Blindness UK, grant no. GR591 (FPMC and Silvia Albert).

Disclosure: **E.H. Runhart**, None; **R. Sangermano**, None; **S.S. Cornelis**, None; **J.B.G.M. Verheij**, None; **A.S. Plomp**, None; **C.J.F. Boon**, None; **D. Lugtenberg**, None; **S. Roosing**, None; **N.M. Bax**, None; **E.A.W. Blokland**, None; **M.H.M. Jacobs-Camps**, None; **S.D. van der Velde-Visser**, None; **J-W.R. Pott**, None; **K. Rohrschneider**, None; **A.A.H.J. Thiadens**, None; **C.W. Klaver**, None; **L.I. van den Born**, None; **C.B. Hoyng**, None; **F.P.M. Cremers**, None

References

- Blacharski P. *Retinal Dystrophies and Degenerations*. New York: Raven Press; 1988.
- Stargardt KI. Über Familiäre, Progressive Degeneration in der Maculagegend des Auges. *Graefes Arch Clin Exp Ophthalmol*. 1909;71:534-550.
- Franceschetti A. A special form of tapetoretinal degeneration: fundus flavimaculatus. *Trans Am Acad Ophthalmol Otolaryngol*. 1965;69:1048-1053.
- Allikmets R, Singh N, Sun H, et al. A photoreceptor cell-specific ATP-binding transporter gene (ABCR) is mutated in recessive Stargardt macular dystrophy. *Nat Genet*. 1997;15:236-246.
- Cremers FP, van de Pol DJ, van Driel M, et al. Autosomal recessive retinitis pigmentosa and cone-rod dystrophy caused by splice site mutations in the Stargardt's disease gene ABCR. *Hum Mol Genet*. 1998;7:355-362.
- Martinez-Mir A, Paloma E, Allikmets R, et al. Retinitis pigmentosa caused by a homozygous mutation in the Stargardt disease gene ABCR. *Nat Genet*. 1998;18:11-12.
- van Driel MA, Maugeri A, Klevering BJ, Hoyng CB, Cremers FP. ABCR unites what ophthalmologists divide(s). *Ophthalmic Genet*. 1998;19:117-122.
- Maugeri A, Flothmann K, Hemmrich N, et al. The *ABCA4* 2588G>C Stargardt mutation: single origin and increasing

- frequency from South-West to North-East Europe. *Eur J Hum Genet.* 2002;10:197-203.
9. Maugeri A, Klevering BJ, Rohrschneider K, et al. Mutations in the ABCA4 (ABCR) gene are the major cause of autosomal recessive cone-rod dystrophy. *Am J Hum Genet.* 2000;67:960-966.
 10. Maugeri A, van Driel MA, van de Pol DJ, et al. The 2588G->C mutation in the ABCR gene is a mild frequent founder mutation in the Western European population and allows the classification of ABCR mutations in patients with Stargardt disease. *Am J Hum Genet.* 1999;64:1024-1035.
 11. Fujinami K, Zernant J, Chana RK, et al. Clinical and molecular characteristics of childhood-onset Stargardt disease. *Ophthalmology.* 2015;122:326-334.
 12. Lambertus S, van Huet RA, Bax NM, et al. Early-onset Stargardt disease: phenotypic and genotypic characteristics. *Ophthalmology.* 2015;122:335-344.
 13. Klevering BJ, Maugeri A, Wagner A, et al. Three families displaying the combination of Stargardt's disease with cone-rod dystrophy or retinitis pigmentosa. *Ophthalmology.* 2004;111:546-553.
 14. Fujinami K, Sergouniotis PI, Davidson AE, et al. Clinical and molecular analysis of Stargardt disease with preserved foveal structure and function. *Am J Ophthalmol.* 2013;156:487-501.e1.
 15. van Huet RA, Bax NM, Westeneng-Van Haaften SC, et al. Foveal sparing in Stargardt disease. *Invest Ophthalmol Vis Sci.* 2014;55:7467-7478.
 16. Westeneng-van Haaften SC, Boon CJ, Cremers FP, Hoefsloot LH, den Hollander AI, Hoyng CB. Clinical and genetic characteristics of late-onset Stargardt's disease. *Ophthalmology.* 2012;119:1199-1210.
 17. Braun TA, Mullins RF, Wagner AH, et al. Non-exonic and synonymous variants in ABCA4 are an important cause of Stargardt disease. *Hum Mol Genet.* 2013;22:5136-5145.
 18. Zernant J, Xie YA, Ayuso C, et al. Analysis of the ABCA4 genomic locus in Stargardt disease. *Hum Mol Genet.* 2014;23:6797-6806.
 19. Bauwens M, De Zaeytjij J, Weisschuh N, et al. An augmented ABCA4 screen targeting noncoding regions reveals a deep intronic founder variant in Belgian Stargardt patients. *Hum Mutat.* 2015;36:39-42.
 20. Bax NM, Sangermano R, Roosing S, et al. Heterozygous deep-intronic variants and deletions in ABCA4 in persons with retinal dystrophies and one exonic ABCA4 variant. *Hum Mutat.* 2015;36:43-47.
 21. Yatsenko AN, Shroyer NF, Lewis RA, Lupski JR. An ABCA4 genomic deletion in patients with Stargardt disease. *Hum Mutat.* 2003;21:636-644.
 22. Zernant J, Schubert C, Im KM, et al. Analysis of the ABCA4 gene by next-generation sequencing. *Invest Ophthalmol Vis Sci.* 2011;52:8479-8487.
 23. Lee W, Xie Y, Zernant J, et al. Complex inheritance of ABCA4 disease: four mutations in a family with multiple macular phenotypes. *Hum Genet.* 2016;135:9-19.
 24. Lek M, Karczewski KJ, Minikel EV, et al. Analysis of protein-coding genetic variation in 60,706 humans. *Nature.* 2016;536:285-291.
 25. Schulz HL, Grassmann F, Kellner U, et al. Mutation spectrum of the ABCA4 gene in 335 Stargardt disease patients from a multicenter German cohort-impact of selected deep intronic variants and common SNPs. *Invest Ophthalmol Vis Sci.* 2017;58:394-403.
 26. Zernant J, Lee W, Collison FT, et al. Frequent hypomorphic alleles account for a significant fraction of ABCA4 disease and distinguish it from age-related macular degeneration. *J Med Genet.* 2017;54:404-412.
 27. Sangermano R, Bax NM, Bauwens M, et al. Photoreceptor progenitor mRNA analysis reveals exon skipping resulting from the ABCA4 c.5461-10T->C mutation in Stargardt disease. *Ophthalmology.* 2016;123:1375-1385.
 28. Sangermano R, Khan M, Cornelis SS, et al. ABCA4 midgenes reveal the full splice spectrum of all reported noncanonical splice site variants in Stargardt disease. *Genome Res.* 2018;28:100-110.
 29. Burke TR, Fishman GA, Zernant J, et al. Retinal phenotypes in patients homozygous for the G1961E mutation in the ABCA4 gene. *Invest Ophthalmol Vis Sci.* 2012;53:4458-4467.
 30. Cella W, Greenstein VC, Zernant-Rajang J, et al. G1961E mutant allele in the Stargardt disease gene ABCA4 causes bull's eye maculopathy. *Exp Eye Res.* 2009;89:16-24.
 31. Cornelis SS, Bax NM, Zernant J, et al. In silico functional meta-analysis of 5,962 ABCA4 variants in 3,928 retinal dystrophy cases. *Hum Mutat.* 2017;38:400-408.
 32. Chowers I, Liu D, Farkas RH, et al. Gene expression variation in the adult human retina. *Hum Mol Genet.* 2003;12:2881-2893.
 33. Lambertus S, Lindner M, Bax NM, et al. Progression of late-onset Stargardt disease. *Invest Ophthalmol Vis Sci.* 2016;57:5186-5191.
 34. Lambertus S, Bax NM, Groenewoud JM, et al. Asymmetric inter-eye progression in Stargardt disease. *Invest Ophthalmol Vis Sci.* 2016;57:6824-6830.
 35. Hoyng CB, Poppelaars F, van de Pol TJ, et al. Genetic fine mapping of the gene for recessive Stargardt disease. *Hum Genet.* 1996;98:500-504.