

Developments and challenges in dermatology: an update from the Interactive Derma Academy (IDeA) 2019

T. Luger^{1,*}  T. Dirschka,^{2,3} K. Eyerich,^{4,5} H. Gollnick,⁶  G. Gupta,⁷ J. Lambert,⁸ G. Micali,⁹ F. Ochsendorf,¹⁰ S. Ständer¹¹ C. Traidl-Hoffmann¹²

¹Department of Dermatology, University of Münster, Münster, Germany

²Centroderm Clinic, Wuppertal, Germany

³Faculty of Health, University Witten-Herdecke, Witten, Germany

⁴Department of Dermatology and Allergy, Technical University of Munich, Munich, Germany

⁵Unit of Dermatology, Department of Medicine, Karolinska Institutet and Karolinska University Hospital, Stockholm, Sweden

⁶Department of Dermatology and Venereology, Otto-von-Guericke University, Magdeburg, Germany

⁷University Department of Dermatology, Edinburgh, UK

⁸Department of Dermatology, Antwerp University Hospital, University of Antwerp, Antwerp, Belgium

⁹Dermatology Clinic, University of Catania, Catania, Italy

¹⁰Department of Dermatology, Frankfurt University Hospital, Frankfurt/Main, Germany

¹¹Center for Chronic Pruritus, Department of Dermatology, University Hospital Münster, Münster, Germany

¹²Chair and Institute of Environmental Medicine, UNIKA-T, Technical University of Munich and Helmholtz Zentrum München, Augsburg, Germany

*Correspondence: T. Luger. E-mail: luger@uni-muenster.de

Abstract The 2019 Interactive Derma Academy (IDeA) meeting was held in Lisbon, Portugal, 10–12 May, bringing together leading dermatology experts from across Europe, the Middle East and Asia. Over three days, the latest developments and challenges in relation to the pathophysiology, diagnosis, evaluation and management of dermatological conditions were presented, with a particular focus on acne, atopic dermatitis (AD) and actinic keratosis (AK). Interesting clinical case studies relating to these key topics were discussed with attendees to establish current evidence-based best practices. Presentations reviewed current treatments, potential therapeutic approaches and key considerations in the management of acne, AK and AD, and discussed the importance of the microbiome in these conditions, as well as the provision of patient education/support. It was highlighted that active treatment is not always required for AK, depending on patient preferences and clinical circumstances. In addition to presentations, two interactive workshops on the diagnosis and treatment of sexually transmitted infections/diseases (STIs/STDs) presenting to the dermatology clinic, and current and future dermocosmetics were conducted. The potential for misdiagnosis of STIs/STDs was discussed, with dermoscopy and/or reflectance confocal microscopy suggested as useful diagnostic techniques. In addition, botulinum toxin was introduced as a potential dermocosmetic, and the possibility of microbiome alteration in the treatment of dermatological conditions emphasized. Furthermore, several challenges in dermatology, including the use of lasers, the complexity of atopic dermatitis, wound care, use of biosimilars and application of non-invasive techniques in skin cancer diagnosis were reviewed. In this supplement, we provide an overview of the presentations and discussions from the fourth successful IDeA meeting, summarizing the key insights shared by dermatologists from across the globe.

Received: 28 September 2020; Accepted: 9 October 2020

Conflict of interest:

Dr. Luger reports grants and personal fees from Meda Pharma S.p.A. (a *Viatrix company*), during the conduct of the study. Dr. Dirschka reports grants and personal fees from Ammirall, Biofrontera, Galderma and Meda Pharma S.p.A. (a *Viatrix company*), grants from Schulze & Böhm GmbH, and personal fees from GSK, LEO, Neracare, Novartis, Janssen-Cilag, Riemsler, Dr Pflieger and Scibase, outside the submitted work. Dr. Eyerich reports grants and personal fees from Abbvie, Janssen, LEO, Lilly and Novartis, personal fees from Ammirall, BMS, Boehringer Ingelheim, Sanofi and UCB, and grants from Galapagos, outside the submitted work. Dr. Gollnick reports personal fees from and other activities with Galderma, Intendis, Meda Pharma S.p.A. (a *Viatrix company*) and S-Biomedic, and other activities with Merz and Vichy, outside the submitted work. Dr. Gupta reports personal fees and non-financial support from Meda Pharma S.p.A. (a *Viatrix company*), during the conduct of the study; personal fees and

non-financial support from Ammirall, and non-financial support from Abbvie, LEO Pharma, Novartis and Galderma, outside the submitted work. Dr. Lambert reports personal fees from Galderma, La Roche Posay, Pierre Fabre and Meda Pharma S.p.A. (a *Viatrix* company), outside the submitted work. Dr. Micali reports personal fees from Meda Pharma S.p.A. (a *Viatrix* company) and Galderma, outside the submitted work. Dr. Ochsendorf has nothing to disclose. Dr. Ständer reports personal fees from Ammirall, Bayer, Beiersdorf, Bionorica, Cara Therapeutics, Claxio Biosciences, Dermasence, Galderma, Kiniksa, Meda Pharma S.p.A. (a *Viatrix* company), Menlo Therapeutics, Novartis, Perrigo, Pfizer, Sanofi, Trevi Therapeutics, Vanda Pharmaceuticals and Vifor, outside the submitted work. Dr. Traidl-Hoffmann reports personal fees from Meda Pharma S.p.A. (a *Viatrix* company), Galderma, Novartis, Lilly, Celgene and La Roche Posay, and grants from Sebapharma and Töpfer, outside the submitted work.

Funding source

The writing/editorial support was funded by Meda Pharma S.p.A., a *Viatrix* company. All authors were speakers at the IDeA 2019 meeting, funded by *Viatrix*.

Introduction

The fourth Interactive Derma Academy (IDeA) meeting was held in Lisbon, Portugal, 10–12 May 2019, with dermatologists from Europe, the Middle East and Asia in attendance. Over three days, presentations on important issues relating to the diagnosis and treatment of acne, atopic dermatitis (AD) and actinic keratosis (AK), and additional presentations summarizing current challenges in dermatology, were delivered. Interesting clinical cases relating to these topics were also discussed to demonstrate current evidence-based best practices and treatment options. In addition, two interactive workshops were conducted on the diagnosis of sexually transmitted infections/diseases (STIs/STDs) presenting to the dermatology clinic, and the possibilities of current and future dermocosmetics. Here, we provide an overview of the presentations and discussions from the successful IDeA 2019 meeting.

Acne

Low adherence to treatment regimens: Falk Ochsendorf

Low adherence to acne treatments is associated with poor outcomes.¹ Adherence is determined by: quality of physician-patient relationship, patient understanding of treatment and pathology, and ease of treatment.^{2–6} Evidence suggests that interventions focusing only on single aspects of disease management, such as information sharing with the patient, motivation of the patient or provision of extra patient support, are not associated with large improvements in adherence.⁷

Physicians should be aware of non-adherence and how this can be improved and/or prevented, including selecting effective, tolerable compounds as part of a simple treatment regimen,⁸ selecting the patient's preferred topical vehicle and developing good physician–patient relationships with scheduled return visits. For example, improved treatment adherence was observed with once-daily combined clindamycin phosphate 1.2%-tretinoin 0.025% gel compared with separate daily applications of clindamycin phosphate gel 1% and tretinoin cream 0.025%

(88% vs. 61%).⁸ Further, patient adherence can be improved by asking three questions at first contact: 'How should therapy be applied?', 'How often should therapy be applied?' and 'What should be done in case of problems?'^{9,10}

Antibiotic resistance: Julien Lambert

Antibiotics (ABs) targeting *Cutibacterium acnes* (*C. acnes*; formerly *Propionibacterium acnes*) are impacted by microbial resistance, necessitating a change in attitude towards their use in acne.^{11,12} Physicians should balance the needs of individual patients with public health concerns as the consequences of AB resistance extend beyond acne treatment, impacting other skin bacteria and the entire human microbiota.^{12,13} AB resistance also affects clinical response in acne, leading to a reduction in and/or absence of response, and/or relapse,^{12,13} as observed in the decreased efficacy of topical erythromycin over time.¹⁴ Limiting the use of ABs in acne therapy has therefore been suggested,^{12,15} particularly as *C. acnes* is only one of four pathogenic factors (excess sebum production, abnormal desquamation, *C. acnes* colonization and inflammation)^{15,16}; thus, its elimination does not cure the condition. With this in mind, guidelines have provided recommendations for the use of ABs in acne management.^{17–19}

Guidelines recommend that topical ABs are not used as monotherapy, with combination treatment (topical retinoids and antimicrobials) endorsed to address three of the four major pathogenic factors in acne.^{18–21} Retinoids normalize desquamation and facilitate entry of the AB into the pilosebaceous duct, while antimicrobials target *C. acnes* and reduce inflammation.^{20–22} The combination of clindamycin/tretinoin significantly reduced the presence of *C. acnes* after 6 weeks of treatment compared with clindamycin alone, including in patients with highly resistant *C. acnes*.²⁰ Furthermore, unlike clindamycin monotherapy,²³ clindamycin/tretinoin treatment has not been associated with an increase in clindamycin-resistant *C. acnes*.²⁴

Other recommendations include avoiding using topical ABs as maintenance therapy,¹⁹ and restricting use of oral ABs in acne.¹²

While useful in the treatment of severe acne, oral ABs are not recommended as monotherapy,¹⁹ or for concurrent treatment with topical ABs.¹² Rather, oral ABs should be combined with topical retinoids and/or benzoyl peroxide (BPO) for involved areas.¹² Additionally, use of oral ABs should be limited to 3–4 months due to the risk of antimicrobial resistance at other body sites.¹²

Evaluation of treatment efficacy: Giuseppe Micali

At present, there is a lack of standardized methods for evaluating treatment efficacy in acne, with at least 25 grading systems developed to date.^{25–28} Current clinical evaluations include lesion counts,²⁹ global severity grading and comprehensive acne severity system (CASS) assessment,³⁰ which have limitations. For example, lesion counts are restricted by subjective evaluation,³¹ and global severity grading cannot estimate the effect of treatment on individual lesions.³² Further, global severity grading is influenced by the presence of a single lesion of the highest grade.³³ In addition, CASS assessment is thought to be imprecise and requires investigator global assessment training to improve reliability. In contrast, use of digital systems in instrumental evaluations may allow more objective evaluation of acne lesions, and movement towards standardized therapeutic monitoring. Instrumental evaluations may include advanced digital photography and, to a limited extent, dermatoscopy and reflectance confocal microscopy.^{25,34,35}

The role of the microbiome in acne: Harald Gollnick

Commensal microbiota inside the body and on the surface of the skin are typically balanced and in a healthy state;³⁶ however, cutaneous dysbiosis can induce immune activation, leading to inflammation.^{37,38} It can also allow non-commensal bacteria to colonize the skin and cause infection.³⁹

C. acnes is considered the ‘gatekeeper’ of the facial microbiome, colonizing the lower part of the follicular canal and inter-follicular epidermis.^{40–42} *C. acnes* strains comprise up to 90% of the facial microbiota;⁴³ however, certain strains or excessive numbers are associated with acne.^{44,45}

Modulation of the microbiome therefore represents a novel treatment strategy for acne.^{46,47} In particular, altering the composition of *C. acnes* strains on the skin, through topical application of strains that are capable of inhibiting pathogenic strains, could reduce inflammation. This is supported by a pilot study in which topical application of selected *C. acnes* strains over 5 weeks reduced non-inflamed lesions and improved comedone counts without causing irritation, flare-up or deterioration in inflammatory lesions.⁴⁷ Microbiome modulation also significantly reduced non-inflamed lesion counts in patients with acne after 42 days, despite a relative increase in *C. acnes* bacteria.⁴⁷ This confirms that downregulation of pathogenic *C. acnes* strains is possible through increasing the number of beneficial strains of *C. acnes*; however, it is not clear if continuous or intermittent treatment is necessary.

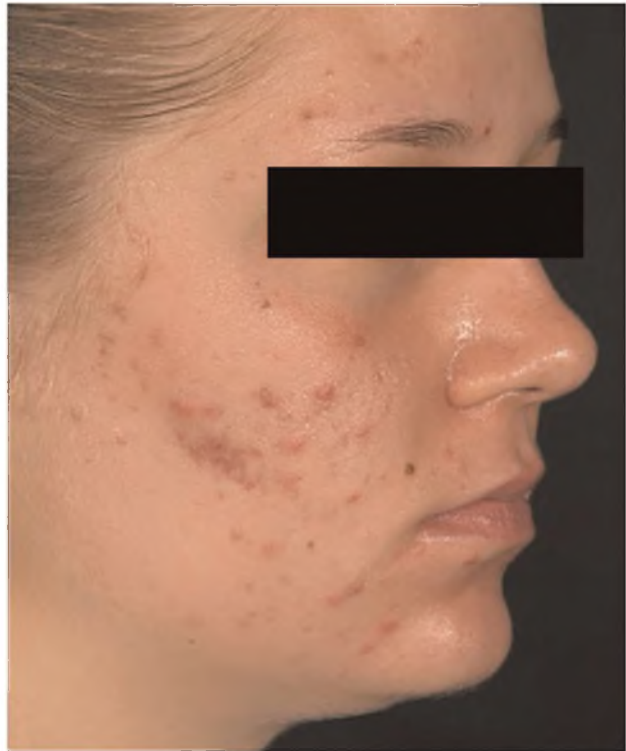

Figure 1 Clinical presentation of mild-to-moderate papulopustular acne in a 19-year-old patient.

Clinical cases

Harald Gollnick discussed several cases, covering aspects of diagnosis, treatment, psychological impact and therapeutic challenges associated with acne and acne-mimicking conditions. Furthermore, differential diagnoses were presented, such as syringomas, eruptive vellus hair cysts, facial sebocystomatosis and rosacea (including demodicosis and trombidiosis).

Falk Ochsendorf contributed a clinical case on the diagnosis and treatment of a 19-year-old female presenting with acne. This patient had suffered from acne since age 12, receiving no previous treatment aside from cosmeceuticals. The patient was diagnosed with mild-to-moderate papulopustular acne (with approximately 10–20 inflammatory lesions on the cheek; Fig. 1) and prescribed topical treatment. Treatment with a fixed-dose combination of topical BPO/retinoid (e.g. BPO/adapalene), BPO/clindamycin or retinoid/clindamycin (e.g. tretinoin/clindamycin) could be administered in-line with the latest guidance for the treatment of mild-to-moderate papulopustular acne.¹⁹

Giuseppe Micali discussed the diagnosis and treatment of a 16-year-old male presenting with an abrupt onset of intense itchy erythema of facial skin (Fig. 2a). This patient had a medical history of mild comedonal acne (previous 1 year) treated

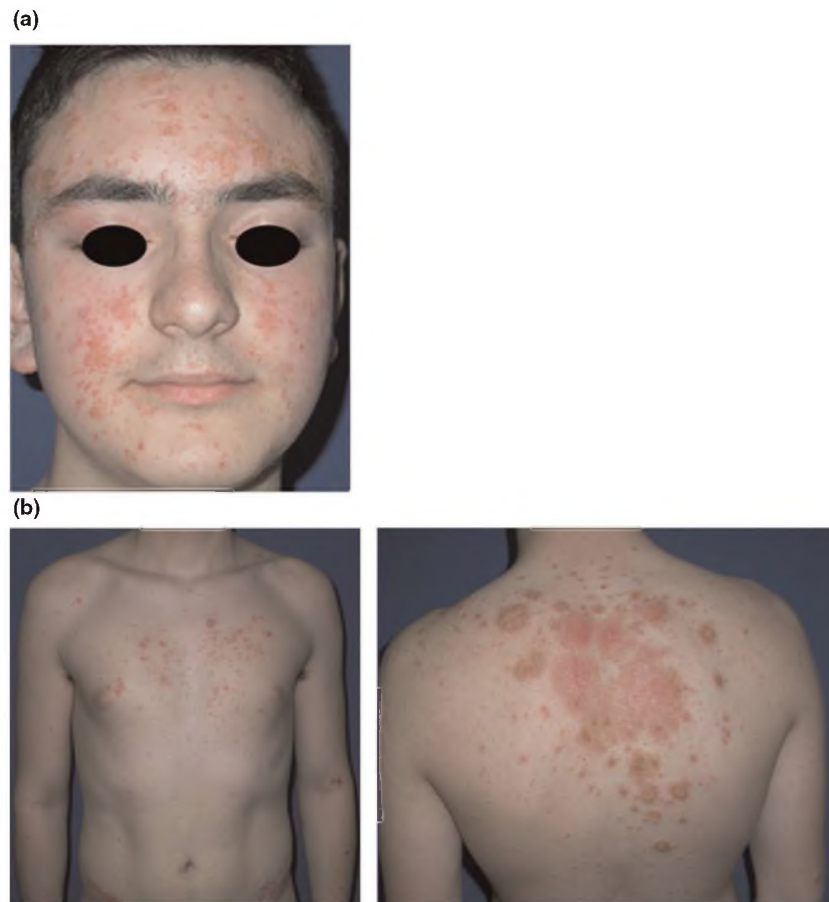

Figure 2 Clinical presentation of acne and AD flare on the face (a) and body (b) of a 16-year-old patient.

with topical retinoids. In addition to an erythematous rash, comedones and papules were present on his face, as well as large eczematous lesions with oozing and crusting on his chest, upper back and shoulders (Fig. 2b). While side-effects from topical retinoid treatment were considered, diagnosis was established as acne and AD flare. AD and acne can coexist and flares of AD may occur in patients with acne.⁴⁸ The AD flare was treated with systemic antibiotics and a topical calcineurin inhibitor (TCI). Once improvement was achieved, topical combination therapy was initiated to treat acne.¹⁹

Atopic dermatitis

Is AD a single disease? Kilian Eyerich

Diagnosis of AD remains based on subjective criteria, including those proposed by Hanifin and Rajka (1980), the UK Working Party (1994) and the American Academy of Dermatology (2014).⁴⁹⁻⁵⁴ Eczema and dermatitis are further classified into sub-categories/variants, such as nummular eczema, dyshidrotic

eczema and chronic contact dermatitis. Recently, there has been movement towards 'endstream oriented therapy', in which eczema is classified as a type 2 immune driven disease.⁵⁵

T-helper type 2 (Th2) immunity is stimulated by specific antigens. Parasites, environmental antigens and humoral immunity can trigger the Th2-mediated pro-inflammatory response, initiating release of serum cytokines (interleukin [IL]-4, IL-5 and IL-13).⁵⁶⁻⁵⁸ Approaches to stratifying AD use serum cytokine levels,⁵⁹ genetic markers,⁶⁰ microbiome analyses⁶¹ and patient ethnicity.^{62,63} Although AD is highly heterogeneous (Fig. 3)⁶⁴, four main endotypes exist: genetic immunology type, non-genetic immunology type, genetic barrier type and non-genetic barrier type, which all result in exaggerated Th2 immunity.⁶⁵

Skin microbiome in health and disease: Claudia Traidl-Hoffmann

There is increasing awareness of a role of the microbiome in skin diseases.^{66,67} The interplay between chemical, physical and immunological factors and microbial barrier function is

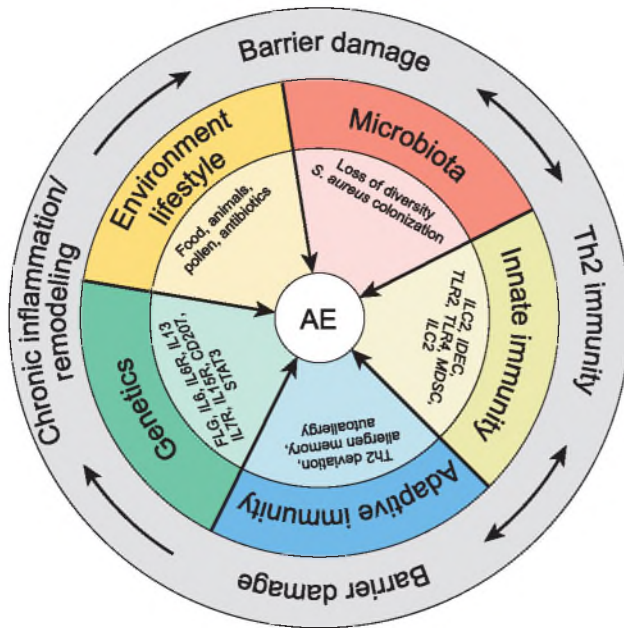


Figure 3 The complex pathophysiology of AD, involving genetic traits, environmental influences and changes in immunity that result in epidermal barrier damage and Th2-driven immune response.⁶⁴ Reprinted from Trends in Immunology, 36(12), Eyerich K, Eyerich S, Biedermann T, The multi-modal immune pathogenesis of atopic eczema, pp 788-801. Copyright 2015 with permission from Elsevier.

complex,⁶⁸ but can potentially be explained by the biodiversity hypothesis. This hypothesis proposes that contact with natural and traditional environments enriches the human microbiome,⁶⁹ whereas urbanization and global warming,⁶⁹ contact with household animals⁷⁰ and consumption of fast food⁷¹ reduce biodiversity. A diverse diet and breastfeeding during infancy may also increase microbiome diversity.^{72,73} However, research is needed to establish the direction of causal relationships between the microbiome and skin disease, i.e. is the microbiome affected by skin disease, or does the microbiome affect skin disease?^{74,75}

In AD, the expression of genes involved in skin barrier function (claudin [CLDN]1, CLDN4, filaggrin [FLG] and tight junction protein [TJP]1) is reduced, with a negative correlation between *Staphylococcus aureus* (*S. aureus*) frequency and expression of CLDN4/5 and TJP1/2.⁷⁶ Additionally, skin pH is higher in patients with AD compared with healthy individuals, which favours growth of *S. aureus* and may impact microbiome diversity.^{77,78} In addition, skin pH-dependent *S. aureus* abundance can serve as a predictor for increasing AD severity. Thus, the microbiome can also serve as a diagnostic and predictive tool.^{74,79} Novel therapies promoting microbiome diversity are in development, including

dual spleen tyrosine kinase (Syk)/Janus kinase (Jak) inhibitor ASN002, which reduces *S. aureus* frequency and Eczema Area and Severity Index (EASI) score.^{80,81}

Itch: pathophysiology and treatment: Sonja Ständer

Pruritus (itch) is a hallmark of AD that severely impacts quality of life;⁸² it is usually associated with flare-ups,⁸³ but may remain after relief from eczema. Pruritus is mediated by multiple cutaneous C Fibre classes, which may be histamine-sensitive or non-histaminergic.⁸⁴

Long-standing pruritus can lead to cutaneous structural and functional neuroanatomical changes.^{85,86} This was recently shown using a model of selective non-histaminergic C Fibre activation, in which neuronal sensitization and more intense pruritus were experienced by patients with AD versus healthy controls.⁸⁷ Patients with AD are also hypersensitive to mechanical stimuli, clinically known as alloknesis or worsening of itch by scratching.⁸⁸ Interestingly, most patients with AD show regular response to pain stimuli.⁸⁷

A recent paper summarized therapeutic recommendations of 14 AD guidelines from Europe, North America, the Asia-Pacific region, and Africa.⁸⁹ While most guidelines recommend first-generation (sedating) antihistamines as anti-pruritic therapies for sleep disturbances (exceptions: German, European and Japanese guidelines), there is limited evidence that second-generation (non-sedating) antihistamines improve pruritus in AD. A recent Cochrane systematic review of 25 studies (representing 3285 patients) found no evidence that H1 antihistamines were more effective than placebo as an 'add-on' therapy for eczema, with the exception of fexofenadine, which appeared to lead to a small improvement in patient-assessed pruritus.⁹⁰ European AD guidelines discuss, but do not recommend routine treatment of itch with opioid receptor antagonists (naltrexone or nalmeferne), or a selective serotonin receptor inhibitor (paroxetine).^{89,91}

Based on expert opinion, therapies such as aprepitant, naltrexone (oral), naloxone (i.v.), selective serotonin reuptake inhibitors (e.g. paroxetine, fluvoxamine), gabapentin, pregabalin, cyclosporine and methotrexate, are effective in relieving pruritus associated with AD, and some are recommended in treatment guidelines.^{92,93} In addition, topical transient receptor potential cation channel subfamily M member 8 (TRPM8) agonists have been considered for the treatment of pruritic skin. In a randomized, double-blind, pilot study, a cooling compound containing two TRPM8 agonists ameliorated severe pruritus and improved quality of life in patients with dry, pruritic skin compared with vehicle.⁹⁴

Importantly, treatment for pruritus should be started early, as prevention of neuroanatomical changes and neuronal sensitization is essential. It is also necessary to treat pruritus for a sufficient duration (several weeks) to impact the central nervous system.

Sensitive skin – pathomechanism and management:

Thomas Luger

Sensitive skin is a disturbing skin condition occurring primarily on the face. Current treatments ameliorate dysfunction of epidermal barriers (e.g. driven by microbial or physical factors, innate immunity, adaptive immunity and cutaneous nerves). These treatments include emollients (the mainstay treatment) and topical anti-inflammatory therapies, such as TCI and topical corticosteroids (TCS).⁹¹ However, TCS are not recommended for the treatment of sensitive skin areas or long-term management,⁹¹ and their use is associated with limitations, including skin barrier impairment, skin atrophy, increased risk of skin infections, tachyphylaxis and corticophobia.⁹⁵⁻⁹⁸ Furthermore, use of TCS on sensitive skin areas is a concern among patients.⁹⁹ European AD guidelines therefore recommend TCI, particularly pimecrolimus, for the treatment of sensitive skin areas, such as the eyelid, perioral skin and genital area.⁹¹

TCI are fast and effective anti-pruritic agents, as demonstrated in adults and children.⁹³ Tacrolimus and pimecrolimus have dual mechanisms of action, targeting both nuclear factor of activated T cells^{100,101} and the transient receptor potential cation channel subfamily V member 1,¹⁰² to reduce inflammation and relieve itch.⁹¹ Importantly, there is no evidence of impairment of epidermal barrier function or skin atrophy with TCI, nor a causal link between TCI and lymphomas/skin tumour occurrence.^{98,103-106} The absence of skin atrophy with TCI favours their use over TCS for topical long-term management of AD.⁹¹

Long-term treatment with pimecrolimus was considered both effective and safe in a trial involving 2418 infants with mild-to-moderate AD, with >85% of patients cleared/almost cleared of AD overall and >95% of patients cleared/almost cleared of facial AD after 5 years of treatment.¹⁰³ Furthermore, pimecrolimus had a substantial steroid-sparing effect, with no evidence of impairing the developing immune system.¹⁰³ It is therefore recommended in children and for the treatment of facial lesions.⁹¹ Pimecrolimus has demonstrated benefits over both TCS and tacrolimus. Firstly, pimecrolimus is an alternative to TCS for the treatment of sensitive skin areas,¹⁰⁷ and has been shown to reduce TCS-induced skin atrophy compared with vehicle after six weeks in a double-blind study.¹⁰⁸ In children, compared with tacrolimus 0.03% ointment, pimecrolimus 1% cream led to a greater reduction from baseline in body surface area affected by AD in the head/neck region after 43 days of treatment (pimecrolimus: 53.7%; tacrolimus: 34.9%).¹⁰⁹ Pimecrolimus 1% cream was reported to cause fewer application-site reactions than tacrolimus 0.03% ointment after 4 days, including itching and erythema/irritation, although the incidence of warmth, stinging and burning sensation was similar in both groups.¹⁰⁹ Additionally, pimecrolimus has the potential to increase adherence to treatment as it is non-greasy, thus preferred over tacrolimus.¹⁰⁹

Hot topic: Education of patients with AD and parents – an updated review of successful programmes: Matthias Augustin

Holistic programmes that aim to maintain the skin barrier and a high level of treatment compliance in AD are needed. The World Health Organization advocates patient-centred care, with joint decision-making between physicians and patients.¹¹⁰ The rationale for educational interventions for AD encompasses the complexity of AD treatment,¹¹¹ high volume of information for patients¹¹² and association between low adherence and poor outcomes.^{113,114} The main elements that should be covered by educational programmes were highlighted, including medical, nutritional and psychological issues,¹¹⁵ as well as the importance of patient motivation.¹¹⁶

In a systematic review, it was unclear whether educational interventions improve health-related quality of life in people with chronic inflammatory skin conditions.¹¹⁷ However, tentative conclusions suggested face-to-face group sessions and text messages may be effective, and that delivery of educational programmes by a multidisciplinary team over six weeks to three months may be associated with positive outcomes.¹¹⁷ Although guidelines, expert consensus papers and patient groups propose standardized interventions for patients with chronic AD, in most countries, few patients receive a structured educational programme due to a lack of financial support/resources.

It was agreed that patients should be well informed about their disease and treatment, and most attendees thought that there was an excellent level of evidence to support the benefits of educational programmes in AD. An interactive survey showed that attendees had a range of experience with educational programmes in AD (Fig. 4a). In this survey, 94% of responses indicated that education was provided for at least some of their patients with AD, with 34% stating that education is provided on a regular basis for all patients (Fig. 4b). Most attendees (68% of responses) stated that a high proportion (>50%) of their patients with AD received therapeutic education, with 42% indicating that >80% of patients received this education (Fig. 4c). Attendees suggested that, if it was offered free of charge, there would be moderate uptake by their patients of an evidence-based educational AD programme (Fig. 4d). Most attendees (75% of responses) indicated they had not used digital technology for educating patients with AD (Fig. 4e), with 19% stating use with some patients and only 5% stating use with all patients.

Hot topic: Education of patients with AD and parents – update on new AD treatments: Thomas Luger

Atopic dermatitis treatments may target phenotypes or genotypes of AD and a personalized approach is required. An overview of treatment milestones was provided (Fig. 5), with key clinical data on novel therapies presented.

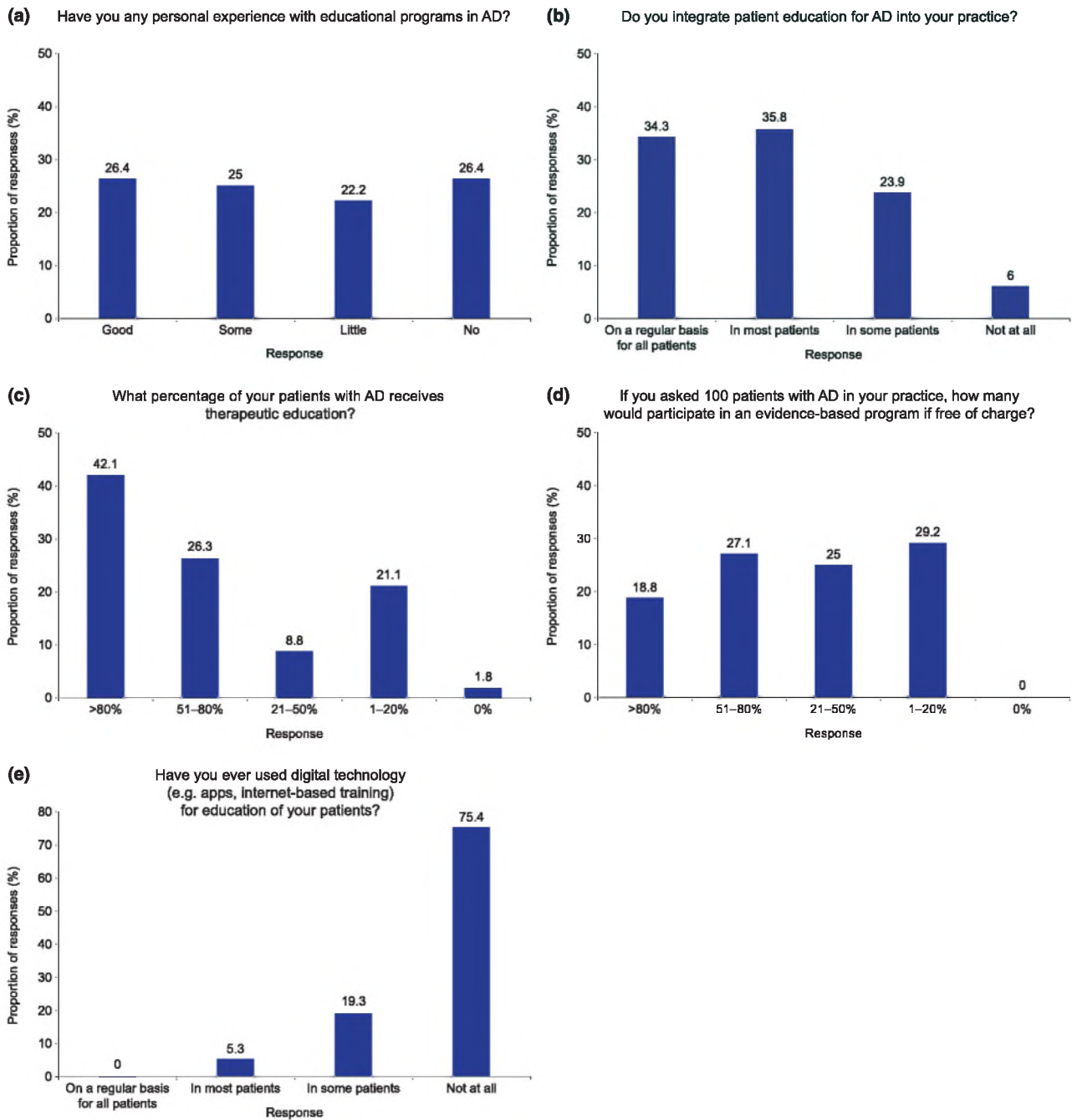


Figure 4 Assessment of experience with educational programmes in AD via interactive survey (a–e) of attendees.

In CHRONOS (a phase 3 study in adults), the monoclonal antibody (mAb) dupilumab, which targets IL-4 and IL-13, was reported to be effective in moderate-to-severe AD, with significantly more patients who received dupilumab plus TCS achieving the co-primary endpoints (Investigator's Global Assessment [IGA] score of 0/1 and EASI 75% improvement [EASI-75] from

baseline) after 16 weeks than patients who received placebo plus TCS.¹¹⁸ In a phase 2 dose-finding study of tralokinumab, another mAb, higher doses (150 and 300 mg) demonstrated meaningful improvements compared with placebo across clinical and patient-reported outcomes for eczema and pruritus.¹¹⁹ Similarly, the first-in-class anti-IL-17C mAb MOR106 demonstrated

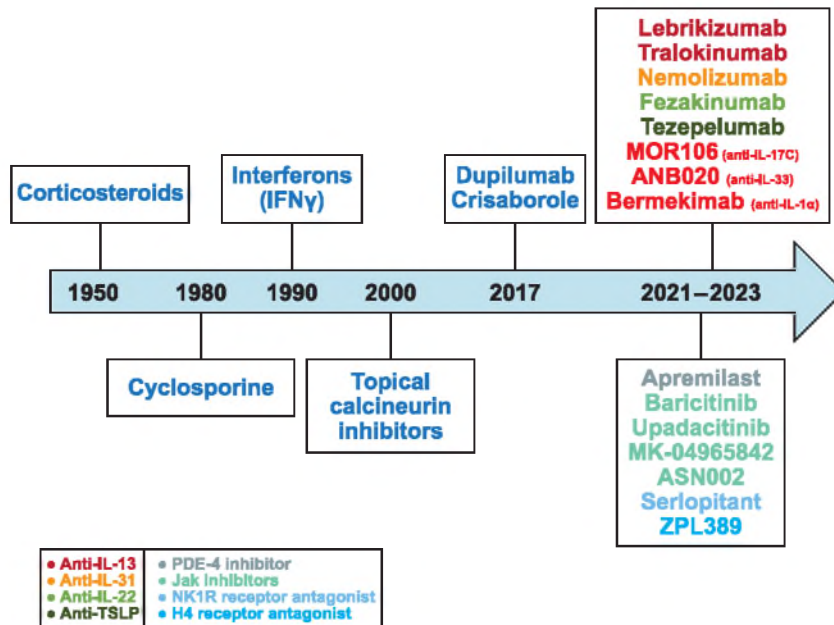


Figure 5 Overview of AD treatment milestones to date. H4, histamine H4; IFN γ , interferon-gamma; IL, interleukin; Jak, Janus kinase; PDE-4, phosphodiesterase-4; NK1R, neurokinin 1 receptor; TSLP, Thymic stromal lymphopoietin.

promising improvements in AD skin efficacy parameters (EASI-50 and Scoring Atopic Dermatitis) vs. placebo in a phase 1 dose-finding study.¹²⁰ Further, in a phase 1 safety and tolerability study of bermekimab (anti-IL-1 α mAb) in moderate-to-severe AD, reductions in itch and pain were reported with higher doses of bermekimab (400 mg vs. 200 mg).¹²¹

In addition to mAbs, Jak inhibitors, neuropeptides, phosphodiesterase-4 inhibitors (PDE-4i) and aryl hydrocarbon receptor (AhR) agonists are in development for use in AD. Jak inhibitors block multiple AD pathways, but baricitinib has been associated with numerous side-effects, such as headache, increased blood creatinine and creatine phosphokinase levels, and nasopharyngitis.¹²² A randomized, double-blind phase 2 trial of baricitinib (a Jak-1 and Jak-2 inhibitor) reported improvements in eczema and itch vs. placebo in moderate-to-severe AD.¹²² Additionally, in a dose-finding study, twice-daily application of a topical Jak inhibitor, ruxolitinib 1.5% cream, was shown to be well tolerated and to provide greater relief from itch compared with vehicle within 36 hours of initiation of treatment.¹²³ Neurokinin 1 receptor agonists are currently undergoing clinical investigation, with a phase 2 trial in chronic pruritus reporting serlopitant to be significantly more efficacious than placebo in reducing pruritus when administered at 1 mg and 5 mg once-daily.¹²⁴ Crisaborole, the first commercially available PDE-4i,¹²⁵ has been reported to be effective in mild-to-moderate AD, significantly and rapidly improving eczema and pruritus compared with vehicle in two double-blind phase 3 studies involving more than

1500 patients aged ≥ 2 years.¹²⁶ In a phase 2 dose-finding study, Tapinarof 1% cream (AhR modulating agent) demonstrated efficacy in AD, in terms of patients achieving EASI-75, compared with vehicle.¹²⁷ Transplantation of the topical microbiome; for example, of antimicrobial coagulase-negative staphylococci reduced *S. aureus*, is also a potential novel therapeutic strategy for AD.¹²⁸

Actinic keratosis

Review of recent publications on AK – discussion of clinical importance: Thomas Dirschka

A new scoring system, the actinic keratosis area and severity index (AKASI), has been proposed for assessing the severity of AK on the head.¹²⁹ AKASI is an objective measure for AK severity and the risk of squamous cell carcinoma (SCC).¹³⁰ AK lesions show varying patterns in basal growth, including crowding, budding and papillary sprouting of cells in the basement of the epidermis.¹³¹ Basal proliferation in AK is linked to SCC.¹³²

Field-directed treatments are essential for AK and should be applied not only to visible lesions, but also the surrounding sun-exposed area.^{133,134} At present, therapy-resistant AK lesions remain enigmatic and require further research. Efforts must be taken to investigate the epidermal/dermal/inflammatory cross talk, and discussions regarding the benefits of sunscreen will continue.

Hard to treat AK – discussion of location and lesion characteristics: Girish Gupta

In some cases, active treatment of AK is not required; instead, primary care monitoring of sun-exposed areas, coupled with prevention and self-care advice may be all that is needed. Ultimately, the most appropriate management strategy should be determined by patient preferences and clinical circumstances.¹³⁵ Where treatment is indicated, there should be an induction phase followed by a maintenance phase. For lesions on the scalp/face and limbs/trunk, recommended induction therapies include 5% 5-fluorouracil cream, 3.75% imiquimod cream, photodynamic therapy (PDT) and 3% diclofenac in 2.5% hyaluron gel.¹³⁶ Maintenance treatments for lesions on the scalp/face include 5% 5-fluorouracil cream and PDT, with the addition of 0.5% 5-fluorouracil cream combined with 10% salicylic acid for lesions on the limbs/trunk.¹³⁶ When used as maintenance treatment, 5% 5-fluorouracil cream can be used three times weekly over a longer period of time (3–6 months). Although there is no evidence that 5% 5-fluorouracil cream extends time to first keratinocyte carcinoma, it has been shown to decrease the risk of SCC by 75% vs. placebo.¹³⁷ Further evidence is required to optimize AK treatment strategies, particularly in organ transplant recipients, who are considered very high risk patients. Oral retinoids have a poor evidence base, comprising mainly of case series with no clear endpoints and short-term follow-up. Additionally, combination therapy with oral retinoid and oral nicotinamide requires further investigation.

AK lesions of particular risk – discussion on detection of 'risky' AK: Giuseppe Micali

AK may develop into non-melanoma skin cancer and is considered a precursor to SCC. Evidence suggests that, in addition to the classical stepwise progression from AK I to AK II and AK III, invasive SCC (iSCC) may arise from direct invasion of proliferating atypical basaloid keratinocytes that are limited mostly to the epidermal basal layer (AK I).¹³⁸ The depth of follicular extension of atypical keratinocytes in AK correlates with the depth of invasion of associated SCC,¹³⁹ and there is a predictive relationship between the number of AKs and the risk of SCC.¹⁴⁰

Two AK clinical cases were presented. The first concerned the diagnosis and treatment of a 68-year-old male with three AK lesions >1 cm² ('AK patch') (Fig. 6a). This patient's medical history included renal transplantation and AK previously treated with cryotherapy and curettage. The chosen treatment was two two-week cycles of imiquimod 3.75% cream, with clearance of lesions observed 15 days after the end of treatment (Fig. 6b). While the majority of patients with AK are treated with PDT, this case highlights that other treatments may be effective in transplant patients. It was noted that in renal transplant patients, presence of a defined skin site with an AK patch >1 cm² results in an approximate 20-fold increased risk of development of SCC compared with skin sites without this feature.¹⁴¹ Furthermore, patients with ≥ 3 AK patches are six times more likely to develop SCC within an 18-month period than those with <3 AK patches.¹⁴¹

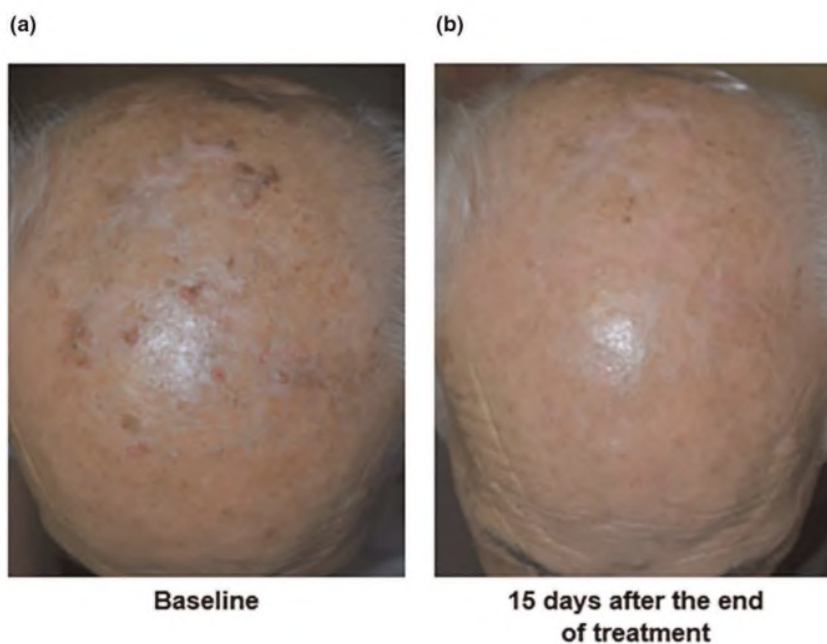


Figure 6 Presentation of AK patches in a 68-year-old patient (a) and following treatment with imiquimod 3.75% cream (b).

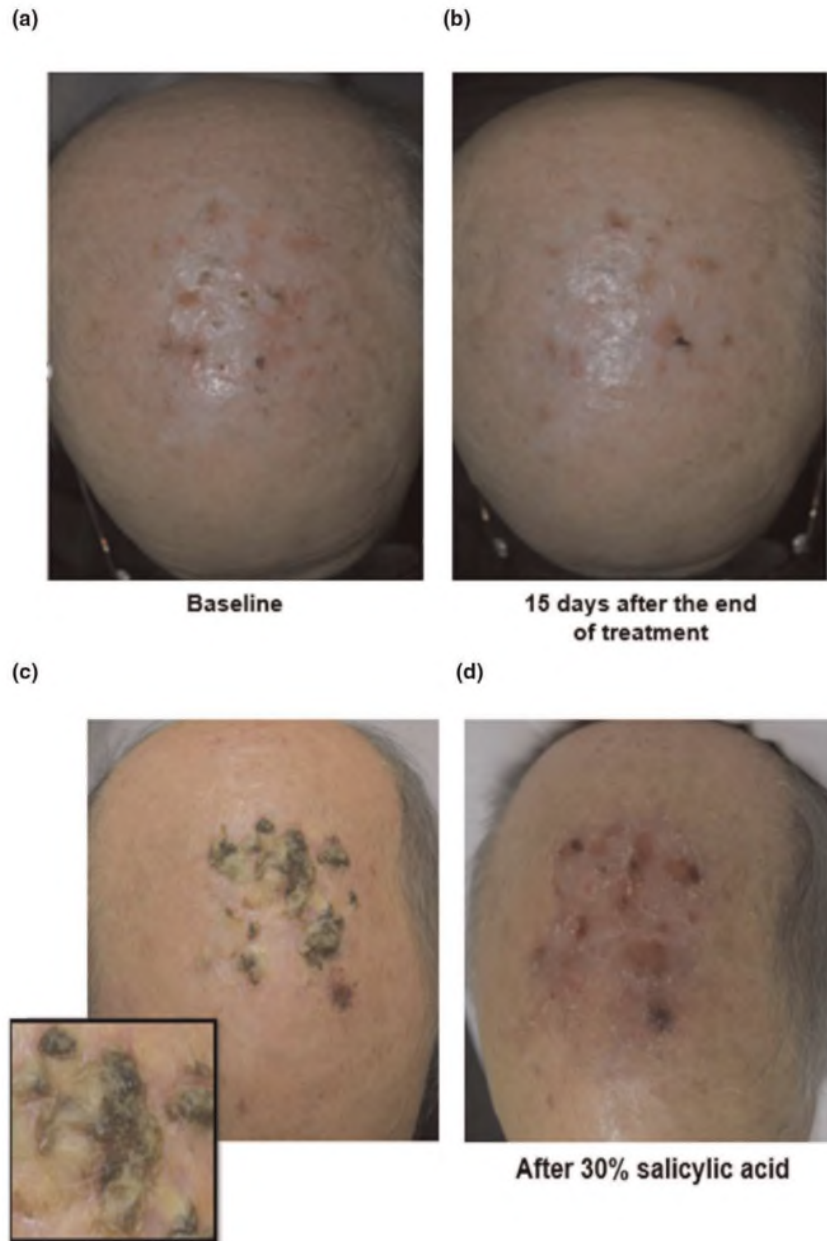


Figure 7 Initial presentation of AK lesions in a 76-year-old patient (a) and following treatment with imiquimod 3.75% cream (b). One year later, hyperkeratotic lesions presented (c) and were treated with 30% salicylic acid ointment (d).

The second clinical case referred to the diagnosis and treatment of a 76-year-old male presenting with AK lesions (Fig. 7a). His medical history revealed AK lesions that had returned following PDT one year prior, and was otherwise unremarkable. Following initial treatment with two two-week cycles of imiquimod 3.75% cream, some lesions remained, as observed 15 days after the end of treatment (Fig. 7b). One

year later, the patient presented with hyperkeratotic lesions (Fig. 7c), which were treated with 30% salicylic acid ointment. After one week (Fig. 7d), two biopsies ruled out AK and iSCC, and allowed diagnosis of erosive pustular dermatitis of the scalp. This skin disorder is rare and occurs mainly in elderly people with sun damaged skin; it is characterized by pustular and crusted lesions. Several factors that trigger

this disorder have been reported, including use of topical medications (fluorouracil, imiquimod, ingenol mebutate and tretinoin), surgery, cryotherapy, radiotherapy, and PDT.¹⁴²⁻¹⁴⁷

Overview of workshops

Sexually transmitted diseases

Colm O'Mahony shared his experiences of daily practice in a UK STI/STD clinic, covering the diagnosis and treatment of STIs/STDs. The importance of physician-patient communication and managing clinical mistakes (e.g. misdiagnosis or misinterpretation of laboratory results) was highlighted.

Giuseppe Micali discussed current diagnostic techniques for common STIs/STDs, including anogenital warts, molluscum contagiosum, herpes simplex, phthiriasis and scabies. The use of dermoscopy and/or reflectance confocal microscopy in the diagnosis of these diseases, and some STIs/STDs with doubtful clinical presentation, was discussed.

Mihael Skerlev discussed the diagnosis and treatment of external genital warts. Guidelines recommend the following patient-applied therapies: imiquimod 3.75% or 5% cream, podoflox 0.5% solution or gel, or sinecatechins 15% ointment.¹⁴⁸ Imiquimod 5% cream in combination with ablation methods (sequential therapy) has been shown to reduce the recurrence of successfully treated anogenital warts¹⁴⁹ and may represent a practical treatment approach. Although treatment options are available for external genital warts, management is difficult and sometimes frustrating; therefore, updated treatment algorithms may be helpful. Preventable measures (human papillomavirus vaccination)^{150,151} also exist and should be promoted.

The future of dermocosmetics

Elena Araviiskaia discussed the uses and applications of modern dermocosmetics, considered an important part of dermatological patient management. This included details on a novel face compact cream containing salix alba and decanediol, which provides effective coverage of acne, and is non-comedogenic, well perceived and well tolerated by patients.¹⁵² Additionally, new areas of research in this field were outlined, including modulation of the skin microbiome,^{153,154} prevention (e.g. of the development of AD¹⁵⁵ or relapse of acne¹⁵⁶), protection from the external environment,^{157,158} nanotechnologies (e.g. for acne treatment)^{159,160} and new vehicles (e.g. lasers) for drug delivery.^{161,162}

Daniela Pinto presented evidence in support of interventions that alter the human microbiome, representing novel diagnostic and therapeutic approaches for the treatment of skin and scalp conditions, as the microbiome is involved in scalp diseases (e.g. hair growth disorders).¹⁶³⁻¹⁶⁵

Firas Al-Niaimi discussed the use of botulinum toxin (BTX) in non-cosmetic dermatology. Use of neurotoxins in medicine is

increasing. As such, dermatologists should expect an increasing number of enquiries from patients regarding BTX. BTX has multiple non-cosmetic uses, including prevention of hypertrophic scars, amelioration of flushing in rosacea, improvement of localized pruritic dermatoses, and treatment of dermatoses aggravated by sweating.^{166,167}

Challenges in dermatology

Laser in dermatology: Firas Al-Niaimi

The use of laser has enormously contributed to dermatology, with different types of lasers providing a range of clinical benefits. Vascular lasers target haemoglobin in capillary malformations, venous malformations, hemangiomas, spider angioma and angiokeratomas.¹⁶⁸ They may also be used to treat non-primary vascular conditions, such as inflammatory acne¹⁶⁹ and inflammatory rosacea.¹⁷⁰ Pigment-specific lasers also have a number of uses, including the treatment of Naevus of Ota. Similarly, ablative lasers, which target water, can treat a number of dermatological conditions, such as sarcoidosis and angiofibromas.^{171,172} Furthermore, use of laser-assisted drug delivery,¹⁷³ and of fractional lasers to treat scarring, is becoming more prominent in dermatology.

Atopic eczema – new hope for a complex disease:

Johannes Ring

In addition to topical dermatotherapy (skin care with emollients), topical anti-inflammatory agents are the cornerstone of proactive, long-term treatment of atopic eczema.^{91,93} Ultraviolet (UV) therapy also has anti-inflammatory and anti-pruritic effects.^{174,175} Despite the availability of these options, the appearance of targeted biologics against mediators of the Th2 inflammatory response (e.g. IL-4, IL-13) offer new hope for the treatment of atopic eczema.^{118,119,176}

Antiseptics and biofilms in wound care: Stan Monstrey

The physiological and pathophysiological principles behind wound healing, and relevant clinical procedures to facilitate the wound healing process, were described. This included details on enzymatic debridement, restoration of moisture balance and infection prevention (through use of antimicrobials, antiseptics and protease inhibitors).

Povidone-iodine (PVP-I), a topical antimicrobial, has a broad spectrum of activity, providing protection from bacteria, viruses, fungi, spores, protozoa, and amoebic cysts.¹⁷⁷ Furthermore, unlike other antiseptics, no acquired resistance or cross-resistance to PVP-I has been reported.¹⁷⁸ PVP-I dressings have been shown to be more effective than silver dressings in the disruption of chronic wound biofilms,¹⁷⁹ which develop as a consequence of the bacterial life cycle (during the multicellular life phase, bacterial cells are sessile and exist as a biofilm).¹⁸⁰

Biologics vs. biosimilars in the treatment of psoriasis:

Matthias Augustin

Biosimilars registered by authorities (e.g. the European Medicines Agency¹⁸¹ and US Food and Drug Administration¹⁸²) for psoriasis are well-controlled and show substantial similarity to biologics.^{183,184} There is currently no evidence to contraindicate the use of biosimilars in psoriasis.¹⁸⁵ Despite this, potential safety issues associated with biosimilars should be considered in real-world care and post-marketing surveillance undertaken,¹⁸⁶ with potential negative expectations of the patient (nocebo effect)¹⁸⁷ managed. Negative expectations can be avoided by providing sufficient patient information¹⁸⁸ and avoiding uncontrolled switches.

Novel non-invasive techniques in the diagnosis of skin

cancers: Caterina Longo

Real-world cases were used to demonstrate current imaging and screening techniques for diagnosing skin cancers, including digital dermatoscopy and confocal microscopy. Digital dermatoscopy is widely used, and can efficiently compare images to detect changes over time in an individual.¹⁸⁹ Confocal microscopy is useful for diagnosing melanoma and basal cell carcinoma.^{190,191} It may also be used to make accurate skin cancer diagnoses in difficult cases.¹⁹²

Conclusions

During the IDeA 2019 meeting, the latest developments and challenges relating to the pathophysiology, diagnosis, evaluation and management of dermatological conditions (including acne, AD and AK) were presented and discussed, and clinical implications noted. Presentations reviewed current treatments, potential therapeutic approaches and key considerations (e.g. antibiotic resistance, selection of appropriate maintenance therapy, recognition of hard to treat lesions) in the management of each condition, as well as discussing the importance of the microbiome in dermatological conditions and of patient education/support. In the management of AK, it was highlighted that active treatment is not always required, depending on patient preferences and clinical circumstances. In addition to the presentations on acne, AD and AK, the diagnosis and treatment of STIs/STDs and the future of dermocosmetics were discussed. Several challenges in dermatology were also reviewed.

Acknowledgements

The authors would like to acknowledge the other speakers from the IDeA 2019 meeting, including Caterina Longo, Colm O'Mahony, Daniela Pinto, Elena Araviiskaia, Firas Al-Niaimi, Johannes Ring, Matthias Augustin, Mihael Skerlev and Stan Monstrey, who contributed valuable presentations/workshops during the meeting. Medical writing assistance in the preparation of this manuscript was provided by Hannah Birchby and Evie Lambert (CircleScience, an Ashfield Company, part of

UDG Healthcare plc), and funded by Meda Pharma S.p.A., a Viatris company. The patients in this manuscript have given written informed consent to publication of their case details.

References

- Moradi Tuchayi S, Alexander TM, Nadkarni A, Feldman SR. Interventions to increase adherence to acne treatment. *Patient Prefer Adherence* 2016; **10**: 2091–2096.
- Dreno B, Thiboutot D, Gollnick H *et al.* Large-scale worldwide observational study of adherence with acne therapy. *Int J Dermatol* 2010; **49**: 448–456.
- Thiboutot D, Dreno B, Layton A. Acne counseling to improve adherence. *Cutis* 2008; **81**: 81–86.
- Zaghoul SS, Cunliffe WJ, Goodfield MJ. Objective assessment of compliance with treatments in acne. *Br J Dermatol* 2005; **152**: 1015–1021.
- Baldwin HE. Tricks for improving compliance with acne therapy. *Dermatol Ther* 2006; **19**: 224–236.
- Feneran AN, Kaufman WS, Dabade TS, Feldman SR. Retinoid plus antimicrobial combination treatments for acne. *Clin Cosmet Investig Dermatol* 2011; **4**: 79–92.
- Nieuwlaat R, Wilczynski N, Navarro T *et al.* Interventions for enhancing medication adherence. *Cochrane Database Syst Rev* 2014:CD000011.
- Yentzer BA, Ade RA, Fountain JM *et al.* Simplifying regimens promotes greater adherence and outcomes with topical acne medications: a randomized controlled trial. *Cutis* 2010; **86**: 103–108.
- Alexander N, Bayerl C, Borelli C *et al.* Erratum und Addendum zur Deutschen S2k-Leitlinie zur Therapie der Akne JDDG 8 (Suppl. 2):S1–S59, 2010. *JDDG* 2010; **8**(Suppl 2):e1–e4.
- Draeos ZK. Patient compliance: enhancing clinician abilities and strategies. *J Am Acad Dermatol* 1995; **32**: S42–S48.
- Luk NM, Hui M, Lee HC *et al.* Antibiotic-resistant Propionibacterium acnes among acne patients in a regional skin centre in Hong Kong. *J Eur Acad Dermatol Venereol* 2013; **27**: 31–36.
- Dreno B, Thiboutot D, Gollnick H *et al.* Antibiotic stewardship in dermatology: limiting antibiotic use in acne. *Eur J Dermatol* 2014; **24**: 330–334.
- Walsh TR, Efthimiou J, Dreno B. Systematic review of antibiotic resistance in acne: an increasing topical and oral threat. *Lancet Infect Dis* 2016; **16**: e23–e33.
- Simonart T, Dramaix M. Treatment of acne with topical antibiotics: lessons from clinical studies. *Br J Dermatol* 2005; **153**: 395–403.
- Thiboutot D, Dreno B, Gollnick H *et al.* A call to limit antibiotic use in acne. *J Drugs Dermatol* 2013; **12**: 1331–1332.
- Bellew S, Thiboutot D, Del Rosso JQ. Pathogenesis of acne vulgaris: what's new, what's interesting and what may be clinically relevant. *J Drugs Dermatol* 2011; **10**: 582–585.
- Adler BL, Kornmehl H, Armstrong AW. Antibiotic resistance in acne treatment. *JAMA Dermatol* 2017; **153**: 810–811.
- Zaenglein AI, Pathy AL, Schlosser BJ *et al.* Guidelines of care for the management of acne vulgaris. *J Am Acad Dermatol* 2016; **74**: 945–973.e33.
- Nast A, Dreno B, Bettoli V *et al.* European evidence-based (S3) guideline for the treatment of acne - update 2016 - short version. *J Eur Acad Dermatol Venereol* 2016; **30**: 1261–1268.
- Leyden JJ. In vivo antibacterial effects of tretinoin-clindamycin and clindamycin alone on Propionibacterium acnes with varying clindamycin minimum inhibitory. *J Drugs Dermatol* 2012; **11**: 1434–1438.
- Ochsendorf F. Clindamycin phosphate 1.2%/tretinoin 0.025%: a novel fixed-dose combination treatment for acne vulgaris. *J Eur Acad Dermatol Venereol* 2015; **29**(Suppl 5): 8–13.
- Leyden J, Stein-Gold L, Weiss J. Why topical retinoids are mainstay of therapy for acne. *Dermatol Ther (Heidelb)* 2017; **7**: 293–304.
- Cunliffe WJ, Holland KT, Bojar R, Levy SF. A randomized, double-blind comparison of a clindamycin phosphate/benzoyl peroxide gel

- formulation and a matching clindamycin gel with respect to microbiologic activity and clinical efficacy in the topical treatment of acne vulgaris. *Clin Ther* 2002; **24**: 1117–1133.
- 24 Dreno B, Lambert J, Bettoli V. Are retinoid/antibiotic fixed-dose combination acne treatments associated with antibiotic resistance? *Eur J Dermatol* 2016; **26**: 90–91.
 - 25 Becker M, Wild T, Zouboulis CC. Objective assessment of acne. *Clin Dermatol* 2017; **35**: 147–155.
 - 26 Ramli R, Malik AS, Hani AF, Jamil A. Acne analysis, grading and computational assessment methods: an overview. *Skin Res Technol* 2012; **18**: 1–14.
 - 27 Min S, Kong HJ, Yoon C, Kim HC, Suh DH. Development and evaluation of an automatic acne lesion detection program using digital image processing. *Skin Res Technol* 2013; **19**: e423–e432.
 - 28 Lehmann HP, Robinson KA, Andrews JS, Holloway V, Goodman SN. Acne therapy: a methodologic review. *J Am Acad Dermatol* 2002; **47**: 231–240.
 - 29 Witkowski JA, Parish LC. The assessment of acne: an evaluation of grading and lesion counting in the measurement of acne. *Clin Dermatol* 2004; **22**: 394–397.
 - 30 Tan JK, Tang J, Fung K *et al*. Development and validation of a comprehensive acne severity scale. *J Cutan Med Surg* 2007; **11**: 211–216.
 - 31 Patwardhan SV, Kaczvinsky JR, Joa JF, Canfield D. Auto-classification of acne lesions using multimodal imaging. *J Drugs Dermatol* 2013; **12**: 746–756.
 - 32 Adityan B, Kumari R, Thappa DM. Scoring systems in acne vulgaris. *Indian J Dermatol Venereol Leprol* 2009; **75**: 323–326.
 - 33 Doshi A, Zaheer A, Stiller MJ. A comparison of current acne grading systems and proposal of a novel system. *Int J Dermatol* 1997; **36**: 416–418.
 - 34 Manfredini M, Mazzaglia G, Ciardo S *et al*. Acne: in vivo morphologic study of lesions and surrounding skin by means of reflectance confocal microscopy. *J Eur Acad Dermatol Venereol* 2015; **29**: 933–939.
 - 35 Sonthalia S, Kaliyadan F. Dermoscopy overview and extradiagnostic applications StatPearls [Internet]. Treasure Island (FL): StatPearls Publishing; 2020. Available at: <https://www.ncbi.nlm.nih.gov/books/NBK537131/> (Last accessed 22 May 2020).
 - 36 Oh J, Byrd AL, Park M, Program NCS, Kong HH, Segre JA. Temporal stability of the human skin microbiome. *Cell* 2016; **165**: 854–866.
 - 37 O’Neill AM, Gallo RL. Host-microbiome interactions and recent progress into understanding the biology of acne vulgaris. *Microbiome* 2018; **6**: 177.
 - 38 Park YJ, Lee HK. The role of skin and orogenital microbiota in protective immunity and chronic immune-mediated inflammatory disease. *Front Immunol*. 2018; **8**: 1955.
 - 39 Naik HB, Nassif A, Ramesh MS *et al*. Are Bacteria Infectious Pathogens in Hidradenitis Suppurativa? Debate at the Symposium for Hidradenitis Suppurativa Advances Meeting, November 2017. *J Invest Dermatol* 2019; **139**: 13–16.
 - 40 Lee YB, Byun EJ, Kim HS. Potential role of the microbiome in acne: a comprehensive review. *J Clin Med* 2019; **8**: 987.
 - 41 Scholz CFP, Kilian M. The natural history of cutaneous propionibacteria, and reclassification of selected species within the genus *Propionibacterium* to the proposed novel genera *Acidipropionibacterium* gen. nov., *Cutibacterium* gen. nov. and *Pseudopropionibacterium* gen. nov. *Int J Syst Evol Microbiol* 2016; **66**: 4422–4432.
 - 42 Kong HH, Segre JA. Skin microbiome: looking back to move forward. *J Invest Dermatol* 2012; **132**: 933–939.
 - 43 Grice EA, Kong HH, Conlan S *et al*. Topographical and temporal diversity of the human skin microbiome. *Science* 2009; **324**: 1190–1192.
 - 44 Jasson F, Nagy I, Knol AC, Zuliani T, Khammari A, Dreno B. Different strains of *Propionibacterium* acnes modulate differently the cutaneous innate immunity. *Exp Dermatol* 2013; **22**: 587–592.
 - 45 Yu Y, Champer J, Agak GW, Kao S, Modlin RL, Kim J. Different *Propionibacterium* acnes phylotypes induce distinct immune responses and express unique surface and secreted proteomes. *J Invest Dermatol* 2016; **136**: 2221–2228.
 - 46 Nodake Y, Matsumoto S, Miura R *et al*. Pilot study on novel skin care method by augmentation with *Staphylococcus epidermidis*, an autologous skin microbe – A blinded randomized clinical trial. *J Dermatol Sci* 2015; **79**: 119–126.
 - 47 Karoglan A, Paetzold B, Pereira de Lima J *et al*. Safety and efficacy of topically applied selected cutibacterium acnes strains over five weeks in patients with acne vulgaris: an open-label, pilot study. *Acta Derm Venereol* 2019; **99**: 1253–1257.
 - 48 Sabry EY. A three-stage strategy in treating acne vulgaris in patients with atopic dermatitis- a pilot study. *J Pakistan Assoc Dermatol* 2009; **19**: 95–105.
 - 49 Hanifin JRG. Diagnostic features of atopic dermatitis. *Acta Derm Venereol* 1980; **92**: 44–47.
 - 50 Eichenfield L, Tom W, Chamlin S *et al*. Guidelines of care for the management of atopic dermatitis. *J Am Acad Dermatol* 2014; **70**: 338–351.
 - 51 Tada J. Diagnostic standard for atopic dermatitis. *JMAJ* 2002; **45**: 460–465.
 - 52 Williams HC, Burney PG, Hay RJ *et al*. The U.K. Working Party’s Diagnostic Criteria for Atopic Dermatitis. I. Derivation of a minimum set of discriminators for atopic dermatitis. *Br J Dermatol* 1994; **131**: 383–396.
 - 53 Williams HC, Burney PG, Pembroke AC, Hay RJ, The UK. Working Party’s Diagnostic Criteria for Atopic Dermatitis. III. Independent hospital validation. *Br J Dermatol* 1994; **131**: 406–416.
 - 54 Williams HC, Burney PG, Strachan D, Hay RJ, The UK. Working Party’s Diagnostic Criteria for Atopic Dermatitis. II. Observer variation of clinical diagnosis and signs of atopic dermatitis. *Br J Dermatol* 1994; **131**: 397–405.
 - 55 Eyerich K, Eyerich S. Immune response patterns in non-communicable inflammatory skin diseases. *J Eur Acad Dermatol Venereol* 2018; **32**: 692–703.
 - 56 Kim BE, Leung DY, Boguniewicz M, Howell MD. Loricrin and involucrin expression is down-regulated by Th2 cytokines through STAT-6. *Clin Immunol* 2008; **126**: 332–337.
 - 57 Eyerich K, Pennino D, Scarponi C *et al*. IL-17 in atopic eczema: linking allergen-specific adaptive and microbial-triggered innate immune response. *J Allergy Clin Immunol* 2009; **123**: 59–66 e4.
 - 58 Eyerich S, Onken AT, Weidinger S *et al*. Mutual antagonism of T cells causing psoriasis and atopic eczema. *N Engl J Med* 2011; **365**: 231–238.
 - 59 Thijs JL, Drylewicz J, Fiechter R *et al*. EASI p-EASI: Utilizing a combination of serum biomarkers offers an objective measurement tool for disease severity in atopic dermatitis patients. *J Allergy Clin Immunol* 2017; **140**: 1703–1705.
 - 60 Dyjack N, Goleva E, Rios C *et al*. Minimally invasive skin tape strip RNA sequencing identifies novel characteristics of the type 2-high atopic dermatitis disease endotype. *J Allergy Clin Immunol* 2018; **141**: 1298–1309.
 - 61 Simpson EL, Villarreal M, Jepson B *et al*. Patients with atopic dermatitis colonized with *Staphylococcus aureus* have a distinct phenotype and endotype. *J Invest Dermatol* 2018; **138**: 2224–2233.
 - 62 Chan TC, Sanyal RD, Pavel AB *et al*. Atopic dermatitis in Chinese patients shows TH2/TH17 skewing with psoriasisiform features. *J Allergy Clin Immunol* 2018; **142**: 1013–1017.
 - 63 Noda S, Suarez-Farinas M, Ungar B *et al*. The Asian atopic dermatitis phenotype combines features of atopic dermatitis and psoriasis with increased TH17 polarization. *J Allergy Clin Immunol* 2015; **136**: 1254–1264.
 - 64 Eyerich K, Eyerich S, Biedermann T. The multi-modal immune pathogenesis of atopic Eczema. *Trends Immunol* 2015; **36**: 788–801.
 - 65 Eyerich K, Novak N. Immunology of atopic eczema: overcoming the Th1/Th2 paradigm. *Allergy* 2013; **68**: 974–982.
 - 66 Alexander H, Paller AS, Traidl-Hoffmann C *et al*. The role of bacterial skin infections in atopic dermatitis: expert statement and review from the International Eczema Council Skin Infection Group. *Br J Dermatol* 2020; **182**: 1331–1342.
 - 67 Reiger M, Schwierzeck V, Traidl-Hoffmann C. Atopic eczema and microbiome. *Hautarzt* 2019; **70**: 407–415.

- 68 Eyerich S, Eyerich K, Traidl-Hoffmann C, Biedermann T. Cutaneous barriers and skin immunity: differentiating a connected network. *Trends Immunol* 2018; **39**: 315–327.
- 69 Haahtela T. A biodiversity hypothesis. *Allergy* 2019; **74**: 1445–1456.
- 70 Fujimura KE, Johnson CC, Ownby DR *et al.* Man's best friend? The effect of pet ownership on house dust microbial communities. *J Allergy Clin Immunol* 2010; **126**: 410–412.e3.
- 71 Sonnenburg ED, Smits SA, Tikhonov M, Higginbottom SK, Wingreen NS, Sonnenburg JL. Diet-induced extinctions in the gut microbiota compound over generations. *Nature* 2016; **529**: 212–215.
- 72 Heiman ML, Greenway FL. A healthy gastrointestinal microbiome is dependent on dietary diversity. *Mol Metab* 2016; **5**: 317–320.
- 73 Ho NT, Li F, Lee-Sarwar KA *et al.* Meta-analysis of effects of exclusive breastfeeding on infant gut microbiota across populations. *Nat Commun* 2018; **9**: 4169.
- 74 Reiger M, Traidl-Hoffmann C, Neumann AU. The skin microbiome as a clinical biomarker in atopic eczema: Promises, navigation, and pitfalls. *J Allergy Clin Immunol* 2020; **145**: 93–96.
- 75 Kong HH, Andersson B, Clavel T *et al.* Performing skin microbiome research: a method to the madness. *J Invest Dermatol* 2017; **137**: 561–568.
- 76 Altunbulakli C, Reiger M, Neumann AU *et al.* Relations between epidermal barrier dysregulation and Staphylococcus species-dominated microbiome dysbiosis in patients with atopic dermatitis. *J Allergy Clin Immunol* 2018; **142**: 1643–1647.e12.
- 77 Panther DJ, Jacob SE. The importance of acidification in atopic eczema: an underexplored avenue for treatment. *J Clin Med* 2015; **4**: 970–978.
- 78 Stewart EJ, Payne DE, Ma TM *et al.* Effect of antimicrobial and physical treatments on growth of multispecies staphylococcal biofilms. *Appl Environ Microbiol* 2017; **83**: e03483–16.
- 79 Hülpiusch C, Tremmel K, Hammel G *et al.* Skin pH-dependent Staphylococcus aureus abundance as predictor for increasing atopic dermatitis severity. *Allergy* 2020; **75**: 2888–2898.
- 80 Hamlin PA, Flinn IW, Wagner-Johnston N *et al.* Efficacy and safety of the dual SYK/JAK inhibitor cerdulatinib in patients with relapsed or refractory B-cell malignancies: Results of a phase I study. *Am J Hematol* 2019; **94**: E90–E93.
- 81 Neumann AU, Reiger M, Bhattacharyya M *et al.* Microbiome correlates of success of treatment of atopic dermatitis with the JAK/SYK inhibitor ASN002. *Allergy* 2019; **74**: S106–S112.
- 82 Nowak DA, Yeung J. Diagnosis and treatment of pruritus. *Can Fam Physician* 2017; **63**: 918–924.
- 83 Peng W, Novak N. Pathogenesis of atopic dermatitis. *Clin Exp Allergy* 2015; **45**: 566–574.
- 84 Potenzieri C, Udem BJ. Basic mechanisms of itch. *Clin Exp Allergy* 2012; **42**: 8–19.
- 85 Tan Y, Ng WJ, Lee SZX *et al.* 3-Dimensional optical clearing and imaging of pruritic atopic dermatitis and psoriasis skin reveals downregulation of epidermal innervation. *J Invest Dermatol* 2019; **139**: 1201–1204.
- 86 Tominaga M, Takamori K. Itch and nerve fibers with special reference to atopic dermatitis: therapeutic implications. *J Dermatol* 2014; **41**: 205–212.
- 87 Pogatzki-Zahn EM, Pereira MP, Cremer A *et al.* Peripheral sensitization and loss of descending inhibition is a hallmark of chronic pruritus. *J Invest Dermatol* 2020; **140**: 203–211.e4.
- 88 Han L, Dong X. Itch mechanisms and circuits. *Annu Rev Biophys* 2014; **43**: 331–355.
- 89 LePoidevin LM, Lee DE, Shi VY. A comparison of international management guidelines for atopic dermatitis. *Pediatr Dermatol* 2019; **36**: 36–65.
- 90 Mattered U, Bohmer MM, Weisshaar E, Jupiter A, Carter B, Apfelbacher CJ. Oral H1 antihistamines as 'add-on' therapy to topical treatment for eczema. *Cochrane Database Syst Rev* 2019; **1**: CD012167.
- 91 Wollenberg A, Barbarot S, Bieber T *et al.* Consensus-based European guidelines for treatment of atopic eczema (atopic dermatitis) in adults and children: part I. *J Eur Acad Dermatol Venereol* 2018; **32**: 657–682.
- 92 Stander S, Pogatzki-Zahn E, Stumpf A *et al.* Facing the challenges of chronic pruritus: a report from a multi-disciplinary medical itch centre in Germany. *Acta Derm Venereol* 2015; **95**: 266–271.
- 93 Wollenberg A, Barbarot S, Bieber T *et al.* Consensus-based European guidelines for treatment of atopic eczema (atopic dermatitis) in adults and children: part II. *J Eur Acad Dermatol Venereol* 2018; **32**: 850–878.
- 94 Stander S, Augustin M, Roggenkamp D *et al.* Novel TRPM8 agonist cooling compound against chronic itch: results from a randomized, double-blind, controlled, pilot study in dry skin. *J Eur Acad Dermatol Venereol* 2017; **31**: 1064–1068.
- 95 Abraham A, Roga G. Topical steroid-damaged skin. *Indian J Dermatol* 2014; **59**: 456–459.
- 96 Coondoo A, Phiske M, Verma S, Lahiri K. Side-effects of topical steroids: A long overdue revisit. *Indian Dermatol Online J* 2014; **5**: 416–425.
- 97 Coondoo A, Sengupta S. Topical corticophobia among parents and caregivers of atopic children. *Indian J Paediatr Dermatol* 2016; **17**: 255–257.
- 98 Jensen JM, Pfeiffer S, Witt M *et al.* Different effects of pimecrolimus and betamethasone on the skin barrier in patients with atopic dermatitis. *J Allergy Clin Immunol* 2009; **124**: R19–28.
- 99 Gollnick H, Luger T, Freytag S, Brautigam M, group Ss. StabiEL: stabilization of skin condition with Elidel – a patients' satisfaction observational study addressing the treatment, with pimecrolimus cream, of atopic dermatitis pretreated with topical corticosteroid. *J Eur Acad Dermatol Venereol* 2008; **22**: 1319–1325.
- 100 Mattila PS, Ullman KS, Fiering S *et al.* The actions of cyclosporin A and FK506 suggest a novel step in the activation of T lymphocytes. *Embo J* 1990; **9**: 4425–4433.
- 101 Rodriguez-Cerdeira C, Sanchez-Blanco E, Molares-Vila A. Clinical application of development of nonantibiotic macrolides that correct inflammation-driven immune dysfunction in inflammatory skin diseases. *Mediators Inflamm* 2012; **2012**: 563709.
- 102 Pereira U, Boulais N, Lebonvallet N, Pennec JP, Dorange G, Misery L. Mechanisms of the sensory effects of tacrolimus on the skin. *Br J Dermatol* 2010; **163**: 70–77.
- 103 Sigurgeirsson B, Boznanski A, Todd G *et al.* Safety and efficacy of pimecrolimus in atopic dermatitis: a 5-year randomized trial. *Pediatrics* 2015; **135**: 597–606.
- 104 Luger T, Boguniewicz M, Carr W *et al.* Pimecrolimus in atopic dermatitis: consensus on safety and the need to allow use in infants. *Pediatr Allergy Immunol* 2015; **26**: 306–315.
- 105 Queille-Roussel C, Paul C, Duteil I *et al.* The new topical ascromycin derivative SDZ ASM 981 does not induce skin atrophy when applied to normal skin for 4 weeks: a randomized, double-blind controlled study. *Br J Dermatol* 2001; **144**: 507–513.
- 106 Aschoff R, Schwanebeck U, Brautigam M, Meurer M. Skin physiological parameters confirm the therapeutic efficacy of pimecrolimus cream 1% in patients with mild-to-moderate atopic dermatitis. *Exp Dermatol* 2009; **18**: 24–29.
- 107 Lubbe J, Friedlander SF, Cribier B *et al.* Safety, efficacy, and dosage of 1% pimecrolimus cream for the treatment of atopic dermatitis in daily practice. *Am J Clin Dermatol* 2006; **7**: 121–131.
- 108 Murrell DF, Calvieri S, Ortonne JP *et al.* A randomized controlled trial of pimecrolimus cream 1% in adolescents and adults with head and neck atopic dermatitis and intolerant of, or dependent on, topical corticosteroids. *Br J Dermatol* 2007; **157**: 954–959.
- 109 Kempers S, Boguniewicz M, Carter B *et al.* A randomized investigator-blinded study comparing pimecrolimus cream 1% with tacrolimus ointment 0.03% in the treatment of pediatric patients with moderate atopic dermatitis. *J Am Acad Dermatol* 2004; **51**: 515–525.
- 110 World Health Organization. Global report on psoriasis, WHO Press, Geneva, 2016.
- 111 Arkwright PD, Motala C, Subramanian H, Spengel J, Schneider LC, Wollenberg A. Management of difficult-to-treat atopic dermatitis. *J Allergy Clin Immunol Pract* 2013; **1**: 142–151.

- 112 Gore C, Johnson RJ, Caress AL, Woodcock A, Custovic A. The information needs and preferred roles in treatment decision-making of parents caring for infants with atopic dermatitis: a qualitative study. *Allergy* 2005; **60**: 938–943.
- 113 Sokolova A, Smith SD. Factors contributing to poor treatment outcomes in childhood atopic dermatitis. *Australas J Dermatol* 2015; **56**: 252–257.
- 114 Smith SD, Stephens AM, Werren JC, Fischer GO. Treatment failure in atopic dermatitis as a result of parental health belief. *Med J Aust* 2013; **199**: 467–469.
- 115 Ahrens B, Staab D. Extended implementation of educational programs for atopic dermatitis in childhood. *Pediatr Allergy Immunol* 2015; **26**: 190–196.
- 116 Schut C, Mahmutovic V, Gieler U, Kupfer J. Patient education programs for childhood atopic dermatitis: who is interested? *J Dtsch Dermatol Ges* 2012; **10**: 657–661.
- 117 Pickett K, Loveman E, Kalita N, Frampton GK, Jones J. Educational interventions to improve quality of life in people with chronic inflammatory skin diseases: systematic reviews of clinical effectiveness and cost-effectiveness. *Health Technol Assess* 2015; **19**: 1–176 v–vi.
- 118 Blauvelt A, de Bruin-Weller M, Gooderham M *et al.* Long-term management of moderate-to-severe atopic dermatitis with dupilumab and concomitant topical corticosteroids (LIBERTY AD CHRONOS): a 1-year, randomised, double-blinded, placebo-controlled, phase 3 trial. *Lancet* 2017; **389**: 2287–2303.
- 119 Wollenberg A, Howell MD, Guttman-Yassky E *et al.* Treatment of atopic dermatitis with tralokinumab, an anti-IL-13 mAb. *J Allergy Clin Immunol* 2019; **143**: 135–141.
- 120 Thaçi D, Constantin MM, Rojkovich B *et al.* MOR106, an anti-IL-17C mAb, a potential new approach for treatment of moderate-to-severe atopic dermatitis: Phase 1 study American Academy of Dermatology (AAD) 2018. Available at: <https://www.gpg.com/docs/view/5a8b0a453276f-en> (Last accessed 23 March 2020).
- 121 Simpson E. Bermekimab - a future treatment for atopic dermatitis? American Academy of Dermatology (AAD) 2019. Available at: <https://conferences.m3medical.com/aad-2019/article/bermekimab-a-future-treatment-for-atopic-dermatitis/> (Last accessed 23 March 2020).
- 122 Guttman-Yassky E, Silverberg JI, Nemoto O *et al.* Baricitinib in adult patients with moderate-to-severe atopic dermatitis: A phase 2 parallel, double-blinded, randomized placebo-controlled multiple-dose study. *J Am Acad Dermatol* 2019; **80**: 913–921 e9.
- 123 Kim BS, Howell MD, Sun K *et al.* Treatment of atopic dermatitis with ruxolitinib cream (JAK1/JAK2 inhibitor) or triamcinolone cream. *J Allergy Clin Immunol* 2020; **145**: 572–582.
- 124 Yosipovitch G, Stander S, Kerby MB *et al.* Serlopitant for the treatment of chronic pruritus: Results of a randomized, multicenter, placebo-controlled phase 2 clinical trial. *J Am Acad Dermatol* 2018; **78**: 882–891 e10.
- 125 Draelos ZD, Stein Gold LF, Murrell DF, Hughes MH, Zane LT. Post hoc analyses of the effect of crisaborole topical ointment, 2% on atopic dermatitis: associated pruritus from phase 1 and 2 clinical studies. *J Drugs Dermatol* 2016; **15**: 172–176.
- 126 Paller AS, Tom WL, Leibold MG *et al.* Efficacy and safety of crisaborole ointment, a novel, nonsteroidal phosphodiesterase 4 (PDE4) inhibitor for the topical treatment of atopic dermatitis (AD) in children and adults. *J Am Acad Dermatol* 2016; **75**: 494–503 e6.
- 127 Peppers J, Paller AS, Maeda-Chubachi T *et al.* A phase 2, randomized dose-finding study of tapinarof (GSK2894512 cream) for the treatment of atopic dermatitis. *J Am Acad Dermatol* 2019; **80**: 89–98 e3.
- 128 Nakatsuji T, Chen TH, Narala S *et al.* Antimicrobials from human skin commensal bacteria protect against *Staphylococcus aureus* and are deficient in atopic dermatitis. *Sci Transl Med* 2017; **9**: eaab4680.
- 129 Dirschka T, Pellacani G, Micali G *et al.* A proposed scoring system for assessing the severity of actinic keratosis on the head: actinic keratosis area and severity index. *J Eur Acad Dermatol Venereol* 2017; **31**: 1295–1302.
- 130 Schmitz L, Gambichler T, Gupta G, Stucker M, Dirschka T. Actinic keratosis area and severity index (AKASI) is associated with the incidence of squamous cell carcinoma. *J Eur Acad Dermatol Venereol* 2018; **32**: 752–756.
- 131 Schmitz L, Gambichler T, Gupta G *et al.* Actinic keratoses show variable histological basal growth patterns - a proposed classification adjustment. *J Eur Acad Dermatol Venereol* 2018; **32**: 745–751.
- 132 Schmitz L, Gambichler T, Kost C *et al.* Cutaneous squamous cell carcinomas are associated with basal proliferating actinic keratoses. *Br J Dermatol* 2019; **180**: 916–921.
- 133 Dirschka T, Gupta G, Micali G *et al.* Real-world approach to actinic keratosis management: practical treatment algorithm for office-based dermatology. *J Dermatolog Treat* 2017; **28**: 431–442.
- 134 Gollnick H, Dirschka T, Ostendorf R, Kerl H, Kunstfeld R. Long-term clinical outcomes of imiquimod 5% cream vs. diclofenac 3% gel for actinic keratosis on the face or scalp: a pooled analysis of two randomized controlled trials. *J Eur Acad Dermatol Venereol* 2020; **34**: 82–89.
- 135 de Berker D, McGregor JM, Mohd Mustapa MF, Exton LS, Hughes BR. British Association of Dermatologists' guidelines for the care of patients with actinic keratosis 2017. *Br J Dermatol* 2017; **176**: 20–43.
- 136 Gupta G, Madan V, Lear J. Squamous cell carcinoma and its precursors. In: Rook's Textbook of Dermatology (eds C. Griffiths, J. Barker, T. Bleiker, R. Chalmers and D. Creamer), 9th edn. John Wiley & Sons, Ltd.; 2016. Chapter 142.
- 137 Weinstock MA, Thwin SS, Siegel JA *et al.* Chemoprevention of Basal and squamous cell carcinoma with a single course of fluorouracil, 5%, cream: a randomized clinical trial. *JAMA Dermatol* 2018; **154**: 167–174.
- 138 Fernandez-Figueras MT, Carrato C, Saenz X *et al.* Actinic keratosis with atypical basal cells (AK I) is the most common lesion associated with invasive squamous cell carcinoma of the skin. *J Eur Acad Dermatol Venereol* 2015; **29**: 991–997.
- 139 Fernandez-Figueras MT, Saenz-Sarda X, Vargas P *et al.* The depth of follicular extension in actinic keratosis correlates with the depth of invasion in squamous cell carcinoma: implication for clinical treatment. *J Eur Acad Dermatol Venereol* 2018; **32**: 1657–1661.
- 140 Green A, Battistutta D. Incidence and determinants of skin cancer in a high-risk Australian population. *Int J Cancer* 1990; **46**: 356–361.
- 141 Jiyad Z, O'Rourke P, Soyer HP, Green AC. Actinic keratosis-related signs predictive of squamous cell carcinoma in renal transplant recipients: a nested case-control study. *Br J Dermatol* 2017; **176**: 965–970.
- 142 Mehmi M, Abdullah A. Erosive pustular dermatosis of the scalp occurring after partial thickness skin graft for squamous cell carcinoma. *Br J Plast Surg* 2004; **57**: 806–807.
- 143 Corradin MT, Forcione M, Giuliani E, Fiorentino R, Ferrazzi A, Alaibac M. Erosive pustular dermatosis of the scalp induced by imiquimod. *Case Rep Dermatol Med* 2012; **2012**: 828749.
- 144 Grattan CE, Peachey RD, Boon A. Evidence for a role of local trauma in the pathogenesis of erosive pustular dermatosis of the scalp. *Clin Exp Dermatol* 1988; **13**: 7–10.
- 145 Rongioletti F, Delmonte S, Rossi ME, Strani GF, Rebora A. Erosive pustular dermatosis of the scalp following cryotherapy and topical tretinoin for actinic keratoses. *Clin Exp Dermatol* 1999; **24**: 499–500.
- 146 Vaccaro M, Barbuzza O, Guarneri B. Erosive pustular dermatosis of the scalp following treatment with topical imiquimod for actinic keratosis. *Arch Dermatol* 2009; **145**: 1340–1341.
- 147 Vaccaro M, Borgia F, Gasco L, Cannavo SP. Erosive pustular dermatosis of the scalp following topical ingenol mebutate for actinic keratoses. *Dermatol Ther* 2017; **30**: e12521.
- 148 Workowski KA, Bolan GA. Sexually transmitted diseases treatment guidelines, 2015. *MMWR Recomm Rep* 2015; **64**: 1–137.
- 149 Schofer H, Van Ophoven A, Henke U, Lenz T, Eul A. Randomized, comparative trial on the sustained efficacy of topical imiquimod 5% cream versus conventional ablative methods in external anogenital warts. *Eur J Dermatol* 2006; **16**: 642–648.
- 150 Bogaards JA, Wallinga J, Brakenhoff RH, Meijer CJ, Berkhof J. Direct benefit of vaccinating boys along with girls against oncogenic human papillomavirus: bayesian evidence synthesis. *BMJ* 2015; **350**: h2016.

- 151 Smith MA, Canfell K. Incremental benefits of male HPV vaccination: accounting for inequality in population uptake. *PLoS One* 2014; **9**: e101048.
- 152 Monfrecola G, Cacciapuoti S, Capasso C, Delfino M, Fabbrocini G. Tolerability and camouflaging effect of corrective makeup for acne: results of a clinical study of a novel face compact cream. *Clin Cosmet Investig Dermatol* 2016; **9**: 307–313.
- 153 Dreno B, Martin R, Moyal D, Henley JB, Khammari A, Seite S. Skin microbiome and acne vulgaris: Staphylococcus, a new actor in acne. *Exp Dermatol* 2017; **26**: 798–803.
- 154 Seite S, Zelenkova H, Martin R. Clinical efficacy of emollients in atopic dermatitis patients – relationship with the skin microbiota modification. *Clin Cosmet Investig Dermatol* 2017; **10**: 25–33.
- 155 Simpson EL, Chalmers JR, Hanifin JM *et al.* Emollient enhancement of the skin barrier from birth offers effective atopic dermatitis prevention. *J Allergy Clin Immunol* 2014; **134**: 818–823.
- 156 Truchuelo MT, Jimenez N, Mavura D, Jaen P. Assessment of the efficacy and safety of a combination of 2 topical retinoids (RetinSphere) in maintaining post-treatment response of acne to oral isotretinoin. *Actas Dermosifiliogr* 2015; **106**: 126–132.
- 157 Tacheau C, Weisgerber F, Fagot D *et al.* Vichy Thermal Spring Water (VTSW), a cosmetic ingredient of potential interest in the frame of skin ageing exposome: an in vitro study. *Int J Cosmet Sci* 2018; **40**: 377–387.
- 158 Grether-Beck S, Marini A, Jaenicke T, Krutmann J. Effective photoprotection of human skin against infrared A radiation by topically applied antioxidants: results from a vehicle controlled, double-blind, randomized study. *Photochem Photobiol* 2015; **91**: 248–250.
- 159 Inui S, Aoshima H, Nishiyama A, Itami S. Improvement of acne vulgaris by topical fullerene application: unique impact on skin care. *Nanomedicine* 2011; **7**: 238–241.
- 160 Santos AC, Morais F, Simoes A *et al.* Nanotechnology for the development of new cosmetic formulations. *Expert Opin Drug Deliv* 2019; **16**: 313–330.
- 161 Ibrahim O, Wenande E, Hogan S, Arndt KA, Haedersdal M, Dover JS. Challenges to laser-assisted drug delivery: Applying theory to clinical practice. *Lasers Surg Med* 2018; **50**: 20–27.
- 162 Haedersdal M, Erlendsson AM, Paasch U, Anderson RR. Translational medicine in the field of ablative fractional laser (AFXL)-assisted drug delivery: A critical review from basics to current clinical status. *J Am Acad Dermatol* 2016; **74**: 981–1004.
- 163 Ma L, Guichard A, Cheng Y *et al.* Sensitive scalp is associated with excessive sebum and perturbed microbiome. *J Cosmet Dermatol* 2019; **18**: 922–928.
- 164 Rebello D, Wang E, Yen E, Lio PA, Kelly CR. Hair growth in two alopecia patients after fecal microbiota transplant. *ACG Case Rep J* 2017; **4**: e107.
- 165 Pinto D, Sorbellini E, Marzani B, Rucco M, Giuliani G, Rinaldi F. Scalp bacterial shift in Alopecia areata. *PLoS One* 2019; **14**: e0215206.
- 166 Forbat E, Ali FR, Al-Niaimi F. Non-cosmetic dermatological uses of botulinum neurotoxin. *J Eur Acad Dermatol Venereol* 2016; **30**: 2023–2029.
- 167 Scala J, Vojvodic A, Vojvodic P *et al.* Botulin toxin use in rosacea and facial flushing treatment. *Open Access Maced J Med Sci* 2019; **7**: 2985–2987.
- 168 Adamic M, Pavlovic MD, Troilius Rubin A, Palmetun-Ekback M, Boixeda P. Guidelines of care for vascular lasers and intense pulse light sources from the European Society for Laser Dermatology. *J Eur Acad Dermatol Venereol* 2015; **29**: 1661–1678.
- 169 Jih MH, Kimyai-Asadi A. Laser treatment of acne vulgaris. *Semin Plast Surg* 2007; **21**: 167–174.
- 170 Ko HS, Suh YJ, Byun JW, Choi GS, Shin J. Pulsed dye laser treatment combined with oral minocycline reduces recurrence rate of rosacea. *Ann Dermatol* 2017; **29**: 543–547.
- 171 Ali FR, Mallipeddi R, Craythorne EE, Sheth N, Al-Niaimi F. Our experience of carbon dioxide laser ablation of angiofibromas: Case series and literature review. *J Cosmet Laser Ther* 2016; **18**: 372–375.
- 172 Al-Niaimi F. Facial cutaneous sarcoid treated successfully with carbon dioxide laser in skin type 6. *J Cutan Aesthet Surg* 2017; **10**: 122–123.
- 173 Ali FR, Al-Niaimi F. Laser-assisted drug delivery in dermatology: from animal models to clinical practice. *Lasers Med Sci* 2016; **31**: 373–381.
- 174 Rodenbeck DL, Silverberg JI, Silverberg NB. Phototherapy for atopic dermatitis. *Clin Dermatol* 2016; **34**: 607–613.
- 175 Legat FJ. The antipruritic effect of phototherapy. *Front Med (Lausanne)* 2018; **5**: 333.
- 176 de Bruin-Weller M, Thaci D, Smith CH *et al.* Dupilumab with concomitant topical corticosteroid treatment in adults with atopic dermatitis with an inadequate response or intolerance to ciclosporin A or when this treatment is medically inadvisable: a placebo-controlled, randomized phase III clinical trial (LIBERTY AD CAFE). *Br J Dermatol* 2018; **178**: 1083–1101.
- 177 Bigliardi PL, Alsagoff SAL, El-Kafrawi HY, Pyon JK, Wa CTC, Villa MA. Povidone iodine in wound healing: A review of current concepts and practices. *Int J Surg* 2017; **44**: 260–268.
- 178 Eggers M. Infectious disease management and control with povidone iodine. *Infect Dis Ther* 2019; **8**: 581–593.
- 179 Hill KE, Malic S, McKee R *et al.* An in vitro model of chronic wound biofilms to test wound dressings and assess antimicrobial susceptibilities. *J Antimicrob Chemother* 2010; **65**: 1195–1206.
- 180 Berlanga M, Guerrero R. Living together in biofilms: the microbial cell factory and its biotechnological implications. *Microb Cell Fact* 2016; **15**: 165.
- 181 Agency EM. Guideline on similar biological medicinal products containing monoclonal antibodies – non-clinical and clinical issues, EMA/CHMP/BMWP/403543/2010 2012. Available at: https://www.ema.europa.eu/en/documents/scientific-guideline/guideline-similar-biological-medicinal-products-containing-monoclonal-antibodies-non-clinical_en.pdf (Last accessed May 2019).
- 182 US Food and Drug Administration. Biosimilars Action Plan 2018. Available at: <https://www.fda.gov/media/114574/download> (Last accessed May 2019).
- 183 McCamish M, Woollett G. The state of the art in the development of biosimilars. *Clin Pharmacol Ther* 2012; **91**: 405–417.
- 184 Puig L, Lopez-Ferrer A. Biosimilars for the treatment of psoriasis. *Expert Opin Biol Ther* 2019; **19**: 993–1000.
- 185 Blauvelt A, Lacour JP, Fowler JF, Jr *et al.* Phase III randomized study of the proposed adalimumab biosimilar GP2017 in psoriasis: impact of multiple switches. *Br J Dermatol* 2018; **179**: 623–631.
- 186 McKinnon RA, Cook M, Liauw W *et al.* Biosimilarity and interchangeability: principles and evidence: a systematic review. *BioDrugs* 2018; **32**: 27–52.
- 187 Kristensen LE, Alten R, Puig L *et al.* Non-pharmacological effects in switching medication: the nocebo effect in switching from originator to biosimilar agent. *BioDrugs* 2018; **32**: 397–404.
- 188 Azevedo A, Bettencourt A, Selores M, Torres T. Biosimilar agents for psoriasis treatment: the perspective of Portuguese patients. *Acta Med Port* 2018; **31**: 496–500.
- 189 Malvey J, Puig S. Follow-up of melanocytic skin lesions with digital total-body photography and digital dermoscopy: a two-step method. *Clin Dermatol* 2002; **20**: 297–304.
- 190 Pellacani G, Guitera P, Longo C, Avramidis M, Seidenari S, Menzies S. The impact of in vivo reflectance confocal microscopy for the diagnostic accuracy of melanoma and equivocal melanocytic lesions. *J Invest Dermatol* 2007; **127**: 2759–2765.
- 191 Guitera P, Menzies SW, Longo C, Cesinaro AM, Scolyer RA, Pellacani G. In vivo confocal microscopy for diagnosis of melanoma and basal cell carcinoma using a two-step method: analysis of 710 consecutive clinically equivocal cases. *J Invest Dermatol* 2012; **132**: 2386–2394.
- 192 Borsari S, Pampena R, Lallas A *et al.* Clinical indications for use of reflectance confocal microscopy for skin cancer diagnosis. *JAMA Dermatol* 2016; **152**: 1093–1098.