

## Original Article

# Diagnostic accuracy study of routine echocardiography for bicuspid aortic valve: a retrospective study and meta-analysis

Mathias Hillebrand<sup>1\*</sup>, Dietmar Koschyk<sup>1\*#</sup>, Pia ter Hark<sup>1</sup>, Helke Schüler<sup>1</sup>, Meike Rybczynski<sup>1</sup>, Jürgen Berger<sup>2</sup>, Amit Gulati<sup>2</sup>, Alexander M. Bernhardt<sup>1</sup>, Christian Detter<sup>1</sup>, Evaldas Girdukas<sup>1</sup>, Stefan Blankenberg<sup>1</sup>, Yskert von Kodolitsch<sup>1</sup>

<sup>1</sup>Centre of Cardiology and Cardiovascular Surgery, <sup>2</sup>Department of Medical Biometry and Epidemiology, University Hospital Eppendorf, Hamburg, Germany

**Contributions:** (I) Conception and design: Y von Kodolitsch, M Hillebrand, D Koschyk; (II) Administrative support: M Hillebrand, P ter Hark; (III) Provision of study materials or patients: D Koschyk, M Rybczynski, C Detter, E Girdukas, AM. Bernhardt; (IV) Collection and assembly of data: M Hillebrand, P ter Hark, D Koschyk, J Berger, A Gulati, AM Bernhardt; (V) Data analysis and interpretation: M Hillebrand, Y von Kodolitsch, P ter Hark, J Berger; (VI) Manuscript writing: All authors; (VII) Final approval of manuscript: All authors.

\*These authors contributed equally to this work.

#Dr. Dietmar Koschyk died on May 18, 2017.

**Correspondence to:** Prof. Dr. Yskert von Kodolitsch, MD, MBA. Centre of Cardiology and Cardiovascular Surgery, Department of Cardiology/Angiology, University Hospital Hamburg Eppendorf, Martinistrasse 52, Hamburg 20246, Germany. Email: [kodolitsch@uke.de](mailto:kodolitsch@uke.de).

**Background:** Transthoracic echocardiography (TTE) is the standard procedure to distinguish tricuspid aortic valve (TAV) from bicuspid aortic valve (BAV). Published studies assessed the accuracy of TTE for BAV under ideal conditions. Conversely, we aimed at assessing accuracy of TTE for BAV under routine conditions.

**Methods:** This retrospective, cross-sectional study of 216 adults included 132 men aged 62±14 years. Of these, 108 had BAV and 108 were age-matched individuals with TAV. All diagnoses were confirmed at surgery. We assessed TTE in two patient groups. First, in the (I) group of all 216 individuals, where we assessed accuracy for BAV according to the original diagnoses as documented by the primary investigators during original TTE examination. Second, we assessed accuracy for BAV according to expert re-evaluation in (II) all 158 TTE with availability of original recordings. Third, we performed a meta-analysis of published results on the accuracy of TTE for BAV according to PRISMA standards.

**Results:** Sensitivity, specificity and accuracy of (I) primary investigators was 46.3%, 97.2, and 71.8% as compared to (II) expert re-evaluation with 59.7%, 93%, and 77.8%, respectively. Sensitivity was significantly higher at re-evaluation ( $P<0.001$ ). TTE at a non-tertiary care center ( $P=0.012$ ), presence of aortic aneurysm ( $P=0.001$ ) and presence of severe aortic valve calcification ( $P=0.003$ ) predicted an inaccurate diagnosis of BAV. Conversely, meta-analysis of published TTE studies identified a pooled sensitivity of 87.7% and a pooled specificity of 88.3% for BAV.

**Conclusions:** The current study shows that TTE yields almost ideal diagnostic accuracy when ideal investigators examine ideal patients. However, the study also shows that TTE yields suboptimal diagnostic accuracy under routine conditions. TTE in non-tertiary care settings, concomitant aortic aneurysm, and presence of severe aortic valve calcification predict an inaccurate diagnosis of BAV.

**Keywords:** Bicuspid aortic valve (BAV); echocardiography; meta-analysis; aorta; evidence; diagnostic error

Submitted Feb 20, 2017. Accepted for publication Apr 07, 2017.

doi: [10.21037/cdt.2017.05.03](https://doi.org/10.21037/cdt.2017.05.03)

View this article at: <http://dx.doi.org/10.21037/cdt.2017.05.03>

## Introduction

Bicuspid aortic valve (BAV) disease is the disease where the aortic valve has only two cusps instead of three tricuspid aortic valve (TAV). With a prevalence of 0.5% to 1.39% in the general population BAV is the most frequent congenital heart disease (1). There is a considerable anatomical variance of BAV, and several systems exist to classify this variance (1-4). The morbidity of BAV is high already at younger adulthood, and 25% of affected persons experience in the course of their life severe aortic valve dysfunction, ascending aortic aneurysm, cardiac death, hospital admission for heart failure, and aortic dissection or rupture (5). Therefore, it is important to diagnose BAV before severe complications develop. Guidelines recommend transthoracic echocardiography (TTE) as the standard procedure to diagnose BAV (6). Indeed, since the initial report of *in vivo* diagnosis of BAV by TTE in 1974 studies continued to report high diagnostic accuracy for BAV (7). However, these studies were performed under ideal conditions, with expert investigators having a special interest in BAV, with usage of high-end TTE equipment, and with exclusion of patients having suboptimal imaging conditions.

We performed the current study in the setting of echocardiography prior to elective surgical replacement of the aortic valve. We aimed at assessing the diagnostic accuracy of routine TTE for BAV. First, we assessed diagnostic accuracy for BAV according to (I) original reports upon preoperative routine echocardiography. Then we assessed diagnostic accuracy for BAV according to (II) expert re-evaluation of all available original TTE recordings. Finally, we performed a meta-analysis of previously published studies to assess accuracy of TTE for diagnosing BAV according to PRISMA recommendations (8). All diagnostic results were validated against the standard reference of intraoperative inspection.

## Methods

### Patients

We analysed all consecutive individuals with BAV who underwent aortic valve replacement at our tertiary care centre between March 2009 and March 2014. We excluded one individual with intraoperative confirmation of a unicuspid aortic valve, and seven individuals with aortic valves that exhibited two cusps but three sinuses with three interleaflet triangles indicating an acquired rather than

congenital bicuspid structure of the aortic valve. We did not identify other congenital aortic valve malformations such as a quadricuspid aortic valve (9-11). Therefore, a total of 108 individuals with BAV confirmed during surgical inspection qualified for inclusion in this study. We established a diagnostic control group by matching each individual with intraoperative diagnosis of BAV with one individual with intraoperative diagnosis of TAV. We identified these control patients by matching according to age at operation, and date of operation and institution where TTE had been performed. Therefore our final study group comprised a total of 216 individuals including 132 men and 84 women at a mean age of  $62 \pm 14$  years (range, 19–82 years). All patients underwent TTE and uncomplicated standard aortic valve replacement surgery. Given the retrospective, observational study design and anonymous data analysis, the Hamburg review board waived the requirement of individual patient consent.

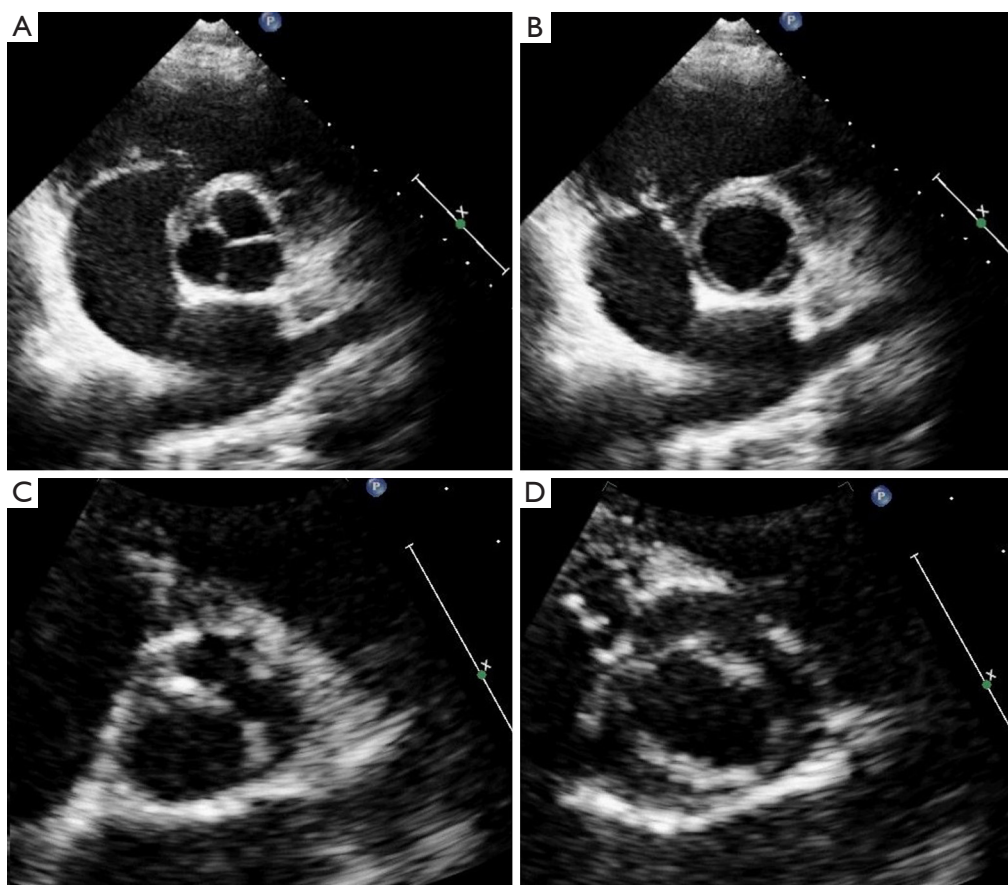
### Two diagnostic groups

We assessed TTE in two patient groups. First, we assessed the diagnostic results in the (I) group of all 216 individuals, where we assessed the diagnosis of BAV according to the original diagnoses as documented by the primary investigators during original TTE examination. Primary investigators comprised board certified cardiologists from private practices or from referring hospitals in 42 patients or interns under the supervision of expert investigators in our hospital in 174 patients.

Second, we performed an (II) expert re-evaluation of all 158 available original TTE recordings. For this re-evaluation we applied the diagnostic criteria of Nistri *et al.* for BAV, where we separated BAV from TAV depending on visualization of two versus three aortic valve cusps in systole and diastole in the short-axis view (*Figure 1*) (12). Two expert-readers with  $\geq 10$  years of echocardiographic experience jointly re-evaluated TTE recordings in all individuals with diagnosis of BAV or TAV on a consensus basis. Both examiners were aware that they took part in a study on the accuracy of TTE for BAV. However, they were blinded to intraoperative findings and results from other imaging procedures.

### Diagnostic criteria

We considered findings on TTE as true positive when BAV was diagnosed on TTE and confirmed at surgery,

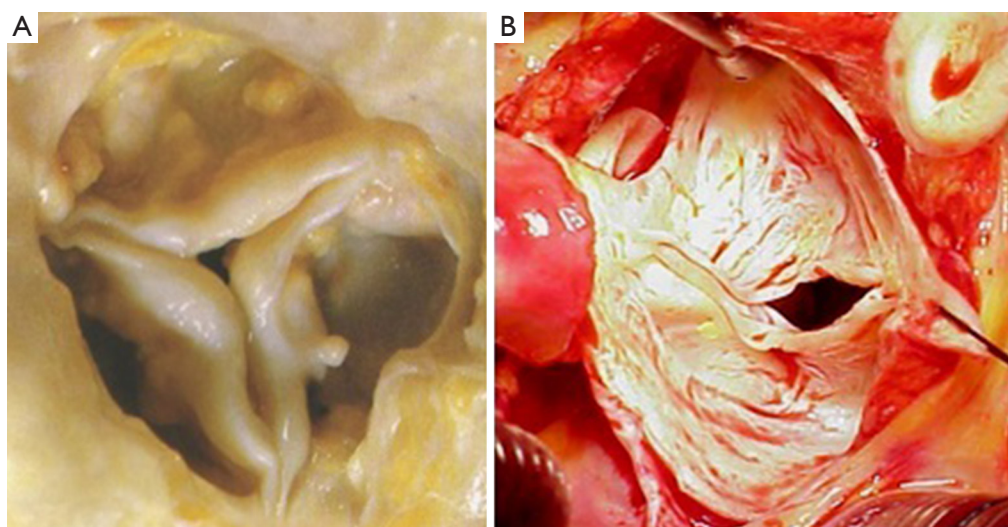


**Figure 1** The parasternal short-axis view on the aortic valve at two-dimensional transthoracic echocardiographic examination. The left upper panel exhibits the Y-shaped commissures of a tricuspid aortic valve in diastole. The left lower panel shows a bicuspid aortic valve with a single commissural line in diastole. The right upper panel shows three commissures during systole in the tricuspid aortic valve. The right lower panel shows an oval opening shape of only two commissures during systole in the bicuspid aortic valve.

as false negative when TAV was found on TTE but BAV was identified at surgery, as true negative when TAV was suggested by TTE and excluded at surgery, and as false positive when BAV was diagnosed by TTE but TAV was identified at surgery (Figure 2). We considered intraoperative diagnosis by the attending surgeon as standard reference for BAV and TAV, because this diagnosis is superior even to aortic tissue examination by a pathologist (13). The classification of BAV according to Schaefer was type 1 with fused right and left coronary cusp, type 2 with fused right and non-coronary cusps, and type 3 with fused non-coronary and left coronary cusps as documented by the attending surgeon (3). All TTE examinations were performed within 30 days prior to aortic valve replacement using standard commercially available systems with current M-mode and 2-dimensional scanning technology.

#### *Clinical variables*

Preoperative variables from patients' charts included age, sex, body height, body weight, and body surface area according to Du Bois (14). We documented whether TTE was performed at our institution or at referring institutions. We assessed indications for valve surgery according to surgical records as isolated or predominant aortic valve stenosis, isolated or predominant aortic valve regurgitation or mixed aortic valve disease when stenosis and regurgitation contributed equally to valve dysfunction. We noted aortic aneurysm with diameters  $\geq 4.0$  cm at the level of the aortic sinuses or the ascending aorta as documented on preoperative TTE or tomographic imaging, severe calcification of the aortic valve with extensive thickening and calcification of all aortic cusps with grade 4 calcification according to Rosenhek *et al.* on



**Figure 2** Photographs of the aortic valve during surgical inspection. The left panel displays three commissures of a tricuspid aortic valve. The right panel displays only two cusps with two commissures as evidence for presence of a bicuspid aortic valve.

TTE (15), and with grade 5 calcification according to Yousry *et al.* on surgical inspection (16).

### *Systematic review and meta-analysis*

We performed a systematic review of the literature to assess published frequencies of true positive, false negative, true positive and true negative diagnoses of BAV as target condition and TAV as control condition on standard two-dimensional echocardiography as index test with intraoperative diagnosis or exclusion of BAV on surgical inspection as reference test. We considered studies published in English, French, or German language with inclusion of individuals of all ages with confirmation of BAV or TAV at surgery of the aortic valve. We used the following key words to search MEDLINE: BAV, echocardiography, diagnosis, sensitivity, specificity, accuracy, and we screened the literature cited in all articles that we retrieved from this search. In this way we identified a total of 68 studies. Of these, we excluded 39 studies, because they did not provide information on sensitivity and specificity, 10 studies, because they did not use intraoperative inspection as reference test, 7 studies because they did not present diagnostic data adequately, and 3 studies because the articles uses another language than English, French or German. We provide the details of these studies in a flow sheet according to PRISMA recommendations (Supplementary, *Figure S1*) (8). Finally, we identified a total

of nine studies for inclusion in our systematic review. Two investigators assessed STARD quality scores (17) of all nine studies independently from each other. They jointly discussed and reconciled discrepant scorings (*Table 1*).

### *Statistical methods*

Unless otherwise specified, we expressed quantitative data as means  $\pm$  standard deviation (SD) and qualitative data as numbers (percentage). For comparison of baseline characteristics we employed the Kruskal-Wallis test for continuous data and the generalized Fisher's exact test for nominal and categorical data (*Table 2*). We derived sensitivity, specificity, accuracy, and positive and negative likelihood ratios of TTE from the number of true positive, false negative, true negative and false negative diagnostic results using standard formulas (26), where we calculated "exact" Clopper-Pearson confidence intervals (CI) (*Table 3*) (27). We used logistic regression to identify clinical variables that related to a correct diagnosis of BAV or TAV (*Table 4*). We considered P values  $<0.05$  as significant, and we included in our multivariate model all variables with significant P value on univariate testing (*Table 4*). For meta-analysis we derived sensitivity, specificity, accuracy, and positive and negative likelihood ratios of TTE and their respective 95% CIs from the number of true positive, false negative, true negative and false negative diagnostic results with the same methods as described above (*Table 1*).

**Table 1** Systematic review of diagnostic results of TTE for BAV according to intraoperative inspection as standard of reference

Final diagnosis	Study population	STARD quality score (17)	True positive	False negative	True negative	False positive
Fowles 1979 (18)	Age 14.9 [5–31], 63% M <sup>1</sup>	11	13	0	5	1
Brandenburg 1983 (19)	Age 32 [2 months–50], 72% M <sup>2</sup>	17	28	8	47	2
Chan 1999 (20)	Age 62±14, 72% M (BAV)	14	36	3	62	3
	Non-diagnostic TTE included	–	36	31	62	46
Tanaka 2010 (21)	Age 70 [43–83], 46% M	16	13	4	20	13
Joziasse 2011 (13)	Age 68.5 [56.5–74], 68% M <sup>3</sup>	14	6	5	21	2
Lee 2012 (22)	Age 53.6 [20–97], 58% M	19	171	3	66	9
Malaisrie 2012 (23)	Age 56.2±15.1 [21–86], 76% M	19	76	12	64	3
	Non-diagnostic TTE included	–	76	47	64	31
Takeda 2013 (24)	Age 70.3±70.8	8 <sup>4</sup>	25	4	86	11
Yousry 2015 (25)	Age 63.9±11.6, 70% M	18	75	23	58	13

Age, given as mean years of age ± standard deviation (range in years). <sup>1</sup>Only 5 individuals had surgical confirmation of aortic valve configuration, but all underwent selective aortic root angiography for confirmation; <sup>2</sup>29 non-diagnostic TTE excluded; <sup>3</sup>inclusion only of individuals with stenotic aortic valves; <sup>4</sup>STARD quality score was assessed only based on the abstract of the publication. TTE, transthoracic echocardiography; BAV, bicuspid aortic valve; M, males.

**Table 2** Patient characteristics

Characteristic	Tricuspid aortic valve (N=108) [%]	Bicuspid aortic valve (N=108) [%]	P value*
Age (years)	69±11	55±14	<0.001
Male sex	53 [49]	79 [73]	<0.001
Body weight (kg)	81±17	82±15	0.418
Body height (m)	1.7±0.1	1.76±0.1	<0.001
Body mass index (kg/m <sup>2</sup> )	28±5	26±5	0.073
Body surface area (m <sup>2</sup> )	1.91±0.21	1.98±0.21	0.039
TTE performed at our institution	89 [82]	85 [79]	0.606
Availability of original TTE recordings	86 [80]	72 [67]	0.045
Indication for valve surgery			0.038
Aortic valve stenosis	69 [64]	54 [50]	–
Aortic valve regurgitation	23 [21]	40 [37]	–
Mixed aortic valve dysfunction	16 [15]	14 [13]	–
Aortic aneurysm	11 [10]	47 [44]	<0.001
Severe aortic valve calcification	64 [59]	57 [53]	0.411
Anatomical type of BAV			
BAV type 1	0	34 [32]	–
BAV type 2 or 3	0	8 [7]	–
Assessment not available	0	66 [61]	–

N, number of persons examined with TTE. \*Kruskal-Wallis test for continuous data and the generalized Fisher's exact test for nominal and categorical data. TTE, transthoracic echocardiography; BAV, bicuspid aortic valve.

**Table 3** Diagnostic results of TTE for BAV in two diagnostic groups

Diagnostic results of TTE for BAV	Group I: results based on original evaluation (N=216)	Group II: results on re-evaluation (N=158)
Number of findings		
True positive	50	43
False negative	58	29
True negative	105	80
False positive	3	6
Proportion estimates (95% CI)		
Sensitivity*	0.463 (0.369–0.557)	0.597 (0.484–0.711)
Specificity <sup>#</sup>	0.972 (0.941–1.003)	0.930 (0.876–0.984)
Accuracy	0.718 (0.658–0.778)	0.778 (0.714–0.843)
Positive LR	16.667 (5.362–51.807)	8.560 (3.867–18.951)
Negative LR	0.552 (0.462–0.660)	0.433 (0.325–0.577)

For statistical comparison of both groups (I) and (II), we analyzed only those 158 individuals with availability of original TTE recordings: \*sensitivity was higher on (I) re-evaluation than on (II) primary documentation ( $P<0.001$ ); <sup>#</sup>specificity was similar in both groups ( $P=0.07$ ). TTE, transthoracic echocardiography; BAV, bicuspid aortic valve; N, number of persons examined with TTE; 95% CI, 95% confidence interval calculated with the modified Wald method; LR, likelihood ratio.

**Table 4** Clinical predictors of correct diagnosis in 216 individuals

Characteristics	Diagnosis of BAV [%]		Odds ratio	Odds ratio (95% CI)		P <sup>§</sup>
	True* (N=155)	False <sup>#</sup> (N=61)		Upper	Lower	
Age (years)	63±15	61±13	1.006	0.985	1.026	0.596
Male sex	91 [59]	41 [67]	0.694	0.372	1.293	0.250
Body weight (kg)	82±16	82±15	0.997	0.979	1.016	0.775
Body height (m)	1.73±0.09	10.74±0.09	0.274	0.012	6.094	0.414
Body mass index (kg/m <sup>2</sup> )	27±6	27±4	0.999	0.945	1.057	0.984
Body surface area (m <sup>2</sup> )	1.95±0.21	10.97±0.21	0.657	0.158	2.728	0.563
TTE performed at our tertiary center	131 [85]	43 [71]	2.285	1.133	4.608	0.021
Indication for valve surgery						
Aortic valve stenosis	83 [54]	40 [66]	–	–	–	0.234
Aortic valve regurgitation	50 [32]	13 [21]	1.854	0.905	3.798	0.092
Mixed aortic valve dysfunction	22 [14]	8 [13]	1.325	0.543	3.236	0.536
Aortic aneurysm	33 [21]	25 [41]	0.390	0.206	0.738	0.004
Severe aortic valve calcification	78 [50]	43 [71]	0.424	0.225	0.799	0.008

\*True positive or true negative diagnosis of BAV; <sup>#</sup>false positive or false negative diagnosis of BAV; <sup>§</sup>univariate logistic regression analysis. BAV, bicuspid aortic valve; CI, confidence interval; N, number of persons examined with TTE; TTE, transthoracic echocardiography.

We used forest plots to display the results of meta-analysis where we computed 95% CIs, weight of studies and pooled sensitivity and specificity. We used IBM-SPSS software (IBM Corp. Released 2013. IBM SPSS Statistics for Windows, Version 22.0. Armonk, NY, USA: IBM Corp) for all statistical tests, with the exception of meta-analysis including Forest plots, where we used Stata, version 14 (StataCorp, College Station, Texas, USA).

## Results

### Patients

This study included 108 adults with BAV and 108 adults with TAV. The indication for aortic valve replacement surgery was isolated or predominant stenosis in 123 (56.9%), isolated or predominant regurgitation in 63 (29.2%), and mixed stenosis and regurgitation in 30 individuals (13.9%). At surgery, BAVs exhibited type 1 morphology in 32%, type 2 or type 3 in 7%. Individuals with BAV were younger, they were predominantly male, and they had larger body surface area as compared to their tricuspid counterparts. Moreover, proximal aortic aneurysm was more common in the BAV group (*Table 2*).

### Diagnostic accuracy

In the (I) group of 216 individuals with diagnoses based on original records of primary investigators, the sensitivity was 46.3%, the specificity was 97.2%, the accuracy was 71.8%, the positive likelihood ratio was 16.667, and the negative likelihood ratio was 0.552. In the (II) group of 158 individuals with availability of original TTE recordings, expert re-evaluation yielded a sensitivity of 59.7%, a specificity of 93%, an accuracy of 77.8%, a positive likelihood ratio of 8.560, and a negative likelihood ratio of 0.433. The sensitivity was higher on (II) re-evaluation than on (II) primary documentation ( $P<0.001$ ), but the specificity was similar in both groups ( $P=0.07$ , *Table 3*).

### Predictors of incorrect diagnosis

Univariate analysis did not identify an impact of age, sex, body weight, body height, body mass index, body surface area, or the type of indication for aortic valve surgery on the accuracy of routine TTE for BAV. However, multivariate analysis identified as independent predictors of incorrect diagnosis of BAV a TTE performed at a non-tertiary care

center [odds ratio (OR) 2.587, 95% CI, 1.228–5.453;  $P=0.012$ ], presence of aortic aneurysm (OR 0.305, 95% CI, 0.153–0.607;  $P=0.001$ ) and presence of severe aortic valve calcification (OR 0.363, 95% CI, 0.185–0.711;  $P=0.003$ ; *Table 4*).

### Systematic review and meta-analysis

Our systematic review identified nine studies that qualified for inclusion in the meta-analysis (*Table 1*). The meta-analysis of these nine studies identified a pooled sensitivity of 87.7% (95% CI, 85.0–90.5%; *Figure 3*) and a pooled specificity of 88.3% (95% CI, 85.6–90.9%; *Figure 4*). Of these nine studies two additionally presented diagnostic accuracy of TTE with inclusion of non-diagnostic TTE images (*Table 1*). We considered the results from these two studies in a separate meta-analysis to assess the diagnostic accuracy of TTE including non-diagnostic TTE results. In the analysis of these two studies we included our own results with expert re-evaluation of TTE recordings. The pooled sensitivity of these three studies for BAV was 59.2% (95% CI, 53.2–65.1%; *Figure 5*) and the pooled specificity was 71.3% (95% CI, 66.4–76.2%; *Figure 6*).

## Discussion

### Main results

The study showed that the primary investigators' sensitivity of routine echocardiography for BAV was only 46.3%. The sensitivity was significantly higher with expert re-evaluation of original TTE recordings, but with 59.7% it still remained suboptimal. The probability of an inaccurate diagnosis of BAV increased with TTE performed at a non-tertiary care center, with presence of an aortic aneurysm and with presence of severe aortic valve calcification. In contrast to these findings the meta-analysis of previously published studies demonstrated a high pooled sensitivity of 87.7%. However, a sub-analysis of published studies with inclusion of suboptimal diagnostic results yielded a pooled sensitivity of only 59.2%.

### Low sensitivity of routine echocardiography

Classical studies of the diagnostic accuracy of TTE suggested a high sensitivity of up to 100% for BAV (18,22). However, these studies were performed at tertiary care centers, with careful selection of patients according to age, adequate image quality, absence of previous surgery

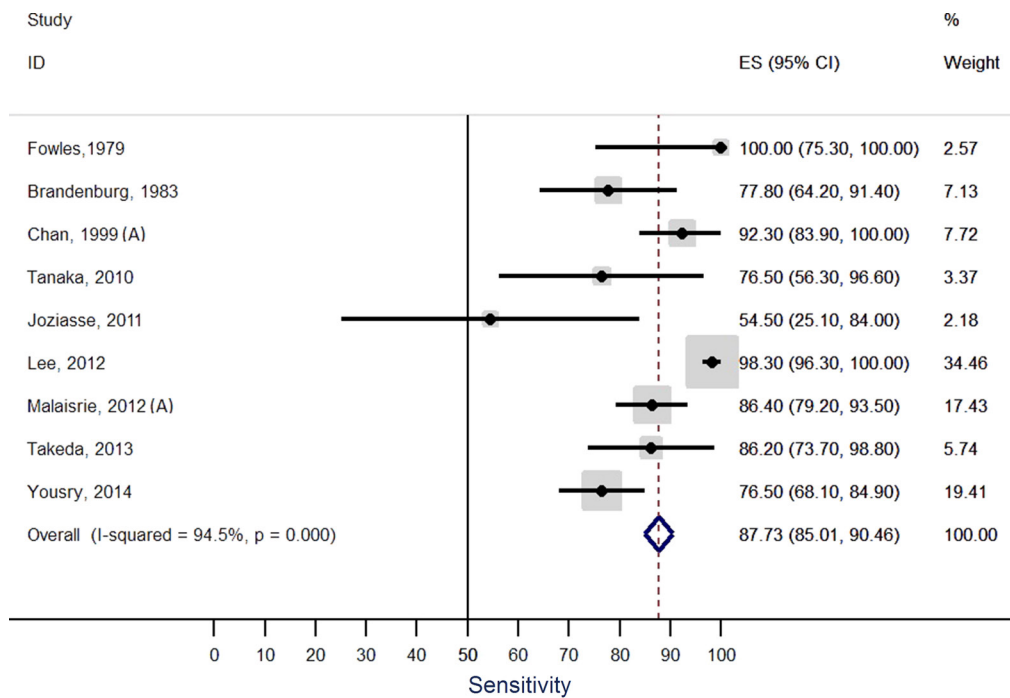


Figure 3 Forest plot of the sensitivity of transthoracic echocardiography reported in nine studies.

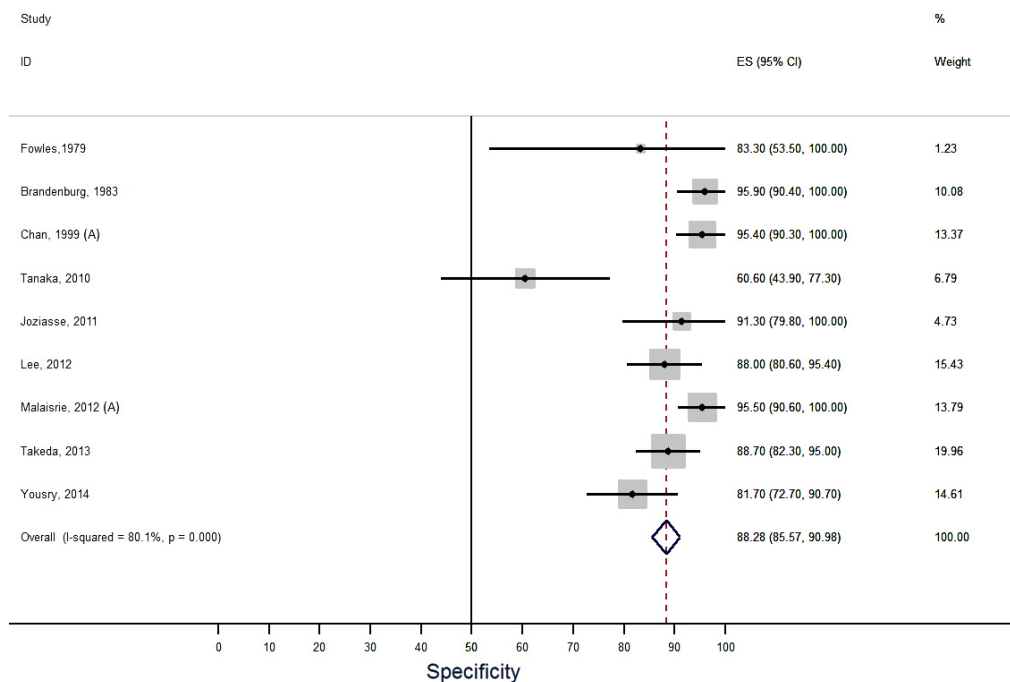
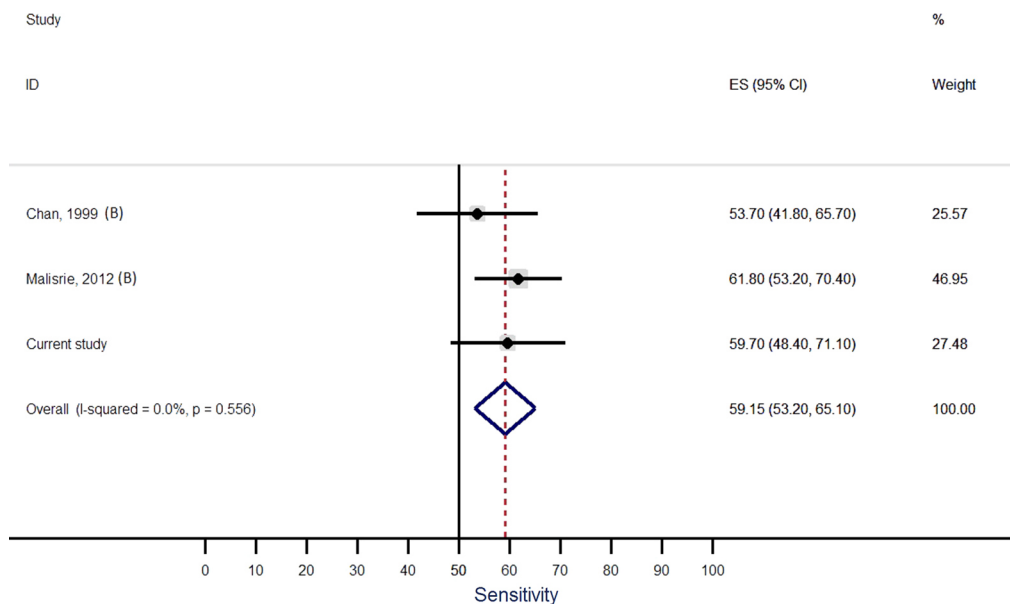
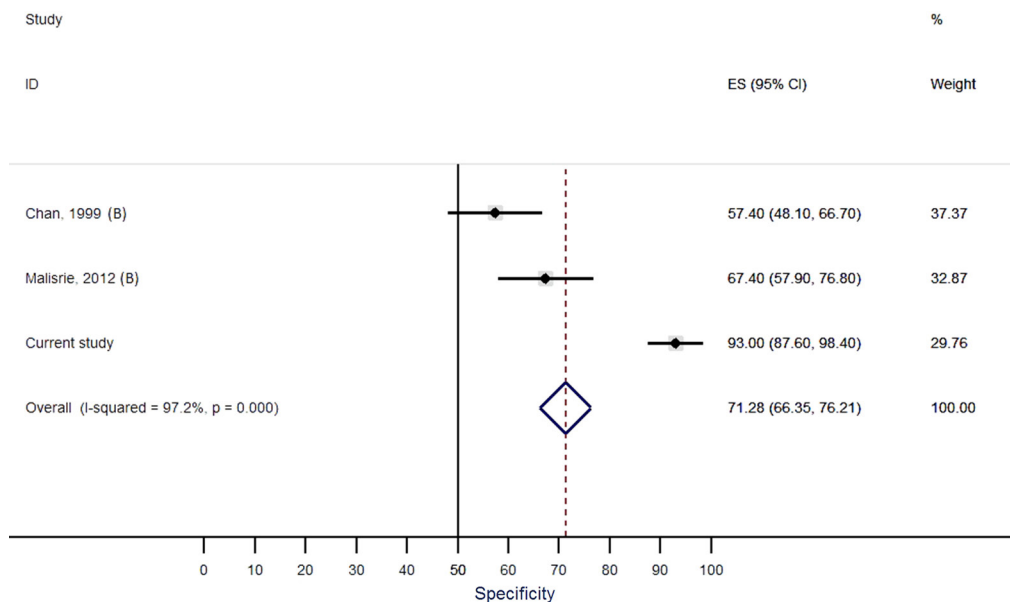


Figure 4 Forest plot of the specificity of transthoracic echocardiography reported in nine studies.





**Figure 5** Forest plot of the sensitivity of transthoracic echocardiography (TTE) reported in three studies comprising the current study, with inclusion of results from TTE with a technical quality that precluded a firm statement on the presence of absence of a bicuspid or a tricuspid aortic valve.



**Figure 6** Forest plot of the specificity of transthoracic echocardiography (TTE) reported in three studies comprising the current study, with inclusion of results from TTE with a technical quality that precluded a firm statement on the presence of absence of a bicuspid or a tricuspid aortic valve.

or intervention, and with expert readers who jointly evaluated images for presence of BAV (18-22). Conversely, we aimed at assessing the diagnostic accuracy of primary investigators during routine echocardiography. Our results reflect the diagnostic performance in a wide spectrum of referring institutions, with investigators at different levels of experience and expertise, and with a varying awareness of BAV as a relevant underlying pathology of aortic valve dysfunction. Moreover, routine conditions in process-optimized clinical settings today include time constraints that discourage detailed investigations and profound discussions of diagnostic findings (28,29). Therefore, the low sensitivity of only 46.3% was not surprising, but rather underpinned that TTE is an investigator-dependent diagnostic tool.

The current study showed that the sensitivity increased significantly when experts re-evaluated the original TTE recordings. Classical studies support the importance of being an expert to exploit the diagnostic potential of TTE (30). In addition, recent studies documented the role of training and experience to increase cognitive knowledge and psychomotor skills for echocardiography (31,32). However, with 59.7% the sensitivity of expert re-evaluation still remained below optimal study results (18,22). The most likely explanation for these suboptimal results of our expert re-evaluation was the suboptimal interpretability of images, where multiple factors are known to contribute. On the one hand, unpreventable patient-related factors are known to play an important role. It is clear that patients with obesity, chest wall deformities, narrow intercostal spaces and pulmonary emphysema yield suboptimal imaging quality. On the other hand, suboptimal imaging quality may have resulted from preventable investigator-related factors. Such factors include sub-optimal positioning of the patient, sub-optimal angulation of the ultrasound probe, incomplete assessment of all aortic valve cusp structures, and incomplete use of all available views, imaging modalities and software options. The important role of experience to assess interpretable images was documented recently for focused cardiac ultrasound (32).

### High specificity of routine echocardiography

In contrast to the relatively low sensitivity to diagnose BAV, routine TTE yielded a relatively high specificity of 97.2% for excluding BAV. This high specificity was even higher than the pooled specificity of 88.3% in our meta-analysis. We suggest that the low rate of false positive diagnoses of BAV in our routine TTE examinations resulted at

least in part from investigators who may not have actively considered BAV when describing "TAV". Indeed, in the present study the specificity dropped to 93% with expert re-evaluation. The experts yielded a higher number of false positive findings most likely because of their deliberate search for BAV.

### Predictors of inaccurate diagnosis

In this study we aimed at identifying factors that predicted an inaccurate diagnosis of BAV on routine evaluation. We did not identify an impact of age, sex, body weight, body height, body mass index, and body surface area on diagnostic accuracy. Conversely, TTE was less accurate when performed at non-tertiary care centers. This finding may suggest an impact of specialization on echocardiographic results. Moreover, when an ascending aortic aneurysm was present the accuracy for BAV was lower. This is surprising, since aortopathy is a well-known marker of BAV (1,2,33). Strictly speaking, the association seems to reflect some type of diagnostic error (34). Such error may be based in a lack of medical knowledge as unawareness of aortopathy as hallmark of BAV. Alternatively, the error may result from cognitive bias such as anchoring. The investigator has an initial impression, such as: "This routine patient simply has a severe aortic stenosis". Anchoring happens, when the investigator disqualifies subsequent information as corroboration of his initial impression, for example he may think: "There is an aneurysm. This is a post-stenotic dilatation that corroborates my initial diagnosis of severe aortic stenosis" (29).

The diagnosis of BAV was less accurate with severe aortic valve calcification. The negative relationship of aortic valve calcification and echocardiographic detection of BAV has been documented previously (25). The most likely reason is that calcified masses can overly and erode the aortic valve anatomy and thereby conceal the underlying cusp structure. Finally, Brandenburg *et al.* pointed out in their classical study of TTE for BAV that in diastole a raphe in BAV may appear like a commissure of TAV (19). Therefore, BAV without a raphe may be easier to diagnose than BAV with a raphe (4). Unfortunately, most of our intraoperative descriptions of the aortic valve did not explicitly exclude presence of a raphe. Similarly, the studies included in our meta-analysis did not investigate the impact of a raphe on the diagnostic accuracy of BAV.

### Meta-analysis

The meta-analysis of previously published studies

demonstrated a pooled sensitivity of 87.7% for BAV which was significantly higher than in the current study. These series utilized an “idealized” design to assess the best possible diagnostic results rather than that they aimed at assessing the diagnostic results under routine conditions. However, we performed a sub-analysis of published studies that included results from echocardiographic examinations with limited diagnostic quality. This sub-analysis yielded a pooled sensitivity of only 59.2%. This sensitivity was almost identical to the sensitivity that we obtained from re-evaluation of routine TTE recordings. Therefore, this meta-analysis supports the view that TTE yields almost ideal diagnostic accuracy when ideal investigators examine ideal patients. However, the meta-analysis also provides evidence that TTE yields suboptimal diagnostic accuracy when non-expert investigators examine patients who exhibit suboptimal conditions for transthoracic examination.

### Study limits

Our study aimed at assessing the diagnostic accuracy of TTE for diagnosing BAV in a routine clinical setting. For matching individuals with BAV, we were unable to identify individuals with TAV who were as young as those with BAV. Despite some age differences between the BAV and the TAV group logistic regression analysis excluded an impact of age on the accuracy of TTE. Moreover, we focused on a surgical patient cohort, and by doing so, we selected only patients with a severe aortic valve dysfunction. By this design, we also excluded inoperable individuals with severe obesity, marked lung diseases or major chest wall deformities and therefore diagnostic accuracy may have been biased towards individuals with fair transthoracic imaging conditions. These limitations also applied to the studies which we included in our meta-analysis. All studies for meta-analysis including our own study relied on surgical inspection as reference standard to distinguish BAV from TAV. However, even though surgical inspection is widely accepted as standard of reference, some studies suggest that diagnoses can differ between surgeon and pathologist, where the quality of both diagnoses may depend on the awareness and experience of individual investigators (13,35).

### Conclusions

The current study shows that TTE yields almost ideal diagnostic accuracy when ideal investigators examine ideal patients in ideal settings. However, the study also shows that

TTE yields suboptimal diagnostic accuracy under routine conditions. Echocardiography in non-tertiary care settings, concomitant aortic aneurysm, and presence of severe aortic valve calcification predict an inaccurate diagnosis of BAV.

For the optimal exploit of the diagnostic potential of TTE for BAV a broader approach to improve the setting of routine evaluation appears necessary. The discourse of diagnostic accuracy in clinical routine settings provides an innovative opportunity to connect the scientific discourse of diagnostic accuracy studies (17) with the scientific discourse of reducing diagnostic errors (29,34,36). Such connection of discourses may open alleys to develop improved concepts for optimal use of imaging modalities in routine settings.

### Acknowledgements

None.

### Footnote

*Conflicts of Interest:* The authors have no conflicts of interest to declare.

*Ethical Statement:* Given the retrospective, observational study design and anonymous data analysis, the Hamburg review board waived the requirement of individual patient consent and ethical approval.

### References

1. von Kodolitsch Y, Kaemmerer H. Bicuspid aortic valve. In: Niwa K, Kaemmerer H. editors. Aortopathy. Tokyo: Springer Japan, 2017:229-56.
2. Girdauskas E, Borger MA. Bicuspid aortic valve and associated aortopathy: an update. *Semin Thorac Cardiovasc Surg* 2013;25:310-6.
3. Schaefer BM, Lewin MB, Stout KK, et al. The bicuspid aortic valve: an integrated phenotypic classification of leaflet morphology and aortic root shape. *Heart* 2008;94:1634-8.
4. Kang JW, Song HG, Yang DH, et al. Association between bicuspid aortic valve phenotype and patterns of valvular dysfunction and bicuspid aortopathy: comprehensive evaluation using MDCT and echocardiography. *JACC Cardiovasc Imaging* 2013;6:150-61.
5. Tzemos N, Therrien J, Yip J, et al. Outcomes in adults with bicuspid aortic valves. *JAMA* 2008;300:1317-25.
6. Nishimura RA, Otto CM, Bonow RO, et al. 2014 AHA/

- ACC guideline for the management of patients with valvular heart disease: a report of the American College of Cardiology/American Heart Association Task Force on Practice Guidelines. *J Thorac Cardiovasc Surg* 2014;148:e1-132.
7. Nanda NC, Gramiak R, Manning J, et al. Echocardiographic recognition of the congenital bicuspid aortic valve. *Circulation* 1974;49:870-5.
  8. Moher D, Liberati A, Tetzlaff J, et al. Preferred Reporting Items for Systematic Reviews and Meta-Analyses: The PRISMA Statement. *PLoS Med* 2009;6:e1000097.
  9. Mookadam F, Thota VR, Lopez AM, et al. Unicuspid aortic valve in children: a systematic review spanning four decades. *J Heart Valve Dis* 2010;19:678-83.
  10. Khan SK, Tamin SS, Araoz PA. Quadricuspid aortic valve by cardiac magnetic resonance imaging: a case report and review of the literature. *J Comput Assist Tomogr* 2011;35:637-41.
  11. Angelini A, Ho SY, Anderson RH, et al. The morphology of the normal aortic valve as compared with the aortic valve having two leaflets. *J Thorac Cardiovasc Surg* 1989;98:362-7.
  12. Nistri S, Basso C, Marzari C, et al. Frequency of bicuspid aortic valve in young male conscripts by echocardiogram. *Am J Cardiol* 2005;96:718-21.
  13. Joziassse IC, Vink A, Cramer MJ, et al. Bicuspid stenotic aortic valves: clinical characteristics and morphological assessment using MRI and echocardiography. *Neth Heart J* 2011;19:119-25.
  14. Du Bois D, Du Bois EF. A formula to estimate the approximate surface area if height and weight be known. *Nutrition* 1989;5:303-11; discussion 12-3.
  15. Rosenhek R, Binder T, Porenta G, et al. Predictors of outcome in severe, asymptomatic aortic stenosis. *N Engl J Med* 2000;343:611-7.
  16. Yousry M, Rickenlund A, Petrini J, et al. Real-time imaging required for optimal echocardiographic assessment of aortic valve calcification. *Clin Physiol Funct Imaging* 2012;32:470-5.
  17. Bossuyt PM, Reitsma JB, Bruns DE, et al. Towards complete and accurate reporting of studies of diagnostic accuracy: The STARD Initiative. *Ann Intern Med* 2003;138:40-4.
  18. Fowles RE, Martin RP, Abrams JM, et al. Two-dimensional echocardiographic features of bicuspid aortic valve. *Chest* 1979;75:434-40.
  19. Brandenburg RO Jr, Tajik AJ, Edwards WD, et al. Accuracy of 2-dimensional echocardiographic diagnosis of congenitally bicuspid aortic valve: echocardiographic-anatomic correlation in 115 patients. *Am J Cardiol* 1983;51:1469-73.
  20. Chan KL, Stinson WA, Veinot JP. Reliability of transthoracic echocardiography in the assessment of aortic valve morphology: pathological correlation in 178 patients. *Can J Cardiol* 1999;15:48-52.
  21. Tanaka R, Yoshioka K, Niinuma H, et al. Diagnostic value of cardiac CT in the evaluation of bicuspid aortic stenosis: comparison with echocardiography and operative findings. *AJR Am J Roentgenol* 2010;195:895-9.
  22. Lee SC, Ko SM, Song MG, et al. Morphological assessment of the aortic valve using coronary computed tomography angiography, cardiovascular magnetic resonance, and transthoracic echocardiography: comparison with intraoperative findings. *Int J Cardiovasc Imaging* 2012;28 Suppl 1:33-44.
  23. Malaisrie SC, Carr J, Mikati I, et al. Cardiac magnetic resonance imaging is more diagnostic than 2-dimensional echocardiography in determining the presence of bicuspid aortic valve. *J Thorac Cardiovasc Surg* 2012;144:370-6.
  24. Takeda H, Muro T, Saito T, et al. Diagnostic accuracy of transthoracic and transesophageal echocardiography for the diagnosis of bicuspid aortic valve: comparison with operative findings. *Osaka City Med J* 2013;59:69-78.
  25. Yousry M, Rickenlund A, Petrini J, et al. Aortic valve type and calcification as assessed by transthoracic and transoesophageal echocardiography. *Clin Physiol Funct Imaging* 2015;35:306-13.
  26. Jaeschke R, Guyatt G, Lijmer J. Diagnostic tests. In: Guyatt G, Rennie D. editors. *Users' guides to the medical literature*. Chicago: AMA Press, 2002.
  27. Clopper CJ, Pearson ES. The use of confidence or fiducial limits illustrated in the case of the binomial. *Biometrika* 1934;26:404-13.
  28. von Kodolitsch Y, Bernhardt AM, Kölbl T, et al. Maximizing therapeutic success: The key concepts of individualized medical strategy (IMS). *Cogent Medicine* 2015;2:1109742.
  29. Lee CS, Nagy PG, Weaver SJ, et al. Cognitive and system factors contributing to diagnostic errors in radiology. *AJR Am J Roentgenol* 2013;201:611-7.
  30. Picano E, Lattanzi F, Orlandini A, et al. Stress echocardiography and the human factor: the importance of being expert. *J Am Coll Cardiol* 1991;17:666-9.
  31. Montealegre-Gallegos M, Mahmood F, Kim H, et al. Imaging skills for transthoracic echocardiography in cardiology fellows: The value of motion metrics. *Ann Card*

- Anaesth 2016;19:245-50.
32. Bobbia X, Pradeilles C, Claret PG, et al. Does physician experience influence the interpretability of focused echocardiography images performed by a pocket device? *Scand J Trauma Resusc Emerg Med* 2015;23:52.
  33. Girdauskas E, Rouman M, Disha K, et al. Morphologic and Functional Markers of Aortopathy in Patients With Bicuspid Aortic Valve Insufficiency Versus Stenosis. *Ann Thorac Surg* 2017;103:49-57.
  34. Graber M, Gordon R, Franklin N. Reducing diagnostic errors in medicine: what's the goal? *Acad Med* 2002;77:981-92.
  35. Roberts WC, Vowels TJ, Ko JM. Comparison of interpretations of valve structure between cardiac surgeon and cardiac pathologist among adults having isolated aortic valve replacement for aortic valve stenosis (+/- aortic regurgitation). *Am J Cardiol* 2009;103:1139-45.
  36. Croskerry P. The importance of cognitive errors in diagnosis and strategies to minimize them. *Acad Med* 2003;78:775-80.

**Cite this article as:** Hillebrand M, Koschyk D, ter Hark P, Schüler H, Rybczynski M, Berger J, Gulati A, Bernhardt AM, Detter C, Girdauskas E, Blankenberg S, von Kodolitsch Y. Diagnostic accuracy study of routine echocardiography for bicuspid aortic valve: a retrospective study and meta-analysis. *Cardiovasc Diagn Ther* 2017;7(4):367-379. doi: 10.21037/cdt.2017.05.03

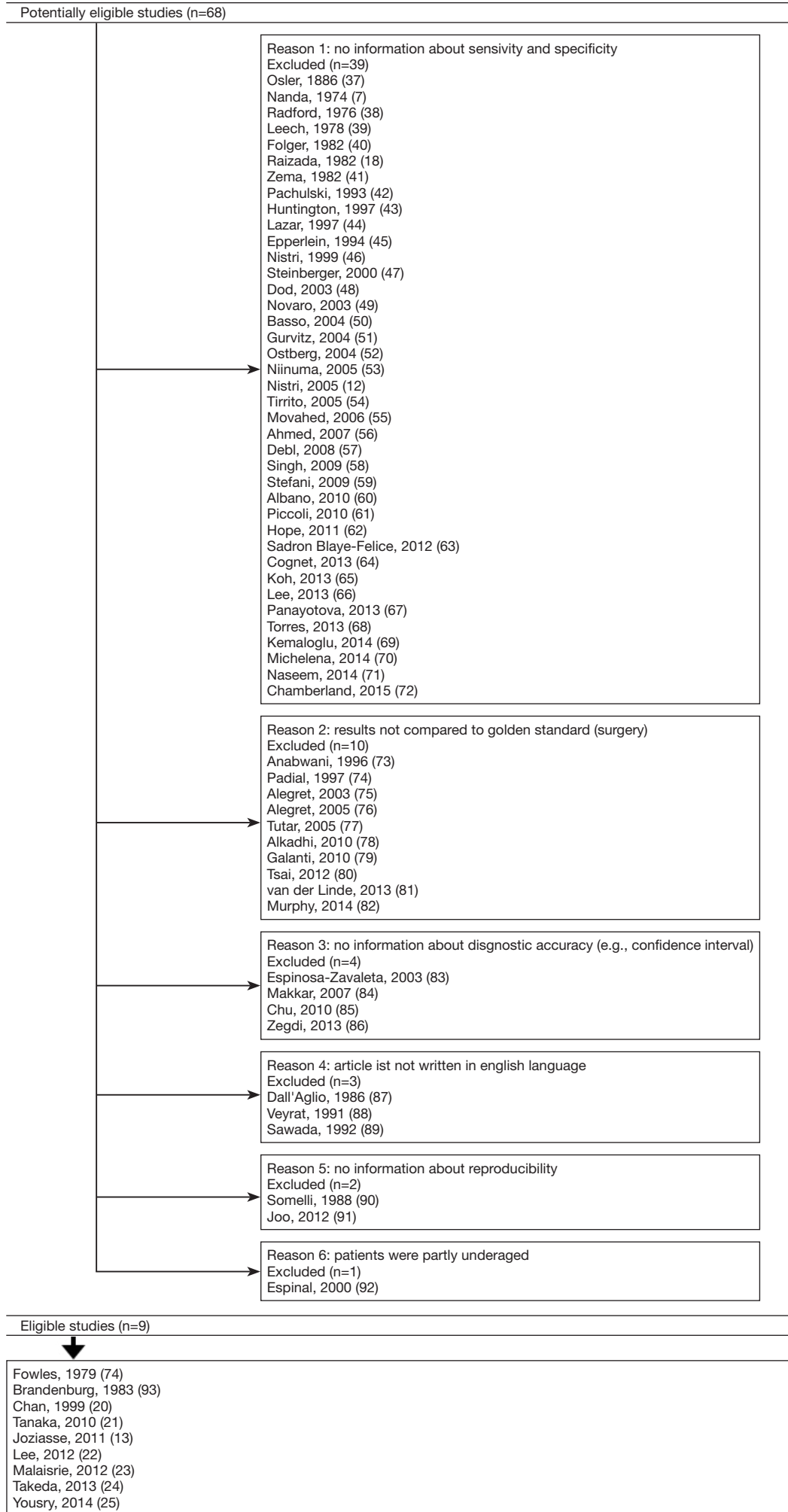


Figure S1 PRISMA (7,12,13,18,20-25,37-47) 2009 (48-67) flow (68-87) diagram (74,88-93).

## References

37. Osler W. The bicuspid condition of the aortic valves. *Trans Assoc Am Physicians* 1886;2:185-92.
38. Radford DJ, Bloom KR, Izukawa T, et al. Echocardiographic assessment of bicuspid aortic valves. Angiographic and pathological correlates. *Circulation* 1976;53:80-5.
39. Leech G, Mills P, Leatham A. The diagnosis of a non-stenotic bicuspid aortic valve. *Br Heart J* 1978;40:941-50.
40. Folger GM Jr, Alam M, Stein PD. M-mode echocardiographic failure to consistently identify the equally bicuspid aortic valve: correlation with orifice-view aortography. *Angiology* 1982;33:111-8.
41. Zema MJ, Caccavano M. Two dimensional echocardiographic assessment of aortic valve morphology: feasibility of bicuspid valve detection. Prospective study of 100 adult patients. *Br Heart J* 1982;48:428-33.
42. Pachulski RT, Chan KL. Progression of aortic valve dysfunction in 51 adult patients with congenital bicuspid aortic valve: assessment and follow up by Doppler echocardiography. *Br Heart J* 1993;69:237-40.
43. Huntington K, Hunter AG, Chan KL. A prospective study to assess the frequency of familial clustering of congenital bicuspid aortic valve. *J Am Coll Cardiol* 1997;30:1809-12.
44. Lazar JM, Smith RH, Scott WC. Intraoperative evaluation of a bicuspid aortic valve. *Journal of Cardiothoracic and Vascular Anesthesia* 1997;11:253-5.
45. Epperlein S, Mohr-Kahaly S, Erbel R, et al. Aorta and aortic valve morphologies predisposing to aortic dissection. An in vivo assessment with transoesophageal echocardiography. *Eur Heart J* 1994;15:1520-7.
46. Nistri S, Sorbo MD, Marin M, et al. Aortic root dilatation in young men with normally functioning bicuspid aortic valves. *Heart* 1999;82:19-22.
47. Steinberger J, Moller JH, Berry JM, et al. Echocardiographic diagnosis of heart disease in apparently healthy adolescents. *Pediatrics* 2000;105:815-8.
48. Dod HS, Nanda NC, Agrawal GG, et al. Three-dimensional transesophageal echocardiographic assessment of aortic valve pathology. *Am J Geriatr Cardiol* 2003;12:209-13.
49. Novaro GM, Mishra M, Griffin BP. Incidence and echocardiographic features of congenital unicuspid aortic valve in an adult population. *J Heart Valve Dis* 2003;12:674-8.
50. Basso C, Boschello M, Perrone C, et al. An echocardiographic survey of primary school children for bicuspid aortic valve. *Am J Cardiol* 2004;93:661-3.
51. Gurvitz M, Chang RK, Drant S, et al. Frequency of aortic root dilation in children with a bicuspid aortic valve. *Am J Cardiol* 2004;94:1337-40.
52. Ostberg JE, Brookes JA, McCarthy C, et al. A comparison of echocardiography and magnetic resonance imaging in cardiovascular screening of adults with Turner syndrome. *J Clin Endocrinol Metab* 2004;89:5966-71.
53. Niinuma H, Yoshioka K, Ogino Y, et al. Three-dimensional demonstration of bicuspid aortic valve by 16-row multidetector computed tomography: comparison with transesophageal echocardiography. *Eur J Cardiothorac Surg* 2005;27:346.
54. Tirrito SJ, Kerut EK. How not to miss a bicuspid aortic valve in the echocardiography laboratory. *Echocardiography* 2005;22:53-5.
55. Movahed MR, Hepner AD, Ahmadi-Kashani M. Echocardiographic prevalence of bicuspid aortic valve in the population. *Heart Lung Circ* 2006;15:297-9.
56. Ahmed S, Honos GN, Walling AD, et al. Clinical outcome and echocardiographic predictors of aortic valve replacement in patients with bicuspid aortic valve. *J Am Soc Echocardiogr* 2007;20:998-1003.
57. Debl K, Djavidani B, Buchner S, et al. Unicuspid aortic valve disease: a magnetic resonance imaging study. *Rofo* 2008;180:983-7.
58. Singh P, Dutta R, Nanda NC. Live/real time three-dimensional transthoracic echocardiographic assessment of bicuspid aortic valve morphology. *Echocardiography* 2009;26:478-80.
59. Stefani L, De Luca A, Maffulli N, et al. Speckle tracking for left ventricle performance in young athletes with bicuspid aortic valve and mild aortic regurgitation. *Eur J Echocardiogr* 2009;10:527-31.
60. Albano AJ, Mitchell E, Pape LA. Standardizing the method of measuring by echocardiogram the diameter of the ascending aorta in patients with a bicuspid aortic valve. *Am J Cardiol* 2010;105:1000-4.
61. Piccoli G, Slavich G, Gianfagna P, et al. Cardiovascular flashlight. Cleft bicuspid aortic valve: the Achilles' heel of echocardiography? *Eur Heart J* 2010;31:2140.
62. Hope MD, Hope TA, Crook SE, et al. 4D flow CMR in assessment of valve-related ascending aortic disease. *JACC Cardiovasc Imaging* 2011;4:781-7.
63. Sadron Blaye-Felice MA, Seguela PE, Arnaudis B, et al. Usefulness of three-dimensional transthoracic echocardiography for the classification of congenital bicuspid aortic valve in children. *Eur Heart J Cardiovasc Imaging* 2012;13:1047-52.
64. Cognet T, Seguela PE, Thomson E, et al. Assessment

- of valvular surfaces in children with a congenital bicuspid aortic valve: preliminary three-dimensional echocardiographic study. *Arch Cardiovasc Dis* 2013;106:295-302.
65. Koh TW. Diagnosis of bicuspid aortic valve: role of three-dimensional transesophageal echocardiography and multiplane review analysis. *Echocardiography* 2013;30:360-3.
  66. Lee M, Sung J, Cho SJ, et al. Aortic dilatation and calcification in asymptomatic patients with bicuspid aortic valve: analysis in a Korean health screening population. *Int J Cardiovasc Imaging* 2013;29:553-60.
  67. Panayotova R, Macnab A, Waterworth PD. A pilot project of familial screening in patients with bicuspid aortic valve disease. *J Heart Valve Dis* 2013;22:150-5.
  68. Torres FS, Windram JD, Bradley TJ, et al. Impact of asymmetry on measurements of the aortic root using cardiovascular magnetic resonance imaging in patients with a bicuspid aortic valve. *Int J Cardiovasc Imaging* 2013;29:1769-77.
  69. Kemaloglu Oz T, Karadeniz FO, Gundlapalli H, et al. Coexisting bicuspid aortic and pulmonary valves with normally related great vessels diagnosed by live/real time three-dimensional transesophageal echocardiography. *Echocardiography* 2014;31:218-21.
  70. Michelena HI, Prakash SK, Della Corte A, et al. Bicuspid aortic valve: identifying knowledge gaps and rising to the challenge from the International Bicuspid Aortic Valve Consortium (BAVCon). *Circulation* 2014;129:2691-704.
  71. Naseem T, Song M, Ianchulev S, et al. The echocardiographic evaluation of a bicuspid aortic valve: the effect of jet eccentricity and left ventricular outflow tract geometry on the effective orifice area. *J Cardiothorac Vasc Anesth* 2014;28:423-7.
  72. Chamberland CR, Sugeng L, Abraham S, et al. Three-Dimensional Evaluation of Aortic Valve Annular Shape in Children With Bicuspid Aortic Valves and/or Aortic Coarctation Compared With Controls. *Am J Cardiol* 2015.
  73. Anabwani GM, Bonhoeffer P. Prevalence of heart disease in school children in rural Kenya using colour-flow echocardiography. *East Afr Med J* 1996;73:215-7.
  74. Padial LR, Oliver A, Sagie A, et al. Two-dimensional echocardiographic assessment of the progression of aortic root size in 127 patients with chronic aortic regurgitation: role of the supraaortic ridge and relation to the progression of the lesion. *Am Heart J* 1997;134:814-21.
  75. Alegret JM, Duran I, Palazon O, et al. Prevalence of and predictors of bicuspid aortic valves in patients with dilated aortic roots. *Am J Cardiol* 2003;91:619-22.
  76. Alegret JM, Palazon O, Duran I, et al. Aortic valve morphology definition with transthoracic combined with transesophageal echocardiography in a population with high prevalence of bicuspid aortic valve. *Int J Cardiovasc Imaging* 2005;21:213-7.
  77. Tutar E, Ekici F, Atalay S, et al. The prevalence of bicuspid aortic valve in newborns by echocardiographic screening. *Am Heart J* 2005;150:513-5.
  78. Alkadhi H, Leschka S, Trindade PT, et al. Cardiac CT for the differentiation of bicuspid and tricuspid aortic valves: comparison with echocardiography and surgery. *AJR Am J Roentgenol* 2010;195:900-8.
  79. Galanti G, Stefani L, Toncelli L, et al. Effects of sports activity in athletes with bicuspid aortic valve and mild aortic regurgitation. *Br J Sports Med* 2010;44:275-9.
  80. Tsai SF, Trivedi M, Daniels CJ. Comparing Imaging Modalities for Screening Aortic Complications in Patients with Bicuspid Aortic Valve. *Congenital Heart Disease* 2012;7:372-7.
  81. van der Linde D, Rossi A, Yap SC, et al. Ascending Aortic Diameters in Congenital Aortic Stenosis: Cardiac Magnetic Resonance versus Transthoracic Echocardiography. *Echocardiography* 2013;30:497-504.
  82. Murphy DJ, McEvoy SH, Iyengar S, et al. Bicuspid aortic valves: diagnostic accuracy of standard axial 64-slice chest CT compared to aortic valve image plane ECG-gated cardiac CT. *Eur J Radiol* 2014;83:1396-401.
  83. Espinola-Zavaleta N, Muñoz-Castellanos L, Attié F, et al. Anatomic three-dimensional echocardiographic correlation of bicuspid aortic valve. *Journal of the American Society of Echocardiography* 2003;16:46-53.
  84. Makkar A, Siddiqui TS, Stoddard MF, et al. Impact of Valvular Calcification on the Diagnostic Accuracy of Transesophageal Echocardiography for the Detection of Congenital Aortic Valve Malformation. *Echocardiography* 2007;24:745-9.
  85. Chu JW, Picard MH, Agnihotri AK, et al. Diagnosis of congenital unicuspid aortic valve in adult population: the value and limitation of transesophageal echocardiography. *Echocardiography* 2010;27:1107-12.
  86. Zegdi R, Ciobotaru V, Huerre C, et al. Detecting aortic valve bicuspidy in patients with severe aortic valve stenosis: high diagnostic accuracy of colour Doppler transoesophageal echocardiography. *Interactive Cardiovascular and Thoracic Surgery* 2013;16:16-20.
  87. Dall'Aglio V, Nicolosi GL, Burelli C, et al. Value and limitations of the echocardiographic definition of the bicuspid aortic valve. *G Ital Cardiol* 1986;16:155-61.
  88. Veyrat C, el Yafi W, Gourtchiglouian C, et al.



- Characteristics of jets in adult bicuspid aortic valve by color Doppler imaging. *Arch Mal Coeur Vaiss* 1991;84:1803-8.
89. Sawada H, Shibata Y, Shionoya M, et al. Echocardiographic assessment of aortic regurgitation and aortic root dilatation in bicuspid aortic valve. *J Cardiol* 1992;22:495-501.
  90. Somelli A, Carrino G, De Majo AM. A bicuspid aortic valve. Usefulness of echocardiography in its identification. *Minerva Cardioangiol* 1988;36:59-66.
  91. Joo I, Park EA, Kim KH, et al. MDCT differentiation between bicuspid and tricuspid aortic valves in patients with aortic valvular disease: correlation with surgical findings. *Int J Cardiovasc Imaging* 2012;28:171-82.
  92. Espinal M, Fuisz AR, Nanda NC, et al. Sensitivity and specificity of transesophageal echocardiography for determination of aortic valve morphology. *American Heart Journal* 2000;139:1071-6.
  93. Brandenburg RO Jr, Tajik AJ, Edwards WD, et al. Accuracy of 2-dimensional echocardiographic diagnosis of congenitally bicuspid aortic valve: echocardiographic-anatomic correlation in 115 patients. *Am J Cardiol* 1983;51:1469-73.