



12-2020

Longitudinally Extensive Transverse Myelitis and Neuromyelitis Optica spectrum Disorder: A Tertiary Care Centre Experience

Safia Bano

KEMU /Mayo hospital, Lahore Pakistan

Muhammad Athar Javed

KEMU /Mayo hospital, Lahore Pakistan

Ahsan Numan

KEMU /Mayo hospital, Lahore Pakistan

Follow this and additional works at: <https://ecommons.aku.edu/pjns>

 Part of the [Neurology Commons](#)

Recommended Citation

Bano, Safia; Javed, Muhammad Athar; and Numan, Ahsan (2020) "Longitudinally Extensive Transverse Myelitis and Neuromyelitis Optica spectrum Disorder: A Tertiary Care Centre Experience," *Pakistan Journal of Neurological Sciences (PJNS)*: Vol. 15 : Iss. 4 , Article 8.

Available at: <https://ecommons.aku.edu/pjns/vol15/iss4/8>

LONGITUDINALLY EXTENSIVE TRANSVERSE MYELITIS AND NEUROMYELITIS OPTICA SPECTRUM DISORDER: A TERTIARY CARE CENTRE EXPERIENCE

Safia bano¹, Muhammad Athar Javed², Ahsan Numan³

¹Assistant professor Neurology, KEMU /Mayo hospital, Lahore

²Professor Neurology (retired.), KEMU /Mayo hospital, Lahore

³Professor Neurology, KEMU /Mayo hospital, Lahore

Safia Bano, Assistant Professor Neurology, KEMU/Mayo Hospital, Lahore safiabano207@gmail.com

Date of submission: May 12, 2020 **Date of revision:** September 15, 2020 **Date of acceptance:** September 25, 2020

ABSTRACT

OBJECTIVE: To determine the frequency of longitudinally extensive transverse myelitis and Causes of longitudinally extensive transverse myelitis

METHODOLOGY: A Cross-Sectional, retrospective study was conducted at Neurology Department, Mayo Hospital, Lahore from 1st January 2015 to 31st December 2015. Patients were included from inpatient with history of weakness of lower limbs/all four limbs with or without visual disturbances. History and clinical examination was consistent with transverse myelitis. Neuroimaging (MRI brain, (orbit in case of optic neuritis) and spinal cord) was done followed by LP/CSF, Vasculitis screening.

RESULTS:

Total 37 patients of transverse myelitis (TM) (1287 patients were admitted in neurology department with various neurological disorders in study year) were enrolled in this study. Demographic data showed age distribution between 15-50 years. Out of 37 patients, LETM was present in 16 patients. They were predominantly females (62.5% versus 37.5% male) patients. With majority has normal MRI brain (93.8% versus 6.2% abnormal). Most common cause of LETM was Neuro Myelitis Optica (NMOSD) 93.8% versus 6.2% Multiple Sclerosis (MS).

CONCLUSION: Longitudinally extensive transverse myelitis (LETM) is not an uncommon disease, however, it remains under-diagnosed in our clinical practice due to either lack or cost of diagnostic facilities. LETM is common presentation of Neuromyelitis Optica Spectrum disorder (NMOSD) followed by multiple sclerosis, ADEM and other autoimmune diseases etc. Thus clinically important as it results in severe morbidity and patients are at risk of further attacks. Early diagnosis and confirmation of the underlying cause is vital in order to initiate appropriate therapy and favorable outcomes

KEYWORDS: Neuro Myelitis Optica Spectrum disorder (NMOSD), Longitudinally Extensive Transverse Myelitis (LETM), Multiple Sclerosis (MS), Sarcoidosis, lupus.

INTRODUCTION

Transverse myelitis is a clinical heterogeneous syndrome, causes inflammation of spinal cord that results in varying degree of residual disability.¹ The etiology of transverse myelitis is broad, it can be infectious (tuberculosis), inflammatory, vascular, neoplastic and paraneoplastic.^{2,17}

Transverse myelitis diagnosis is made on clinical history, examination findings, radiological, immunological and CSF analysis studies³ transverse myelitis causes florid inflammation of spinal cord and can lead to devastating

neurological deficit within minutes to hours.⁴

On imaging it shows involvement of one or more vertebral segments, if 3 or more vertebral segments are involved it is called longitudinal extensive transverse myelitis.⁵ Demyelinating disorders are the most common causes of acute transverse myelitis, main categories of acute inflammatory transverse myelitis includes multiple sclerosis, Neuromyelitis optica, Neuromyelitis optica spectrum disorders and idiopathic transverse myelitis.³

The differential diagnosis of LETM includes Multiple

sclerosis, Neuromyelitis optica spectrum disorder, vasculitis esp. Lupus (SLE), and sarcoidosis, acute disseminated encephalomyelitis, idiopathic and others.^{6,16}

A study from, E. Carnero Contentti, J.P. Hryb, et al, reported LETM being caused by NMOSD (37%), MS (3.7%) and other etiology as lupus (22.2%), idiopathic LETM (22.2%), tumor (11.1%) acute disseminated encephalomyelitis (7.4%), dural fistula (7.4%) etc.¹⁶. although several studies have been done worldwide but there is variability in the studies that are published. The results of this study will help us to understand the disease variability in our local cohort and it will open windows for newer research protocols and will set the priorities of the patient's treatment.

OBJECTIVES

- To find out the frequency of longitudinally extensive transverse myelitis.
- To find out the causes of longitudinally extensive transverse myelitis

METHODOLOGY

A Cross-Sectional, Retrospective study was conducted at Neurology Department, Mayo Hospital, Lahore from 1st January 2015 to 31st December 2015. Inclusion criteria was; all cases of Transverse Myelitis, Both genders, Age 15-60 years, MRI cervical or dorsal spine consistent.

Longitudinally extensive transverse myelitis (LETM) was defined as involvement of the spinal cord, with abnormal T2 signal on MRI with at least three or more vertebral body segments in length.

The patients were excluded if; Cases of compressive Myelopathy due to any cause (n-16), MRI consistent with patchy demyelization (n-5) rather than LETM, Age below 15 or above 60 years and MRI could not be done.

Patients were included from inpatient with history of weakness of lower limbs/all four limbs with or without visual disturbances. Clinically, history and examination was consistent with transverse myelitis and optic neuritis. Neuroimaging (MRI brain, (orbit in case of optic neuritis) and spinal cord) was done followed by LP/CSF (normal in all patients), vasculitis screening. Aquaporin -4 antibodies level could not be checked due to lack of availability and cost. For diagnosis of NMOSD/MS, Wingerchuk's criteria¹⁸ and modified McDonald's criteria¹⁹ was used.

RESULTS

Total 37 patients of transverse myelitis (TM) (1287 patients were admitted in neurology department with various neurological disorders in study year) were enrolled in this study. Out of 37 patients, 16 patient's neuroimaging was consistent with LETM. Demographical data showed age distribution between 15-50 years. Mean age of the patients was 27.3 ± 8.5 years (range 15-50 years).

Patients had longitudinally extensive transverse myelitis (LETM) i.e. 16. They were predominantly females 10(62.5%) versus 6(37.5%) males. Frequency distribution according to age is shown in table (Figure 1). With majority has normal MRI brain (93.8% versus 6.3% abnormal). Most common cause of LETM was Neuro Myelitis Optica spectrum disorder (NMOSD) 93.8% versus 6.2% Multiple Sclerosis (MS)(MRI brain was consistent with MS "dissemination in space criteria") MS figure 2.

According to episodes of myelitis distribution, 9(56.3%) had Myelitis and optic neuritis, while 4(25%), 2(12.5%) and 1(6.2%) had recurrent attack of myelitis(neuroimaging finding favor's), single attack of myelitis (anti aquaporin-4 antibodies was positive) and recurrent attack of optic neuritis with myelitis figure 3.

DISCUSSION

The most common cause of longitudinal extensive transverse myelitis is Neuromyelitis optica spectrum disorder (NMOSD).^{7,16} To reach the correct diagnosis and exact etiology of LETM is quite a challenging task. In our study most frequent cause for LETM found to be Neuromyelitis optica Spectrum disorder (NMOSD) 93.8% with female predominance 62.5%.

A study from, E. Carnero Contentti, J.P. Hryb, et al, reported LETM being caused by NMOSD (37%), MS (3.7%) and other etiology as lupus (22.2%), idiopathic LETM (22.2%), tumor (11.1%) acute disseminated encephalomyelitis (7.4%), dural fistula (7.4%) etc.¹⁶ results are consistent to our study as NMOSD is the most common cause followed by MS.

Another study results showed frequent cause of LETM is NMOSD (46.8%), MS (1.6%), isolated LETM (16%), recurrent LETM (14%), infectious etiology (11%) etc.²⁰ which also support our study results.

Acute transverse myelitis has a varied clinical presentation, etiology and outcome.⁸ NMOSD is a recurrent disorder, continuous lesion on MRI affecting central cord,⁹ whereas multiple sclerosis involves more peripheral part of the spinal cord and is patchy in nature.⁹

NMOSD is a autoimmune disease affecting optic

nerves, unilateral or bilateral at presentation- optic neuritis and spinal cord- myelitis and causes severe functional impairment.¹⁰ It predominantly affects women than men in a 3:1 ratio.¹¹ The median age of onset is late 30s, however cases in pediatric population has been described.¹¹

A study which include 76 patients with diagnosis of LETM, conducted in the United Kingdom in which 53 patients of LETM were diagnosed with NMOSD, 5 had ADEM, 5 had idiopathic LETM, 4 had infectious causes, 3 had MS, 2 had other inflammatory diseases etc.as in our study which show NMOSD is common cause of LETM.²¹

NMOSD should be suspected in every case when patient presents with unilateral, bilateral optic neuritis or vision of light perception or worse.¹² Prevention of further attacks is a crucial importance in the management of this clinically varied inflammatory disease.¹³ Treatment with immunosuppressive drugs are recommended to prevent relapses.¹³

Classic multiple sclerosis (CMS) is a chronic degenerative, inflammatory disease that also have female predominance like NMOSD. CMS can present with isolated transverse myelitis, spinal cord lesions extending less than 2 vertebral segments, abnormal imaging, and positive oligoclonal bands in CSF.¹⁴ Optica spinal multiple sclerosis is a variant of multiple sclerosis.¹⁵ In our study there was 6.3% subjects had optica-spinal multiple sclerosis.

A limitation of this study was few number of cases and lack of anti-aquaporin 4 antibodies testing for confirmation of diagnosis in every case due to non-affordability and only admitted /hospitalized patient with history of weakness were included.

CONCLUSION

Longitudinally extensive transverse myelitis (LETM) is not an uncommon disease, however, it remains under-diagnosed in our clinical practice due to either lack or cost of diagnostic facilities. LETM is common presentation of Neuro Myelitis Optica Spectrum disorder (NMOSD) followed by multiple sclerosis, ADEM and other autoimmune diseases etc. Thus clinically important as it results in severe morbidity and patients are at risk of further attacks. Early diagnosis and confirmation of the underlying cause is vital in order to initiate appropriate therapy and favorable outcome.

LIMITATIONS OF STUDY

No study from Pakistan about Longitudinally extensive

transverse myelitis.

No International Study about exact frequency and causes of longitudinally extensive transverse myelitis. Limited data available.

REFERENCES

1. Krishnan C, Kaplin AI, Deshpande DM, Pardo CA, Kerr DA. Transverse myelitis: pathogenesis, diagnosis and treatment. *Front Biosci.* 2004;9:1483-99.
2. Besteiro B, Guimarães J. Review of the Etiological Causes and Diagnosis of Myelitis and Its Medical Orientation Protocol. *J Neurol Neurophysiol* 2013;8:415
3. Jacob A, Weinschenker BG. An approach to the diagnosis of acute transverse myelitis. *Semin Neurol.* 2008;28(1):105-20.
4. Tosi L, Rigoli G, Beltramello A. Fibrocartilaginous embolism of the spinal cord: a clinical and pathogenetic reconsideration. *J Neurol Neuro-Surg & Psy.* 2013;60(1):55-60.
5. Young V, Quaghebeur G Transverse Myelitis and Neuromyelitis Optica Spectrum Disorders. *Semin Ultrasound CT MR.* 2016;37(5):384-95
6. Huang LK, Chung CC, Chen BZ, Chi NF, Hu CJ. Systemic lupus erythematosus presented as extensive longitudinal myelitis. *Acta Neurol Taiwan* 2013;22: 67-71.
7. Trebst C, Raab P, Voss EV, Rommer P, Abu-Mughe isib M, Zettl UK, Stangel M. Longitudinal extensive transverse myelitis—it's not all neuromyelitis optica. *Nature Reviews Neurol.* 2011;7(12):688.
8. Pandit L. Transverse myelitis spectrum disorders. *Neurol India.* 2009;57(2):126-33.
9. Wingerchuk DM, Lennon VA, Pittock SJ, Lucchinetti CF, Weinschenker BG. Revised diagnostic criteria for neuromyelitis optica. *Neurol.* 2006;66:1485–1489.
10. Sánchez AM, Posada LMG, Toscano CAO, López AL. Diagnostic approach to myelopathies. *Rev Colomb Radiol* 2011;22:1-21.
11. Trebst C, Jarius S, Berthele A, Paul F, Schippling S, Wildemann B, Borisow N, Kleiter I, Aktas O, Kümpfel T, Neuromyelitis Optica Study Group. Update on the diagnosis and treatment of neuro myelitis optica: recommendations of the Neuromyelitis Optica Study Group (NEMOS). *J Neurol.* 2014;261(1):1-6.

12. Lana-Peixoto MA. Devic's neuromyelitis optica: a critical review. *Arq Neuropsiquiatr.* 2008;66(1):120-38.
13. Nandhagopal R, Al-Asmi A, Gujjar AR. Neuromyelitis optica: an overview. *Postgrad Med J.* 2010;86(1013):153-9.
14. Sigliti-Henrietta Pelidou, Sotirios Giannopoulos, Sotiria Tzavidi, Georgios Lagos, and Athanassios P Kyritsis Multiple sclerosis presented as clinically isolated syndrome: the need for early diagnosis and treatment. *Ther Clin Risk Manag.* 2008;4(3):627–630.
15. Kira J. Neuromyelitis optica and optico spinal multiple sclerosis: Mechanisms and pathogenesis. *Pathophysiol.* 2011;18(1):69-79.
16. E. Carnero Contentti, J.P. Hryb, F. Leguizamón, J.L. Di Pace, J. Celso, E. Knorre, M.B. Perassolo. Differential diagnosis and prognosis for longitudinally extensive myelitis in Buenos Aires, Argentina. *Neurología*, 2017; 32(2) : 99-105
17. Catalina COCLITUa, Athena MERGEANIA, Teodora PARVUa, Octaviana RUSUa, Andrei CIOBOTARUa, Ovidiu BAJENARUa,b, Florina ANTOCHIA. An Uncommon Cause of Longitudinally Extensive Transverse Myelitis. *MAEDICA – a Journal of Clinical Medicine* 2016; 11(3):245-249
18. Wingerchuk DM, Banwell B, Bennett JL et al. International consensus diagnostic criteria for neuromyelitis optica spectrum disorders. *Neurology.* 2015
19. 2017 McDonald MS Diagnostic Criteria (Thompson et al., 2017)
20. Samira Apostolos-Pereira, Paulo Marchiori, Alessandra Dellavance, Leandro Lucato, Frederico Jorge, Renata Simm, Douglas Sato, Dagoberto Callegaro, Differential Diagnosis of Longitudinally Extensive Transverse Myelitis, *Neurology* Feb 2013, 80 (7 Supplement) P02.109
21. J. Kitley, M.I. Leite, W. Küker, G. Quaghebeur, J. George, P. Waters, et al. Longitudinally extensive transverse myelitis with and without aquaporin 4 antibodies. *JAMA Neurol.* 70 (2013), pp. 1375-1381

Figure 1: Frequency distribution of Age:

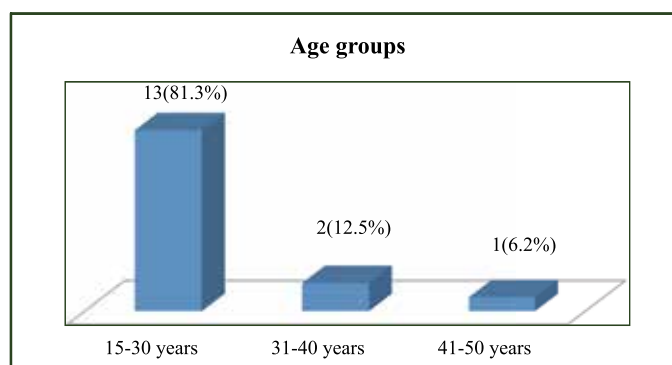


Figure 2: Frequency distribution of common cause of LETM:

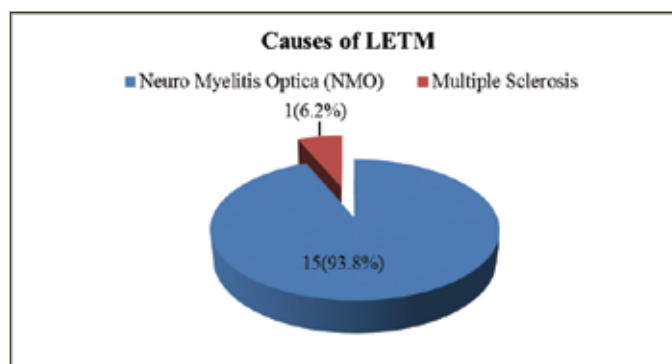
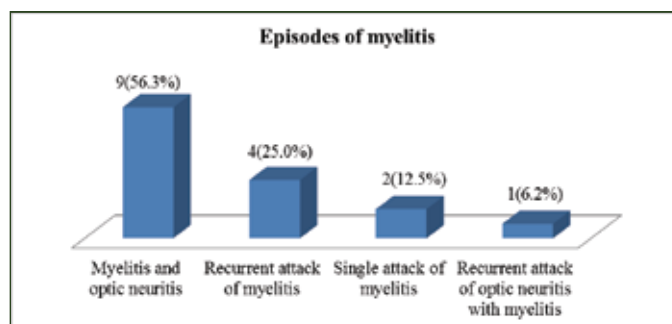


Figure 3: Frequency distribution of episodes of myelitis:



Conflict of interest: Author declares no conflict of interest.

Funding disclosure: Nil

Author's contribution:

Safia Bano; concept, data collection, data analysis, manuscript writing, manuscript review

Muhammad Ather Javed; data collection, data analysis, manuscript writing, manuscript review

Ahsan Numan; data collection, data analysis, manuscript writing, manuscript review