

Vipul Kumar Sharma¹, Kirti Yadav², Amit Nagar³, Pradeep Tandon⁴, TP Chaturvedi⁵

¹Assistant Professor, ⁵Professor and Head, Department of Orthodontics and Dentofacial Orthopaedics, FODS, IMS, BHU, Varanasi, Uttar Pradesh.

²Senior Resident, Department of Periodontology, ³Professor, ⁴Professor and Head, Department of Orthodontics and Dentofacial Orthopaedics, FODS, KGMU, Lucknow, Uttar Pradesh.

Correspondence to:
Dr. Vipul Kumar Sharma, Department of Orthodontics and Dentofacial Orthopaedics, FODS, IMS, BHU, Varanasi, Uttar Pradesh.

E-mail Id:
dr.vipul2010@gmail.com

How to cite this article:
Sharma VK, Yadav K, Nagar A et al. Treatment of Pseudo Class III Malocclusion with Multiple Loop Protraction Utility Arch. *J Adv Res Dent Oral Health* 2016; 1(2): 22-26.

ISSN: 2456-141X

Treatment of Pseudo Class III Malocclusion with Multiple Loop Protraction Utility Arch

Abstract

Pseudo Class III malocclusion has been characterized by an anterior crossbite in the presence of a forward mandibular displacement. There are various methods to correct pseudo Class III malocclusion, e.g., Inclined planes, reverse stainless steel crown, bonded composite resin slopes, tongue blade, the removable appliance with auxiliary springs, and maxillary lingual arch with finger springs. In this article, we are presenting a case of pseudo Class III malocclusion treated with multiple loop protraction utility arch. Patient had functional mandibular anterior deviation resulting into traumatic anterior cross bite and concave profile. We fabricated multiple loop arch wire (0.016"×0.022" blue elgiloy) which was activated at four 90° bends without disturbing other segments of the arch.

Keywords: Pseudo Class III malocclusion, Anterior crossbite, Protraction utility arch.

Introduction

Pseudo Class III malocclusion has been characterized by an anterior crossbite in the presence of a forward mandibular displacement. Profile of pseudo Class III malocclusion appears normal at centric relation (CR) and slightly concave at habitual occlusion (HO); moreover, molar relationship is Class I at CR and Class III at HO.^{1,2} In Asian societies, the frequency of Class III malocclusions is higher due to a large percentage of patients with maxillary deficiency. The incidence ranges between 4 and 5% among the Japanese and 4 and 14% among the Chinese.^{3,4} The etiological factors of this malocclusion may be functional, which includes abnormal tongue position, nasal-respiratory problems, and neuromuscular conditions; skeletal, such as maxillary transverse deficiency; and dental, which includes ectopic eruption of the maxillary central incisors and early loss of the deciduous molars.^{5,6} In most cases, retroclined maxillary incisors are the main cause of pseudo Class III malocclusion.⁷ There are various methods to correct pseudo Class III malocclusion, e.g., inclined planes, reverse stainless steel crown, bonded composite resin slopes, tongue blade, the removable appliance with auxiliary springs, and maxillary lingual arch with finger springs. In this article, we are presenting a case of pseudo Class III malocclusion treated with multiple loop protraction utility arch.

Case Report

A fifteen-year-old male presented at Orthodontic Postgraduate Clinic with the chief complaint of inability of biting from his anterior teeth. His medical and family history was not significant. Extraoral examination showed concave facial profile in centric occlusion and orthognathic in centric relation position with competent lips. On intraoral examination in centric relation, edge-to-edge incisor and Class I molar relation was found. Angle's Class III molar relation and anterior cross bite was found in habitual occlusion position with increased curve of spee and 100% deep bite (Fig. 1). Cephalometric analysis showed mild skeletal Class III (ANB=-1, Wit's=-3), average growth pattern (FMA=26°, SN-MP=30°) with retroclined maxillary incisors (Mx 1 to NA=1/12, Mx 1 to SN= 7°, Md 1 to NB=4/17, IMPA=82°) (Table 1). Orthopantomographic analysis revealed no abnormal finding.

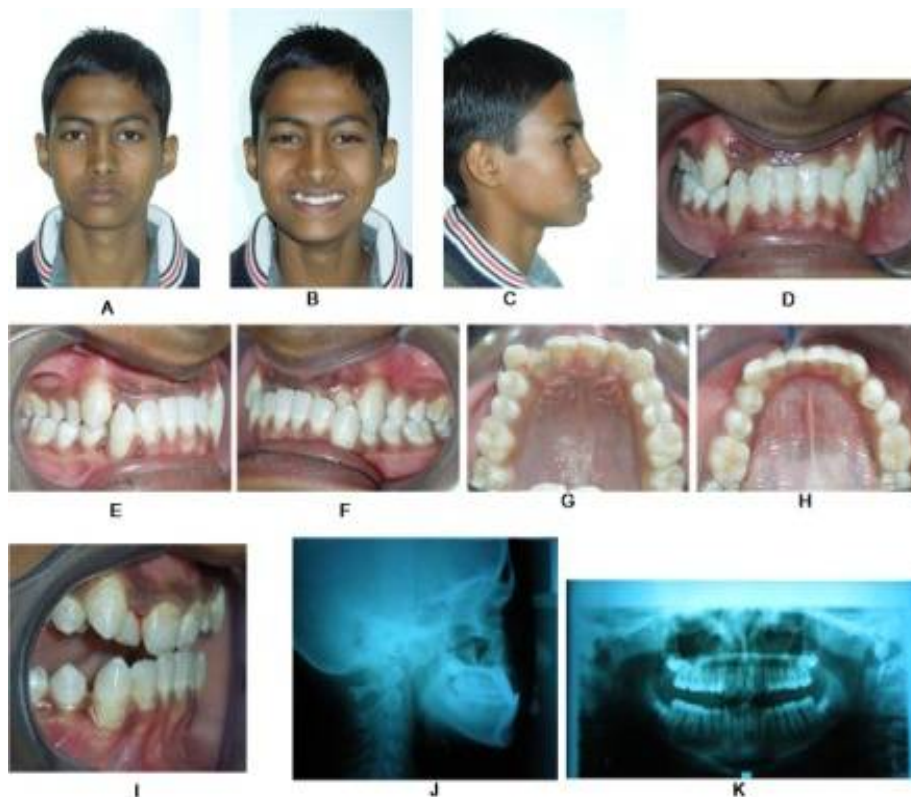


Figure 1. Pretreatment Photographs: (A-C) Extraoral; (D-H) Intraoral; (I) Edge-to-Edge Bite in CR; Radiographs: (J) Lateral Cephalogram; (K) Orthopantomogram

Table 1. Cephalometric Measurements

Measurements	Normal	Pre-treatment	Post-treatment
Horizontal Skeletal			
SNA (°)	82	84	85
SNB (°)	80	85	83
ANB (°)	2	-1	2
Wits appraisal (mm)	0-1	-4	0
Vertical Skeletal			
FMA (°)	25	26	28
Go-Gn to SN (°)	32	30	31
Dental			
Mx. 1 to NA (°/mm)	4/22	1/12	7/36
Mx. 1 to SN (°)	104 ± 7	97	121
Md. 1 to NB (°/mm)	4/25	4/17	5/21
IMPA (°)	90	82	88
Interincisal angle (°)	135	152	125
Soft Tissue			
Rickett's e-line (upper) (mm)	-4	-4	-2
Rickett's e-line (lower) (mm)	-2	0	2
Steiner's upperlip (mm)	0	-1	1
Steiner's lowerlip (mm)	-2	2	0
Lowerlip to H-line (mm)	1-2	4	2
Naso-labial angle (°)	94-110	100	105
Upperlip length (mm)	24	14	19

Based on the analysis of available diagnostic record, case was diagnosed as pseudo Class III malocclusion.

Treatment objectives were to correct anterior cross bite and concave profile, to eliminate CR-CO discrepancy, to achieve Class I molar relation, normal overjet and overbite.

Treatment Planning and Treatment Progress

Bite registration was done for temporary bite raiser to clear the anteriors by 2 mm. Bonding of maxillary incisors was done in MBT prescription (0.022"×0.028" slot). A protraction utility arch was used to procline the

maxillary incisors like 2×4 appliances. 0.016"×0.022" blue elgiloy was used to make T-loop between central incisors and L-loop with helix between central and lateral on both sides to decrease load deflection rate, allowing easy ligation. Four 90° bends were made; two distal to laterals and two mesial to first molars. Bite raiser was placed and utility arch was activated by 5 mm by opening the 90° bends (Fig. 2). After subsequent activation at every 6 weeks, incisors were proclined in 5 months (Fig. 3). Bite raiser was removed. Remaining teeth were bonded and final alignment and leveling was done using 0.016" NiTi, 0.017"×0.025" NiTi followed by 0.019"×0.025" stainless steel.

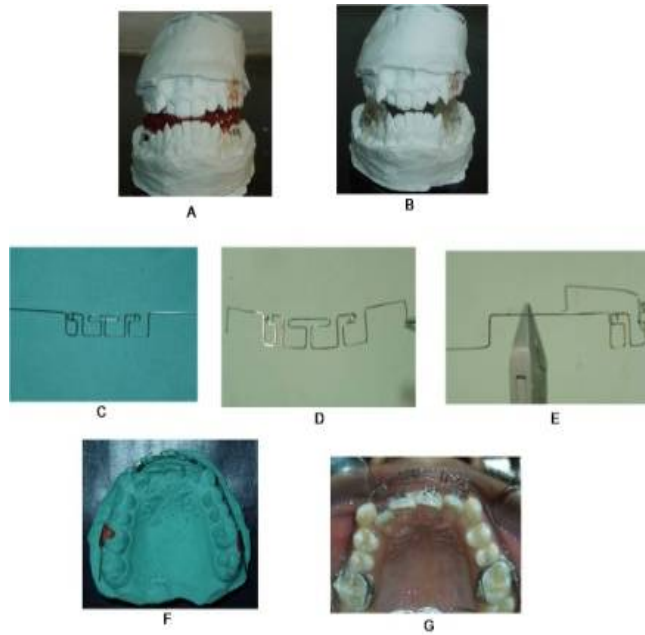


Figure 2.(A) Bite Registrar; (B) Temporary Bite Raiser; (C-G) Multiple Loop Protraction Utility Arch

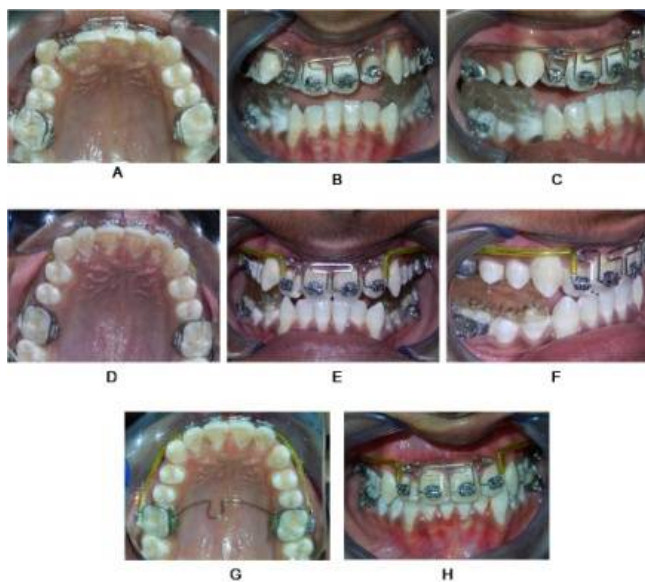

Figure 3.(A-C) Utility Arch Installed; (D-E) 13 Weeks after Treatment; (F-G) 5 Months after Treatment

After 10 months of treatment, the case was deboned and pleasing facial profile obtained with normal overjet,

overbite and no CR-CO discrepancy (Figs. 4 and 5).

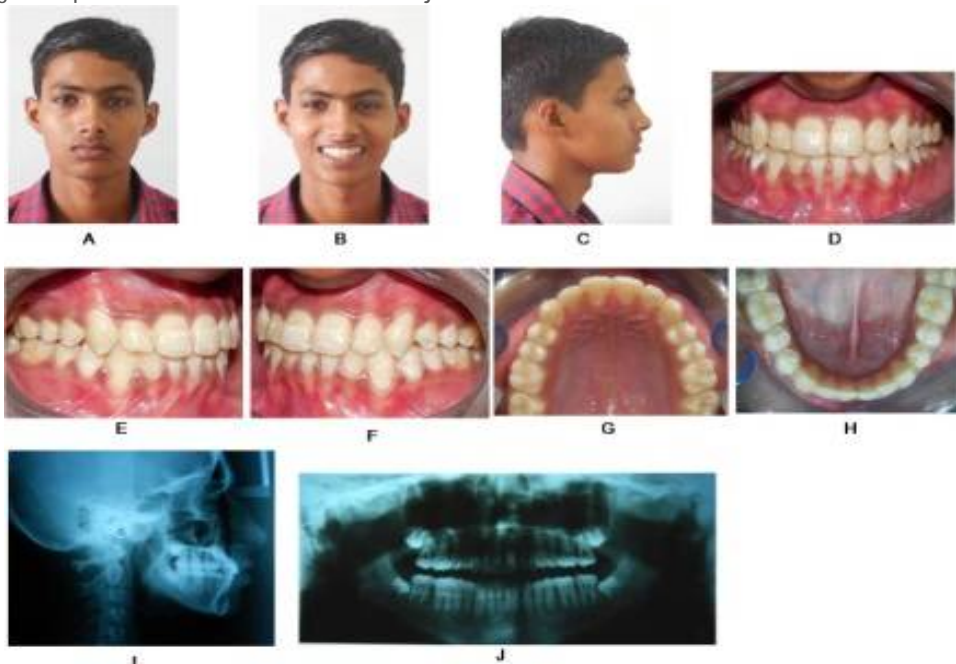


Figure 4.(A-H) Post-Treatment Photographs; (I-J) Radiographs

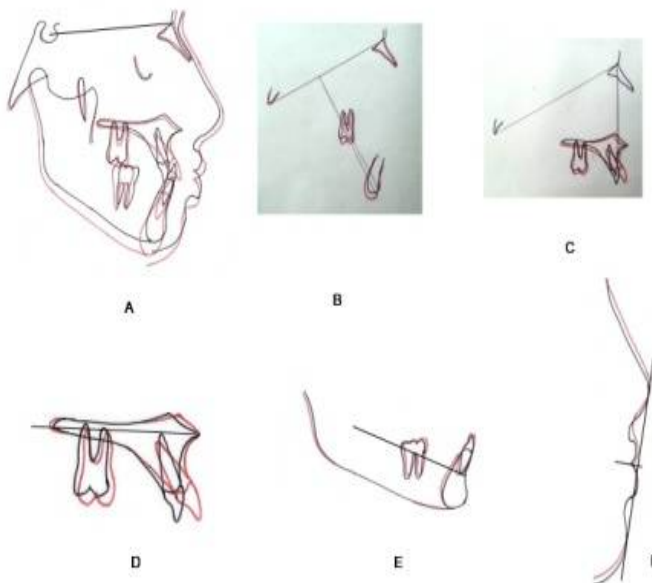


Figure 5.(A) Steiner's Overall Superimposition; (B-F) Rickett's Regional Superimpositions

Discussion

Treatment of Class III problems starts with differential diagnosis of anterior crossbites.⁸ Anterior crossbite may be due to the abnormal inclination of the maxillary and mandibular incisors, occlusal interferences (functional), or skeletal discrepancies of the maxilla and/ or mandible.⁹ Therefore, it is important to diagnose the degree of skeletal discrepancy in order to develop a

proper treatment plan. Early interceptive treatment may prevent progressive, irreversible soft-tissue or bony changes, improve occlusal function and provide a more pleasing facial esthetic, thus improving the psychosocial development of the child.¹⁰ Delaying the treatment until the permanent dentition may cause loss of space required for the eruption of the canines.¹¹ After introduction of utility arch by Ricketts, various modifications were done, i.e., protraction, retraction,

contraction and expansion utility arches.¹² We fabricated protraction utility arch and used in 2×4 fashion which corrected anterior crossbite without disturbing other segments of the arch. Compared to alternative approaches to the early treatment of pseudo Class III malocclusion (such as chin cap, reverse headgear and Frankel III), 2×4 fixed appliance offers an effective way to control tooth movements in an anteroposterior direction, i.e., proclination.¹³ Pseudo Class III malocclusion is self-retentive after correction, so we did not plan for any retention. Since the upper limit of incisor to SN plane is 120°, precaution should be taken to procline the upper incisors.¹⁴

Conclusion

The ability to differentiate between pseudo Class III malocclusion and true skeletal Class III malocclusion can help clinicians formulate early treatment for these patients. The lack of space could be caused by the retroclination of upper incisors frequently found in pseudo Class III malocclusions. Early orthodontic intervention for pseudo Class III malocclusion should be initiated to prevent existing problems from getting worse, and minimize or eliminate the need for comprehensive orthodontic treatment at a later stage.

Conflict of Interest: None

References

1. Lee BD. Correction of crossbite. *Dent Clin North Am* 1978; 22: 647-68.
2. Major PW, Glover K. Treatment of anterior crossbite in early mixed dentition. *J Can Dent Assoc* 1992; 58: 574-75, 578-79.
3. Ishii H, Morita S, Takeuchi Y et al. Treatment effect of combined maxillary protraction and chin cap appliance in severe skeletal Class III cases. *Am J Orthod Dentofacial Orthop* 1987; 92: 304-12.
4. Allwright WC, Burndred WH. A survey of handicapping dentofacial anomalies among Chinese in Hong Kong. *Int Dent J* 1964; 14: 505-19.
5. Giancotti A, Maselli G, Mampieri et al. Pseudo-Class III malocclusion treatment with Balters' Bionator. *J Orthod* 2003; 30(3): 203-15.
6. Raveli DB, Chiavini PCR, Paulin RF et al. Treatment of a case of pseudo-Class III by braces. *J Bras Orthop Facial Orthod* 2004; 9(52): 356-62.
7. Almeida MR, Almeida RR, Oltramari-Navarro PV et al. Early treatment of Class III malocclusion: 10-year clinical follow-up. *J Appl Oral Sci* 2011; 19(4): 431-39.
8. Ngan P, Hu AM, Field HW. Treatment of Class III problems begins with differential diagnosis of anterior crossbites. *American Academy of Pediatric Dentistry* 1997; 19(6): 386-95.
9. Vadiakas G, Viazis AD. Anterior crossbite correction in the early deciduous dentition. *Am J Orthod Dentofacial Orthop* 1992; 102: 160-62.
10. Joondeph DR. Early orthodontic treatment. *Am J Orthod Dentofacial Orthop* 1993; 104: 199-200.
11. Sharma PS, Brown RV. Pseudomesiocclusion: Diagnosis and treatment. *J Dent Child* 1968; 35: 385-91.
12. Bench RW, Gugino CF, Hilgers JJ. Bio-progressive therapy, Part 7: The utility and sectional arches in bio-progressive therapy mechanics. *J Clin Orthod* 1978; 12(3): 192-207.
13. Rabie ABM, Gu Y. Management of pseudo Class III malocclusion in southern Chinese children. *Br Dent J* 1999; 186(4): 183-87.
14. Burns NR, Musich DR, Martin Ch et al. Class III camouflage treatment: What are the limits? *Am J Orthod Dentofacial Orthop* 2010; 137: 9.e1-9.e13.

Date of Submission: 08th Apr. 2016

Date of Acceptance: 08th Apr. 2016