



## Medical Imagery

## Case of eosinophilic meningitis in an autistic child



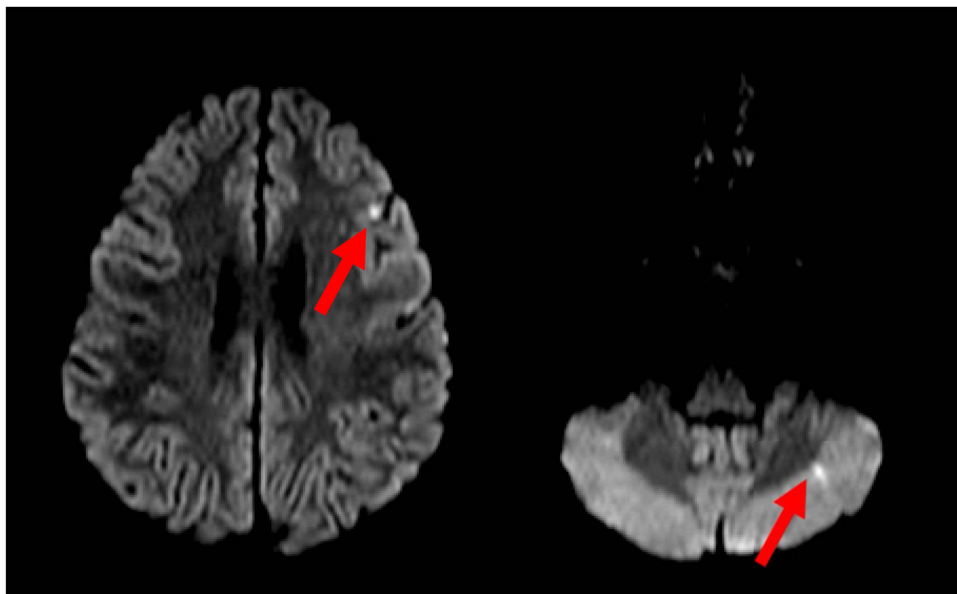
An eight-year-old boy, autistic and with a history of unusual eating habits (like live snails), was brought to the hospital with sleepiness, nausea and vomiting. At the beginning he also had a generalized seizure.

His white blood count cells showed a leukocytosis with eosinophilia. Lumbar puncture was performed and his cerebrospinal fluid (CSF) showed 530 leukocytes with 64% of eosinophils. The result of the CSF analysis detected *Angiostrongylus cantonensis* antibodies and antigen (methods ELISA IgG and Western Blot). The diagnosis of eosinophilic meningitis caused by that nematode was done. Albendazole and steroids were used for treatment, with clinical improvement.

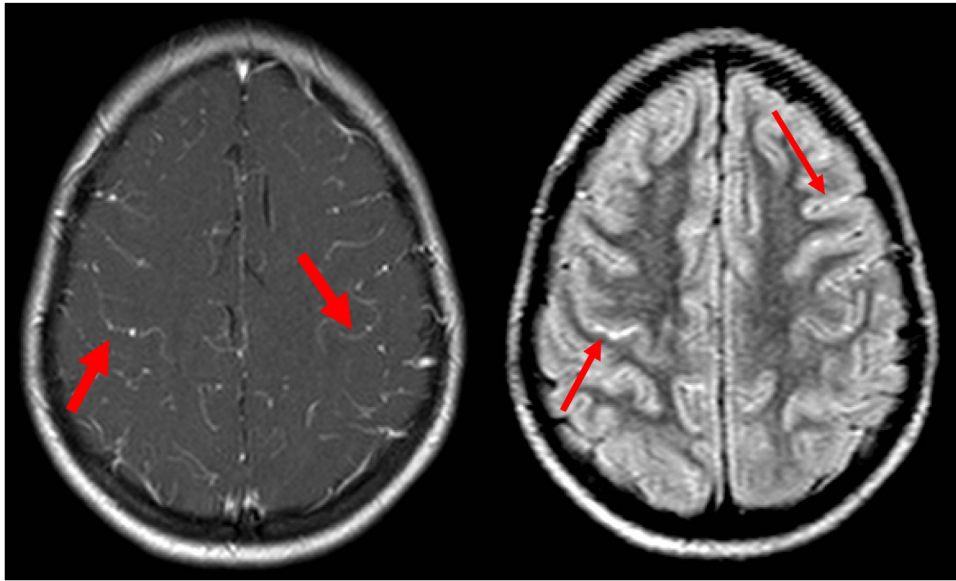
Magnetic resonance imaging (MRI) was also performed (Figures. 1 and 2).

Multiple scattered hyperintensities with and without contrast enhancement are the most commonly described findings on MRI (Rai et al., 2014). Sometimes computed tomogram (CT) and MRI may not reveal any abnormality (Rai et al., 2014). The finding on diffusion weighted-imaging (DWI) can represent foci of microabscesses or developing infarcts and is not commonly described in the literature (Rai et al., 2014; Federspiel et al., 2020).

The final diagnosis of neuroangiostrongyliasis is based on serology and CSF cell counts (Rai et al., 2014). In this case, the unusual eating habits could increase the suspect, once *Angiostrongylus cantonensis* is an emerging parasite in Brazil and can be found in snails (Morassuti et al., 2014).



**Figure 1.** Some punctate foci of diffusion (DWI) restriction in supra and infratentorial compartments (arrows).



**Figure 2.** Diffuse leptomeningeal enhancement (thick arrows on post-contrast T1) and sulcal FLAIR hyperintensity (thin arrows). Ectasic ventricles were also found (not shown).

#### Authors contributions

Lillian Gonçalves Campos and João Ricardo Hass Massena: Collected data, contributed data and wrote the paper.

Juliana Ávila Duarte: Conceived the idea, contributed data and reviewed the paper.

#### Conflict of interest

None declare.

#### Funding source

None.

#### Ethical approval

Written informed consent was obtained from the patient. Patient's data was anonymized.

#### References

Federspiel F, Skovmand S, Skarphedinsson S. Eosinophilic meningitis due to *Angiostrongylus cantonensis* in Europe. *Int J Infect Dis* 2020;93:28–39.

Morassuti AL, Thiengo SC, Fernandez M, Sawanyawisuth K, Graeff-Teixeira C. Eosinophilic meningitis caused by *Angiostrongylus cantonensis*: an emergent disease in Brazil. *Mem Inst Oswaldo Cruz* 2014;109:339–407.

Rai S, Madi D, Pai S, Baliga S. Unusual larva in the CSF and unique MRI findings in a case of eosinophilic meningitis. *J Clin Imaging Sci* 2014;4:76.

Lillian Gonçalves Campos<sup>a,\*</sup>

João Ricardo Hass Massena<sup>b</sup>

Juliana Ávila Duarte<sup>c</sup>

<sup>a</sup>Serviço de Radiologia do Hospital de Clínicas de Porto Alegre, Porto Alegre, RS, Brazil

<sup>b</sup>Unisinos, Curso de Medicina, Porto Alegre, RS, Brazil

<sup>c</sup>Universidade Federal do Rio Grande do Sul, Programa de Pós Graduação em Ciências Médicas, Departamento de Medicina Interna, Porto Alegre, RS, Brazil

\* Corresponding author.

E-mail address: [lcampos@hcpa.edu.br](mailto:lcampos@hcpa.edu.br) (L. Campos).

Received 11 August 2020

Received in revised form 27 August 2020

Accepted 1 September 2020