



## Structural development of cortical lobes during the first 6 months of life in infant macaques

Z.A. Kovacs-Balint<sup>a</sup>, C. Payne<sup>a,b</sup>, J. Steele<sup>a</sup>, L. Li<sup>b,c</sup>, M. Styner<sup>d</sup>, J. Bachevalier<sup>a,e</sup>, M. Sanchez<sup>a,f,\*</sup>

<sup>a</sup> Yerkes National Primate Research Center, Emory University, Atlanta, GA, 30329, United States

<sup>b</sup> Marcus Autism Center, Children's Healthcare of Atlanta, Atlanta, GA, 30329, United States

<sup>c</sup> Department of Pediatrics, School of Medicine, Emory University, Atlanta, GA, 30322, United States

<sup>d</sup> Department of Psychiatry, University of North Carolina, Chapel Hill, NC, 27514, United States

<sup>e</sup> Department of Psychology, Emory University, Atlanta, GA, 30322, United States

<sup>f</sup> Department of Psychiatry & Behavioral Sciences, School of Medicine, Emory University, Atlanta, GA, 30322, United States

### ARTICLE INFO

#### Keywords:

Rhesus monkey  
Infant brain development  
Structural MRI  
Brain developmental patterns  
Cortical lobes  
Nonhuman primate model

### ABSTRACT

This study mapped the developmental trajectories of cortical regions in comparison to overall brain growth in typically developing, socially-housed infant macaques. Volumetric changes of cortical brain regions were examined longitudinally between 2–24 weeks of age (equivalent to the first 2 years in humans) in 21 male rhesus macaques. Growth of the prefrontal, frontal, parietal, occipital, and temporal cortices (visual and auditory) was examined using MRI and age-specific infant macaque brain atlases developed by our group. Results indicate that cortical volumetric development follows a cubic growth curve, but maturational timelines and growth rates are region-specific. Total intracranial volume (ICV) increased significantly during the first 5 months of life, leveling off thereafter. Prefrontal and temporal visual cortices showed fast volume increases during the first 16 weeks, followed by a plateau, and significant growth again between 20–24 weeks. Volume of the frontal and temporal auditory cortices increased substantially between 2–24 weeks. The parietal cortex showed a significant volume increase during the first 4 months, whereas the volume of the occipital lobe increased between 2–12 weeks and plateaued thereafter. These developmental trajectories show similarities to cortical growth in human infants, providing foundational information necessary to build nonhuman primate (NHP) models of human neurodevelopmental disorders.

### 1. Introduction

Neurodevelopmental disorders, such as Autism Spectrum Disorder (ASD), schizophrenia, ADHD and mental retardation, are characterized by behavioral and cognitive deficits rooted in early derailment of brain development. Thus, an enhanced knowledge of typical structural and functional brain development is critical not just to understand early healthy trajectories, but to elucidate neuropathological processes and neural markers of those developmental disorders early in life. Recent neuroimaging studies have started to map brain development in human infants by characterizing brain grey matter (GM) and white matter (WM) structures using MRI and diffusion tensor imaging (DTI), and functional connectivity (FC) using resting state functional MRI (rs-fMRI) (Giedd et al., 1999; Casey et al., 2000; Gogtay et al., 2004; Knickmeyer

et al., 2008; Lin et al., 2008; Gao et al., 2009; Geng et al., 2012; Gilmore et al., 2012; Tanaka et al., 2012; Dean et al., 2014; O'Muircheartaigh et al., 2014; Gao et al., 2015; Song et al., 2015; Deoni et al., 2016; Remer et al., 2017; Wang et al., 2019; Gilmore et al., 2020). They have shown that total brain volume (TBV) doubles during the first postnatal year, followed by a slower growth (15 % increase) in the second year of life (Knickmeyer et al., 2008), although with different developmental trajectories for GM and WM. WM volume (myelinated axons) increases by about 11 % in the first year and continues to expand during the second postnatal year (Knickmeyer et al., 2008; Geng et al., 2012; Dean et al., 2014; O'Muircheartaigh et al., 2014; Dean et al., 2015; Deoni et al., 2016), as confirmed by DTI studies of WM structural integrity maturation (Deoni et al., 2011; Geng et al., 2012; Song et al., 2015; Deoni et al., 2016). Cortical gyrification also expands significantly (Li et al., 2014).

\* Corresponding author at: Yerkes National Primate Research Center, Emory University, 954 Gatewood Road, Atlanta, GA, 30329, United States.  
E-mail address: [mmsanch@emory.edu](mailto:mmsanch@emory.edu) (M.M. Sanchez).

<https://doi.org/10.1016/j.dcn.2020.100906>

Received 15 May 2020; Received in revised form 6 December 2020; Accepted 17 December 2020

Available online 8 January 2021

1878-9293/© 2021 The Author(s).

Published by Elsevier Ltd.

This is an open access article under the CC BY-NC-ND license

(<http://creativecommons.org/licenses/by-nc-nd/4.0/>).

Notably, the robust growth of the human infant brain during the first 2 years seems driven mainly by GM growth, which increases 1.5-fold from birth through 12 months alone (Knickmeyer et al., 2008; Gilmore et al., 2012). This rapid cortical GM growth and WM structural expansion likely support the motor, cognitive and social development during infancy. Structural brain development continues through late adolescence/young adulthood with a critical remodeling period during the pubertal transition, where a sharp reduction in GM volume has been reported, thought to reflect dendritic pruning (Casey et al., 2000; Gogtay et al., 2004; Casey et al., 2010; Giedd and Rapoport, 2010). However, studies of human brain structural development, more specifically in the early perinatal period are limited due to challenges related to subject burden, attrition and ethical considerations when acquiring densely-sampled longitudinal MRI scans in early postnatal ages (Raschle et al., 2012). Given these limitations, the use of animal models provides a critical alternative not only to understand the early normative development of brain circuits using longitudinal designs with high experimental control over common confounding factors in human studies (diet, perinatal exposure to drugs/alcohol), but also to use experimental manipulations (chemogenetic, neuromodulation) of specific neural circuits at specific ages to determine the origin of atypical brain development and to test novel therapies.

Among nonhuman primate (NHP) models, the rhesus macaque (*Macaca mulatta*) has been widely studied due to the biological and phylogenetic closeness to humans in brain and developmental similarities (e.g. gestation of a single offspring; maturational stage of the neonatal brain at birth; protracted maturation of regions such as the prefrontal cortex and its connectivity with social neural circuits), as well as the complex, higher order behavioral and cognitive functions associated with encephalization (Rilling and Insel, 1999; Price and Coe, 2000; Passingham, 2009; Bauman and Schumann, 2018). A handful of neuroimaging studies have already shown that development of total brain volume (TBV), intracranial volume (ICV: GM + WM + cerebrospinal fluid –CSF-) and of cortical GM and WM volumes in rhesus monkeys follows similar patterns to those reported in humans. Similarities include rapid, exponential growth of GM in the first 3 months of life (roughly equivalent to the first year in humans), and a continuous, slower growth thereafter, up to puberty, whereas WM volume increases more slowly but continuously until young adulthood in both species (Malkova et al., 2006; Knickmeyer et al., 2010; Payne et al., 2010; Liu et al., 2015; Scott et al., 2016; Liu et al., 2019; Kim et al., 2020).

Most of these NHP studies, though, have focused on development from 6 months to the juvenile and adolescence periods, sometimes using cross-sectional designs and small sample sizes, with the exception of three recent longitudinal studies (Scott et al., 2016; Liu et al., 2019; Kim et al., 2020), which have provided additional information of cortical GM, WM and whole cortical lobes (GM + WM) volumes from 2 through 6 months and thereafter, through the juvenile and adult periods. These three studies report (1) rapid volume increases in cortical regions from 2 to 6 months, followed by arrest in ICV and cortical volume growth between 5–6 and 9 months, with moderate volume increases thereafter, consistent with previous findings (Malkova et al., 2006); (2) laterality effects emerging at 6 months and sex differences -accelerated brain development in females than males- (Scott et al., 2016); (3) region-specific rates and trajectories of growth, with the frontal and temporal lobes showing the largest but most protracted increases, and the occipital lobe the smallest (Scott et al., 2016; Kim et al., 2020); and (4) GM maturation proceeding in caudo-rostral and dorso-ventral directions (Liu et al., 2019; Kim et al., 2020) similar to those reported in human studies (Gilmore et al., 2012), though human GM maturation is much slower than in macaques.

Although these three recent longitudinal studies (Scott et al., 2016; Liu et al., 2019; Kim et al., 2020) provide critical information on macaque cortical development from 6 months onward, they lack granular information before that age due to the sparse scan sampling. In fact, the Liu et al. (2019) and Kim et al. (2020) papers lack neurodevelopmental

data before 8 weeks (equivalent to 8 months in humans), are based on small sample size ( $n = 6$  control/breastfed infants, Liu et al., 2019) and originate from infants reared with their mothers in cages (i.e. in limited social environments; Kim et al., 2020). The Scott et al. (2016) study included earlier scans (at 1, 4, 8, 13 weeks) but acquired half of scans with a lower field strength (1.5 T) scanner and the other half with a 3 T scanner that resulted in technical issues (susceptibility artifacts) in the temporal lobe, which warranted the need of a follow up study with high quality images, particularly in the temporal cortex.

In summary, there is a need to understand the early neonatal and infant cortical developmental trajectories in the macaque model for translational studies in humans, addressing shortcomings and technical limitations of previous neuroimaging studies and adding critical early data to the existing body of research. Therefore, we conducted a within-subject, longitudinal, study using a high field 3 T magnet, high resolution sequences and densely sampled structural MRI scans in socially reared infant macaques from birth through 6 months (equivalent to the first 2 years in human infants). Scans were acquired at 2, 4, 8, 12, 16, 20 and 24 weeks to measure the developmental growth of cortical lobe volumes (occipital, parietal, frontal, prefrontal and temporal cortex -divided into temporal auditory and temporal visual areas-). In order to address technical issues in previous reports (e.g. susceptibility artifacts in temporal lobe), we used optimized scanning sequences that resulted in higher resolution images (0.5mm<sup>3</sup>) and minimized artifacts. Importantly, we also used age-specific brain infant atlases developed by our group and optimized processing pipelines that use both T1- and T2-weighted data from each subject in full multi-modal fashion to improve tissue segmentation and anatomic parcellations of cortical regions, particularly at the early ages. Given the earlier findings, we hypothesized that maturational timelines and magnitude of cortical volume growth will be region-specific, with GM + WM volumes expanding faster during the first 12 weeks and in the occipital lobe than in the temporal, parietal and frontal lobes. In addition, we also hypothesized that cortical growth will taper off around 5–6 months -the oldest ages studied here-, and that no significant asymmetries will be detected, given that laterality effects have been reported to emerge after 6 months of age (Scott et al., 2016).

## 2. Methods

### 2.1. Subjects and housing

Twenty-one infant male rhesus monkeys (*Macaca mulatta*) were studied longitudinally as part of a larger project that also examined developmental trajectories of resting state functional brain connectivity (Kovacs-Balint et al., 2019), white matter maturation (DTI), and social visual perception of relevance for ASD-deficits using eye-tracking (Muschinski et al., 2016; Parr et al., 2016; Wang et al., 2020). Only males were studied due to the higher male:female ratio diagnosis of ASD (Loomes et al., 2017; Baio et al., 2018) and other neurodevelopmental disorders, and to increase power for our analyses. Subjects lived with their mothers in large social groups at the Yerkes National Primate Research Center (YNPRC) Field Station, in Lawrenceville, GA (RRID: SCR\_001914), which provided critical species-specific social experiences for the study of typical brain development. The groups consisted of 55–130 adult females with their adolescent, juvenile, and infant offspring, and 2–4 adult males. The animals were housed in outdoor compounds, with access to a climate-controlled indoor housing area. Standard high fiber, low fat monkey chow (Purina Mills Int., Lab Diets, St. Louis, MO) and seasonal fruits and vegetables were provided twice daily, in addition to enrichment items. Water was available *ad libitum*. Exclusion criteria included: 1) infants of primiparous, or abusive/neglectful females to control for potential effects of mothering quality and experience, 2) infants from the highest- and lowest-ranked families to control for potential developmental effects of extreme social status/-rank, and 3) infant birth weight <450 g, to avoid effects of

prematurity/low birth weight on brain development (Scott et al., 2016). All procedures were approved by the Emory University Institutional Animal Care and Use Committee (IACUC) in accordance with the Animal Welfare Act and the U.S. Department of Health and Human Services "Guide for Care and Use of Laboratory Animals."

## 2.2. MRI data acquisition

Whole-brain structural MRI scans were collected longitudinally at 2, 4, 8, 12, 16, 20 and 24 weeks of age after birth, on a 3 T Siemens TIM Trio MRI scanner (Siemens Med. Sol., Malvern, PA, USA), using an 8-channel phase array coil. T1- and T2-weighted scans were collected during a single session per subject and age, under isoflurane anesthesia (0.8–1 % to effect, inhalation), following initial telazol induction ( $2.56 \pm 0.05$  mg/kg BW, i.m.). Physiological parameters were monitored using oximeter, ECG, rectal thermistor, and blood pressure monitor; an i.v. catheter was used to maintain normal hydration (administer dextrose/NaCl 0.45 %), and an MRI-compatible heating pad helped maintain the infants' body temperature. A custom-made non-ferrous head holder with ear bars and a mouth piece were used to prevent head movement (to avoid motion artifacts); and a vitamin E capsule was placed on the right temple to identify the right hemisphere. Upon completion of the scans and full recovery from anesthesia, each infant was immediately returned to their mother and the pair was returned to their social group together on the following day. No changes in mother's or infant's behavior are detected when these procedures are used in animals that are trained and habituated (Howell et al., 2019; Morin et al., 2021).

High-resolution T1-weighted MRI scans were acquired using a 3D magnetization prepared rapid gradient echo (3D-MPRAGE) parallel image sequence (TR/TE = 2600/3.38 msec, FoV: 128 mm, voxel size:  $0.5\text{mm}^3$  isotropic, 8 averages, GRAPPA, R = 2). High-resolution T2-weighted MRI scans were collected in the same direction as the T1 (TR/TE = 3200/373 msec, FoV: 128 mm, voxel size:  $0.5\text{mm}^3$  isotropic, 3 averages, GRAPPA, R = 2) to improve registration to atlas space, parcellation of cortical regions and segmentation of WM, GM, and CSF tissue classes.

## 2.3. MRI data processing

All datasets were processed using AutoSeg\_3.0.2 segmentation package (Wang et al., 2014, RRID: SCR\_009438; AutoSeg was used in combination with NeoSeg -version 1.0.7.- for 2 and 4 weeks data), to measure ICV (defined as total GM + total WM + total CSF in the ventricles and in the subarachnoid cavity), and volumes of each cortical lobe region of interest -ROI- (defined as GM + WM: prefrontal -PFC-, frontal, parietal, occipital, temporal visual and temporal auditory cortices), following previously published protocols (Styner et al., 2007; Knickmeyer et al., 2010; Shi et al., 2017; Reding et al., 2020). Briefly, MRI image processing steps included: 1) Averaging the T1 and the T2 images -respectively-; 2) Intensity inhomogeneity correction; 3) Rigid body registration of the images to reference atlas space; 4) Tissue segmentation and skull-stripping using atlas-based classification (ABC); 5) Registration of the atlas to the subject's brain to generate cortical parcellations (affine + deformable ANTS registration) and computations of the respective volumes by hemisphere. For this study we used age-specific T1- and T2-weighted atlases of the infant rhesus brain generated by our group (Shi et al., 2017); based on best match of neuroanatomical characteristics, we registered the 2- and 4-week scans to a 2-week atlas, the 8-, 12- and 16-week scans to a 3-month atlas, and the 20- and 24-week scans to a 6-month atlas. The age-specific T1- and T2-weighted atlases were employed for multi-modal registration of the subject's brain to reference atlases for the purpose of ROI parcellation, multi-atlas structural segmentation and tissue classification. At each time point, both T1- and T2-weighted data from each subject were employed jointly in full multi-modal fashion for all registration and

segmentation steps of data processing, and thus both are considered of equal importance. Particularly at the youngest ages, the inclusion of the T2-weighted data is crucial for good results. Cortical ROIs were generated and defined based on published macaque MRI anatomical lobar parcellations (Knickmeyer et al., 2010) mapped onto the infant macaque brain atlases (Shi et al., 2017) and manually edited to ensure accurate anatomical definition following published criteria (Saleem and Logothetis, 2012; Reding et al., 2020). Developmental changes in cortical lobar volumes were analyzed as raw ROI volumetric data, as well as corrected by ICV (entered as a covariate in the statistical models below) to account for individual differences in whole brain volume at each age.

## 2.4. Statistical data analysis

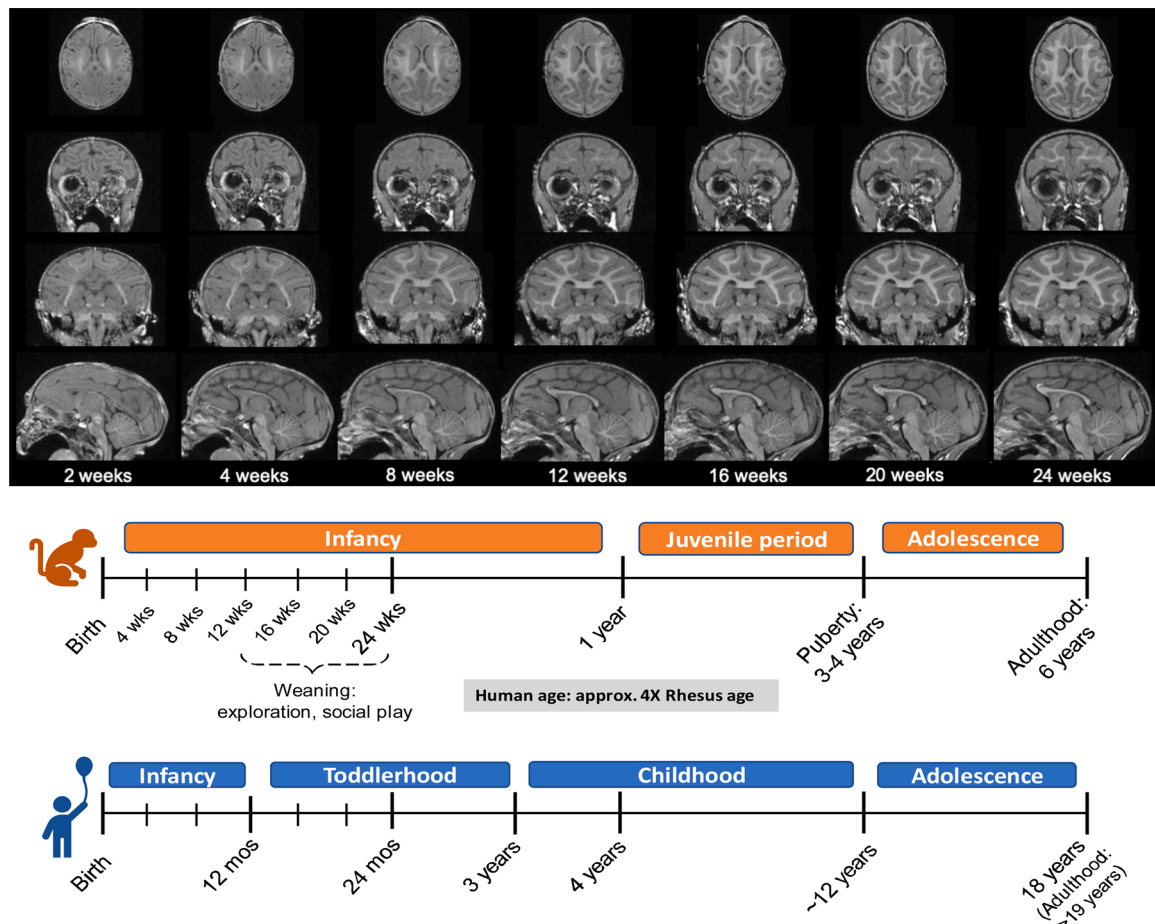
Mixed-effects Models (MEM), which accounts for missing data and correlated within-subjects variance, was used to determine the influence of age on overall brain growth (ICV) and the volumetric development of cortical brain areas (prefrontal, frontal, parietal, occipital, and temporal cortex -visual and auditory areas-), using IBM SPSS Statistics v.26 (IBM Corporation, Armonk, NY, RRID: SCR\_002865). Normal distribution of residuals was checked to assess the appropriateness of the tested models. All volumetric measures were centered to reduce nonessential collinearity. To characterize both the unique growth of each cortical region and in relation to the overall brain growth, all trajectories were modeled with and without ICV as a covariate, respectively. Linear and curvilinear (quadratic, cubic, and exponential) patterns were modeled for ICV and total cortical ROI volume (sum of the left and right hemispheres), as well as separately, by hemisphere (right, left). The models that best fit the data were identified using several factors. Previous developmental studies in rhesus macaques have indicated global and regional brain growth are best characterized by nonlinear models and exhibit regional differences that reflect the unique GM and WM ratios and developmental timescale of each region (Payne et al., 2010, 2017). Given the early age range in this study, which has not previously been fully characterized using structural MRI in rhesus macaques, we took an iterative approach to assessing which parameters best characterized the regional data. For every ROI, we began by assessing the fit of simplest linear model. An analysis of residuals was used to indicate whether a higher-order model should be considered to better describe the data. When indicated, higher-order models (quadratic, cubic, exponential) were assessed iteratively in the same manner (assessment model fit, followed by analysis of residuals to determine whether higher-order model should be considered). The log-likelihood ratio is commonly used to determine best fit when multiple models can be used to characterize the data. However, comparing this ratio across models containing a different number of variables or structure can be problematic. Hence, when multiple models could be used to characterize the data, the linearity of the residual plots identified the best fit, which was subsequently confirmed by the log-likelihood ratio when appropriate. Significant results were considered at  $p < 0.05$ . Post-hoc pairwise comparisons were performed using Student's *t*-test with Bonferroni adjustments when AGE significant effects were detected (adjusted p-value for significance:  $p < 0.0024$ ). No subjects were excluded from the analyses due to missing data.

## 3. Results

As shown in Figs. 1 (top) and 2, the infant macaque brain undergoes drastic increases in overall brain size, ICV, GM and WM volumes, and tissue contrast with age during the first 6 postnatal months. Fig. 2A depicts the cortical ROIs studied. Fig. 1 (bottom) provides a diagram of rhesus developmental charts compared to humans.

### 3.1. Intracranial volume (ICV)

The ICV growth was best characterized by a cubic function (F



**Fig. 1.** (Top) Structural brain development during the first 6 months of life in an infant macaque example. T1-weighted scans were acquired longitudinally between 2 and 24 postnatal weeks, from each subject ( $n = 21$ ). GM and WM volumes and contrast increased as the brain developed. (Bottom) Rhesus macaque developmental charts, milestones and ages (brown) compared to humans (blue).

(1,123.054) = 34.897,  $p = 3.17 \times 10^{-8}$ , -2 Log Likelihood: 2655.72; Fig. 2B(a)), with significant growth increases from 2 to 20 weeks of age (see Table 1 for detailed volume fold increases between specific ages and pairwise comparisons  $p$  values), at which point the growth appears to level off. ICV showed an average 39 % (1.39-fold) increase between 2–24 weeks of life ( $p = 3.71 \times 10^{-18}$ ).

### 3.2. Prefrontal cortex (PFC)

Age-related GM + WM growth associated with the development of the PFC was best characterized by a cubic function ( $F(1,123.031) = 21.679$ ,  $p = 8.00 \times 10^{-6}$ , -2 Log Likelihood: 1937.07; Fig. 2B(b)). The volume of the PFC increased significantly from 2 to 16 weeks (1.29-fold increase,  $p = 2.49 \times 10^{-16}$ ; see Table 1 for detailed volume fold increases between specific ages and pairwise comparisons  $p$  values), and from 20 to 24 weeks of age (1.02-fold increase,  $p = 3.42 \times 10^{-4}$ ), plateauing in-between (Fig. 2B(b), Table 1). The PFC showed an average 32 % (1.32-fold) increase between 2–24 weeks of life ( $p = 3.83 \times 10^{-18}$ ).

Development of the PFC did not vary by hemisphere ( $F(1,267.004) = 0.003$ ,  $p = 0.958$ ).

Age effects were no longer observed when ICV was included in the model as a covariate ( $F(1,115.256) = 0.438$ ,  $p = 0.509$ ). This suggests that the PFC volume increases are explained by overall brain growth and appear to show less robust developmental gains than ICV during this early age range.

### 3.3. Frontal cortex

The frontal cortex showed significant volumetric increase with age, best characterized by a cubic function ( $F(1,123.024) = 28.922$ ,  $p = 3.648 \times 10^{-7}$ , -2 Log Likelihood: 1961.74; Fig. 2B(c)). The volume of the frontal cortex showed an average 36 % continuous increase from 2 weeks to 24 weeks of age (1.36-fold increase,  $p = 3.1 \times 10^{-17}$ ), with the most dramatic volumetric increase occurring between 2 and 16 weeks of age (1.32-fold increase,  $p = 1.12 \times 10^{-16}$ ; see Fig. 2B(c) and Table 1 for detailed fold increases between specific ages and pairwise comparison  $p$  values). No developmental differences were observed across the two hemispheres ( $F(1,266.999) = 1.912 \times 10^{-12}$ ,  $p = 0.99$ ).

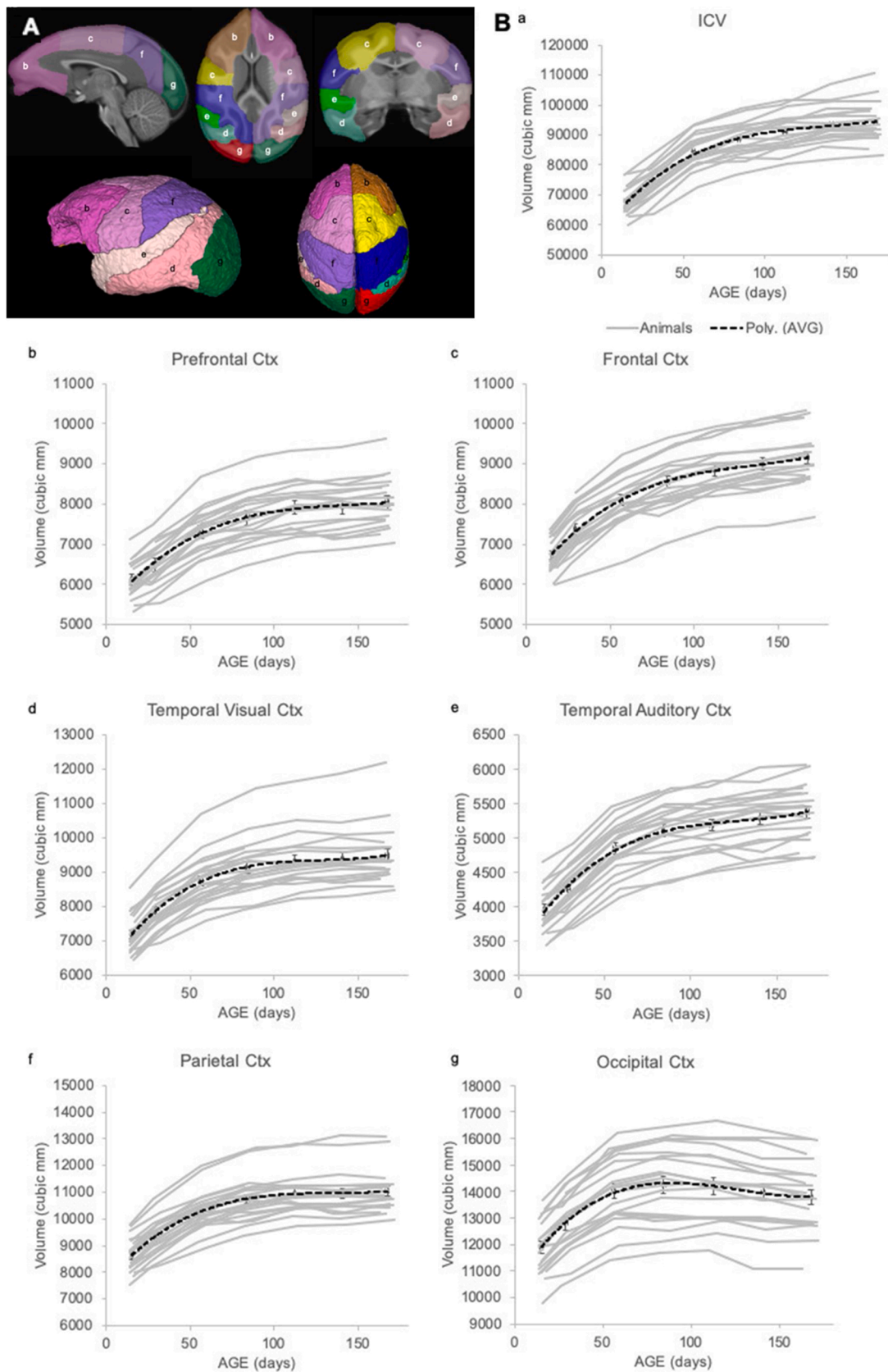
After adjusting for ICV, the developmental growth of the frontal cortex remained significant and showed a linear developmental trajectory ( $F(1,113.607) = 38.397$ ,  $p = 9.524 \times 10^{-9}$ , -2 Log Likelihood: 1992.41). This suggests that there is region-specific growth not fully explained by the overall brain growth, but that the timing of those changes may not differ from general growth.

### 3.4. Temporal cortex

The temporal cortex was divided into two functionally different areas: temporal visual and temporal auditory areas. Therefore, the results are presented separately for the two areas below.

#### 3.4.1. Temporal visual area

A significant effect of age was detected on the temporal visual area volume, best characterized by a cubic function ( $F(1,123.036) = 44.871$ ,



**Fig. 2.** Developmental brain and cortical trajectories. **(A)** Cortical brain ROIs represented in the 12 months infant brain atlas. **(B)** Individual developmental trajectories of the cortical (GM + WM) ROIs (gray lines) and 3rd order polynomial fit for the group average (+/- SEM; black dashed lines). a: ICV, b: Prefrontal, c: Frontal, d: Temporal visual, e: Temporal auditory, f: Parietal, and g: Occipital cortices.

**Table 1**

Volumetric fold-increase matrices. For ICV and each cortical ROI, colored squares represent volumetric increase between 2 age points (the darker the color, the higher the volume increase). \*:  $10^{-5} \leq p < 0.0024$ , \*\*:  $10^{-10} \leq p < 10^{-5}$ , \*\*\*:  $p < 10^{-10}$ .

ICV						
	2wk	4wk	8wk	12wk	16wk	20wk
2wk						
4wk	1.08**					
8wk	1.24***	1.16***				
12wk	1.30***	1.21***	1.05**			
16wk	1.34***	1.25***	1.08**	1.03*		
20wk	1.38***	1.28***	1.11***	1.06**	1.03*	
24wk	1.39***	1.29***	1.12***	1.06**	1.04**	1.01

Prefrontal cortex						
	2wk	4wk	8wk	12wk	16wk	20wk
2wk						
4wk	1.06**					
8wk	1.19***	1.13***				
12wk	1.25***	1.18***	1.05**			
16wk	1.29***	1.22***	1.08***	1.03**		
20wk	1.3***	1.22***	1.09***	1.03**	1.00	
24wk	1.32***	1.24***	1.1***	1.05**	1.02*	1.01*

Temporal visual cortex						
	2wk	4wk	8wk	12wk	16wk	20wk
2wk						
4wk	1.09**					
8wk	1.22***	1.11***				
12wk	1.27***	1.16***	1.04**			
16wk	1.3***	1.19***	1.07**	1.02**		
20wk	1.3***	1.19***	1.07**	1.03**	1.01	
24wk	1.32***	1.21***	1.08***	1.04**	1.02*	1.01*

Parietal cortex						
	2wk	4wk	8wk	12wk	16wk	20wk
2wk						
4wk	1.08***					
8wk	1.19***	1.1***				
12wk	1.24***	1.15***	1.04**			
16wk	1.27***	1.17***	1.06**	1.02*		
20wk	1.27***	1.18***	1.07**	1.02*	1.00	
24wk	1.28***	1.18***	1.07**	1.03*	1.01	1.01

Frontal cortex						
	2wk	4wk	8wk	12wk	16wk	20wk
2wk						
4wk	1.10***					
8wk	1.20***	1.1***				
12wk	1.27***	1.16***	1.06**			
16wk	1.32***	1.20***	1.09***	1.04**		
20wk	1.34***	1.22***	1.11***	1.05**	1.02*	
24wk	1.36***	1.24***	1.13***	1.07***	1.03**	1.02**

Temporal auditory cortex						
	2wk	4wk	8wk	12wk	16wk	20wk
2wk						
4wk	1.07**					
8wk	1.23***	1.14***				
12wk	1.29***	1.2***	1.05**			
16wk	1.31***	1.22***	1.07***	1.02*		
20wk	1.34***	1.24***	1.09***	1.04**	1.02*	
24wk	1.36***	1.27***	1.11***	1.05***	1.04**	1.02*

Occipital cortex						
	2wk	4wk	8wk	12wk	16wk	20wk
2wk						
4wk	1.08**					
8wk	1.18***	1.09***				
12wk	1.2***	1.11***	1.02*			
16wk	1.19***	1.11***	1.01	1.00		
20wk	1.17***	1.09**	1.00	0.98*	0.98*	
24wk	1.16***	1.08**	0.98	0.97**	0.97**	0.99*

$p = 6.703 \times 10^{-10}$ , -2 Log Likelihood: 2024.94; Fig. 2B(d)). The volume showed a significant increase from 2 to 16 weeks (1.3-fold increase,  $p = 3.69 \times 10^{-15}$ ), and then again between 20–24 weeks of age (1.01-fold increase,  $p = 2.15 \times 10^{-3}$ ; see Table 1 and Fig. 2B(d) for details). This region showed an average 32 % (1.32-fold) volume increase between 2–24 weeks ( $p = 2.59 \times 10^{-15}$ ).

Development of the temporal visual area did not vary by hemisphere ( $F(1,267.004) = 2.166, p = 0.142$ ).

When ICV was included as a covariate in the model, the temporal visual cortex growth remained significant and was best described by a linear fit ( $F(1,118.629) = 12.283, p = 0.001$ , -2 Log Likelihood: 2014.11). These results suggest region-specific growth not fully explained by overall brain growth, but that the timing of those changes may not differ from general growth.

### 3.4.2. Temporal auditory area

The temporal auditory area showed significant age-related volumetric changes, best characterized by a cubic function ( $F(1,123.011) = 50.923, p = 7.274 \times 10^{-11}$ , -2 Log Likelihood: 1820.85; Fig. 2B(e)). The volume increased significantly and substantially from 2 to 24 weeks of life (36 % [or 1.36-fold] increase,  $p = 1.06 \times 10^{-17}$ ; see Table 1 and Fig. 2B(e) for detailed fold changes between ages and pairwise comparisons p-values). Although there was a trend for the growth in this area to vary by hemisphere, these differences did not reach statistical significance ( $F(1,266.993) = 3.395, p = 0.067$ ).

Age-related effects disappeared when ICV was included in the model as a covariate ( $F(1,110.882) = 0.480, p = 0.490$ ), suggesting that the temporal auditory cortex volume increases were explained by overall brain growth and were not region-specific.

### 3.5. Parietal cortex

A significant effect of age was observed in the parietal cortex ( $F(1,123.032) = 42.503, p = 1.637 \times 10^{-9}$ , -2 Log Likelihood: 2025.53), with volume growth best characterized by a cubic function (Fig. 2B(f)). Parietal cortex volume showed a significant increase from 2 to 16 weeks (1.27-fold increase,  $p = 7.49 \times 10^{-17}$ ; see Table 1 and Fig. 2B(f) for detailed volume fold increases between specific ages and pairwise comparisons p values), at which point the growth levels off. The parietal cortex showed an average 28 % (1.28-fold) volume increase between 2–24 weeks ( $p = 1.86 \times 10^{-16}$ ). Development of the parietal cortex did not vary by hemisphere ( $F(1,267.003) = 0.185, p = 0.668$ ).

When controlling for ICV, the developmental growth of parietal cortex volume remained significant and was best described with a linear function ( $F(1,114.293) = 15.015, p = 1.78 \times 10^{-4}$ , -2 Log Likelihood: 2067.67), suggesting that the volume increases are not explained by overall brain growth, but region-specific; although the timing of those changes may not differ from general growth.

### 3.6. Occipital cortex

Significant age-related growth was also identified in the occipital cortex ( $F(1,123.023) = 85.892, p = 7.901 \times 10^{-16}$ , -2 Log Likelihood: 2117.19), best characterized by a cubic function (Fig. 2B(g)). The volume of the occipital cortex increased during the first 3 months of life (1.2-fold increase from 2 to 12 weeks,  $p = 6.00 \times 10^{-14}$ ), followed by a plateau from 12 to 16 weeks, and a small but significant volumetric decrease from 16 to 24 weeks (0.97-fold change,  $p = 6.86 \times 10^{-7}$ ). This cortical area showed the smallest overall volumetric growth 2–24 weeks of age (16 % [or 1.16-fold] increase,  $p = 3.97 \times 10^{-13}$ ; see Table 1 and

Fig. 2B(g) for detailed volume fold changes between ages and pairwise comparisons  $p$ -values). Although there was a trend for laterality of growth between hemispheres, this difference failed to reach statistical significance ( $F(1,267.004) = 3.722, p=0.055$ ).

When controlling for ICV, the developmental growth of the occipital cortex remained significant, but was best described by a linear function ( $F(1,112.617) = 333.716, p = 1.826 \times 10^{-35}, -2 \text{ Log Likelihood: } 2164.66$ ). This suggests that the age-related changes in occipital volume are region-specific and not fully explained by overall brain growth changes during these 6 postnatal months, although the timing of those changes may not differ from general brain growth.

### 3.7. Summary of results

Results of the present study suggest that overall brain volume (measured as ICV) and all cortical lobes studied show volumetric development that follows a cubic growth curve, but maturational timelines and magnitude of volume growth are region-specific. ICV grew an average of 39 % between 2–24 weeks, but the most significant growth took place during the first 20 weeks, leveling off thereafter. The prefrontal, frontal, and temporal –visual and auditory– cortices, like the ICV, showed sharp volume increases between 2–24 weeks (between 32 %–36 %), in contrast with the smaller growth shown by the parietal (28 %) and occipital (16 %) cortices. Cortical lobes with blunted growth (occipital, parietal) also showed earlier growth, and plateau at 12 weeks –decreasing thereafter– (occipital) or 16 weeks (parietal). Prefrontal and temporal visual cortices showed significant growth between 2–16 weeks, followed by a plateau and further growth from 20 to 24 weeks. And frontal and temporal auditory cortices volumes increased constantly from 2 to 24 weeks. Consistent with hemispheric differences found only after 6 months of age in previous NHP studies (Scott et al., 2016; Kim et al., 2020), we did not find robust hemispheric differences in any cortical regions, though for certain cortical areas (temporal auditory, occipital), hemispheric differences fell just short of significance. Most of the volume growth in all these cortical areas (75–80 %) took place in the first 12 weeks, similarly to the cortical growth reported in human infants (Lenroot and Giedd, 2006; Knickmeyer et al., 2008), which takes place mainly in the first 12 months of life. However, in contrast to reports in human infants, we did not find significant hemispheric differences in any of the cortical areas studied. These striking similarities in cortical developmental trajectories provide strong support for NHPs as translational models of human neurodevelopmental disorders.

## 4. Discussion

The goal of this study was to investigate the developmental trajectories of growth of different cortical regions in comparison to overall brain structural volume changes in typically developing, socially-housed, infant macaques. This provides foundational information necessary to establish future NHP models of human neurodevelopmental disorders. Volumetric changes of cortical brain regions were examined longitudinally from 2 weeks until 6 months of age (equivalent to 2 years in humans) in 21 male rhesus macaques, using a within-subject experimental design. Structural growth in the prefrontal, frontal, parietal, occipital, and temporal cortex (visual and auditory) was examined using MRI techniques and age-specific infant macaque brain atlases developed by our group. Our findings suggest a substantial increase in total brain and cortical volume growth during the first 12 weeks with slower increases from 12 to 24 weeks, although maturational timelines and growth rates were region-specific. These developmental trajectories show similarities to cortical growth in human infants, providing foundational information for translational studies.

Overall, the current findings parallel those of earlier studies revealing an expansion of total brain and cerebral lobe volumes from 2 to 6 months of age, but particularly fast during the first 12 postnatal

weeks in rhesus macaques (Malkova et al., 2006; Payne et al., 2010; Scott et al., 2016; Liu et al., 2019; Kim et al., 2020). In addition, using a full longitudinal design with densely scan sampling at the earlier ages (2, 4, 8, 12 weeks), high resolution scan sequences and minimized artifacts, as well as age-specific infant atlases and processing pipelines that use both T1- and T2-weighted data in multi-modal fashion to optimize tissue segmentation and cortical parcellations at these early ages, our study provides novel findings demonstrating a substantial overall brain and cortical growth at the earliest ages between 1–4 weeks of age. This growth spurt continued during the first 12 weeks of age, followed by region-specific differences in developmental trajectory thereafter. Our results support additional findings of earlier studies showing that brain development in infant macaques reaches a plateau around 6 months of age (Malkova et al., 2006; Liu et al., 2015; Scott et al., 2016; Liu et al., 2019; Kim et al., 2020), although the present study does not have evidence beyond 6 months of age.

These volumetric changes likely reflect pronounced remodeling of GM and WM within cortical areas during this early postnatal period. Detailed knowledge of postnatal structural development of specific cortical areas in primates is still limited, but it is believed that cortical development reflects similar structural changes that may follow region-specific maturational timelines and growth rates. The development of cortical areas has been divided in four broad phases in the cortical histogenesis: (1) the early fetal phase of progressive of intensive proliferation, migration, and neuronal differentiation; (2) late fetal phase, characterized by transient patterns of cortical organization; (3) the early postnatal phase of reorganization and overproduction of cortical circuitry elements; (4) the phase of late postnatal maturation with dendritic pruning and refinement of cortical circuits. Below we will review the main structural findings of this study.

### 4.1. Prefrontal lobe

In the present study, the PFC showed a substantial volumetric growth from 2 to 16 weeks of age, followed by a plateau phase and further significant growth from 20 to 24 weeks. In primates (see for reviews (Mrzljak et al., 1990; Kostovic et al., 2008), neurogenesis in the PFC begins prenatally with proliferation and migration of cells from the subplate that will level off in the first postnatal months. Thus, as compared to other cortical regions, the PFC of the newborn infant has a well-developed subplate (Mrzljak et al., 1988; Kostovic et al., 1989), which only gradually disappears during the first 6 postnatal months. The early postnatal period and infancy are characterized by a reorganization and over production of the different cortical circuitry elements with the progressive differentiation of pyramidal neurons in both the supra-granular and infragranular layers along with neuronal death and rapid formation and elimination of synapses (Goldman-Rakic, 1987; Lenroot and Giedd, 2006; Kuboshima-Amemori and Sawaguchi, 2007). Interestingly, the time courses of such neuronal and synaptic formation and elimination are considerably different across diverse cortical areas, with the PFC generally being one of the latest (Huttenlocher and Dabholkar, 1997; Gogtay et al., 2004). After birth, there is rapid and massive production of spines that increases steadily and reaches its maximum around 1.5 years in monkeys (2.5 years in human). Interestingly, in areas 9 and 46 of the rhesus monkey PFC, the spine density of layer III pyramidal neurons increases by 50 % during the first two postnatal months, remaining at a plateau through 1.5 years of age, and then decreasing over the peripubertal age range until stable adult levels are achieved (Rakic et al., 1986; Goldman-Rakic, 1987; Bourgeois et al., 1994; Anderson et al., 1995; Hoftman and Lewis, 2011). At the same time, major changes of prefrontal WM also occur and are characterized by the cessation of growth of major subcortical fibers, the dynamic growth of short cortical axons connecting cortical columns, and the exuberance and then pronounced reduction of callosal axons, from 180 million to 50 million (Innocenti and Price, 2005), which occurs much before the reduction in number of synapses. Thus, although the

continuous increase in spinogenesis and synaptogenesis may be related to the growth of PFC volume from 2 weeks to 6 months, the marked reduction in callosal fibers may be associated to the appearance of a short plateau in volumetric changes between 16 and 20 weeks. Given that the PFC plays crucial role in several cognitive functions (e.g. working memory, selective and spatial attention, decision-making, emotion regulation) that are highly developed in primates, including humans and macaque species (Goldman-Rakic, 1987; Diamond and Goldman-Rakic, 1989; Fuster, 1997; Rolls, 2004; Krangelbach, 2005), the substantial increase in PFC volume during the first 6 months parallels the progressive maturation of PFC functions described in the literature. For example, the ability to perform working memory tasks first appears between 2 and 4 months of age in rhesus monkeys and then progressively improves to reach adult levels of performance after 3 years of age (Goldman-Rakic, 1987; Diamond and Goldman-Rakic, 1989).

#### 4.2. Frontal lobe

As the PFC and other cortical areas, most of the frontal cortex progressive proliferation, migration, and neuronal differentiation events occur prenatally. The early postnatal phase is characterized by reorganization and overproduction of cortical circuitry elements with intensive dendritic growth, overproduction of synapses that lasts for 2 years. In contrast to the PFC, the frontal lobe developmental trajectory indicates, instead, a continuous volume increase from 2 to 24 weeks of postnatal life in infant macaques, with the most dramatic growth occurring during the first 12–16 weeks. Although a precocial species, infant rhesus macaques are not born equipped with mature motor skills (such as walking, standing, or sitting up), adult postural and locomotor skills develop during the first 2–3 months of life (Dunbar and Badam, 1998). By the time weaning and exploration of the environment begins (around 10–12 weeks of life (Suomi, 2005), infants have developed most of the basic adult postural and locomotor patterns and their movements become increasingly coordinated and independent (Dunbar and Badam, 1998). The substantial increase of the frontal lobe volume during the first 12–16 weeks of life parallels (and likely support) the motor developmental milestones described in the literature, and as for other cortical areas is likely related to increases in synaptogenesis and myelination.

#### 4.3. Temporal lobe

The temporal visual area, which contains cortical areas part of the ventral object pathway, shows continuous, significant, volume increase from 2 to 16 weeks, followed by a plateau and further growth between 20–24 weeks. Increasing volume of the temporal visual cortex is consistent with reports of synaptic proliferation and rapid dendritic spine increase observed in many cortical areas during the first 12 weeks of life (Rakic et al., 1986), with a sharp increase in metabolic activity reported in the most posterior visual cortical areas from 8 to 16 weeks (Bachevalier et al., 1991; Distler et al., 1996) and increasing FC between the most caudal visual areas during the first 12 weeks (Kovacs-Balint et al., 2019). In contrast, rostral visual areas and those in the inferior temporal cortex show a more protracted increase in metabolic activity (Bachevalier et al., 1991) and in FC from 2 to 12 weeks. Altogether, these structural and functional maturational changes may enable more precise object discrimination and face evaluation, which emerges during the first months of macaque life (Lutz et al., 1998; Kuwahata et al., 2004; Muschinski et al., 2016; Parr et al., 2016).

The volume of the temporal auditory cortex -which contains brain regions responsible for auditory processing and motion perception, such as body movement, as well as face- and eye-movement detection-, increased substantially and constantly from 2 to 24 weeks, although most of the volume growth (80 %) takes place from 2 to 12 weeks, like in the other cortical areas. These volumetric developmental changes parallel: 1) the development of motion direction detection, which emerges around 2 weeks and continues to improve until around 12 weeks

(Kiorpes and Movshon, 2004; Kiorpes et al., 2012); and 2) the ability to evaluate direct-gaze faces, which emerges around 12 weeks of age, as well (Mendelson et al., 1982; Muschinski et al., 2016).

#### 4.4. Parietal lobe

Developmental trajectory of the parietal lobe showed increasing volume until 16 weeks, after which point the growth leveled off. This is somewhat earlier than what Scott et al. (2016) found in their study. They showed that near maximal parietal cortex volume is achieved by 9–10 months of age, with little or no increase thereafter. This cortical lobe, together with the occipital cortex, also showed the smallest growth of all cortical regions between 2–24 weeks. It also parallels the earliest maturation of metabolic activity in the posterior parietal areas as compared to the ventral temporal cortical areas (Distler et al., 1996). Studies in human infants revealed that areas within the parietal cortex are associated with controlling action -including the oculo-motor systems- and spatially-directed attention, and that visuo-motor exploration (such as reaching) starts to develop around 4 months of age (Milner and Goodale, 1995). Macaques around 1 month of age, which is roughly equivalent to 4 months in human infants, also start to increase exploration of their environment, spending more time engaging in social interactions with other group members (Suomi, 2005). We assume that the steadily increase in parietal cortex volume from 2 to 12 weeks in the present study might aid the development of spatially directed attention in macaques.

#### 4.5. Occipital cortex

The observed volumetric changes in the occipital cortex were different from the above cortical regions. First, it was the cortical region with the smallest volume growth from 2 to 24 weeks (only 16 %). Second, whereas the volume of most cortical areas continued to increase during the first 6 months of life, the volume of the occipital cortex increased from 2 to 12 weeks of life, followed by a small, but significant, volumetric decrease thereafter. This finding is consistent with previous reports in rhesus monkeys, showing that the volume of the occipital cortex declines through the first 5 years of life (Scott et al., 2016). In addition, a previous functional MRI study in a subset of infant macaques of the present study revealed strengthening of resting-state FC between occipital visual cortical areas (V1-V3) during the first 3 months of life (Kovacs-Balint et al., 2019), which seems to parallel the increasing occipital lobe volume found in the present study in the same time period.

The volumetric trajectory of the occipital lobe largely follows the structural changes that have been reported in this early postnatal period (see for review White and Fitzpatrick, 2007). In rhesus monkey V1, for example, the phase of rapid synaptogenesis ensues late in the third trimester before birth and continues exponentially over the first two postnatal months before achieving a stable density of synaptic profiles in neuropil by the third month that persists until adolescence (Bourgeois et al., 1989). This explosive increase in V1 synaptogenesis is accompanied by a comparable increase in the outgrowth of intrinsic axonal projections in V1. Thus, the long-range horizontal connections in layer 2/3 that are known to establish connections among cortical columns with similar response properties (Malach et al., 1993) are elaborated and achieve their mature distributions over this same period of postnatal development. Adult-like distributions of intrinsic connections occur at about the same time in postnatal development when the rate of synaptogenesis begins to decline and synaptic densities in layer 2/3 of V1 reach a stable level. Thus, the volumetric changes of the occipital lobe early on likely reflects a combination of increasing number of axons/-synapses within the visual cortical mantle as well as myelination of WM, and probably serves as a basis for the early development of visual skills. For example, visual object discrimination develops fairly early in rhesus macaques, around 3–6 months of age (Rakic et al., 1986; Goldman-Rakic, 1987).



To sum up, our results show that the volume of the cortical regions studied here increased substantially during the first 6 months -particularly during the first 3 months- of postnatal life in rhesus macaques, although with region-specific maturational timelines and growth rates. The occipital cortex showed a particularly different developmental trajectory, with more rapid and less robust volume increases than the other cortical areas, and a slowly decreasing volume after 12 weeks of age. The studied cortical regions followed region-specific developmental trajectories, except for the PFC and the temporal auditory area, whose growth mirrored the overall brain growth during this 6-months period. Although earlier histopathology studies revealed increased synaptic density between 2–4 months of life, structural MRI and DTI studies revealed a simultaneous increase in WM volume and myelination during the first 6 months of life in rhesus macaques (Malkova et al., 2006; Knickmeyer et al., 2010; Payne et al., 2010; Liu et al., 2015; Scott et al., 2016). Given the different developmental trajectories of the GM and WM noted in earlier human studies (Knickmeyer et al., 2008; Geng et al., 2012; Gilmore et al., 2012; Dean et al., 2014; O’Muircheartaigh et al., 2014; Dean et al., 2015; Deoni et al., 2016), future analyses of the WM volumes in the cortical areas we reported here are clearly needed to more precisely characterize the volumetric changes we observed in the present study.

The developmental trajectories of cortical areas in infant monkeys from birth to 6 months of age parallel those reported in human infants from early postnatal months to 2 years. For example, neuroimaging studies revealed rapid increases in total brain and WM volumes in human infants during the first 2 years of life, and in infant macaques during the first 6 months of life -although the growth is much faster during the first year of life in humans- (Malkova et al., 2006; Knickmeyer et al., 2008; Dean et al., 2014; O’Muircheartaigh et al., 2014; Dean et al., 2015; Deoni et al., 2016; Scott et al., 2016). In addition, histopathological investigations showed that PFC synaptogenesis reaches a peak synaptic density around 15 months of age in human infants, and around 4 months of age in infant macaques, (Rakic et al., 1986; Goldman-Rakic, 1987; Huttenlocher and Dabholkar, 1997). These results suggest that the brain develops similarly during infancy in humans and macaques, and that macaque infant monkeys provide a useful translational model to better understand the intrinsic structural and circuitry cortical changes that are associated with brain volumetric changes in human infants.

## 5. Limitations

First, only male subjects were used in this study to avoid potential sex differences in brain development and increase our sample size, but also to assess neurodevelopmental changes important for ASD-related social deficits where the prevalence rate is greater in males than females (Christensen et al., 2016). Second, the exclusion of infants from extreme high or low social ranks might have masked individual variability in brain maturation potentially due to differences in social hierarchy. Therefore, future studies are needed to establish (1) the developmental trajectories at later ages (>6 months), (2) differences due to extreme social status and (3) in females, as well as (4) to identify cellular/molecular mechanisms responsible for the cortical region-specific volumetric changes identified during early infancy, and the growth acceleration detected at certain ages.

Despite the limitations of this study and the questions that remain for future studies, the striking similarities in cortical developmental trajectories between infant macaques and humans provide a strong support for NHPs as translational models of human neurodevelopmental disorders.

## Declaration of Competing Interest

The authors reported no declarations of interest.

## Acknowledgements

This study was conducted with invaluable help from Dr. Lisa Parr, Jenna Brooks, Marie Collantes, Shannon Moss, Trina Jonesteller, Ruiyue Hong and Madison Wallace at the Yerkes National Primate Research Center (YNPRC) Field Station, and Ruth Connelly, Sudeep Patel and Doty Kempf at the YNPRC Imaging Center. This work was supported by the National Institutes of Health (NIH) grant numbers MH100029, MH078105-01S1, MH091645, U54 HD079124, EB027147, MH119251, MH118534, MH118285 and the NIH’s Office of the Director, Office of Research Infrastructure Programs, P51OD011132 (YNPRC Base Grant). The YNPRC is fully accredited by AAALAC, International.

## References

- Anderson, S.A., Classey, J.D., Conde, F., Lund, J.S., Lewis, D.A., 1995. Synchronous development of pyramidal neuron dendritic spines and parvalbumin-immunoreactive chandelier neuron axon terminals in layer III of monkey prefrontal cortex. *Neuroscience* 67, 7–22.
- Bachevalier, J., Hagger, C., Mishkin, M., 1991. Functional maturation of the occipitotemporal pathway in infant rhesus monkeys. *Brain work and mental activity*. In: Lassen, N., Ingvar, D., Raichle, M., Friberg, L. (Eds.), *Alfred Benzon Symposium* 31. Copenhagen, Munksgaard, pp. 231–240.
- Baio, J., Wiggins, L., Christensen, D.L., Maenner, M.J., Daniels, J., Warren, Z., Kurzius-Spencer, M., Zahorodny, W., Robinson Rosenberg, C., White, T., Durkin, M.S., Imm, P., Nikolaou, L., Yeargin-Allsopp, M., Lee, L.C., Harrington, R., Lopez, M., Fitzgerald, R.T., Hewitt, A., Pettygrove, S., Constantino, J.N., Vehorn, A., Shenouda, J., Hall-Lande, J., Van Naarden Braun, K., Dowling, N.F., 2018. Prevalence of autism spectrum disorder among children aged 8 years - autism and developmental disabilities monitoring network, 11 sites, United States, 2014. *Surveill. Summ.* 67, 1–23.
- Bauman, M.D., Schumann, C.M., 2018. Advances in nonhuman primate models of autism: integrating neuroscience and behavior. *Exp. Neurol.* 299, 252–265.
- Bourgeois, J.P., Jastreboff, P.J., Rakic, P., 1989. Synaptogenesis in visual cortex of normal and preterm monkeys: evidence for intrinsic regulation of synaptic overproduction. *Proc Natl Acad Sci U S A.* 86, 4297–4301.
- Bourgeois, J.P., Goldman-Rakic, P.S., Rakic, P., 1994. Synaptogenesis in the prefrontal cortex of rhesus monkeys. *Cereb. Cortex* 4, 78–96.
- Casey, B.J., Giedd, J.N., Thomas, K.M., 2000. Structural and functional brain development and its relation to cognitive development. *Biol. Psychol.* 54, 241–257.
- Casey, B.J., Duhoux, S., Malter Cohen, M., 2010. Adolescence: what do transmission, transition, and translation have to do with it? *Neuron.* 67, 749–760.
- Christensen, D.L., Baio, J., Braun, K.V., Bilder, D., Charles, J., Constantino, M.D., Daniels, J., Durkin, M.S., Fitzgerald, R.T., Kurzius-Spencer, M., Lee, L., Pettygrove, S., Robinson, C., Schulz, E., Wells, C., Wingate, M.S., Zahorodny, W., Yeargin-Allsopp, M., 2016. Prevalence and characteristics of autism spectrum disorder among children aged 8 years — autism and developmental disabilities monitoring network, 11 sites, United States, 2012. *Surveillance Summaries.* 65, 1–23.
- Dean 3rd, D.C., O’Muircheartaigh, J., Dirks, H., Waskiewicz, N., Lehman, K., Walker, L., Han, M., Deoni, S.C., 2014. Modeling healthy male white matter and myelin development: 3 through 60 months of age. *Neuroimage* 84, 742–752.
- Dean 3rd, D.C., O’Muircheartaigh, J., Dirks, H., Waskiewicz, N., Walker, L., Doernberg, E., Piryatinsky, I., Deoni, S.C., 2015. Characterizing longitudinal white matter development during early childhood. *Brain Struct. Funct.* 220, 1921–1933.
- Deoni, S.C., Mercure, E., Blasi, A., Gasston, D., Thomson, A., Johnson, M., Williams, S.C., Murphy, D.G., 2011. Mapping infant brain myelination with magnetic resonance imaging. *J. Neurosci.* 31, 784–791.
- Deoni, S.C., O’Muircheartaigh, J., Elison, J.T., Walker, L., Doernberg, E., Waskiewicz, N., Dirks, H., Piryatinsky, I., Dean 3rd, D.C., Jumble, N.L., 2016. White matter maturation profiles through early childhood predict general cognitive ability. *Brain Struct. Funct.* 221, 1189–1203.
- Diamond, A., Goldman-Rakic, P.S., 1989. Comparison of human infants and rhesus monkeys on Piaget’s AB task: evidence for dependence on dorsolateral prefrontal cortex. *Exp. Brain Res.* 74, 24–40.
- Distler, C., Bachevalier, J., Kennedy, C., Mishkin, M., Ungerleider, L.G., 1996. Functional development of the corticocortical pathway for motion analysis in the macaque monkey: a 14C-2-deoxyglucose study. *Cereb. Cortex* 6, 184–195.
- Dunbar, D.C., Badam, G.L., 1998. Development of posture and locomotion in free-ranging primates. *Neurosci. Biobehav. Rev.* 22, 541–546.
- Fuster, J., 1997. The prefrontal cortex. *Journal.*
- Gao, W., Zhu, H., Giovanello, K.S., Smith, J.K., Shen, D., Gilmore, J.H., Lin, W., 2009. Evidence on the emergence of the brain’s default network from 2-week-old to 2-year-old healthy pediatric subjects. *Proc Natl Acad Sci U S A.* 106, 6790–6795.
- Gao, W., Alcauter, S., Smith, J.K., Gilmore, J.H., Lin, W., 2015. Development of human brain cortical network architecture during infancy. *Brain Struct. Funct.* 220, 1173–1186.
- Geng, X., Gouttard, S., Sharma, A., Gu, H., Styner, M., Lin, W., Gerig, G., Gilmore, J.H., 2012. Quantitative tract-based white matter development from birth to age 2 years. *Neuroimage.* 61, 542–557.
- Giedd, J.N., Rapoport, J.L., 2010. Structural MRI of pediatric brain development: what have we learned and where are we going? *Neuron.* 67, 728–734.

- Giedd, J.N., Blumenthal, J., Jeffries, N.O., Castellanos, F.X., Liu, H., Zijdenbos, A., Paus, T., Evans, A.C., Rapoport, J.L., 1999. Brain development during childhood and adolescence: a longitudinal MRI study. *Nat. Neurosci.* 2, 861–863.
- Gilmore, J.H., Shi, F., Woolson, S.L., Knickmeyer, R.C., Short, S.J., Lin, W., Zhu, H., Hamer, R.M., Styner, M., Shen, D., 2012. Longitudinal development of cortical and subcortical gray matter from birth to 2 years. *Cereb. Cortex* 22, 2478–2485.
- Gilmore, J.H., Langworthy, B., Girault, J.B., Fine, J., Jha, S.C., Kim, S.H., Cornea, E., Styner, M., 2020. Individual variation of human cortical structure is established in the first year of life. *Biol. Psychiatry Cogn. Neurosci. Neuroimaging* 5, 971–980.
- Gogtay, N., Giedd, J.N., Lusk, L., Hayashi, K.M., Greenstein, D., Vaituzis, A.C., Nugent 3rd, T.F., Herman, D.H., Clasen, L.S., Toga, A.W., Rapoport, J.L., Thompson, P.M., 2004. Dynamic mapping of human cortical development during childhood through early adulthood. *Proc Natl Acad Sci U S A.* 101, 8174–8179.
- Goldman-Rakic, P.S., 1987. Development of cortical circuitry and cognitive function. *Child Dev.* 58, 601–622.
- Hofman, G.D., Lewis, D.A., 2011. Postnatal developmental trajectories of neural circuits in the primate prefrontal cortex: identifying sensitive periods for vulnerability to schizophrenia. *Schizophr. Bull.* 37, 493–503.
- Howell, B.R., Ahn, M., Shi, Y., Godfrey, J.R., Hu, X., Zhu, H., Styner, M., Sanchez, M.M., 2019. Disentangling the effects of early caregiving experience and heritable factors on brain white matter development in rhesus monkeys. *Neuroimage* 197, 625–642.
- Huttenlocher, P.R., Dabholkar, A.S., 1997. Regional differences in synaptogenesis in human cerebral cortex. *J. Comp. Neurol.* 387, 167–178.
- Innocenti, G.M., Price, D.J., 2005. Exuberance in the development of cortical networks. *Nat. Rev. Neurosci.* 6, 955–965.
- Kim, J., Jung, Y., Barcus, R., Bachevalier, J.H., Sanchez, M.M., Nader, M.A., Whitlow, C. T., 2020. Rhesus macaque brain developmental trajectory: a longitudinal analysis using tensor-based structural morphometry and diffusion tensor imaging. *Cereb. Cortex* 30, 4325–4335.
- Kiorpes, L., Movshon, J.A., 2004. Development of sensitivity to visual motion in macaque monkeys. *Vis. Neurosci.* 21, 851–859.
- Kiorpes, L., Price, T., Hall-Haro, C., Movshon, J.A., 2012. Development of sensitivity to global form and motion in macaque monkeys (*Macaca nemestrina*). *Vision Res.* 63, 34–42.
- Knickmeyer, R.C., Gouttard, S., Kang, C., Evans, D., Wilber, K., Smith, J.K., Hamer, R.M., Lin, W., Gerig, G., Gilmore, J.H., 2008. A structural MRI study of human brain development from birth to 2 years. *J. Neurosci.* 28, 12176–12182.
- Knickmeyer, R.C., Styner, M., Short, S.J., Lubach, G.R., Kang, C., Hamer, R., Coe, C.L., Gilmore, J.H., 2010. Maturational trajectories of cortical brain development through the pubertal transition: unique species and sex differences in the monkey revealed through structural magnetic resonance imaging. *Cereb. Cortex* 20, 1053–1063.
- Kostovic, I., Lukinovic, N., Judas, M., Bogdanovic, N., Mrzljak, L., Zecevic, N., Kubat, M., 1989. Structural basis of the developmental plasticity in the human cerebral cortex: the role of the transient subplate zone. *Metab. Brain Dis.* 4, 17–23.
- Kostovic, I., Judas, M., Petanjek, Z., 2008. Structural development of the human prefrontal cortex. *Journal.* 213–236.
- Kovacs-Balint, Z., Feczko, E., Pincus, M., Earl, E., Miranda-Dominguez, O., Howell, B., Morin, E., Maltbie, E., Li, L., Steele, J., Styner, M., Bachevalier, J., Fair, D., Sanchez, M., 2019. Early developmental plasticity of functional connectivity along the visual pathways in Rhesus monkeys. *Cereb. Cortex* 29, 3514–3526.
- Kringelbach, M.L., 2005. The human orbitofrontal cortex: linking reward to hedonic experience. *Nat. Rev. Neurosci.* 6, 691–702.
- Kuboshima-Amemori, S., Sawaguchi, T., 2007. Plasticity of the primate prefrontal cortex. *Neuroscientist.* 13, 229–240.
- Kuwahata, H., Adachi, I., Fujita, K., Tomonaga, M., Matsuzawa, T., 2004. Development of schematic face preference in macaque monkeys. *Behav. Processes* 66, 17–21.
- Lenroot, R.K., Giedd, J.N., 2006. Brain development in children and adolescents: insights from anatomical magnetic resonance imaging. *Neurosci. Biobehav. Rev.* 30, 718–729.
- Li, G., Wang, L., Shi, F., Lyall, A.E., Lin, W., Gilmore, J.H., Shen, D., 2014. Mapping longitudinal development of local cortical gyrification in infants from birth to 2 years of age. *J. Neurosci.* 34, 4228–4238.
- Lin, W., Zhu, Q., Gao, W., Chen, Y., Toh, C.H., Styner, M., Gerig, G., Smith, J.K., Biswal, B., Gilmore, J.H., 2008. Functional connectivity MR imaging reveals cortical functional connectivity in the developing brain. *AJNR Am. J. Neuroradiol.* 29, 1883–1889.
- Liu, C., Tian, X., Liu, H., Mo, Y., Bai, F., Zhao, X., Ma, Y., Wang, J., 2015. Rhesus monkey brain development during late infancy and the effect of phencyclidine: a longitudinal MRI and DTI study. *Neuroimage.* 107, 65–75.
- Liu, Z., Neuringer, M., Erdman Jr, J.W., Kuchan, M.J., Renner, L., Johnson, E.E., Wang, X., Kroenke, C.D., 2019. The effects of breastfeeding versus formula-feeding on cerebral cortex maturation in infant rhesus macaques. *Neuroimage.* 184, 372–385.
- Loomes, R., Hull, L., Mandy, W.P.L., 2017. What is the male-to-female ratio in autism Spectrum disorder? A systematic review and meta-analysis. *J. Am. Acad. Child Adolesc. Psychiatry* 56, 466–474.
- Lutz, C.K., Lockard, J.S., Gunderson, V.M., Grant, K.S., 1998. Infant monkeys' visual responses to drawings of normal and distorted faces. *Am. J. Primatol.* 44, 169–174.
- Malach, R., Amir, Y., Harel, M., Grinvald, A., 1993. Relationship between intrinsic connections and functional architecture revealed by optical imaging and in vivo targeted biocytin injections in primate striate cortex. *Proc Natl Acad Sci U S A.* 90, 10469–10473.
- Malkova, L., Heuer, E., Saunders, R.C., 2006. Longitudinal magnetic resonance imaging study of rhesus monkey brain development. *Eur. J. Neurosci.* 24, 3204–3212.
- Mendelson, M.J., Haith, M.M., Goldman-Rakic, P.S., 1982. Face scanning and responsiveness to social cues in infant rhesus-monkeys. *Dev. Psychol.* 18, 222–228.
- Milner, A.D., Goodale, M.A., 1995. The visual brain in action. *Journal.*
- Morin, E., Howell, B., Feczko, E., Earl, E., Pincus, M., Reding, K., Kovacs-Balint, Z., Meyer, J.S., Styner, M., Fair, D., Sanchez, M., 2021. Developmental outcomes of early adverse care on amygdala functional connectivity in nonhuman primates. *Dev. Psychopathol.* In Press.
- Mrzljak, L., Uylings, H.B., Kostovic, I., Van Eden, C.G., 1988. Prenatal development of neurons in the human prefrontal cortex: I. A qualitative Golgi study. *J. Comp. Neurol.* 271, 355–386.
- Mrzljak, L., Uylings, H.B., Van Eden, C.G., Judas, M., 1990. Neuronal development in human prefrontal cortex in prenatal and postnatal stages. *Prog. Brain Res.* 85, 185–222.
- Muschinski, J., Feczko, E., Brooks, J.M., Collantes, M., Heitz, T.R., Parr, L.A., 2016. The development of visual preferences for direct versus averted gaze faces in infant macaques (*Macaca mulatta*). *Dev. Psychobiol.* 58, 926–936.
- O'Muircheartaigh, J., Dean 3rd, D.C., Ginstet, C.E., Walker, L., Waskiewicz, N., Lehman, K., Dirks, H., Piriyatinsky, I., Deoni, S.C., 2014. White matter development and early cognition in babies and toddlers. *Hum. Brain Mapp.* 35, 4475–4487.
- Parr, L.A., Murphy, L., Feczko, E., Brooks, J., Collantes, M., Heitz, T.R., 2016. Experience-dependent changes in the development of face preferences in infant rhesus monkeys. *Dev. Psychobiol.*
- Passingham, R., 2009. How good is the macaque monkey model of the human brain? *Curr. Opin. Neurobiol.* 19, 6–11.
- Payne, C., Machado, C.J., Bliwise, N.G., Bachevalier, J., 2010. Maturation of the hippocampal formation and amygdala in *Macaca mulatta*: a volumetric magnetic resonance imaging study. *Hippocampus.* 20, 922–935.
- Payne, C., Cirilli, L., Bachevalier, J., 2017. An MRI study of the corpus callosum in monkeys: developmental trajectories and effects of neonatal hippocampal and amygdala lesions. *Dev. Psychobiol.* 59, 495–506.
- Price, K.C., Coe, C.L., 2000. Maternal constraint on fetal growth patterns in the rhesus monkey (*Macaca mulatta*): the intergenerational link between mothers and daughters. *Hum. Reprod.* 15, 452–457.
- Rakic, P., Bourgeois, J.P., Eckenhoff, M.F., Zecevic, N., Goldman-Rakic, P.S., 1986. Concurrent overproduction of synapses in diverse regions of the primate cerebral cortex. *Science.* 232, 232–235.
- Raschle, N., Zuk, J., Ortiz-Mantilla, S., Sliva, D.D., Franceschi, A., Grant, P.E., Benasich, A.A., Gaab, N., 2012. Pediatric neuroimaging in early childhood and infancy: challenges and practical guidelines. *Ann. N. Y. Acad. Sci.* 1252, 43–50.
- Reding, K.M., Styner, M.M., Wilson, M.E., Toufexis, D., Sanchez, M.M., 2020. Social subordination alters estradiol-induced changes in cortico-limbic brain volumes in adult female rhesus monkeys. *Psychoneuroendocrinology.* 114, 104592.
- Remer, J., Croteau-Chonka, E., Dean 3rd, D.C., D'Arpino, S., Dirks, H., Whitley, D., Deoni, S.C.L., 2017. Quantifying cortical development in typically developing toddlers and young children, 1–6 years of age. *Neuroimage* 153, 246–261.
- Rilling, J.K., Insel, T.R., 1999. The primate neocortex in comparative perspective using magnetic resonance imaging. *J. Hum. Evol.* 37, 191–223.
- Rolls, E.T., 2004. The functions of the orbitofrontal cortex. *Brain Cogn.* 55, 11–29.
- Saleem, K.S., Logothetis, N.K., 2012. A combined MRI and histology atlas of the Rhesus monkey brain in stereotaxic coordinates. *Journal.*
- Scott, J.A., Grayson, D., Fletcher, E., Lee, A., Bauman, M.D., Schumann, C.M., Nucunore, M.H., Amaral, D.G., 2016. Longitudinal analysis of the developing rhesus monkey brain using magnetic resonance imaging: birth to adulthood. *Brain Struct. Funct.* 221, 2847–2871.
- Shi, Y., Budin, F., Yapuncich, E., Rumble, A., Young, J., Payne, C., Zhang, X., Hu, X., Godfrey, J., Howell, B., Sanchez, M., Styner, M., 2017. UNC-Emory Infant atlases for macaque brain image analysis: postnatal brain development through 12 months. *Front. Neurosci.* 10.
- Song, J.W., Mitchell, P.D., Kolasinski, J., Ellen Grant, P., Galaburda, A.M., Takahashi, E., 2015. Asymmetry of white matter pathways in developing human brains. *Cereb. Cortex* 25, 2883–2893.
- Styner, M., Knickmeyer, R., Joshi, S., Coe, C., Short, S.J., Gilmore, J., 2007. Automatic brain segmentation in rhesus monkeys. In: *Medical Imaging 2007: Image Processing.* Pts 1–3. 6512: L5122–L5122.
- Suomi, S.J., 2005. Mother-infant attachment, peer relationships, and the development of social networks in Rhesus monkeys. *Hum. Dev.* 48, 67–79.
- Tanaka, C., Matsui, M., Uematsu, A., Noguchi, K., Miyawaki, T., 2012. Developmental trajectories of the fronto-temporal lobes from infancy to early adulthood in healthy individuals. *Dev. Neurosci.* 34, 477–487.
- Wang, J., Vachet, C., Rumble, A., Gouttard, S., Ouziel, C., Perrot, E., Du, G., Huang, X., Gerig, G., Styner, M., 2014. Multi-atlas segmentation of subcortical brain structures via the AutoSeg software pipeline. *Front. Neuroinform.* 8, 7.
- Wang, F., Lian, C., Wu, Z., Zhang, H., Li, T., Meng, Y., Wang, L., Lin, W., Shen, D., Li, G., 2019. Developmental topography of cortical thickness during infancy. *Proc Natl Acad Sci U S A.* 116, 15855–15860.
- Wang, A., Bachevalier, J., Moss, S., Jones, W., 2020. Development of visual social engagement in infant monkeys from 1 to 24 weeks. *Dev. Cogn. Neurosci.* In press.
- White, L.E., Fitzpatrick, D., 2007. Vision and cortical map development. *Neuron.* 56, 327–338.