

**Acute Flaccid Myelitis Caused by Enterovirus D68 Unmasking Primary
Intracranial Tumour In a Previously Healthy Child.**

Instructive Case

Wajanat Jan FRCR,¹ Brynmor Jones FRCR,¹ Noor ul Owase Jeelani FRCS,²
Thomas S Jacques FRCPATH,³ Hermione Lyall FRCPCH,¹ Paul Randell MD,¹
Leena Mewasingh FRCPCH,¹ Elizabeth Whittaker MRCPCH.¹

Imperial College Healthcare NHS Trust¹, Great Ormond Street Hospital² and
University College London³, London, UK

Corresponding author: Dr. Wajanat Jan, FRCR. Department of Imaging,
Imperial College Healthcare NHS Trust, St Mary's Hospital, Praed Street,
Paddington, London W2 1NY. +4420 3311 1234. w.jan@nhs.net

Conflicts of Interest: The authors declare no conflict of interest.

Clinical History:

A previously healthy 2.5-years-old Caucasian female with 2 week history of fever and upper respiratory tract symptoms, presented with 1-day history of right sided facial weakness, neck pain and torticollis. There was no preceding history of insect bites, animal contacts or unwell contacts. Clinical examination showed a right lower motor neuron facial palsy. With a presumptive diagnosis of Bell's palsy, she was started on oral prednisolone (1mg/Kg) in the Emergency Department as a treatment for three days.

Over the next 48 hours, the clinical picture evolved into asymmetric progressive flaccid weakness. The right arm was flaccid with hardly any movements proximally (1/5 power at shoulder flexion/extension); distally there was some finger movements with gravity eliminated (2/5 grade). Tone in the left arm was normal with slight weakness (3/5 grade). The biceps, supinator and triceps reflexes were present and appeared normal in the left upper limb, in contrast to being particularly brisk in the right upper limb. Lower limbs power was 3/5 with normal tone, bilateral brisk reflexes (knee & ankle) and bilateral upgoing planters. She had marked truncal hypotonia with head lag, and was unable to sit up without support. Cranial nerves examination showed weakness of the right side of her face including right forehead (right lower motor neurone cranial nerve VII palsy) with the remainder of her cranial nerves assessment being normal.

She was admitted for further investigations. Cerebrospinal fluid (CSF) had 32 white cells (62% mononuclear), raised protein of 1.9 g/L (normal range 0.10 - 0.44 g/L), glucose of 3.8 mmol/L (normal range 1.8 - 4.7 mmol/L). Initial polymerase chain reaction tests (PCRs) including herpes simplex virus (HSV), Enterovirus and varicella zoster virus (VZV) were negative in CSF. Bloods were largely

unremarkable, including normal liver function tests and full blood count. Empiric treatment with acyclovir, amoxicillin and ceftriaxone was commenced.

MRI of the head and cervical cord (without IV contrast) performed on Day 3 (**Fig1 A-C**) revealed an extensive rhomboencephalitis and myelitis. Intravenous immunoglobulin (IVIg) 2g/kg was given on day 6 as there was no improvement; a course of Methylprednisolone (30mg/kg/day) was given from day 7-9.

Diagnostic work up for infections included respiratory viral panel, CSF viral panel, human immunodeficiency virus (HIV), toxoplasma, atypical bacteria, rickettsia and tick borne encephalitis serology (**Table 1**). An autoimmune screen was also sent (**Table 1**).

The nerve conduction study (NCS) showed no electrophysiological evidence of generalised large fibre polyneuropathy or myopathy. Electromyogram (EMG) examination of the right extensor digitorum demonstrated reduced recruitment of motor units and there was no voluntary activity in biceps. The right median and ulnar motor amplitudes were reduced compared to the contralateral side. Since the EMG did not show active denervation but rather markedly reduced recruitment due to the weakness, the findings likely reflect central limb weakness.

Repeat MRI on day 10 (**Fig1 D-F**) showed almost complete resolution of the inflammatory changes of the rhombencephalon and cord but persistent vermian abnormality with avid enhancement and space-occupying properties, raising the possibility of an unrelated primary tumour such as a pilocytic astrocytoma or low-grade glioneuronal tumour. Repeat CSF a day after MRI, showed 1 white cell and protein 0.84 g/L. The patient was referred for neuro-oncology MDT discussion.

Consensus opinion was that of persistent inflammation with discrepant response to treatment.

Subsequently, a five-days course of plasma exchange was undertaken to treat possible autoimmune encephalitis, but with limited improvement. The patient completed three weeks of IV ceftriaxone and IV acyclovir and two weeks of doxycycline, although ultimately there was no evidence of rickettsia or other atypical infections. As listeria PCR was negative, amoxicillin was discontinued after 10 days. The admission nasopharyngeal aspirate (NPA) was positive for rhinovirus and parechovirus. Typing of the parechovirus in the Public Health England (PHE) reference laboratory in Colindale confirmed a human parechovirus type 5, but also revealed Enterovirus D68 (EV-D68) using EV-D68 specific PCR. An EV71 was also detected suggesting mixed infection. Subsequent testing revealed both parechovirus and EV-D68 were detectable on respiratory samples from admission and up to 4 weeks later. As is usually the case with EV-D68, CSF was persistently negative.

Clinically, the patient demonstrated improvement in her weakness with intensive rehabilitation, however significant disability persisted, particularly weakness of her right arm.

Repeat MRI on Week 6 of presentation (**Fig1 G-I**) demonstrated progression of the vermian abnormality, so the patient was referred again for Neuro-oncology MDT discussion and decision was made to undertake a biopsy of the vermian lesion based on the alarming rate of growth on MRI. Biopsy of the vermian mass showed *BRAF fusion positive* pilocytic astrocytoma (WHO grade 1). The patient continued to make slow recovery but has persistent right arm weakness.

Discussion:

Rhombencephalitis or brainstem encephalitis can be infectious (*Listeria*, Enteroviruses, HSV most commonly), autoimmune or paraneoplastic.¹ Treatment is with appropriate anti-microbials and immunosuppressive treatment (including IVIG, steroids). Morbidity is high with 18.5% either dying or having a poor outcome with severe residual deficit.¹ Less than 25% of patients make full recovery.

Acute flaccid myelitis (AFM) is a neuroinflammatory disease of the spinal cord, characterised by weakness in one or more limbs +/- bulbar or respiratory weakness, associated with CSF pleocytosis and T2 hyperintensities in the spinal cord and brainstem on MRI.²⁻⁴ The majority of cases (>90%) follow a prodromal flu-like illness and viruses including enterovirus and adenoviruses are usually implicated. Poliovirus causing acute flaccid paralysis (AFP) has largely been eradicated, with the last case in Europe described in 2002. Enterovirus 71 is well described as a cause of both rhombencephalitis and AFM, usually causing disease in children in the Asian-pacific region.² More recently, Enterovirus D68 has been implicated in a number of outbreaks of AFM in Asia, USA and Europe, including an outbreak in the UK.³⁻⁶ A novel genetically distinct strain, Clade B1, has been associated with AFM.^{5,6} Detection of strain type to this detail was not available for this patient due to limitations of sample quality. Identification of the same strain in patients with and without neurological involvement suggest host differences in severity of presentation. As in this case, the virus is typically only identified on upper respiratory samples and not in CSF, and clinical improvement lags behind radiological improvement.⁷ A variety of immunosuppressive therapies, including IVIG, steroids and/or plasma exchange have been trialled, with limited response and there is currently no targeted treatment with enough evidence for management of AFM.⁸ There is no vaccine

currently, but both live attenuated strains and subunit virus like particles (VLP) are being evaluated in mice models with promise.^{9,10}

Most cases of AFM occur more than 7 days following onset of the presumed causative upper respiratory infection, affecting yield and titres of virus in the sample.³ In our case, Enterovirus D68 was only detected at low levels, using EV-D68 specific PCR, thus highlighting the importance both of sending the correct samples (respiratory), timing of samples (at first presentation) and a high index of suspicion to request the appropriate diagnostic test. Rhinovirus detected on the first respiratory sample likely represented cross reactivity of Enterovirus-D68 and rhinovirus on the respiratory virus panel platform.¹¹ This patient had evidence of a mixed infection (Parechovirus, EV-D68 +/- EV71 +/- rhinovirus). It is difficult to know definitively which virus is most implicated but Parechovirus and EV-D68 were both detected on multiple samples. The significance of the Enterovirus 71, which was only detected on one sample, is unclear.

In hindsight, the symptoms of neck pain and torticollis (not present on examination in A&E) should have been viewed as red flags, raising suspicion regarding an underlying aetiology, other than Bell's palsy. A unilateral VIIth cranial nerve palsy involving upper and lower face can only be labelled 'Bell's palsy' in the absence of any other symptoms and signs, as this remains a diagnosis of exclusion.

Brain tumours are the most common solid tumours of childhood and half of all paediatric brain tumours occur in the posterior fossa. Pilocytic astrocytoma is the most common glioma in the paediatric population with generally good prognosis. Surgical excision is frequently curative with a survival rate greater than 95% at 10-year follow-up.¹² On imaging, pilocytic astrocytoma tumours are relatively well defined with the majority presenting as a cystic lesion with an enhancing mural

nodule, although there is a range of imaging appearances. Calcifications are not uncommon.¹³ In this case, the tumour was asymptomatic and incidental.

Cases of brain tumours have been reported in patients presenting with encephalitis and the potential role of viruses in brain tumour initiation and oncomodulation is an evolving field¹⁴ although in this case, the two pathologies were probably coincidental.

This is a case where imaging of a neurological complication of a common childhood infection revealed an unexpected, but the commonest form of childhood solid tumour. Currently our patient is making good progress.

Learning Points:

This case illustrates many learning points with regard to:

1. The importance of screening for EV-D68 on appropriate samples (NPA/throat or stool)
2. Management of EV-D68 encephalomyelitis and long term outcome
3. Diagnostic challenges posed by coexistence of a brain tumour with CNS infection
4. Multidisciplinary approach to complex CNS presentations.

References:

1. Campos LG, Trindade RAR, Faistauer A, *et al.* Rhombencephalitis: pictorial essay. *Radiol Bras.* 2016 Sep-Oct; 49(5): 329–336.
2. Huang CC, Liu CC, Chang YC, *et al.* Neurologic complications in children with enterovirus 71 infection. *N Engl J Med* 1999; 341:936–42.
3. Greninger AL, Naccache SN, Messacar K, *et al.* A novel outbreak enterovirus D68 strain associated with acute flaccid myelitis cases in the USA (2012-14): a retrospective cohort study. *Lancet Infect Dis* 2015; 15:671–82.
4. Kirolos A, Mark K, Shetty J, *et al.* Outcome of paediatric acute flaccid myelitis associated with enterovirus D68: a case series. *Dev Med Child Neurol* 2019; 61:376–80.
5. Dyda A, Stelzer-Braid S, Adam D, *et al.* The association between acute flaccid myelitis (AFM) and Enterovirus D68 (EV-D68) - what is the evidence for causation? *Euro Surveill* 2018; 23.
6. Messacar K, Asturias EJ, Hixon AM, *et al.* Enterovirus D68 and acute flaccid myelitis-evaluating the evidence for causality. *Lancet Infect Dis* 2018; 18:e239–47.
7. Gordon-Lipkin E, Muñoz LS, Klein JL, *et al.* Comparative quantitative clinical, neuroimaging, and functional profiles in children with acute flaccid myelitis at acute and convalescent stages of disease. *Dev Med Child Neurol* 2019; 61:366–75.
8. CDC interim clinical management guidance for AFM (<https://www.cdc.gov/acute-flaccid-myelitis/hcp/clinical-management.html>).

9. Yee PTI, Tan SH, Ong KC, *et al.* Development of live attenuated Enterovirus 71 vaccine strains that confer protection against lethal challenge in mice. *Sci Rep* 2019; 9:4805.
10. Dai W, Zhang C, Zhang X, *et al.* A virus-like particle vaccine confers protection against enterovirus D68 lethal challenge in mice. *Vaccine* 2018; 36:653–9.
11. McAllister SC, Schleiss MR, Arbefeville S, *et al.* Epidemic 2014 Enterovirus D68 Cross-React with Human Rhinovirus on a Respiratory Molecular Diagnostic Platform. *PLoS ONE*. 2015; 10(3): e0118529.
12. Collins V P, Jones DTW and Giannini C. Pilocytic astrocytoma: pathology, molecular mechanisms and markers. *Acta Neuropathol*. 2015; 129(6): 775–788.
13. Koeller KK, Rushing EJ. From the archives of the AFIP: pilocytic astrocytoma: radiologic-pathologic correlation. *Radiographics*. 2004; 24 (6): 1693-708.
14. Kofman A, Marcinkiewicz L, Dupart E, *et al.* The roles of viruses in brain tumor initiation and oncomodulation. *J Neurooncol*. 2011; 105(3): 451–466.

Figure Legends:

Fig1 A, B & C: MRI on Day 3 of admission: Dorsum of brainstem signal changes extending into middle cerebellar peduncles, dentate nuclei and vermis. Note mass effect of the vermis lesion. There is involvement of the central grey matter of the cervical cord.

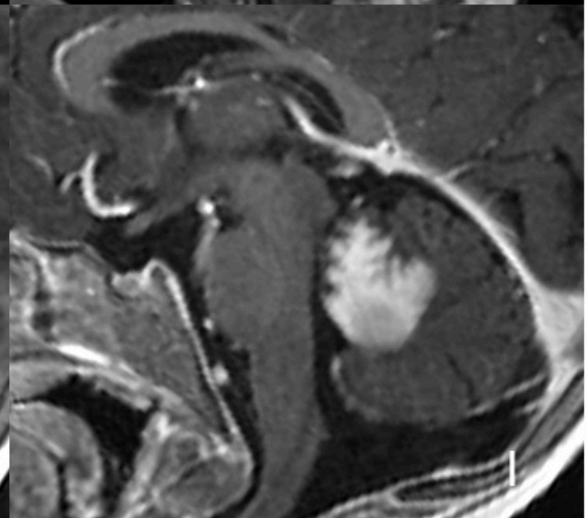
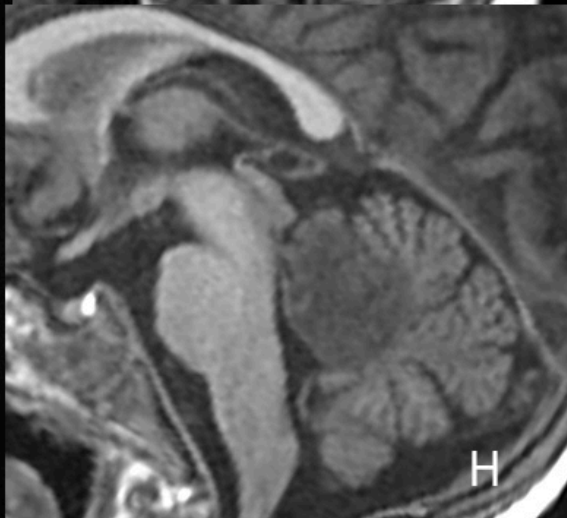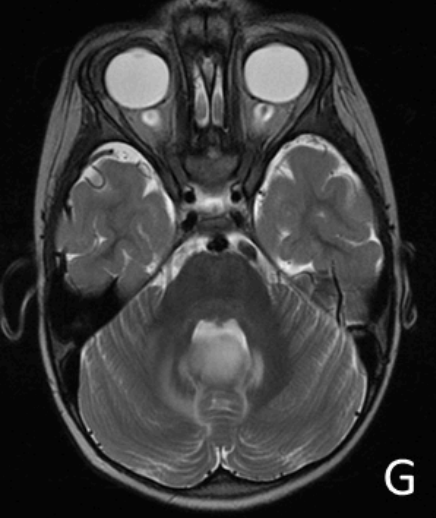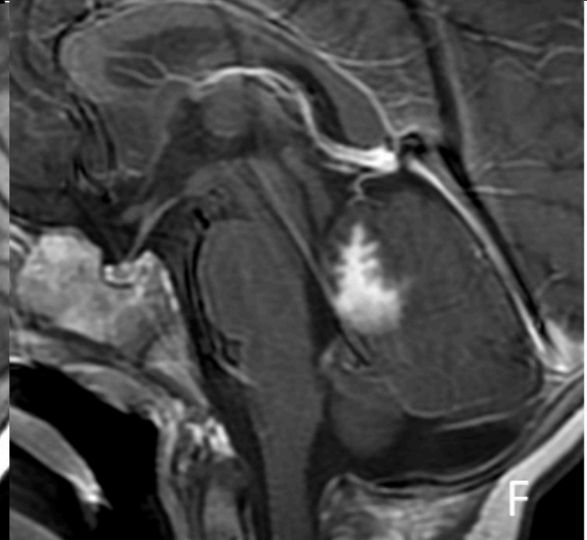
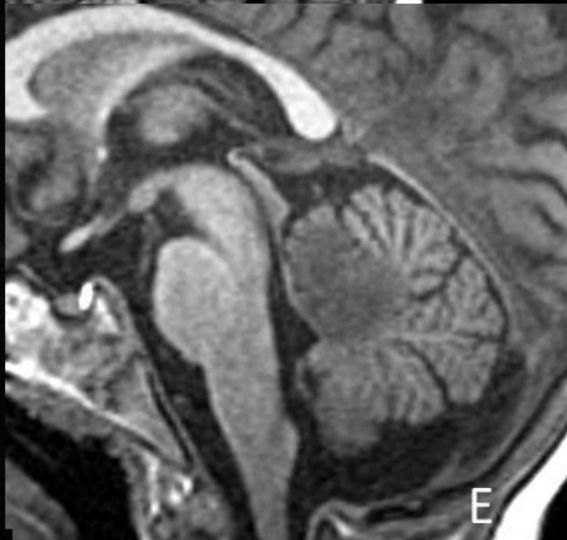
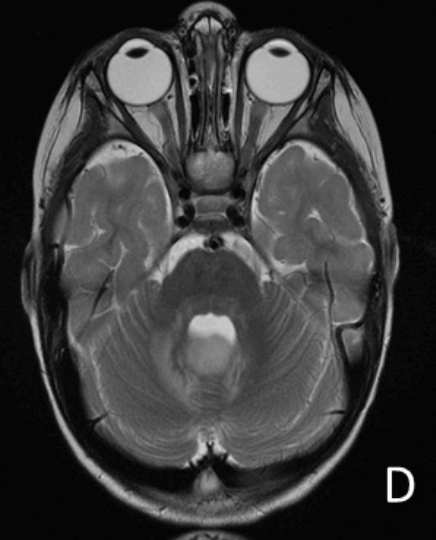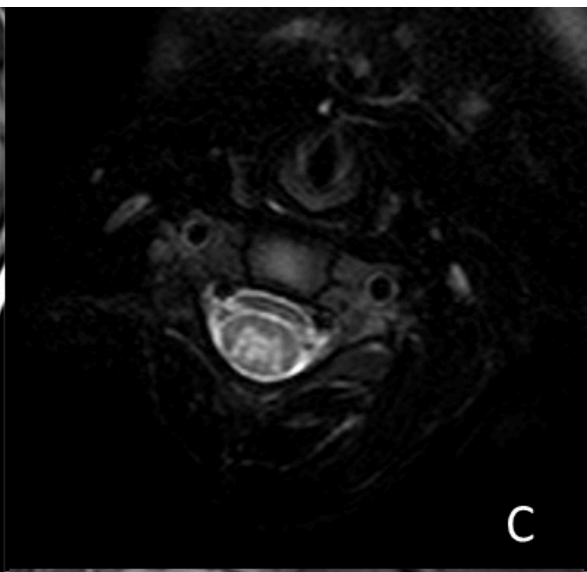
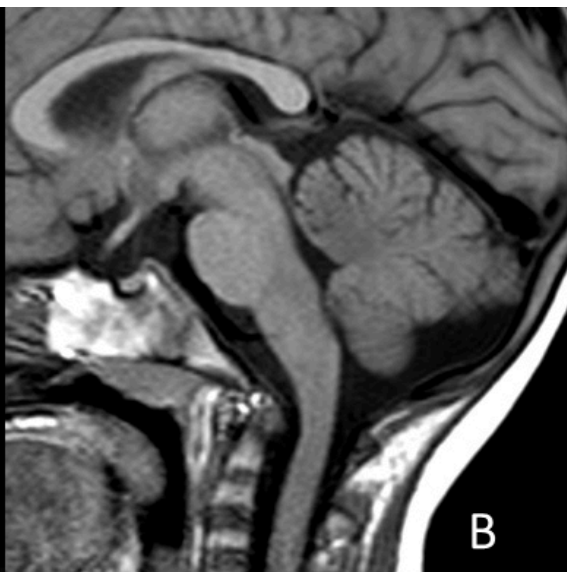
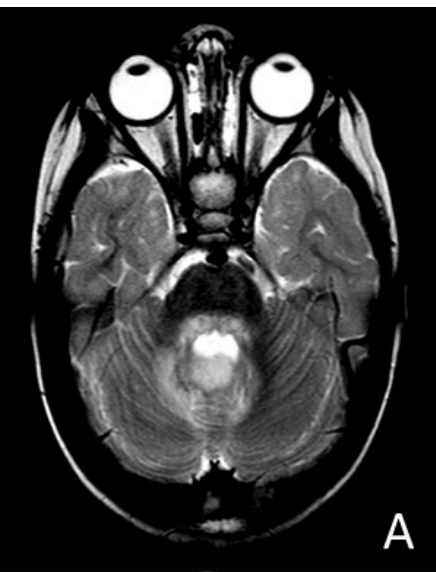Fig 1 D, E & F: MRI Day 10 of admission: Improvement of the brainstem and middle cerebellar peduncles signal changes. Persistence of the vermis space-occupying signal abnormality superior to the fastigium, with avid enhancement of superior vermis. An underlying tumour is suspected.

Fig 1 G, H & I: 6 weeks after initial presentation: Progressive increase in size and mass effect of the lesion superior to the fastigium. The continued interval growth is concerning for an aggressive tumour.

Table 1:

Summary of relevant diagnostic investigations: ND – not detected. NPA – nasopharyngeal aspirate. CSF – Cerebrospinal fluid. MN – mononuclear Ab-antibody. TSH – thyroid stimulating hormone. ANA – anti-nuclear antibodies. Rh-rheumatoid. ANCA – Anti-neutrophil cytoplasmic antibodies. HSV – herpes simplex virus. VZV – varicella zoster virus. MOG - myelin oligodendrocyte glycoprotein. HIV – human immunodeficiency virus. NMDA -N-methyl-D-

aspartate. HHV- human herpes virus. CMV – cytomegalovirus. EBV – Epstein-Barr virus



Virology – NPA and Faeces							CSF			Blood results				
	Day 1	Day 6	Day 10	4 weeks	6 weeks	6 weeks		Day 3	Day 10		Day 3		Day 3	
Sample Type	NPA	NPA	Faeces	NPA	Faeces	NPA		CSF		Clinical Biochemistry		Blood Serology		
Rhinovirus	Detected (CT 33.17)	ND	-	ND		ND	Microscopy	32 white cell/cmm (62% MN)	1 white cell/cmm	Thyroid Function	TSH 2.06 (milliunit/L), Free T4 10.5 pmol/L		Bartonella, Borrelia, Brucella, Coxiella, Listeria, Rickettsia, Mycoplasma, Toxoplasma	ND
Enterovirus	ND	ND	ND	Detected	ND	ND	Biochemistry	Protein 1.9g/L	protein 0.84g/L	Blood Autoimmune screen				
Parechovirus	Detected (CT 26.74)	Detected (CT 34.67)	Detected	Detected	ND	ND	HSV, Enterovirus, VZV, Parechovirus, HHV6, EBV, West Nile Virus, Adenovirus	ND	ND	ANA, ANCA, RhFactor	ND			
	Human Parechovirus type 5	Human Parechovirus type 5	-	Human Parechovirus type 5	-	-				Myeloperoxidase Ab	ND			
Enterovirus D68	Detected	Detected	Enterovirus detected at PHE but untypable	Detected	ND	ND	Bacterial Culture	ND	ND	Proteinase 3 Ab	ND			
Parainfluenza 4	Unable to confirm by sanger sequencing	EV 71 also detected - consistent with mixed infection.					16s PCR	ND	NDA	Thyroid peroxidase Ab, TSG Receptor Ab	ND			
Influenza A, Influenza B, Parainfluenza 1-4, Adenovirus, Respiratory Syncytial Virus, Human Metapneumovirus	ND	ND	ND	ND	ND	ND	Autoimmune antibody screen (anti-NMDA, Anti-Mog, Aquaporin 4)	ND	ND	Anti-MOG, Anti-NMDA Aquaporin 4 Ab	ND			
										Anti-Voltage Gated K channel				