

649

**Factors Affecting the Structure of
Salmonid Epidermis**

by

N. Blackstock

A thesis submitted to the University of Stirling
in partial fulfilment of the requirements for the
degree of Doctor of Philosophy.

School of Animal Biology
University College of North Wales
Bangor
Gwynedd, LL57 2UW
30th April 1985

8/85

Acknowledgments

My thanks in particular are due to Dr A.D. Pickering (F.B.A.) for supervision and guidance throughout the period of this investigation. I am also very grateful to my academic supervisor Dr R.H. Richards (Stirling) for advice and encouragement, and to Professor R.J. Roberts (Stirling) for stimulating discussion.

For maintenance of cultured fish at The Ferry House I am indebted to Mrs J. Pollard and also to Miss J.M. Fletcher; Mrs Pollard also carried out some of the post mortem examinations. Thanks are also due to Dr J.M. Elliott (F.B.A.) and A. Vardy (Bangor) for advice on sampling techniques and statistical analyses; to T.G. Pottinger (F.B.A.) for processing tissue for scanning electron microscopy; to J.Heron (F.B.A.) for carrying out some of the water analyses; and to Dr C.B. Crosby, T.G. Pottinger, F. Prickett (all of the F.B.A.) and J Moffat (North West Water Authority) for assistance with sampling wild fish.

I am grateful to E.D. LeCren and the Freshwater Biological Association for permission to register this project for the degree of Doctor of Philosophy, and to Professor J.M. Dodd and the University College of North Wales for the use of histological facilities.

Contents

Abstract

1. Introductory review of integumental epithelia in teleost fishes with particular reference to salmonids 1
2. Survey of epidermal structure in salmonid fish
 - 2.1. Introduction 9
 - 2.2. Materials and methods 10
 - 2.3. Results 14
 - 2.4. Discussion 21
3. Changes in epidermal mucification in brown trout during the early stages of growth
 - 3.1. Introduction 28
 - 3.2. Materials and methods 29
 - 3.3. Results 33
 - 3.4. Discussion 35
4. Changes in cellular composition in the epidermal surface associated with costiasis in O+ brown trout
 - 4.1. Introduction 40
 - 4.2. Materials and methods 43
 - 4.3. Results 50
 - 4.4. Discussion 55

5. The sequential pathology of costiasis in O+ brown trout and the effects of long- term formalin prophylaxis on epidermal structure	
5.1. Introduction	60
5.2. Materials and methods	64
5.3. Results	68
5.4. Discussion	76
6. An acidophilic granular cell in the epi- dermis of brown trout and other salmonids	
6.1. Introduction	87
6.2. Materials and methods	89
6.3. Results	92
6.4. Discussion	97
7. Concluding remarks and discussion	103
References	114
Appendix	138

NOMENCLATURAL ADDENDUM

In common with a number of other recent publications, the binomial Ichtyobodo necator is used throughout this thesis for the bodonid ectoparasite described by Joyon & Lom (1969); these latter authors incorrectly cited the generic spelling used by Grassé (1952) who in fact referred to Ichthyobodo Pinto 1928.

Abstract

The recent literature concerning the structure of teleost epidermis is reviewed; particular attention is given to salmonids and epidermal variability and plasticity. A preliminary survey of hatchery-reared and wild O+ brown trout Salmo trutta L. suggested that quantitative and qualitative variation in epidermal structure are related inter alia to development and disease. A subsequent, temporal investigation of disease-free brown trout revealed a decline in the density of superficial mucous cells and a change in their histochemistry early in development; these findings are discussed in relation to habitat and the functional role of epidermal mucous secretion. Infestations by the ectoparasite Ichtyobodo necator were shown to cause a significant depletion of epidermal mucous cells and an increase in the abundance of a previously undescribed acidophilic cell in O+ brown trout; these pathogenic effects were found to be reversible by therapeutic formalin administration.

The sequential histopathology of costiasis in cultured and wild juvenile brown trout is described. Ichtyobodo infestation stimulated an initial hypersecretion of mucus; as infestation intensified Malpighian cell proliferation occurred, mucous cells disappeared and the density of acidophilic cells continued to increase. In the chronic phase of the disease there was a cycle of epidermal hyperplasia and sloughing, but by autumn, as infestation became less severe,

NOMENCLATURE ADDENDUM

In common with a number of other recent publications, the binomial Ichtyobodo necator is used throughout this thesis for the bodonid ectoparasite described by Joyon & Lom (1969); these latter authors incorrectly cited the generic spelling used by Grassé (1952) who in fact referred to Ichthyobodo Pinto 1928.

Abstract

The recent literature concerning the structure of teleost epidermis is reviewed; particular attention is given to salmonids and epidermal variability and plasticity. A preliminary survey of hatchery-reared and wild O+ brown trout Salmo trutta L. suggested that quantitative and qualitative variation in epidermal structure are related inter alia to development and disease. A subsequent, temporal investigation of disease-free brown trout revealed a decline in the density of superficial mucous cells and a change in their histochemistry early in development; these findings are discussed in relation to habitat and the functional role of epidermal mucous secretion. Infestations by the ectoparasite Ichtyobodo necator were shown to cause a significant depletion of epidermal mucous cells and an increase in the abundance of a previously undescribed acidophilic cell in O+ brown trout; these pathogenic effects were found to be reversible by therapeutic formalin administration.

The sequential histopathology of costiasis in cultured and wild juvenile brown trout is described. Ichtyobodo infestation stimulated an initial hypersecretion of mucus; as infestation intensified Malpighian cell proliferation occurred, mucous cells disappeared and the density of acidophilic cells continued to increase. In the chronic phase of the disease there was a cycle of epidermal hyperplasia and sloughing, but by autumn, as infestation became less severe,

progressive re-development of a normal epidermal structure took place in surviving fish. Analogous changes in cell composition were observed in fish subjected to formalin prophylaxis, and possible applications to fish farm management are suggested. The contents of a presumed secretory acidophilic cell in brown trout, which was also shown to occur in other salmonid taxa, were found to be granular and proteinaceous. Finally, the possibility that there are non-specific epidermal responses to surface active irritation in teleosts is considered in relation to effects of irritants on epithelial mucosae in higher vertebrates.

Chapter 1

Introductory Review of Integumental Epithelia in Teleost Fishes with Particular Reference to Salmonids

The decade prior to the commencement of the present investigation, in 1977, saw considerable advances in the understanding of the nature of the teleost epidermis and its associated slime layer. The structure of this protective epithelial system, together with the other underlying layers of the integument, has been investigated in species from such diverse orders of teleosts as the Anguilliformes (e.g. Henrikson & Matoltsy, 1968a; b; c), Salmoniformes (e.g. Roberts, Shearer, Elson & Munro, 1970), Cypriniformes (e.g. Yamada, 1968; Mittal, Agarwal & Banerjee, 1976), Siluriformes (e.g. Mittal & Munshi, 1969; Ferri, Stipp, Sesso & Correa, 1977), Gadiformes (Bullock, Roberts & Gordon, 1976), Channiformes (Mittal & Banerjee, 1975), Synbranchiformes (Mittal & Munshi, 1971), Perciformes (e.g. Fishelson, 1972), Pleuronectiformes (e.g. Roberts, Young & Milne, 1971) and Teraodontiformes (Mittal & Banerjee, 1976), together with that in a selachian (Albanese Carmignani & Zaccone, 1975).

The overall impression to be gained from the above accounts, as well as from the foundations embodied in the earlier literature, is that there is striking uniformity in the major structural elements of the integument of teleost fishes. The skin, consisting of two primary zones, is

attached to the musculature by an areolar hypodermis. The proximal zone or dermis, underlying the epidermis, is subdivided into a stratum compactum situated below a stratum spongiosum. The former is principally composed of regularly arranged layers of collagen fibres, while the latter has a loose network of fibrous tissue and contains the scale beds together with a more varied cellular component including pigment cells, mast cells and mononuclear cells. Blood vessels and nerve fibres enter the stratum spongiosum through the collagen matrix of the stratum compactum.

The distal zone or epidermis is composed predominantly and universally of filament-containing Malpighian cells. However, the range and abundance of other cell types in the epidermis varies considerably between species and sometimes between individuals of the same taxon. Club cells, chloride cells, a variety of granule-containing cells, sensory cells and also unicellular glands have all been reported in the descriptions of teleost epidermis. Although the epidermis is not generally formed in distinct layers, it is convenient for descriptive purposes to subdivide it into basal, mid and surface strata. The basal Malpighian cells are columnar or ovoid and arranged in a single layer on the basement membrane which separates the epidermis from the dermis. In the middle layers the Malpighian cells are more or less spherical and of uniform size, whereas in the outer strata the epidermal cells are flattened. Lymphocytes are also present, usually between the basal cells, and macrophages migrate through the epidermis.

The number of layers of Malpighian cells in the mid and outer strata varies between different species. Keratinization does not as a rule take place in the outer layers of fish epidermis, although it has been observed in a very few species, e.g. Notopterus notopterus (Pallas) and Bagarius bagarius (Hamilton) (Mittal & Banerjee, 1974a; b). The evidence available from cytokinetic studies indicates that, in contrast to mammals, cells can be mitotically active at all levels in the epidermis of teleosts, as has been demonstrated in goldfish Carassius auratus (L.) (Henrickson, 1967), Atlantic salmon Salmo salar L. suffering from ulcerative dermal necrosis (Roberts, Shearer, Elson & Munro, 1970) and, more recently, in plaice Pleuronectes platessa L. (Bullock, Marks & Roberts, 1978). In this respect teleost skin epithelia would appear to have closer affinities with vertebrate mucous membranes than the outer layers of mammalian skin. In common with many other types of animal, the external layers of the epidermis are continually sloughed, a process which undoubtedly also aids the removal of pathogenic agents from the skin surface.

The published descriptions of the organization of the epidermal Malpighian cells in species belonging to the Salmonidae indicate that it does not deviate from that of the generalized fish epidermis. Harris & Hunt (1975a) have characterized the fine structure of the filament-containing cells in the basal, mid and peripheral levels in the epidermis of Atlantic salmon and brown trout Salmo trutta L.;

they also showed (Harris & Hunt, 1975b) that the only unicellular glands in salmonid epidermis, the apocrine goblet mucous cells, are basally derived and move outwards to the epidermal surface. Mucous cells occur in the epidermis of all teleost fish; they elaborate their secretions and increase in size as they migrate to the peripheral surface (Bullock & Roberts, 1975). From the results of a detailed ultrastructural investigation of various bony fishes, Whitear (1970) described a thin cuticular layer on the external surface of the skin epithelium, which was thought to consist predominantly of mucopolysaccharides secreted by the outer epidermal cells. She further postulated that the discharge of mucus from the goblet cells may have distinct functions related, for instance, to stress conditions. There is no unequivocal evidence that Malpighian cells in salmonid epidermis are secretory. In their study of the epidermis of Atlantic salmon and brown trout, Harris & Hunt (1975b) have demonstrated that the mucous cells release their products over the epidermal surface. In view of the similarities between the composition of the external mucous layer and the mucous cell contents, they also suggested that goblet cell secretions are the major constituents of integumental, epithelial mucus in salmonid fish. The surface of the superficial layer of epidermal cells in salmonids is generally patterned with micro-ridges which Hawkes (1974), in an investigation of the coho salmon Oncorhynchus kisutch (Walbaum), considered were likely to aid the retention of

mucous secretions on the skin. Apart from the goblet mucous cell, no other secretory cells have been detected in salmonid epidermis, although Bullock & Roberts (1975) have noted the presence of an eosinophilic granule cell which was said to have been seen most frequently under pathological conditions, and Pickering & Macey (1977) have observed an eosinophilic cell in the epidermis of char Salvelinus alpinus L.

The stratified teleost epidermis with its external mucous layer represents the primary protective barrier between the fish and its environment. Henrikson & Matoltsy (1968b) have pointed out that since the teleost epidermis is non-keratinized, the protective role of this epithelial system is likely to be related primarily to the deposition of the outer mucoid coat. Various properties have in fact been attributed to the external mucous layer in teleost fishes. Its ability to reduce frictional drag has been demonstrated by Rosen & Cornford (1971), and the effectiveness of the mucous layer in maintenance of laminar flow has been reviewed by Hoyt (1975) for a variety of species. The physical properties of mucus have been discussed by Wilson (1976) who suggested that its viscosity helps to safeguard the fish against mechanical damage, and that the constant renewal of the external coat would also tend to prevent attachment of ectoparasites. In addition, the outer mucoid layer of certain species is known to contain inhibitory substances (e.g. Fletcher & White, 1973) which suggests it may play a more specialized, defensive role against pathogenic organisms. The aquatic

environment imposes problems not encountered in a terrestrial habitat, and Fletcher (1978) has pointed out that the physical integrity of the external mucus is important for the retention of active substances in the vicinity of the fish. Histochemical descriptions of the mucous cells have indicated that they contain both protein and carbohydrate. In an investigation of brown trout, Harris, Watson & Hunt (1973) found that the main components of the goblet cells were sialic acid-containing glycoproteins, although neutral mucosubstances were also present, and it was noted that sulphated acid polysaccharides occur in the mucous cells of other species. Sialated mucopolysaccharides have also been shown to be the main constituents of salmonid mucous cells by Fletcher, Jones & Reid (1976) and Pickering & Macey (1977), with the principal sialic acid in brown trout being N-acetyl neuraminic acid (Pickering, 1974; 1976).

It has been intimated that the mucus-secreting epidermis is capable of responding to a variety of environmental stimuli, including pathogenic agents, by altering the nature as well as the quantity of its secretions (Jakowska, 1963). Some supporting evidence is available for this suggestion in that it is known that the abundance and/or size of mucous cells is sensitive to a wide range of external stimuli. These include ultra-violet radiation (Bell & Hoar, 1950), environmental salinity (e.g. Roberts, Shearer, Elson & Munro, 1970), pH stress (Daye & Garside, 1976), handling stress (Pickering & Macey, 1977) and also ectoparasitic infestations (e.g.

Rogers & Gaines, 1975). Besides being responsive to these perturbations, seasonal changes in epidermal structure are known to take place, e.g. in the eel Anquilla japonica Temminck & Schlegel (Yamada & Yakote, 1975), and a sexual dimorphism in respect of skin epithelial thickness and mucification has been described in the sea trout Salmo trutta L. (Stoklosowa, 1966). Through the use of quantitative methods to investigate the structural variation in salmonid epidermis, Pickering (1974) has demonstrated that the frequency of superficial mucous cells is not necessarily constant over the body in individual brown trout and char, and he subsequently (Pickering, 1977) observed both a sexual dimorphism and seasonal changes in the skin structure of brown trout. These latter quantified descriptions have laid a foundation on which to extend the various qualitative observations that have been reported on the variability of teleost epidermis.

An understanding of the functions of the teleost epidermis has also become increasingly important in view of the modern developments in fish farming, particularly of salmonids. For instance, Needham (1979) has reported a tenfold increase in the production of trout in Britain during the decade prior to 1976. Outbreaks of skin infestations frequently occur under culture conditions and juvenile fish are often said to be especially susceptible. In one of the few studies of the pathogenesis of an ectoparasitic protozoan infestation in teleost epidermis, Hines & Spira (1974) recorded mucification and other responses in the skin of the mirror carp Cyprinus

carpio L. affected with ichthyophthiriasis. Pickering (1977) has also suggested that there may be a negative correlation between salmonid epidermal goblet cell abundance and susceptibility to disease. Further information on the pathological responses of the salmonid epidermis to infestations of the more prevalent skin parasites may lead to more effective measures of disease control and enhanced productivity.

In conclusion, it is clear that despite a general overall similarity, the structure and composition of the epidermis of teleost fish is not constant but should be considered as a plastic system the inherent variability of which is capable of response, through changes in form and presumably function, to both internal and external stimuli. An obvious prerequisite in any investigation of factors responsible for alterations in the 'normal' epidermal structure is that the latter has been rigorously described by repeated observation. Deviation from the expected in this respect must also take into account the variation due to age, sex, seasonality etc.; normality does not necessarily imply constancy.

Chapter 2

Survey of Epidermal Structure in Salmonid Fish

2.1. Introduction

It has been pointed out in Chapter 1 that the structure of the salmonid epidermis is not constant but has a plasticity which enables it to respond to a variety of stimuli. One of the most notable changes involves variation in the numbers of goblet mucous cells. This in turn can be expected to directly affect the mucus-producing capacity of the epithelium and hence the thickness, and possibly the quality, of the external mucous layer. This mucosal system represents the primary protective barrier between the fish and its aqueous environment.

In order to determine some of the factors that influence the protective potential of the epidermis and its associated slime layer in salmonids, it was decided to carry out a preliminary survey to assess the range of variation in epidermal structure between and within a number of different populations. This survey includes both hatchery-reared and wild fish from sites in the north-west of England. The initial work led to a more detailed study in the Freshwater Biological Association's hatchery at The Ferry House of the range of epidermal structure in 1+ brown trout Salmo trutta. Temporal changes were also investigated by monitoring 0+ fish

in this hatchery and both 0+ and older, sexually immature fish in one wild population of brown trout at frequent intervals over a period of twelve months.

2.2. Materials and Methods

Study sites and sampling procedures

Brown trout and Atlantic salmon Salmo salar were sampled from four hatcheries in the north-west of England. Culture conditions varied between the hatcheries, as summarized in Table 2.1. Wild brown trout were sampled from five different becks also in the north-west of England; details of each sampling site are given in Table 2.2. Hatchery-reared fish were removed from their holding tanks by means of a hand net and wild fish were obtained by electro-fishing. (A preliminary experiment in the hatchery established that there was no significant difference (Student's *t*-test) in mean superficial epidermal goblet cell density between fish netted (690 cells mm⁻¹, n=10) or fish stunned (572 cells mm⁻², n=10) by electricity and then netted from the same pond.) Each fish was placed immediately into a solution of MS 222 (Sandoz, 0.1 g l⁻¹). When fully anaesthetized, a skin sample was removed from the shoulder area of the fish (Fig. 2.1). Pickering (1974) has shown that epidermal structure is not uniform over the body of brown trout and that there is a gradual decrease in goblet cell abundance towards the posterior of the fish. For comparative purposes, therefore, it was necessary to

Hatchery	Pond type	Water supply	Notes
Ferry House	Circular, 2 m dia., fibre-glass, c. 1500 l capacity.	Constant supply of Windermere lake water, pH 6.9-7.2, temp. range 3-14°C.	Fish not graded.
Langcliffe	Circular, 2 m dia., fibre-glass, c. 1500 l capacity.	Water supply from limestone catchment, high pH (<9.5).	
Carlisle	Square, 3 m x 0.5 m deep, fibre-glass, c. 6000 l capacity.	Bore hole water, constant temp. 10°C.	
Dunsop Bridge	Large earth ponds.	Water supply from Loaderdale beck, high turbidity.	<u>Gyrodactylus</u> present.

Table 2.1. Comparison of culture conditions at four hatcheries in the north-west of England from which fish were sampled in August 1976.

Sampling site	Description	Geology	Substrate at site	Fish species present	Water conditions
Scandale Beck	Fast-flowing mountain stream consisting of a series of waterfalls and deep pools in a tree lined gully.	Borrowdale volcanics.	Large boulders, stones and gravel.	<u>Salmo trutta</u>	pH 7.2 Temp. May 7.9°C Aug. 12.7°C [Ammonia-N] <5 µgl ⁻¹ [O ₂] Aug. 10.4 ppm
Saint Sunday's Beck	Fast-flowing lowland river.	Carboniferous limestone.	Flat, silty bottom.	<u>S. trutta</u> <u>Gasterosteus aculeatus</u> <u>Cottus gobio</u> <u>Lampetra fluviatilis</u> <u>Anguilla anguilla</u>	pH 8.5 Temp. 9.5°C
Dale Park Beck	Slow-flowing, wide, shallow stream liable to dry up during drought conditions.	Silurian slate.	Large stones and gravel.	<u>S. trutta</u>	pH 6.5 Temp. >15°C [Ammonia-N] 16.3 µgl ⁻¹ [O ₂] 4.7 ppm
Black Brows Beck	Narrow, shallow, slow-flowing tributary of Dale Park Beck; does not dry up.	Silurian slate.	Silty.	<u>S. trutta</u> <u>S. salar</u> <u>A. anguilla</u>	pH 7.0 Temp. 14.5°C [Ammonia-N] 11.3 µgl ⁻¹ [O ₂] 8.9 ppm
Wise Zen Beck	Short, narrow beck flowing between two tarns at 200 m.	Silurian slate.	Small stones and gravel.	<u>S. trutta</u>	pH 6.9 Temp. 14.4°C [Ammonia-N] 16.3 µgl ⁻¹ [O ₂] 9.14 ppm

Table 2.2. Comparison of five becks in the north-west of England from which wild brown trout were taken in 1977. Scandale Beck was sampled in May and in August, Saint Sunday's Beck was sampled in May only and the remaining three becks were sampled in August only.

Figure 2.1. Skin sampling area. Adjacent pieces of skin were removed from the shoulder area of anaesthetized fish. One sample was preserved for surface epidermal cell counts and the other processed for histological examination.

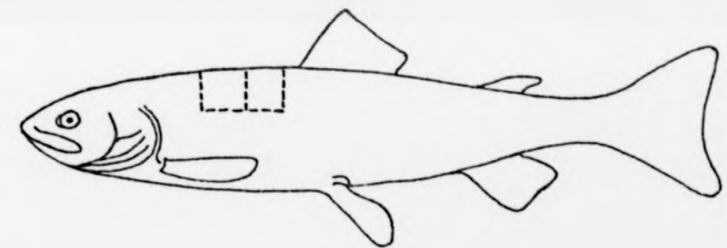


Figure 2.1.

consistently take skin samples from the same part of the body. The samples were immediately placed in the appropriate fixative (see below). Each fish was killed by spinal section without being allowed to recover from the anaesthetic and body weight, fork length and sex (when possible) were recorded.

Estimation of goblet cell density and statistical treatment

Skin samples for subsequent cell counts were fixed in a solution of 10% formalin in 0.6% Na Cl for a minimum of 12 hours. They were then washed and stained in Alcian blue (pH 2.5 or pH 1) using the method described by Pickering (1974). With this technique only the superficial goblet cells are stained and therefore the results are independent of epidermal thickness. In this preliminary study, epidermal mucous cell density (number of cells per unit area) was estimated from the mean of six randomly-placed 0.36 mm² quadrat samples on each piece of skin. Comparisons between samples of fish were made by means of the Student's t-test (Elliott, 1977), or by one-way analysis of variance (Snedecor & Cochran, 1967) when more than two samples were involved. These analyses were carried out on transformed counts if the results of a F-test (prior to t-test) or a F max-test (prior to analysis of variance) showed that variances were heterogeneous (Sokal & Rohlf, 1969). The significance of the relationship between variables was tested by linear regression analysis.

Histology

Skin samples adjacent to those used for estimations of mean goblet cell density (Fig. 2.1) were removed from the shoulder area of the anaesthetized fish and fixed immediately in Bouin's fluid or in 10% formalin (in phosphate buffer) for 24 hours. After fixation, Bouin's fluid was removed with several changes of 70% alcohol (until excess picric acid was no longer released) and the formalin-treated tissue was washed in running water overnight. The tissue was then dehydrated in a graded series of methanol solutions and cleared in cedarwood oil prior to infiltration and embedding in paraffin wax (melting point 58°C). Sections were cut at 5 or 6 μ m and stained with Ehrlich's acid haematoxylin and eosin (H&E), Alcian blue (AB pH 2.5 or pH 1.0) or Ewen's aldehyde fuchsin with Halmi's counterstain (Ewen, 1962).

Water chemistry

The following analyses were carried out either in the field or on water samples brought back to the laboratory from several of the sampling sites.

Dissolved oxygen concentration was either calculated from percentage O₂ saturation and temperature measured in the field with an oxygen probe and thermistor or was estimated using the Winkler method as described by Mackereth, Heron & Talling (1978) except that 0.2 M thiosulphate was used to titrate the iodine produced in the water sample by the Winkler reactions. The thiosulphate solution was standardized

against 0.1 M potassium iodate and was dispensed from a micro-pipette (0.5 ml capacity) with a micrometer gauge delivery. The O_2 concentration in the sample = $8000 \times M \times V_1/V_2 \text{ mg l}^{-1}$ (where M = molarity of thiosulphate, V_1 = volume of thiosulphate used and V_2 = volume of subsample titrated).

The concentration of total ammonia-nitrogen was estimated by the indophenol blue method (Mackereth, Heron & Talling, 1978) which depends on the reaction of ammonia with phenol under alkaline conditions to produce indophenol blue. Sodium nitroprusside was used as a catalyst to facilitate colour development. Absorbance was read at 635 nm using a spectrophotometer with a 1 cm flow-through-cell and concentration estimated from a standardized curve.

For pH determinations, samples were brought to the laboratory for measurement using a pH meter with glass electrode. Readings accurate to 2 decimal places were corrected for temperature.

Alkalinity was determined by titration with 0.01 M HCl using BDH 4.5 indicator (Mackereth, 1963); alkalinity = $0.1 \times V \text{ meq l}^{-1}$ bicarbonate (where V = volume of acid used in titration).

The concentration of dissolved, free carbon dioxide was estimated from pH and alkalinity using a nomogram drawn from the data of Moore, (1939), (in Mackereth, 1963). If the pH determination is reasonably precise (to 0.02 by glass electrode) then the nomogram gives a better estimation of free carbon dioxide than titration (Mackereth 1963).

Temperature was measured in the field with a mercury thermometer or with a thermistor attached to the oxygen probe.

2.3. Results

Hatchery-reared fish

A survey of underyearling (0+) salmonid fish from the four hatcheries in the north-west of England, sampled during August 1976, revealed a marked variation in skin structure between populations (Table 2.3). Mean epidermal goblet cell densities of brown trout from three hatcheries, The Ferry House (29.5 mm^{-2}), Dunsop Bridge (342.2 mm^{-2}) and Carlisle (1057.6 mm^{-2}), and Atlantic salmon from two hatcheries, Carlisle (873.6 mm^{-2}) and Langcliffe (542 mm^{-2}), were found to be significantly different, ($p < 0.001$ and $p < 0.01$ respectively). A significant difference ($p < 0.05$) was also demonstrated between mean epidermal goblet cell densities of brown trout and Atlantic salmon sampled from one of the hatcheries (Carlisle). Within these three groupings of the fish, mean weights and mean lengths were also significantly different ($p < 0.01$ for mean weights and lengths of brown trout from three different hatcheries and Atlantic salmon from two different hatcheries, and $p < 0.001$ for mean weights and lengths of brown trout and Atlantic salmon from the same hatchery). However, there was no correlation between body size and epidermal mucous cell density in the brown trout;

Hatchery	Species	Body weight g	Body length cm	Mucous cells mm ⁻²	Significance of differences between mucous cell densities
Ferry House	bt	4.60 ± 1.76 (6)	6.75 ± 0.06 (6)	29.5 ± 30.2 (6)	<div style="display: flex; justify-content: space-around; align-items: center;"> <div style="text-align: center;"> $\left. \begin{array}{l} \text{***} \\ \text{*} \\ \text{**} \end{array} \right\}$ </div> </div>
Dunsop Bridge	bt	6.14 ± 0.96 (10)	7.57 ± 0.37 (10)	342.2 ± 168.9 (10)	
Carlisle	bt	3.13 ± 0.51 (6)	6.39 ± 0.16 (6)	1057.6 ± 159.9 (6)	
Carlisle	sa	0.90 ± 0.09 (8)	4.15 ± 0.15 (8)	873.6 ± 73.4 (8)	
Langcliffe	sa	2.53 ± 0.93 (12)	5.56 ± 0.63 (12)	542.0 ± 130.3 (12)	

Table 2.3. Body weight, fork length and epidermal mucous cell density of 0+ brown trout (bt) and salmon (sa) sampled in August 1976 from hatcheries in the north-west of England. Values given represent mean ± 95% confidence limits (sample size): * p<0.05, ** p<0.01, *** p<0.001. Details of significant differences between weights and between lengths are given in the text.

the hatchery with the smallest fish sampled had the highest cell counts per unit area, and that with the largest fish sampled had an intermediate number.

Histological sections of skin samples from fish in these hatcheries led to the discovery of a previously undescribed cell type in brown trout epidermis. These cells, which were not found in Atlantic salmon, were similar in size and shape to the goblet mucous cells. However, their staining reactions were negative to both Alcian blue (pH 2.5) and aldehyde fuchsin, but they stained intensely with eosin and with orange G in Halmi's counterstain. After the initial finding of these cells in 1976, eosin was added to the formaldehyde solution; acidophilic cells were thus stained during fixation and their presence or absence noted during counts of superficial goblet cells in sheets of skin.

The results of this initial survey led to a more detailed investigation in one hatchery (The Ferry House) where all brown trout were of the same genetic stock. Analysis of variance was used to compare mean epidermal goblet cell densities of between ten and twelve 1+ brown trout sampled from each of three different ponds on the same day in January 1977. The differences in epidermal structure between ponds, ranging from a mean of 147 to a mean of 664 mucous cells mm^{-2} , were found to be highly significant ($p < 0.001$, see Table 2.4). The ponds were identical in shape and size but it had been observed that trout in pond 14 grew more rapidly and fed more readily than those in the other two ponds. Significant

Pond no	Body wt g	Body length cm	Mucous cells mm ⁻²	Significance of differences between mucous cell densities
8	19.06 ± 6.4 (10)	11.38 ± 1.29 (10)	227.00 ± 107.74 (10)	***
14	36.27 ± 6.79 (11)	14.39 ± 0.94 (11)	663.91 ± 155.22 (11)	
9	19.3 ± 4.7 (12)	11.8 ± 1.03 (12)	146.58 ± 56.23 (12)	

Table 2.4. Body weight, fork length and epidermal mucous cell density of 1+ brown trout sampled in January 1977 from three ponds at The Ferry House hatchery. Values given represent mean ± 95% confidence limits (sample size); *** p<0.001. Details of significant differences between weights and between lengths are given in the text.

differences were also demonstrated between mean body weights and mean body lengths ($p < 0.01$ in each case) of the three samples of fish and, in this case, a significant, positive correlation between body weight and epidermal mucous cell density, $r = 0.81$ ($p < 0.001$), was established using linear regression analysis (Fig. 2.2). The relationship between body size and skin structure was further investigated by comparing the mean epidermal mucous cell density of separate samples of ten small and ten large 1+ brown trout from each of seven ponds in February 1977. The results (Table 2.5) were subjected to analysis of variance of sub-sample means (Snedecor & Cochran, 1967). With this analysis it was possible to separate the components of variance into that due to differences between ponds ($p < 0.05$) and that due to size classes within ponds ($p < 0.01$). It was also found that water flow rate and water chemistry varied markedly between ponds (Table 2.6). Examination of the data further suggested that mucous cell densities fell into two groups on the basis of flow rate, i.e. ponds with a flow rate of greater than 7 l min^{-1} and those with a lower discharge. Re-analysis of the data, divided in this way (see Table 2.5), showed that differences in skin structure between ponds within each group were not significant (see Table 2.5 column (b)), but that the mean epidermal mucous cell density of trout in ponds with the greater flow rates (ponds 13, 14, 15 & 16) was significantly higher (see Table 2.5 column (c)) than that of trout in the ponds with lower flow rates (ponds 6, 8, & 9). Furthermore, a

Figure 2.2. Relationship of goblet cell density to body weight of 1+ brown trout from each of three ponds sampled at The Ferry House in January 1977. Correlation coefficient, $r=0.81$ ($p<0.001$). (●) represent samples from pond 8; (○) from pond 9; (*) from pond 14.

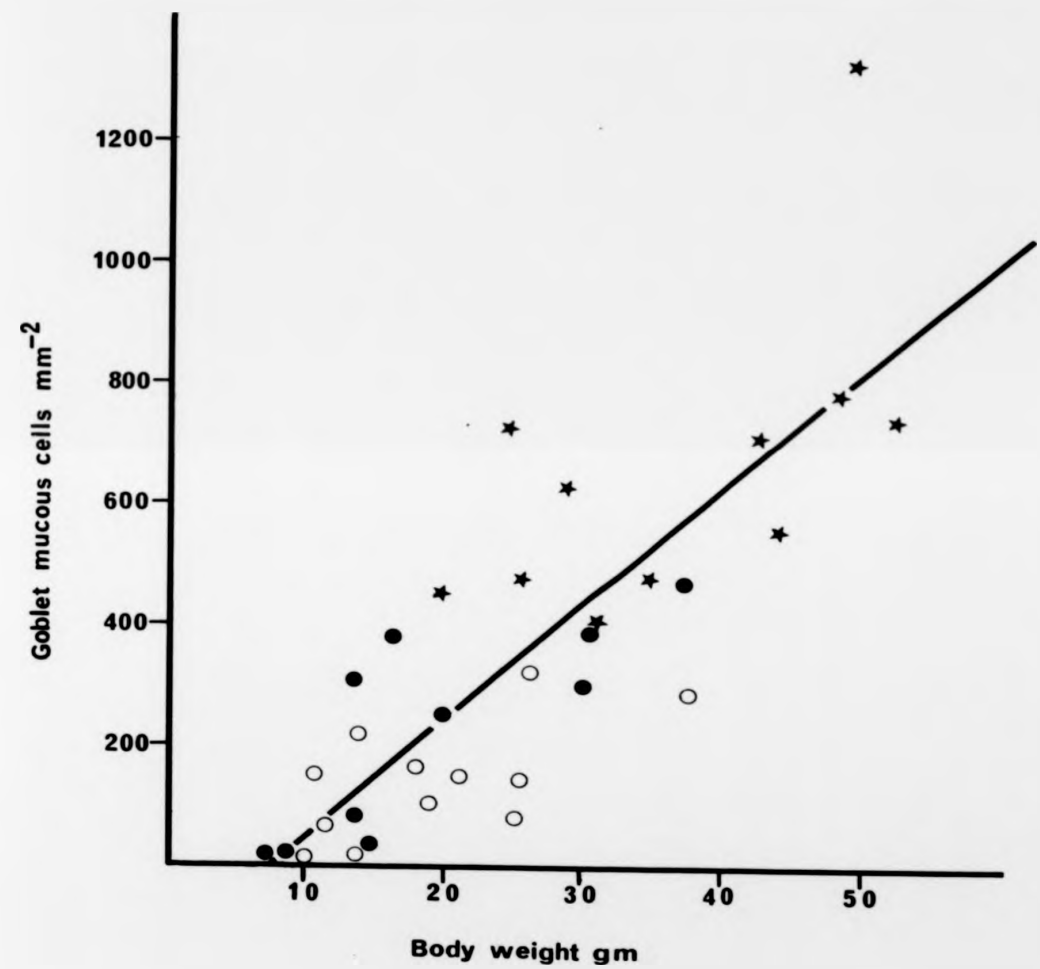


Figure 2.2.

Pond no	Size	Body weight g	Body length cm	Mucous cells mm ⁻²	Significance of differences between mucous cell densities		
					(a)	(b)	(c)
6	S	10.02 ± 1.42 (10)	9.43 ± 1.34 (10)	86.04 ± 41.22 (10)]**	nsd]**
	L	44.55 ± 4.1 (10)	15.52 ± 0.48 (10)	231.16 ± 61.76 (10)			
8	S	10.01 ± 0.94 (10)	9.47 ± 0.3 (10)	56.76 ± 35.38 (10)]**	nsd]**
	L	39.49 ± 2.76 (10)	14.89 ± 0.38 (10)	278.2 ± 121.66 (10)			
9	S	7.79 ± 2.44 (10)	8.73 ± 0.8 (10)	25.11 ± 36.86 (10)]**	nsd]**
	L	38.59 ± 2.56 (10)	14.73 ± 0.3 (10)	195.51 ± 51.8 (10)			
13	S	7.28 ± 1.1 (10)	8.54 ± 0.41 (10)	294.12 ± 165.5 (10)]nsd	nsd]**
	L	43.48 ± 3.56 (10)	15.29 ± 0.42 (10)	417.36 ± 74.84 (10)			
14	S	16.79 ± 1.36 (10)	11.02 ± 0.4 (10)	294.49 ± 62.66 (10)]nsd	nsd]**
	L	51.48 ± 4.92 (10)	16.14 ± 0.56 (10)	408.42 ± 92.74 (10)			
15	S	13.26 ± 2.04 (10)	10.49 ± 0.4 (10)	485.1 ± 153.8 (10)]**	nsd]**
	L	50.99 ± 3.4 (10)	16.42 ± 0.38 (10)	641.29 ± 94.04 (10)			
16	S	8.47 ± 0.94 (10)	8.99 ± 0.38 (10)	299.88 ± 64.24 (10)]**	nsd]**
	L	47.28 ± 1.02 (10)	15.81 ± 0.20 (10)	367.13 ± 61.86 (10)			

Table 2.5. Body weight, fork length and epidermal mucous cell density of fish from small (S) and large (L) size classes from each of seven ponds of 1+ brown trout sampled from The Ferry House hatchery in February 1977. Values given represent mean ± 95% confidence limits (sample size); * p<0.05, ** p<0.01, nsd no significant difference. Significances of differences in mucous cell densities refer to: (a) between S and L size classes in each pond; (b) between ponds with similar flow rates; (c) between groups of ponds with different flow rates. Further explanation of the statistical treatment is given in the text.

Pond no	Flow rate $l \text{ min}^{-1}$	Dissolved $[O_2]$ ppm	Alkalinity $\text{meq } l^{-1}$ bicarbonate	Dissolved $[CO_2]$ $\text{mg } l^{-1}$	[Ammonia-N] $\mu\text{g } l^{-1}$	pH	Temp
6	6.0	11.18	0.242	1.4	59.3	7.24	5.5
8	6.1	11.17	0.224	1.45	56.75	7.17	5.5
9	6.7	10.55	0.242	2.15	157.35	7.03	5.5
13	7.8	10.4	0.238	2.1	176.27	7.04	5.5
14	9.8	10.93	0.238	1.4	121.24	7.22	5.5
15	9.2	10.9	0.252	1.95	120.38	7.1	5.5
16	8.2	-	-	-	-	-	5.5

Table 2.6. Water conditions in seven ponds with 1+ brown trout sampled at The Ferry House hatchery in February 1977.

series of t-tests comparing mean epidermal mucous cell densities of small and large fish size classes within each pond demonstrated that in three ponds, all belonging to the group with higher flow rates, the differences were not significant (see Table 2.5 column (a)).

Temporal changes in skin structure within one age class (0+) were also investigated at The Ferry House hatchery. In 1975 and 1976 mean epidermal mucous cell density (monthly fish sample size six - forty-four) had been monitored during the development of young brown trout at this hatchery by other workers (Fig. 2.3a, b). In 1977 random samples of twelve individuals were taken at monthly intervals from the alevin and fry stocks and the sequence of change was found to follow the same pattern (Fig. 2.3c); mucous cell density was highest (c. 1500 cells mm^{-2}) immediately post-hatching but then decreased over the next few months until by June they had almost completely disappeared from the epidermis. However, when the trout were approximately three months old in 1977 (May sample), colonies of the parasite Ichtyobodo necator were identified on the skin surface and re-examination of sections prepared in previous years revealed that those fish had also been infested with this protozoan disease. It was also found that acidophilic cells occurred in increasing abundance as the goblet cells decreased. The observed changes in mucous cell density in whole skin preparations from 0+ trout in 1977 were confirmed by histological examination of skin from fish infested with Ichtyobodo.

Figure 2.3. Temporal changes in mean epidermal goblet cell density in 0+ brown trout sampled in The Ferry House hatchery over three consecutive years. Vertical bars represent 95% confidence limits.

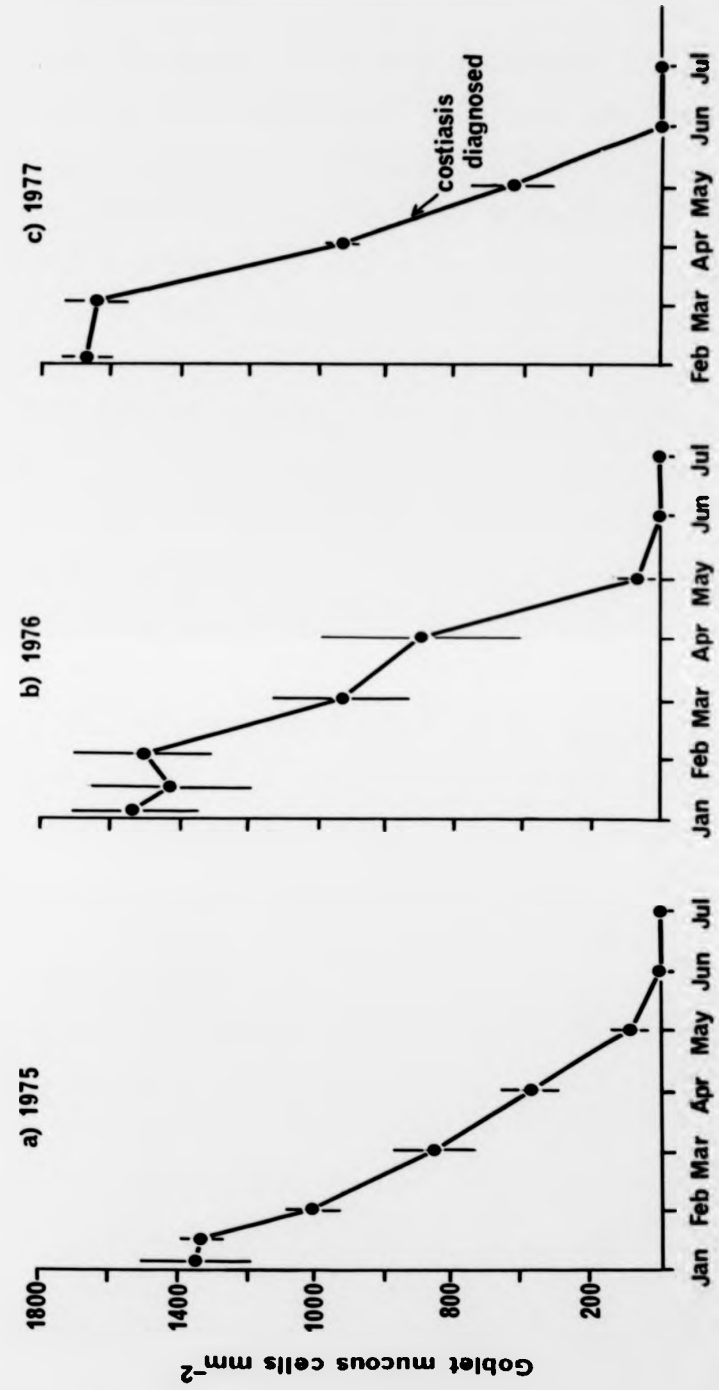


Figure 2.3.

Sections stained with Alcian blue (pH 2.5) followed by Ehrlich's haematoxylin and eosin or by Ewen's method showed that the decrease in mucification was not confined to the surface layers but was evident through the whole depth of the epidermis (Fig. 2.4).

Histochemical changes in the epidermal mucous cells were also noticed during the development of the young brown trout at The Ferry House hatchery. The integument of newly-hatched alevins gave different results compared to free-swimming fry when sheets of skin were stained with Alcian blue at either pH 2.5 or pH 1.0. In the very young brown trout (<1 month) the majority of epidermal mucous cells were found to take up Alcian blue at either pH, whereas in the fry (c. 6 months of age) they showed little affinity for the dye at pH 1.0 but stained intensely at pH 2.5. These preliminary results suggested that newly-hatched alevins secrete mucus with a different composition to that of fry.

Wild brown trout

A survey of O+ wild brown trout in various streams in north-west England also revealed significant differences in skin structure between some populations. The first samples were taken from Saint Sunday's Beck and Scandale Beck during May 1977. No significant differences in mean epidermal goblet cell densities were found between fish from these two streams (Table 2.7). Four becks were sampled during August of the same year. There had been very little rainfall for several

Figure 2.4. Section through the skin of O+ brown trout suffering from costiasis, showing a paucity of mucous cells throughout the epidermis. (H&E). X 1000.

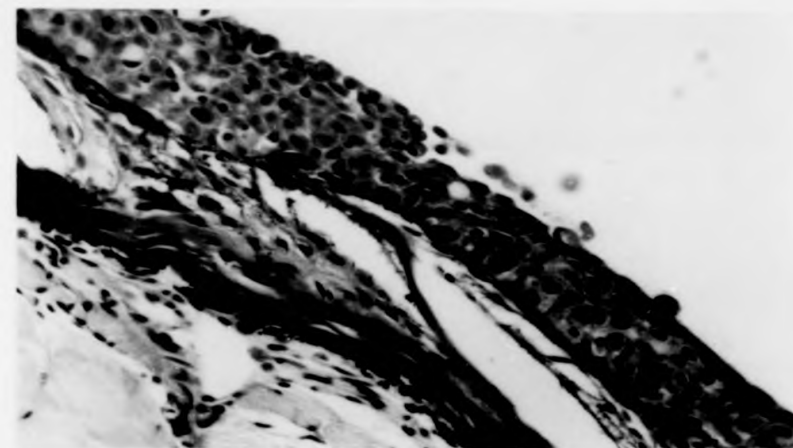


Figure 2.4.

Figure 2.4. Section through the skin of 0+ brown trout suffering from costiasis, showing a paucity of mucous cells throughout the epidermis. (H&E). X 1000.

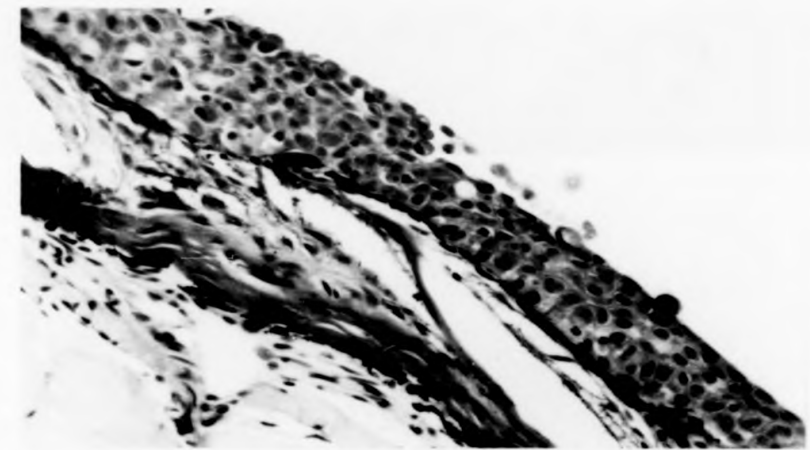


Figure 2.4.

Sampling site	Month	Body weight g	Body length cm	Mucous cells mm ⁻²	Significance of differences between mucous cell densities
Saint Sunday's Beck	May	0.23 ± 0.04 (14)	2.77 ± 0.1 (14)	830.2 ± 196.03 (14)] nsd
Scandale Beck	May			830.4 ± 169.21 (9)	
Scandale Beck	Aug	3.53 ± 0.54 (10)	6.27 ± 0.32 (10)	1154.4 ± 132.88 (10)] *
Dale Park Beck	Aug	2.71 ± 0.46 (14)	6.32 ± 0.52 (14)	228.9 ± 140.8 (14)	
Black Brows Beck	Aug	1.55 ± 0.38 (14)	5.27 ± 0.52 (14)	285.6 ± 125.37 (14)	
Wise Zen Beck	Aug	2.62 ± 0.4 (11)	6.20 ± 0.28 (11)	652.6 ± 147.8 (11)	

Table 2.7. Body weight, fork length and epidermal mucous cell density of 0+ brown trout sampled from streams in the north-west of England in 1977. Values given represent mean ± 95% confidence limits (sample size); * p<0.05, nsd no significant difference. Results of analysis of variance of weights and of lengths are given in the text.

weeks prior to sampling, with the result that at Dale Park Beck there was no visible water flow and trout were taken from an isolated pool in the stream bed. Analysis of variance was used to compare mean epidermal mucous cell densities of brown trout from the four streams. Significant differences in skin structure were found between trout from Scandale Beck (>1100 cells mm^{-2}), Wise Een Beck (c. 650 cells mm^{-2}) and Dale Park Beck and Black Brows Beck (both <300 cells mm^{-2}). Significant differences were also found between mean body weights ($p<0.001$) and between mean body lengths ($p<0.005$) of fish from the four streams sampled. However, there was no correlation between body size and epidermal structure in the wild fish. Acidophilic cells, staining intensely with eosin, of the same type or similar to those found in the hatchery-reared fish, were present in the epidermis of trout from each of the five sites and were most abundant in the Dale Park Beck population. Protozoans, including Scyphidia spp. and Vorticella spp. were seen in skin scrape preparations from all sites, but Ichtyobodo was found only on trout from Dale Park Beck (on six fish out of fourteen) and Black Brows Beck (on two fish out of fourteen).

The brown trout population in Scandale Beck was sampled throughout 1977 at approximately monthly intervals. Unfortunately it was not possible to obtain the yolk-sac stages from this fast-flowing stream. Fig. 2.5 shows the temporal variation of mean epidermal goblet cell density in $0+$ fish (sample size nine-eleven) and in sexually immature

Figure 2.5. Temporal changes in mean epidermal goblet cell density of a) 0+ brown trout and b) immature (1+ and older) brown trout sampled in Scandale Beck during 1977. Vertical bars represent 95% confidence limits. Asterisks indicate a significant difference in mean goblet cell density to that of the previous sample: * $p < 0.05$; ** $p < 0.01$. Results of analysis of variance are given elsewhere in the text.

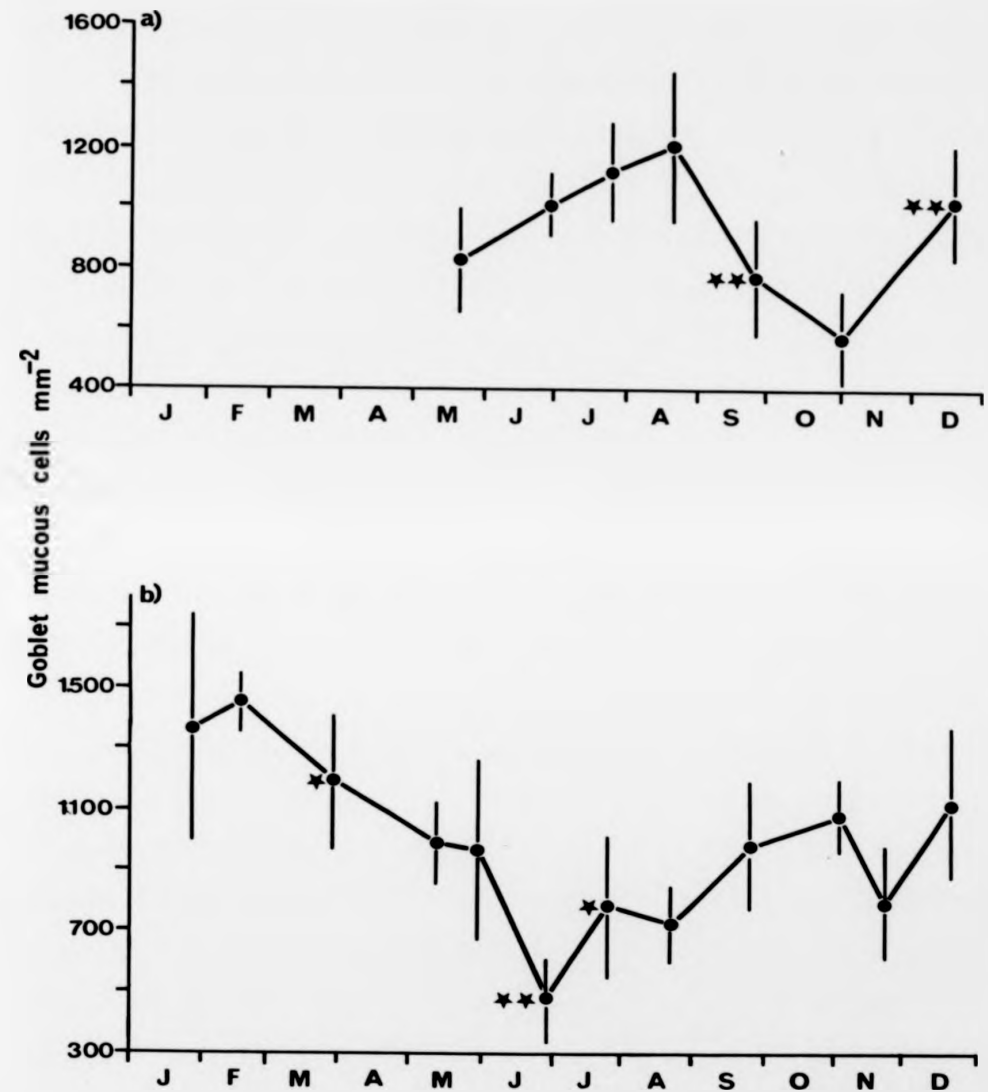


Figure 2.5.

fish of 1+ and older (sample size three-ten). Analysis of variance revealed significant differences between some of the samples within both groups of fish ($p < 0.001$ in both cases). A series of t -tests was then used to pinpoint significant differences between consecutive samples as indicated in Fig. 2.5. In the 1+ and older fish (Fig. 2.5.b) there was a gradual decrease in mucous cell density from approximately 1400 cells mm^{-2} at the beginning of the year to only 474 cells mm^{-2} in June, with significant decreases in density between February and March ($p < 0.05$) and between May and June ($p < 0.01$). There was then a significant increase in numbers between June and July to 781 cells mm^{-2} ($p < 0.05$) followed by a more gradual increase over the rest of the year until by December the density of epidermal mucous cells was again over 1000 cells mm^{-2} .

The changes in skin structure found in the 0+ fish from Scandale Beck did not follow the same trend (see Fig. 2.5.a). From the first sample, obtained in May, there was a gradual increase in epidermal mucous cell numbers from 830 to approximately 1100 cells mm^{-2} by August, but differences between samples were not significant. However, this was followed by a considerable and significant ($p < 0.01$) loss of goblet cells between August and September, the density falling to 778 cells mm^{-2} ; the decline subsequently continued until November. There was then a significant ($p < 0.01$) increase between November and December when the density of surface mucous cells was again over 1000 cells mm^{-2} .

Regular monitoring for skin infestations revealed that the protozoan ciliate Scyphidia spp. was fairly common in both groups of fish, especially during the summer months (June, July and August). A metazoan monogenetic trematode parasite Gyrodactylus sp. was also found, but on the O+ fish only. It was first seen on one fish in July, but was present in seven out of ten fish in the August sample and five out of ten in September; by November only one fish was infested.

2.4. Discussion

This survey of both wild and hatchery-reared salmonid fish has demonstrated that significant differences in epidermal structure can occur both between and within populations. These disparities could be due to a host of individual or interacting factors including both genetic differences and variation in environmental conditions. However, due to the large number of variables and the incompleteness of the information, it is not possible at this stage to pinpoint specific causes.

Significant quantitative differences in epidermal mucous cell density between brown trout and salmon reared at Carlisle hatchery may be simply a reflection of a differential response of these species to similar culture conditions. However, species differences in epidermal structure seem unlikely to be a complete explanation for this finding as Wilkins & Jancsar (1979) have recently recorded

Regular monitoring for skin infestations revealed that the protozoan ciliate Scyphidia spp. was fairly common in both groups of fish, especially during the summer months (June, July and August). A metazoan monogenetic trematode parasite Gyrodactylus sp. was also found, but on the O+ fish only. It was first seen on one fish in July, but was present in seven out of ten fish in the August sample and five out of ten in September; by November only one fish was infested.

2.4. Discussion

This survey of both wild and hatchery-reared salmonid fish has demonstrated that significant differences in epidermal structure can occur both between and within populations. These disparities could be due to a host of individual or interacting factors including both genetic differences and variation in environmental conditions. However, due to the large number of variables and the incompleteness of the information, it is not possible at this stage to pinpoint specific causes.

Significant quantitative differences in epidermal mucous cell density between brown trout and salmon reared at Carlisle hatchery may be simply a reflection of a differential response of these species to similar culture conditions. However, species differences in epidermal structure seem unlikely to be a complete explanation for this finding as Wilkins & Jancsar (1979) have recently recorded

epidermal mucous cell densities of approximately 1100 cells mm^{-2} in sexually immature hatchery-bred Atlantic salmon in July in Ireland; this value is very similar to the mean density of 1058 cells mm^{-2} measured in brown trout at Carlisle hatchery in August during the present survey.

The significant differences in epidermal structure within a single population at one point in time at The Ferry House hatchery may at least in part be related to water quality, since fish in the ponds with the higher flow rates also tended to have higher mucous cell densities. There is little published information concerning the effects of water chemistry on skin structure, but Burrows (1964) has shown that accumulated secretory products can affect the structure of the gill epithelium of hatchery-reared salmonids, and Daye & Garside (1980) have shown that 'sublethal alterations' occur in the integument of Atlantic salmon alevins incubated at low pH.

Even within a single hatchery pond, fish of the same age but in different size classes were shown to have significantly different epidermal mucous cell densities in The Ferry House hatchery. It is known from the work of Brown (1946a, b) that a 'size hierarchy' can develop in groups of brown trout fry and in older fish, and that an individual's specific growth rate is dependent on its position in the hierarchical order: the larger the fish, the higher its rate of growth. She also showed that there is an optimal degree of crowding for maximum productivity, and that overcrowding

adversely affects the specific growth rate of a population although a size hierarchy will still operate on the growth of individuals. It is for these reasons that the practice of size grading within age classes has become an integral feature of fish farm husbandry. Evidence for smaller fish being submissive has also been presented by Beitingger & Magnuson (1975) who found that small bluegills Lepomis macrochirus Rafinesque moved out of water of a preferred temperature if any larger bluegill was introduced. Subordinate fish can also apparently be under more stress. Using interrenal activity as an indicator of stress in Salmo gairdneri Richardson, Noakes & Leatherland (1977) have shown that an inverse correlation can develop between dominance rank and stress and also stress tolerance. Sparks, Waller & Cairns (1972) found that submissive bluegills succumb to lethal concentrations of zinc more quickly than dominant ones. The findings of the present investigation indicate that there is also an interaction between size hierarchy and water quality which is in turn reflected in skin structure; in ponds with low flow rates significant differences in epidermal mucous cell density were found between fish in small and large size classes, the smaller (presumably subordinate) fish having less goblet cells. How these interacting factors may operate to change skin structure is unknown, but, as well as a possible direct influence of water quality, there may also be additional effects mediated through skin infestations. In the wild fish, it was the samples from the slow

streams that had the lowest goblet cell numbers and also the greatest abundance of skin parasite infestations (see also below). The extreme case was Dale Park Beck which had dried up to such an extent that fish were isolated in a small pool where the low oxygen concentration was indicative of poor water quality. It might be expected that under adverse environmental conditions, subordinate fish with low epidermal goblet cell densities would be the first individuals in a population to succumb to ectoparasitic infestations.

The recorded changes in goblet cell densities in the cultured fish during the first few months after hatching are consistent with the observations of Stuart (1953) who found that newly-hatched brown trout alevins have a thicker mucous coat than free-swimming fry. He considered that a relatively thick mucous layer would provide protection from abrasion for the alevin in the gravel redd. The skin and its associated mucous layer is often described as the fish's primary defence against a potentially hostile environment (see, for instance, Pickering & Richards, 1980). In this respect, it is interesting that in The Ferry House hatchery a severe outbreak of costiasis in 0+ brown trout was associated with low epidermal goblet cell density. Richards & Pickering (1978) have suggested that susceptibility to Saprolegnia infection may also be associated with comparatively low epidermal goblet cell densities in brown trout; initial infection was observed most frequently on parts of the body known to have less mucification. In addition, they demonstrated that mature

male brown trout are more frequently infected than mature females which was related to a known sexual dimorphism in epidermal structure in Salmo trutta at spawning time described by Stoklosowa (1966) in sea trout and Pickering (1977) in brown trout.

Within populations of both wild and hatchery-reared brown trout studied in this preliminary survey, no clear relationships were observed between temporal changes in epidermal structure and variation in the environmental parameters measured. It has, however, already been shown that at one point in time, water flow rate can influence the mucification of hatchery-reared fish; this factor may also be expected to affect other variables, e.g. the concentration of ammonia-nitrogen and dissolved oxygen. It was thus important in subsequent experimental investigations into the temporal effects of ectoparasitic infestation, to establish similar culture conditions, with respect to flow rate and stocking density, between batches of fish to be subjected to different treatments.

As well as quantitative changes in skin structure, a qualitative change in epidermal mucous cell content was observed in O+ fish at The Ferry House hatchery during the first 6 months of life. The results of the histochemical tests carried out suggested that newly-hatched alevins have a more sulphated mucus than free-swimming fry (see Lev & Spicer, 1964; Jones & Reid, 1973). The possibility that this change in the chemistry of mucus may be associated with the

dramatic change from a benthic to a pelagic habitat that young salmonid fish in the wild experience following emergence from the gravel, warrants further investigation. Qualitative changes in mucous composition associated with changes in environmental conditions have been observed in mammals, which Gona (1979) has suggested may have a parallel in fish.

This survey has also drawn attention to cells of a type previously undescribed in brown trout epidermis. These cells, despite being similar in appearance to the goblet mucous cells, have very different staining affinities, showing negative reactions to tests for acid mucopolysaccharides and staining strongly with eosin. Although present in all of the populations of trout sampled, their abundance varied considerably and generally increased following a decrease in goblet mucous cell density. These acidophilic cells were particularly prevalent in fish suffering from costiasis.

The results of this initial survey support the view that the epidermis of salmonid fish is highly plastic and demonstrate that, as well as marked temporal changes, significant structural differences can occur both within and between populations. They point to the need for further investigation into changes in skin structure particularly with respect to alevin emergence, disease, water quality, irritation and social hierarchy, both in terms of variation in mucous cell density and in mucous quality. An attempt to elucidate the structure and functional role of the acidophilic cell(s) in

salmonid epidermis would also be desirable. In the chapters that follow, results are reported of investigations into some of these fields, in particular: the changes in brown trout skin structure and mucous cell histochemistry associated with alevin emergence, the pathogenesis of costiasis in 0+ fish and the effects of formalin treatment on the epidermis. The ultrastructure and histochemistry of one acidophilic cell type in the salmonid epidermis is also described.

salmonid epidermis would also be desirable. In the chapters that follow, results are reported of investigations into some of these fields, in particular: the changes in brown trout skin structure and mucous cell histochemistry associated with alevin emergence, the pathogenesis of costiasis in O+ fish and the effects of formalin treatment on the epidermis. The ultrastructure and histochemistry of one acidophilic cell type in the salmonid epidermis is also described.

Chapter 3

Changes in Epidermal Mucification in Brown Trout during the Early Stages of Growth

3.1. Introduction

It became clear during the preceding survey that the epidermis of 0+ brown trout Salmo trutta is particularly responsive to environmental change. The results indicated that 'natural changes' take place in the epidermis which may be related to the life history of the fish. During the early development of brown trout, the fish experience a dramatic change in habitat conditions and mode of life from burrowing activity in the gravel redd to a free-swimming life-style. Changes in skin structure and function at this time might not be unexpected. Although there is little detailed published information on the subject, there is some evidence that the epidermis undergoes structural and histochemical changes during the alevin-fry transition, e.g. Stuart (1953); Porcelli & Massari (1969). It is also well known that first-feeding salmonid fry are particularly susceptible to skin infestations, such as costiasis, under hatchery conditions (e.g. Robertson, 1979), and data presented earlier (in Fig 2.3, Chapter 2) indicate that the outbreak of disease can coincide with marked changes in epidermal structure.

In order to assess the pathological changes associated

with disease or adverse environmental conditions, it is necessary to initially establish the 'normal' sequence of development in the epidermis of disease-free fish. In the present investigation results are reported of a quantitative, histological and histochemical study of the epidermis of hatchery-reared and wild brown trout from hatching through to the free-swimming fry stage.

3.2. Materials and Methods

Hatchery-reared fish and stream sampling sites

In 1978 eyed eggs were obtained from a commercial hatchery in Yorkshire and hatched in a Heath incubator with a constant flow of Windermere lake water (at 9 l min^{-1}), with a temperature range of $2.3\text{--}6.0^{\circ}\text{C}$ during incubation). Resulting alevins were transferred to 4 floating cages each inside a separate fibre-glass tank (capacity 80 l) at a stocking density of 600 fish per cage and supplied with filtered, Windermere lake water which was sterilized with ultra-violet light (peak emission 254nm). Photoperiod and temperature were controlled to match outdoor conditions in The Ferry House hatchery. Dissolved oxygen concentration, pH, total ammonia-nitrogen concentration, alkalinity, temperature and the concentration of free carbon dioxide were measured regularly (using the methods described in Chapter 2). Alevins were fed four times daily with a commercially prepared diet (Baker's No.1) and tanks were cleaned daily with a siphon system. Frequent

checks were made for skin infestations on sacrificed fish by means of microscopical examination of fresh skin scrapes. No ectoparasites were found during the course of the investigation.

Wild fish were obtained from five different streams in north-west England (Black Brows Beck, Dale Park Beck, Scandale Beck, Saint Sunday's Beck and Wise Een Beck, descriptions of which are given in Table 2.2, Chapter 2) on several occasions during the years 1976-79. Eggs and alevins were obtained by kick samples and fry were collected by electro-fishing. Only samples in which all fish were free of skin parasites or other signs of infection were used in this study.

Histology

A sample of ten alevins (2 day old) from the hatchery and ten free-swimming young fry from Saint Sunday's Beck were fixed in 10% formalin (in phosphate buffer) and processed for histological examination (as described in Chapter 2). Skin sections were stained with Alcian blue (pH 2.5) and Heidenhain's haematoxylin (He) and counterstained with eosin or Mallory's aniline blue/orange G (AnB/OG).

Histochemistry and cell counting

Fish were anaesthetized in MS 222 (Sandoz, 0.1 g l⁻¹) and fixed whole in 10% formalin in 0.6% NaCl with the addition of 0.001% eosin. This solution selectively stains acidophilic

cells in the epidermis during fixation. For epidermal cell counts and histochemical tests skin was removed from the whole of one side of the body and examined microscopically after staining as a sheet of tissue by one of the following procedures.

i. Alcian blue (AB pH 2.5)/periodic acid-Schiff's reagent (PAS)

Skin samples were washed in running water, rinsed in 3% acetic acid (pH 2.5) and stained for 10 minutes in 1% AB in 3% acetic acid (pH 2.5). After a 10-minute wash in running water, the tissue was oxidized for 10 minutes in 0.5% periodic acid, washed for a further 10 minutes and then placed in Schiff's reagent for 10 minutes. The reaction was stopped with three 2-minute baths of 0.05 M sodium bisulphite followed by a final 10-minute wash in running water. After subsequent dehydration and clearing the tissue was mounted in Canada balsam.

ii. Alcian blue (pH 2.5)

The AB (pH 2.5)/PAS procedure showed that all superficial goblet cells contained acid mucopolysaccharides. It was therefore appropriate to use the AB (pH 2.5) procedure of Pickering (1974) to stain these for subsequent cell counting. The numbers of superficial mucous cells and acidophilic cells (previously observed during preliminary survey work, see Chapter 2) were counted in each of 30 randomly-placed 0.0076 mm² quadrats per fish. Since it was possible that the cell

types had contagious distributions, a small quadrat size was chosen to increase the accuracy of the estimates of mean cell densities (Elliott, 1977); quadrats were positioned randomly to avoid bias resulting from differential patterns of dispersion between the cell types in the surface of the skin samples. Samples of ten individuals were taken from one batch of fish at fortnightly intervals from the hatchery. In the wild populations there were no obvious differences between healthy fish at similar stages of development from different sites or between different years and, because it was not possible to obtain all stages from each site, the data for the wild fish were pooled.

iii. Alcian blue (pH 1)/Alcian yellow (AY pH 2.5)

This procedure is based on that described by Wijdenes, van Minnen & Boer (1980) but modified to suit thin sheets of tissue. The fixed skin was rinsed in distilled water, placed in 0.1 M HCl (pH 1.0) for 5 minutes and then stained with 0.5% AB in 0.1 M HCl for 20 minutes. Following 5 minute rinses in 0.1 M HCl and 3% acetic acid (pH 2.5) the tissue was stained with 0.25% AY in 3% acetic acid for 20 minutes and rinsed successively in 3% acetic acid and distilled water. Specimens were rapidly dehydrated, cleared and mounted in Canada balsam. Superficial epidermal mucous cells were stained either blue (sulphated acid mucopolysaccharides), yellow (carboxylated acid mucopolysaccharides) or green (a combination of both types). Differential cell counts were

made for each fish from fifty randomly-placed quadrats (0.01 mm^2) and the proportions of mucous cells giving the three different staining reactions were calculated. The data for the wild fish in this case were obtained from a single population (Black Brows Beck) within one year (1979). The weight and fork length of each fish were also recorded. Samples of ten fish were obtained at approximately monthly intervals from January to July in the hatchery and from May to July in the wild population.

3.2. Results

Changes in epidermal structure

In the hatchery-reared fish superficial epidermal mucous cell density was highest (c. $1500 \text{ cells mm}^{-2}$) during the period January to March, i.e. during the period of yolk sac resorption (Figs 3.1; 3.3.a). Mucous cell density then declined rapidly during April to c. $700 \text{ cells mm}^{-2}$ and remained at this level during the succeeding fry stage (May, June and July). The pattern of changes in mucous cell density in the wild fish was very similar although the timing of the decrease was approximately one month later. However, when considered in terms of development, the changes occurred at the same stage in the young fish (Figs 3.2.; 3.3.b). The decrease in mucification in the wild fish was coincident with the period during which the young fish were emerging from the gravel redd. There was no significant change in the density

Figure 3.1. Temporal changes in mean epidermal goblet cell density during the early development of hatchery-reared brown trout sampled at The Ferry House in 1978. The stages of alevin development are shown according to the scheme of Stuart (1953). Vertical bars represent 95% confidence limits.

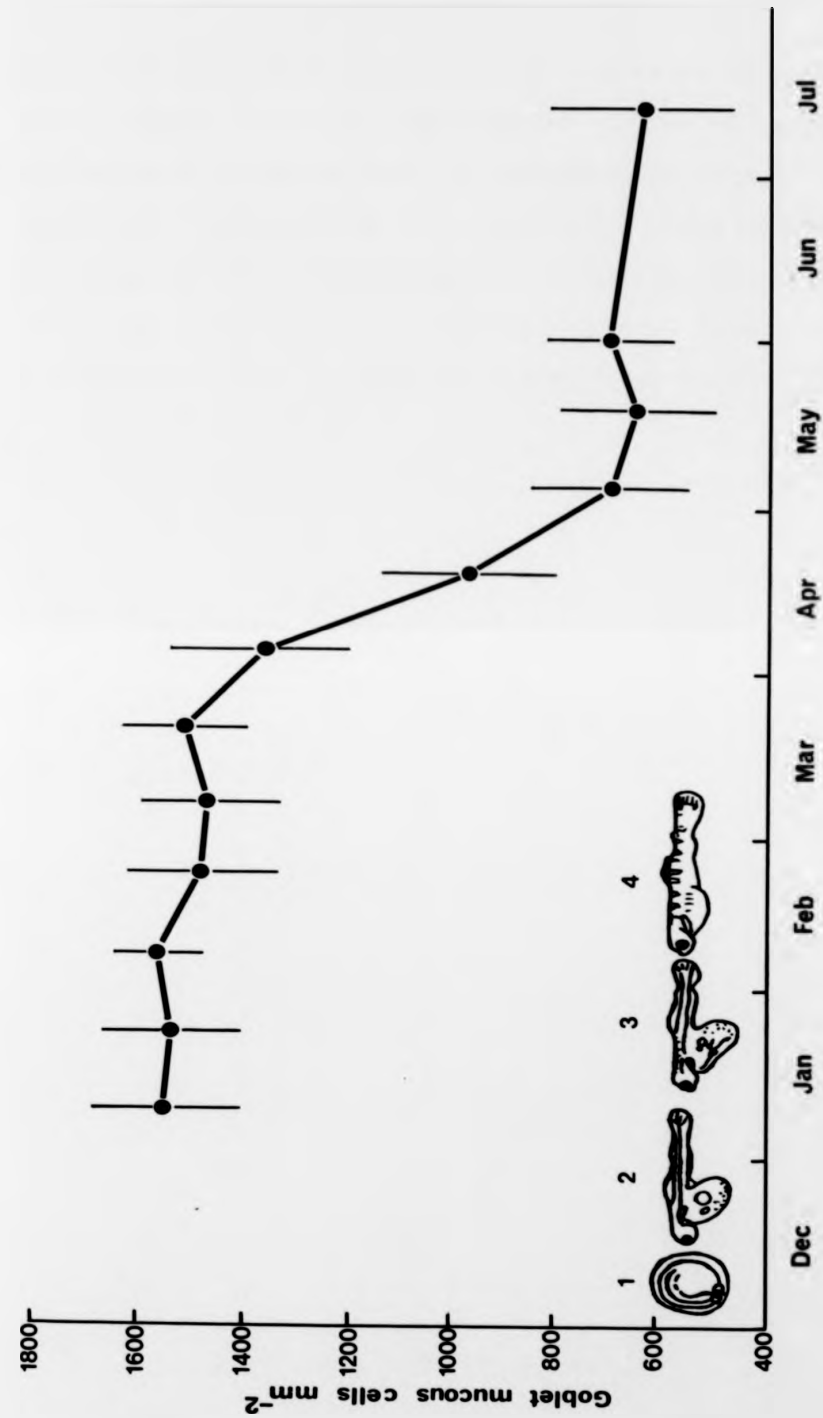


Figure 3.1.

Figure 3.2. Temporal changes in mean epidermal goblet cell density during the early development of wild brown trout sampled from several streams in north-west England in 1976-9. Only samples in which all fish were free from ectoparasitic infestation are included. The stages of alevin development are shown according to the scheme of Stuart (1953). Vertical bars represent 95% confidence limits.

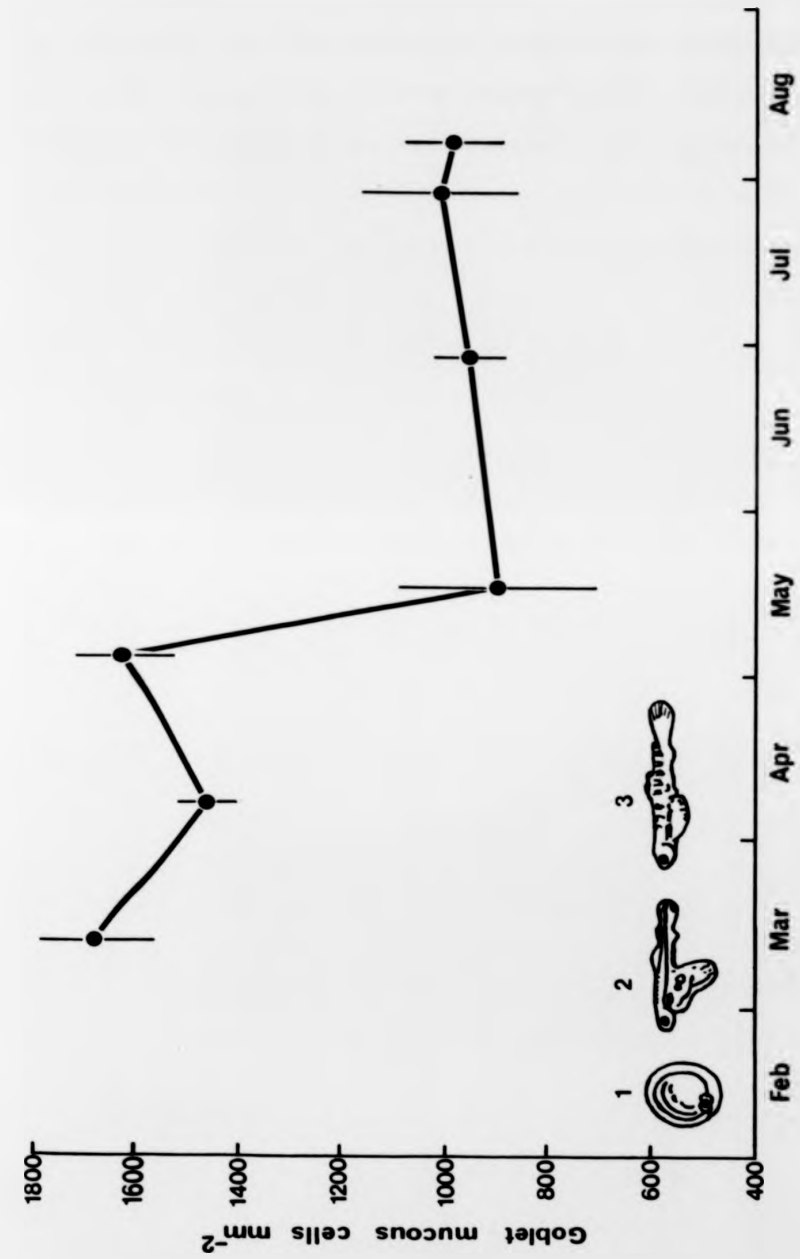


Figure 3.2.

Figure 3.3. Transverse section through (a) the skin of a cultured brown trout 2 days post-hatching showing abundant, actively-secreting mucous cells, and (b) the skin of a wild brown trout soon after emergence from the redd demonstrating the reduction of epidermal mucous cells. (a) stained with AB (pH 2.5), He&E; (b) stained with AB (pH 2.5), He&AnB/OG. Both X 1000.

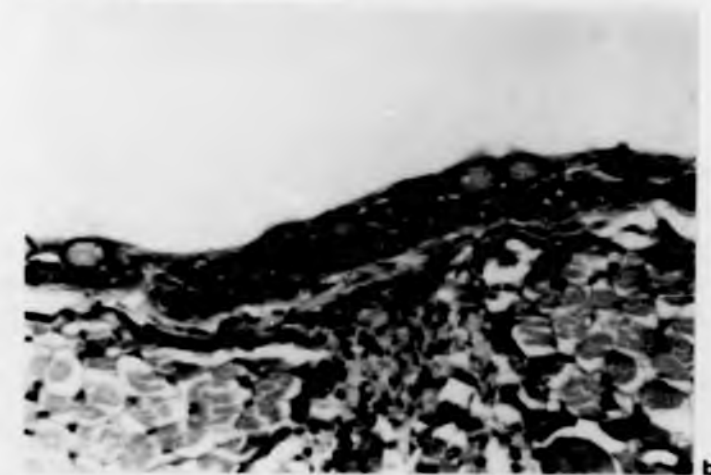
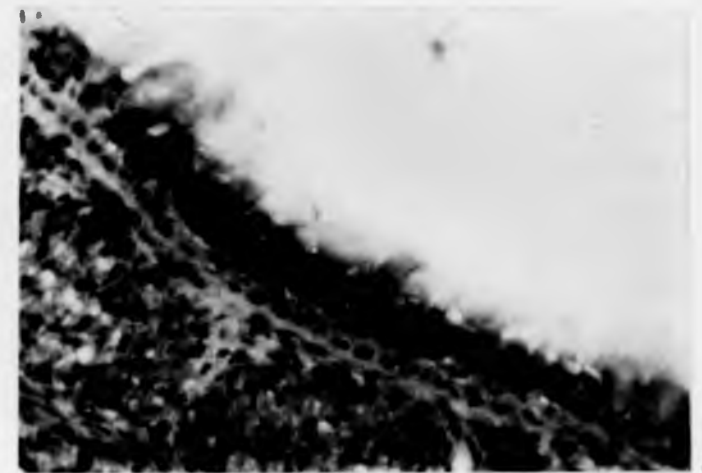


Figure 3.3.

Figure 3.3. Transverse section through (a) the skin of a cultured brown trout 2 days post-hatching showing abundant, actively-secreting mucous cells, and (b) the skin of a wild brown trout soon after emergence from the redd demonstrating the reduction of epidermal mucous cells. (a) stained with AB (pH 2.5), He&E; (b) stained with AB (pH 2.5), He&AnB/OG. Both X 1000.

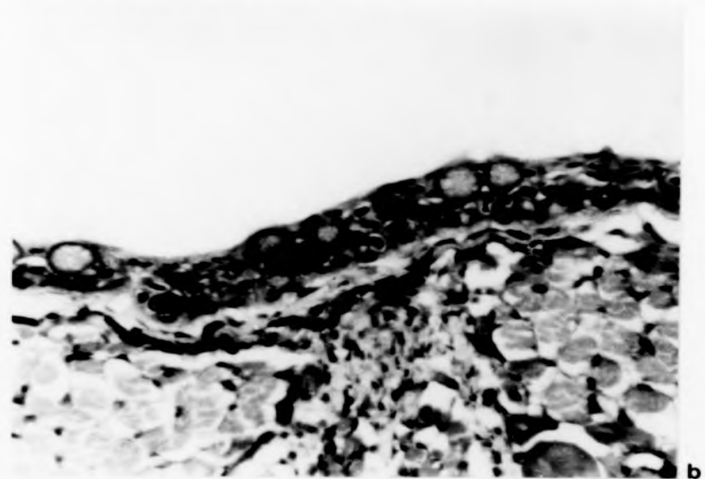
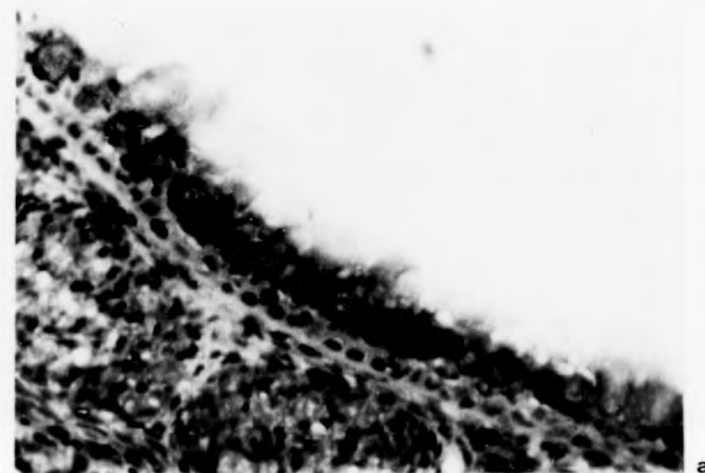


Figure 3.3.

of acidophilic cells during the investigation (Kruskal-Wallis non-parametric test for differences in location in ranked data grouped by single classification) in both the hatchery-reared and wild brown trout.

Changes in mucous cell histochemistry

With the AB (pH 2.5)/PAS procedure all cells stained blue or blue/purple. Goblet cells containing only neutral mucopolysaccharides (stained magenta) were very rarely seen at any stage of development. Using the AB (pH 1)/AY (pH 2.5) technique, however, changes were observed in mucous cell histochemistry during the early stages of brown trout development. In the hatchery-reared fish the majority of epidermal mucous cells stained green immediately post-hatching, i.e. contained both sulphated and carboxylated acid mucopolysaccharides (Fig 3.4). The percentage of green cells remained more or less stable during the period of yolk-sac resorption (January-March), but during April-June there was a change in the proportion of cells staining blue, green or yellow and by July cells staining with Alcian yellow alone predominated. Similar changes in epidermal mucous cell histochemistry were observed in the wild fish at comparable stages of development (Fig 3.5). The change in composition of the epidermal mucins from a mixture of sulphated and carboxylated to almost entirely carboxylated acid mucopolysaccharides occurred at the time when the wild fish were emerging from the redd. At the end of this investigation (in July) only

Figure 3.4. Histograms showing temporal changes in the histochemistry of epidermal goblet cells during the early development of hatchery-reared brown trout sampled at The Ferry House in 1978. For each month the proportions of cells with different staining properties are shown: sulphated acid mucopolysaccharides only (stained blue with AB pH 1) in blocks with vertical lines; sulphated and carboxylated acid mucopolysaccharides (stained green with AB pH 1 and AY pH 2.5) in open blocks; carboxylated acid mucopolysaccharides only (stained yellow with AY pH 2.5) in blocks with open circles. Vertical bars represent 95% confidence limits.

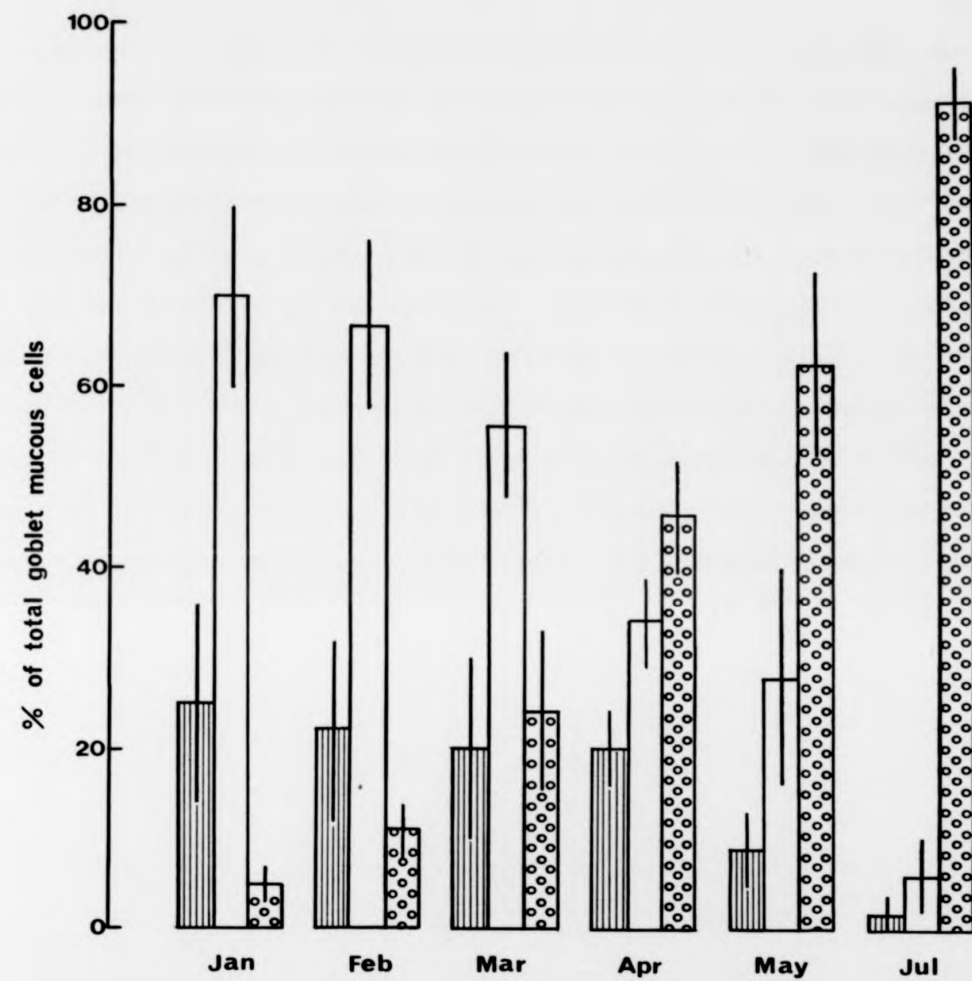


Figure 3.4.

Figure 3.5. Histograms showing temporal changes in the histochemistry of epidermal goblet cells during the early development of wild brown trout sampled from Black Brows Beck in 1979. For each month the proportions of cells with different staining properties are shown: sulphated acid mucopolysaccharides only (stained blue with AB pH 1) in blocks with vertical lines; sulphated and carboxylated acid mucopolysaccharides (stained green with AB pH 1 and AY pH 2.5) in open blocks; carboxylated acid mucopolysaccharides only (stained yellow with AY pH 2.5) in blocks with open circles. Vertical bars represent 95% confidence limits.

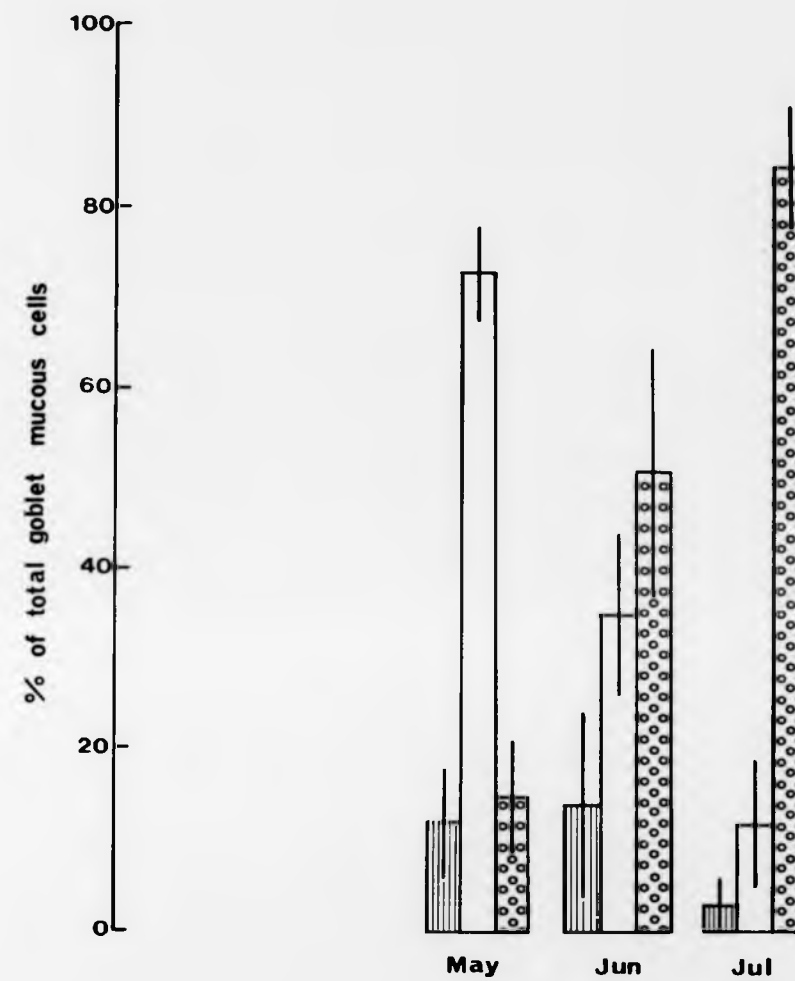


Figure 3.5.

very few cells stained with Alcian blue alone, i.e. contained only sulphated acid mucopolysaccharides, and these were usually located close to the lateral line.

3.4. Discussion

The results of this investigation (see also Blackstock & Pickering, 1982) have confirmed and extended the preliminary findings presented in Chapter 2. There are marked changes in epidermal mucous cell density and in mucous chemistry during the alevin and fry stages of brown trout. At the time of emergence from the gravel there is a considerable reduction in mucification of the epidermis concomitant with a change in the histochemistry of the goblet cells towards a decrease in sulphation and an increase in carboxylation of their mucopolysaccharide content. These changes were found in both wild and hatchery-reared fish kept under artificial conditions during the whole period of the alevin-fry transition, despite the fact that hatchery-reared fish were maintained in gravel-free conditions. Stuart (1953) observed that recently-hatched brown trout alevins have a thicker layer of mucus than do free-swimming fry and he also suggested that a thick coat of mucus confers protection to the young fish from abrasion whilst in the gravel; the timing of changes in epidermal mucous cell density reported here supports this hypothesis.

If the suggestion that a high mucous cell density has an

important protective role during the existence of young trout alevins in the gravel redd is correct, then, conversely, it might be expected that epidermal mucification would increase during development in fish species with pelagic larval stages and benthic adult stages. There is some published information indicating that this can indeed be the case. The American eel Anquilla rostrata (LeSueur) is a teleost with such a life cycle. Leonard & Summers (1976) noted that the numbers of epidermal mucous cells increased progressively in this species during development from the pelagic leptocephalus larva, through the glass eel and the elver stages, to the benthic adult eel. Roberts, Bell & Young (1973), in a study of the skin of the plaice Pleuronectes platessa, also reported an increase in mucification from the pelagic larval stage through metamorphosis to the benthic adult.

In the present study, the results of histochemical tests on the goblet cells indicated that substantial amounts of sulphated acid mucopolysaccharides are present during the early, highly-mucified, benthic alevin phase of development in brown trout. In contrast, the less-mucified epidermis of the free-swimming stage was associated with a decrease in sulphation and an increase in the proportion of goblet cells containing carboxylated acid mucopolysaccharides. N-acetyl neuraminic acid has been demonstrated to be the principal sialic acid present in the goblet cells and epidermal mucous secretions of the brown trout (Pickering, 1974; 1976), and it therefore seems likely that the increase in carboxylation

reflects an increase in the sialic acid content of the mucous cells. Such an increase in the sialic acid content of the epidermal mucous cells during development has been reported for the rainbow trout Salmo gairdneri by Porcelli & Massari (1969).

Other published examples provide some support for the suggestion of an association of a sulphated epidermal mucous secretion with a benthic habit and a more carboxylated mucus with a pelagic habit. For example, Roberts, Bell & Young (1973) found that sulphated mucins progressively appear as the pelagic larval form of the plaice develops into a benthic adult. Furthermore, a number of predominantly benthic or burrowing species of fish are reported to have sulphated epidermal mucins, including Heteropneustes fossilis (Bloch), Monopterus albus (Hamilton) (= Amphipneustes albus) and Mastacembelus panculus (Hamilton) (Mittal & Munshi, 1971), Channa striata (Bloch) (Mittal & Banerjee, 1975) and Anguilla anguilla (L.) (Archer, 1979), whereas free-swimming salmonid fish are known to have predominantly carboxylated mucins as has been shown in the cases of Atlantic salmon Salmo salar (Harris & Hunt, 1973), brown trout (Harris, Watson & Hunt, 1973), rainbow trout (Fletcher, Jones & Reid, 1976) and char Salvelinus alpinus (Pickering & Macey, 1977). However, these represent only a very small proportion of the many thousands of benthic and pelagic fish species, and further comparative histochemical studies are required to clarify the situation.

In mammals, bronchial mucosae respond to certain forms of

irritation by an increase in goblet cell density and in the acidity of their mucopolysaccharide content (Reid, 1970; Jones, Bolduc & Reid, 1973). It has been suggested that this pattern of change may have an analogy in fish (Gona, 1979). Keal (1971) has demonstrated a positive correlation between neuraminic acid content and the degree of viscosity of mucus in mammalian sputum, and so it is possible that the relatively sulphated mucus of the epidermis of the benthic brown trout alevin may have different physical properties to the mainly carboxylated mucin(s) of the free-swimming fry. In addition, Lopez-Vidriero, Jones, Reid & Fletcher (1980) have compared the sulphated mucus of plaice to that of normal, human bronchial secretions which contain both sulphated and sialated mucus, and have shown the plaice mucus to be low in non-dialysable material and to have a low viscosity. Changes in the physical properties of the mucus of young brown trout could be related to the need for protection from abrasion in the alevins during burrowing activity in gravel, and the need for an efficient lubricant to aid free-swimming in the fry. The friction-reducing properties of fish slime have been reported by Rosen & Cornford (1971), Hoyt (1975) and Daniel (1981).

Another role often attributed to fish mucus is to act as a barrier to potential pathogens in the environment. This may be in the form of a physical barrier which is constantly sloughed off and replenished (see Willoughby & Pickering, 1977) or a barrier containing molecules with possible anti-

biotic properties (Fletcher & Grant, 1969; Bradshaw, Richard & Sigel, 1971). It is noteworthy that the time at which young hatchery-reared salmonid fish are particularly prone to skin infections (at the end of yolk-sac resorption and at the onset of first-feeding) is coincident with the marked decline in epidermal mucification and the shift from sulphation to carboxylation. Further work is needed to investigate the physical and biological properties of the epidermal mucus at different phases during the development of brown trout.

The results presented here have given a partial explanation of the data presented in Fig 2.3, Chapter 2. It has been shown that the initial decline in mucous cell density observed in the first three months of life in three successive years was an entirely natural phenomenon. However, in each of the three years (1975-77) the mucous cell density did not stabilize in subsequent weeks but continued to decrease so that by the age of 4-5 months the brown trout epidermis was devoid of mucous cells. In 1977 this depletion was coincident with a severe outbreak of costiasis and it is now known that this disease had also occurred in the preceding two years. Having established the normal sequence of changes in O+ brown trout epidermis there is a basis on which to evaluate the impact of this protozoan parasite. In the following chapter, the results of an investigation to quantify structural changes induced by costiasis under controlled conditions are reported.

Chapter 4

Changes in Cellular Composition in the Epidermal Surface Associated with Costiasis in O+ Brown Trout

4.1. Introduction

Some of the normal structural changes in the epidermis of the alevin and fry stages of disease-free brown trout Salmo trutta have been described in the previous chapter. Also, the vulnerability of hatchery-reared brown trout to protozoan skin infestations at the time of yolk-sac resorption and commencement of first-feeding has been noted. Brown trout reared at The Ferry House hatchery and monitored during 1977 (as outlined in Chapter 2) contracted costiasis at this stage of development; it was further established that fish in this hatchery had been affected by the disease in previous years.

Costiasis is the now familiar term for the ectoparasitic condition caused by Ichtyobodo necator (Henneguy) Pinto (= Costia necatrix). Although another species, C. pyriformis, has been described by Davis (1943), it is now considered to be no more than a small form of the highly variable Ichtyobodo necator (Becker, 1977), and Ichtyobodo is generally treated as a monotypic genus. Ichtyobodo has also had a chequered history at higher levels of taxonomic rank. Grassé (1952) was unable to resolve its systematic position within the zooflagellates; even recently it has been assigned

to the Tetramitidae (Olsen, 1974) on the grounds of earlier reports of forms with four flagella, which have in fact been shown, by Joyon & Lom (1966), to be pre-division stages. It is now accepted as a member of the Bodonidae (Joyon & Lom, 1969) in which it had been provisionally placed by Henneguy (1883) on the basis of his early, elegant morphological observations.

Various aspects of the life history and ecology of Ichtyobodo are still incompletely described, and no culture methods have as yet been developed for this bodonid. Longitudinal division is known to take place but whether there is a sexual and/or dormant phase remains to be determined. Cyst formation has been reported by Moroff (1904) but he was unable to repeat and confirm his initial observations. Ichtyobodo can exist in two forms, one free-swimming and the other attached to fish integument (e.g. Grassé, 1952), but according to Henneguy (1884) it is a true parasite which cannot survive for any length of time in isolation from its host. Using the modern technique of electron microscopy, it has been shown that this small (c. 10 μ m) ectoparasite actually penetrates the host cell from which it probably derives most of its nutritional requirements (Schubert, 1968; Joyon & Lom, 1969).

Ichtyobodo is known to infest both the gills and the skin of fish. Costiasis of the gills has been considered to cause more damage than skin infestations, and mortalities have been attributed to subsequent dyspnoea (e.g. Léger, 1909; Savage,

1935). On the other hand, Robertson (1979) in an investigation of costiasis in farmed rainbow trout Salmo gairdneri, reported that although both the gills and skin were affected, epidermal infestations were more prolonged. At The Ferry House, the intensity of gill infestation was never observed to be as great as on the epidermis, and this is also in agreement with other published reports (e.g. Fish, 1940a; Tavalga & Nigrelli, 1947). Robertson (1979) also found that, in both Atlantic salmon S. salar and rainbow trout, Ichtyobodo infestation reached a peak in young fish four weeks after commencement of first-feeding. Robertson, Roberts & Bullock (1981) demonstrated an association between the incidence of this disease and depletion of epidermal mucous cells; however, this depletion was not quantified nor its time scale established.

In the present investigation, experiments were undertaken, from September 1977 to September 1978, to compare the response of surface epidermal cell structure in O+ brown trout to Ichtyobodo infestation with that of fish kept disease-free. The effects of costiasis on the density of both superficial goblet cells and the acidophilic cells observed during preliminary survey work (Chapter 2) are considered. One of the methods employed for maintaining stocks free of Ichtyobodo infestation is by treatment with formalin, the most commonly used agent for controlling protozoan skin infestations in fish farms in Britain. The more detailed histopathological effects of costiasis will be reported in

the next chapter where the effects of long-term formalin prophylaxis will also be described.

4.2. Materials and Methods

Fish rearing methods

In 1978 batches of brown trout were reared under different culture conditions at The Ferry House hatchery. One group of batches, group A, was maintained throughout the year in lake water from Windermere, the probable source of Ichtyobodo infection. Two other groups were kept disease-free for at least part of the year. Group B was reared in ultra-violet light sterilized lake water for the first part of the year prior to being transferred to untreated lake water. Group C was subjected to formalin prophylaxis throughout the year.

In all cases eggs obtained from a commercial hatchery were hatched in a Heath incubator with a constant supply of lake water (at 9 l min⁻¹ with a temperature range of 2.3-6.0°C). After hatching the majority of alevins (groups A and C) were transferred to outdoor fibre-glass troughs (each with a 20 l capacity) at an initial stocking density of 700 fish per trough; each trough had a constant supply of coarsely filtered (glass-wool) lake water (at 6 l min⁻¹). The fish in group C had been given a daily dose of formalin at 330 ppm for 15 minutes at the egg stage; after hatching, a weekly formalin treatment was applied at 33 ppm for 15 minutes. In total, there were twelve troughs with fish in group A, and

eight troughs with fish in group C. The troughs were covered until swim-up when the covers were gradually replaced with green plastic mesh shading to simulate light conditions in the wild. Fish in group B were kept indoors in u.v.-sterilized lake water (see Chapter 3); temperature and day-length were regulated to match those experienced by the alevins in the outdoor troughs. These fish were reared in four cages each with an initial stocking density of 600 individuals per cage, (which was equivalent to that in the troughs of group A and C).

At 5 months of age, fry from all three groups were moved to larger outdoor fibre-glass ponds (1500 l capacity) with a constant lake water supply (at 8 l min⁻¹). Fish under the different treatments were kept in three separate ponds, each with an initial stocking density of 1000 individuals per pond. In the pond with fish in group C, formalin prophylaxis was continued. In the group B pond, fish which had been reared in u.v.-sterilized water now experienced a change to untreated lake water, (at this age it was no longer practical to keep fish indoors in u.v.-sterilized water). Each pond had an initial water depth of 20 cm which was increased gradually over 5 months to 50 cm as the fish grew. No attempts were made to grade the fish so that handling stress, which is known to influence epidermal mucification in older salmonids (Pickering & Macey, 1977; Pickering, Pottinger & Christie, 1982), was avoided after initial transfer. Due to unavoidable circumstances, the diet of all the fish had to be changed to

one of a different composition and manufacture in early August. To minimize the effects of this dietary change, the fish were fed for a week with a mixture of the old and new diets but a certain amount of stress resulted; fish were inappetant for at least 2-3 days after transfer to the new diet and an increase in the mortality rate occurred. Through the course of the year, the same feeding and cleaning regime was maintained for each group of fish and regular checks were made for ectoparasitic infestations. Dead fish were removed daily and post mortem examinations carried out. Various environmental parameters were also monitored, namely pH, total ammonia-nitrogen concentration, alkalinity, dissolved oxygen concentration, temperature and the concentration of free carbon dioxide (using the techniques given in Chapter 2).

Brown trout reared at The Ferry House hatchery in 1977 were also used in this investigation. Until the age of 7 months, fish were kept in lake water under the same conditions as those in group A above. At the age of 3 months, costiasis had been diagnosed but no remedy had been administered at that stage. In September 1977, therapeutic formalin treatment was applied under controlled conditions to some of the diseased fish. Brown trout were maintained in three separate fibre-glass ponds (each with 1500 l capacity) at an initial stocking density of c. 650 fish per pond. No treatment was given to pond D. The fish in pond E received formalin treatment at 200 ppm for 20 mins, the recommended

dose to cure costiasis (Roberts & Shepherd, 1974). This was a single dose given on day 0 after the first sample of fish had been taken (see below). Pond F received a similar dose of formalin on day 0 and twice more at monthly intervals to combat possible reinfection.

For all the samples of fish taken during the course of the experiments outlined below, the fork length and body weight of each individual was recorded.

Experimental design

Experiment 1

The aim of this investigation was to quantify the effect of Ichtyobodo on the epidermal structure of young brown trout in comparison with that of fish kept free of ectoparasites through the use of u.v.-sterilized water or by formalin prophylaxis. Samples of ten fish were taken at fortnightly intervals after hatching, from January to May 1978, from each of three single batches of brown trout reared under the following controlled conditions.

Group A: exposed to Ichtyobodo, in untreated lake water.

Group B: unexposed to Ichtyobodo, in u.v.-sterilized lake water.

Group C: reared in lake water regularly treated with formalin.

The fish were anaesthetized, fixed and the skin was removed and stained with Alcian blue (pH 2.5) using the

method described in Chapter 3. The numbers of goblet mucous cells, acidophilic cells and Ichtyobodo individuals were counted in each of thirty randomly-positioned 0.0076 mm² quadrats on the skin preparations from each fish (some of the results of group B fish have also been presented separately in Fig. 3.1, Chapter 3). Comparisons between the mean epidermal goblet cell densities of the three groups of fish were made by means of a two-factor analysis of variance using the Genstat package (Rothamsted Experimental Station) on the North-West computer network. The analysis was carried out on untransformed data following the results of a F max test for homogeneity of variance. The factors were: treatments (three) versus sampling times (eight). Epidermal structure and Ichtyobodo infestation were also monitored in additional monthly samples taken from one other batch of fish under each of the three treatments.

Experiment 2

This experiment was designed to investigate the effects of Ichtyobodo infestation on the epidermal structure of previously uninfected 5 month old brown trout.

From January to May 1978 0+ brown trout (group B) were reared in u.v.-sterilized lake water. Regular examinations were carried out for skin infections using fresh skin scrapes from sacrificed fish and on fish fixed at fortnightly intervals. No sign of ectoparasitic disease was seen during this period.

At the beginning of June the fish were transferred to untreated lake water and thereby exposed to Ichtyobodo. Samples of ten fish from one batch were removed at approximately monthly intervals after exposure until September, and regular examinations for skin parasites were continued. The methods used for fixation, staining and the estimation of epidermal cell densities were the same as those employed in Experiment 1.

Experiment 3

The aim of this investigation, carried out in 1977, was to examine the epidermal response to the removal of ectoparasitic infestation by formalin treatment in O+ brown trout suffering from costiasis. Fish from batches known have been infested with Ichtyobodo were sampled at fortnightly intervals from September to November. At each sampling time ten fish were removed from each of the following three ponds in which different therapeutic formalin treatments were applied.

Pond D: no treatment.

Pond E: single formalin treatment on day 0.

Pond F: single formalin treatment on day 0, followed by two further treatments at monthly intervals.

The fish in each sample were anaesthetized, fixed and skin samples from these older fish were taken from the shoulder area (see Fig. 2.1, Chapter 2). Mean goblet cell densities were estimated using the method described in Chapter 2.

Comparisons between the mean goblet cell densities of the fish under the three different treatments were made using a two-factor analysis of variance (Snedecor & Cochran, 1967). The analysis was carried out on untransformed counts following a F max test for homogeneity of variance. The factors were: treatments (three) versus sampling times (six). The acidophilic cell abundance in each skin sample was scored visually and given a rank in an order of increasing density from 1 to 5. Comparisons of acidophilic cell abundance between fish under the different treatments were carried out using the following non-parametric tests: the Kruskal-Wallis test for differences in location in ranked data grouped by single classification, the Mann-Whitney U-test for two samples of ranked observations and the STP a posteriori test for non-parametric multiple comparisons (Sokal & Rohlf, 1969). Regular checks for ectoparasitic infestations were made on fresh skin scrapes from sacrificed fish throughout the experiment.

Experiment 4

This investigation was designed to compare the spatial relationship between epidermal mucous cell abundance and the intensity of Ichtyobodo infestation on the skin of 0+ brown trout.

Fish were sampled at different time intervals after diagnosis of costiasis and data, collected from a total of twenty-three individuals sampled in 1977 and 1978, were

pooled from the groups outlined below. Each fish was anaesthetized, fixed and its skin removed and stained as in Experiments 1 and 2. Quadrats were positioned randomly on each skin sample and the numbers of mucous cells and Ichtyobodo parasites were counted in each of the following groups.

Group i: 1 month after infection; three fish sampled with thirty 0.0076 mm² quadrats per skin sample.

Group ii: 2 months after infection; ten fish sampled with fifteen 0.0814 mm² quadrats per skin sample.

Group iii: 4 months after infection; ten fish sampled with fifteen 0.0814 mm² quadrats per skin sample.

An additional four fish, sampled 1 month after diagnosis of costiasis, were examined in more detail. Counts of the number of goblet mucous cells and Ichtyobodo individuals were made in 0.01 mm² quadrats positioned at the intersections of a 1 mm or 0.5 mm grid over the skin samples. The results from these four fish are presented separately, and are also included in the pooled data.

4.3. Results

Experiment 1

The changes in epidermal goblet cell density of the three groups of brown trout reared under different conditions from January to May are shown in Fig. 4.1. Costiasis was diagnosed in the group A fish (reared in untreated lake water) in mid-

pooled from the groups outlined below. Each fish was anaesthetized, fixed and its skin removed and stained as in Experiments 1 and 2. Quadrats were positioned randomly on each skin sample and the numbers of mucous cells and Ichtyobodo parasites were counted in each of the following groups.

Group i: 1 month after infection; three fish sampled with thirty 0.0076 mm^2 quadrats per skin sample.

Group ii: 2 months after infection; ten fish sampled with fifteen 0.0814 mm^2 quadrats per skin sample.

Group iii: 4 months after infection; ten fish sampled with fifteen 0.0814 mm^2 quadrats per skin sample.

An additional four fish, sampled 1 month after diagnosis of costiasis, were examined in more detail. Counts of the number of goblet mucous cells and Ichtyobodo individuals were made in 0.01 mm^2 quadrats positioned at the intersections of a 1 mm or 0.5 mm grid over the skin samples. The results from these four fish are presented separately, and are also included in the pooled data.

4.3. Results

Experiment 1

The changes in epidermal goblet cell density of the three groups of brown trout reared under different conditions from January to May are shown in Fig. 4.1. Costiasis was diagnosed in the group A fish (reared in untreated lake water) in mid-

Figure 4.1. Changes in mean epidermal mucous cell densities in different batches of hatchery-reared 0+ brown trout, during the period January to May 1978, showing the effects of exposure to Ichtyobodo infestation. Mucous cell densities in the batches under different treatments are shown as: open circles for the batch exposed to infestation (group A); open squares for the batch kept disease-free in u.v.-sterilized water (group B); solid circles for the batch kept disease-free by formalin prophylaxis (group C). Vertical bars represent standard errors. Sample size = 10.

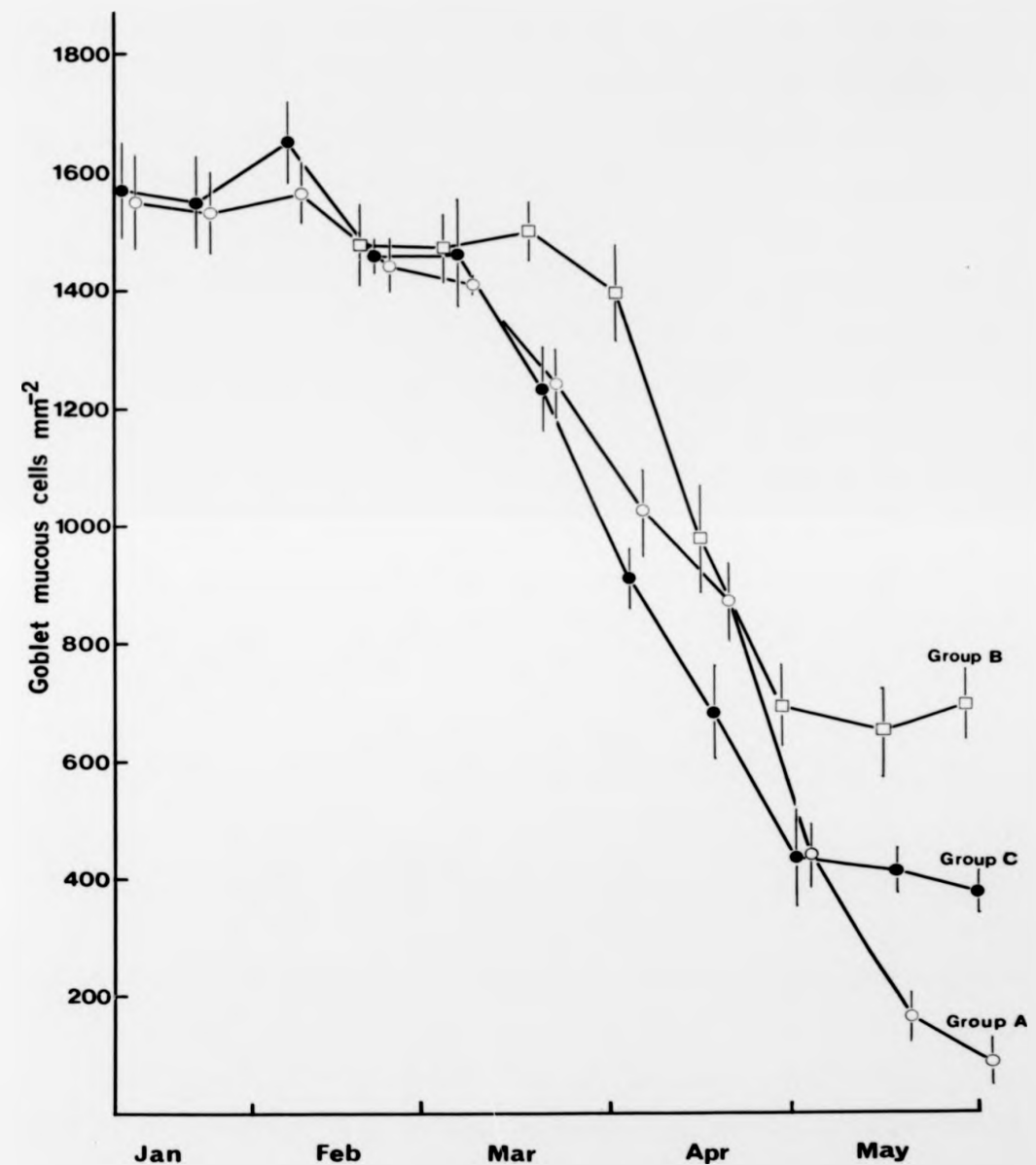


Figure 4.1.

April; no Ichtyobodo infestations were recorded on the group B fish (reared in u.v.-sterilized lake water) or on the group C fish (subjected to formalin prophylaxis). Mucous cell density was highest (c. 1500 mm⁻²) in the immediate post-hatching period, January and February, and was similar among all fish regardless of treatment. Over the next few weeks the abundance of mucous cells decreased in all cases, but the rate of decline and the density at the end of the experiment varied between treatments. The mucous cell density in the group B fish stabilized during May at c. 700 cells mm⁻². In the group A fish, suffering from costiasis, the mucous cell density was still decreasing during May and had declined to less than 100 cells mm⁻² by the end of the month. The rate of decline in mucous cell abundance dropped during May in the group C fish and by the end of the experimental period was somewhat intermediate between the other two groups at c. 400 cells mm⁻². Analysis of variance revealed that the overall effect of treatment on the observed differences in mucification was highly significant ($p < 0.001$), as was the overall effect of time ($p < 0.001$) which can clearly be seen in Fig. 4.1. There was also a significant treatment-time interaction ($p < 0.001$) due to the differences in skin structure between the fish under the different treatments becoming more pronounced through time. The two-factor analysis was broken down to localize these differences. It was found that the overall mucous cell density of the group B fish (in u.v.-sterilized lake water) was significantly different ($p < 0.01$)

to that in fish in the other two treatment groups. There was no overall difference in mucous cell density between group A fish (exposed to Ichtyobodo) and the group C fish (subjected to formalin prophylaxis), but there was a significant treatment-time interaction ($p < 0.001$) which was accounted for when the skin structure of these two groups was compared at each sampling time. In the last two samples in May there were significant differences ($p < 0.01$) in mucous cell density between the two groups.

Throughout the period of the experiment the density of acidophilic cells in the epidermis of fish in groups B and C was constantly less than ten cells mm^{-2} . Prior to the diagnosis of costiasis there was a similar low density of these cells in the group A fish. However, after the onset of Ichtyobodo infestation in mid-April, the abundance of acidophilic cells in the group A fish increased until, by the end of May, they had reached a density of thirty cells mm^{-2} , which was significantly higher ($p < 0.001$) than that of the other two groups at that stage. By that time the density of Ichtyobodo had reached a level of more than 3000 individuals mm^{-2} .

Similar trends in the variation of epidermal structure were observed in other batches of fish under the three treatments which were sampled at monthly intervals.

It had previously been found (see Chapter 2) that differences in epidermal structure could also occur between fish in different size classes within a single pond. However, in the

present case, tests using Spearman's formula for rank correlation showed that there was no correlation between fish size and mucous cell density within the batches under the different treatments at any sampling time.

Experiment 2

The overall effect on epidermal structure of exposing previously uninfected 5 month old brown trout to costiasis was a reduction in the density of mucous cells and an increase in the abundance of acidophilic cells (Fig. 4.2). Fish were reared in sterilized water until early June when they were exposed to Ichtyobodo infestation in untreated lake water. Costiasis was first diagnosed 4 weeks after exposure. Epidermal mucous cell density had not changed significantly 1 week after diagnosis but thereafter decreased rapidly over the next two monthly samples to c. 100 cells mm^{-2} by September. Conversely, the abundance of acidophilic cells increased after diagnosis of costiasis from an initial very low level, and reached a density of c. 350 cells mm^{-2} by September.

Experiment 3

Treatment of O+ brown trout suffering from costiasis with formalin, applied either as a single dose (pond E) or in three doses at monthly intervals (pond F), caused the removal of all parasites from the skin. In the fish under both treatments there was a subsequent increase in epidermal mucous

Figure 4.2. Changes in the mean densities of epidermal mucous cells and acidophilic cells in hatchery-reared brown trout exposed to *Ichtyobodo* infestation at the age of 5 months in 1978. Prior to infection with *Ichtyobodo* the fish were reared in u.v.-sterilized water. Vertical bars represent 95% confidence limits. Sample size = 10.

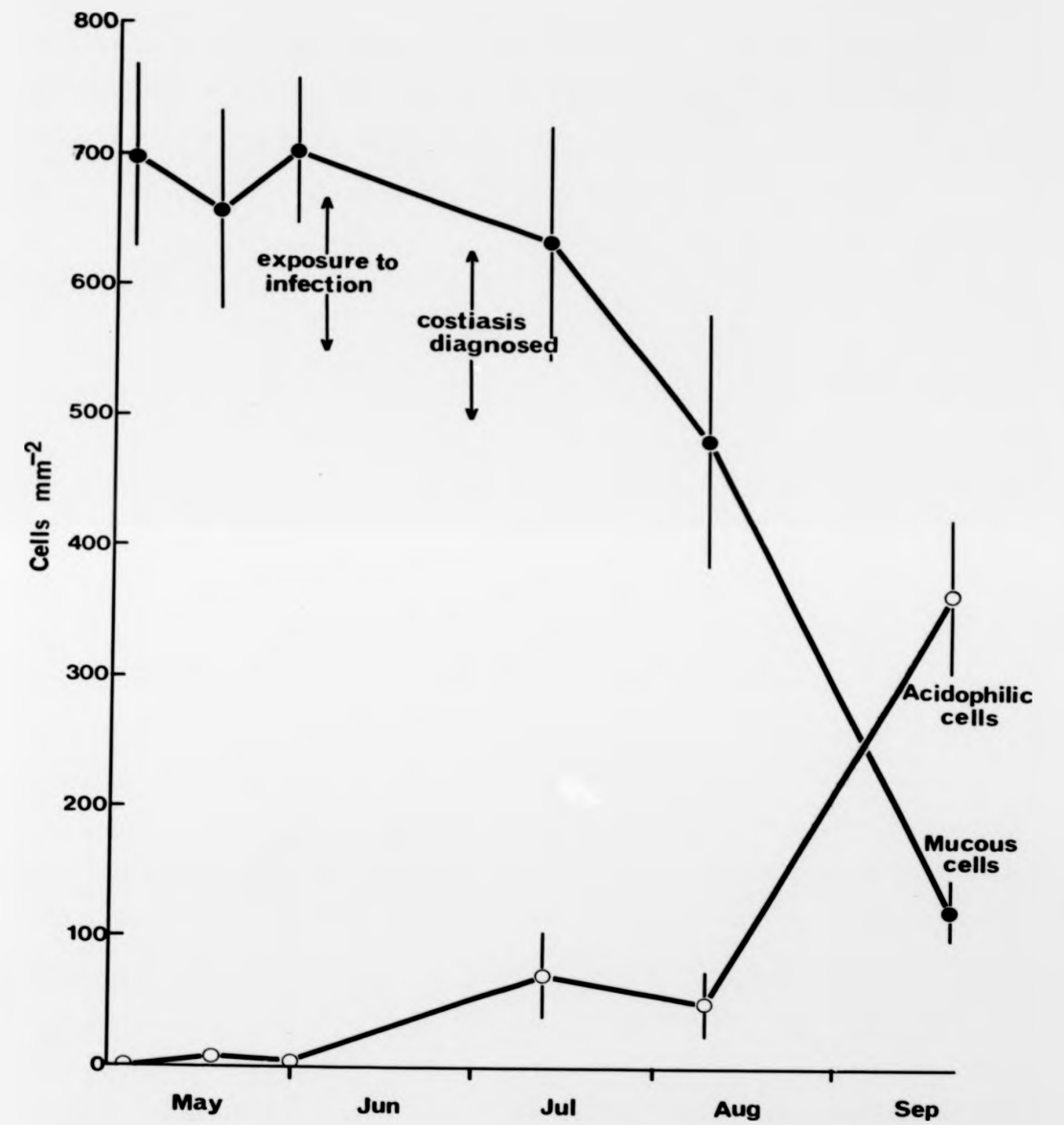


Figure 4.2.

cell density (Fig. 4.3) and a decrease in the abundance of acidophilic cells (Table 4.1) in comparison to fish maintained in untreated lake water (pond D). The observed differences in mucous cell densities were shown to be significantly different ($p < 0.01$) in terms of the overall effects of treatment by analysis of variance, and there was also a significant treatment-time interaction ($p < 0.001$). When the analysis was subdivided, the goblet cell density of infested fish in pond D was found to be significantly different to that of the formalin-treated fish in both ponds E and F ($p < 0.01$). However, there were no significant differences in mucification between fish in ponds E and F. No Ichtyobodo parasites were found on fish in these two ponds during the course of the investigation (although the ciliate Scyphidia spp. was seen in small numbers on fish in pond E from mid-October onwards), whereas the trout in pond D continued to be affected by costiasis.

There were no significant differences in acidophilic cell density between the fish in the different ponds at the beginning of the experiment (Kruskal-Wallis test). The density of these cells remained unchanged in the infected fish in pond D (Mann-Whitney U-test). However, in the fish in both of the formalin-treated ponds, the abundance of acidophilic cells decreased during the experiment and by November both batches had a significantly lower density in the epidermis than in the brown trout which were still infested with Ichtyobodo (STP test).

Figure 4.3. Changes in mean epidermal mucous cell densities in different batches of hatchery-reared O+ brown trout, during the period September to November 1977, showing the effects of therapeutic formalin treatments on fish infested with *Ichtyobodo*. Mucous cell densities in the batches under different treatments are shown as: solid circles for the untreated batch (pond D); open squares for the batch given a single formalin treatment (pond E); open circles for the batch given three formalin treatments at monthly intervals (pond F). Ft indicates times at which formalin treatment was administered. Vertical bars represent standard errors. Sample size = 10.

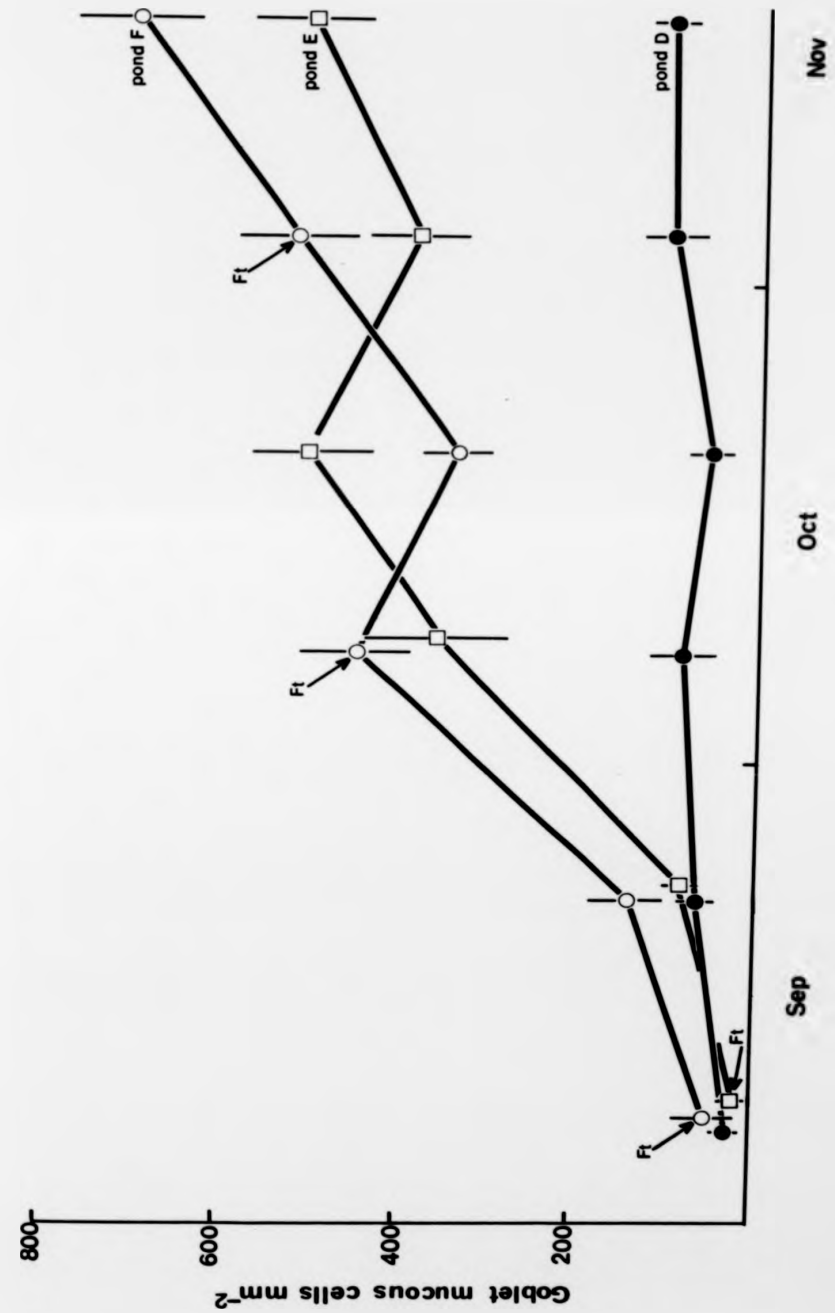


Figure 4.3.

Experiment 4

The results of the differential counts of goblet cells and Ichtyobodo parasites in the regularly-positioned quadrats over the epidermal surface of four individual brown trout are shown in Fig. 4.4. In each case a negative association can be seen, i.e. the quadrats with the highest goblet cell counts contained the lowest number of parasites and vice versa. Fig. 4.5 shows the pooled data from twenty-seven fish; the same negative relationship emerged from the results of quadrats sampled on the skin of fish at different intervals after diagnosis of costiasis.

4.4. Discussion

Significant changes in the cellular composition at the epidermal surface of hatchery-reared brown trout have been shown to result from infestations of an ectoparasitic protozoan. In this experimental investigation, particular attention has been given to the pathogenic effects of Ichtyobodo infestation on the mucous producing capacity of the epidermis during the early stages of growth in juvenile brown trout.

The outbreak of costiasis occurred at the time when the initial phase of decline in superficial mucous cell density had taken place (see Chapter 3; Blackstock & Pickering, 1982). Thereafter this infestation caused a further reduction in mucous cell abundance so that by late May there were

Figure 4.4. Histograms showing the relationship between epidermal mucous cell density and intensity of Ichtyobodo infestation in different parts of the skin sampled from four individual O+ brown trout 1 month after diagnosis of costiasis. The mean mucous cell densities are shown for quadrats in which different numbers of Ichtyobodo parasites were present. Vertical bars represent 95% confidence limits.

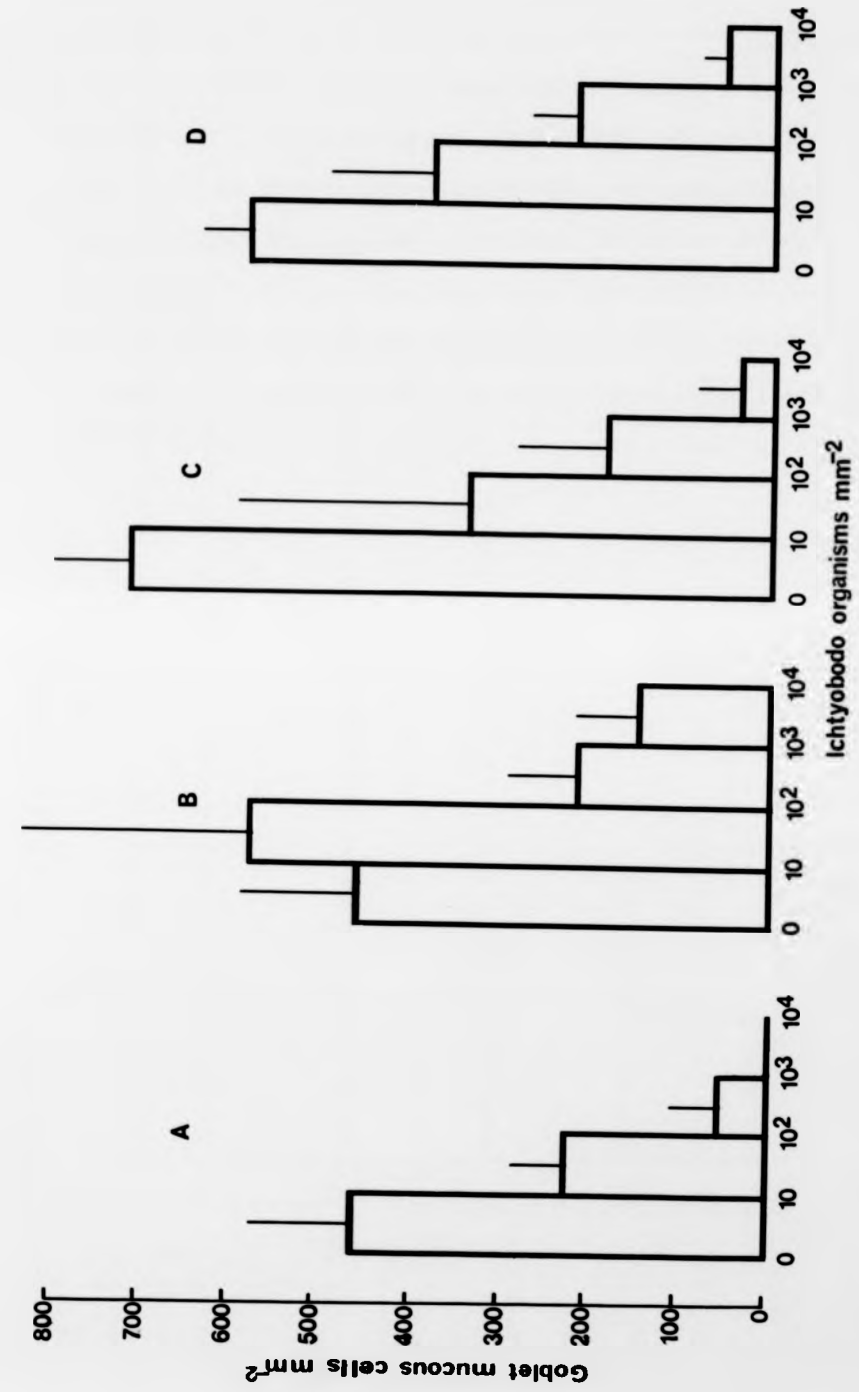


Figure 4.4.

Figure 4.5. Histogram showing the relationship between epidermal mucous cell density and intensity of Ichtyobodo infestation in different parts of the skin of twenty-seven 0+ brown trout at 1-4 months after diagnosis of costiasis. Quadrat data from all fish have been combined; the mean mucous cell densities are shown for quadrats in which different numbers of Ichtyobodo parasites were present. Vertical bars represent 95% confidence limits.

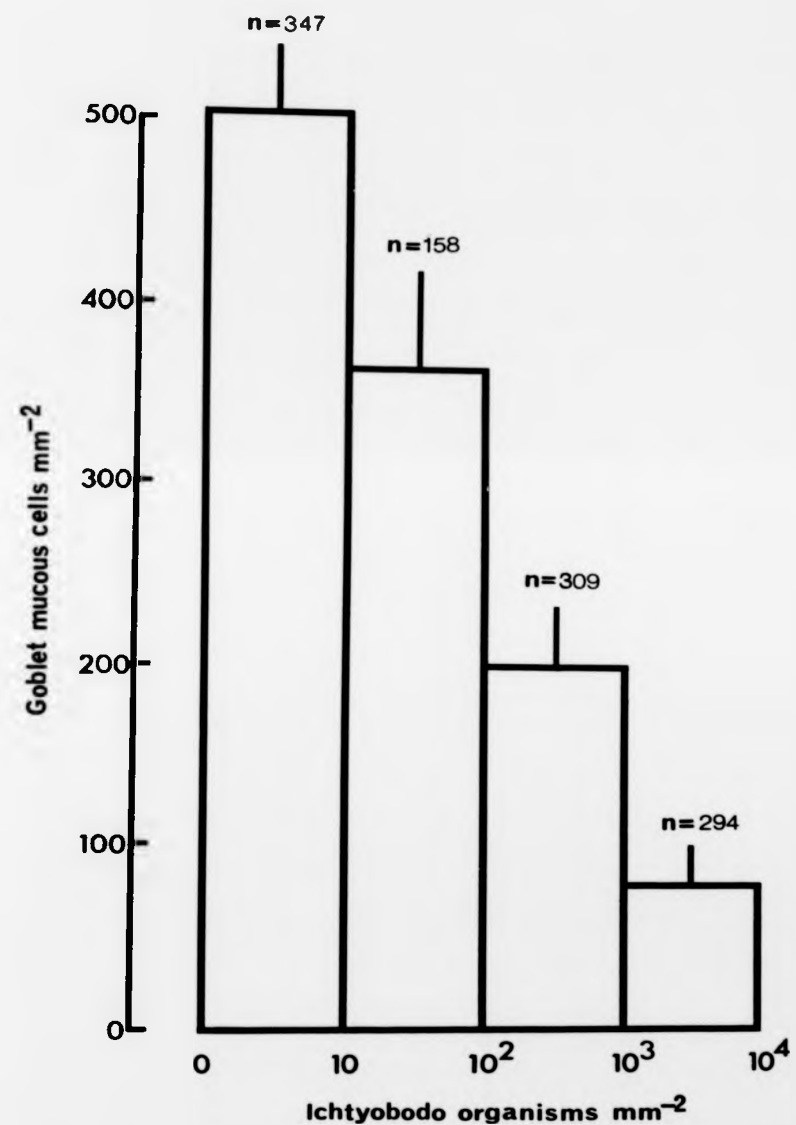


Figure 4.5.

considerably fewer mucous cells per unit area in the epidermis of fish suffering from costiasis than in those kept disease-free in u.v.-sterilized water or by formalin prophylaxis. Interestingly, by that stage there were also lower mucous cell densities in fish subjected to regular formalin treatment than in those reared in sterile conditions. This result will be given further consideration in the next chapter.

Coincident with the reduction in mucous cell abundance in the diseased fish, there was an increase in the density of acidophilic cells which did not occur in the uninfested fish. This observation is consistent with the suggestion mentioned in Bullock & Roberts (1975) that eosinophilic cells in salmonid epidermis occur most frequently under pathological conditions.

There are frequent reports that first-feeding fry are particularly susceptible to costiasis (e.g. Robertson, 1979), and the findings in Experiment 1 have provided a detailed, quantitative description of the epidermal response to the early stages of Ichtyobodo infestation in young brown trout. Furthermore, it has been shown that previously uninfected 5 month old cultured brown trout are still vulnerable to the disease. In Experiment 2, fish reared in sterile water up to that age became infested after 4 weeks of exposure to the parasite in untreated lake water. The subsequent alterations in skin structure were very similar to those observed in the younger diseased fish: a reduction in superficial goblet cell

density was followed by an increase in abundance of acidophilic cells.

When formalin was used to treat an existing infestation in brown trout at 7 months of age, rather than as a preventative measure, in Experiment 3, Ichtyobodo was completely eradicated by a single treatment. Epidermal mucification then increased progressively and there was a decline in acidophilic cell abundance in comparison with untreated fish suffering from chronic costiasis. Therapeutic administration of formalin in fact completely reversed the effects of the ectoparasite on epidermal structure.

Evidence for costiasis causing an increased depletion in mucous cell density after the alevin-fry transition was further corroborated by the results of the investigation of the spatial relationship between the intensity of Ichtyobodo infestation and the abundance of mucous cells over the skin surface, in Experiment 4. There was a clear negative association between Ichtyobodo abundance and the number of goblet mucous cells within quadrats sampled over the integuments of individual brown trout; this negative relationship was reaffirmed by the combined results of quadrat samples from fish in which the disease had progressed for different lengths of time.

The reduction in mucous cell production in infested brown trout, and the negative spatial correlation between Ichtyobodo and mucous cells in the epidermal surface, would appear to be at variance with other descriptions of the

clinical symptoms of the disease. An excess or increased production of mucus has been invoked to explain the characteristic greyish-white film which develops over the body of young fish heavily infested with Ichtyobodo (e.g. Rogers & Gaines, 1975; Becker, 1977). According to Pickering (1974), the rate of mucous production in teleost epidermis is dependent on at least two variables: the concentration of mucous cells within the epidermis and the turnover rate of these cells. There is also evidence that surface Malpighian cells are capable of secreting a thin layer of mucus, in at least some teleosts (e.g. Mittal, Whitear & Agarwal, 1980). It would seem highly improbable that the symptomatic greyish coat associated with costiasis is in fact due to a thicker mucous layer resulting from increased goblet cell production, at least in juvenile brown trout. The turnover period of teleost epidermis is relatively long compared to mammals and is known to be in the order of several days, e.g. in excess of 4.5 days in plaice Pleuronectes platessa (Bullock, Marks & Roberts, 1978), c. 11 days in the stickleback Gasterosteus aculeatus L. (Lester & Adams, 1974) and about 1 week in brown trout (Pickering, 1976). In The Ferry House hatchery in 1978, fish were sampled at fortnightly intervals and any increase in superficial goblet cell abundance would have to have been extremely short-lived to remain undetected, especially as it is unlikely that the onset of Ichtyobodo infestation occurred in complete synchrony among the fish in the fry troughs. Additionally, it has been previously shown (Chapter 2) that

goblet mucous cells were absent from all layers of the epidermis at a later stage of infestation. However, hypertrophy of and/or hypersecretion from existing mucous cells during the initial phase of infection cannot be discounted. Robertson, Roberts & Bullock (1981) have recently speculated that fish may respond to Ichtyobodo infestation by an exhaustion of mucus from the goblet cells. The unequivocal reduction in mucous cell density associated with Ichtyobodo infestation reported here is not necessarily inconsistent with this suggestion. In the next chapter the results of a complementary histological investigation of the sequential pathology of costiasis will be presented.

Another interesting feature of the present investigation concerns the use of formalin to treat or prevent costiasis. The results indicate that comparatively low doses can be successfully used for prophylaxis in young brown trout, and it was further found that a single treatment could cure fish suffering from chronic infestations of Ichtyobodo. In the next chapter, the results of an extended investigation of formalin prophylaxis will be discussed with particular reference to its irritant properties and also possible applications for fish farm management.

Chapter 5

The Sequential Pathology of Costiasis in O+ Brown Trout and the Effects of Long-Term Formalin Prophylaxis on Epidermal Structure

5.1. Introduction

Infestations of the ectoparasite Ichtyobodo necator have been widely reported in the stocks of freshwater fish farms, and can have a significant impact on the development of cultured fish, particularly during the early stages of growth. Costiasis, the condition caused by Ichtyobodo infestation, was first recorded in France by Henneguy (1883; 1884) in farmed trout alevins which had been decimated by this protozoan skin parasite. At the beginning of this century, Léger (1909) considered that costiasis represented the greatest threat to the rearing of indigenous brown trout Salmo trutta, rainbow trout S. gairdneri and also Atlantic salmon S. salar, the most valuable species from an economic standpoint. More recently, Becker (1977) noted that in the Northern Hemisphere outbreaks of the disease can occur wherever fish are cultured, where high host density encourages direct transmission and rapid development of ectoparasitic infestations. Besides salmonids, Ichtyobodo is known to infest a wide variety of freshwater fish species including swordtails Xiphophorus helleri (Günther), platyfish X.

maculatus (Heckel), guppies Poecilia reticulatus Peters, and African 'mouthbreeders' Sarotherodon melanotheron Rüppel (Tavolga & Nigrelli, 1947) and carp Cyprinus carpio L. (Becker, 1977). It is also known to parasitize the larvae of amphibians (Vickerman, 1976) as well as fish.

In terms of fish farm management, the disease takes on further significance in that salmonid alevins in good condition have been shown to be equally susceptible to infestation as those in poor condition (Robertson, 1979). There have also been several recent reports of Ichtyobodo infestation in sea water, on farmed Atlantic salmon smolts (Ellis & Wootten, (1978), wild plaice Pleuronectes platessa (Bullock & Robertson, 1982) and captive winter flounder Pseudopleuronectes americanus (Walbaum) (Cone & Wiles, 1984).

In view of the economic implications of outbreaks of costiasis, it is surprising that only few experimental studies concerning the pathogenic effects of the parasite on its host species have been reported in the literature. Most of the published information on Ichtyobodo is related to its life cycle, ultrastructure and taxonomic status (see Chapter 4). For almost a century after the first recorded incidence of costiasis, there was no detailed description of the pathology of this disease. Robertson, Roberts & Bullock (1981), however, have recently documented the pathogenesis of Ichtyobodo infestation in the epidermis of experimentally infected farmed salmon alevins over a period of 14 days. But prior to the commencement of the present investigation, there

was still no account of the pathology of costiasis in wild salmonids and only a brief description of its effects in naturally infected farmed Atlantic salmon smolts in sea water (Ellis & Wootten, 1978).

It has previously been shown (in Chapter 4) that one of the principal consequences of Ichtyobodo infestation in brown trout after the alevin-fry transition is a further marked reduction in the abundance of epidermal mucous cells. A major objective of the present investigation was to describe the histopathology of the annual progress of natural outbreaks of the disease from first diagnosis, through the acute and chronic stages, and to compare the epidermal responses in hatchery-reared O+ fish with those in a wild brown trout population in which infestations of this parasite were known to occur. In order to further clarify the pathological development of costiasis, a combination of methods was used, involving additional histological techniques and scanning electron microscopy as well as estimations of the relative abundance of mucous cells, acidophilic cells and Ichtyobodo individuals in the surface of sheets of whole integument. Skin samples for histological investigation were taken from an area adjacent to the dorsal fin. This is the part of the epidermis where Ichtyobodo infestations have most frequently been noted (e.g. Fish, 1940a; Tavolga & Nigrelli, 1947; Grassé, 1952). Robertson, Roberts & Bullock (1981) also found it to be a focus of infestation and similar observations were obtained from routine post mortem examinations at The Ferry

House.

A further aim of this work was to establish the effects, if any, of long-term formalin prophylaxis on the epidermal structure of O+ brown trout, and to compare these with the pathogenic effects of ectoparasitic infestation. The use of formalin to control costiasis was first recommended by Léger (1909). It was later tested against several other disinfectants by Fish (1940b) and found to be the most efficacious agent; he advised monthly or bi-monthly treatment at 250 ppm for 1 hour. Smith & Piper (1972), however, have shown that a single treatment of formalin (at 167 or 250 ppm for 1 hour) can result in swelling and sometimes complete desquamation of the epithelium of the gills of rainbow trout. Furthermore, it has been found that significant differences in epidermal structure can develop between brown trout alevins subjected to formalin prophylaxis at very low doses (33 ppm for 15 minutes per week) and alevins reared in sterilized water (as reported in Chapter 4). The results of an extended investigation will also be considered in relation to the use of formalin in commercial fish farm husbandry. The relative mortality rates of cultured brown trout infected with costiasis as first-feeders or at 5 months of age and those kept ectoparasite-free throughout the year by means of formalin prophylaxis under controlled conditions will also be presented.

5.2. Materials & Methods

Cultured fish: rearing methods

In 1978 batches of brown trout were reared under controlled conditions in The Ferry House hatchery. Full details of the culture conditions of three groups of batches in which epidermal structure and mortality were monitored in this investigation are given in Chapter 4.

Group A was maintained in untreated lake water and thereby exposed to Ichtyobodo infestation. Post-hatching, twelve batches of alevins were transferred to outdoor troughs at an initial stocking density of 700 fish per trough. At 5 months of age fry were moved to a larger rearing pond.

Group B was reared in u.v.-sterilized water for the first 5 months of life; four batches of alevins were kept in indoor cages at an initial stocking density of 600 fish per cage. Thereafter 1000 fry were transferred to a large outdoor pond supplied with untreated lake water.

Group C was subjected to regular formalin prophylaxis consisting of a weekly treatment of 33 ppm for 15 minutes. Eight batches of alevins were reared in troughs until June when fish were removed to a rearing pond at the same stocking density as groups A and B.

Histological investigations were carried out on O+ brown trout reared at The Ferry House during 1977. Fish were maintained in untreated lake-water under the same conditions as group A in 1978; further details are given in Chapter 2. Skin

samples prepared for scanning electron microscopy were taken from Ichtyobodo-infested O+ brown trout reared in 1980.

Environmental parameters, namely water temperature, pH, alkalinity and the concentrations of dissolved oxygen, free carbon dioxide and total ammonia-nitrogen, were monitored regularly throughout 1977-1978. In addition, the body weight and fork length of each fish sampled were recorded.

Wild fish: study sites and sampling procedures

O+ brown trout were sampled in Black Brows Beck where Ichtyobodo infestations were known to occur, and Scandale Beck where costiasis had never been recorded in the fish population. Both streams are situated in north-west England, (for further details see Table 2.2, Chapter 2).

Yolk-sac stages were obtained from the Black Brows Beck population by kick samples in 1979 and free-swimming O+ fish were collected by electro-fishing in 1977, 1978 and 1979. The population was sampled on several occasions in 1977 and monthly in 1978 and 1979. Costiasis was diagnosed in each year. The Scandale beck population was sampled monthly after emergence from the redd in 1977.

At each sampling time water temperature, pH, alkalinity and the concentrations of dissolved oxygen, free carbon dioxide and total ammonia-nitrogen, were measured in both streams. The body weight and fork length of all fish sampled were also recorded.

Ectoparasite and superficial cell counting methods

At The Ferry House in 1978, samples of ten fish were removed from one batch in each of the three groups immediately post-hatching and thereafter at fortnightly intervals. Monthly samples of ten 0+ brown trout were also obtained for cell and parasite counts from the Black Brows Beck population during May to September in 1978 and March to July in 1979.

At each sampling time all fish were anaesthetized, fixed and the skin was removed and stained using the procedures outlined in Chapter 3 and in Experiment 1, Chapter 4. The numbers of superficial mucous cells, acidophilic cells and Ichtyobodo parasites were counted in each of thirty randomly-positioned 0.0076 mm^{-2} quadrats on the integument preparations from each fish, (some of the results from the first 5 months in the hatchery-reared fish have been presented in Chapter 4). Examinations for the presence of ectoparasitic infestations were regularly undertaken on sampled fish and on additional fish sacrificed from all groups.

Mortality data from the hatchery-reared fish

Throughout the course of 1978 in The Ferry House, dead fish were removed daily from each batch of brown trout reared in the three treatment groups. Post mortem examinations were carried out and the weekly percentage mortality was computed for each group from all the alevin-fry troughs (twelve in group A, four in group B and eight in group C) and the fry-

fingerling ponds (one in each group).

Histology

Samples of ten brown trout reared in untreated lake water at The Ferry House were removed 2 days after hatching and then at monthly intervals during 1977. An additional sample of twenty fish was taken at the time when costiasis was diagnosed. For comparative purposes, histological investigations were also carried out on samples of brown trout from wild populations in Black Brows Beck (Ichtyobodo present) and Scandale Beck (Ichtyobodo absent) which were obtained in 1977. The fish were anaesthetized, fixed and embedded in paraffin wax as described in Chapter 2. Sections (5 or 6 μ m) were cut from an area adjacent to the dorsal fin and then stained using the following procedures.

- i. Ehrlich's haematoxylin and 0.5% aqueous eosin.
- ii. Heidenhain's haematoxylin and 0.5% aqueous eosin.
- iii. Alcian blue (pH 2.5), followed by i.
- iv. Alcian blue (pH 2.5), followed by ii.
- v. Alcian blue (pH 2.5), followed by Heidenhain's haematoxylin and Mallory's aniline blue/orange G counterstain.

After dehydration and clearing the sections were mounted in Canada balsam.

Scanning electron microscopy (SEM)

In May 1980, Ichtyobodo-infested integument of O+ brown trout reared in untreated lake water at The Ferry House, was pre-

pared for SEM examination. The fish were anaesthetized and skin samples were taken from the mid-flank region. Pieces of excised skin, 0.5 X 1.0 cm, attached to the musculature were fixed in 3.5% glutaraldehyde in 0.1M sodium cacodylate buffer (pH 7.2) for 90 minutes. Following primary fixation, the tissue was rinsed three times in 15.2% sucrose in 0.1M sodium cacodylate buffer, and post-fixed in 2.0% osmium tetroxide in sucrose buffer for 30 minutes, followed by three further rinses in sucrose buffer. These initial stages were carried out in slow rotation to aid removal of mucus. The post-fixed tissue was washed in sucrose buffer for 30 minutes and then dehydrated through an acetone series to 100%. The tissue pieces were critical-point dried from liquid CO_2 , and then sputter-coated with gold:palladium. The coated material was examined in a JEOL 25S scanning electron microscope.

5.3. Results

Temporal variation in superficial cell density and ectoparasitic infestations

In May 1978, costiasis in the hatchery-reared brown trout in untreated lake water (group A) had reached a severe condition (Fig. 5.1). By that stage there had been a marked decline in the density of mucous cells which then almost completely disappeared from the epidermal surface over the next 4 weeks. After a delay of 4-6 weeks following the initial diagnosis of costiasis in mid-April, the abundance of acidophilic cells

Figure 5.1. Seasonal changes in the densities of mucous cells and acidophilic cells in the epidermis of hatchery-reared O+ brown trout exposed to *Ichtyobodo* infestation (group A) during 1978. Changes in abundance of ectoparasites in skin samples, the weekly % mortalities of fish exposed to infestation and the variation in water temperature are also shown.

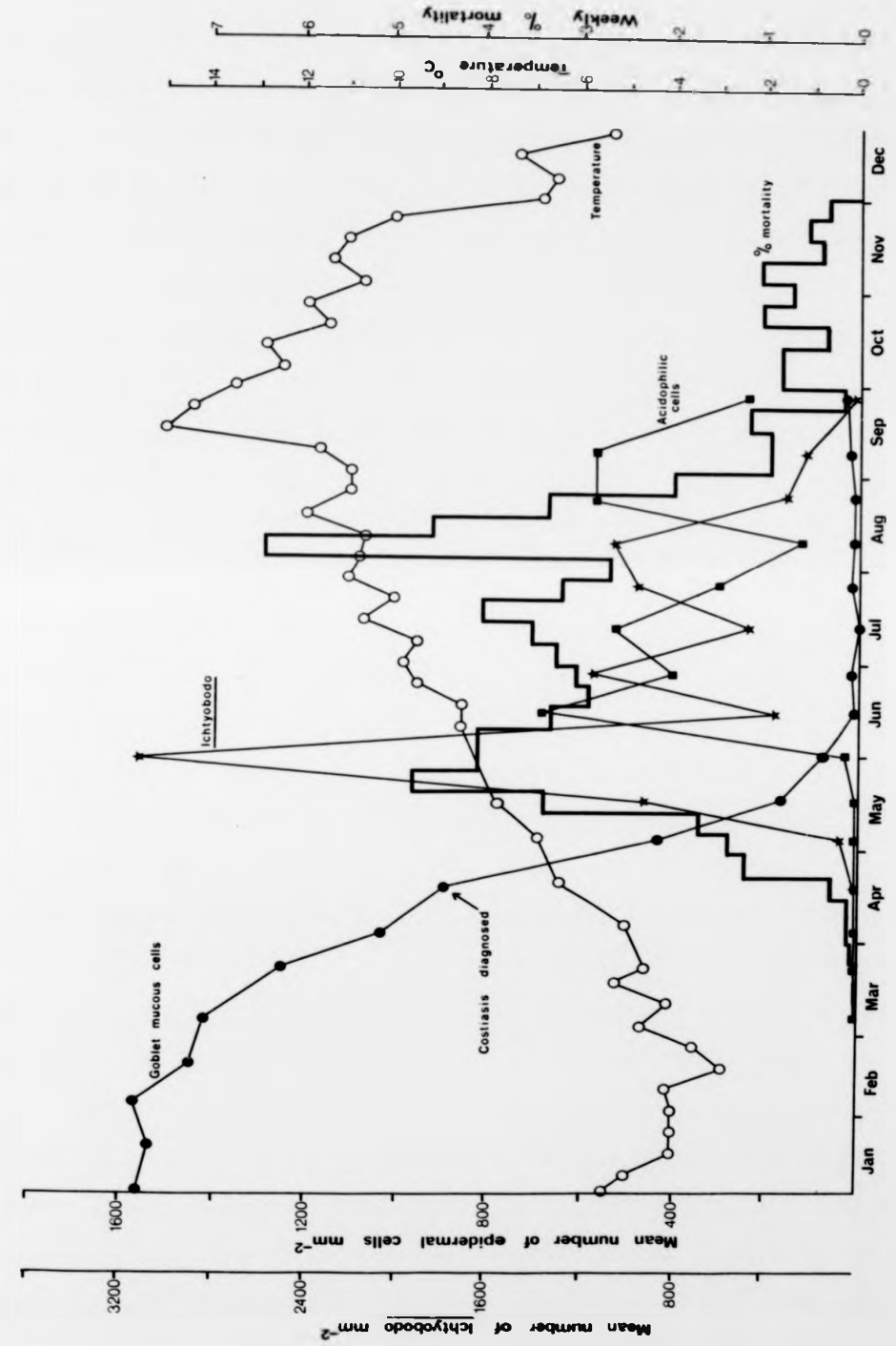


Figure 5.1.

rose considerably shortly after a massive increase in Ichtyobodo infestation. As the disease reached a chronic stage, superficial mucous cells disappeared and fluctuations in the density of Ichtyobodo parasites on the skin surface were followed by fluctuations in the abundance of acidophilic cells. Goblet mucous cells only began to reappear in late August when the intensity of Ichtyobodo infestation had declined; by early December the mucous cell density was c. 200 cells mm^{-2} . By the end of September, there was little sign of the disease in the skin samples and the density of acidophilic cells had also declined by that time, and continued to do so through to December. There had been negligible mortality in the group A fish prior to April, but with the onset of Ichtyobodo infestation the weekly mortality soon increased to c. 3.5-4.5% during the acute and chronic phases of the disease. It is probable, however, that the high mortality shown for August in Fig. 5.1 was exaggerated by the enforced change in diet at that time (see Chapter 4).

A similar but less pronounced pattern of structural variation occurred in the Black Brows Beck brown trout population during 1978 and 1979 (Fig. 5.2). Comparatively low levels of Ichtyobodo infestation were first observed in fish sampled at the end of May. Although superficial mucous cells did not disappear from the epidermis, their density declined to a lower level (<300 cells mm^{-2}) after the onset of costiasis in comparison to that in the wild fish samples in which Ichtyobodo was never recorded during 1976-9 and where the

Figure 5.2. Changes in the densities of mucous cells and acidophilic cells in the epidermis of O+ brown trout sampled from a wild population at Black Brows Beck during 1978 and 1979. Changes in abundance of Ichtyobodo parasites on skin samples and the variation in water temperature are also shown. Data from both years have been combined for the period May-September; data shown for March and April were recorded in 1979.

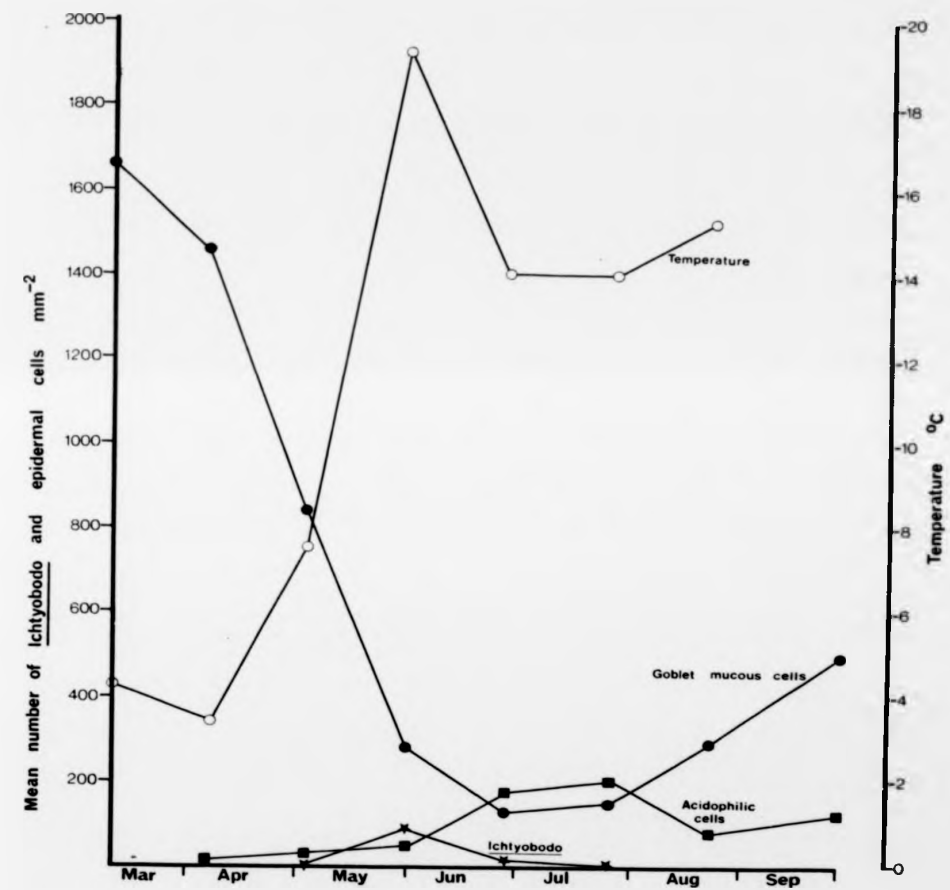


Figure 5.2.

mean mucous cell density never dropped below 800 cells mm^{-2} , (see Fig. 3.3, Chapter 3). An acidophilic cell response was also initiated in the wild population even though the effects of the disease appeared to be less severe. The full impact and intensity of Ichtyobodo infestation in the Black Brows Beck population would be difficult to assess without a far more intensive and concentrated sampling regime. In the present investigation severely infested individuals, whose probability of surviving the effects of competition as well as predation would have been reduced, were unlikely to have been sampled.

It has already been shown (in the results of Experiment 2, Chapter 4) that the previously uninfested 5 month old brown trout (group B in The Ferry House) were still susceptible to costiasis. However, the weekly mortality in this group was considerably lower (Fig. 5.3.) than in group A which had been exposed to Ichtyobodo infestation at an earlier age. After onset of the disease, epidermal mucification again declined and was also accompanied by an increase in abundance of acidophilic cells. By mid-September, the mean acidophilic cell density was greater than 400 cells mm^{-2} (similar to the density in mid-August in the group A fish in which ectoparasitic infestations had appeared 10 weeks earlier), and by this stage the weekly mortality had dropped to less than 1%.

No Ichtyobodo infestations were recorded in the hatchery-reared group C fish subjected to prophylaxis with very low, weekly doses of formalin. The superficial mucous cell

mean mucous cell density never dropped below 800 cells mm^{-2} , (see Fig. 3.3, Chapter 3). An acidophilic cell response was also initiated in the wild population even though the effects of the disease appeared to be less severe. The full impact and intensity of Ichtyobodo infestation in the Black Brows Beck population would be difficult to assess without a far more intensive and concentrated sampling regime. In the present investigation severely infested individuals, whose probability of surviving the effects of competition as well as predation would have been reduced, were unlikely to have been sampled.

It has already been shown (in the results of Experiment 2, Chapter 4) that the previously uninfested 5 month old brown trout (group B in The Ferry House) were still susceptible to costiasis. However, the weekly mortality in this group was considerably lower (Fig. 5.3.) than in group A which had been exposed to Ichtyobodo infestation at an earlier age. After onset of the disease, epidermal mucification again declined and was also accompanied by an increase in abundance of acidophilic cells. By mid-September, the mean acidophilic cell density was greater than 400 cells mm^{-2} (similar to the density in mid-August in the group A fish in which ectoparasitic infestations had appeared 10 weeks earlier), and by this stage the weekly mortality had dropped to less than 1%.

No Ichtyobodo infestations were recorded in the hatchery-reared group C fish subjected to prophylaxis with very low, weekly doses of formalin. The superficial mucous cell

Figure 5.3. Seasonal changes in the densities of mucous cells and acidophilic cells in the epidermis of 0+ brown trout reared in sterilized water until May and then exposed to *Ichtyobodo* infestation (Group B) during 1978. The time at which costiasis was diagnosed is indicated. The weekly % mortalities of fish in this group and the variation in water temperature are also shown.

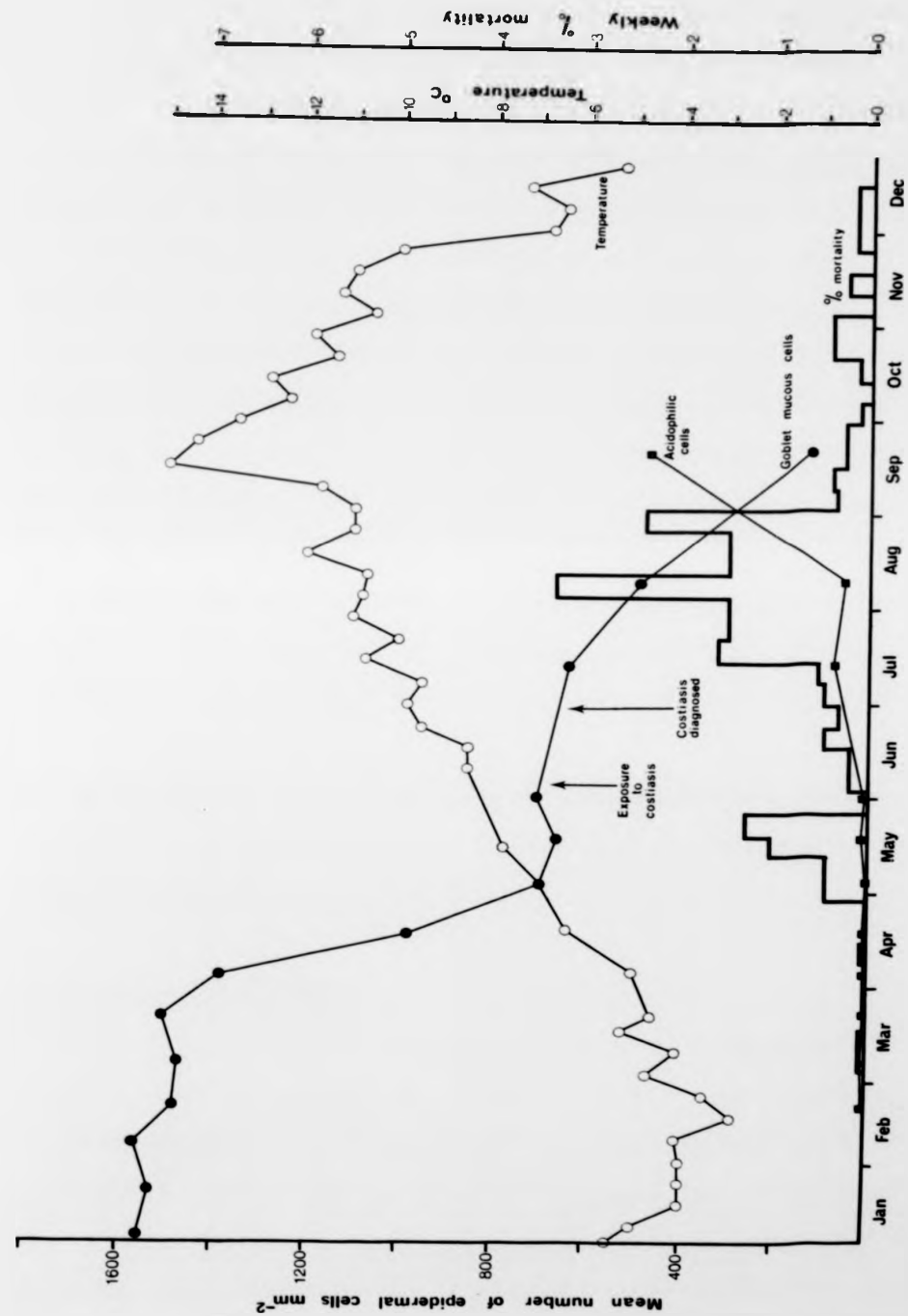


Figure 5.3.

density, which by late May had been found to be significantly lower than in brown trout reared in sterilized water (see Experiment 1, Chapter 4), declined to a very low level by mid-July (Fig. 5.4). By this time there had been a considerable increase in the abundance of acidophilic cells which was later followed by the reappearance of higher numbers of mucous cells in the quadrat samples. It is not improbable that the subsequent decline in mucification and increase in mortality during August were at least partly related to the stress imposed by the change in diet at the beginning of that month. It is noteworthy that following this period there was another peak in acidophilic cell density in the epidermis after which the abundance of mucous cells continued to increase. By the end of the year the group C fish had grown to a notably larger size than those reared in untreated lake water.

The temperature range over which costiasis was encountered in the hatchery-reared brown trout and in the Black Brows Beck population was 5.3-19.3°C.

Post mortem examinations

In both 1977 and 1978, costiasis was first diagnosed in The Ferry House hatchery in mid-April. In both years Ichtyobodo infestations were first observed on the dorsal part of the body of brown trout. Shortly after diagnosis in 1978, eight of the poorest-looking fish were sacrificed; seven of these individuals were found to be suffering from costiasis. During

Figure 5.4. Seasonal changes in the densities of mucous cells and acidophilic cells in the epidermis of O+ brown trout subjected to regular formalin treatment (group C) during 1978. The weekly % mortalities of fish in this group and the variation in water temperature are also shown.

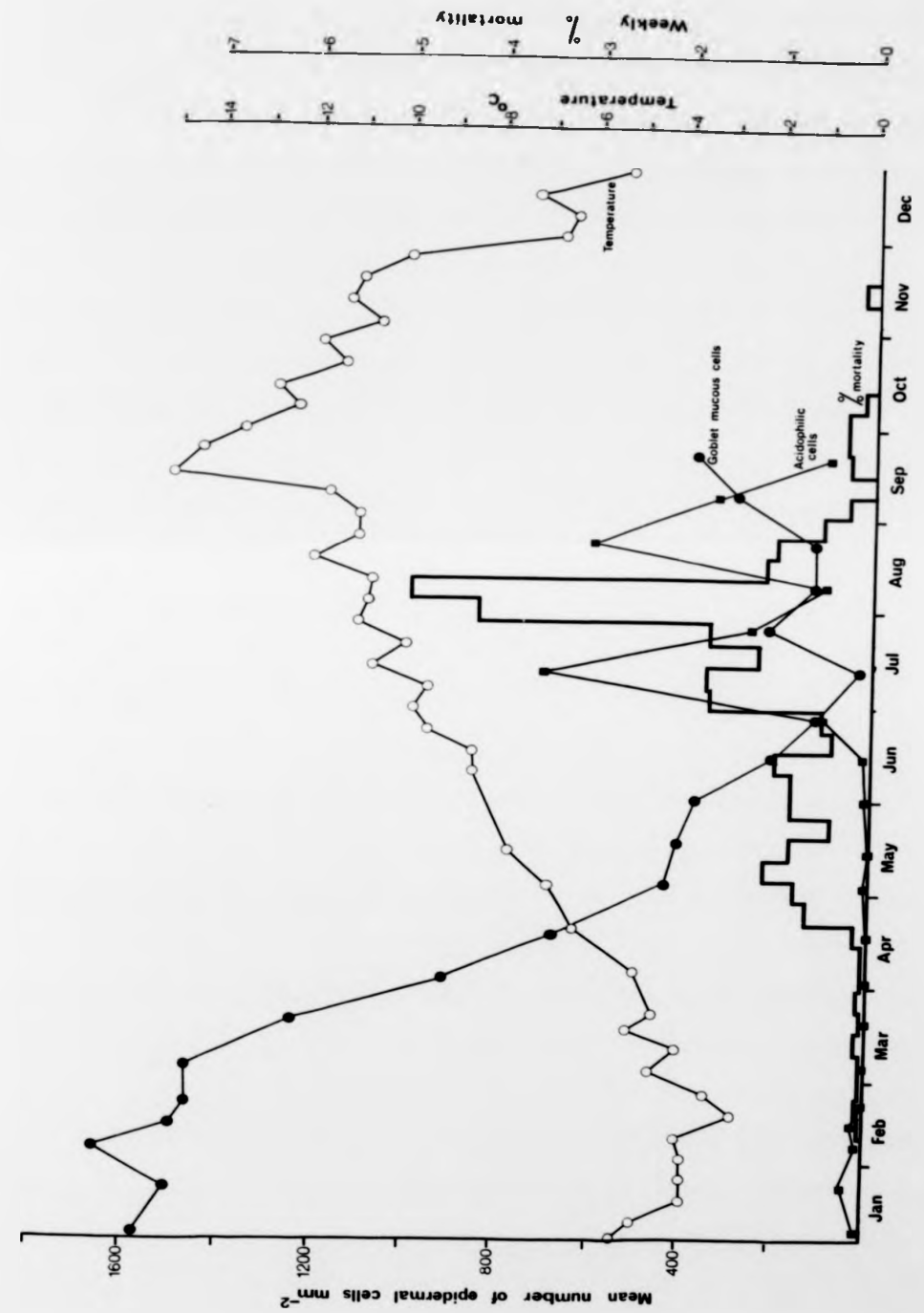


Figure 5.4.

the quadrat sampling programme in the group A batch, only two fish were infested in mid-April but by the next sampling time at the beginning of May infestations were recorded in quadrats from all ten individuals. Heavy Ichtyobodo infestations were never observed on the gills of the hatchery-reared O+ brown trout during the period of this investigation. In addition, no other ectoparasite species were encountered on the fish in the experimental troughs, (although Chilodonella sp. appeared in other troughs with a much lower water flow rate in the hatchery). After the fish had been transferred to the rearing ponds in 1978, the ciliates Apiosoma sp. and Scyphydia spp. were occasionally observed from September onwards on trout in groups A and B.

Histopathology

The initial response to Ichtyobodo infestation observed in 1977 at The Ferry House in O+ brown trout was an explosive secretion of mucus from the epidermal goblet cells (Fig. 5.5.a). This feature marks a clear contrast with the position in recently-hatched, uninfested alevins (see Fig. 3.3.a, Chapter 3) where, although there was a copious production of mucus, the goblet cells retained their integrity and characteristic narrow-necked goblet shape. The sudden emission of mucus associated with the onset of infestation caused an apparent exhaustion of many of the goblet cells resulting in a reduction of the mucus-producing capacity of the epidermis. While some alevins were able to survive continued infesta-

Figure 5.5. Transverse sections through the skin of O+ cultured brown trout infested with Ichtyobodo. (a) Explosive secretion of mucus from epidermal goblet cells at a very early stage of infection in mid-April. AB (pH 2.5), He. X 1300. (b) Thin epidermis of moribund fish in late May with one-two layers of indistinct flattened cells and the effete remains of a goblet cell (arrowed). Note the prominent melanophores in the dermis. AB (pH 2.5), H&E. X 1000. (c) Thin epidermis of moribund fish in late May showing detachment of the hypodermis from the underlying musculature. The melanophores form a continuous layer in the dermis and Ichtyobodo parasites (arrowed) can be seen on the skin surface. AB (pH 2.5), H&E. X 1600. (d) Skin from a healthy-looking fish in late May with several layers of epidermal cells; goblet cells are hypertrophic and actively secreting through very wide pores. AB (pH 2.5), He&E. X 1500.

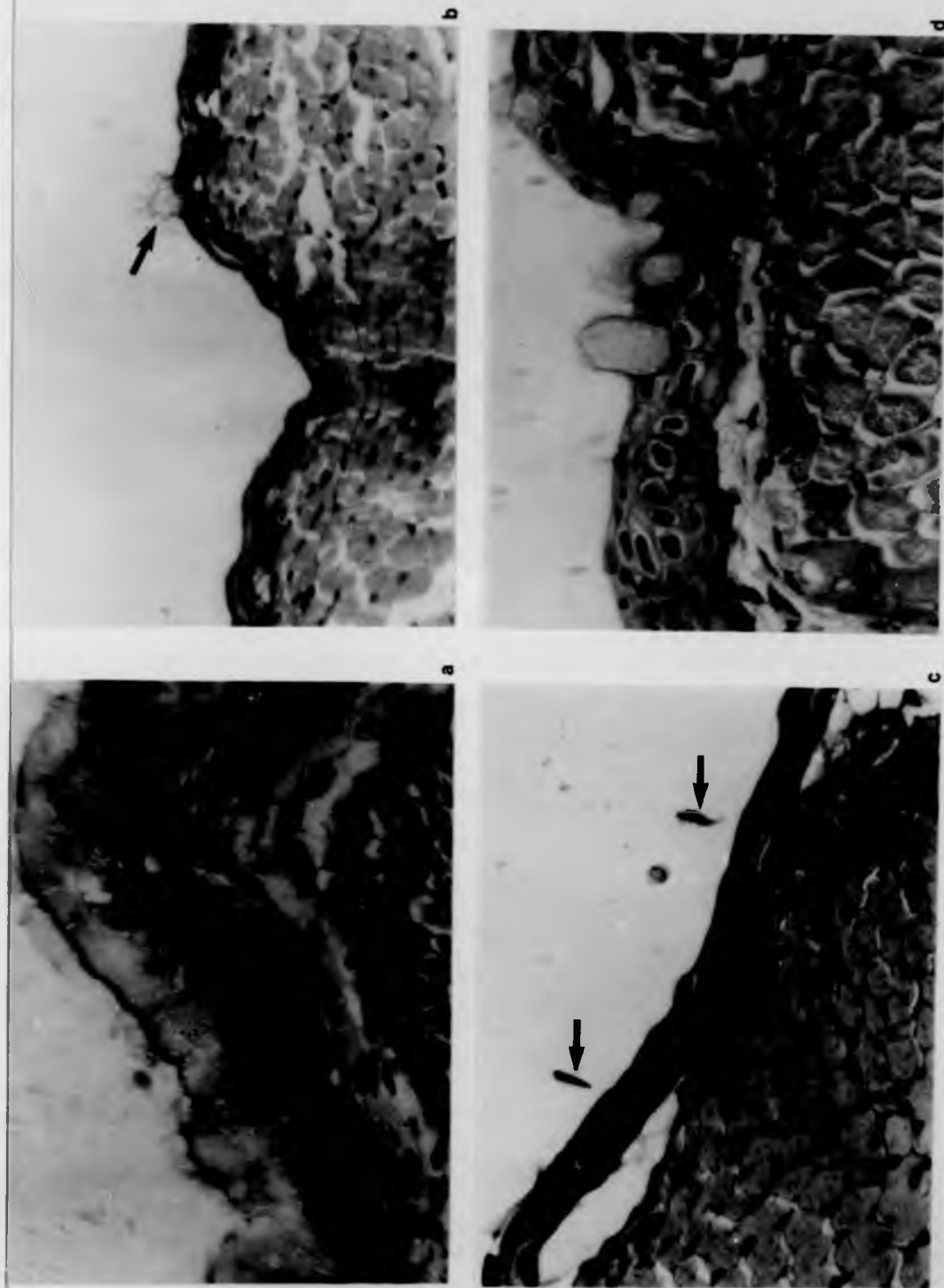


Figure 5.5.

Figure 5.5. Transverse sections through the skin of 0+ cultured brown trout infested with Ichtyobodo. (a) Explosive secretion of mucus from epidermal goblet cells at a very early stage of infection in mid-April. AB (pH 2.5), He. X 1300. (b) Thin epidermis of moribund fish in late May with one-two layers of indistinct flattened cells and the effete remains of a goblet cell (arrowed). Note the prominent melanophores in the dermis. AB (pH 2.5), H&E. X 1000. (c) Thin epidermis of moribund fish in late May showing detachment of the hypodermis from the underlying musculature. The melanophores form a continuous layer in the dermis and Ichtyobodo parasites (arrowed) can be seen on the skin surface. AB (pH 2.5), H&E. X 1600. (d) Skin from a healthy-looking fish in late May with several layers of epidermal cells; goblet cells are hypertrophic and actively secreting through very wide pores. AB (pH 2.5), He&E. X 1500.

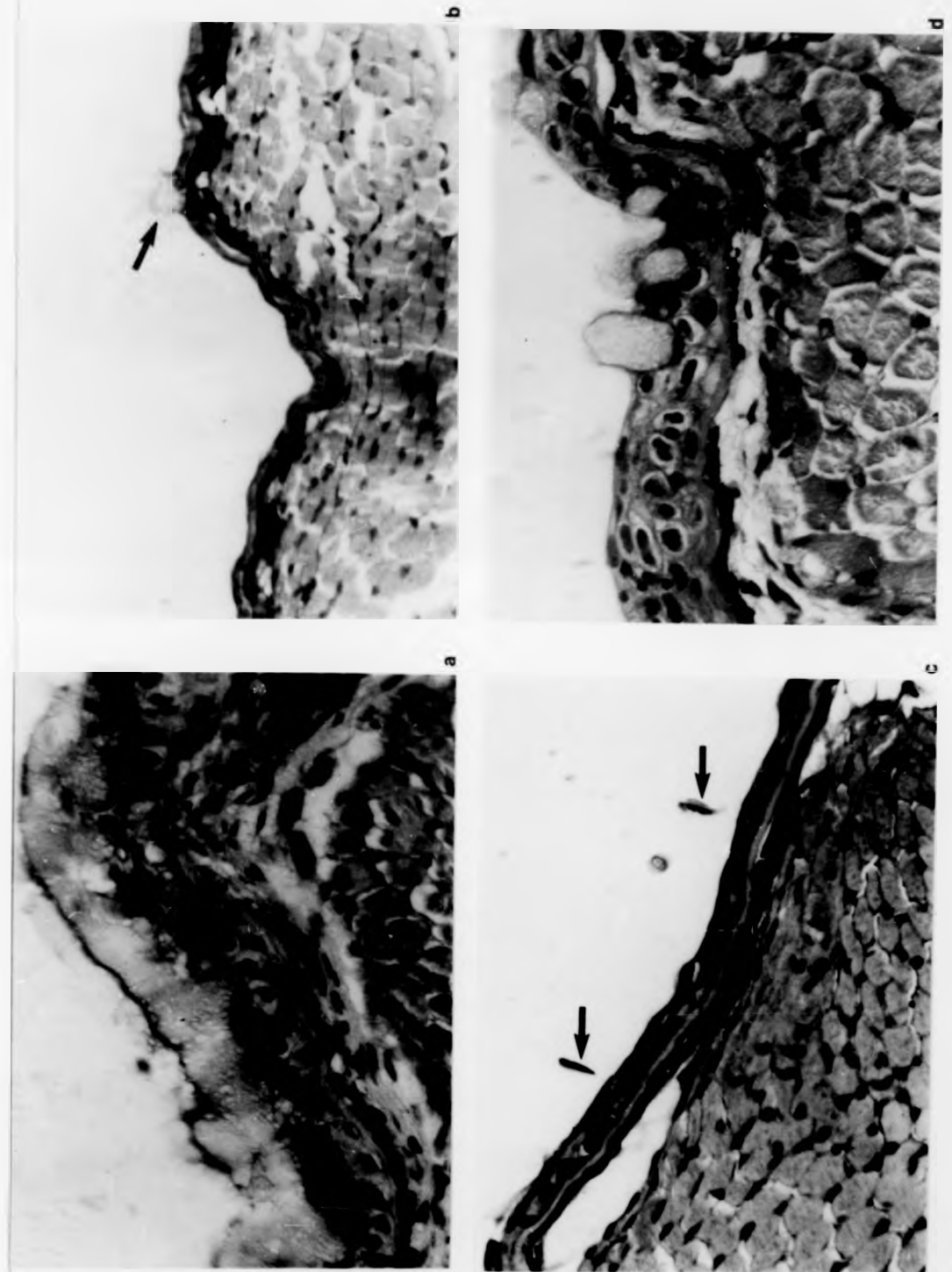


Figure 5.5.

tion, to others it was fatal. Moribund fish became emaciated and were dark in colour; epidermal sections from such individuals revealed an almost complete absence of mucous cells with only their effete remains present (Fig. 5.5.b). The epidermis of these fish was very thin with only one or two layers of indistinct flattened cells, and no acidophilic cells were observed. Dermal melanophores were very prominent and the whole skin was frequently detached in places from the underlying musculature (Fig. 5.5.c). The gills of moribund fish were found to be only lightly infested. Healthy-looking individuals of the same age were also infested, but superficial goblet cells were still present in the epidermis which was several cell layers thick (Fig. 5.5.d). However, the goblet mucous cells present were frequently hypertrophic with very large pores and were generally confined to the epidermal surface. Hyperplasia was also evident in parts of the epidermis in these fish where parasitic infestation was intense; proliferation resulted in eight-twelve layers of undifferentiated cells with pale swollen nuclei and also a highly irregular epidermal surface (Fig. 5.6.a). In other parts of the epidermis of such individuals where Ichtyobodo was not present, the epidermal structure was far less impaired and dermal melanophores were generally inconspicuous, but even in these uninfested areas a proportion of the goblet cells was enlarged and Malpighian cell oedema had occurred (Fig. 5.6.b).

By June and July the disease had reached a chronic condi-

Figure 5.6. Transverse sections through the skin of O+ cultured brown trout suffering from costiasis. (a) Hyperplastic area of the epidermis in late May showing c. ten layers of cells with pale swollen nuclei and numerous Ichtyobodo parasites (arrowed) on the very irregular epidermal surface. No goblet cells are present and acidophilic cells are pale. AB (pH 2.5), He&E. X 1300. (b) Another part of the epidermis where Ichtyobodo was not present; the structure is less impaired and melanophores are less prominent. Spongiosis is evident and some goblet cells have very wide pores. AB (pH 2.5), H&E. X 1000. (c) Sloughing of necrotic epidermal cells with pycnotic nuclei at the chronic stage of the disease in June. Note the corrugation of the dermis. AB (pH 2.5), H&E. X 1600. (d) Large numbers of acidophilic cells (arrowed) in the epidermis in July. AB (pH 2.5), H&E. X 1600.

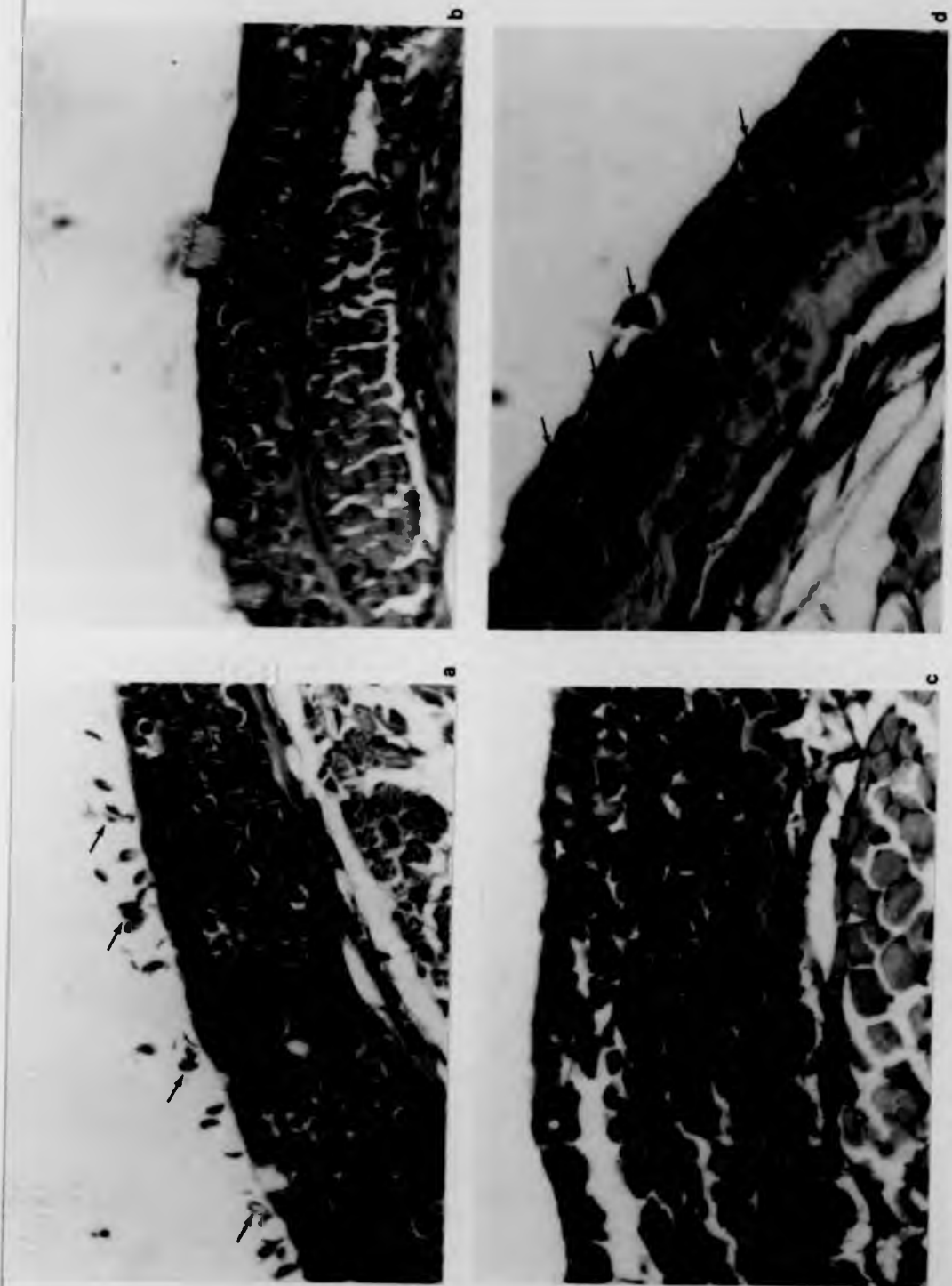


Figure 5.6.

Figure 5.6. Transverse sections through the skin of O+ cultured brown trout suffering from costiasis. (a) Hyperplastic area of the epidermis in late May showing c. ten layers of cells with pale swollen nuclei and numerous Ichtyobodo parasites (arrowed) on the very irregular epidermal surface. No goblet cells are present and acidophilic cells are pale. AB (pH 2.5), He&E. X 1300. (b) Another part of the epidermis where Ichtyobodo was not present; the structure is less impaired and melanophores are less prominent. Spongiosis is evident and some goblet cells have very wide pores. AB (pH 2.5), H&E. X 1000. (c) Sloughing of necrotic epidermal cells with pycnotic nuclei at the chronic stage of the disease in June. Note the corrugation of the dermis. AB (pH 2.5), H&E. X 1600. (d) Large numbers of acidophilic cells (arrowed) in the epidermis in July. AB (pH 2.5), H&E. X 1600.

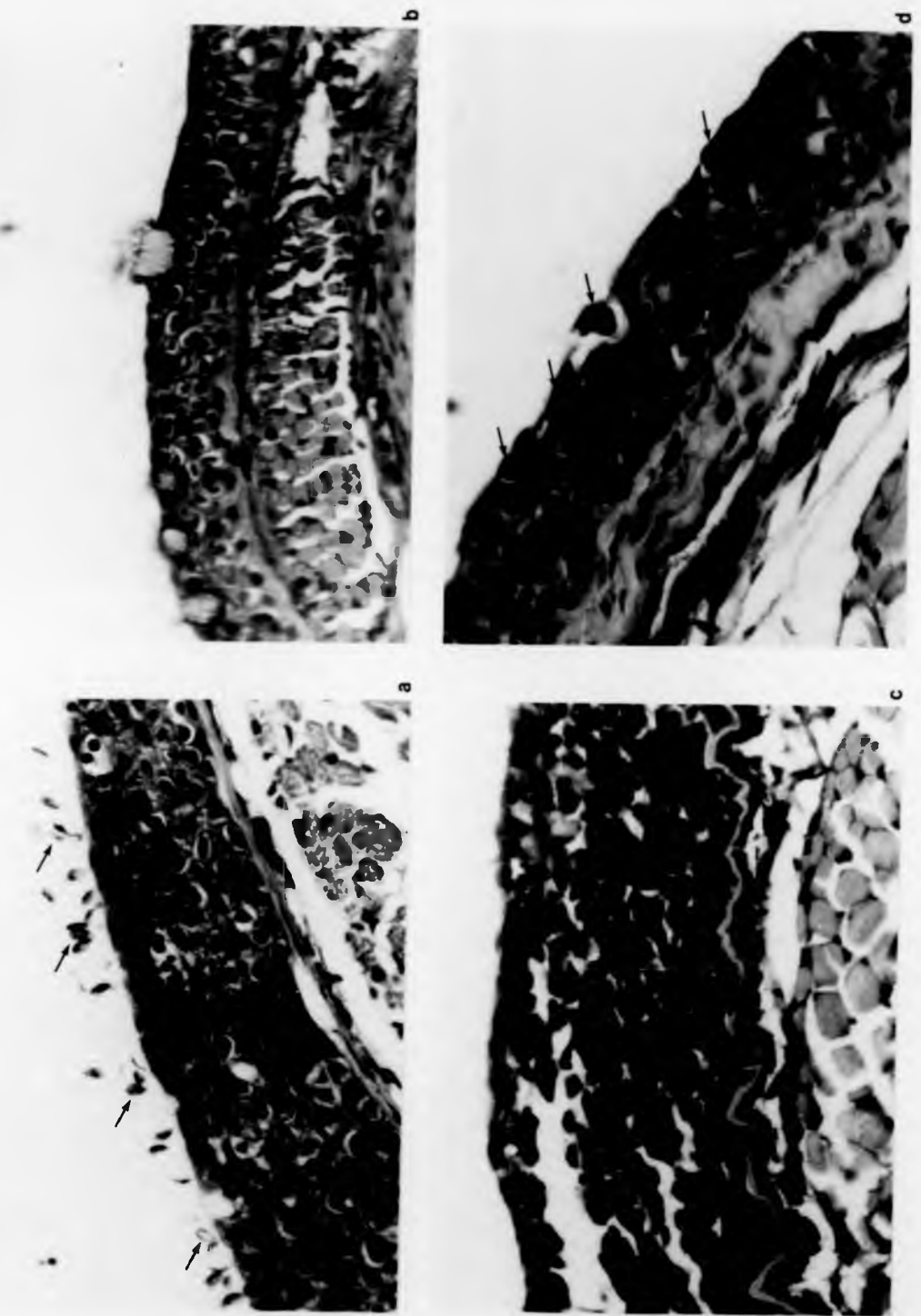


Figure 5.6.

tion in the hatchery-reared brown trout. All of the surviving fish were heavily infested and areas of the thickened epidermis, produced by hyperplasia of the Malpighian cells, were frequently observed to be sloughing off. The epidermal cells at this stage were small and indistinct with basophilic nuclei and a thin rim of pale-staining cytoplasm (Fig. 5.6.c); distinctive folding of the basement membrane and underlying dermal collagen was also observed. Another notable development, however, was the appearance of large numbers of acidophilic cells in parts of the epidermis (Fig. 5.6.d); these cells were also observed in the epidermis of brown trout from the Black Brows Beck population (Fig. 5.7.a). This event marked the beginnings of recovery from the disease and the recommencement of cell differentiation in the epidermis. Skin sections of uninfested fish of the same age from the Scandale Beck population had a full complement of goblet cells in an epidermis c. four-six cells thick (Fig. 5.7.b). During the phase of chronic costiasis in the fish in the hatchery rearing ponds, there appeared to be a cycle of cell production and cast-off; proliferation of Malpighian cells and production of acidophilic cells (Fig. 5.7.c) was followed by a slough of several layers of the epidermis with its parasitic fauna (Fig. 5.7.d), and in some areas the epidermis was almost completely eroded (Fig. 5.8.a). Similar features were observed in the skin sections of fish from Black Brows Beck; Fig. 5.8.b shows a single incomplete layer of swollen epidermal cells on the basement membrane in an area where the

Figure 5.7. Transverse sections through the skin of 0+ brown trout. (a) Acidophilic cells (arrowed) in the epidermis of a wild brown trout suffering from costiasis in August. AB (pH 2.5), He&E. X 1000. (b) Numerous goblet cells in the middle and upper layer of the epidermis in a fish from an uninfected wild population in August. AB (pH 2.5), He&E. X 1000. (c) Proliferation of epidermal cells and abundant acidophilic cells in a cultured fish suffering from chronic costiasis in July. H&E. X 1000. (d) Sloughing of epidermal layers with attached parasites in an infested cultured fish in August. H&E. X 1000.

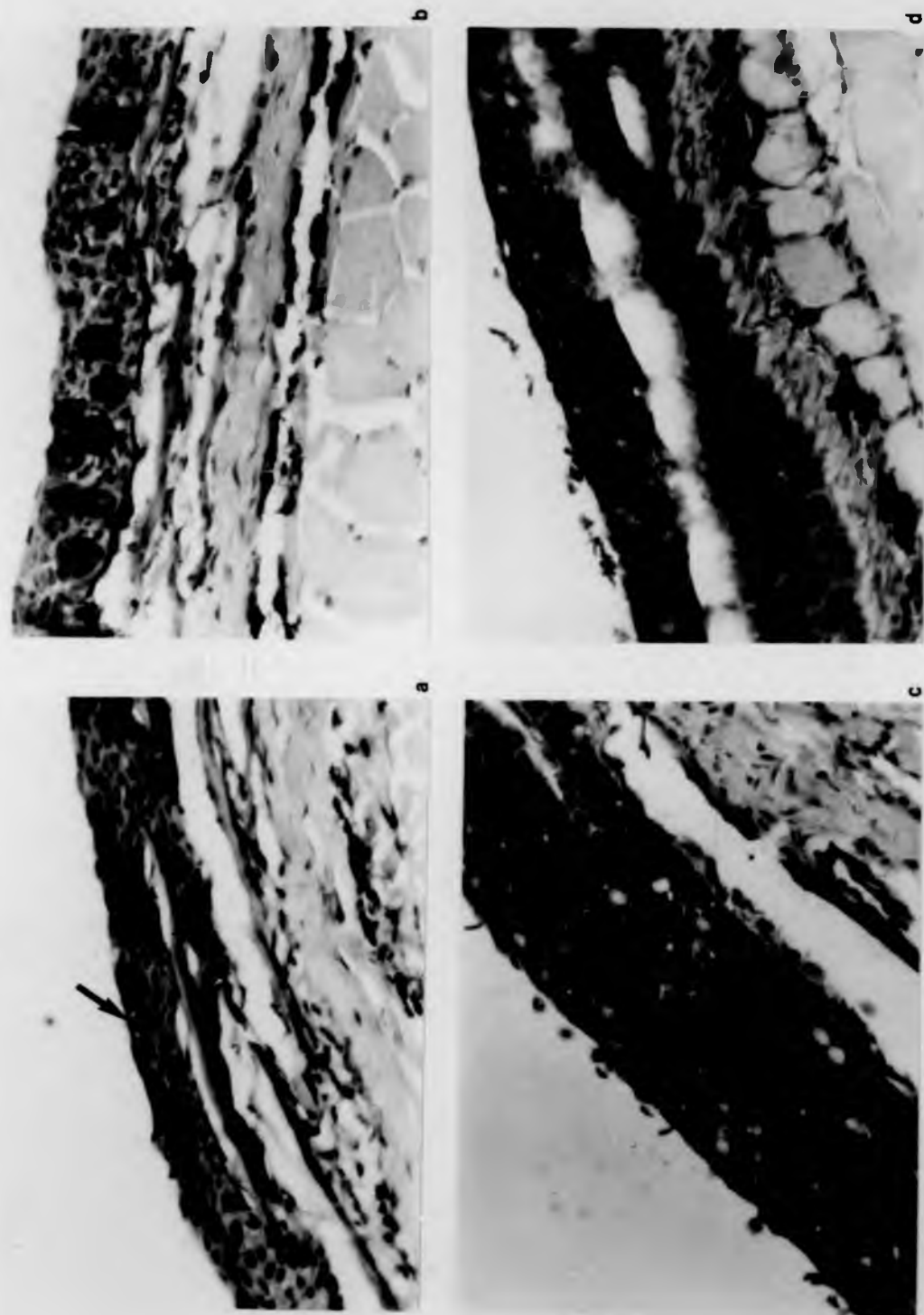


Figure 5.7.

Figure 5.7. Transverse sections through the skin of O+ brown trout. (a) Acidophilic cells (arrowed) in the epidermis of a wild brown trout suffering from costiasis in August. AB (pH 2.5), He&E. X 1000. (b) Numerous goblet cells in the middle and upper layer of the epidermis in a fish from an uninfected wild population in August. AB (pH 2.5), He&E. X 1000. (c) Proliferation of epidermal cells and abundant acidophilic cells in a cultured fish suffering from chronic costiasis in July. H&E. X 1000. (d) Sloughing of epidermal layers with attached parasites in an infested cultured fish in August. H&E. X 1000.

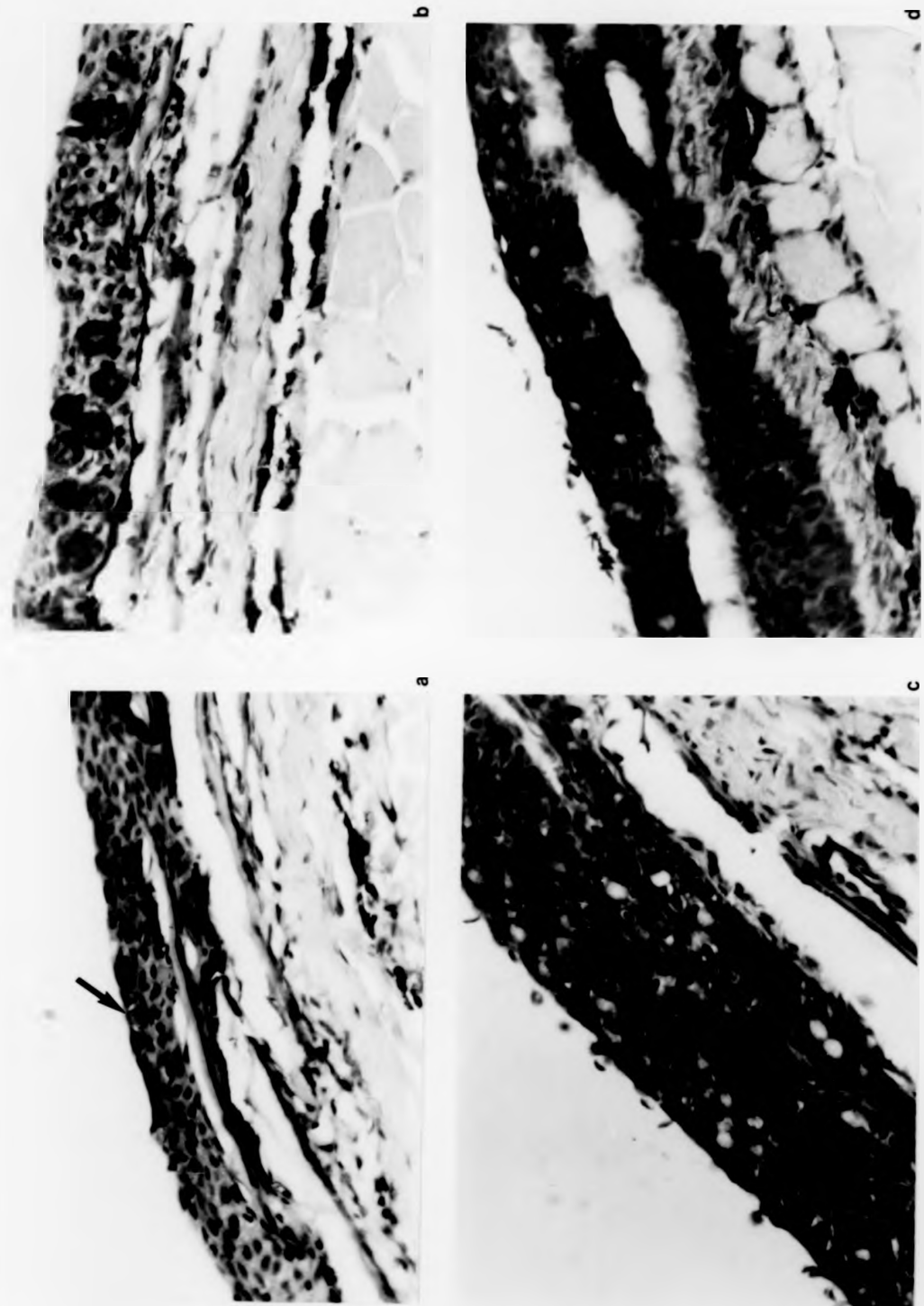


Figure 5.7.

Figure 5.8. Transverse sections through the skin of 0+ brown trout. (a) An area, from a cultured fish suffering from chronic costiasis in August, where the epidermal plaque has been sloughed off leaving a few layers of oedematous cells; the surrounding hyperplastic epidermis consists of c. twenty layers of pale indistinct cells. AB (pH 2.5), H&E. X 1000. (b) A single incomplete layer of swollen cells on the basement membrane of an infected wild fish in August. AB(pH 2.5), H&E. X 1000. (c) Hypertrophic goblet cells in the epidermis of a cultured fish recovering from costiasis in September; acidophilic cells (arrowed) are less common at this stage. H&E. X 1000. (d) Macrophage - like cells (arrowed) containing melanin in a cultured fish recovering from infestation in September. AB (pH 2.5), H&E. X 1000.

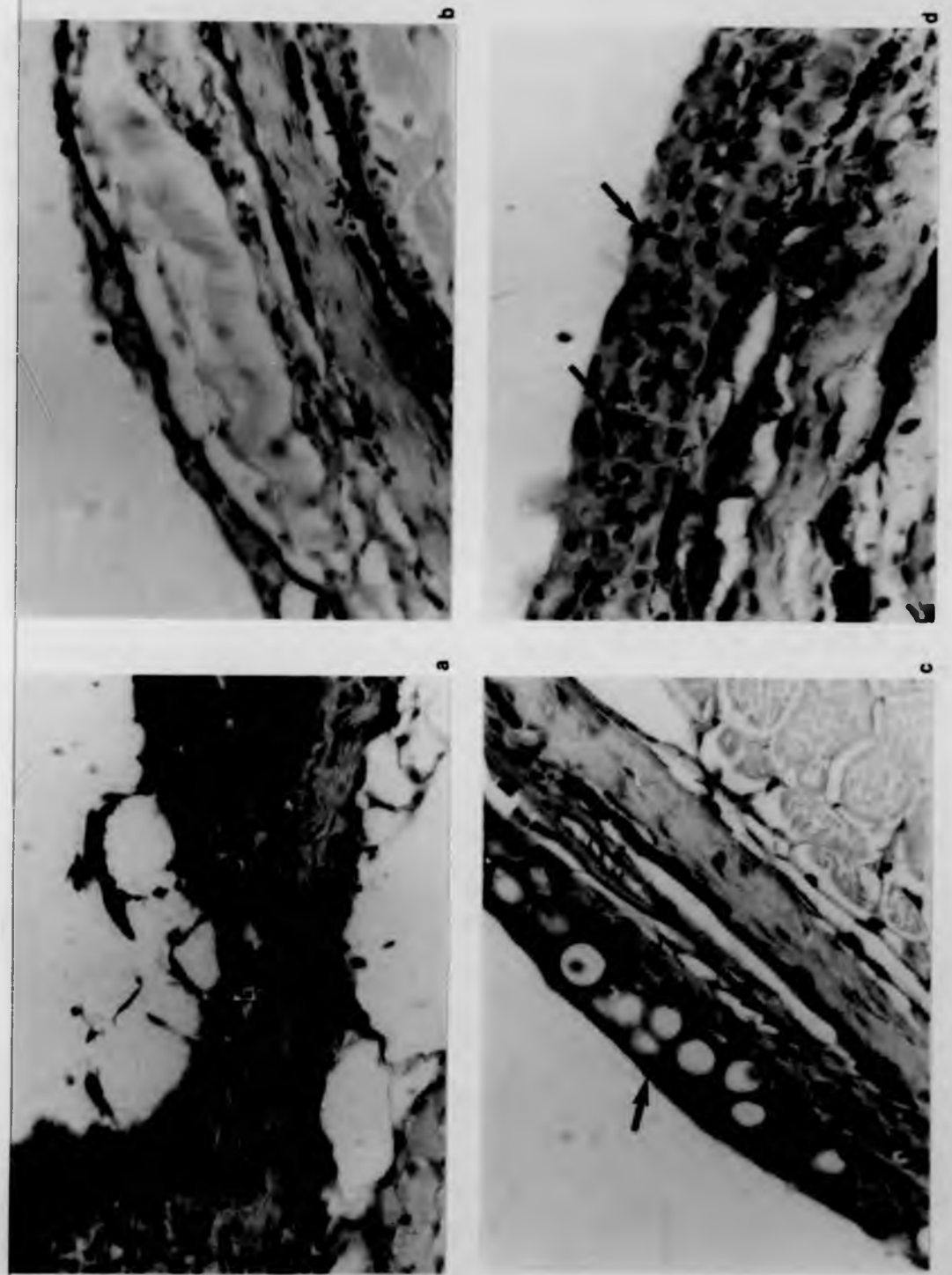


Figure 5.8.

Figure 5.8. Transverse sections through the skin of 0+ brown trout. (a) An area, from a cultured fish suffering from chronic costiasis in August, where the epidermal plaque has been sloughed off leaving a few layers of oedematous cells; the surrounding hyperplastic epidermis consists of c. twenty layers of pale indistinct cells. AB (pH 2.5), H&E. X 1000. (b) A single incomplete layer of swollen cells on the basement membrane of an infected wild fish in August. AB(pH 2.5), H&E. X 1000. (c) Hypertrophic goblet cells in the epidermis of a cultured fish recovering from costiasis in September; acidophilic cells (arrowed) are less common at this stage. H&E. X 1000. (d) Macrophage-like cells (arrowed) containing melanin in a cultured fish recovering from infestation in September. AB (pH 2.5), H&E. X 1000.

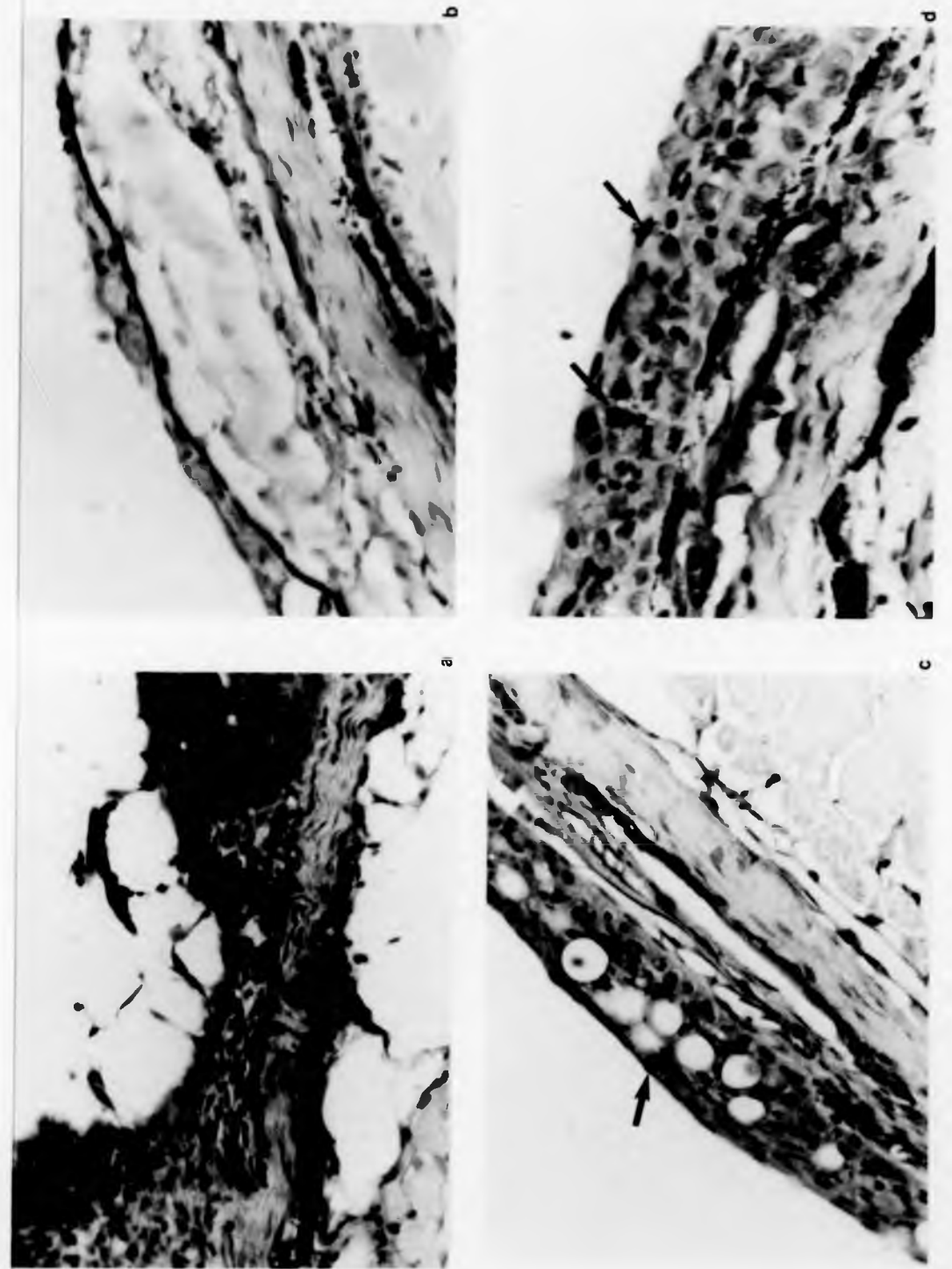


Figure 5.8.

dermis had also become swollen.

By September goblet mucous cells had begun to reappear in the epidermis of the hatchery-reared fish, and in some sections were fairly numerous but often hypertrophic (Fig. 5.8.c). Acidophilic cells were less frequent at this stage and macrophage-like cells containing melanin were commonly present (Fig. 5.8.d). In other sections the epidermis was clearly seen to be regaining its normal structure (Fig. 5.9.a); although intercellular spaces were still present and phagocytes were observed containing the ingested remains of necrotic cells, the epidermal surface was far more intact and complete by this stage. By the end of the year the epidermis had a fully stratified structure, often with a prominent leucocyte layer in the basal region (Fig. 5.9.b). It was notable, however, that the epidermis was still thickened in comparison with that of the uninfested wild brown trout of the same age, in which leucocytes and acidophilic cells were considerably less abundant and there was a distinct external layer of mucus present (Figs 5.9.c; 5.9.d). At this stage the position in the wild and hatchery-reared fish may not be strictly comparable as the remaining cultured fish had grown to a larger size in spite of Ichtyobodo infestation. Nevertheless, the epidermis of the fish which were recovering from the disease was still evidently hyperplastic in places with large numbers of migrating leucocytes above an intact basal layer (Fig. 5.10.a); spongiosis could also be observed and mitoses were still frequent (Fig. 5.10b).

Figure 5.9. Transverse sections through the skin of 0+ brown trout. (a) Phagocyte (arrowed) with the ingested remains of necrotic cells in the epidermis of a cultured fish recovering from costiasis; normal sized goblet cells and a few acidophilic cells can be seen, and spongiosis is still evident. H&E. X 1000. (b) Stratified epidermis of a cultured fish which has almost recovered from costiasis in December. Note the prominent leucocyte layer above the basal cells. AB (pH 2.5), H&E. X 1000. (c) Epidermis of a wild brown trout from an uninfected population in December; the epidermis is thinner and leucocytes (large arrow) and acidophilic cells (small arrow) are less frequent than in (b). AB (pH 2.5), H&E. X 1000. (d) Epidermis of a wild fish from an uninfected population in December with a distinct external mucous layer. AB (pH 2.5), H&E. X 1000.

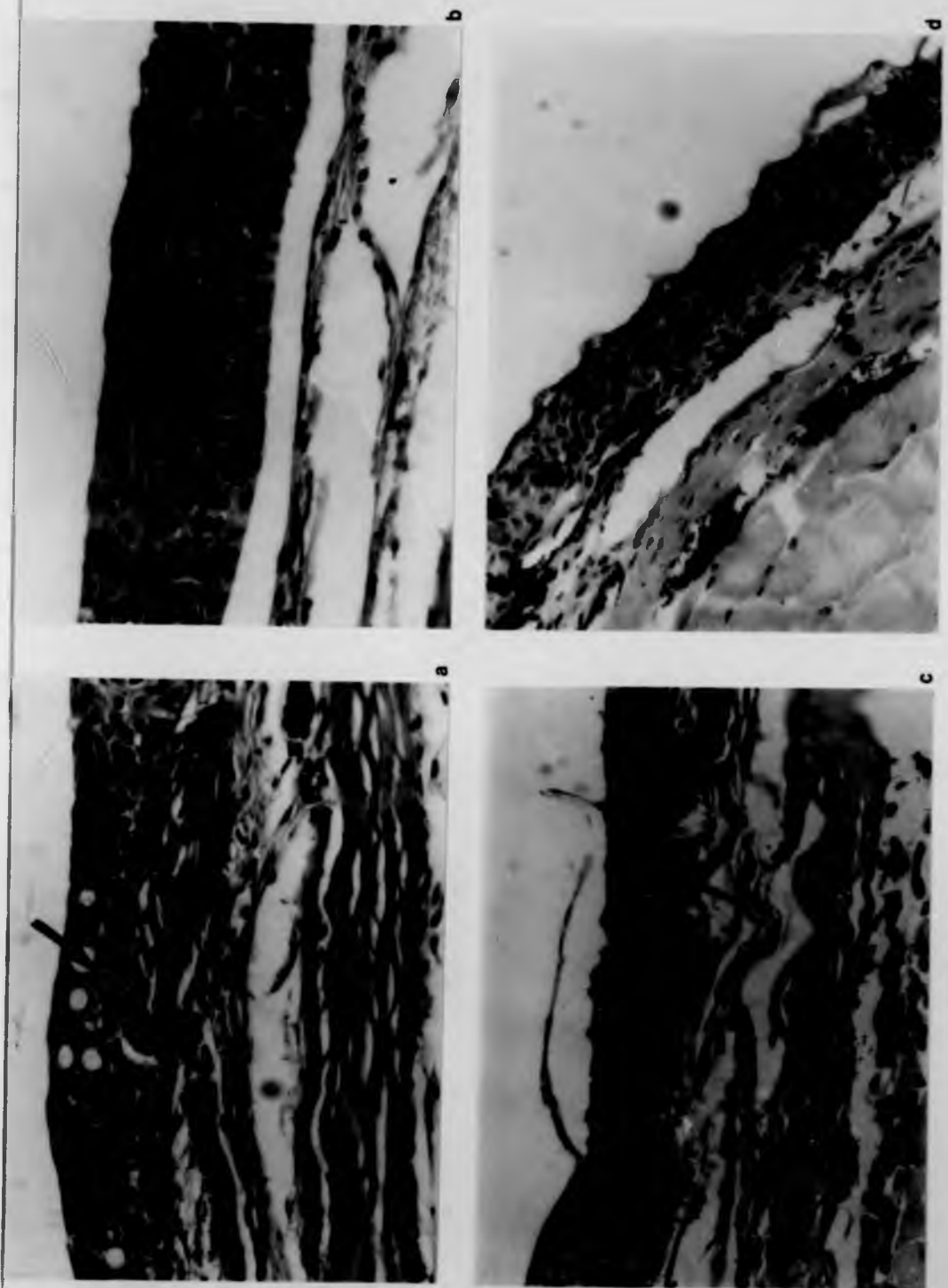


Figure 5.9.

Figure 5.9. Transverse sections through the skin of 0+ brown trout. (a) Phagocyte (arrowed) with the ingested remains of necrotic cells in the epidermis of a cultured fish recovering from costiasis; normal sized goblet cells and a few acidophilic cells can be seen, and spongiosis is still evident. H&E. X 1000. (b) Stratified epidermis of a cultured fish which has almost recovered from costiasis in December. Note the prominent leucocyte layer above the basal cells. AB (pH 2.5), H&E. X 1000. (c) Epidermis of a wild brown trout from an uninfected population in December; the epidermis is thinner and leucocytes (large arrow) and acidophilic cells (small arrow) are less frequent than in (b). AB (pH 2.5), H&E. X 1000. (d) Epidermis of a wild fish from an uninfected population in December with a distinct external mucous layer. AB (pH 2.5), H&E. X 1000.

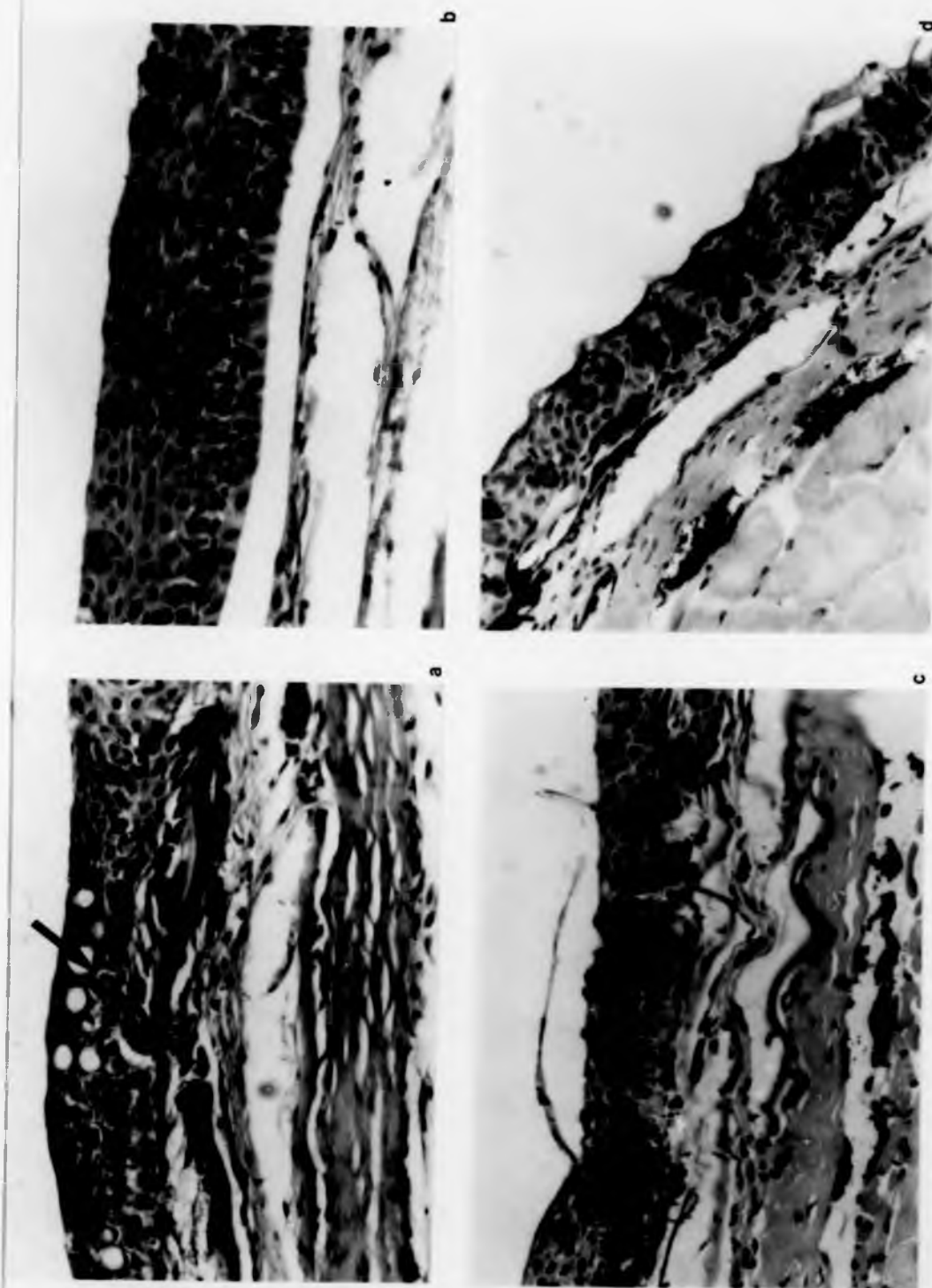


Figure 5.9.

Figure 5.10. Transverse sections through the skin of cultured O+ brown trout recovering from costiasis in December. (a) An area of the epidermis still very much thickened and is inflamed with a massive leucocyte infiltration in the middle layers; acidophilic cells (large arrow) and goblet cells (small arrow) are both present. AB (pH 2.5), H&E. X 1000. (b) Mitotic cells in the basal layers of the epidermis (arrowed); differentiating acidophilic cells can also be seen in the lower layers. AB (pH 2.5), H&E. X 1000.




Figure 5.10.

Figure 5.10. Transverse sections through the skin of cultured O+ brown trout recovering from costiasis in December. (a) An area of the epidermis still very much thickened and is inflamed with a massive leucocyte infiltration in the middle layers; acidophilic cells (large arrow) and goblet cells (small arrow) are both present. AB (pH 2.5), H&E. X 1000. (b) Mitotic cells in the basal layers of the epidermis (arrowed); differentiating acidophilic cells can also be seen in the lower layers. AB (pH 2.5), H&E. X 1000.

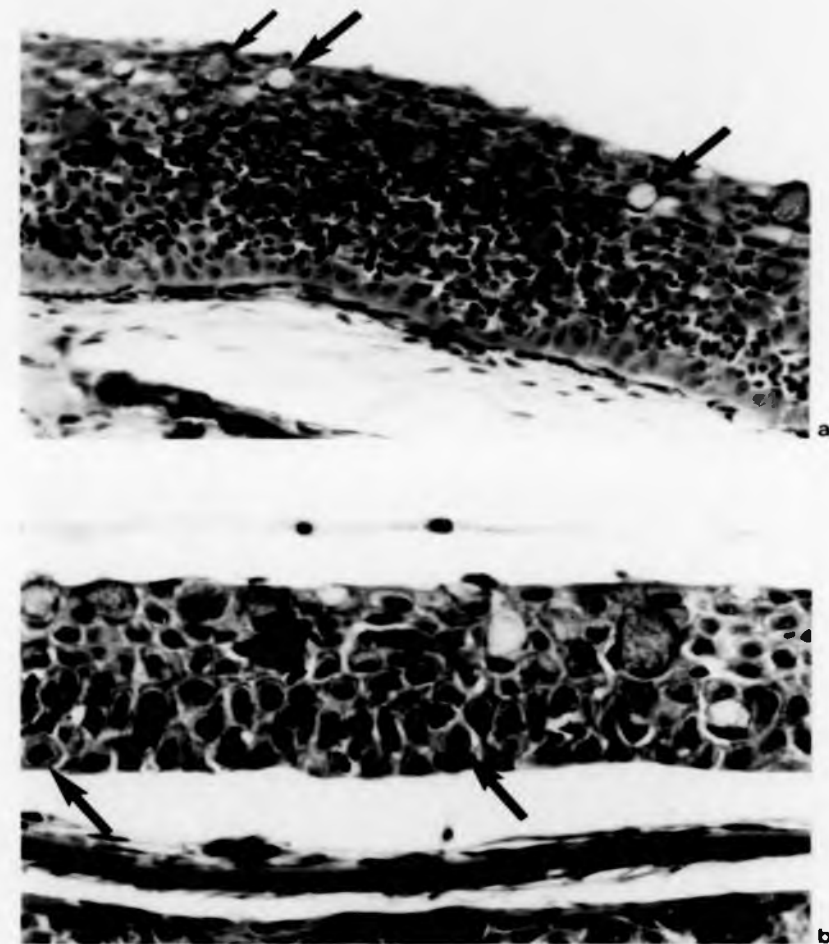


Figure 5.10.

Scanning electron microscopy

The micrographs obtained from SEM facilitate a visual conception of the impact of severe Ichtyobodo infestation on the epidermal surface of O+ brown trout (Fig. 5.11.a). In Fig 5.11.b it can be seen that a single epidermal cell appears to be able to support several parasites. Fig. 5.11.c shows an area of the epidermis where surface cells have been sloughed off and the pattern of micro-ridges on the exposed Malpighian cells is far from complete. In Fig. 5.11.d the micro-ridges are intact, and Ichtyobodo parasites can clearly be seen to penetrate the epidermal surface with their attenuated anterior ends.

5.4. Discussion

An enhanced description of the sequential pathology of costiasis, in both hatchery-reared and wild juvenile brown trout, has been accomplished through the adoption of two different but complementary approaches to the study of the effects of the bodonid ectoparasite on its salmonid host. Quantification of structural changes in the skin surface has supplemented information on the epidermal responses that would otherwise have only been suggested by the necessarily limited areas of tissue sectioned for histopathological observation. On the other hand, if only the former data had been collected, certain critical features of the host reaction to Ichtyobodo infestation, e.g. the initial

Figure 5.11. Scanning electron micrographs of Ichtyobodo parasites on the skin of O+ hatchery-reared brown trout in May. (a) An area of intensely infested epidermis at the acute stage of infection; the enlarged pores of some goblet cells can be seen at the bottom of the micrograph. X 300. (b) A heavily infested piece of tissue demonstrating that several parasites can be attached to one epidermal cell. X 3000. (c) An area where some epidermal cells have been sloughed off and the pattern of micro-ridges on exposed Malpighian cells is incomplete. X 3000. (d) Infested tissue where Ichtyobodo parasites can clearly be seen to penetrate the epidermal cells. X 4500.

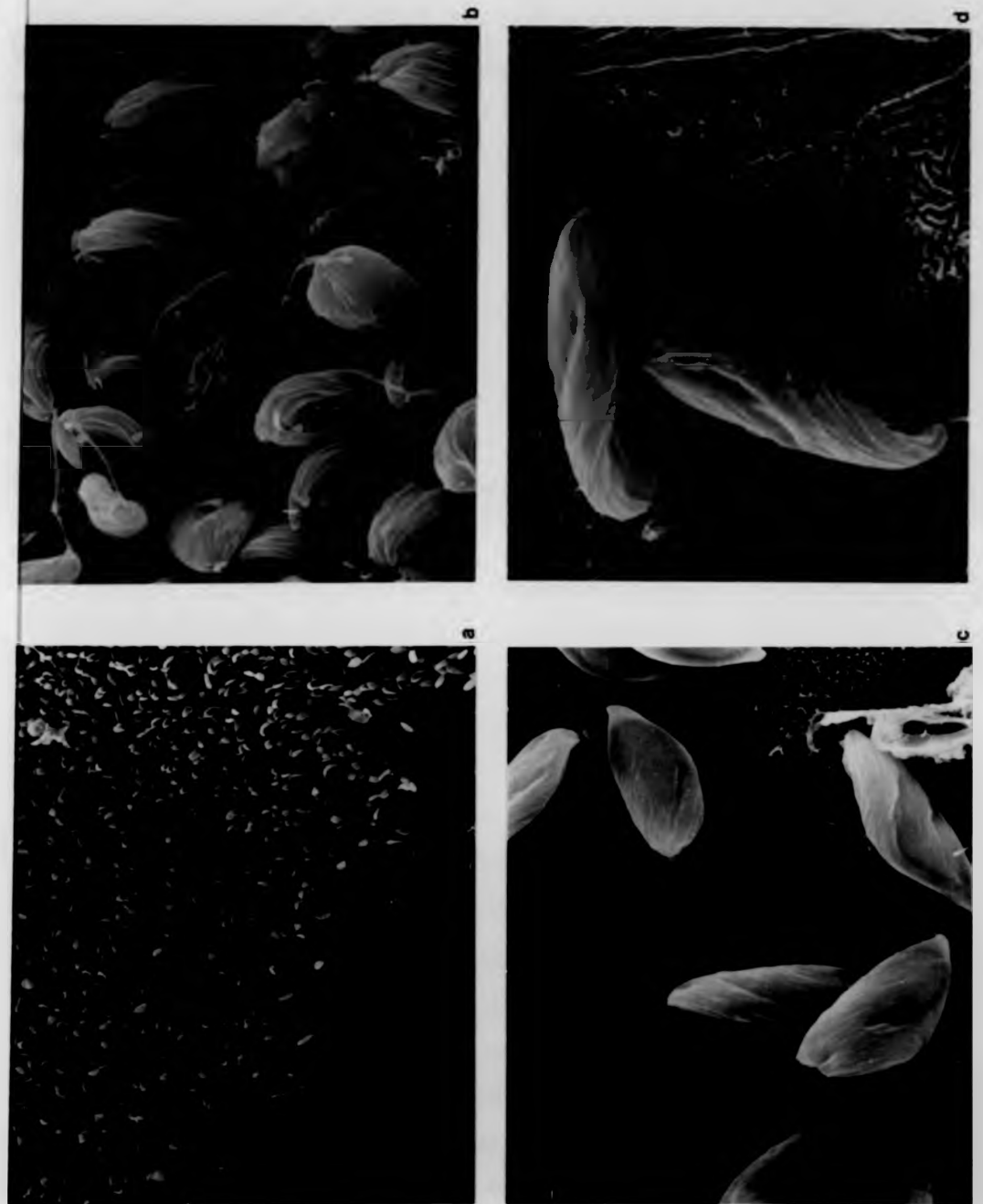


Figure 5.11.

Figure 5.11. Scanning electron micrographs of Ichtyobodo parasites on the skin of O+ hatchery-reared brown trout in May. (a) An area of intensely infested epidermis at the acute stage of infection; the enlarged pores of some goblet cells can be seen at the bottom of the micrograph. X 300. (b) A heavily infested piece of tissue demonstrating that several parasites can be attached to one epidermal cell. X 3000. (c) An area where some epidermal cells have been sloughed off and the pattern of micro-ridges on exposed Malpighian cells is incomplete. X 3000. (d) Infested tissue where Ichtyobodo parasites can clearly be seen to penetrate the epidermal cells. X 4500.

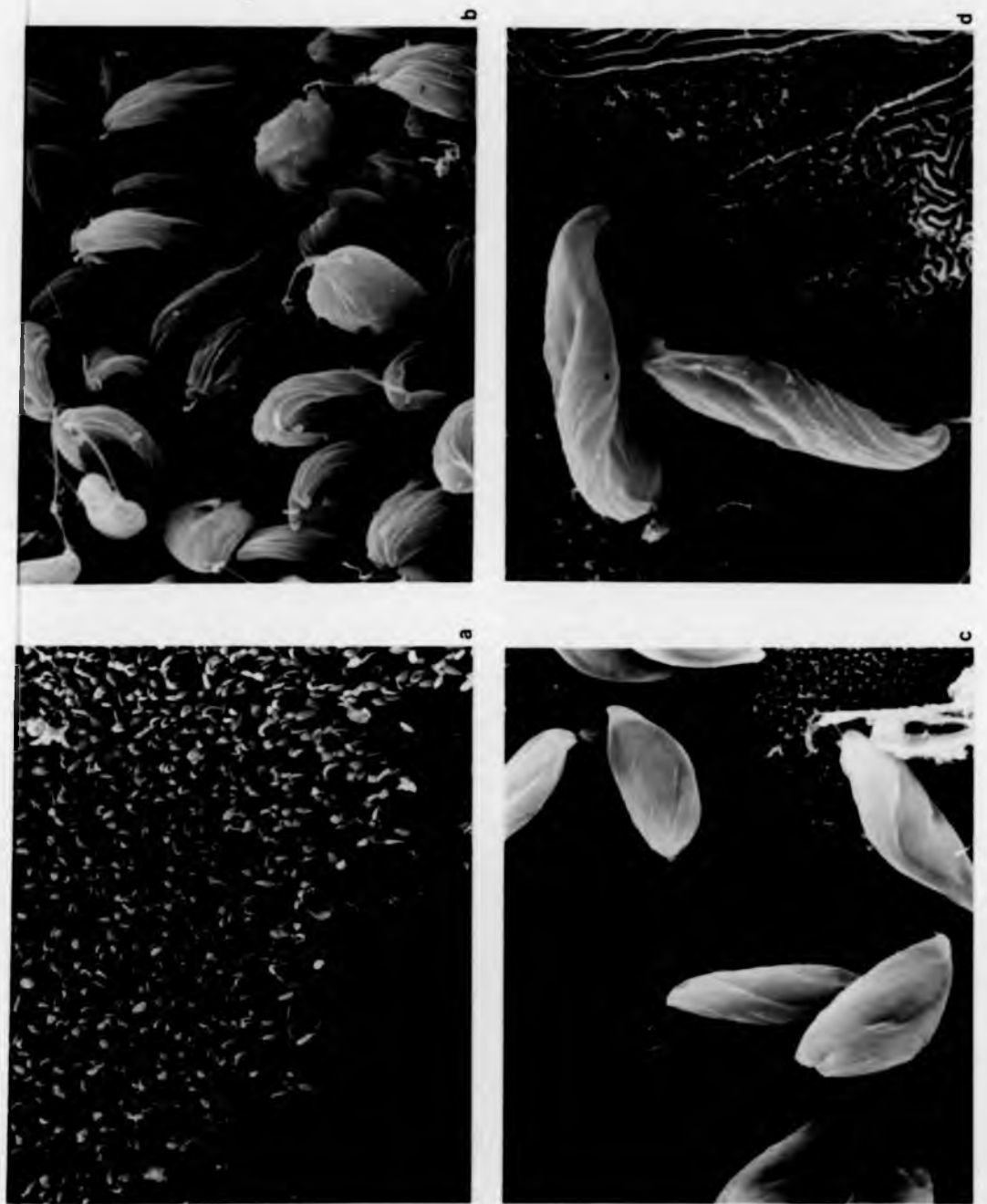

Figure 5.11.

explosive release of mucus, would have remained undetected. Furthermore, pathological investigation of fish reared under controlled conditions in the hatchery, besides providing comparative data from uninfested epidermis, has also allowed additional inferences to be drawn from observations on the pathological effects of the parasite in the wild. In addition, the use of regular formalin treatment to maintain disease-free stocks of hatchery-reared fish, has permitted the irritant properties of this prophylactic agent to be observed.

In the two years during which detailed observations were carried out at The Ferry House, Ichtyobodo infestations first appeared in O+ brown trout in late spring, after the normal decline in epidermal goblet cell abundance had commenced. Ichtyobodo was found to stimulate a rapid and exhaustive secretion of mucus from the epidermis. Thereafter, as the disease progressed to a more chronic condition, only few, spent goblet cells were seen in skin sections. This observation was reaffirmed by data from quadrat samples on stained sheets of whole skin which clearly demonstrated that superficial mucous cells had virtually disappeared from the epidermis by early June. That the infestation caused this reduction in mucification was also confirmed by analysis of individual quadrats (presented in Chapter 4): there was a conclusive negative relationship between abundance of the ectoparasite and the number of goblet cells present in different parts of the epidermal surface. At no time did the

goblet cell densities decline to such an extent in fish subjected to formalin treatment nor in those reared in sterilized water until June. Besides causing a reduction in the mucus-producing capacity of its host, Ichtyobodo infestation resulted in increased mortality of cultured brown trout during the acute and chronic phases of the disease. This period was marked by the appearance of high densities of at least one type of acidophilic cell in the epidermis of surviving fish. Epidermal development in the infested fish was then punctuated by a cycle of cell proliferation followed by sloughing of the epidermal plaque with its ectoparasite complement. By autumn, infestation had become increasingly less severe, and skin sections showed progressive re-development towards a normal epidermal structure; this was again confirmed by the quadrat samples in which the number of goblet cells increased towards December while the abundance of acidophilic cells decreased.

The pathogenesis of Ichtyobodo infestation in the hatchery-reared fish was matched in many respects in a wild brown trout population. Although the overall observed pattern of epidermal response was less pronounced, there is no evidence to suggest that other structural defence mechanisms, not seen in the hatchery, were activated in the epidermis of wild fish by infestations of this ectoparasite. It has already been pointed out that severely infested individuals in the wild population were unlikely to have been sampled in this investigation.

This time course study has provided the first seasonal account of the pathology of a naturally induced ectoparasitic protozoan skin disease in either cultured or wild fish. In the literature, many of the descriptions of the pathogenic effects of epidermal infestations in fishes are not accompanied by information concerning the specific duration of the disease nor even, in most cases, whether it was generally an acute or chronic reaction. There are, however, a number of reports that ectoparasitic protozoa promote excessive or increased secretion of mucus from the skin or gills of their host species. Such responses have been attributed to infestations of a variety of different ectoparasitic protozoans, including Trichodina spp., Ophyoqlena sp. and Chilodonella (Rogers & Gaines, 1975), Chilodonella cyprini and Trichodina fultoni (Hoffman, 1978) and Cryptobia (Needham & Wootten, 1978). Conversely, Paperna (1980) found no mucous cells in the gills of Dicentrarchus labrax (L.) heavily infested with Amyloodinium ocellatum. In the few studies where the course of infection has been followed, albeit for only a short period of time, it is clear that the mucification response varies with the stage and intensity of the infestation. In the mirror carp Cyprinus carpio, for example, epidermal mucous cells, after an initial increase in abundance, were found to completely disappear within 14-26 days after infection with Ichthyophthirius by Hines & Spira (1974), and Pottinger, Pickering & Blackstock (1984) found that the magnitude of a reduction in superficial mucus-

secreting goblet cells, associated with the ectoparasites Trichodina and Scyphidia on brown trout, was related to the intensity of infection. Robertson, Roberts & Bullock (1981) have also reported an ectoparasite-induced depletion of goblet cells over a 14 day period after infection of 100 farmed Atlantic salmon alevins with Ichtyobodo. In that case the ample inoculum employed, which consisted of fifty O+ rainbow trout heavily infested with Ichtyobodo, promoted a rapid spread of the disease but the time scale of the decline in mucification and subsequent hyperplasia in the Atlantic salmon epidermis could not be resolved. In the present investigation, it has clearly been demonstrated that the initial hypertrophy of and hypersecretion from the goblet cells at the onset of costiasis, in naturally infested O+ brown trout, is followed by a continued absence of epidermal mucous cell production throughout the subacute and chronic stages of the disease.

In the published information on the pathogenesis of ectoparasitic protozoa in fishes, epidermal hyperplasia in the host species has frequently been reported. It is the pathological response most commonly ascribed to costiasis (e.g. Fish, 1940a; Ellis & Wootten, 1978; Robertson, Roberts & Bullock, 1981) as well as to infestations of other surface parasites (e.g. Rogers & Gaines, 1975; Roberts & Bullock, 1976). It has often been observed that cell proliferation in the host epidermis is followed by oedematous changes (spongiosis) in the epithelium as well as extensive degenera-

tion and necrosis; infiltration by leucocytes and macrophages transporting melanin from damaged melanophores to the surface has been frequently noted (e.g. Roberts, 1975a; Roberts & Bullock, 1976), and Malpighian cell nuclei after an initial swelling are commonly said to become pycnotic and intensely basophilic. In many cases severe infestations have been shown to culminate in epidermal layers being sloughed, sometimes down to the basement membrane, which probably constitutes the greyish slime often mentioned in association with ectoparasitic protozoan fish disease (e.g. Fish, 1940a). All of these pathological responses in the epidermis were observed in the present investigation of juvenile brown trout parasitized by Ichtyobodo which is known to penetrate and ingest parts of the contents of the epidermal cells (Joyon & Lom, 1969).

The appearance of at least one type of acidophilic cell in the epidermis of brown trout, which increased in abundance during the acute and chronic phases of costiasis, has not previously been described. In other fish species, however, the presence of epidermal eosinophilic cells, particularly in gill epithelia, has been associated with infestations of different ectoparasites. These cells have been reported in Morone saxatilis (Walbaum) with heavy infestations of the crustacean Ergasilus labracis (Paperna & Zwerner, 1982), Anquilla anquilla infested by Dermocystidium sp. (Wootten & McVicar, 1982) and Oncorhynchus kisutch and O. tshawytscha (Walbaum) suffering from glochidiosis caused by the mollusc Margaritifera margaritifera (Meyers, Millemann & Fustish,

1980). Also, excessive production of acidophilic cells has been observed in the gills of the carp and the grasscarp Ctenopharyngodon idella (Valenciennes) with the onset of infection due to sphaerosporosis (Molnár, 1979). It is not known whether any of these cells resemble the acidophilic cell seen in the epidermis of brown trout, or those present in the outer integumentary layers of Mola mola L. parasitized by the platyhelminth Capsala martinieri and the crustacean Philorthagoriscus serratus, which have been said to resemble chloride cells (Logan & Odense, 1974). A more detailed account of the histology, histochemistry and ultrastructure of an epidermal acidophilic cell in brown trout is presented in the following chapter.

Costiasis also caused increased mortality in hatchery-reared O+ brown trout at The Ferry House in 1978. On the assumption that a dietary change resulted in exaggerated mortality in August, the weekly percentage mortalities compared well with those recorded by Robertson (1979) in farmed rainbow trout, naturally infested with Ichtyobodo, over a period of 7 months. Bullock & Roberts (1981) expected normal mortality in cultured O+ salmon to be the equivalent of 2.6% per week in a farm in Scotland; at The Ferry House this rate was not exceeded, apart from in August, in batches of O+ brown trout either subjected to formalin prophylaxis or reared in sterilized water for the first 5 months with the exception of a brief period after 6 weeks exposure to Ichtyobodo in the latter group. The increased mortality of

juvenile brown trout during the acute and chronic phases of Ichtyobodo infestation probably resulted from haemodilution due to impaired osmoregulation, as has been suggested for salmon suffering from costiasis by Robertson, Roberts & Bullock (1981), and by Richards & Pickering (1978) for brown trout and char Salvelinus alpinus with Saprolegnia fungal infection.

The reasons why some juvenile brown trout are able to survive severe Ichtyobodo infestation remain obscure. The fact that there was lower mortality in fry which had been reared in sterilized water for 5 months prior to exposure to infestation than in fish which were infected at an earlier age, indicates that the probability of survival for an individual is dependent on its age and/or size at the time of initial infestation; young alevins appear to be particularly susceptible to costiasis. Robertson (1979) has suggested that an unknown change may take place in the epidermis of salmonids which prevents colonization by the parasite, and it is not inconceivable that the production of large quantities of acidophilic cells plays a role in the counteraction of the disease.

The temporal variation in epidermal structure observed during this investigation in O+ brown trout subjected to prolonged formalin prophylaxis, bore a number of similarities to that induced by costiasis. High densities of acidophilic cells were recorded in the skin surface following an initial increased depletion of goblet mucous cell abundance in the

first part of the year.

The analogous changes that have been observed in mucification promoted by pathogenic agents and by formalin treatment, give rise to the suggestion that there may be common features in the epidermal responses of fish to various forms of surface active irritation. Different types of physical and chemical irritants together with other artificial stress factors are known to influence mucification in teleost epidermis; these include urea (Srivastava & Srivastava, 1979), osmotic stress (Wendelaar Bonga & Meis, 1981) pH stress (Daye & Garside, 1976; Zuchelkowski, Lantz & Hinton, 1981) ultra-violet radiation (Bell & Hoar, 1950), abrasion during spawning (Smith, 1978), crude oil pollutants (Haensly, Neff, Sharp, Morris, Bedgood & Boem, 1982) and handling stress (Pickering & Macey, 1977; Pickering, Pottinger & Christie, 1982). In some cases mucus production has been said to increase, and in others to decrease. However, it is not possible to compare directly the intensity of irritation caused by such widely differing stimuli and unfortunately the duration of the stress has not always been known. Also, the influence of other variables often precludes direct comparison of observed epidermal responses to irritation, whether chemical, physical or pathogenic, even within a single species. Differences in environmental temperature, for instance, can modify substantially the fish's rate of defence response and also the irritant's activity (see Roberts, 1975b). Developmental and seasonal changes in the epidermal

structure are also known to take place (as described in Chapter 3 and, for instance, by Roberts, Bell & Young, 1973; Wilkins & Jancsar, 1979) and, in addition, a sexual dimorphism in skin structure has been described in salmonid species at spawning time (Stoklosowa, 1966; 1970; Pickering, 1977). Thus, although this study of juvenile brown trout has indicated that there may be a non-specific mucification response to epidermal irritation, further experimental work in a variety of taxa is required to clarify the situation.

The results presented here of long-term regular formalin treatment also indicate that successful prophylaxis can be achieved by the application of considerably lower doses than are generally recommended (e.g. Fish 1940a; b). In view of the effects formalin has been shown to induce in the epidermis of O+ brown trout, and also the fact that this chemical can cause damage to gill epithelium (Smith & Piper, 1972; Wedemeyer & Yasutake, 1974), it would be advisable for pisciculturists to consider the costs as well as the benefits of its use as a prophylactic agent. In this respect, further experimentation into minimum doses required for prophylaxis and therapeutic treatment would be helpful, but a delay in treatment until the initial signs of ectoparasitic infection are evident would appear to be appropriate. This would necessitate regular inspection for the presence of the parasite. Later stages of the disease are characterized by loss of appetite, listlessness and 'flashing' caused by diseased individuals rubbing on the bottom of their rearing

tanks; in severe cases the body may also assume a bluish-grey cast (Fish, 1940a; Tavalga & Nigrelli, 1947; Rogers & Gaines, 1975; Becker, 1977). During post mortem examination, in the case of costiasis account should be taken of the rapid detachment of the parasite on the death of its host, a process which takes c. 15 seconds (Joyon & Lom, 1969).

Histological investigation of the effects of formalin irritation in the epidermis would represent another interesting line of enquiry. In addition, information on the possible influence of this and other irritants including disease organisms on the histochemistry of the epidermal mucous cells might enhance the interpretation of results presented earlier (in Chapter 3), where histochemical changes in these cells were found to be correlated with emergence from an abrasive environment in brown trout alevins. The results of further studies on the acidophilic cells, which were found to increase in abundance in response to both Ichtyobodo infestation and formalin treatment, are given in the next chapter.

Chapter 6

An Acidophilic Granular Cell in the Epidermis of Brown Trout and other Salmonids

6.1. Introduction

The presence of acidophilic cells in the epidermis of both hatchery-reared and wild juvenile brown trout Salmo trutta has been reported in previous chapters. Although their abundance has been found to increase markedly following ectoparasitic infestation and also after prolonged formalin treatment, these cell types have also been observed in disease-free brown trout reared under various conditions as well as in the wild. There is thus no reason to suppose that their presence, rather than their abundance, in the epidermis of brown trout is dependent on surface active irritation.

Epidermal cells with a strong affinity for acid dyes are known to occur in a wide variety of non-salmonid fish species (see, for instance, Bhatti, 1938; Roberts, Young & Milne, 1971; Roberts and Bullock, 1976; 1980; Zaccone, 1980a) and their presence has also been noted in some salmonid species (Bullock & Roberts, 1975; Pickering & Macey, 1977). However, prior to the present investigation (see also Blackstock & Pickering, 1980), there was no detailed published description of an epidermal acidophilic cell in salmonid fish. That their presence in brown trout skin epithelium has never been

mentioned in the results of previous structural investigations (e.g. Harris & Hunt, 1975a), may be at least in part due to the relatively small samples of tissue used in conventional histological and ultrastructural studies. The employment of a quadrat sampling procedure over the surface of sheets of juvenile brown trout skin has shown conclusively that acidophilic cells are sometimes present in very high densities. However, considerable variation in the abundance of these epidermal acidophilic cells has been recorded between individuals within populations; inter population differences and temporal fluctuations in their numbers have also been observed.

Although acidophilic cells have been reported in a number of diverse teleost species, their function is largely unknown. As a first step to elucidating the properties and possible functions of these cells, an investigation was planned to describe the histology, histochemistry and ultrastructure of one acidophilic cell type in the skin of the O+ brown trout. Additionally, it was decided to carry out surface histological examinations of the epidermis of older brown trout and also a number of other taxa to determine whether acidophilic cells occur more widely in salmonids.

6.2. Materials and Methods

Survey of acidophilic cells in the epidermis of 1+ and older brown trout and other salmonids

Examination of the epidermal surface for acidophilic cells in 0+ fish of the species listed below, which were reared at The Ferry House hatchery, was undertaken in 1978. In each case the sample size and times of sampling are given.

i. Sea trout Salmo trutta: ten fish sampled in both May and June.

ii. Rainbow trout S. gairdneri: monthly samples of ten fish were taken from May to August.

iii. Atlantic salmon S. salar: monthly samples of ten fish were taken from May to August.

iv. Char Salvelinus alpinus: ten fish sampled in May.

In addition the following wild salmonid populations in north-west England were sampled.

v. 1+ and older brown trout in Scandale Beck: monthly samples of ten-eighteen fish were obtained from January 1977 to February 1978.

vi. 1+ and older brown trout from three other different streams were sampled in August 1977.

vii. A sample of twenty 1+ and older brown trout was trapped in Wise Een Tarn in the autumn of 1978.

viii. A sample of twenty sexually mature char was netted on their spawning grounds in Windermere in 1978.

At each sampling time all fish were anaesthetized in a

solution of MS 222 (Sandoz, 0.1 g l^{-1}) and killed by spinal section. The body weight, fork length, age and sex (when possible) were recorded for each fish. The age of wild fish was deduced from scale readings. Small fish (up to 5 cm in length) were fixed whole and examined for ectoparasites after fixation; from larger individuals pieces of skin (approximately 1 cm square) were taken from the shoulder region and the presence of ectoparasites was determined from fresh skin scrapes from the flanks. All samples were immediately fixed in 10% formalin containing 0.6% NaCl and 0.001% eosin. This solution selectively stains acidophilic cells during the fixation process. Skin samples were further stained with 1% Alcian blue (pH 2.5) to demonstrate the presence or absence of superficial goblet cells (Pickering, 1974).

Histology, histochemistry and ultrastructure of an acidophilic cell type in hatchery-reared O+ brown trout

For histological and histochemical investigations of this acidophilic cell (as well as the goblet mucous cell which was also considered for comparative purposes), adjacent pieces of skin from each of thirty O+ brown trout (reared at The Ferry House and sampled in July 1978) were fixed in Bouin's fluid, 10% formalin in phosphate buffer, Helly's fluid (with post-chromation) or Zenker's fluid. The tissue was then dehydrated, cleared, embedded in paraffin wax and sectioned at $6 \mu\text{m}$. A wide range of stains and histochemical procedures

(see Table 6.1), including tests for proteins, carbohydrates and lipids, was then applied. Details of these procedures are given in Pearse (1968) and Lillie & Fullmer (1976). In addition, integument samples from twenty-five hatchery-reared, juvenile brown trout (sampled in July and August 1978) were processed for electron microscopy. All fish used in this investigation were reared in ponds where Ichtyobodo infestations were known to have occurred; formalin treatment was applied prior to sampling in each case.

During a preliminary ultrastructural study, considerable difficulty had been experienced in achieving suitable fixation and staining of the skin for electron microscopy. Several variations of technique were tried and the following procedure was found to give the most satisfactory results. A small skin sample (1 mm³) was placed in 1 ml of 12% glutaraldehyde in 0.1 M sodium cacodylate buffer (pH 7.2) at room temperature and, after 3 minutes, 2 ml of 1% osmium tetroxide in cacodylate buffer was added to the same tube. The tissue was left to fix in this solution for a further 2 hours, and then rinsed in 15.2% sucrose in cacodylate buffer, dehydrated through a graded series of ethanol and embedded either directly in Spurr's resin or via propylene oxide in Epon. Semi-thin (0.5 µm) sections were etched with sodium ethoxide (Lane & Europa, 1965), stained with eosin, and examined by light microscopy in order to identify acidophilic cells. Adjacent thin sections were then used for electron microscopy. The sections were stained with a saturated solution of

uranyl acetate in 25% methanol, followed by lead citrate (Reynolds, 1963) diluted to 50% with methanol. Sections were examined with an AEI EM6B or a Corinth 500 electron microscope.

6.3. Results

The occurrence of acidophilic cells in salmonid epidermis

Examination of the skin samples with the light microscope revealed the presence of epidermal cells with a strong affinity for eosin (acidophilic) in at least some of the fish in the samples of the different taxa under investigation, with the exception of the hatchery-reared 0+ Atlantic salmon. Of the other hatchery-reared juvenile fish, acidophilic cells were first observed in the epidermis of 0+ sea trout sampled in June when infestations of Ichtyobodo were also recorded. In the 0+ rainbow trout, acidophilic cells were not observed in the May and June samples but were present in July when Ichtyobodo infestations were also first recorded; in the August sample acidophilic cells were still present but Ichtyobodo infestation was no longer evident. Acidophilic cells were present in the epidermal surface of the 0+ char sampled in May. In the Scandale Beck brown trout population (in which infestations of costiasis have never been recorded), acidophilic cells were seen in the epidermis of both sexes of sexually immature and mature fish in all the age classes (1+-7+) sampled. In the early part of the year acidophilic cells

were only observed in a proportion of the fish, but between July and September they were present in all fish sampled from this population, after which their abundance in the epidermis again decreased. Epidermal acidophilic cells were also present in all the fish (1+-5+) sampled in the other three streams, and appeared to be most abundant in the populations known to be infested with Ichtyobodo. Similarly, acidophilic cells were present in both the 1+ and older brown trout and the sexually mature char, sampled in Wise Ean Tarn and Windermere respectively.

Thus, although the proportion of fish in which they were observed and their density in the epidermis varied between sampling times, acidophilic cells are apparently a normal constituent of the epidermis in a variety of salmonids. Relatively few of these cells were observed in healthy individuals and they seemed to be most prevalent in hatchery-reared juvenile fish, particularly following outbreaks of costiasis when the abundance of superficial mucous cells had declined. In 0+ fish, acidophilic cells were most commonly recorded on the antero-ventral regions of the body, and on larger older fish (>1+) they were frequently observed in the epidermis overlying the postero-ventral margins of the scales.

Histology and histochemistry

The technique of examining preparations of whole skin fixed in formalin containing eosin provides information about the

presence or absence of superficial acidophilic cells, but does not allow the possibility of the presence of structurally different types of acidophilic cells to be examined. Only one type of acidophilic cell was in fact observed in O+ brown trout skin processed for ultrastructural investigation during this study, although choice of fixative influenced the structure as seen at the light microscope level. The acidophilic material appeared as a homogenous spherical mass after fixation in formalin whereas discrete acidophilic granules could be seen after Bouin's fixation. Roberts, Young & Milne (1971) have reported a similar differential effect of fixation for the eosinophilic granular cell in the epidermis of the plaice Pleuronectes platessa. The ultrastructural studies (see below) confirmed the granular nature of the contents of one type of acidophilic cell in juvenile brown trout.

Acidophilic granular cells (AGCs) were found throughout the epidermis of young brown trout with the exception of the basal layer. They appear to differentiate in the lower levels of the epidermis and increase in size in the more superficial layers (Fig. 6.1). At the epidermal surface, part of the plasma membrane was often exposed to the surface and, in formalin fixed whole mounts, this gave the impression of the presence of an apical pore. The spherical or oval mature cell has a basal nucleus and a supranuclear area containing numerous acidophilic granules. These granules appeared slightly yellowish and refractive in unstained sections under bright field illumination, but had a strong affinity for acid

Figure 6.1. Transverse section of brown trout epidermis. Note the numerous AGCs (arrowed) at different stages of development and the large mucus-secreting goblet cells (m). H&E. X 700.

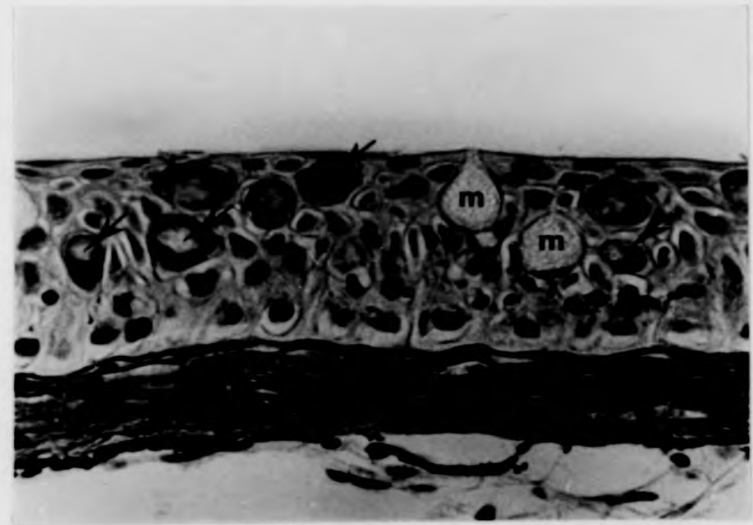


Figure 6.1.

Figure 6.1. Transverse section of brown trout epidermis. Note the numerous AGCs (arrowed) at different stages of development and the large mucus-secreting goblet cells (m). H&E. X 700.

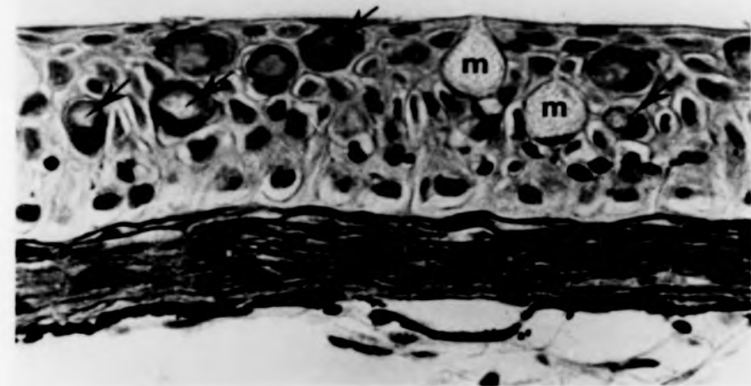


Figure 6.1.

dyes including Orange G, erythrosin and eosin. A comparison of the staining and histochemical properties of the contents of these AGCs and of the goblet mucous cells in the brown trout epidermis is shown in Table 6.1. The mucus-secreting goblet cells showed the characteristic histochemical responses of carbohydrate-containing mucosubstances to the PAS procedure, aldehyde fuchsin and Alcian blue. By comparison, the AGCs in this tissue normally gave negative reactions to these staining procedures (the slight pink coloration following the PAS reaction was thought to be non-specific because it occurred even without prior oxidation of the tissue), but were positive to Millon's test, the diazotization procedure and to mercury bromophenol blue. Considering these responses and the intense acidophilia of these cells, it is concluded that a major component of the presumed secretory product of this AGC is basic protein. The AGCs in brown trout epidermis also gave positive responses to Verhoeff's iron haematoxylin stain for elastin and to pyronin Y, although in the latter case prior RNA-ase digestion did not diminish the intensity of the staining. After fixation in Helly's fluid, a slight positive response of the AGCs to Sudan black B was noted, and this may indicate the presence of some lipid material.

Ultrastructure

Mature acidophilic cells in the brown trout epidermal tissue were typically 10-18 μm in diameter but occasionally were as

Staining procedure	To demonstrate	Fixative	Acidophilic granular cell	Mucus secreting goblet cell
Ehrlich's Acid Haematoxylin and Eosin	General histology	B, F, H, Z	Red	Unstained
Aldehyde Fuchsin with Orange G.	General histology	B, F	Orange	Purple
Mallory's Triple Stain	General histology	B	Orange/Red	Pale blue
Leishman's Stain	Blood cells	B, F, H	Pink	Very pale blue
Wright's Stain	Blood cells	B	Pink	Unstained
Clara's Dilute Haematoxylin	Blood eosinophils	F	Deep purple	Not present in sections
Toluidine Blue	Mast cells	F	Unstained	Not present in sections
Mercury-Bromophenol Blue	Protein	B, F, H	Blue	Unstained
Diazotization-coupling method	Tyrosine	B, F, H	Light purple	Unstained
Millon's Reaction	Tyrosine	B, F, H	Pink	Unstained
Sudan Black B	Lipids	H	Grey	Unstained
Verhoeff's Stain	Elastin	B	Black	Pale grey
Verhoeff's Stain saturated with urea	Inhibition of elastin staining	B	Unstained	Grey

Methyl Green/Pyronin Y	RNA	B	Red	Unstained
Methyl Green/Pyronin Y after incubation in RNA-ase	Digestion of RNA	B	Red	Unstained
Methyl Green/Pyronin Y after incubation in buffer	Control for RNA-ase	B	Red	Unstained
Periodic Acid-Schiff's Reaction (PAS)	Vicinal hydroxyl groups	B, F, H	Pink	Magenta
Schiff's reagent without prior oxidation	Free aldehydes	B, F	Pink	Unstained
PAS with prior amylase treatment	Control for glycogen	F	Pink	Magenta
Alcian Blue (pH 2.5)	Acidic mucopolysaccharides	B, F, H	Unstained	Blue
Alcian Blue (pH 2.5)/PAS	Acidic and neutral mucopolysaccharides	B, F, H	Pink or unstained	Magenta-Blue
Alcian Blue (pH 2.5)/Schiff's reagent without prior oxidation	Control for acidic and neutral mucopolysaccharides	B, F, H	Pink	Blue
Alcian Blue (pH 2.5)/PAS with prior amylase treatment	Control for acidic and neutral mucopolysaccharides	B, F, H	Pink	Magenta-Blue

Table 6.1. Staining reactions and histochemical responses of the secretory contents of the acidophilic granular cells and goblet cells in the epidermis of the brown trout.
Key to fixatives: B = Bouin's fluid; F = formalin (in phosphate buffer); H = Helly's fluid; Z = Zenker's fixative

large as 30 μm . The most prominent feature observed in these cells was an accumulation of membrane-bound granules (0.1-1.5 μm in diameter) in the supranuclear region (Fig. 6.2.a). These granules, formed by an active Golgi region (Fig. 6.2.b), appeared in some cells to change in electron density as they accumulated within the cell. Mitochondria were present in the cytoplasm around the apical and lateral margins of the nucleus, and a well-developed rough endoplasmic reticulum (RER), sometimes with dilated cisternae, was seen to occur in the perinuclear regions of the cell (Figs 6.2.a; 6.2.b). Desmosomal attachments were observed between AGCs and adjacent epidermal cells (Fig. 6.2.b), but these AGCs were not found to contain the large bundles of tonofilaments so characteristic of the Malpighian cells in teleost epidermis. At the epidermal surface a small aperture was often evident between adjacent superficial epidermal cells through which the apical cytoplasm of an AGC protruded (Fig. 6.3.a). Although no unequivocal evidence of granular secretion was obtained, the close proximity of the granules to the exposed cell membrane indicated that such a release is likely to occur (see Fig. 6.3.b). Unlike the mucus-secreting goblet cell, there appeared to be little fusion, if any, of adjacent secretory granules within the apical cytoplasm. Also, the displacement of organelles to the periphery in mature cells is less pronounced in this AGC as compared to the goblet cell.

Developing AGCs could be recognised in the deeper layers

Figure 6.2. Electron micrographs of AGCs in O+ brown trout epidermis. (a) A mature AGC with a basal nucleus, well-developed Golgi body and perinuclear RER; the secretory granules are accumulated in the supranuclear region of the cell. X 5750. (b) A desmosome (arrowed) between an AGC and an adjacent epidermal cell; granules (g) are formed in the Golgi region (Gr) of the AGC and abundant RER is present. X 30 000.

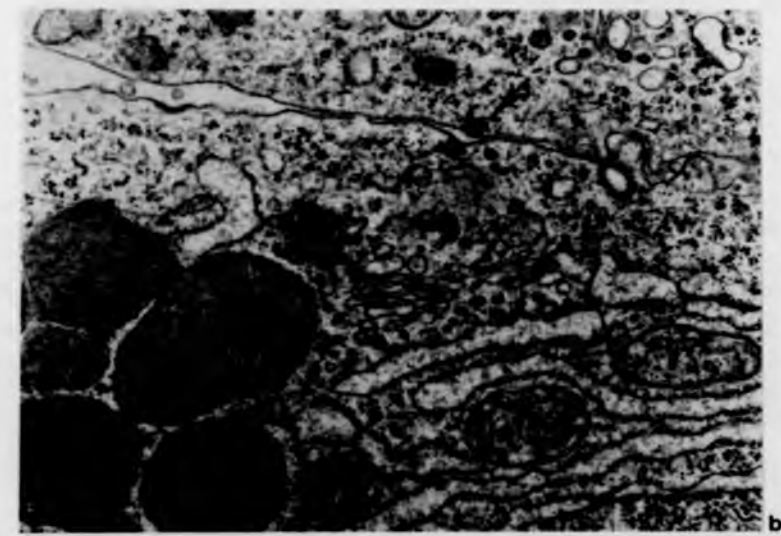


Figure 6.2.

Figure 6.2. Electron micrographs of AGCs in O+ brown trout epidermis. (a) A mature AGC with a basal nucleus, well-developed Golgi body and perinuclear RER; the secretory granules are accumulated in the supranuclear region of the cell. X 5750. (b) A desmosome (arrowed) between an AGC and an adjacent epidermal cell; granules (g) are formed in the Golgi region (Gr) of the AGC and abundant RER is present. X 30 000.

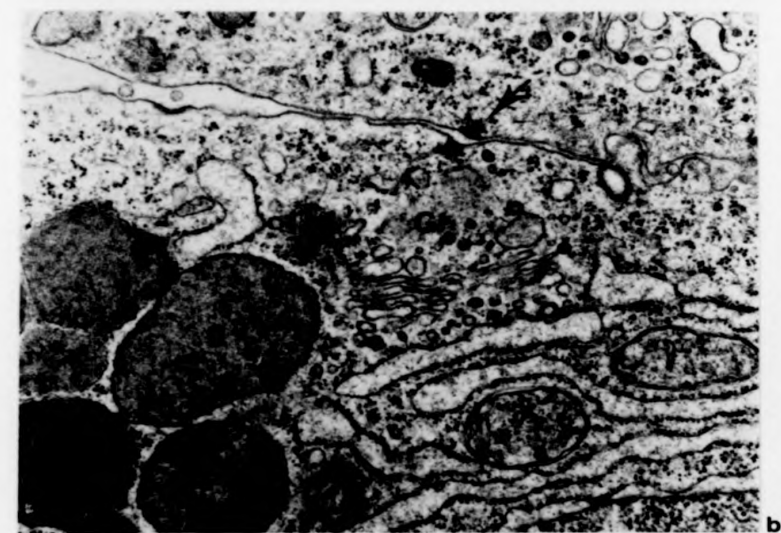
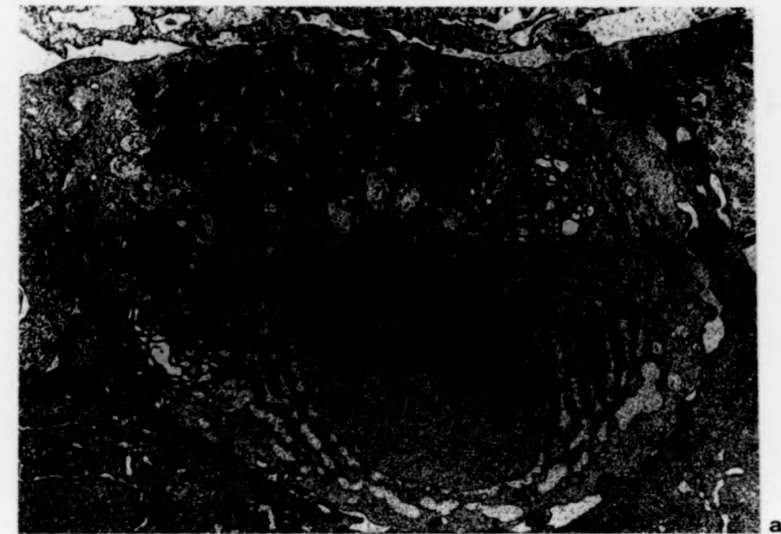


Figure 6.2.

Figure 6.3. Electron micrographs of AGCs in O+ brown trout epidermis. (a) AGC protruding between two superficial epidermal cells. X 5450. (b) Shows the close proximity of granules to the exposed cell membrane in a superficial AGC. X 47 200. (c) A developing AGC in the lower layers of the epidermis with abundant RER and a large nucleus with a prominent nucleolus. Granules in the process of formation can be seen in the very active and extensive Golgi region, and desmosomes are present between the AGC and adjacent epidermal cells. Part of a macrophage is visible in the lower section of the micrograph. X 9500.

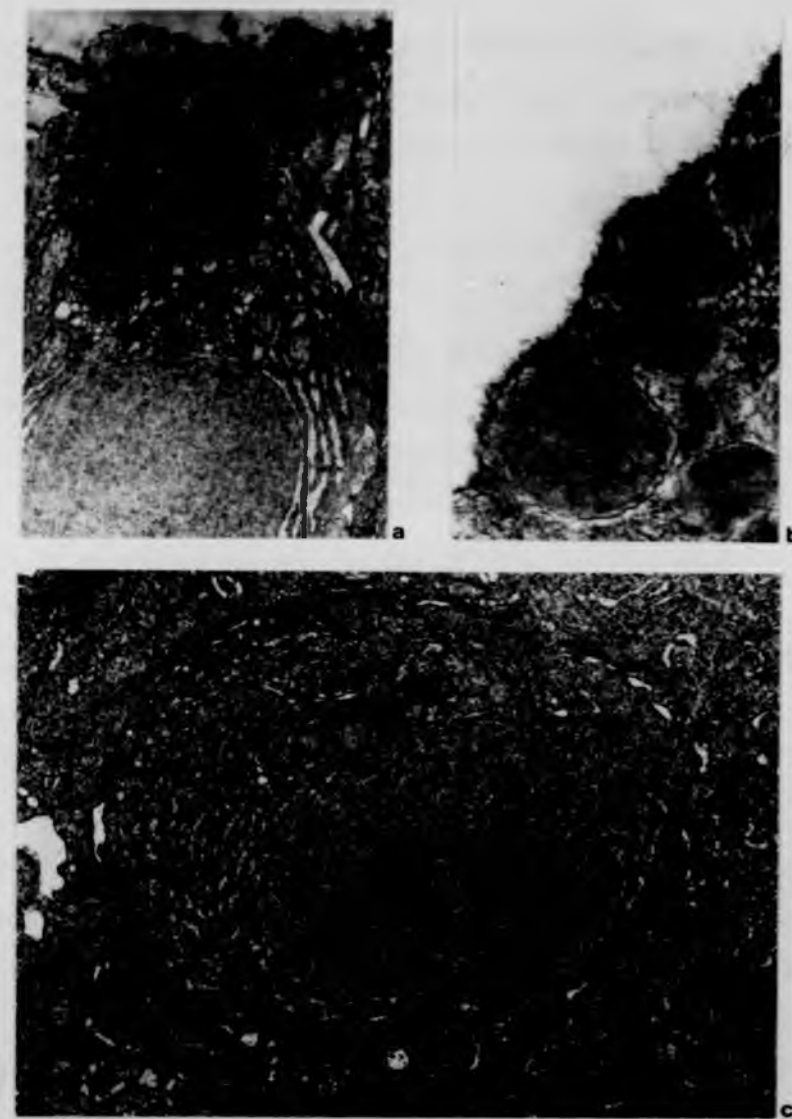


Figure 6.3.

Figure 6.3. Electron micrographs of AGCs in O+ brown trout epidermis. (a) AGC protruding between two superficial epidermal cells. X 5450. (b) Shows the close proximity of granules to the exposed cell membrane in a superficial AGC. X 47 200. (c) A developing AGC in the lower layers of the epidermis with abundant RER and a large nucleus with a prominent nucleolus. Granules in the process of formation can be seen in the very active and extensive Golgi region, and desmosomes are present between the AGC and adjacent epidermal cells. Part of a macrophage is visible in the lower section of the micrograph. X 9500.

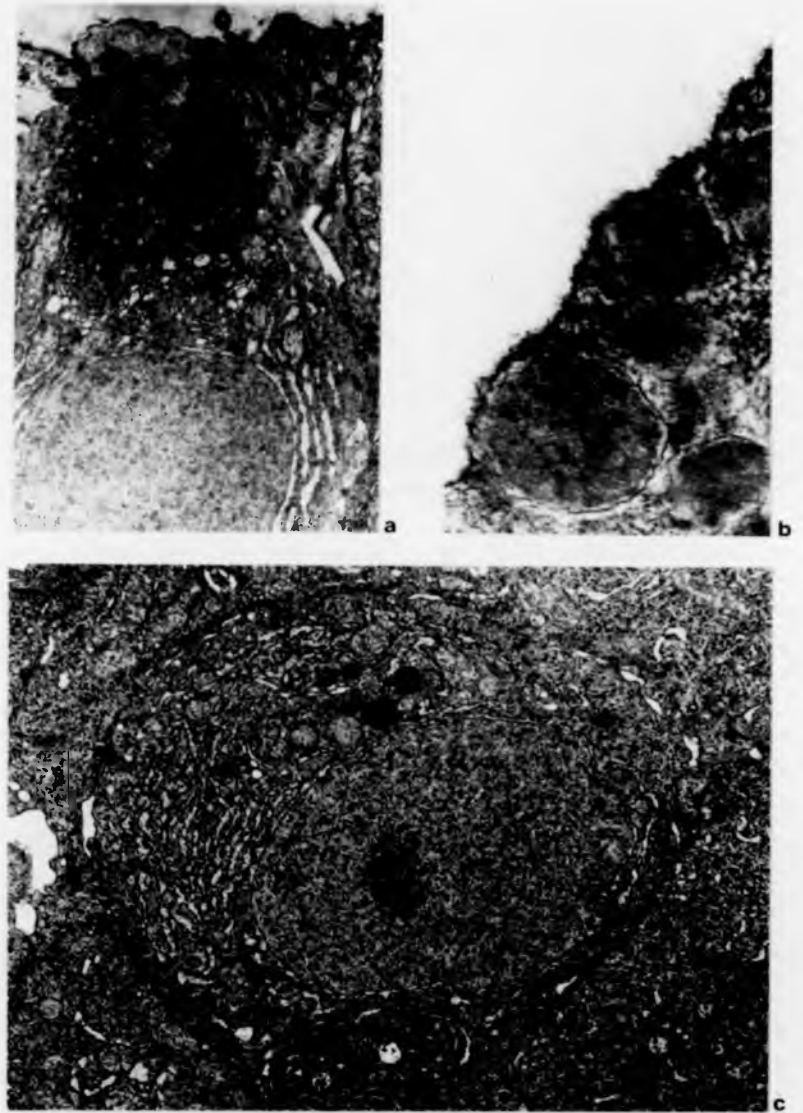


Figure 6.3.

of the epidermis and these were characterized by a large nucleus with a prominent nucleolus, abundant RER throughout the cytoplasm, occasional mitochondria and a very active supranuclear Golgi region. Granules in the process of formation by the Golgi apparatus were also observed (Fig. 6.3.c).

6.4 Discussion

Despite being long overlooked and uncharacterized, epidermal acidophilic cells appear to be a common feature of salmonid fish. They have been shown to exist in species from two genera, and also to be present in the epidermis of fish of various ages. Although they were undetected in Atlantic salmon during this investigation, examination of individuals at different stages of growth and from a greater range of populations is required before their absence in this species can be confirmed. Interestingly, another structural type of eosinophilic cell has recently been recognised in the epidermis of O+ brown trout (A.D. Pickering, pers. comm., 1980), but it is not known at this stage whether it occurs in other salmonid taxa.

The abundance of acidophilic cells appears to increase in salmonids affected by infestations of the ectoparasite Ichtyobodo, particularly in juvenile cultured fish. This is entirely consistent with the findings of earlier quantitative studies reported in Chapters 4 and 5 where, after the onset

of costiasis in O+ brown trout, a marked increase in acidophilic cell density in the epidermal surface was found to occur following an earlier depletion of goblet mucous cells; a similar response was also recorded in fish subjected to repeated formalin treatment.

Acidophilic cells have been observed in the epidermis of a wide range of fishes including South American and Asian freshwater teleosts (Bhatti, 1938; Mittal & Munshi, 1971; 1974; Mittal & Banerjee, 1975; 1976; Mittal, Agarwal & Banerjee, 1976; Mittal & Agarwal, 1977), marine flatfish (Roberts, Young & Milne, 1971; Bullock & Roberts, 1975), several members of the Cottidae (Sato, 1967), the ocean sunfish Mola mola (Logan & Odense, 1974), the selachian Torpedo ocellata Rafinesque (Celada & de Paoli, 1962), and several other marine species (Zaccone, 1979; 1980b; 1981). However, whilst all these cells have in common an affinity for acid dyes and a proteinaceous content (as found in those tested), there would appear to be considerable structural differences between some of them (see also Mittal, Whitear & Bullock, 1981). Since the functions of any of these cells have not been conclusively demonstrated it would be premature to speculate on possible homologies.

In the acidophilic granular cells of brown trout epidermis described here, the abundant RER, active Golgi region, accumulation of granules, increase in cell size with maturity, and the exposure of the apical cytoplasm at the epidermal surface in superficial cells, all suggest that this

cell type is secretory. It is not surprising, therefore, that some of these features are shared by the epidermal goblet cell. However, the results of various histochemical tests on the presumed secretory products of this AGC and the goblet mucous cell clearly show that the two cell types are quite distinct. It is of interest that an increase in abundance of acidophilic cells in O+ brown trout has been shown to be normally preceded by a decrease in superficial goblet cells and vice versa. This inverse relationship between acidophilic cell density and goblet cell density is not unique to brown trout but has been observed in the epidermis of other teleost species (Bhatti, 1938; Sato, 1967). Transformation of the goblet cell into another epidermal cell type (the chloride cell) is thought to occur in the guppy Poecilia reticulata (Schwerdtfeger & Bereiter-Hahn, 1978), and consequently an inter-conversion between the AGC and the goblet cell in brown trout epidermis would seem to be a possibility that should be considered. However, cells that could be regarded as intermediates between these two cell types were never identified during this study, and the available evidence indicates that the AGC develops from undifferentiated cells deep in the epidermis, often alongside recognisable, differentiating goblet cells.

In view of the positive staining reaction with Clara's dilute haematoxylin, which is known to stain the granules of human eosinophil leucocytes (Lillie & Fullmer, 1976), another possibility is that this AGC is a type of blood cell that has

migrated into the epidermis. It is certainly true that leucocytes can be fairly common between adjacent filament-containing cells in the suprabasal layers of the epidermis of brown trout (Pickering & Richards, 1980) and of other teleosts (Roberts & Bullock, 1980), and they have occasionally been seen passing through the basement membrane. Nevertheless, fully differentiated acidophilic cells were not observed passing through or adjacent to either side of the basement membrane during this work. Furthermore, eosinophilic granulocytes are not normally found in the peripheral blood of the brown trout (Blaxhall & Daisley, 1973), although they do occur in other fish species (see Ellis, 1977). The presence of desmosomal attachments between AGCs and adjacent epidermal cells is taken as further evidence that these AGCs are not invasive or transformed bloodcells, (desmosomes were not observed between lymphocytes and epidermal cells).

The results of histochemical tests suggest that basic protein is a major component of the presumed secretory content of this AGC in brown trout epidermis. The positive staining of the granules with Verhoeff's iron haematoxylin is usually thought to specifically indicate the presence of elastin (e.g. Brissie, Spicer, Hall & Thompson 1974). This finding is in agreement with that reported by Mittal & Agarwal (1977) for acidophilic cells in the epidermis of Monopterusuchia, and Zaccone (1979) for those in the marine teleost Muraena helena (L.). Mittal & Agarwal (1977) have suggested that elastin may alter the physical properties of

the mucous layer by increasing its viscosity, thereby protecting the fish more effectively against chemical damage. However, until elastin has been conclusively identified in the mucous layer of fish, this must remain a matter of speculation. It is unlikely that the positive response of the acidophilic granules to pyronin Y indicates the presence of appreciable amounts of RNA because the staining was equally intense after incubation with RNA-ase, whereas that of the nucleolus was considerably reduced after such treatment.

The function(s) of any of the acidophilic cells, other than chloride cells and sensory cells which are also eosinophilic, in the teleost epidermis have yet to be satisfactorily elucidated. A possible protective role as part of the defence mechanisms operative at the surface of the fish has been considered by Mittal & Munshi (1974) and Banerjee, Agarwal, Rai & Mittal (1976). In this respect it is interesting that as early as 1935, the toxicity of certain fish mucous secretions to ectoparasites was demonstrated (Nigrelli, 1935). More recently, the source of lysozyme, an enzyme with possible antibiotic activity, has been traced in the epidermis of plaice to subepidermal lymphocytes around the scale pockets (Murray & Fletcher 1976). Natural antibodies and bactericidins (St. Louis-Cormier, Osterland & Anderson, 1984) and immunoglobulins (e.g. Fletcher & Grant, 1969; Bradshaw, Richard & Sigel, 1971), have also been recognised in fish mucus, and so far the cellular sources of all of these molecules have not been discovered although immuno-

globulin-positive lymphocytes have recently been identified in rainbow trout epidermis (Peleteiro & Richards, 1985).

That the presence of large numbers of eosinophilic cells appears to be associated with irritation in juvenile brown trout epidermis, either by ectoparasitic infestation (Ichtyobodo) or by prolonged formalin treatment, is consistent with the observation noted by Bullock & Roberts (1975) that salmonid epidermal eosinophilic granular cells are more abundant under pathological conditions. Further work, aimed at establishing the exact biochemical nature of the protein content of the presumed secretory product of this acidophilic cell, is now needed in order to shed more light on its role in the epidermis.

Chapter 7

Concluding Remarks and Discussion

Much of the work reported in this thesis has been directly concerned with factors affecting the mucosal skin epithelium of brown trout Salmo trutta during the early stages of development. Adaptive seasonal changes in the structure of the epidermis, particularly with respect to its mucus-secreting potential, have been related to the different ecological conditions experienced by this species during the first year of life. Epidermal mucous cells are especially abundant in the benthic alevin and have been shown to decline in the free-swimming fry; the transition is also accompanied by histochemical changes of the mucin content of the cells. After this transitional phase young brown trout are particularly vulnerable to ectoparasitic infection, especially under artificial culture conditions. Skin disease can result in profound alterations in the structure of the epidermis as has been found with infestations of the ectoparasite Ichtyobodo; analogous effects were also observed with frequent formalin treatment. On the basis of these results and other published information, it has been suggested that there are generalized non-specific responses in the teleost epidermis to various forms of surface irritation.

There are only very few accounts in the literature of the long-term effects of superficial irritation on skin epithelia

in either salmonid or other teleost fish species (see Chapter 5). Parallel effects to some of those reported here have been observed in teleost alimentary mucosa (e.g. Gardner & Yevich, 1970; Srivastava & Srivastava, 1979; McDonough & Gleeson, 1981) and also in fish gills (e.g. Daye & Garside, 1976; Wedemeyer & Yasutake, 1974; Ellis & Wootten, 1978), but very much more is understood about the responses of mammalian mucus-secreting epithelia to irritation. Although less likely to be influenced by ambient temperature, there are interesting and noteworthy examples of the effects of surface irritation on mammalian mucosal systems which help to broaden the interpretation of observations on the teleost epidermis.

A major initial response observed in O+ brown trout epidermis to Ichtyobodo infestation was a sudden and immediate release of mucus from the surface goblet cells. Similar responses have been reported in the intestine of the common mummichog Fundulus heteroclitus (L.) exposed to cadmium (Gardner & Yevich, 1970), in rat intestine infected with the nematode Nippostrongylus (Levy & Frondosa, 1983) and in rabbit airway epithelium irritated with commercial soot after exposure to periods of synthetic smog (Falk, Kotin & Rowlette, 1963). The main benefit conferred on the stressed individual by an increased secretion of mucus would appear to be the prevention of direct contact with the irritant. If surface stress is short-lived, as with handling stress in fish (Pickering & Macey, 1977), or of relatively low intensity, e.g. weak formalin administration on cat trachea

(Florey, Carleton & Wells, 1932) and exposure of rat airway to low levels of tobacco smoke (Reid, 1970), goblet mucous cell hyperplasia in the epithelium can ensue. Increases in mucous cell abundance have also been reported in the epidermis surrounding the attachment sites of parasitic copepods in fish skin (Smith, 1975), in the epithelium around the penetration points of acanthocephalans in the intestine of the rainbow darter Etheostoma caeruleum (Storer) (McDonough & Gleeson, 1981) and in the transition zone between epidermal papillomata and normal epidermis in Atlantic salmon Salmo salar (Bylund, Valtonen & Niemalä, 1980). If the physiology of the mucosal epithelium is sufficiently unimpaired to allow continued production of mucus during irritation, a dynamic equilibrium may become established; the capacity for complete recovery and repair maintains the effectiveness of the protective mucoid layer (Schrager & Oates, 1978).

An increase in mucous cell abundance may also be accompanied by a change in the histochemistry of the mucous secretions. Such histochemical changes have been observed with human intestinal diseases such as ulcerative colitis and tumour of the colon (Reid, Culling, Dunn, Ramey & Clay, 1984), and also in cases of Crohn's disease of the ileum (Reid, Culling, Dunn & Clay, 1984), as well as in mammalian respiratory tracts inflamed by bronchitis or irritated by cigarette smoke or sulphur dioxide (Widdicombe, 1978). Usually, a change in the proportions of different types of mucopolysaccharide is involved rather than an alteration in

(Florey, Carleton & Wells, 1932) and exposure of rat airway to low levels of tobacco smoke (Reid, 1970), goblet mucous cell hyperplasia in the epithelium can ensue. Increases in mucous cell abundance have also been reported in the epidermis surrounding the attachment sites of parasitic copepods in fish skin (Smith, 1975), in the epithelium around the penetration points of acanthocephalans in the intestine of the rainbow darter Etheostoma caeruleum (Storer) (McDonough & Gleeson, 1981) and in the transition zone between epidermal papillomata and normal epidermis in Atlantic salmon Salmo salar (Bylund, Valtonen & Niemalä, 1980). If the physiology of the mucosal epithelium is sufficiently unimpaired to allow continued production of mucus during irritation, a dynamic equilibrium may become established; the capacity for complete recovery and repair maintains the effectiveness of the protective mucoid layer (Schrager & Oates, 1978).

An increase in mucous cell abundance may also be accompanied by a change in the histochemistry of the mucous secretions. Such histochemical changes have been observed with human intestinal diseases such as ulcerative colitis and tumour of the colon (Reid, Culling, Dunn, Ramey & Clay, 1984), and also in cases of Crohn's disease of the ileum (Reid, Culling, Dunn & Clay, 1984), as well as in mammalian respiratory tracts inflamed by bronchitis or irritated by cigarette smoke or sulphur dioxide (Widdicombe, 1978). Usually, a change in the proportions of different types of mucopolysaccharide is involved rather than an alteration in

the basic constituents of the mucus; the production of acidic relative to neutral mucins is increased, and there is also a greater proportion of sulphated than sialated mucins. In mammals, a shift in the balance towards enhanced levels of acid mucins frequently coincides with an increase in the viscosity of the mucus (Solanki & Benjamin, 1982). Interestingly, Kollerstrom, Lord & Whimster (1977) have shown that there is not only a higher ratio of sulphated to sialated mucus in the respiratory tract of human smokers compared to non-smokers, but also that in both cases the ratio decreases in the bronchioles with distance from the trachea. The latter graded response could be due to the diminishing effects of irritants, but could also reflect a requirement for mucus of different rheological properties in airways of decreasing radii. In the present investigation, changes in epidermal mucous cell density together with changes in mucous cell histochemistry in juvenile brown trout, involving a transformation from sulphated to a greater proportion of sialated mucins, were correlated with the requirement for protection against abrasion from gravel in the early benthic stages of growth followed by the need for effective lubrication in the free-swimming fry. Histochemical changes in the mucin content of epidermal goblet cells during development have also been reported in plaice Pleuronectes platessa (Roberts, Bell & Young, 1973) and in rainbow trout Salmo gairdneri (Porcelli & Massari, 1969), but in general little is known about the variability of the constituents of

fish mucus. Jirge (1971) has shown that goblet cell abundance in the intestinal epithelium of larval Sarotherodon mossambicus (Peters) increases with age, and that there is a concomitant increase in neutral and sialated but not sulphated mucoglycoproteins; this was related to the need for lubrication to effect the passage of undigested cellulose along the gut. Through the use of surrogate artificial anemones, Brooks & Mariscal (1984) have shown that the anemone fish Amphipron clarkii (Bennett) can acquire resistance, through presumed alterations in its mucous coat triggered by physical or visual stimuli, to the cnidae of its sea anemone host. However, histochemical responses in the epidermal mucous cells of fish to either pathogenic agents or chemical irritants have not been investigated.

In cases of chronic and/or severe irritation, hyperplasia of epithelial cells is often initiated and mucous cells become increasingly infrequent or absent; this negative correlation between Malpighian cell hyperplasia and mucous cell abundance is known to be a general feature of the mucus-secreting epithelia in various groups of vertebrates (Roberts & Bullock, 1976; Parke, 1978). It has been observed in Atlantic salmon alevins heavily infested with the ectoparasite Ichtyobodo by Robertson, Roberts & Bullock (1981), and also in juvenile brown trout suffering from chronic costiasis or subjected to repeated formalin treatment (as reported in Chapter 5); a similar response has also been shown to occur in the mirror carp Cyprinus carpio affected by

ichthyophthiriasis by Hines & Spira (1974). Examples from mammals where similar features have been reported include rat respiratory epithelium subjected to high levels of tobacco smoke (Reid, 1970), cat trachea following administration of large doses of formalin (Florey, Carleton & Wells, 1932), humans in the advanced stages of progressive or recurrent pulmonary disease (Tappan & Zalar, 1963) and mammalian gastric mucosae in response to drugs such as aspirin and irritants including alcohol, chilli powder and chewed tobacco (Parke, 1978).

Localized sloughing of epithelial tissue is frequently one of the final responses to very severe and prolonged irritation. Under pathological conditions, epidermal sloughing in teleost fishes has been reported in cases of intense parasitic infestation including costiasis (Robertson, Roberts & Bullock, 1981; see also Chapter 5), ichthyophthiriasis (Hines & Spira, 1974) and chilodonellasis (Rogers & Gaines, 1975). Sloughing has also been observed in salmonid skin due to exposure to UV-A after oral administration of phenothiazine, a recognised photosensitising compound (Bullock & Roberts, 1979; Bullock, 1982), and with ulcerative dermal necrosis (Roberts, Shearer, Munro & Elson, 1970). Under conditions of severe pH stress, sloughing in the gills and skin of the brook trout Salvelinus fontinalis (Mitchill) has been reported by Daye & Garside (1976), and similar features have been observed by Falk, Kotin & Rowlette (1963) in the respiratory tract of rabbits following prolonged exposure to

commercial soot.

Thus there appears to be a number of common responses in a variety of vertebrate mucus-secreting epithelia to a range of biological, physical and chemical irritants. An initial increase in mucous secretion from existing goblet cells, which in some cases is followed by a temporary acceleration in the production of new mucous cells, can be accompanied by chemical changes in the mucosubstances. If severe irritation continues, the epithelium often becomes hyperplastic and its mucus-producing capacity reduced; patchy sloughing of highly stressed areas can then ensue. The occurrence of all these apparently non-specific responses clearly depends on the severity and duration of the stress factor; the common function throughout is to provide protection for the underlying tissues from direct damage.

Mammalian mucus is also known to contain biologically active molecules, some of which, e.g. lysozyme and secretory IgA in tracheobronchial secretions, are believed to be synthesized locally and protect the mucosa against infection (Roberts, 1978). Studies of fish diseases suggest that fish tissue is capable of responding to pathogenic agents in much the same way as that of mammals except, that is, in the production of a true purulent response (Wolke, 1975). The external mucous layer of fish skin has been found to contain natural antibodies, bactericidins and lysozyme; it is also very likely that an additional, inducible antibody (IgM-like) defence system, which is activated by the presence of anti-

bodies, operates at this level so providing fish, like mammals, with a secretory immune system in conjunction with the circulating Ig system (St. Louis-Cormier, Osterland & Anderson, 1984). In humans it is additionally known that the presence of immunoglobulins can alter the rheological properties of mucus by cross-linkage with glycoproteins (Puchelle, Zahm & Aug, 1981). In fishes, rheological investigations of mucus have been extremely limited and the possible interrelationships between mucous viscosity and superficial stress are unknown.

In common with many vertebrate epithelial mucosae, the teleost epidermis with its associated mucous layer thus appears to operate as both a physically dynamic and chemically active protective barrier. However, it is clear that far more work is required on the relationship between these distinct but complementary roles, and in particular on the precise location of the origin of the biologically active proteins in the epidermis. During the present study, a proteinaceous acidophilic granular cell (AGC) was found to markedly increase in abundance in the epidermis of juvenile brown trout suffering from chronic costiasis or exposed to frequent treatment with formalin; this increase was generally preceded by a depletion in the numbers of epidermal goblet cells. Amongst the integumental glands of vertebrates there are two basic cell lines, a mucous cell stem line and a proteinaceous cell stem line (Quay, 1972). The functional role of the brown trout epidermal AGC is yet to be fully

elucidated, but it is almost certainly secretory and does share certain of the features of other granule-containing cells in mammalian epithelia which are also associated with pathological conditions. One such cell present in mammalian mucosae, e.g. respiratory epithelia, is the globule leucocyte. It has been suggested that this cell type, which is currently thought to be derived from mucosal mast cells (Huntley, Newlands & Millar, 1984), is a source of immunoglobulins but this has yet to be fully confirmed (Vandenbergh & Baert, 1981). Globule leucocytes have been reported from a variety of animals although it is not known whether all the cells described as such are in fact homologous (Gregory, 1979). Salmonid 'globule leucocytes' have been detected in the intestine of brook trout infected with acanthocephalans (Bullock, 1967), but the mammalian globule leucocyte differs from the brown trout epidermal AGC in not forming desmosomal attachments with neighbouring Malpighian cells. Another secretory proteinaceous acidophilic granular cell present in mammalian alimentary tracts is Paneth's cell which is also known to increase in quantity in association with disease. The secretory granules of this cell contain lysozyme, and it has been shown that in disease-free rats the granules are 'autophagocytized' by lysosomes also present in the cells (Satoh, 1984). Although the brown trout epidermal AGC has certain characteristics in common with both globule leucocytes and Paneth's cells, i.e. its contents are eosinophilic, proteinaceous and granular, information on its enzyme

histochemistry is needed before further inferences can be drawn concerning a possible protective function.

Mucous secretions in fishes have also long been known to be influenced by hormonal factors. Artificially increased levels of prolactin have been shown to cause an increase in epidermal mucous cell density, e.g. in seawater adapted euryhaline fish (e.g. Mattheij & Stroband, 1971), and it would seem possible that a winter reduction in mucification in the winter flounder Pseudopleuronectes americanus as found by Burton & Fletcher (1983), may also be under control of this hormone since there is evidence that prolactin decreases over winter in freshwater fish (Ogawa, 1970). However, the winter decline in superficial epidermal mucous cells in sexually mature male brown trout, reported by Pickering (1977), has recently been shown to be correlated with elevated androgen levels by Pottinger & Pickering (1985a) who also observed a reduction in mucification in immature brown trout after intraperitoneal implantation of 11-ketotestosterone (Pottinger & Pickering, 1985b). Gona (1981) has shown that prolactin can initiate a mucification response in rat ileum, and she was further able to demonstrate that it can affect the histochemistry of mucus, causing a decrease in the proportion of sulphated mucins in this case. The influence of prolactin and other hormonal factors on the chemical composition of fish mucus has not been investigated. However, Olivereau & Lemoine (1971a; b) measured a reduction in sialic acid concentration in the skin of the European eel Anquilla anquilla following

hypophysectomy; this decrease was prevented by injection of ovine prolactin or by autotransplantation of the pituitary gland into the dorsal muscle. They suggested that the reduction in the concentration of sialic acid reflected a decrease in mucous production, but the possibility of a change in mucous cell chemistry was not considered. It would be interesting to test the effects of hypophysectomy and prolactin administration on the epidermal changes that are associated with emergence in young brown trout and also those caused by parasitic infestation and chemical irritation.

In view of the importance of the protective functions of epithelial mucosae, it is not surprising that far more is known about their properties in humans and other mammals than in other groups. However, with the recent and increasing development of fish farming as a source of protein, an understanding of the structure and function of the primary barrier between the fish and its environment is clearly desirable in the interests of maximizing productivity. The work reported here on the epidermis of juvenile brown trout has not only provided further insight into the pathogenic effects of a common and troublesome disease, but has also shown that the pathological responses to disease are mimicked in many respects by those stimulated through the administration of a prophylactic chemical that is in widespread use.

References

- Albanese Carmignani, M.P. & Zaccone, G. (1975). Histochemical analysis of epidermal cells and mucous cells in the skin of Torpedo ocellata Rafinesque. Acta histochem. **52**, 100-110.
- Archer, G.C. (1979). The skin and mucous secretion of the European eel, Anguilla anguilla L. Ph. D. Thesis, Plymouth Polytechnic, England.
- Banerjee, T.K., Agarwal, S.K., Rai, A.K. & Mittal, A.K. (1976). Histochemical localization of alkaline phosphatase, acid phosphatase, and succinic dehydrogenase activities in the epidermis of the freshwater teleost, Amphipnous cuchia (Hamilton) (Symbranchiformes, Pisces). Mikroskopie **32**, 294-300.
- Becker, C.D. (1977). Flagellate parasites of fish. In Kreier, J.P., ed. Parasitic Protozoa, Vol. 1, pp. 358-412. Academic Press, London.
- Beitinger, T.L. & Magnuson, J.J. (1975). Influence of social rank and size on thermoselection behavior of bluegill (Lepomis macrochirus). J. Fish. Res. Bd Can. **32**, 2133-2136.
- Bell, G.M. & Hoar, W.S. (1950). Some effects of ultraviolet radiation on sockeye salmon eggs and alevins. Can. J. Res. **D28H**, 35-43.
- Bhatti, H.K. (1938). The integument and dermal skeleton of Siluroidea. Trans. zool. Soc. Lond. **24**, 1-102.

- Blackstock, N. & Pickering, A.D. (1980). Acidophilic granular cells in the epidermis of the brown trout, Salmo trutta L. Cell Tiss. Res. **210**, 359-369.
- Blackstock, N. & Pickering, A.D. (1982). Changes in the concentration and histochemistry of epidermal mucous cells during the alevin and fry stages of the brown trout Salmo trutta. J. Zool., Lond. **197**, 463-471.
- Blaxhall, P.C. & Daisley, K.W. (1973). Routine haematological methods for use with fish blood. J. Fish Biol. **5**, 771-781.
- Bradshaw, C.M., Richard, A.S. & Sigel, M.M. (1971). IgM antibodies in fish mucus. Proc. Soc. exp. Biol. Med. **136**, 1122-1124.
- Brissie, R.M., Spicer, S.S., Hall, B.J. & Thompson, N.T. (1974). Ultrastructural staining of thin sections with iron hematoxylin. J. Histochem. Cytochem. **22**, 895-907.
- Brooks, W.R. & Mariscal, R.N. (1984). The acclimation of anemone fishes to sea anemones : protection by changes in the fish's mucous coat. J. Exp. Mar. Biol. Ecol. **81**, 277-285.
- Brown, M.E. (1946a). The growth of brown trout (Salmo trutta Linn.). I. Factors influencing the growth of trout fry. J. Exp. Biol. **22**, 118-129.
- Brown, M.E. (1946b). The growth of brown trout (Salmo trutta Linn.). II. The growth of two-year-old trout at a constant temperature of 11.5°C. J. Exp. Biol. **22**, 130-144.

- Bullock, A.M. (1982). The pathological effects of ultraviolet radiation on the epidermis of teleost fish with reference to the solar radiation effect in higher animals. Proc. R. Soc. Edimb. **81B**, 199-210.
- Bullock, A.M., Marks, R. & Roberts, R.J. (1978). The cell kinetics of teleost fish epidermis: mitotic activity of the normal epidermis at varying temperatures in plaice (Pleuronectes platessa). J. Zool., Lond. **184**, 423-428.
- Bullock, A.M. & Roberts, R.J. (1975). The dermatology of marine teleost fish. I. The normal integument. Oceanogr. Mar. Biol. Ann. Rev. **13**, 383-411.
- Bullock, A.M. & Roberts, R.J. (1979). Skin photosensitisation by phenothiazine in cultured rainbow trout (Salmo gairdneri Richardson). Vet Rec. **104**, 55.
- Bullock, A.M. & Roberts, R.J. (1981). Sunburn lesions in salmonid fry: a clinical and histological report. J. Fish Dis. **4**, 271-275.
- Bullock, A.M., Roberts, R.J. & Gordon, J.D.M. (1976). A study on the structure of the whiting integument (Merlangius merlangus L.). J. mar. biol. Ass. U.K. **56**, 213-226.
- Bullock, A.M. & Robertson, D.A. (1982). A note on the occurrence of Ichtyobodo necator (Henneguy, 1883) in a wild population of juvenile plaice, Pleuronectes platessa L. J. Fish Dis. **5**, 531-533.
- Bullock, W.L. (1967). Intestinal histology of some salmonid fishes with particular reference to the histopathology of acanthocephalan infections. J. Morph. **112**, 23-35.

- Burrows, R.E. (1964). Effects of accumulated excretory products on hatchery-reared salmonids. U.S. Bur. Sport Fish. Wildlife Serv., Res. Rep. 66, 1-12.
- Burton, D. & Fletcher, G.L. (1983). Seasonal changes in the epidermis of the winter flounder, Pseudopleuronectes americanus. J. mar. biol. Ass. U.K. **63**, 273-287.
- Bylund, G., Valtonen, E.T. & Niemelä, E. (1980). Observations on epidermal papillomata in wild and cultured Atlantic salmon Salmo salar L. in Finland. J. Fish Dis. **3**, 525-528.
- Celada, M. & De Paoli, A.M. (1962). Contributo alla conoscenza delle cellule albuminose (Schneider) cutanee di Torpedo ocellata Raf. Riv. Istochim. norm. Path. **8**, 411-416.
- Cone, D.K. & Wiles, M. (1984). Ichtyobodo necator (Henneguy, 1883) from winter flounder, Pseudopleuronectes americanus (Walbaum), in the north-west Atlantic Ocean. J. Fish Dis. **7**, 87-89.
- Daniel, T.L. (1981). Fish mucus: in situ measurements of polymer drag reduction. Biol. Bull. **160**, 376-382.
- Davis, H.S. (1943). A new polymastigine flagellate, Costia pyriformis, parasitic on trout. J. Parasitol. **29**, 385-386.
- Daye, P.G. & Garside, E.T. (1976). Histopathologic changes in surficial tissues of brook trout, Salvelinus fontinalis (Mitchill), exposed to acute and chronic levels of pH. Can. J. Zool. **54**, 2140-2155.

- Daye, P.G. & Garside, E.T. (1980). Structural alterations in embryos and alevins of the Atlantic salmon, Salmo salar L., induced by continuous or short-term exposure to acidic levels of pH. Can. J. Zool. **58**, 27-43.
- Elliott, J.M. (1977). Some methods for the statistical analysis of samples of benthic invertebrates. Scient. Publs Freshwat. biol. Ass. No. **25**, 2nd edn.
- Ellis, A.E. (1977). The leucocytes of fish: a review. J. Fish Biol. **11**, 453-491.
- Ellis, A.E. & Wootten, R. (1978). Costiasis of Atlantic salmon, Salmo salar L. smolts in seawater. J. Fish Dis. **1**, 389-393.
- Ewen, A.B. (1962). An improved aldehyde fuchsin staining technique for neurosecretory products in insects. Trans. Am. Microsc. Soc. **81**, 94-96.
- Falk, H.L., Kotin, P. & Rowlette, W. (1963). The response of mucus-secreting epithelium and mucus to irritants. Ann. N. Y. Acad. Sci. **106**, 583-603.
- Ferri, S., Stipp, A.C.M., Sesso, A. & Correa, H. (1977). Ultrastructure of the epidermal cells of the teleost Pimelodus maculatus Lacépède, 1803 (Pisces). Anat. Anz. **141**, 345-363.
- Fish, F.F. (1940a). Notes on Costia necatrix. Trans. Am. Fish. Soc. **70**, 441-445.
- Fish, F.F. (1940b). A report on the prevention and control of Costia necatrix. Prog. Fish-Cult. **48**, 1-10.

- Fishelson, L. (1972). Histology and ultrastructure of the skin of Lepadichthys lineatus (Gobiesocidae: Teleostei). Mar. Biol. **17**, 357-364.
- Fletcher, T.C. (1978). Defence mechanisms in fish. In Malins, D.C. & Sargent, J.R., eds. Biochemical and biophysical perspectives in biology, Vol. IV, pp.189-222. Academic Press, London.
- Fletcher, T.C. & Grant, P.T. (1969). Immunoglobulins in the serum and mucus of the plaice (Pleuronectes platessa). Biochem. J. **115**, 65p.
- Fletcher, T.C., Jones, R. & Reid, L. (1976). Identification of glycoproteins in goblet cells of epidermis and gill of plaice (Pleuronectes platessa L.), flounder (Platichthys flesus (L.)) and rainbow trout (Salmo gairdneri Richardson). Histochem. J. **8**, 597-608.
- Fletcher, T.C. & White, A. (1973). Lysozyme activity in the plaice (Pleuronectes platessa L.). Experientia **29**, 1283-1285.
- Florey, H., Carleton, H.M. & Wells, A.Q. (1932). Mucus secretion in the trachea. Br. J. Exp. Path. **13**, 269-284.
- Gardner, G.R. & Yevich, P.P. (1970). Histological and hematological responses of an estuarine teleost to cadmium. J. Fish. Res. Board. Can. **27**, 2185-2196.
- Gona, O. (1979). Mucous glycoproteins of teleostean fish: a comparative histochemical study. Histochem. J. **11**, 709-718.

- Gona, O. (1981). Prolactin and ergocryptine effects on mucus glycoproteins of the rat ileum. Histochem. J. **13**, 101-107.
- Grassé, P.P. (1952). Zooflagellés de position systématique incertaine. In Grassé, P.P., ed. Traité de Zoologie, Tome I, pp. 1005-1022. Masson, Paris.
- Gregory, M.W. (1979). The globule leucocyte and parasitic infection- a brief history. Vet. Bull., Weybridge **49**, 821-827.
- Haensly, W.F., Neff, J.M., Sharp, J.R., Morris, A.C., Bedgood, M.F. & Boem, P.D. (1982). Histopathology of Pleuronectes platessa L. from Aber Wrac'h and Aber Benoit, Brittany, France: long-term effects of the Amoco Cadiz crude oil spill. J. Fish Dis. **5**, 365-391.
- Harris, J.E. & Hunt, S. (1973). Epithelial mucins of the Atlantic salmon (Salmo salar L.) Trans. Biochem. Soc. **1**, 98-100.
- Harris, J.E. & Hunt, S. (1975a). The fine structure of the epidermis of two species of salmonid fish, the Atlantic salmon (Salmo salar L.) and the brown trout (Salmo trutta L.). I. General organization and filament-containing cells. Cell Tiss. Res. **157**, 553-565.
- Harris, J.E. & Hunt, S. (1975b). The fine structure of the epidermis of two species of salmonid fish, the Atlantic salmon (Salmo salar L.) and the brown trout (Salmo trutta L.). II. Mucous cells. Cell Tiss. Res. **163**, 535-543.

- Harris, J.E., Watson, A. & Hunt, S. (1973). Histochemical analysis of mucous cells in the epidermis of brown trout Salmo trutta L. J. Fish Biol. **5**, 345-351.
- Hawkes, J.W. (1974). The structure of fish skin. I. General organization. Cell Tiss. Res. **149**, 147-158.
- Henneguy, L.F. (1883). Sur un infusoire flagellé ectoparasite des poissons. C. R. Acad. Sci. **96**, 658-660.
- Henneguy, L.F. (1884). Sur un infusoire flagellé ectoparasite de la truite. Arch. Zool. Exp. Gen. 2e, série, **2**, 403-411.
- Henrikson, R.C. (1967). Incorporation of tritiated thymidine by teleost epidermal cells. Experientia **23**, 357-358.
- Henrikson, R.C. & Matoltsy, A.G. (1968a). The fine structure of teleost epidermis. I. Introduction and filament-containing cells. J. Ultrastruct. Res. **21**, 194-212.
- Henrikson, R.C. & Matoltsy, A.G. (1968b). The fine structure of teleost epidermis. II. Mucous cells. J. Ultrastruct. Res. **21**, 213-221.
- Henrikson, R.C. & Matoltsy, A.G. (1968c). The fine structure of teleost epidermis. III. Club cells and other cell types. J. Ultrastruct. Res. **21**, 222-232.
- Hines, R.S. & Spira, D.T. (1974). Ichthyophthiriasis in the mirror carp Cyprinus carpio (L.). III. Pathology. J. Fish Biol. **6**, 189-196.
- Hoffman, G.L. (1978). Ciliates of freshwater fishes. In Kreier, J.P., ed. Parasitic Protozoa, Vol. II, pp. 583-632. Academic Press, London.

- Hoyt, J.W. (1975). Hydrodynamic drag reduction due to fish slimes. In Wu, T.V.T., Brokaw, C.J. & Brennon, C., eds. Swimming and flying in nature, pp. 653-672. Plenum Press, New York.
- Huntley, J.F., Newlands, G. & Millar, H.R.P. (1984). The isolation and characterization of globule leucocytes: their derivation from mucosal mast cells in parasitized sheep. Parasit. Immunol. **6**, 371-390.
- Jakowska, S. (1963). Mucous secretion in fish- a note. Ann. N. Y. Acad. Sci. **106**, 458-462.
- Jirge, S.K. (1971). Histochemical investigations on the goblet cells of tilapian larvae during development. Studies on goblet cells. Acta histochem. **39**, 43-48.
- Jones, R., Bolduc, P. & Reid, L. (1973). Goblet cell glycoprotein and tracheal gland hypertrophy in rat airways: the effect of tobacco smoke with or without the anti-inflammatory agent phenylmethyloxadiazole. Br. J. exp. Path. **54**, 229-239.
- Jones, R. & Reid, L. (1973). The effect of pH on Alcian blue staining of epithelial acid glycoproteins. I. Sialomucins and sulphomucins (singly or in simple combinations). Histochem. J. **5**, 9-18.
- Joyon, L. & Lom, J. (1966). Sur l'ultrastructure de Costia necatrix Leclercq (Zooflagellé); place systématique de ce Protiste. C. R. Acad. Sci. Série, D, **262**, 660-663.

- Joyon, L. & Lom, J. (1969). Etude cytologique, systématique et pathologique d'Ichtyobodo necator (Henneguy, 1883) Pinto, 1928 (Zooflagelle). J. Protozool. **16**, 703-719.
- Keal, E.E. (1971). Biochemistry and rheology of sputum in asthma. Postgrad. Med. J. **47**, 171-177.
- Kollerstrom, N., Lord, P.W. & Whimster, W.F. (1977). A difference in the composition of bronchial mucus between smokers and non-smokers. Thorax **32**, 155-159.
- Lane, B.P. & Europa, D.L. (1965). Differential staining of ultrathin sections of epon-embedded tissue for light microscopy. J. Histochem. Cytochem. **13**, 579-582.
- Léger, L. (1909). La costiaie et son traitement chez les jeunes alevins de truite. C. R. Acad. Sci. **148**, 1284-1286.
- Leonard, J.B. & Summers, R.G. (1976). The ultrastructure of the integument of the American eel, Anquilla rostrata. Cell Tiss. Res. **171**, 1-30.
- Lester, R.J.G. & Adams, J.R. (1974). Gyrodactylus alexanderi: reproduction, mortality, and effect on its host Gasterosteus aculeatus. Can. J. Zool. **52**, 827-833.
- Lev, R. & Spicer, S.S. (1964). Specific staining of sulphate groups with Alcian blue at low pH. J. Histochem. Cytochem. **12**, 309.
- Levy, D.A. & Frondosa, C. (1983). Immunity to intestinal parasites: role of mast cells and goblet cells. Federation Proc. **42**, 1750-1755.

- Lillie, R.D. & Fullmer, H.M. (1976). Histopathologic technic and practical histochemistry, 4th edn. McGraw-hill, New York.
- Logan, V.H. & Odense, P.H. (1974). The integument of the ocean sunfish (Mola mola L.) (Plectognathi) with observations on the lesions from two ectoparasites, Capsala martinieri (Trematoda) and Philorthagoriscus serratus (Copepoda). Can. J. Zool. **52**, 1039-1045.
- Lopez-Vidriero, M.T., Jones, R., Reid, L. & Fletcher, T.C. (1980). Analysis of skin mucus of plaice Pleuronectes platessa L. J. comp. Path. **90**, 415-420.
- Mackereth, F.J.H. (1963). Some methods of water analysis for limnologists. Scient. Publs Freshwat. biol. Ass. No. **21**.
- Mackereth, F.J.H., Heron, J. & Talling, J.F. (1978). Water analysis: some revised methods for limnologists. Scient. Publs Freshwat. biol. Ass. No. **36**.
- Mattheij, J.A.M. & Stroband, H.W.J. (1971). The effects of osmotic experiments and prolactin on the mucous cells in the skin and the ionocytes in the gills of the teleost Cichlasoma biocellatum. Z. Zellforsch. **121**, 93-101.
- McDonough, J.M. & Gleeson, L.N. (1981). Histopathology in the rainbow darter, Etheostoma caeruleum, resulting from infections with the acanthocephalans, Pomphorhynchus bulbocolli and Acanthocephalus dirus. J. Parasitol. **67**, 403-409.

- Meyers, T.R., Millemann, R.E. & Fustish, C.A. (1980). Glochidiosis of salmonid fishes. IV. Humoral and tissue responses of coho and chinook salmon to experimental infection with Margaritifera margaritifera (L.) (Plecypoda: Margaritanidae). J. Parasitol. **66**, 274-281.
- Mittal, A.K. & Agarwal, S.K. (1977). Histochemistry of the unicellular glands in relation to their physiological significance in the epidermis of Monopterusuchia (Synbranchiformes, Pisces). J. Zool., Lond. **182**, 429-439.
- Mittal, A.K., Agarwal, S.K. & Banerjee, T.K. (1976). Protein and carbohydrate histochemistry in relation to the keratinization in the epidermis of Barbus sophor (Cyprinidae, Pisces). J. Zool., Lond. **179**, 1-17.
- Mittal, A.K. & Banerjee, T.K. (1974a). Structure and keratinization of the skin of a fresh-water teleost Notopterus notopterus (Notopteridae, Pisces). J. Zool., Lond. **174**, 341-355.
- Mittal, A.K. & Banerjee, T.K. (1974b). A histochemical study of the epidermal keratinization in the skin of a fresh-water teleost Bagarius bagarius (Ham.) (Sisoridae, Pisces). Mikroskopie **30**, 337-348.
- Mittal, A.K. & Banerjee, T.K. (1975). Histochemistry and the structure of the skin of a murrel, Channa striata (Bloch, 1797) (Channiformes, Channidae). I. Epidermis. Can. J. Zool. **53**, 833-843.

- Mittal, A.K. & Banerjee, T.K. (1976). Functional organization of the skin of the 'green-puffer fish' Tetraodon fluviatilis (Ham.-Buch.) (Tetraodontidae, Pisces). Zoomorphologie **84**, 195-209.
- Mittal, A.K. & Munshi, J.S.D. (1969). Histochemical and autoradiographic studies of the skin glands of Rita rita (Ham.) (Bagridae, Pisces). Mikroskopie **24**, 193-205.
- Mittal, A.K. & Munshi, J.S.D. (1971). A comparative study of the structure of the skin of certain air-breathing fresh-water teleosts. J. Zool., Lond. **163**, 515-532.
- Mittal, A.K. & Munshi, J.S.D. (1974). On the regeneration and repair of superficial wounds in the skin of Rita rita (Ham.) (Bagridae, Pisces). Acta Anat. **88**, 424-442.
- Mittal, A.K., Whitear, M. & Agarwal, S.K. (1980). Fine structure and histochemistry of the epidermis of the fish Monopterus albus. J. Zool., Lond. **191**, 107-125.
- Mittal, A.K., Whitear, M. & Bullock, A.M. (1981). Sacciform cells in the skin of teleost fish. Z. mikrosk.-anat. Forsch. **95**, 559-585.
- Molnár, K. (1979). Gill sphaerosporosis in the common carp and grasscarp. Acta vet. hung. **27**, 99-113.
- Moroff, T. (1904). Beitrag zur Kenntnis einiger Flagellaten. Arch. Protistenk. **3**, 69-106.
- Murray, C.K. & Fletcher, T.C. (1976). The immunohistochemical localization of lysozyme in plaice (Pleuronectes platessa L.) tissues. J. Fish Biol. **9**, 329-334.

- Needham, E.A. (1979). Fish farming in the UK- a view from industry. Biologist **26**, 158-161.
- Needham, E.A. & Wootten, R. (1978). The parasitology of teleosts. In Roberts, R.J., ed. Fish pathology, pp. 144-182. Bailliere Tindall, London.
- Nigrelli, R.F. (1935). On the effect of fish mucus on Epibdella melleni, a monogenetic trematode of marine fishes. J. Parasitol. **21**, 438.
- Noakes, D.L.G. & Leatherland, J.F. (1977). Social dominance and interrenal cell activity in rainbow trout, Salmo gairdneri (Pisces, Salmonidae). Env. Biol. Fish. **2**, 131-136.
- Ogawa, M. (1970). Effects of prolactin on the epidermal mucous cells of the goldfish, Carassius auratus L. Can. J. Zool. **48**, 501-503.
- Olivereau, M. & Lemoine, A.M. (1971a). Action de la prolactine chez l'anguille intacte et hypophysectomisée. VII. Effet sur la teneur en acide sialique (N-acétyl-neuraminique) de la peau. Z. vergl. Physiol. **73**, 34-43.
- Olivereau, M. & Lemoine, A.M. (1971b). Teneur en acide N-acétyl-neuraminique de la peau chez l'anguille après autotransplantation de l'hypophyse. Z. vergl. Physiol. **73**, 44-52.
- Olsen, O.W. (1974). Animal parasites, their life cycle and ecology. University Park Press, Baltimore.

- Paperna, I. (1980). Amyloodinium ocellatum (Brown, 1931) (Dinoflagellida) infestations in cultured marine fish at Eilat, Red Sea: epizootiology and pathology. J. Fish Dis. **3**, 363-372.
- Paperna, I. & Zwerner, D.E. (1982). Host-parasite relationship of Ergasilus labracis Krøyer (Cyclopidea, Ergasilidae) and the striped bass, Morone saxatilis (Walbaum) from the lower Chesapeake Bay. Ann. Parasitol. **57**, 393-405.
- Parke, D.V. (1978). Pharmacology of mucus. Br. Med. Bull. **34**, 89-94.
- Pearse, A.G.E. (1968). Histochemistry. Theoretical and applied, Vol. I, 3rd edn. London.
- Peleteiro, M.C. & Richards, R.H. (1985). Identification of lymphocytes in the epidermis of the rainbow trout, Salmo gairdneri Richardson. J. Fish Dis. In press.
- Pickering, A.D. (1974). The distribution of mucous cells in the epidermis of the brown trout Salmo trutta (L.) and char Salvelinus alpinus (L.). J. Fish Biol. **6**, 111-118.
- Pickering, A.D. (1976). Synthesis of n-acetyl neuraminic acid from [¹⁴C]glucose by the epidermis of the brown trout, Salmo trutta L. Comp. Biochem. Physiol. **53B**, 325-328.
- Pickering, A.D. (1977). Seasonal changes in the epidermis of the brown trout Salmo trutta (L.). J. Fish Biol. **10**, 561-566.

- Pickering, A.D. & Macey, D.J. (1977). Structure, histochemistry and the effect of handling on the mucous cells of the epidermis of the char Salvelinus alpinus (L.). J. Fish Biol. **10**, 505-512.
- Pickering, A.D., Pottinger, T.G. & Christie, P. (1982). Recovery of the brown trout, Salmo trutta L., from acute handling stress: a time course study. J. Fish Biol. **20**, 229-244.
- Pickering, A.D. & Richards, R.H. (1980). Factors influencing the structure, function and biota of the salmonid epidermis. Proc. R. Soc. Edinb. **79B**, 93-104.
- Porcelli, F. & Massari, S. (1969). Dati istochimici sulle cellule mucipare cutanee durante lo sviluppo della trota. Boll. Soc. ital. Biol. sper. **45**, 1273-1276.
- Pottinger, T.G. & Pickering, A.D. (1985a). Changes in skin structure with elevated androgen levels in maturing male brown trout, Salmo trutta L. J. Fish Biol. In press.
- Pottinger, T.G. & Pickering, A.D. (1985b). The effect of 11-ketotestosterone and testosterone on the skin structure of brown trout, Salmo trutta L. Gen. Comp. Endocrinol. In press.
- Pottinger, T.G., Pickering, A.D. & Blackstock, N. (1984). Ectoparasite induced changes in epidermal mucification of the brown trout, Salmo trutta L. J. Fish Biol. **25**, 123-128.

- Puchelle, E., Zahm, J.-M. & Aug, F. (1981). Viscoelasticity, protein content and ciliary transport rate of patients with recurrent and chronic bronchitis. Biorheology **18**, 659-666.
- Quay, W.B. (1972). Integument and the environment: glandular composition, function, and evolution. Am. Zool. **12**, 95-108.
- Reid, L. (1970). Chronic bronchitis- a report on mucus research. Proc. R. Inst. Gt Br. **43**, 438-463.
- Reid, P.E., Culling, C.F.A., Dunn, W.L. & Clay, M.G. (1984). Chemical and histochemical studies of normal and diseased human gastrointestinal tract. II. A comparison between histologically normal small intestine and Crohn's disease of the small intestine. Histochem. J. **16**, 253-264.
- Reid, P.E., Culling, C.F.A., Dunn, W.L., Ramey, C.W. & Clay, M.G. (1984). Chemical and histochemical studies of normal and diseased human gastrointestinal tract. I. A comparison between histologically normal colon, colonic tumours, ulcerative colitis and diverticular disease of the colon. Histochem. J. **16**, 235-251.
- Reynolds, E.S. (1963). The use of lead citrate at high pH as an electron-opaque stain in electron microscopy. J. Cell. Biol. **17**, 208-212.

- Richards, R.H. & Pickering, A.D. (1978). Frequency and distribution patterns of Saprolegnia infection in wild and hatchery-reared brown trout Salmo trutta L. and char Salvelinus alpinus (L.). J. Fish Dis. 1, 69-82.
- Roberts, G.P. (1978). Chemical aspects of respiratory mucus. Br. Med. Bull. 34, 39-41.
- Roberts, R.J. (1975a). Melanin-containing cells of teleost fish and their relation to disease. In Ribelin, W.E. & Migaki, G., eds. The pathology of fishes, pp. 399-425. University of Wisconsin Press, Madison.
- Roberts, R.J. (1975b). The effects of temperature on diseases and their histopathological manifestations in fish. In Ribelin, W.E. & Migaki, G., eds. The pathology of fishes, pp. 477-496. University of Wisconsin Press, Madison.
- Roberts, R.J., Bell, M. & Young, H. (1973). Studies on the skin of plaice (Pleuronectes platessa L.). II. The development of the larval plaice skin. J. Fish Biol. 5, 103-108.
- Roberts, R.J. & Bullock, A.M. (1976). The dermatology of marine teleost fish. II. Dermatopathology of the integument. Oceanogr. Mar. Biol. Ann. Rev. 14, 227-246.
- Roberts, R.J. & Bullock, A.M. (1980). Histochemistry and kinetics of the epidermis of some British teleost fishes. In Spearman, R.I.C. & Riley, P.A., eds. The skin of vertebrates, Symp. Linn. Soc. No. 9, pp. 13-22. London.

- Roberts, R.J., Shearer, W.M., Elson, K.G.R. & Munro, A.L.S. (1970). Studies on ulcerative dermal necrosis of salmonids. I. The skin of the normal salmon head. J. Fish Biol. **2**, 223-229.
- Roberts, R.J., Shearer, W.M., Munro, A.L.S. & Elson, K.G.R. (1970). Studies on ulcerative dermal necrosis of salmonids. II. The sequential pathology of the lesions. J. Fish Biol. **2**, 373-378.
- Roberts, R.J. & Shepherd, C.J. (1974). Handbook of trout and salmon diseases. Fishing News (Books) Ltd, West Byfleet.
- Roberts, R.J., Young, H. & Milne, J.A. (1971). Studies on the skin of plaice (Pleuronectes platessa L.). I. The structure and ultrastructure of normal plaice skin. J. Fish Biol. **4**, 87-98.
- Robertson, D.A. (1979). Host-parasite interactions between Ichtyobodo necator (Henneguy, 1883) and farmed salmonids. J. Fish Dis. **2**, 481-491.
- Robertson, D.A., Roberts, R.J. & Bullock, A.M. (1981). Pathogenesis and autoradiographic studies of the epidermis of salmonids infested with Ichtyobodo necator (Henneguy, 1883). J. Fish Dis. **4**, 113-125.
- Rogers, W.A. & Gaines, J.L. (1975). Lesions of protozoan diseases in fish. In Ribelin, W.E. & Migaki, G., eds. The pathology of fishes, pp. 117-141. University of Wisconsin Press, Madison.

- Rosen, M.W. & Cornford, N.E. (1971). Fluid friction of fish slimes. Nature, Lond. **234** 49-51.
- Sato, M. (1967). Histochemical and histological observations on the eosinophilic vesicles found in the head epidermis of Blepsias cirrhosus (Pallas). A preliminary report. Arch. Histol. Jpn **28**, 377-382.
- Sato, Y. (1984). Ultrastructure of Paneth cells in germ-free rats, with special reference to the secretory granules and lysosomes. Arch. Histol. Jpn **47**, 293-301.
- Savage, J. (1935). Notes on costiasis. Trans. Am. Fish. Soc. **65**, 332-333.
- Schrager, J.G. & Oates, M.D.G. (1978). Human gastrointestinal mucus and disease states. Br. Med. Bull. **34**, 79-82.
- Schubert, G. (1968). The injurious effects of Costia necatrix. Bull. Off. int. Epiz. **69**, 1171-1178.
- Schwerdtfeger, W.K. & Bereiter-Hahn, J. (1978). Transient occurrence of chloride cells in the abdominal epidermis of the guppy, Poecilia reticulata Peters, adapted to sea water. Cell Tiss. Res. **191**, 463-471.
- Smith, C.E. & Piper, R.G. (1972). Pathological effects in formalin-treated rainbow trout (Salmo gairdneri). J. Fish Res. Bd. Can. **29**, 328-329.
- Smith, F.G. (1975). Crustacean parasites of marine fishes. In Ribelin, W.E. & Migaki, G., eds. The pathology of fishes, pp. 189-203. University of Wisconsin Press, Madison.

- Smith, R.J.F. (1978). Seasonal changes in the histology of the gonads and dorsal skin of the fathead minnow, Pimephales promelas. Can. J. Zool. **56**, 2103-2109.
- Snedecor, G.W. & Cochran, W.G. (1967). Statistical methods, 6th edn. Iowa State University Press, Ames.
- Sokal, R.R. & Rohlf, F.J. (1969). Biometry. Freeman, San Francisco.
- Solanki, T.G. & Benjamin, M. (1982). Changes in the mucous cells of the gills, buccal cavity and epidermis of the nine-spined stickleback, Pungitius pungitius L., induced by transferring the fish to sea water. J. Fish Biol. **21**, 563-575.
- Sparks, R.E., Waller, W.T. & J. Cairns, Jr. (1972). Effect of shelters on the resistance of dominant and submissive bluegills (Lepomis macrochirus) to lethal concentration of zinc. J. Fish. Res. Bd Can. **29**, 1356-1358.
- Srivastava, G.J. & Srivastava, O.P. (1979). Urea induced histopathology in skin and gastric lining of the teleost Channa punctatus (Bl.). Ind. J. Exp. Biol. **17**, 840-843.
- St.Louis-Cormier, E.A., Osterland, C.K. & Anderson, P.D. (1984). Evidence for a cutaneous secretory immune system in rainbow trout (Salmo gairdneri). Dev. Comp. Immunol. **8**, 71-80.
- Stoklosowa, S. (1966). Sexual dimorphism in the skin of sea-trout, Salmo trutta. Copeia, **1966**, 613-614.

- Stoklosowa, S. (1970). Further observations on the sexual dimorphism in the skin of Salmo trutta trutta in relation to sexual maturity. Copeia, 1970, 332-339.
- Stuart, T.A. (1953). Spawning migration, reproduction and young stages of loch trout (Salmo trutta L.). Freshwat. Salm. Fish. Res. 5, pp. 39. Edinburgh.
- Tappan, V. & Zalar, V. (1963). The pathophysiology of bronchial mucus. Ann. N. Y. Acad. Sci. 106, 722-745.
- Tavolga, W.N. & Nigrelli, R.F. (1947). Studies on Costia necatrix (Henneguy). Trans. Am. Microsc. Soc. 66, 366-378.
- Vandenbergh, M.P. & Baert, J. (1981). Globule leucocytes in the tracheal epithelium of rats. Acta anat. 111, 268-276.
- Vickerman, K. (1976). The diversity of the kinetoplastid flagellates. In Lumsden, W.H.R. & Evans, D.A., eds. The biology of the Kinetoplastida, Vol. I, pp. 1-30. Academic Press, London.
- Wedemeyer, G. & Yasutake, W.T. (1974). Stress of formalin treatment in juvenile spring chinook salmon (Oncorhynchus tshawytscha) and steelhead trout (Salmo gairdneri). J. Fish. Res. Bd Can. 31, 179-184.
- Wendelaar Bonga, S.E. & Meis, S. (1981). Effects of external osmolality, calcium and prolactin on growth and differentiation of the epidermal cells of the cichlid teleost Sarotherodon mossambicus. Cell Tiss. Res. 221, 109-123.

- Whitear, M. (1970). The skin surface of bony fishes. J. Zool., Lond. **160**, 437-454.
- Widdicombe, J.G. (1978). Control of secretion of tracheo-bronchial mucus. Br. Med. Bull. **34**, 57-61.
- Wijdenes, J., van Minnen, J. & Boer, H.H. (1980). A comparative study on neurosecretion demonstrated by the Alcian blue-Alcian yellow technique in three terrestrial pulmonates (Stylommatophora). Cell Tiss. Res. **210**, 47-56.
- Wilkins, N.P. & Jancsar, S. (1979). Temporal variations in the skin of Atlantic salmon Salmo salar L. J. Fish Biol. **15**, 299-307.
- Willoughby, L.G. & Pickering, A.D. (1977). Viable Saprolegniaceae spores on the epidermis of the salmonid fish Salmo trutta and Salvelinus alpinus. Trans. Br. mycol. Soc. **68**, 91-95.
- Wilson, J.G.M. (1976). Immunological aspects of fungal disease in fish. In Jones, E.B.G., ed. Recent advances in aquatic mycology, pp. 573-601. Paul Elek (Scientific Books) Ltd, London.
- Wolke, R.E. (1975). Pathology of bacterial and fungal diseases affecting fish. In Ribelin, W.E. & Migaki, G., eds. The pathology of fishes, pp. 33-116. University of Wisconsin Press, Madison.
- Wootten, R. & McVicar, A.H. (1982). Dermocystidium from cultured eels, Anguilla anguilla L., in Scotland. J. Fish Dis. **5**, 215-222.

- Yamada, J. (1968). A study on the structure of the surface cell layers in the epidermis of some teleosts. Annot. Zool. Japon. **41**, 1-8.
- Yamada, K. & Yakote, M. (1975). Morphochemical analysis of mucosubstances in some epithelial tissues of the eel (Anguilla japonica). Histochemistry **43**, 161-172.
- Zaccone, G. (1979). Histochemistry of keratinization and epithelial mucins in the skin of the marine teleost Muraena helena (L.) (Anguilliformes, Pisces). Cell. Molec. Biol. **24**, 37-50.
- Zaccone, G. (1980a). On the occurrence of eosinophilic granular cells in teleost epidermis. A review. Zool. Jb. Anat. **104**, 139-143.
- Zaccone, G. (1980b). Structure, histochemistry and effect of stress on the epidermis of Ophisurus serpens (L.) (Teleostei: Ophichthidae). Cell. Molec. Biol. **26**, 663-674.
- Zaccone, G. (1981). Histochemical studies of glycoproteins and activities of some enzymes in the skin epidermis and sucking disc of the Connemara clingfish Lepadogaster candollei Risso 1810 (Gobiesociformes, Pisces). Arch. Biol., Bruxelles **92**, 317-342.
- Zuchelkowski, E.M., Lantz, R.C. & Hinton, D.E. (1981). Effects of acid-stress on epidermal mucous cells of the brown bullhead Ictalurus nebulosus (LeSeur): a morphometric study. Anat. Rec. **200**, 33-39.

Appendix

Work published during the course of the investigation

Blackstock, N. & Pickering, A.D. (1980). Acidophilic granular cells in the epidermis of the brown trout, Salmo trutta L. Cell Tiss. Res. **210**, 359-369.

Blackstock, N. & Pickering, A.D. (1982). Changes in the concentration and histochemistry of epidermal mucous cells during the alevin and fry stages of the brown trout Salmo trutta. J. Zool., Lond. **197**, 463-471.

Pottinger, T.G., Pickering, A.D. & Blackstock, N. (1984). Ectoparasite induced changes in epidermal mucification of the brown trout, Salmo trutta L. J. Fish Biol. **25**, 123-128.

Ectoparasite induced changes in epidermal mucification of the brown trout, *Salmo trutta* L.

T. G. POTTINGER, A. D. PICKERING AND N. BLACKSTOCK*

Freshwater Biological Association, The Ferry House, Far Sawrey, Ambleside, Cumbria

(Received 1 October 1983, Accepted 24 October 1983)

The apparent effects of environmental factors on skin structure in hatchery-reared brown trout are shown to be mediated by the influence of these factors on the skin parasite population. The presence of ectoparasites promotes a reduction in the concentration of epidermal mucus-secreting goblet cells, the magnitude of which is related to the intensity of infection.

I. INTRODUCTION

Despite frequent intimations that the teleost epidermis is involved in the basic processes of locomotion, osmoregulation, mechanical protection and disease resistance (Jakowska, 1963; Krejsa, 1979) direct evidence of its precise role(s) is usually lacking. One approach to this problem is to correlate structural changes in the epidermis with changes in the environment or within the fish itself and use this information as the basis for future experimental design. Changes in the structure of the salmonid epidermis are associated with the age, sex and state of maturity of the fish (Stokolsowa, 1966, 1970; Pickering, 1977; Blackstock & Pickering, 1982), occur on a seasonal basis (Wilkins & Jancsar, 1979) and in response to handling stress (Pickering & Macey, 1977; Pickering *et al.*, 1982). During some of our studies, this tissue plasticity has also manifested itself as a significant difference in epidermal mucification between replicate tanks of fish maintained under apparently identical conditions. The present investigation demonstrates this tank to tank variation in skin structure of the brown trout, *Salmo trutta* L., and identifies the ectoparasitic fauna as a major factor responsible for differences in epidermal mucification.

II. MATERIALS AND METHODS

FISH

A total of 1708 1+ brown trout were sampled during the experimental period. All the fish were sexually immature ($\sigma : \varnothing$ ratio 1:0) and within the weight range 8.6–248.5 g. The fish were maintained in large (1500 l), outdoor, fibreglass tanks each supplied with a constant flow of Windermere lake water (temperature range 5–17°C) and fed once daily with commercial trout pellets (1–2% body weight day⁻¹ dependent upon temperature).

SKIN SAMPLES

Skin samples were taken from the shoulder region of anaesthetized fish (100 mg l⁻¹ MS222) and prepared for superficial mucous cell estimation (see Pickering, 1974 for details). Adjacent samples were also fixed in neutral, buffered 10% formalin, embedded in paraffin wax, sectioned at 6 μ m and stained with acid haematoxylin/alcian blue (pH 2.5)/eosin. In

*Present address: School of Animal Biology, University of North Wales, Bangor, Gwynedd, Wales.

Ectoparasite induced changes in epidermal mucification of the brown trout, *Salmo trutta* L.

T. G. POTTINGER, A. D. PICKERING AND N. BLACKSTOCK*

Freshwater Biological Association, The Ferry House, Far Sawrey, Ambleside, Cumbria

(Received 1 October 1983, Accepted 24 October 1983)

The apparent effects of environmental factors on skin structure in hatchery-reared brown trout are shown to be mediated by the influence of these factors on the skin parasite population. The presence of ectoparasites promotes a reduction in the concentration of epidermal mucus-secreting goblet cells, the magnitude of which is related to the intensity of infection.

I. INTRODUCTION

Despite frequent intimations that the teleost epidermis is involved in the basic processes of locomotion, osmoregulation, mechanical protection and disease resistance (Jakowska, 1963; Krejsa, 1979) direct evidence of its precise role(s) is usually lacking. One approach to this problem is to correlate structural changes in the epidermis with changes in the environment or within the fish itself and use this information as the basis for future experimental design. Changes in the structure of the salmonid epidermis are associated with the age, sex and state of maturity of the fish (Stokolsowa, 1966, 1970; Pickering, 1977; Blackstock & Pickering, 1982), occur on a seasonal basis (Wilkins & Jancsar, 1979) and in response to handling stress (Pickering & Macey, 1977; Pickering *et al.*, 1982). During some of our studies, this tissue plasticity has also manifested itself as a significant difference in epidermal mucification between replicate tanks of fish maintained under apparently identical conditions. The present investigation demonstrates this tank to tank variation in skin structure of the brown trout, *Salmo trutta* L., and identifies the ectoparasitic fauna as a major factor responsible for differences in epidermal mucification.

II. MATERIALS AND METHODS

FISH

A total of 1708 1+ brown trout were sampled during the experimental period. All the fish were sexually immature (σ : ρ ratio 1:0) and within the weight range 8.6-248.5 g. The fish were maintained in large (1500 l), outdoor, fibreglass tanks each supplied with a constant flow of Windermere lake water (temperature range 5-17°C) and fed once daily with commercial trout pellets (1-2% body weight day⁻¹ dependent upon temperature).

SKIN SAMPLES

Skin samples were taken from the shoulder region of anaesthetized fish (100 mg l⁻¹ MS222) and prepared for superficial mucous cell estimation (see Pickering, 1974 for details). Adjacent samples were also fixed in neutral, buffered 10% formalin, embedded in paraffin wax, sectioned at 6 μ m and stained with acid haematoxylin/alcian blue (pH 2.5)/eosin. In

*Present address: School of Animal Biology, University of North Wales, Bangor, Gwynedd, Wales.

TABLE I. Variations in the number of superficial mucous cells in the epidermis of 1+ brown trout, *Salmo trutta*, maintained under four combinations of stocking density and flow rate. Mucous cell counts are expressed as mean \pm S.E.M. $n = 27$ for each value

Stocking density	Flow rate	No. mucous cells mm^{-2}
Low (100 fish in 1100 l)	High (40 l min^{-1})	561.4 \pm 32.4
Low (100 fish in 1100 l)	Low (10 l min^{-1})	275.9 \pm 21.4
High (250 fish in 275 l)	High (40 l min^{-1})	365.5 \pm 20.2
High (250 fish in 275 l)	Low (10 l min^{-1})	322.2 \pm 17.4

two experiments, skin scrapings were taken from the flank of the fish with a scalpel and examined as wet mounts under phase contrast and dark field illumination. Skin parasites were identified to the genus level and a semi-quantitative estimate of their abundance was made (Scored 0-4, absent-abundant). To ensure consistency throughout this study, these estimates were made by the same investigator. After all the skin samples had been taken, the fish were weighed, measured and sexed.

EXPERIMENTAL DESIGN

Tank to tank variation in epidermal mucification

Twenty fish were sampled from each of seven tanks and the concentration of superficial mucous (goblet) cells was determined for each fish. Each tank contained c. 400 fish of the same age and from the same stock. They were part of a routine rearing programme and had not been experimentally manipulated.

Effects of a combination of crowding and flow rate on epidermal structure

The water inflow rates, tank volumes and numbers of fish of a group of 12 tanks were adjusted according to Table I to give four different combinations of crowding and flow rate (uncrowded-high flow, uncrowded-low flow, crowded-high flow, crowded-low flow) with three replicate tanks for each combination. After 110 days, skin samples of nine fish from each tank were processed for superficial mucous cell counting and for histological examination.

Effects of crowding on epidermal structure

Twelve tanks, each containing 200 l+ brown trout, were mixed and randomly divided into two groups. The volume of water in each tank from one group was then reduced from 1200 l (uncrowded) to 250 l (crowded) but the flow rate to all tanks (40 l min^{-1}) remained unaltered. In addition, three crowded and three uncrowded tanks were given a twice-weekly dose of malachite green (0.3 mg l^{-1}) in an attempt to keep half the experimental fish free of parasites. Superficial goblet cells counts, histological preparations and estimates of skin parasite abundance were made for six fish from each tank at the start of the experiment (prior to crowding) and at 1, 2 and 3 months following crowding.

Effects of water flow rate on epidermal structure

The water flow to three of six tanks, each containing 200 l+ brown trout, was reduced from 40 l min^{-1} to 7 l min^{-1} . Skin samples were taken from eight fish in each tank at the start of the experiment (prior to flow rate reduction) and 1 month after the reduction in flow rate. Superficial mucous cell counts, histological preparations and estimates of parasite abundance were obtained for each fish.

STATISTICS

For each experiment, superficial mucous cell counts were subjected to analysis of variance (Genstat-ANOVA) with tank, flow rate, degree of crowding, time and prophylactic treatment as factors (where appropriate) and parasite abundance as covariate (where rele-

vant). Homogeneity of variances were checked by F_{\max} tests or by plotting the residuals against fitted values and appropriate transformations of the data were made where necessary. The significance of variations in parasite abundance were assessed by χ^2 analysis and linear regression was used to investigate the relationship between mucous cell concentration and parasite abundance.

III. RESULTS

TANK TO TANK VARIATION IN EPIDERMAL MUCIFICATION

Highly significant differences ($P < 0.001$) in the concentration of superficial epidermal mucous cells were found between different tanks of fish each containing fish of the same age and stock. Of the seven tanks studied, the lowest mucous cell concentration was 110.3 ± 14.8 (20) cells mm^{-2} [mean \pm s.e.m. (n)] and the highest was 563.2 ± 42.1 (20). The flow rates to each tank appeared similar but a closer examination showed that, at the time of sampling, the three tanks containing fish with the lowest mucous cell concentration were also the 3 tanks with the lowest flow rates (< 6.7 l min^{-1} cf. 7.8 – 9.8 l min^{-1}).

EFFECTS OF A COMBINATION OF CROWDING AND FLOW RATE ON EPIDERMAL MUCIFICATION

The mean mucous cell concentrations for all combinations of crowding and flow rate are given in Table I. Analysis of variance showed that reduced flow rate was accompanied by a significant decrease in epidermal mucification ($P < 0.01$) although a slight flow rate/crowding interaction ($P < 0.05$) was also evident. This interaction was resolved as a significantly lower mucous cell count in the crowded-high flow rate tanks when compared with the uncrowded-high flow rate tanks ($P < 0.001$).

EFFECTS OF CROWDING ON EPIDERMAL MUCIFICATION

In this experiment, analysis of variance showed that there was no significant effect of chronic crowding on the degree of epidermal mucification. However, prophylactic treatment with malachite green had a major influence on the number of goblet cells [424.7 ± 10.9 (144) cells mm^{-2} for treated fish cf. 362.1 ± 10.9 (144) cells mm^{-2} for untreated fish, $P < 0.005$]. An examination of the skin scrapings from these fish revealed that, although not totally effective, malachite green significantly reduced the severity of ectoparasitic infestation ($P < 0.01$, χ^2 analysis). On untreated fish, the ciliates *Trichodina* and *Scyphidia* were frequently found as was the monogenetic fluke *Gyrodactylus*. Less abundant were the flagellate *Ichtyobodo* and the fungus *Saprolegnia*.

When the mucous cell data were reanalysed with the total parasite score (cumulative score for all parasite species) as a covariate, the treatment effect disappeared and the covariate was shown to be a significant factor affecting the degree of epidermal mucification ($P < 0.05$). Thus, the effect of malachite green on the skin of the fish can be totally explained in terms of its effect in reducing the ectoparasite load. Confirmation that malachite green was not acting directly on the epidermal mucous cells was obtained by comparing the epidermal structure of untreated, parasite-free fish and malachite green-treated, parasite-free fish. No significant difference in epidermal mucification was found [477.1 ± 28.7 (18) cf. 446.4 ± 38.4 (16) goblet cells mm^{-2} respectively]. Figure 1 illustrates the inverse relationship

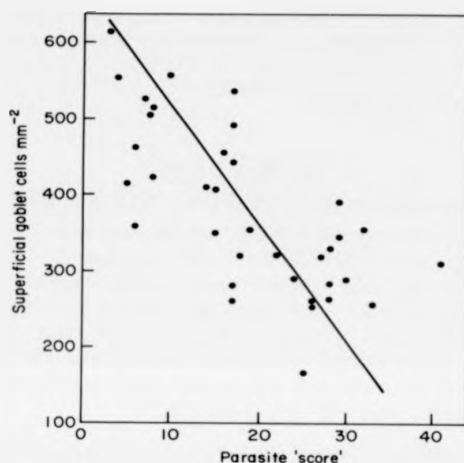


FIG. 1. Total scores for all parasites plotted against number of superficial goblet cells (mm^{-2}). Each point represents the mean value for a single pond ($n=6$). Linear regression revealed a significant correlation ($r=0.71$, $P<0.001$).

between epidermal mucification and ectoparasitic infestation (expressed as the total parasite score). When the score for each parasite was used separately as a covariate, *Trichodina* alone was shown to have a significant effect on the number of epidermal mucous cells ($P<0.025$). From a study of the histological material, no differences in epidermal thickness could be found between heavily parasitized and non-parasitized fish despite the obvious differences in mucification [68.2 ± 6.9 (13) cf. 84.0 ± 7.7 (17) μm respectively].

EFFECTS OF FLOW RATE ON EPIDERMAL MUCIFICATION

Flow rate was found to be a significant factor affecting the degree of epidermal mucification ($P<0.05$, ANOVA). At the end of the experiment, the mean epidermal mucous cell count for the fish kept in tanks with a high inflow rate was greater than that for fish under low flow rate conditions [565.5 ± 34.6 (24) cf. 462.5 ± 24.8 (24) cells mm^{-2} , $P<0.05$]. The ciliate *Scyphidia* was the only parasite found in the skin scrapings and χ^2 analysis showed it to be more abundant in the final sample, in fish from the low flow rate regime ($P<0.005$). No significant difference in distribution was present at the start of the experiment. When the mucous cell data were reanalysed with the parasite index as a covariate the effect of flow rate was no longer apparent. Thus, the influence of flow rate on the degree of epidermal mucification could be explained in terms of its effect on the abundance of *Scyphidia* on the skin of the fish.

IV. DISCUSSION

The ectoparasite fauna on the skin of 1+ brown trout has been shown to cause a significant reduction in the number of epidermal goblet cells. Of the parasites identified during the present investigation, *Trichodina* appeared to have the

greatest effect although the evidence suggests that, under certain circumstances, *Scyphidia* may also promote epidermal demucification. The apparent effects of reduced flow-rate and malachite green treatment on the skin of brown trout can be explained by the influence of these factors on the skin parasite population. It is reasonable to suppose that any conditions conducive to ectoparasite infestation will result in a reduction in the number of epidermal goblet cells.

In the absence of strictly quantitative information on parasite numbers it is difficult to make valid comparisons with other studies. However, the parasite-related reduction in concentration of goblet cells reported here is contrary to the commonly held (but rarely substantiated) view that ectoparasite infestations cause an increase in the production of mucus (Bauer *et al.*, 1969; Rogers & Gaines, 1975; Ahmed, 1976). An increase in the concentration of goblet cells in the gills of *Ichtyobodo*-infested salmon, *Salmo salar*, was observed by Ellis & Wooten (1978) although Robertson *et al.* (1981) reported a depletion of epidermal goblet cells in response to the same parasite. In similar studies at this laboratory we found that severe *Ichtyobodo* infestation of brown trout, *Salmo trutta*, resulted in a loss of goblet cells from the epidermis (Blackstock & Pickering, unpubl.). A number of other reports have described a loss of mucous cells associated with parasitic infestations (Hines & Spira, 1974; Logan & Odense, 1974; Paperna, 1980). These conflicting observations may arise due to the diverse nature of hosts and parasites examined and/or variation in the time course of events following infection, in which case both a proliferation and exhaustion of mucous cells may be part of the same response to infestation. Robertson *et al.* (1981) reported also a marked hyperplasia of the epidermis although in the present study no such response was observed. However, it should be noted that the fish used during this series of experiments appeared healthy and in good condition, showing no obvious signs of severe parasitic infestation (abrasions, damaged fins etc.). It therefore seems likely that the overall parasite burdens at no time reached a level sufficient to cause severe tissue damage and/or a total depletion of goblet cells, but were sufficient to cause a significant reduction in goblet cell numbers. Therefore differences in the degree of ectoparasite infestation may result in a significant tank to tank variation in epidermal mucification unless precautions are taken to control or minimize parasites.

If the secretion of mucus by the skin of fish is a protective mechanism to prevent colonization by potential pathogens (Pickering & Willoughby, 1982) the significance of the response reported in the present investigation is not immediately clear. Further work may reveal the functional implications of this response and the relative roles of mucus-producing goblet cells and other epidermal secretory cells during ectoparasite infestations.

The authors thank Mrs J. Pollard and Miss J. Fletcher for maintaining the experimental fish, Mrs M. Hurley for advice on statistical procedures and Mr A. Stewart for assistance during sampling.

References

- Ahmed, A. T. A. (1976). Trichodiniasis of goldfish and other carps. *Bangladesh J. Zool.* 4(1), 12-20.
- Bauer, O. N., Musselius, V. A. & Strelkov, Yu. A. (1969). *Diseases of Pond Fishes*, pp. 52-152. Israel Program for Scientific Translations: Jerusalem 1973.

- Blackstock, N. & Pickering, A. D. (1982). Changes in the concentration and histochemistry of epidermal mucous cells during the alevin and fry stages of the brown trout *Salmo trutta*. *J. Zool. Lond.* **197**, 463-471.
- Ellis, A. E. & Wootten, R. (1978). Costiasis of Atlantic salmon, *Salmo salar* L. smolts in seawater. *J. Fish Dis.* **1**, 389-393.
- Hines, R. S. & Spira, D. T. (1974). Ichthyophthiriasis in the mirror carp *Cyprinus carpio* (L.) III. Pathology. *J. Fish Biol.* **6**, 189-196.
- Jakowska, S. (1963). Mucus secretion in fish. *Ann. N. Y. Acad. Sci.* **106**, 458-462.
- Krejsa, R. J. (1979). The comparative anatomy of the integumental skeleton. In *Hyman's Comparative Vertebrate Anatomy*, 3rd Edn (M. H. Wake, ed.). Chicago: University of Chicago Press.
- Logan, V. H. & Odense, P. H. (1974). The integument of the ocean sunfish (*Mola mola* L.) (Plectognathi) with observations on the lesions from two ectoparasites, *Capsala martinieri* (Trematoda) and *Philorthagoriscus serratus* (Copepoda). *Can. J. Zool.* **52**, 1039-1045.
- Paperna, I. (1980). *Caligus minimus* (Caligadae: Copepoda) infections of the Sea bass *Dicentrarchus labrax* in the Bardawil Lagoon, Israel. *Ann. Parasitol. Hum. Comp.* **55**(6), 687-706.
- Pickering, A. D. (1974). The distribution of mucous cells in the epidermis of the brown trout *Salmo trutta* (L.) and the char *Salvelinus alpinus* (L.). *J. Fish Biol.* **6**, 111-118.
- Pickering, A. D. (1977). Seasonal changes in the epidermis of the brown trout *Salmo trutta* (L.). *J. Fish Biol.* **10**, 561-566.
- Pickering, A. D. & Macey, D. J. (1977). Structure, histochemistry and the effect of handling on the mucous cells of the epidermis of the char *Salvelinus alpinus* (L.). *J. Fish Biol.* **10**, 505-512.
- Pickering, A. D. & Willoughby, L. G. (1982). Saprolegnia infections of salmonid fish. In *Microbial Diseases of Fish* (R. J. Roberts, ed.), pp. 271-297. London: Academic Press.
- Pickering, A. D., Pottinger, T. G. & Christie, P. (1982). Recovery of the brown trout, *Salmo trutta* L., from acute handling stress: a time course study. *J. Fish Biol.* **20**, 229-244.
- Robertson, D. A., Roberts, R. J. & Bullock, A. M. (1981). Pathogenesis and autoradiographic studies of the epidermis of salmonids infested with *Ichtyobodo necator* Henneguy, 1883). *J. Fish Dis.* **4**, 113-125.
- Rogers, W. A. & Gaines, J. L. (1975). Lesions of protozoan diseases in fish. In *The Pathology of Fishes* (W. E. Ribelin & G. Migaki, eds), pp. 117-141. Madison: University of Wisconsin Press.
- Stoklosowa, S. (1966). Sexual dimorphism in the skin of sea trout, *Salmo trutta*. *Copeia* **3**, 613-614.
- Stoklosowa, S. (1970). Further observations on the sexual dimorphism in the skin of *Salmo trutta trutta* in relation to sexual maturity. *Copeia* **2**, 332-339.
- Wilkins, N. P. & Jancsar, S. (1979). Temporal variations in the skin of Atlantic salmon *Salmo salar* L. *J. Fish Biol.* **15**, 299-307.

- Blackstock, N. & Pickering, A. D. (1982). Changes in the concentration and histochemistry of epidermal mucous cells during the alevin and fry stages of the brown trout *Salmo trutta*. *J. Zool., Lond.* **197**, 463-471.
- Ellis, A. E. & Wootten, R. (1978). Costiasis of Atlantic salmon, *Salmo salar* L. smolts in seawater. *J. Fish Dis.* **1**, 389-393.
- Hines, R. S. & Spira, D. T. (1974). Ichthyophthiriasis in the mirror carp *Cyprinus carpio* (L.) III. Pathology. *J. Fish Biol.* **6**, 189-196.
- Jakowska, S. (1963). Mucus secretion in fish. *Ann. N. Y. Acad. Sci.* **106**, 458-462.
- Krejsa, R. J. (1979). The comparative anatomy of the integumental skeleton. In *Hyman's Comparative Vertebrate Anatomy*, 3rd Edn (M. H. Wake, ed.). Chicago: University of Chicago Press.
- Logan, V. H. & Odense, P. H. (1974). The integument of the ocean sunfish (*Mola mola* L.) (Plectognathi) with observations on the lesions from two ectoparasites, *Capsala martinieri* (Trematoda) and *Philorthagoriscus serratus* (Copepoda). *Can. J. Zool.* **52**, 1039-1045.
- Paperna, I. (1980). *Caligus minimus* (Caligadae: Copepoda) infections of the Sea bass *Dicentrarchus labrax* in the Bardawil Lagoon, Israel. *Ann. Parasitol. Hum. Comp.* **55**(6), 687-706.
- Pickering, A. D. (1974). The distribution of mucous cells in the epidermis of the brown trout *Salmo trutta* (L.) and the char *Salvelinus alpinus* (L.). *J. Fish Biol.* **6**, 111-118.
- Pickering, A. D. (1977). Seasonal changes in the epidermis of the brown trout *Salmo trutta* (L.). *J. Fish Biol.* **10**, 561-566.
- Pickering, A. D. & Macey, D. J. (1977). Structure, histochemistry and the effect of handling on the mucous cells of the epidermis of the char *Salvelinus alpinus* (L.). *J. Fish Biol.* **10**, 505-512.
- Pickering, A. D. & Willoughby, L. G. (1982). Saprolegnia infections of salmonid fish. In *Microbial Diseases of Fish* (R. J. Roberts, ed.), pp. 271-297. London: Academic Press.
- Pickering, A. D., Pottinger, T. G. & Christie, P. (1982). Recovery of the brown trout, *Salmo trutta* L., from acute handling stress: a time course study. *J. Fish Biol.* **20**, 229-244.
- Robertson, D. A., Roberts, R. J. & Bullock, A. M. (1981). Pathogenesis and autoradiographic studies of the epidermis of salmonids infested with *Ichtyobodo necator* Henneguy, 1883). *J. Fish Dis.* **4**, 113-125.
- Rogers, W. A. & Gaines, J. L. (1975). Lesions of protozoan diseases in fish. In *The Pathology of Fishes* (W. E. Ribelin & G. Migaki, eds), pp. 117-141. Madison: University of Wisconsin Press.
- Stoklosowa, S. (1966). Sexual dimorphism in the skin of sea trout, *Salmo trutta*. *Copeia* **3**, 613-614.
- Stoklosowa, S. (1970). Further observations on the sexual dimorphism in the skin of *Salmo trutta trutta* in relation to sexual maturity. *Copeia* **2**, 332-339.
- Wilkins, N. P. & Jancsar, S. (1979). Temporal variations in the skin of Atlantic salmon *Salmo salar* L. *J. Fish Biol.* **15**, 299-307.

Changes in the concentration and histochemistry of epidermal mucous cells during the alevin and fry stages of the Brown trout *Salmo trutta*

N. BLACKSTOCK* AND A. D. PICKERING**

Freshwater Biological Association, Ferry House, Far Sawrey, Nr. Ambleside, Cumbria, England, U.K.

(Accepted 8 December 1982)

(With 4 figures in the text)

Changes in the concentration and histochemistry of epidermal mucous cells have been shown to be similar in both natural and hatchery-reared Brown trout during the early stages of development. Superficial mucous (goblet) cell concentration is greatest immediately post-hatching (≈ 1500 cells/mm²) and remains high in the alevin epidermis during the period of yolk-sac resorption. Once the yolk sac has been resorbed and the free-swimming fry have left the spawning redds, the epidermal mucous cell concentration falls to ≈ 700 cells/mm². During the alevin-fry transition there is also a progressive decrease in the relative proportion of mucous cells containing sulphated (or a mixture of sulphated and carboxylated) acid mucopolysaccharides and an increase in the proportion of cells containing exclusively carboxylated acid mucopolysaccharides. These findings are discussed in relation to habitat and to the functional roles of epidermal mucous secretion in fishes. It is suggested that the high potential for production of mucus in the alevin stages is related to the need for protection against abrasion during the period of residence in the gravel of the spawning redds.

Contents

	Page
Introduction ..	463
Materials and methods ..	464
Fish ..	464
Histology and histochemistry ..	465
Results ..	465
Mucous cell concentration ..	465
Histochemistry ..	466
Discussion ..	468
Summary ..	470
References ..	470

Introduction

It is now well established that the epidermis of salmonid fish has the ability to change in structure in response to a variety of external and internal stimuli. A pronounced sexual

*Present address: School of Animal Biology, University College of North Wales, Bangor, Gwynedd, North Wales.

**Send reprint requests to: Dr A. D. Pickering, Freshwater Biological Association, Ferry House, Far Sawrey, Nr. Ambleside, Cumbria, England.

dimorphism occurs in the epidermis of both Sea trout and Brown trout *Salmo trutta* at spawning time (Stoklosowa, 1966, 1970; Pickering, 1977) and sexually-independent, seasonal changes in the thickness and degree of mucification of the epidermis of the Atlantic salmon *Salmo salar* have also been reported (Wilkins & Jancsar, 1979). Physical handling influences mucification in both the Char *Salvelinus alpinus* (Pickering & Macey, 1977) and the Brown trout (Pickering, Pottinger *et al.*, 1982) and marked changes in epidermal structure occur in response to severe ectoparasitic infestation of the Brown trout (Blackstock & Pickering, 1980).

However, there is very little available information concerning the epidermal structure of salmonid fish during the early stages of their life history (alevin and fry) despite the fact that these young fish are particularly vulnerable to protozoan skin infestations such as Ichtyobodiasis and Chilodonelliasis. Moreover, the development of young salmonid fish involves a dramatic change in habit from that of a burrowing animal in the gravel of the spawning redds to that of a free-swimming fish. There are some indications in the literature that, during this period, the epidermis may undergo marked structural and functional changes. For example, Stuart (1953) reported that "the entire body of Brown trout alevins appears to be covered by a thick coat of mucus which becomes less evident as the yolk sac is absorbed" and Porcelli & Massari (1969) present histochemical evidence for an increase in the sialic acid content of the mucous cells of young Rainbow trout *Salmo gairdneri* during the stages immediately following hatching.

The epidermis and its associated layers of mucus form the interface between the internal tissues of a fish and its potentially hostile environment and may be the first line of defence against pathogenic invasion (Pickering & Richards, 1980). Consequently, it is important to establish the *normal* changes that occur in this system during the fish's life cycle before pathological conditions associated with adverse environmental conditions or disease can be assessed. The present investigation is a quantitative, histological and histochemical study of the epidermis of both hatchery-reared and wild Brown trout during the period from hatching to the free-swimming fry stage.

Materials and methods

Fish

Hatchery-reared Brown trout

Eggs were hatched in a Heath incubator supplied with a constant flow of filtered, Windermere lake water (temperature range during the incubation period 2.3–6.0°C). Resultant alevins were transferred to four floating cages (1000 fish/cage) each inside a separate fibreglass tank (capacity 80 l) supplied with filtered, sterilized (ultra-violet radiation), Windermere lake water. Photoperiod and temperature were controlled to simulate natural conditions. The fish were fed four times daily with a commercially prepared trout diet (Baker's No. 0) and the tanks cleaned on a daily basis with a siphon. Samples of fish were checked for skin infections at frequent intervals by means of direct microscopical examination (dark field and phase contrast) of fresh skin scrapes. No ectoparasites were found on any of these fish throughout the investigation. Ten fish were taken at fortnightly intervals between January and July 1978 for subsequent histological and histochemical examination.

Natural Brown trout

Fish were sampled from five different streams in the Lake District (Black Brow's Beck, Dale Park

Beck, Scandale Beck, St. Sunday's Beck, Wise Een Beck) on several occasions during the years 1976–79. Eggs and alevins were obtained by kick samples and fry were collected by electrofishing. Only samples in which all fish were free of skin parasites or other signs of infection were used in this study.

Histology and histochemistry

Fish were anaesthetized in MS 222 (Sandoz) and fixed as whole animals in 10% formalin in 0.6% NaCl. The skin was removed from the whole of one side of the fixed fish and examined microscopically for ectoparasites after staining as a sheet of tissue by one of the following procedures.

Alcian blue (pH 2.5)/periodic acid—Schiff's reagent (PAS)

Skin samples were washed in running water, rinsed in 3% acetic acid (pH 2.5) and stained for 10 min in a solution of 1% Alcian blue in 3% acetic acid. After a 10-min wash in running water, the tissue was oxidized for 10 min in 0.5% periodic acid, washed for a further 10 min and then placed in Schiff's reagent for 10 min. The reaction was stopped with three 2-min baths of 0.05 M sodium bisulphite followed by a final 10-min rinse in running tap water. After dehydration and clearing the tissue was mounted in Canada balsam.

Alcian blue (pH 2.5)

The Alcian blue (pH 2.5)/PAS procedure clearly showed that all the superficial mucous (goblet) cells of the young Brown trout at all stages contained acid mucopolysaccharides. Consequently, it was appropriate to apply the Alcian blue (pH 2.5) procedure of Pickering (1974) to stain these cells for subsequent counting. Counts from 30 random quadrats (0.0076 mm²) per fish were used to estimate the density of superficial mucous cells. In the natural populations there were no obvious differences between healthy fish of similar stages of development from different sites or between different years and because it was not always possible to obtain all developmental stages from each site, the data for wild fish were pooled.

Alcian blue (pH 1)/Alcian yellow (pH 2.5)

This procedure is based on that of Wijdenes *et al.* (1980) but modified to suit thin sheets of tissue. The fixed skin was rinsed in distilled water, placed in 0.1 N HCl (pH 1.0) for 5 min and stained with 0.5% Alcian blue in 0.1 N HCl for 20 min. Following 5-min rinses in 0.1 N HCl and 3% acetic acid (pH 2.5) the tissue was stained with 0.25% Alcian yellow in 3% acetic acid for 20 min and rinsed successively in 3% acetic acid and distilled water. Specimens were rapidly dehydrated, cleared and mounted in Canada balsam. Superficial mucous cells in the epidermis were stained either blue (sulphated acid mucopolysaccharide), yellow (carboxylated acid mucopolysaccharide) or green (a combination of both types). Differential counts were made for each fish from 50 random quadrats (0.01 mm²) and the proportions of mucous cells with the three different staining reactions calculated. The data for wild fish were obtained from a single population within one year.

Results

Mucous cell concentration

In hatchery-reared Brown trout the concentration of epidermal mucous cells was highest (≈ 1500 cells/mm²) during the period January–March, the period of yolk sac resorption (Fig. 1). During April, the epidermal mucous cell concentration decreased to approximately 700 cells/mm² and stabilized at this level during the succeeding fry stage (May, June, July).

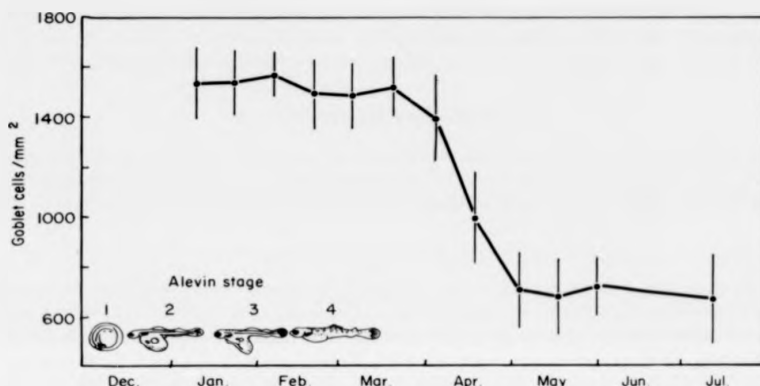


FIG. 1. Changes in the concentration of superficial epidermal mucous cells associated with the early developmental stages of the hatchery-reared Brown trout. The stages of alevin development are according to the scheme of Stuart (1953). Vertical lines indicate 95% confidence intervals.

A similar pattern of change in epidermal mucification was found in wild Brown trout alevins and fry sampled from local becks (Fig. 2). The timing of the decrease in mucous cell concentration of the wild fish was approximately 1 month later than the hatchery-reared fish but when considered in terms of the developmental stage of the young fish it is clear that the epidermal changes were similar in both groups. The concentration of epidermal mucous cells in the fry stage of the wild fish stabilized at 900–1000 cells/mm², slightly higher than in the hatchery-reared fish. It was observed that the decrease in mucification of wild Brown trout coincided with the period during which the developing fish emerged from the gravel of the spawning redds.

Histochemistry

With the combined Alcian blue (pH 2.5)/PAS technique, the epidermal mucous cells of the developing Brown trout stained either blue or blue/purple. This showed that acid mucopolysaccharides were a major constituent of the mucous cell secretions. Goblet cells containing neutral mucopolysaccharides alone (PAS + ve, AB - ve i.e. stained magenta) were rarely observed in trout at any developmental stage during the present investigation.

An examination of the nature of the acid mucopolysaccharides by means of the Alcian blue (pH 1)/Alcian yellow (pH 2.5) technique revealed interesting changes in the mucous cell histochemistry during the course of development of the fish. In the cultured fish, the majority of the epidermal mucous cells stained green immediately post-hatching, indicating that they contained both sulphated and carboxylated acid mucopolysaccharides (Fig. 3). The percentage of these cells remained fairly constant during the period of yolk-sac resorption (January–March) but then there was a change during the period April–July in which goblet cells staining with Alcian yellow alone predominated. A similar histochemical change was observed in wild Brown trout at the equivalent developmental stage (Fig. 4). This shift in chemical composition of the epidermal mucus from a mixture of sulphated and carboxylated

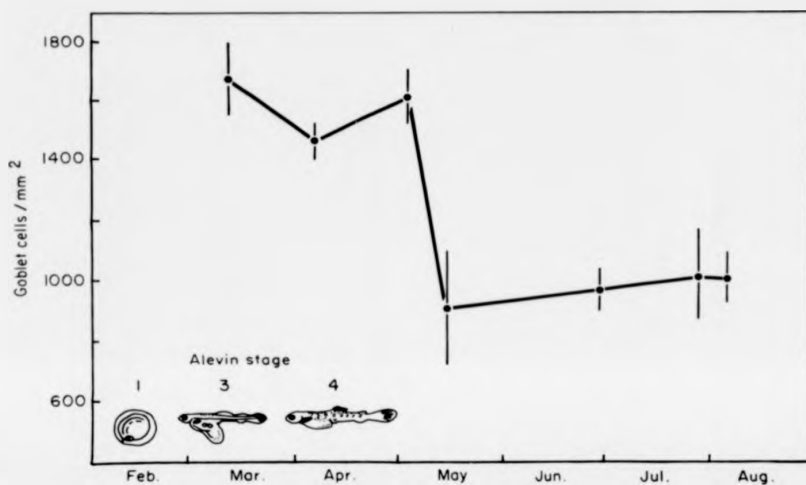


FIG. 2. Changes in the concentration of superficial epidermal mucous cells associated with the early developmental stages of wild Brown trout populations. Each point represents the pooled data of fish from different becks in the Lake District. The stages of alevin development are according to the scheme of Stuart (1953). Vertical lines indicate 95% confidence limits.

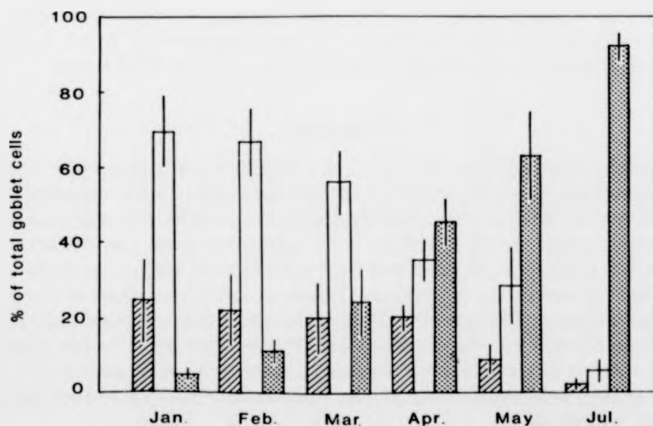


FIG. 3. Changes in the histochemistry of the superficial goblet cells in the epidermis of the hatchery-reared Brown trout during the period of alevin-fry transition. Mucous cell histochemistry was assessed according to the Alcian blue/Alcian yellow procedure. ■, Sulphated mucopolysaccharides only (stained blue); □, sulphated and carboxylated mucopolysaccharides (stained green); ▨, carboxylated mucopolysaccharides only (stained yellow). Vertical lines indicate the 95% confidence interval.

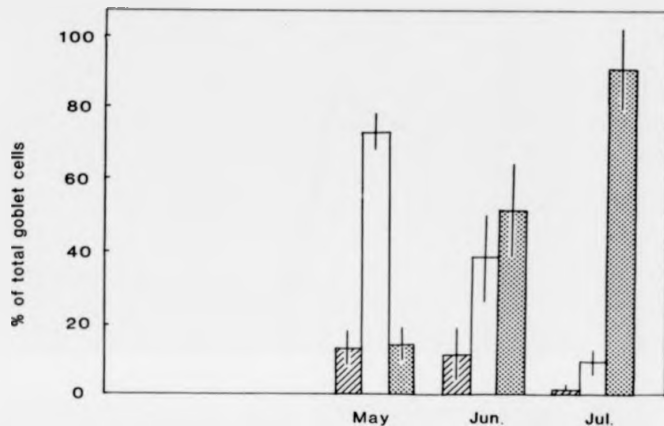


FIG. 4. Changes in the histochemistry of the superficial goblet cells in the epidermis of Brown trout from Black Brow's Beck during the period of alevin-fry transition. Mucous cell histochemistry was assessed according to the Alcian blue/Alcian yellow procedure. ▨, Sulphated mucopolysaccharides only (stained blue); □, sulphated and carboxylated mucopolysaccharides (stained green); ▩, carboxylated mucopolysaccharides only (stained yellow). Vertical lines indicate the 95% confidence interval.

to almost entirely carboxylated mucopolysaccharides occurred at the time when the young fish were emerging from the gravel of the redd to become free-swimming fish. Towards the end of the period under investigation, only a few epidermal mucous cells appeared to contain exclusively sulphated acid mucopolysaccharides (staining blue with the Alcian blue/Alcian yellow technique) and these were usually located close to the lateral line.

Discussion

The present investigation has shown that at the time of emergence of Brown trout fry from the gravel of the spawning redds there is a marked reduction in the concentration of epidermal mucous cells together with a shift towards decreased sulphation and increased carboxylation of their mucopolysaccharide content. This phenomenon was observed in both wild populations of Brown trout and in hatchery-reared fish kept under artificial conditions during the whole period of alevin-fry transition. These quantitative studies confirm and extend the qualitative observations of Stuart (1953) who reported that recently-hatched Brown trout alevins have a thicker layer of mucus than do free-swimming fry. He suggested that the high potential for mucus production is necessary to protect the young fish from abrasion whilst it is in the gravel and the timing of the epidermal changes found during the present study supports this hypothesis.

If high concentrations of epidermal mucous cells are functionally important to alevin trout living under such benthic conditions it might be expected that fish with a pelagic larval stage and a benthic adult stage may show an *increased* epidermal mucification during the course of development. The American eel *Anguilla rostrata* is one example of a fish with such a

life cycle and Leonard & Summers (1976) have noted that the concentration of epidermal mucous cells increased progressively as the fish develops from the pelagic leptocephalus larva, through the glass eel and elver stages, to the adult eel. Similarly, Roberts *et al.* (1973) in their study of the skin of the Plaice *Pleuronectes platessa* reported a progressive increase in mucification from the pelagic larval stage, through metamorphosis to the benthic stage.

In the present study, the histochemical responses of the goblet cells of the highly mucified, benthic alevin stage indicated the presence of significant amounts of sulphated acid mucopolysaccharides whereas the less mucified, free-swimming fry stage was associated with a decrease in the degree of sulphation and an increase in the proportion of goblet cells containing carboxylated acid mucopolysaccharides. N-acetyl neuraminic acid has been demonstrated as the principal sialic acid in the goblet cells and epidermal mucous secretion of the brown trout (Pickering, 1974, 1976) and it seems likely, therefore, that the increased carboxylation reflects an increase in the sialic acid content of the mucous cells. Porcelli & Massari (1969) noted an increase in the sialic acid content of the epidermal mucous cells of the developing Rainbow trout.

The possible correlation of sulphated mucins with a benthic habit and of carboxylated mucins with a free-swimming or pelagic habit gains some support from a consideration of the literature. For example in the Plaice, sulphated mucins progressively appear as the pelagic, larval form develops into a benthic fish (Roberts *et al.*, 1973). Furthermore, many predominantly benthic or burrowing species are reported to have sulphated, epidermal mucins (*Heteropneustes fossilis*, *Amphipnous cuchia*, *Mastacembelus panculus*—Mittal & Munshi, 1971; *Pleuronectes platessa*—Roberts *et al.*, 1973; Fletcher, Jones *et al.*, 1976; *Channa striata*—Mittal & Banerjee, 1975; *Anguilla anguilla*—Archer, 1979) whereas free-swimming salmonid fish have predominantly carboxylated mucins (*Salmo salar*—Harris & Hunt, 1973; *Salmo trutta*—Harris, Watson *et al.*, 1973; *Salmo gairdneri*—Fletcher, Jones *et al.*, 1976; *Salvelinus alpinus*—Pickering & Macey, 1977). However, it is recognized that these are only a few of the many thousands of benthic and pelagic fish and that there are, perhaps, many exceptions. It is suggested that further comparative, histochemical studies may clarify the situation.

In mammals, the bronchial mucosa responds to certain forms of irritation by increasing both the goblet cell concentration and the degree of acidification of their contents (Lamb & Reid, 1968; Reid, 1970; Jones *et al.*, 1973). Gona (1979) suggests that this pattern of change may have a parallel in fish. It is possible that the sulphated mucin produced by the benthic alevin Brown trout may have different physical properties to the mainly carboxylated mucin of the free-swimming fish because Keal (1971) has demonstrated a positive correlation between the neuraminic acid content and the degree of viscosity of mammalian mucus. In addition, Lopez-Vidriero *et al.* (1980) have shown that the sulphated mucus of Plaice is low in non-dialysable material and also has low viscosity when compared with normal, human bronchial secretion which contains both sulphated and sialated mucus. Changes in the physical properties of the mucus of the Brown trout may be related to the need for protection of the alevin against abrasion as it burrows through the gravel and the need for an efficient lubricant to aid free-swimming in the fry. Rosen & Cornford (1971) have demonstrated the friction-reducing properties of fish slime in relation to free-swimming.

Another role assigned to the mucous layer on teleost fish is to act as a barrier to potential pathogens in the environment. This may take the form of a physical barrier which is being constantly sloughed off and replenished (see Willoughby & Pickering, 1977) or a barrier con-

taining molecules with possible antibiotic activity (Fletcher & Grant, 1969; Bradshaw *et al.*, 1971). It is interesting that the time at which young hatchery-reared salmonid fish become particularly prone to skin infections (at the end of yolk-sac resorption and the start of first feeding) is coincident with the marked decline in epidermal mucification and the shift from sulphation to carboxylation. Further work is now needed to investigate the physical and biological properties of the epidermal mucus at different stages during the life cycle of the Brown trout.

Summary

The present study is a quantitative investigation of the changes in mucification of the epidermis of both wild and hatchery-reared Brown trout during the period of early development. Both groups of fish showed similar changes in epidermal structure during alevin-fry transition. The concentration of epidermal mucous cells was high in newly-hatched alevins (≈ 1500 cells/mm²) and remained at this level during the period of yolk-sac resorption. Once the yolk-sac was resorbed and, in the case of the wild fish, the Brown trout fry had emerged from the gravel of the spawning redds, the epidermal mucous cell concentration decreased to approximately half its original value. At the same time, the percentage of epidermal mucous cells containing sulphated acid mucopolysaccharides, or mixtures of both sulphated and carboxylated acid mucopolysaccharides, decreased until, in the free-swimming fry stage, the majority of the mucous cells contained exclusively carboxylated acid mucopolysaccharides. It is likely that these histochemical changes are accompanied by changes in the physical properties of the secreted mucins and it is suggested that the high potential for mucus production in the benthic, alevin stage affords protection from abrasion during the fish's movement both in and from the gravel of the spawning redd. The decrease in epidermal mucification of hatchery-reared Brown trout at the time of yolk-sac resorption and first feeding coincides with a period during which the young fish are particularly susceptible to skin infections. Further work is now needed to investigate the physical and biological properties of Brown trout mucus in relation to its role as a lubricant and as a barrier to potential pathogens.

We are grateful to Mrs C. B. Crosby, Mr T. G. Pottinger, Mr F. Prickett (FBA), Mr J. Moffat (NWWA) for assistance with sampling the natural Brown trout populations, Mrs J. Pollard and Miss J. Fletcher (FBA) for rearing the experimental fish, Dr R. H. Richards (Stirling) for advice and for his critical comments on the manuscript and Professor R. J. Roberts (Stirling) for his advice and encouragement throughout the investigation. Some of this work forms part of a study by one of us (N.B.) for the degree of Doctor of Philosophy.

REFERENCES

- Archer, G. C. (1979). *The skin and mucous secretion of the European eel, Anguilla anguilla L.* Ph.D. Thesis, Plymouth Polytechnic, England.
- Blackstock, N. & Pickering, A. D. (1980). Acidophilic granular cells in the epidermis of the Brown trout, *Salmo trutta L.* *Cell Tiss. Res.* **210**: 359-369.
- Bradshaw, C. M., Richard, A. S. & Sigel, M. M. (1971). IgM antibodies in fish mucus. *Proc. Soc. exp. Biol. Med.* **136**: 1122-1124.
- Fletcher, T. C. & Grant, P. T. (1969). Immunoglobulins in the serum and mucus of the plaice (*Pleuronectes platessa*). *Biochem. J.* **115**: 65P.

- Fletcher, T. C., Jones, R. & Reid, L. (1976). Identification of glycoproteins in goblet cells of epidermis and gill of plaice (*Pleuronectes platessa* L.), flounder (*Platichthys flesus* L.) and rainbow trout (*Salmo gairdneri* Richardson). *Histochem. J.* **8**: 597-608.
- Gona, O. (1979). Mucous glycoproteins of teleostean fish: a comparative histochemical study. *Histochem. J.* **11**: 709-718.
- Harris, J. E. & Hunt, S. (1973). Epithelial mucins of the Atlantic salmon (*Salmo salar* L.). *Trans. Biochem. Soc.* **1**: 153-155.
- Harris, J. E., Watson, A. & Hunt, S. (1973). Histochemical analysis of mucous cells in the epidermis of brown trout *Salmo trutta* L. *J. Fish Biol.* **5**: 345-351.
- Jones, R., Bolduc, P. & Reid, L. (1973). Goblet cell glycoprotein and tracheal gland hypertrophy in rat airways: the effect of tobacco smoke with or without the anti-inflammatory agent phenylmethyloxadiazole. *Br. J. exp. Path.* **54**: 229-239.
- Keal, E. E. (1971). Biochemistry and rheology of sputum in asthma. *Postgrad. Med. J.* **47**: 171-177.
- Lamb, D. & Reid, L. (1968). Mitotic rates, goblet cell increase and histochemical changes in mucus in rat bronchial epithelium during exposure to sulphur dioxide. *J. Path. Bact.* **96**: 97-111.
- Leonard, J. B. & Summers, R. G. (1976). The ultrastructure of the integument of the American eel, *Anguilla rostrata*. *Cell Tiss. Res.* **171**: 1-30.
- Lopez-Vidriero, M. T., Jones, R., Reid, L. & Fletcher, T. C. (1980). Analysis of skin mucus of plaice *Pleuronectes platessa* L. *J. comp. Path.* **90**: 415-420.
- Mittal, A. K. & Bannerjee, T. K. (1975). Histochemistry and the structure of the skin of a murrelet, *Channa striata* (Bloch, 1797) (Channiformes, Channidae). I. Epidermis. *Can. J. Zool.* **53**: 833-843.
- Mittal, A. K. & Munshi, J. S. D. (1971). A comparative study of the structure of the skin of certain air-breathing fresh-water teleosts. *J. Zool., Lond.* **163**: 515-532.
- Pickering, A. D. (1974). The distribution of mucous cells in the epidermis of the brown trout *Salmo trutta* (L.) and the char *Salvelinus alpinus* (L.). *J. Fish Biol.* **6**: 111-118.
- Pickering, A. D. (1976). Synthesis of n-acetyl neuraminic acid from (¹⁴C) glucose by the epidermis of the brown trout, *Salmo trutta* L. *Comp. Biochem. Physiol.* **54B**: 325-328.
- Pickering, A. D. (1977). Seasonal changes in the epidermis of the brown trout *Salmo trutta* L. *J. Fish Biol.* **10**: 561-566.
- Pickering, A. D. & Macey, D. J. (1977). Structure, histochemistry and the effect of handling on the mucous cells of the epidermis of the char *Salvelinus alpinus* (L.). *J. Fish Biol.* **10**: 505-512.
- Pickering, A. D., Pottinger, T. G. & Christie, P. (1982). Recovery of the brown trout, *Salmo trutta* L., from acute handling stress: a time-course study. *J. Fish Biol.* **20**: 229-244.
- Pickering, A. D. & Richards, R. H. (1980). Factors influencing the structure, function and biota of the salmonid epidermis. *Proc. R. Soc. Edinb.* **79B**: 93-104.
- Porcelli, F. & Massari, S. (1969). Dati istochimici sulle cellule mucipare cutanee durante lo sviluppo della trota. *Boll. Soc. ital. Biol. sper.* **45**: 1273-1276.
- Reid, L. (1970). Chronic bronchitis—a report on mucus research. *Proc. R. Inst. Gt Br.* **43**: 438-463.
- Roberts, R. J., Bell, M. & Young, H. (1973). Studies on the skin of plaice (*Pleuronectes platessa* L.) II. The development of larval plaice skin. *J. Fish Biol.* **5**: 103-108.
- Rosen, M. W. & Cornford, N. E. (1971). Fluid friction of fish slimes. *Nature, Lond.* **234**: 49-51.
- Stoklosowa, S. (1966). Sexual dimorphism in the skin of sea-trout, *Salmo trutta*. *Copeia* **1966**: 613-614.
- Stoklosowa, S. (1970). Further observations on the sexual dimorphism in the skin of *Salmo trutta trutta* in relation to sexual maturity. *Copeia* **1970**: 332-339.
- Stuart, T. A. (1953). Spawning migration, reproduction and young stages of loch trout (*Salmo trutta* L.). *Freshwat. Salm. Fish. Res.* **5**: 1-39.
- Wijdenes, J., van Minnen, J. & Boer, H. H. (1980). A comparative study on neurosecretion demonstrated by the Alcian blue-Alcian yellow technique in three terrestrial pulmonates (Stylommatophora). *Cell Tiss. Res.* **210**: 47-56.
- Wilkins, N. P. & Jancsar, S. (1979). Temporal variations in the skin of Atlantic salmon *Salmo salar* L. *J. Fish Biol.* **15**: 299-307.
- Willoughby, L. G. & Pickering, A. D. (1977). Viable Saprolegniaceae spores on the epidermis of salmonid fish *Salmo trutta* and *Salvelinus alpinus*. *Trans. Br. mycol. Soc.* **68**: 91-95.

Acidophilic Granular Cells in the Epidermis of the Brown Trout, *Salmo trutta* L.

N. Blackstock* and A.D. Pickering

Freshwater Biological Association, Ferry House, Far Sawrey, Nr. Ambleside, Cumbria, England

Summary. Acidophilic cells occur in the epidermis of several species of salmonid fish, although their abundance fluctuates considerably between individuals within the same population and at different times during the life cycle. The histology, histochemistry and ultrastructure of an acidophilic, granular cell-type in the epidermis of the brown trout, *Salmo trutta* L., is described. At the light microscope level this cell type is easily distinguished from the large, mucus-secreting, epidermal goblet cells by its acidophilic, proteinaceous secretion. At the ultrastructural level this secretion consists of membrane-bound granules formed by the very active Golgi region. It is argued that the acidophilic, granular cell is not a transformed blood cell but constitutes a normal epidermal component of the brown trout. Possible roles of this cell in the function(s) of the epidermis are discussed.

Key words: Epidermis – Acidophilic cell – Histochemistry – Ultrastructure – *Salmo trutta* L.

The salmonid epidermis is a stratified epithelium composed of two major cell-types, the filament-containing (Malpighian) cell and the large, unicellular mucous gland or goblet cell (for details of structure see Roberts et al. 1970; Harris and Hunt

Send offprint requests to: Dr. A.D. Pickering, Freshwater Biological Association, Ferry House, Far Sawrey, Nr. Ambleside, Cumbria, England

* Present address: Department of Zoology, University College of North Wales, Bangor, Gwynedd, North Wales

Acknowledgements. The authors would like to thank Mrs. J. Pollard and Miss J. Fletcher (F.B.A.) for maintaining the experimental fish, Miss C.B. McGrory and Mr. T.G. Pottinger (F.B.A.) for assistance with sampling wild brown trout, Mr. K. Shepherd and Mr. F. Prickett (F.B.A.) for providing specimens of char from Windermere, Mr. M.J. Adams for assistance with some of the histology, Professor R.J. Roberts and Dr. R.H. Richards (Stirling) for their advice and encouragement throughout the work and Dr. M. Whitear (University College, London) for her critical comments on the manuscript. Some of this work forms part of a study by one of us (N.B.) for the degree of Doctor of Philosophy

1975a, b). Many functions have been ascribed to the epidermis and its associated mucous layer (see Jakowska 1963) although convincing supporting evidence is not always available. However, it is clear that the salmonid epidermis can change in structure in response to both internal and external stimuli (Pickering and Richards 1980). This plasticity has been demonstrated by Stoklosowa (1966, 1970) who reported a sexual dimorphism in epidermal thickness and cellular composition of the mature sea trout, *Salmo trutta* L., and by Pickering and Macey (1977) who showed that physical handling of the char, *Salvelinus alpinus* (L.), increased the degree of epidermal mucification. Furthermore, using a histochemical approach, Porcelli and Massari (1969) found changes in the chemical nature of the epidermal goblet cell secretion during the development of larval and adult trout, *Salmo irideus* (Bean).

Acidophilic cells of unknown function occur in the epidermis of a variety of non-salmonid, teleost fish (e.g. Bhatti 1938; Roberts et al. 1971; Roberts and Bullock 1976) and eosinophilic cells have been noted in the epidermis of certain salmonid fish (Bullock and Roberts 1975; Pickering and Macey 1977). However, there is no detailed, published account of the histochemistry and fine structure of acidophilic cells in salmonid fish. During a study of factors influencing the structure and function of the brown trout epidermis, acidophilic granular cells (AGCs) were frequently seen, sometimes in large numbers on particular fish. As a first step towards elucidating the function of this cell-type the present paper describes the histology, histochemistry and ultrastructure of an AGC in the epidermis of the brown trout, *Salmo trutta* L.

Materials and Methods

Samples of 0+ brown trout, sea trout, char, rainbow trout *Salmo gairdneri* Richardson, and Atlantic salmon *Salmo salar* L., were taken from the F.B.A.'s hatchery at the Windermere laboratory at weekly intervals throughout 1977 and 1978. In addition, samples of Atlantic salmon and brown trout were obtained from three other local hatcheries, wild brown trout from two small Cumbrian becks and an upland tarn, and landlocked Arctic char *Salvelinus alpinus* (L.) from Windermere.

Each fish was anaesthetized (MS 222) and killed by spinal section. The body weight, fork length, sex and age of each fish were recorded. The age of wild fish was determined from scale readings. Small fish (up to 5 cm) were fixed whole and examined for ectoparasitic infestations after fixation, but in larger fish pieces of skin (approx. 1 cm square) were taken from the shoulder region and the presence of ectoparasites was determined from fresh skin scrapes taken from the flanks. All skin samples were immediately fixed in 0.6% NaCl in 10% formalin containing 0.001% eosin. This solution selectively stains acidophilic epidermal cells during the fixation process. Skin samples were further stained with 1% Alcian blue in 3% acetic acid to demonstrate the superficial goblet cells (Pickering 1974).

For further histological and histochemical investigations, adjacent pieces of skin from each of 30 brown trout were fixed in Bouin's fluid, buffered neutral formalin, Helly's fluid (with post-chromation) and Zenker's fixative and then embedded in paraffin wax and sectioned at 6 μ m. A wide range of histochemical procedures (Table 1), including tests for carbohydrates, proteins and lipids, were then applied (for details of procedures refer to Pearse (1968) and Lillie and Fullmer (1976)). In addition, skin samples from 25 brown trout were prepared for electron microscopy.

During preliminary ultrastructural studies, considerable difficulty in fixation and subsequent staining was experienced. From a variety of techniques the following procedure was found to produce the most satisfactory results. A small skin sample (1 mm²) was placed in 1 ml 12% glutaraldehyde in 0.1 M sodium cacodylate buffer (pH 7.2) at ambient temperature and after 3 min, 2 ml 1% OsO₄ in cacodylate buffer was added to the same tube. The sample was left to fix in this solution for a further 2 h.

1975a, b). Many functions have been ascribed to the epidermis and its associated mucous layer (see Jakowska 1963) although convincing supporting evidence is not always available. However, it is clear that the salmonid epidermis can change in structure in response to both internal and external stimuli (Pickering and Richards 1980). This plasticity has been demonstrated by Stokłosowa (1966, 1970) who reported a sexual dimorphism in epidermal thickness and cellular composition of the mature sea trout, *Salmo trutta* L., and by Pickering and Macey (1977) who showed that physical handling of the char, *Salvelinus alpinus* (L.), increased the degree of epidermal mucification. Furthermore, using a histochemical approach, Porcelli and Massari (1969) found changes in the chemical nature of the epidermal goblet cell secretion during the development of larval and adult trout, *Salmo irideus* (Bean).

Acidophilic cells of unknown function occur in the epidermis of a variety of non-salmonid, teleost fish (e.g. Bhatti 1938; Roberts et al. 1971; Roberts and Bullock 1976) and eosinophilic cells have been noted in the epidermis of certain salmonid fish (Bullock and Roberts 1975; Pickering and Macey 1977). However, there is no detailed, published account of the histochemistry and fine structure of acidophilic cells in salmonid fish. During a study of factors influencing the structure and function of the brown trout epidermis, acidophilic granular cells (AGCs) were frequently seen, sometimes in large numbers on particular fish. As a first step towards elucidating the function of this cell-type the present paper describes the histology, histochemistry and ultrastructure of an AGC in the epidermis of the brown trout, *Salmo trutta* L.

Materials and Methods

Samples of 0+ brown trout, sea trout, char, rainbow trout *Salmo gairdneri* Richardson, and Atlantic salmon *Salmo salar* L., were taken from the F.B.A.'s hatchery at the Windermere laboratory at weekly intervals throughout 1977 and 1978. In addition, samples of Atlantic salmon and brown trout were obtained from three other local hatcheries, wild brown trout from two small Cumbrian becks and an upland tarn, and landlocked Arctic char *Salvelinus alpinus* (L.) from Windermere.

Each fish was anaesthetized (MS222) and killed by spinal section. The body weight, fork length, sex and age of each fish were recorded. The age of wild fish was determined from scale readings. Small fish (up to 5 cm) were fixed whole and examined for ectoparasitic infestations after fixation, but in larger fish pieces of skin (approx. 1 cm square) were taken from the shoulder region and the presence of ectoparasites was determined from fresh skin scrapes taken from the flanks. All skin samples were immediately fixed in 0.6% NaCl in 10% formalin containing 0.001% eosin. This solution selectively stains acidophilic epidermal cells during the fixation process. Skin samples were further stained with 1% Alcian blue in 3% acetic acid to demonstrate the superficial goblet cells (Pickering 1974).

For further histological and histochemical investigations, adjacent pieces of skin from each of 30 brown trout were fixed in Bouin's fluid, buffered neutral formalin, Helly's fluid (with post-chromation) and Zenker's fixative and then embedded in paraffin wax and sectioned at 6 μ m. A wide range of histochemical procedures (Table 1), including tests for carbohydrates, proteins and lipids, were then applied (for details of procedures refer to Pearse (1968) and Lillie and Fullmer (1976)). In addition, skin samples from 25 brown trout were prepared for electron microscopy.

During preliminary ultrastructural studies, considerable difficulty in fixation and subsequent staining was experienced. From a variety of techniques the following procedure was found to produce the most satisfactory results. A small skin sample (1 mm³) was placed in 1 ml 12% glutaraldehyde in 0.1 M sodium cacodylate buffer (pH 7.2) at ambient temperature and after 3 min, 2 ml 1% OsO₄ in cacodylate buffer was added to the same tube. The sample was left to fix in this solution for a further 2 h.

then rinsed in 15.2% sucrose in cacodylate buffer, dehydrated in ethanol and embedded either directly in Spurr's resin or via propylene oxide in Epon. Semi-thin (0.5 μm) sections were etched with sodium ethoxide (Lane and Europa 1965), stained with eosin, and examined by light microscopy in order to identify the AGCs for electron microscopy. Adjacent thin sections were then used for electron microscopy. Thin sections were stained with saturated uranyl acetate in 25% methanol followed by lead citrate (Reynolds 1963) diluted to 50% with methanol. Material was examined with an AEI EM6B or Corinth 500 electron microscope.

Results

Distribution of Acidophilic Cells in Salmonid Epidermis

Acidophilic cells were found in some fish from all the localities sampled during this investigation and in all species except the Atlantic salmon, although only small numbers of salmon were examined and all of these were the same age. The proportion of fish with acidophilic cells and the concentration of these cells varied between sampling sites and sampling times. As acidophilic cells were found, albeit in low numbers, on most fish immediately post-hatching, it would appear that acidophilic cells are a normal component of the epidermis. In general, hatchery-reared fish appeared to have more of these cells than did the wild fish and the highest concentration (up to 1,800 mm^{-2} epidermis) was recorded in 0+ fish during the months of August and September. In successive years, both in hatchery-reared brown trout and in natural brown trout from Black Brows Beck, Cumbria, these high concentrations of epidermal acidophilic cells were coincident with severe ectoparasitic infestation by the flagellate *Ichthyobodo* Sp. (= *Costia*). Large numbers of acidophilic cells were also observed on hatchery-reared brown trout which had been kept free of ectoparasites by means of weekly formalin treatment (167 p.p.m.). However, relatively few of these cells were found in parasite-free fish kept indoors in ultra-violet sterilized lake water. In 0+ fish acidophilic cells were most abundant on the antero-ventral regions of the body surface and on larger, older fish (> 1+) these cells were more frequent in the epidermis overlying the postero-ventral margins of the scales.

Histology and Histochemistry

The choice of fixative markedly influences the acidophilic cell structure in the epidermis of the brown trout. With neutral-buffered formalin, the eosinophilic material in the cell appears as a homogeneous spherical mass whereas in Bouin's fixed material it is composed of discrete granules (Fig. 1a). It is interesting that a differential fixation effect has also been reported by Roberts et al. (1971) for the eosinophilic granular cell of the plaice, *Pleuronectes platessa* L. The ultrastructural studies (see below) confirm the granular nature of the cell content.

Acidophilic granular cells (AGCs) are found at all levels in the epidermis with the exception of the basal cell layer. The cells appear to differentiate deep in the epidermis and increase in size in the more superficial layers (Fig. 1a). When the cells reach the epidermal surface part of the plasma membrane is exposed to the

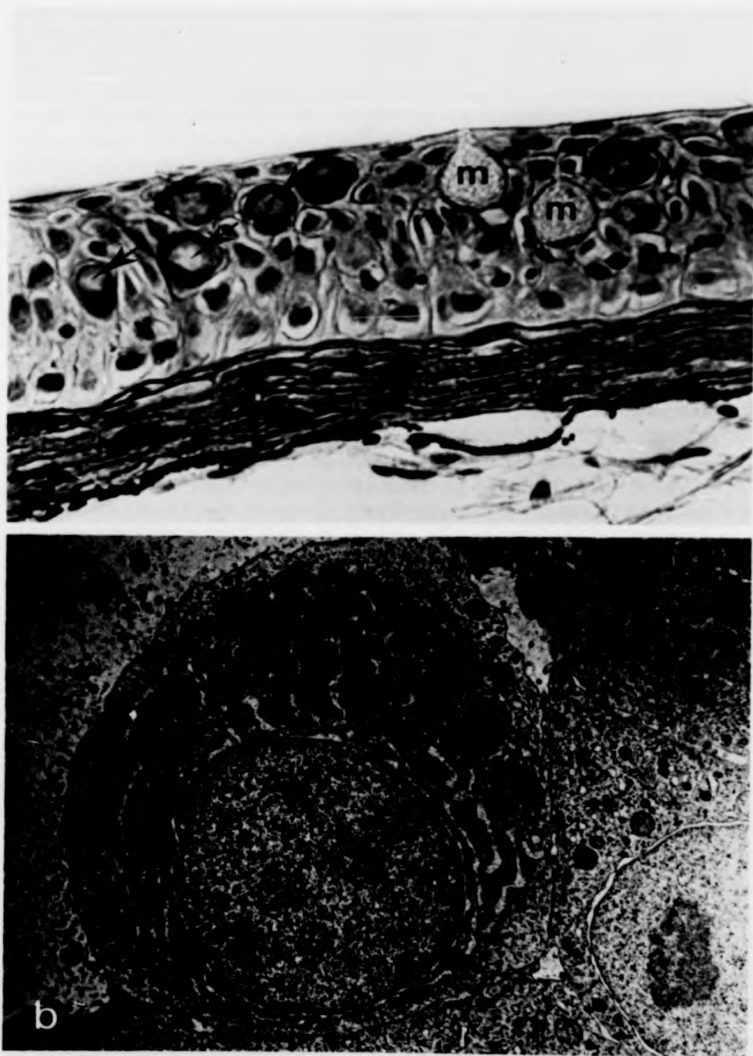


Fig. 1. **a** V.S. of brown trout epidermis. Note the numerous acidophilic granular cells (*arrowed*) at different stages of development and the large, mucous-secreting goblet cells (*m*). Bouin's fixation, haematoxylin and eosin. $\times 700$ **b** Electron micrograph of an acidophilic granular cell with a basal nucleus, well-developed Golgi and rough endoplasmic reticulum. The secretory granules accumulate in the supranuclear region of the cell. $\times 7000$

environment and, in formalin-fixed whole mounts, this may appear as an apical pore. The apparently mature cell is spherical or oval in shape with a basal nucleus and a supranuclear area containing numerous acidophilic granules.

These granules appear slightly yellowish and refractive in unstained sections under bright field illumination, but have a strong affinity for acid dyes such as orange G, erythrosin and eosin. A comparison of the histochemical responses of the contents of the AGCs and the goblet cells in the brown trout epidermis is presented in Table 1. The mucous-secreting goblet cells show the characteristic histochemical responses of carbohydrate-containing mucosubstances to the PAS procedure, aldehyde fuchsin and Alcian blue. By comparison, the AGCs normally give a negative response to these procedures (the slight pink colouration following the PAS reaction is thought to be non-specific because it occurs without prior oxidation of the tissue) but are positive to Millon's reaction, the diazotization procedure and to mercury-bromophenol blue. Considering these responses and the intense acidophilia of these cells, it would appear that a major component of the presumed secretory product of the AGC is basic protein. The AGCs also give positive responses to Verhoeff's iron haematoxylin stain for elastin and to pylonin Y, although in the latter case prior RNA-ase digestion does not diminish the response. After fixation in Helly's fluid, a slight positive response of the AGCs to Sudan black B is noted, and this may indicate the presence of some lipid material.

Ultrastructure

Mature AGCs are typically 10–18 μm in diameter but on occasions may reach 30 μm in diameter. The most prominent feature of these cells is an accumulation of membrane-bound granules (0.1–1.5 μm in diameter) in the supranuclear region (Fig. 1b). These granules are formed by an active Golgi region (Fig. 2a) and in certain cells appear to change in electron density as they accumulate within the cell. Mitochondria are located in the cytoplasm around the apical and lateral margins of the nucleus, and well-developed rough endoplasmic reticulum (RER), sometimes with dilated cisternae, occurs in the perinuclear areas of the cell (Figs. 1b, 2a). Desmosomal attachments are found between the AGCs and adjacent epidermal cells (Fig. 2a) but the AGCs do not contain the large bundles of tonofilaments so characteristic of Malpighian cells. At the surface of the epidermis a small opening is often evident between adjacent, superficial Malpighian cells through which protrudes the apical cytoplasm of an AGC (Fig. 2b). Although no unequivocal evidence of release of the granules from the cell was obtained, in view of the close proximity of many of the granules to the exposed cell membrane, it seems likely that such a release does occur. Unlike the mucous-secreting goblet cell, there appears to be little fusion of adjacent, secretory granules within the apical cytoplasm. Also, the displacement of organelles to the periphery of the cell is less marked in the mature AGC as compared with the mature goblet cell.

Developing AGCs may be found in the deeper layers of the epidermis and these are characterized by a large nucleus with prominent nucleolus, abundant RER throughout the cytoplasm, occasional mitochondria and a very active, supra-

Table 1. Staining reactions and histochemical responses of the secretory contents of the acidophilic granular cells and goblet cells in the epidermis of the brown trout

Staining procedure	To demonstrate	Fixative	Acidophilic granular cell	Mucous-secreting goblet cell
Ehrlich's Acid Haematoxylin and Eosin	General histology	B, F, H, Z	Red	Unstained
Aldehyde Fuchsin with Orange G.	General histology	B, F	Orange	Purple
Mallory's Triple Stain	General histology	B	Orange Red	Pale blue
Leishman's Stain	Blood cells	B, F, H	Pink	Very pale blue
Wright's Stain	Blood cells	B	Pink	Unstained
Clara's Dilute Haematoxylin	Blood eosinophils	F	Deep purple	Not present in section
Toluidine Blue	Mast cells	F	Unstained	Not present in section
Mercury-Bromophenol Blue	Protein	B, F, H	Blue	Unstained
Diazotization-coupling method	Tyrosine	B, F, H	Light purple	Unstained
Millon's Reaction	Tyrosine	B, F, H	Pink	Unstained
Sudan Black B	Lipids	H	Grey	Unstained
Verhoeff's Stain	Elastin	B	Black	Pale grey
Verhoeff's Stain saturated with urea	Inhibition of elastin staining	B	Unstained	Grey
Methyl Green Pyronin Y	RNA	B	Red	Unstained
Methyl Green Pyronin Y with prior RNA-ase treatment	Removal of RNA	B	Red	Unstained
Methyl Green Pyronin Y with prior buffer treatment	Control for RNA-ase	B	Red	Unstained
Periodic Acid-Schiff's Reaction (PAS)	Vicinal hydroxyl groups	B, F, H	Pink	Magenta
Schiff's Reagent without prior oxidation	Free aldehydes	B, F	Pink	Unstained
PAS with prior amylase treatment	Control for glycogen	F	Pink	Magenta
Alcian Blue (pH 2.5)	Acidic glycoproteins	B, F, H	Unstained	Blue
Alcian Blue (pH 2.5)/PAS	Acidic and neutral glycoproteins	B, F, H	Pink or unstained	Magenta → Blue
Alcian Blue (pH 2.5) Schiff's Reagent without prior oxidation	Control for acidic and neutral glycoproteins	B, F, H	Pink	Blue
Alcian Blue (pH 2.5) PAS with prior amylase treatment	Control for acidic and neutral glycoproteins	B, F, H	Pink	Magenta → Blue

Key to fixatives: B = Bouin's fluid, F = neutral buffered formalin, H = Helly's fluid, Z = Zenker's fixative

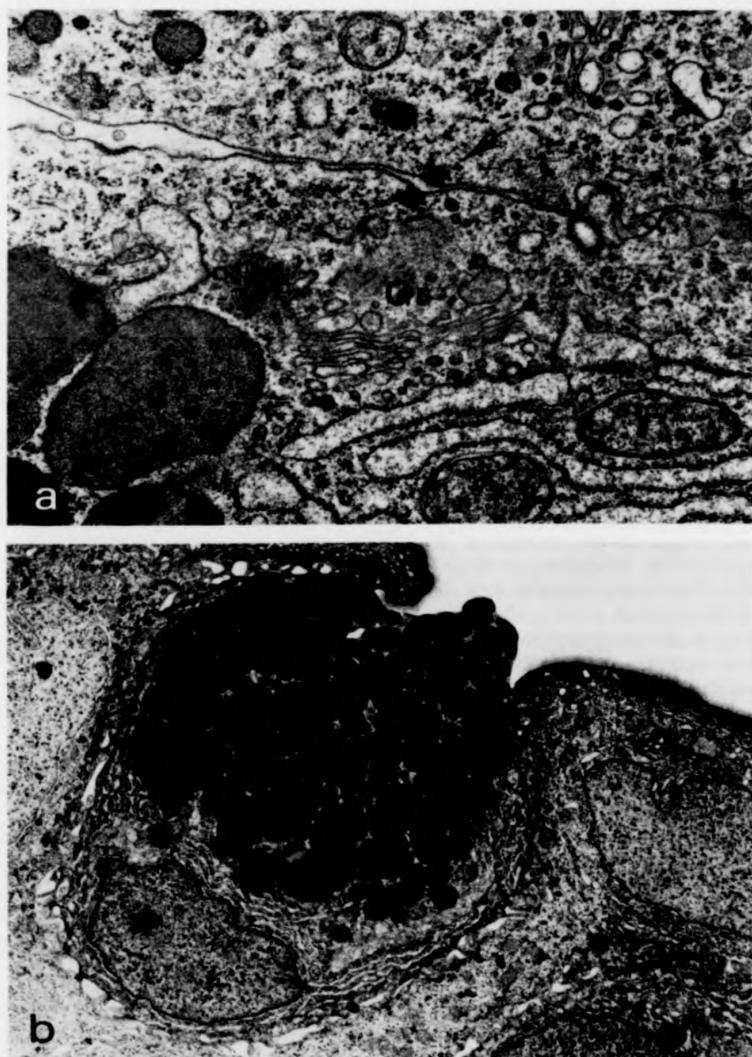


Fig. 2. a Desmosome (*arrowed*) between an acidophilic granular cell and an adjacent epidermal cell. Secretory granules (*g*) are formed in the Golgi region (*Gr*). Note also the abundant, rough endoplasmic reticulum. $\times 30,000$ **b** Acidophilic granular cell protruding between two superficial epidermal cells. $\times 5000$

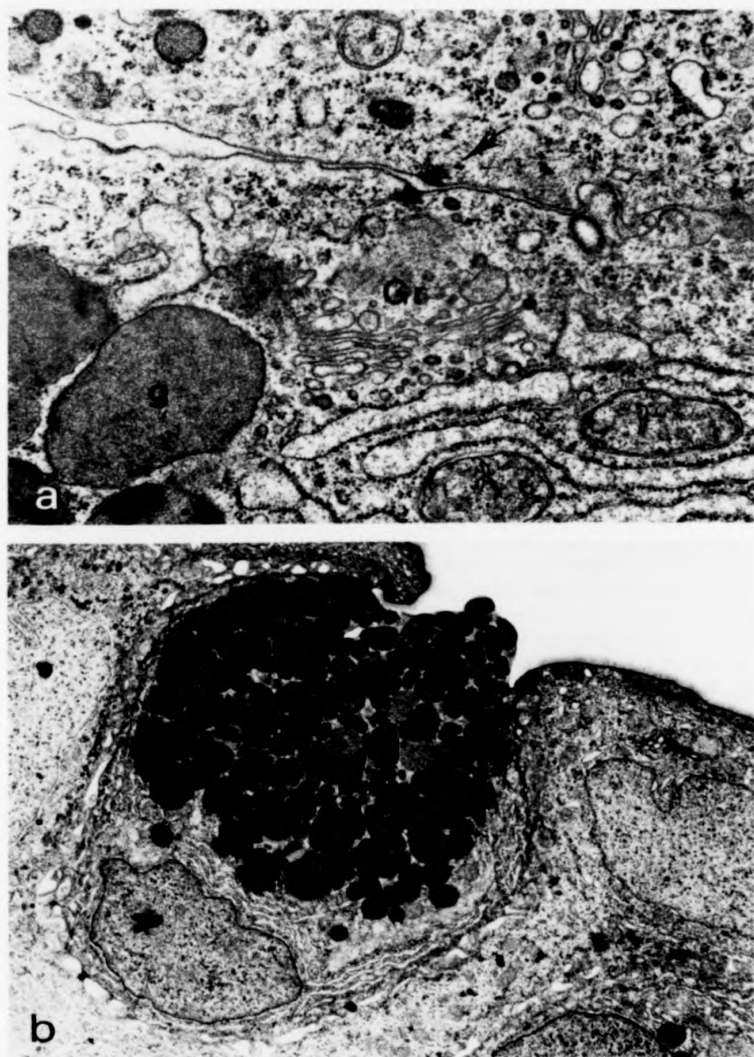


Fig. 2. **a** Desmosome (*arrowed*) between an acidophilic granular cell and an adjacent epidermal cell. Secretory granules (*g*) are formed in the Golgi region (*Gr*). Note also the abundant, rough endoplasmic reticulum. $\times 30,000$ **b** Acidophilic granular cell protruding between two superficial epidermal cells. $\times 5000$

nuclear Golgi region. Secretory granules may be observed in the process of formation by the Golgi apparatus.

Discussion

Acidophilic cells have been described in the epidermis of a wide variety of fish including South American and Asian freshwater teleosts (Bhatti 1938; Mittal and Munshi 1971, 1974; Mittal and Banerjee 1975, 1976; Mittal et al 1976; Mittal and Agarwal 1977), marine flatfish (Roberts et al. 1971; Bullock and Roberts 1975), several members of the Cottidae (Sato 1967), the ocean sunfish *Mola mola* L. (Logan and Odense 1974), and the selachian *Torpedo ocellata* Raf. (Celada and de Paoli 1962). However, whilst all these cells have in common an affinity for acidic dyes, there would appear to be marked structural differences between some of them (see also Mittal et al. 1980). Because the functions of any of these cells have not been conclusively demonstrated it would be premature to speculate on possible homologies. Previous investigations of the structure and histochemistry of the epidermis of the brown trout have not reported the occurrence of AGCs (Harris and Hunt 1975a; Pickering 1974, 1977). In view of the marked individual and temporal variation in the occurrence of these cells, their often irregular distribution within the epidermis, and the relatively small sample of tissue normally used for histological investigations, it is entirely possible for AGCs not to have been present in the material examined. Pickering and Macey (1977) have previously reported eosinophilic cells in the epidermis of the char and the present investigation has confirmed this finding.

In the AGC of the brown trout epidermis the abundant RER, active Golgi region, accumulation of granules, increase in cell size as it matures, and the exposure of the apical cytoplasm at the epidermal surface, all suggest that this cell type is secretory. It is not surprising, therefore, that the AGC has some of these features in common with the epidermal goblet cell. However, the histochemical examination of the secretory products of the AGC and the goblet cell has shown that the two cell types are quite distinct. It is of interest that throughout the present investigation an increase in the number of AGCs was normally associated with a decrease in the number of goblet cells. A similar inverse correlation between goblet cells and acidophilic cells has also been noted in other species (Bhatti 1938; Sato 1967). Transformation of the goblet cell into another cell type (the chloride cell) is thought to occur in the guppy *Poecilia reticulata* Peters (Schwerdtfeger and Bereiter-Hahn 1978), and an inter-conversion between the AGC and the goblet cell in the brown trout epidermis would seem to be a possibility. However, cells that could be regarded as intermediates between the two cell types were never seen in the present investigation, and the data suggest that the AGCs develop from undifferentiated cells deep in the epidermis, often alongside recognisable goblet cells.

In view of the affinity of AGCs for Clara's dilute haematoxylin, another possibility that must be considered is that the AGC represents a type of blood cell in the epidermis. It is certainly true that lymphocyte-like cells are quite common

between adjacent Malpighian cells in the suprabasal layer of the brown trout epidermis (Pickering and Richards 1980) and have occasionally been seen migrating across the basement membrane. Nevertheless, fully differentiated AGCs, either passing through or adjacent to either side of the basement membrane, have not been seen. Furthermore, eosinophilic granulocytes are not normally found in the peripheral blood of the brown trout (Blaxhall and Daisley 1973), although they do occur in other fish species (see Ellis 1977). The presence of desmosomal attachments between AGCs (but not presumed lymphocytes) and adjacent epidermal cells is taken as further evidence that AGCs are not invasive or transformed blood cells.

The histochemical reactions of the secretory granules of the AGCs in the epidermis of the brown trout suggest that a major component is basic protein. The apparently specific response of the granules to Verhoeff's iron haematoxylin is thought to indicate the presence of elastin (Brissie et al. 1974), a finding in agreement with that of Mittal and Agarwal (1977) for the acidophilic cells in the epidermis of the freshwater teleost *Monopterus albus*, and Zaccone (1979) for the marine teleost *Muraena helena* (L.). Mittal and Agarwal (1977) have suggested that elastin may alter the physical properties of the mucous layer by increasing its viscosity, thereby protecting the fish more effectively against chemical damage. However, until elastin has been positively identified in the mucous layer of the fish this must remain speculation. It is unlikely that the granules of the AGCs contain appreciable amounts of RNA because their positive response to pyronin Y was equally intense after incubation with RNA-ase, whereas the staining of the nucleolus under these conditions was considerably reduced.

The function(s) of acidophilic cells in the teleost epidermis have not been satisfactorily elucidated. A possible protective role in the defence mechanisms at the surface of the fish has been considered by Mittal, Banerjee and co-workers (Mittal and Munshi 1974; Banerjee et al. 1976). In this respect, it is interesting that as early as 1935, the toxicity of certain fish mucous secretions to ectoparasites was demonstrated (Nigrelli 1935). More recently, immunoglobulins have been demonstrated in fish mucus (Bradshaw et al. 1971; Fletcher and Grant 1969), and lysozyme, and enzyme with possible antibiotic activity, has been isolated from plaice mucus (Fletcher and Grant 1968). As far as we are aware, the cellular sources of these molecules have not been established.

In the present investigation large numbers of eosinophilic cells appeared to be associated with irritation of the salmonid epidermis, either by the ectoparasite *Ichthyobodo* sp. or by repeated formalin treatment. This is not inconsistent with the observation of Bullock and Roberts (1975) that salmonid eosinophilic granular cells are more abundant under pathological conditions. Further work is needed to define more clearly the factors which influence AGC numbers together with a biochemical investigation of their presumed secretory contents.

References

- Banerjee TK, Agarwal SK, Rai AK, Mittal AK (1976) Histochemical localisation of alkaline phosphatase, acid phosphatase, and succinic dehydrogenase activities in the epidermis of the

- freshwater teleost, *Amphipnous cuchia* (Hamilton) (Symbranchiformes, Pisces). *Mikroskopie* 32:294-300
- Bhatti HK (1938) The integument and dermal skeleton of siluroidea. *Trans Zool Soc Lond* 24:1-102
- Blaxall PC, Daisley KW (1973) Routine haematological methods for use with fish blood. *J Fish Biol* 5:771-781
- Bradshaw CM, Richard AS, Sigel MM (1971) IgM antibodies in fish mucus. *Proc Soc Exp Biol Med* 136:1122-1124
- Brissie RM, Spicer SS, Hall BJ, Thompson NT (1974) Ultrastructural staining of thin sections with iron hematoxylin. *J Histochem Cytochem* 22:895-907
- Bullock AM, Roberts RJ (1975) The dermatology of marine teleost fish. 1. The normal integument. *Oceanogr Mar Biol Ann Rev* 13:383-411
- Celada M, de Paoli AM (1962) Contributo alla conoscenza delle cellule albuminose (Schneider) cutanee di *Torpedo ocellata* Raf. *Riv Istochim Norm Pat* 8:411-416
- Ellis AE (1977) The leucocytes of fish: A review. *J Fish Biol* 11:453-491
- Fletcher TC, Grant PT (1968) Glycoproteins in the external mucous secretions of the plaice, *Pleuronectes platessa*, and other fishes. *Proc Biochem Soc* 12P. In *Biochem J* 106
- Fletcher TC, Grant PT (1969) Immunoglobulins in the serum and mucous of the plaice (*Pleuronectes platessa*). *Proc Biochem Soc* 65P. In *Biochem J* 115
- Harris JE, Hunt S (1975a) The fine structure of the epidermis of two species of salmonid fish, the atlantic salmon (*Salmo salar* L.) and the brown trout (*Salmo trutta* L.). I. General organization and filament-containing cells. *Cell Tissue Res* 157:553-565
- Harris JE, Hunt S (1975b) The fine structure of the epidermis of two species of salmonid fish, the atlantic salmon (*Salmo salar* L.) and the brown trout (*Salmo trutta* L.). II. Mucous cells. *Cell Tissue Res* 163:535-543
- Jakowska S (1963) Mucous secretion in fish - A note. *Ann NY Acad Sci* 106:458-462
- Lane BP, Europa DL (1965) Differential staining of ultrathin sections of epon-embedded tissues for light microscopy. *J Histochem Cytochem* 13:579-582
- Lillie RD, Fullmer HM (1976) *Histopathologic technic and practical histochemistry*. McGraw-Hill New York: 4th ed.
- Logan VH, Odense PH (1974) The integument of the ocean sunfish (*Mola mola* L.) (Plectognathi) with observations on the lesions from two ectoparasites, *Capsala mustinieret* (Trematoda) and *Philorthagoriscus serratus* (Copepoda). *Cand J Zool* 52:1039-1045
- Mittal AK, Agarwal SK (1977) Histochemistry of the unicellular glands in relation to their physiological significance in the epidermis of *Monopterus cuchia* (Symbranchiformes, Pisces). *J Zool, Lond* 182:429-439
- Mittal AK, Banerjee TK (1975) Histochemistry and the structure of the skin of a murrel, *Channa striata* (Bloch, 1797) (Channiformes, channidae). I. Epidermis. *Cand J Zool* 53:833-843
- Mittal AK, Banerjee TK (1976) Functional organization of the skin of the 'Green-Puffer-Fish' *Tetraodon lineatus* (Ham-Buck.) (Tetraodontidae, Pisces). *Zoomorphologie* 84:195-209
- Mittal AK, Munshi JSD (1971) A comparative study of the structure of the skin of certain air-breathing fresh-water teleosts. *J Zool, Lond* 163:515-532
- Mittal AK, Munshi JSD (1974) On the regeneration and repair of superficial wounds in the skin of *Rita rita* (Ham.) (Bagridae, Pisces). *Acta Anat* 88:424-442
- Mittal AK, Agarwal SK, Banerjee TK (1976) Protein and carbohydrate histochemistry in relation to the keratinization in the epidermis of *Barbus sophur* (Cyprinidae, Pisces). *J Zool, Lond* 179:1-17
- Mittal AK, Whitear M, Bullock AM (1980) Sacciform cells in teleost fish. In press
- Nigrelli RF (1935) On the effect of fish mucous on *Epibdella melieni*, a monogenetic trematode of marine fishes. *J Parasitol* 21:438
- Pearse AGE (1968) *Histochemistry theoretical and applied*. Little, Brown and Co. Boston. 3rd ed Vol. 1
- Pickering AD (1974) The distribution of mucous cells in the epidermis of the brown trout *Salmo trutta* (L.) and the char *Salvelinus alpinus* (L.). *J Fish Biol* 6:111-118
- Pickering AD (1977) Seasonal changes in the epidermis of the brown trout *Salmo trutta* (L.). *J Fish Biol* 10:561-566
- Pickering AD, Macey DJ (1977) Structure, histochemistry and the effect of handling on the mucous cells of the epidermis of the char *Salvelinus alpinus* (L.). *J Fish Biol* 10:505-512
- Pickering AD, Richards RH (1980) Factors influencing the structure, function and biota of the salmonid epidermis. *Proc R Soc Edin B*. In press

- Porcelli F, Massari S (1969) Dati istochimici sulle cellule mucipare cutanee durante lo sviluppo della trota. *Boll Soc Ital Biol Sper* 45:1273-1276
- Reynolds ES (1963) The use of lead citrate at high pH as an electron-opaque stain in electron microscopy. *J Cell Biol* 17:208-212
- Roberts RJ, Bullock AM (1976) The dermatology of marine teleost fish. II. Dermatopathology of the integument. *Oceanogr Mar Biol Ann Rev* 14:227-246
- Roberts RJ, Shearer WM, Elson KGR, Munro ALS (1970) Studies on ulcerative dermal necrosis of salmonids. 1. The skin of the normal salmon head. *J Fish Biol* 2:223-229
- Roberts RJ, Young H, Milne JA (1971) Studies on the skin of plaice (*Pleuronectes platessa* L.). 1. The structure and ultrastructure of normal plaice skin. *J Fish Biol* 4:87-98
- Sato M (1967) Histological and histochemical observations on the eosinophilic vesicles found in the head epidermis of *Blepias cirrhosus* (Pallas). A preliminary report. *Arch Histol Jpn* 28:377-382
- Schwerdtfeger WK, Breiter-Hahn J (1978) Transient occurrence of chloride cells in the abdominal epidermis of the guppy, *Poecilia reticulata* Peters, adapted to sea water. *Cell Tissue Res* 191:463-471
- Stoklosowa S (1966) Sexual dimorphism in the skin of sea-trout, *Salmo trutta*. *Copeia* No 3. 613-614
- Stoklosowa S (1970) Further observations on the sexual dimorphism in the skin of *Salmo trutta trutta* in relation to sexual maturity. *Copeia* No 2. 332-339
- Zaccone G (1979) Histochemistry of keratinization and epithelial mucins in the skin of *Muraena helena* (L.). *Cell Mol Biol* 24:37-50

Accepted June 4, 1980