

# Management of COVID-19 in cancer patients receiving cardiotoxic anti-cancer therapy. Future recommendations for cardio-oncology

Hasan Kobat,<sup>1</sup> Islam Elkonaissi,<sup>2</sup> Mehmet Tevfik Dorak,<sup>3</sup> Shereen Nabhani-Gebara<sup>1</sup>

<sup>1</sup>Department of Pharmacy, School of Life Sciences, Pharmacy and Chemistry, Kingston University London, Penrhyn Road, Kingston Upon Thames; <sup>2</sup>Pharmacy Department, Cambridge University Hospitals NHS Foundation Trust, Cambridge; <sup>3</sup>Head of School of Life Sciences, Pharmacy and Chemistry, Kingston University London, Penrhyn Road, Kingston Upon Thames, United Kingdom

## Abstract

Cardiotoxicity induced by anti-cancer treatment has become a significant threat as the number of cardiotoxic anti-cancer agents is growing. Cancer patients are at an increased risk of contracting coronavirus disease 2019 (COVID-19) because of immune suppression caused by anti-cancer drugs and/or supportive treatment. Deterioration in lung functions due to COVID-19 is responsible for many cardiac events. The presence of COVID-19 and some of its treatment modalities may increase the chance of cardiotoxicity development in cancer patients receiving potentially cardiotoxic agents. This review provides evidence-based information on the cardiotoxicity risk in cancer patients clinically diagnosed with COVID-19 who are receiving potentially cardiotoxic anti-cancer agents. Proposed strategies relating to the management of this patient cohorts are also discussed.

Correspondence: Hasan Kobat, Department of Pharmacy, School of Life Sciences, Pharmacy and Chemistry, Kingston University London, Penrhyn Road, Kingston Upon Thames, KT1 2EE, United Kingdom. Tel.: +44.7761.715184. E-mail: k1411572@kingston.ac.uk

Key words: COVID-19; cardiotoxicity; cardio-oncology; cancer; management.

Contributions: everyone was involved in the conception and design of the article. HK was involved in drafting the manuscript and collecting the recent published data about COVID-19 and the pharmacotherapies used in COVID-19. SN-G and IE are oncology pharmacists. The design of the cardiotoxic anti-cancer agents related parts of the article, and the revision, editing and proofreading of the manuscript were carried out by them and HK. MTD is a medical doctor. He took part in investigation, writing, revision and proofreading of the article in terms of the relationship between COVID-19 and cancer. All authors have read and approved the final version of the manuscript prior to submission.

Conflict of interests: the authors declare no potential conflict of interests.

Received for publication: 14 August 2020.  
Revision received: 22 November 2020.  
Accepted for publication: 26 January 2021.

This work is licensed under a Creative Commons Attribution NonCommercial 4.0 License (CC BY-NC 4.0).

©Copyright: the Author(s), 2021  
Licensee PAGEPress, Italy  
Oncology Reviews 2021; 15:510  
doi:10.4081/oncol.2021.510

## Introduction

Coronavirus disease 2019, more commonly referred to as COVID-19, is a novel viral infection that has affected more than 185 countries worldwide.<sup>1</sup> Following its declaration as a pandemic by the World Health Organisation (WHO) in March 2020, COVID-19 has been responsible for as many as 1,178,475 deaths globally as of 30 October 2020.<sup>2</sup> Severe acute respiratory syndrome coronavirus 2 (SARS-CoV-2) is the causative strain of COVID-19. Common features among infected individuals include fever, continuous cough and anosmia, however in more severe cases complications such as pneumonia and acute respiratory failure have been reported.<sup>3</sup> The continuous pressure of providing patient care while maintaining strict infection control measures has revealed and accumulated inadequacies in health-care systems that make it harder to manage patients with acute respiratory distress syndrome (ARDS) as a result of COVID-19.<sup>4</sup> Although the majority of admitted patients were discharged without any serious respiratory deteriorations, the number of patients requiring respiratory support remains significant.<sup>5</sup> In addition to the burden of providing intensive respiratory intervention, there is some evidence to suggest a relationship between COVID-19 and the development of cardiotoxicity among some patients. Cardiovascular complications among those diagnosed with COVID-19, such as myocardial injury and cardiac dysfunction, have been attributed to an increase in mortality in these acutely unwell patients.<sup>6,7</sup> During this pandemic, a subset of the population was defined as vulnerable and in need of shielding. People living with cancer are one example and have been shown to be more susceptible due to immune suppression and overlapping toxicities. A study published in *The Lancet* demonstrated the clinical outcomes of cancer patients with COVID-19.<sup>8</sup> Analysis of 928 patients showed high 30-day mortality of cancer patients with COVID-19 which was associated with general or unique risk factors to cancer patients. Older age, male sex, smoking status, increased number of comorbidities, Eastern Cooperative Oncology Group (ECOG) performance status 2 or higher, active cancer were the independent factors associated with increased 30-day mortality. Many anti-cancer drugs play a role in the development of cardiotoxicity leading to an increase in patient mortality.<sup>9-14</sup> It is therefore not unreasonable to assume that patients exposed to both COVID-19 and certain anti-cancer agents are at a greatly increased risk of severe and potentially life-threatening cardiotoxic complications.

This review presents the evidence base of the cardiotoxicity risk in cancer patients clinically diagnosed with COVID-19 alongside proposed management strategies.

## Cardiovascular complications of COVID-19

The development of cardiac muscle injury can be attributed to a number of factors or events. Adverse drug reactions, existing comorbidities and other potential confounders such as age, smoking and body mass index have a role to play.<sup>15</sup> Interestingly, the work by Ruane *et al.*<sup>16</sup> has shown patients suffering from respiratory infections experience an increase in the occurrence of acute cardiovascular abnormalities, namely myocardial infarction (MI).<sup>16</sup> Relative risk (RR) for MI was found to be elevated among participants (17.0, 95% CI 13.2-21.8), even in those with milder symptoms (13.5, CI 10.2-17.7). Similarly, in a recent study by Wang *et al.*<sup>17</sup> on 138 COVID-19 patients, cardiotoxicity developed in nearly 24% of the sample cohort.<sup>17</sup> This 24% comprised two major cardiac pathologies including arrhythmia (16.7%,  $P < 0.001$ ) and acute cardiac injury (7.2%,  $P < 0.001$ ). For patients admitted to the intensive care unit, the incidence of arrhythmia (44.4%) and acute cardiac injury (22.2%) was much higher. In a report by the National Health Commission of China, 11.8% of the hospitalised COVID-19 patients experienced a cardiac arrest or increase in cardiac troponin I levels (cTnI), without any previous history of underlying cardiovascular disease.<sup>18</sup> A meta-analysis, including 30 studies and a total of 6389 COVID-19 patients, presented critical cardiovascular complications.<sup>19</sup> Arrhythmia (16.6%), acute cardiac injury (15.7%) and heart failure (11.5%) were within the most prevalent cardiovascular complications. Presence of previous cardiac disease contributes to high mortality rates in COVID-19 patients. Although the development of cardiovascular toxicities is sometimes associated with COVID-19, pre-existing cardiovascular morbidities are also playing a role in the conditions of the patients with COVID-19. According to a meta-analysis, heart failure was associated with poor outcome in COVID-19 patients. Higher mortality and hospitalisation were also more common in COVID-19 patients with heart failure than without.<sup>20</sup> This underscores the importance of management of patients with pre-existing heart disease during COVID-19. Beside the effects of heart failure during COVID-19, endothelial dysfunction further increases the chance of cardiotoxicity development in patients diagnosed with COVID-19. The relationship between endothelial dysfunction and COVID-19 associated coagulopathy and vascular inflammation has been demonstrated.<sup>21</sup> Viral infections in endothelial cells play a role in endothelial activation and dysfunction. The presence of COVID-19 relatively contributes to endothelial damage which can further affect other organs such as the heart.<sup>22</sup> In the presence of already existed endothelial damage along with further diagnosis of COVID-19, cardiotoxicity risk increases even more as COVID-19 also facilitates the endothelial damage.

Apart from effects of previous cardiac disease in COVID-19, several case studies show development of multiple cardiovascular events in patients without having any pre-existing cardiac disease. The majority of COVID-19 patients do not develop serious cardiovascular side-effects whereas some patients exhibit multiple and life-threatening cardiovascular conditions despite having no pre-existing cardiovascular disease. The outcomes for these patients were demonstrated with case reports. In a case study of a 37-year old patient with COVID-19, myocardial injury was also reported.<sup>23</sup> The electrocardiography (ECG) showed ST-segment elevation, acute myocardial infarction and a significant increase in cardiac markers [cTnI, brain natriuretic peptide (BNP), creatine kinase isoenzyme (CK MB)]. Echocardiography also revealed ventricular systolic dysfunction, showing 27% left ventricular ejection fraction (LVEF). Elevated cTnI and N-terminal pro-brain natriuretic peptide (NT-proBNP) levels, together with left ventricular dysfunction (LVEF: 32%), were present in another case study of a 63-

year old COVID-19 patient having no previous history of cardiac disease.<sup>24</sup> Aside from elevations in cardiac biomarkers and left ventricular dysfunction, COVID-19 and the resulting pharmacotherapy have been attributed to other cardiovascular events, such as QTc prolongation, as shown in Table 1.<sup>25,26</sup>

## Cardiovascular effects of pharmacotherapies used in COVID-19

To date, there is no finalised treatment strategy demonstrating the exact therapeutic approach for COVID-19, however numerous agents are being investigated for their therapeutic effect including antiviral agents, corticosteroids, anti-inflammatory and immune-based therapies and hydroxychloroquine. In this review, we focused on cardiovascular effects of hydroxychloroquine, remdesivir, lopinavir/ritonavir, favipiravir, tocilizumab and dexamethasone. Both COVID-19 and its currently proposed treatment regimens can contribute to cardiac abnormalities.<sup>27-30</sup> Concurrent administration of hydroxychloroquine and azithromycin (a macrolide antibiotic) was a treatment strategy employed to tackle COVID-19 in the beginning of pandemic.<sup>28</sup> This combination was believed to have a favourable effects on patient outcomes, however they were associated with several clinically significant cardiovascular adverse events including QTc prolongation, drug associated *torsades de pointes* and sudden cardiac death.<sup>31-33</sup> Evidence comparing the use of chloroquine or hydroxychloroquine alone *versus* in combination with a macrolide antibiotic was provided by a large scale multi-national project which included results for 96,032 patients hospitalised with COVID-19.<sup>34</sup> Ventricular arrhythmias were demonstrated to be the highest incidence in patients receiving a combination of hydroxychloroquine together with a macrolide antibiotic. This paper is retracted by *The Lancet* due to issuing an expression of concern on 5 June 2020. Although hydroxychloroquine treatment was authorised to be used as emergency by Food and Drug Administration (FDA), its authorisation withdrawn because of the not effective results and the severe side effects.<sup>35</sup> This regimen has now since been abandoned due to reports of no added benefit and increased hospitalisation associated with its use.

Multiple research studies have reported on remdesivir, an antiviral drug, to be effective in the treatment of adult COVID-19 patients.<sup>36-38</sup> Clinical improvements were observed in hospitalised patients. Even though its application showed improved patient outcomes, cardiovascular side-effects such as severe hypotension (8%), atrial fibrillation (6%), hypernatremia (6%) and multi-organ dysfunction were observed.<sup>36</sup> A case of cardiac arrest was demonstrated in another study by Wang *et al.* in which the efficacy and safety of remdesivir in COVID-19 patients in comparison with the placebo group were tested.<sup>39</sup> There is a need for increased amount of clinical trials, especially multi-centre, demonstrating efficacy and cardiac safety of remdesivir in COVID-19 patient populations. There are ongoing trials investigating the therapeutic efficacy of remdesivir in COVID-19 patients.<sup>40</sup>

**Table 1. Demonstration of several potential cardiovascular complications in patients clinically diagnosed with COVID-19.**

Cardiovascular complications in COVID-19 patients	QTc prolongation Acute myocardial infarction Left ventricular dysfunction Ventricular arrhythmia (ventricular tachycardia, ventricular fibrillation) Sudden cardiac death
---	---

Lopinavir/ritonavir, a protease-inhibitor and antiretroviral agent, is in use to check whether it is effective in the treatment of COVID-19. Findings from a recent study showed some benefits of lopinavir/ritonavir for secondary endpoints (*i.e.* shorter stay in intensive care unit, duration of hospital stay, *etc.*).<sup>41</sup> According to a pharmacovigilance data in France, lopinavir/ritonavir was associated with numerous cardiotoxicities in COVID-19 patients.<sup>42</sup> These include ventricular arrhythmias, QTc prolongation, bradycardia and bundle branch block. Another case report demonstrated the outcomes of the two patients received lopinavir/ritonavir for human immunodeficiency virus (HIV).<sup>42</sup> Both patients developed severe cardiac arrhythmia within a month after the onset of drugs. There are ongoing clinical trials testing the efficacy and safety of lopinavir/ritonavir.<sup>43</sup>

Favipiravir is a synthetic prodrug and believed to be effective in the treatment of COVID-19 due to its inhibitory effect of specific viral enzyme called RNA-dependent RNA polymerase (RdRp) as Shannon *et al.* found SARS-CoV-2-RdRp complex is 10 times more active than other viral RdRp known.<sup>44</sup> Trials show favipiravir to be effective in viral clearance, disease progression and relief of cough and pyrexia.<sup>45,46</sup> The cardiotoxicity incidence and safety profile of favipiravir is relatively safe although there is one published case study showing QTc interval prolongation in patient who received favipiravir for Ebola virus.<sup>47</sup> Use of other agents such as vitamin C, dexamethasone, interferon-alpha, and monoclonal antibodies are under extensive research to find maximum efficacy and safety in the treatment of COVID-19. These drugs are also associated with several forms of cardiotoxicity either for COVID-19 or other indications.<sup>48-51</sup>

Monoclonal antibody agents are one of the most popular therapeutic strategies for the treatment of COVID-19. Trials with tocilizumab, a recombinant monoclonal antibody, targeting the interleukin (IL)-6 receptor has been shown to be an effective treatment of COVID-19 with reduced mortality rates.<sup>52</sup> According to a meta-analysis published before pandemic in non-COVID-19 patients, tocilizumab was found to be safe in terms of cardiovascular side-effects than other anti-rheumatoid agents.<sup>53</sup> Tocilizumab is believed to reduce the effects of COVID-19 on the heart because of its ability to improve endothelial functions and reduce inflammation and oxidative stress.<sup>54</sup> Of particular relevance, the oxidative stress theory is the proposed cardiotoxicity mechanism of anthracycline chemotherapy.<sup>55</sup> The most significant ongoing trial testing the efficacy of tocilizumab and other agents such as dexamethasone is the RECOVERY trial (clinicaltrials.gov no: NCT04381936) with an aim to reach to estimated sample size of 20,000 patients.<sup>56</sup>

According to the published preliminary results of the RECOVERY trial, dexamethasone, a glucocorticosteroid, was found to improve 28-day mortality among hospitalised patients with COVID-19 receiving respiratory support.<sup>57</sup> National Health Service (NHS) United Kingdom suggested the use of dexamethasone in critically ill patients with COVID-19 with a letter in accordance with WHO suggestions.<sup>58</sup> Although the exact cardiovascular safety of dexamethasone in patients with COVID-19 was not demonstrated in available literature, dexamethasone has a known cardiovascular side-effect profile. The evidence of increased blood pressure, tachycardia and other cardiac events were demonstrated.<sup>59-64</sup>

There are several agents under investigation for the treatment of COVID-19. Some of these are known to trigger cardiovascular events and some are relatively safe. However, the majority of pharmacotherapies used in COVID-19 has at least one event of cardiovascular toxicity as explained above. Cardiac monitoring should become an integral part of patient care, particularly in those with

other risk factors, such as exposure to anti-cancer agents, which in turn may contribute to the risk of cardiotoxicity.

## Cardiotoxicity of several anti-cancer drugs

### Anthracycline and trastuzumab induced cardiotoxicity: Increased risk when used as concurrent

Beyond the scope of the evidence provided by the various cohort and case studies identifying cardiotoxicity associated with a COVID-19 diagnosis and treatment alone, another significant sample of patients at risk includes those receiving anti-cancer therapies that are also associated with cardiotoxicity.<sup>65</sup> The cardiotoxicity of anthracyclines, particularly doxorubicin and the human epidermal growth factor receptor-2 (HER-2) antagonist trastuzumab, were extensively studied in breast cancer patients, which found an increase in risk as high as 34% when administered as combination therapy.<sup>66-70</sup> The type of cardiovascular event for these anti-cancer treatments ranged from asymptomatic reduction in LVEF to sudden cardiac death.<sup>71,72</sup> Doxorubicin and trastuzumab exhibit their cardiotoxic effects via different pathways, hence they synergistically increase the risk of cardiovascular events when given concurrently. Doxorubicin is responsible for permanent cardiac muscle death, whereas trastuzumab promotes reversible cardiomyocyte dysfunction.<sup>73</sup> In addition, doxorubicin cardiotoxicity is cumulatively dose-related, in contrast trastuzumab related myocardial injury is dose-independent and can occur at any time. The risk of cardiotoxicity with trastuzumab treatment alone is low but the doxorubicin-trastuzumab combinational regimen for HER-2 positive breast cancer increases the risk of cardiotoxicity.<sup>70</sup> The mechanism of cardiotoxicity for both agents intersect at HER-2 activity. Doxorubicin binds to topoisomerase 2 $\beta$  in the heart causing DNA double strands to break. This results in mitochondrial dysfunction and free radical generation promoting cellular death.<sup>74</sup> Myocardial tissue has a regenerative mechanism through HER-2 upregulation, however, inhibition of HER-2 with the addition of trastuzumab inhibits the myocardial repair, which further increases the risk of cardiotoxicity.<sup>75</sup>

### Cardiotoxicity of new agents: tyrosine-kinase inhibitors and immune check-point inhibitors

#### Tyrosine-kinase inhibitors

Dramatic improvements in cancer survival-rates have been observed with the introduction of tyrosine-kinase inhibitors (TKIs) and immune check-point inhibitors.<sup>76-81</sup> Although they are currently employed to treat a range of cancers, their cardiotoxic side effects restrict their overall usability.<sup>82,83</sup> While anthracycline and trastuzumab cardiotoxicity is related to changes in systolic function, TKI associated cardiotoxicities are more specifically related with hypertension and ECG findings such as QTc prolongation, bradycardia, tachycardia and T-wave inversion (*e.g.* atrial fibrillation, ventricular arrhythmia).<sup>84-89</sup> The exact mechanism of TKI-induced cardiotoxicity has not been completely identified. One theory suggests vascular endothelial growth factor inhibition may be a pathway through which the decrease in the amount of available nitric oxide (NO) results in an increasing abundance of reactive oxygen species that contribute to various cardiovascular complications.<sup>90</sup> A meta-analysis of clinical trials using TKIs to target the vascular endothelial growth factor receptor by Ghatalia *et al.*<sup>91</sup> found an increased risk of QTc prolongation.<sup>91</sup> Vantedanib, sunitinib, and pazopanib were the particular drugs of interest. QTc pro-



longation was observed in 4.41% (n=165/3737) and 0.25% (n=7/2811) of the patients receiving TKI and non-TKI drugs, respectively. Patients receiving TKIs were at higher risk of QTc prolongation than patients receiving other drugs (RR=8.66, 95% CI 4.92-15.2, P<0.001). In addition, the TKI cohort were at a greater risk of high-grade QTc prolongation than non-TKI group (RR=2.69, 95% CI 1.33-5.44, P=0.006). Other TKIs used in the treatment of non-small cell lung cancer such as osimertinib, crizotinib, ceritinib and brigatinib were also associated with several types of cardiotoxicity including: QTc prolongation, hypertension, bradycardia, etc.<sup>92-95</sup>

### Immune check-point inhibitors

Newer therapeutic options, such as immune check-point inhibitors, are also an effective treatment choice for several cancers. Chemotherapy, radiotherapy, and targeted treatments were designed to directly inhibit cancer cell growth. Immune check-point inhibitors utilise the immune system in order to recognise cancer cells more effectively.<sup>96,97</sup> Currently, there are eight approved immune check-point inhibitors each with a different target receptor. Ipilimumab and tremelimumab target cytotoxic T-lymphocyte-associated protein 4 (CTLA-4), pembrolizumab and nivolumab target programmed cell death protein 1 (PD-1). The remaining three immune check-point inhibitors, atezolizumab, durvalumab and avelumab target programmed death-ligand 1 (PD-L1) receptor. Ipilimumab, most commonly used in the treatment of melanoma, has been associated with incidence of pericarditis, myocardial fibrosis and cardiomyopathy.<sup>98-100</sup> Furthermore, there are case studies demonstrating the development of myocarditis with nivolumab and pembrolizumab.<sup>101,102</sup> Aside from myocarditis, additional cardiovascular events, including ventricular arrhythmia and Takotsubo-like cardiomyopathy, have been observed with a number of immune check-point inhibitors.<sup>103</sup> Given the rise in availability of cardiotoxic anti-cancer agents, the need for collaboration between cardiologists and oncologists has become even more pertinent in the management of patient care. From this necessity, a novel discipline of cardio-oncology has emerged.<sup>104</sup> Cardio-oncology is a field that not only seeks to provide patient care following the development of cardiovascular events, but also aims to determine and establish risk factors, early diagnosis, cardiac biomarkers, preventative and early treatment strategies as key principles of patient management.

## Pharmacotherapies used in COVID-19 and cardiotoxic anti-cancer drugs: common cardiac side-effects

It is not unsurprising that those receiving treatment for cancer are included in the high-risk group for COVID-19 given the effects of immunosuppressant therapies and the impact of compromised immune systems on contracting communicable diseases.<sup>105</sup> However, despite this, the number of studies examining the incidence of cancer in COVID-19 patients are limited. In a COVID-19 cohort study search, cancer comorbidity was reported in 10 studies (Table 2).

Severe cases of COVID-19, pharmacotherapeutic approach and receiving cardiotoxic anti-cancer treatment are all risk factors for the development of cardiotoxicity. Therefore, cancer patients receiving COVID-19 treatment should be monitored even more closely given the potential synergistic risk posed by the numerous factors that contribute to cardiotoxicity. Anti-cancer drug induced cardiotoxicity can develop as an early- and/or late-onset. Some of the cardiovascular events associated with anti-cancer treatments can develop right after first cycle whereas some may develop years after the termination of chemotherapy.

### Early-onset cardiotoxicity

Hydroxychloroquine, azithromycin and some anti-viral agents should be used cautiously among cancer patients whose anti-cancer regimen contains a TKI given the shared tendency for QTc prolongation.<sup>31-33,42,47</sup> QTc prolongation is a predominantly early-onset which may develop days to weeks after anti-cancer drug administration. Concurrent use of agents may lead to a sudden increase in QTc levels (>60 ms) resulting in value and to a level >500 ms, which may further contribute to ventricular arrhythmias and sudden cardiac death, especially in older populations.<sup>106,107</sup> In addition, COVID-19 patients treated with doxorubicin alone or in combination with trastuzumab require additional monitoring as both COVID-19, and some pharmacotherapies can increase the risk of left ventricular dysfunction. A decrease in LVEF >10% from baseline, associated with a drop to a level below 50% is an accepted definition for left ventricular dysfunction.<sup>108,109</sup> Left ventricular dysfunction can be an early- or late- onset event.<sup>110</sup> Therefore, stopping cancer treatment in patients receiving doxorubicin and trastuzumab in order to commence COVID-19 therapy

**Table 2. Studies showing the incidence of cancer in patients clinically diagnosed with COVID-19.**

Study	Total COVID-19 cases (n)	Total cancer cases (n)	Cancer incidence (%)
Liang <i>et al.</i> <sup>112</sup>	1590	18	1.1
Zhang <i>et al.</i> <sup>113</sup>	1276	28	2.2
Guan <i>et al.</i> <sup>114</sup>	1099	8	0.7
Onder <i>et al.</i> <sup>115</sup>	355 <sup>o</sup>	87	24.5
Shi <i>et al.</i> <sup>116</sup>	416	9	2.2
*Report from China <sup>117</sup>	44672	107	0.5
Richardson <i>et al.</i> <sup>118</sup>	5700	320	6
Nikpouraghdam <i>et al.</i> <sup>119</sup>	2964	17	0.5
Cai <i>et al.</i> <sup>120</sup>	383	5	1.3
Lei <i>et al.</i> <sup>121</sup>	34 <sup>#</sup>	5	14.7
Biran <i>et al.</i> <sup>139</sup>	764	98	12.8
Guaraldi <i>et al.</i> <sup>143</sup>	354	10	2.8

\*Nationwide investigation from China; <sup>o</sup>all patients were dead; <sup>#</sup>all patients underwent to a surgical operation for another reason.

may not always be preferable, particularly in the long term. Although lower cumulative doses of doxorubicin are associated with a lower incidence of cardiotoxicity development, cardiac events resulting from trastuzumab are dose-independent and can occur at any time, from days after first cycle to years after the final dose of chemotherapy.<sup>111</sup> As a result, the predictability of left ventricular dysfunction is poor in patients receiving anthracyclines and trastuzumab therapy. It is logical to assume that the potential for the development of cardiotoxicity might strongly increase with the presence of COVID-19 and concurrent administration of pharmacotherapies.

### Late-onset cardiotoxicity

There is not enough current evidence to definitely outline the time-onset of cardiotoxicity. Anthracycline-induced cardiotoxicity can be classified under three main types: acute, early-onset chronic and late-onset chronic.<sup>112,113</sup> Late-onset chronic progressive cardiotoxicity generally develops following one year from the termination of anthracycline chemotherapy and can present as dilated cardiomyopathy and arrhythmias.<sup>112</sup> In a prospective study by Tassan-Mangina *et al.*<sup>114</sup> of adults receiving anthracycline therapy, late-onset left ventricular function alteration was observed.<sup>114</sup> The LVEF of the patients was recorded at its lowest value (LVEF: 56±8%) 3.5 years after completion of anthracycline treatment when compared with readings at baseline and 1-3 months after the termination of chemotherapy, which reported LVEF values of 72±6% and 71±8%, respectively. In another study by Tsai *et al.*,<sup>115</sup> the cardiac function was evaluated of long-term survivors of Hodgkin's lymphoma that received radiotherapy with or without anthracycline chemotherapy.<sup>116</sup> Echocardiography was performed 22±2 years after treatment cessation that confirmed myocardial function alteration among both study groups, however it should be noted that additional long-term negative left ventricular systolic function effects were observed in the anthracycline treatment group. When considering the needs of cancer patients with COVID-19 and their available treatment options, it is essential to discuss their treatment history, particularly given the potential cardiotoxic impact of anthracyclines even decades after completion of chemotherapy. Newly diagnosed COVID-19 patients who have a history of cardiotoxic anti-cancer regimen may be more susceptible to develop new cardiotoxicities in the case of COVID-19 and the administration of its potential pharmacotherapies.

### Paediatric COVID-19 populations: overlapping risks

Cardiotoxicity risk is significant and life-threatening for paediatric populations. In developed countries, 5-years survival rate is around 85% for paediatric cancer patients.<sup>116</sup> Late chronic conditions such as cardiovascular system abnormalities had increased with prolonged life expectancy in children with cancer.<sup>117</sup> According to a long term follow-up study, 27% of the childhood cancer survivors exhibited abnormalities in cardiac dysfunction which was associated with cumulative anthracycline dose, radiation and young age at the time of diagnosis.<sup>118</sup> The majority of children with COVID-19 experience mild symptoms and do not require hospitalisation. However, small number of children with COVID-19 demonstrated the incidence of paediatric multisystem inflammatory syndrome (PIMS) alike to Kawasaki disease which affects multi-organ system including cardiovascular system.<sup>119</sup> Paediatric patients who exhibited PIMS showed serious cardiac events such as biventricular dysfunction, left ventricular systolic

impairment and coronary vessel abnormalities.<sup>119</sup> The increased incidence of hyperinflammatory events affecting multi-organ system, has been proposed to overlap with COVID-19 diagnosis. Although the reason remains unclear, it is pretty well known that the multisystemic inflammation accelerates the incidence of cardiovascular events as one of its proposed mechanisms.<sup>120</sup> Children with cancer should be closely and carefully monitored because bidirectional risk of cardiotoxicity of both morbidities is severely life-threatening. Children with cancer who receive cardiotoxic anti-cancer agents and diagnosed with COVID-19 can be at higher risk to cardiotoxicity than older patients due to higher incidence of cardiovascular events associated with anti-cancer treatment and severity of potential cardiac risks of multi-inflammation affecting multi-organ system during COVID-19.

### Thoracic radiotherapy

Administration of thoracic radiation in addition to anti-cancer treatment is a frequent strategy used to target a number of cancers. As single therapy, in combination or post- chemotherapy radiotherapy can result in several pulmonary and cardiovascular complications.<sup>121</sup> Fibrotic changes in cardiac valves, coronary artery disease, and damage to the peri- and myocardium have all been associated with radiation therapy.<sup>122</sup> Thoracic radiation can also cause permanent damage to pulmonary tissue resulting in respiratory dysfunction in up to 30% of patients.<sup>123</sup> Changes in the morphology of respiratory and cardiac tissue are associated with severe COVID-19 infections, as well as treatments such as hydroxychloroquine, and therefore may further exacerbate the burden of pulmonary fibrosis experienced by patients receiving thoracic radiation. Concurrent use of thoracic radiotherapy together with cardiotoxic anti-cancer drugs in COVID-19 cancer patients will potentially increase patient mortality as a result of the augmented risk to this patient group, therefore careful consideration should be taken prior to the initiation of treatment, especially in those with breast and lung cancers (Figure 1).

### Hypertension

Cardiovascular risk factors in cancer patients such as age, renal failure, previous cardiac disease and hypertension might increase the chance of cardiotoxicity development in patients suffering both from cancer and COVID-19 (Figure 2).<sup>124</sup> According to European Society of Cardiology (ESC), hypertension is a cardiovascular risk factor for cancer patients receiving treatment with anthracyclines.<sup>124</sup> Incidentally, the presence of hypertension is believed to increase the severity of COVID-19 due to the administration of antihypertensives such as angiotensin-converting enzyme inhibitors (ACEIs) and angiotensin receptor blockers (ARBs). The proposed link to an increased susceptibility COVID-19 is theorised as a result of upregulation of angiotensin converting enzyme-2 (ACE-2) expression in lungs with ACEI and ARB therapy.<sup>125-127</sup> ACE-2 facilitates viral transmission into cells which may potentially increase the development of ARDS.<sup>128</sup> However, ESC and International Society of Hypertension (ISH) announced statements advocating not to discontinue ACEI/ARB treatment.<sup>129,130</sup> Their statement follows a recent meta-analysis that describes the overall benefit for continued ACEI/ARB treatment in COVID-19 patients, which found an overall reduction in severity and mortality.<sup>131</sup> The authors note that individual factors such as ACE-2 polymorphism however still require further evaluation to help stratify patient risk

on a case by case basis. ACE-2 is not only expressed in lungs but also widely presented in the myocardium which may shed some light on the underlying mechanism contributing to the high incidence of cardiotoxicity in patients with hypertension. However, further investigation is warranted given the overall paucity of evidence and disagreement across the current literature. Taking the current findings into account, management of patients presenting with cancer, COVID-19 and hypertension should be comprehensive in its approach to monitoring and assessing patients on a case by case basis while we await further clarification on best practice for this cohort.

cer drugs, COVID-19 and its proposed pharmacotherapies is possible by comprehensive evaluation of drug history at the baseline.

### Importance of baseline and serial cardiovascular evaluation

Baseline cardiovascular assessments are an integral part of patient care for those with cancer and receiving cardiotoxic anti-cancer agents.<sup>131</sup> A comprehensive baseline evaluation should include ECG, echocardiography, biochemical marker testing, physical cardiology check and a comprehensive evaluation of drug history. Each potentially cardiotoxic anti-cancer treatment were identified with different forms of cardiotoxicity with different onsets. The use of biochemical markers in early diagnosis/prediction of cardiotoxicity in cancer patients is controversial in the literature and their role has not become clear yet together with considerable amount of studies could not show any predictive value. The use of biochemical markers can be misleading in patients with COVID-19 and cancer as biomarkers may rise due to other rea-

### Management of COVID-19 in patients living with cancer

Finding the cardiovascular-associated links between anti-can-

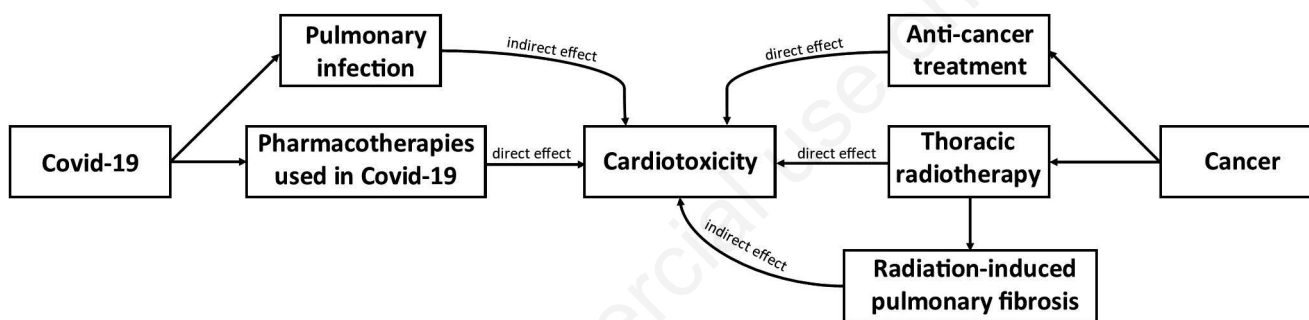


Figure 1. Demonstration of several factors (i.e. pulmonary function alteration due to COVID-19, pharmacotherapies used in COVID-19, administration of potentially cardiotoxic agents and thoracic radiotherapy-induced pulmonary fibrosis) inducing cardiovascular toxicity development.

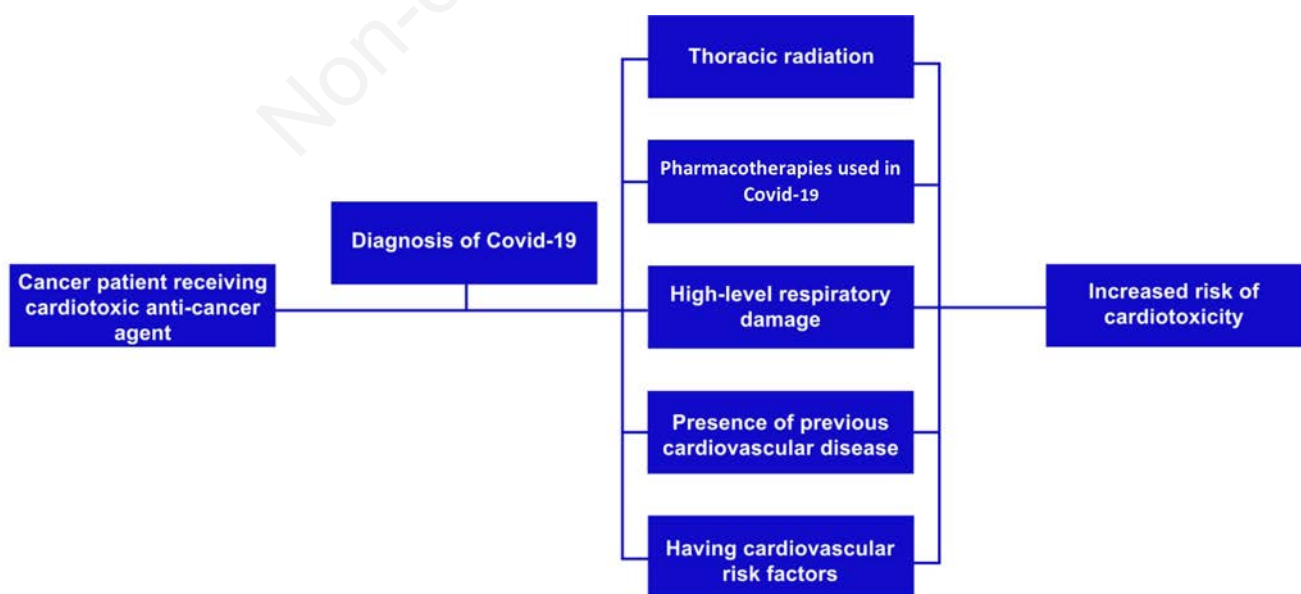


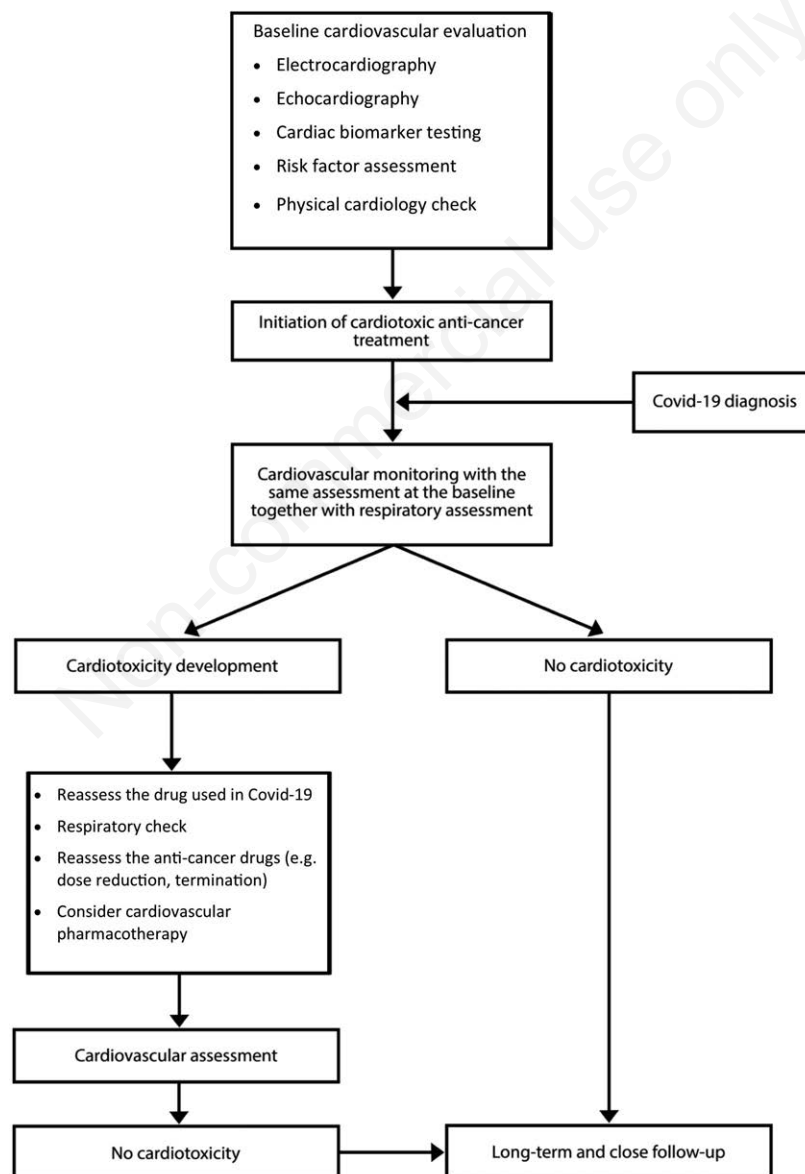
Figure 2. Factors that increase cardiotoxicity development risk in COVID-19 cancer patients receiving cardiotoxic anti-cancer treatments.

son(s) during the viral infections. Therefore it is hard to attribute the marker elevation and cardiovascular events to anti-cancer therapy or to COVID-19.<sup>132</sup> The baseline evaluation provides an opportunity for comparison of future results with pre-chemotherapy data. Serial monitoring is another key practice of cardio-oncology. Serial ECGs and echocardiography assessments pave the way for detecting potential cardiovascular events as early as possible. In addition to routine assessments, patients should be evaluated at the time of and serially following a clinical diagnosis of COVID-19 (Figure 3). A respiratory assessment should also be an integral part of patient management given the correlation between the severity of respiratory infection and the development of cardiotoxicity.<sup>16</sup> Under normal circumstances, cardiologists, oncologists, and nurses make up the bulk of the cardio-oncology team.<sup>133,134</sup> For severe COVID-19 cases, in which there is respiratory function alteration, intervention from respiratory teams is vital in supporting the role of cardio-oncology. This also extends to pharmacists

who can offer critical insights on medicines management including: safety and efficacy of prescribed treatments and doses, comprehensive drug history and medicines reconciliation and the monitoring of treatment response and adverse effects, particularly cardio-toxicity.

### Cardiovascular toxicity guidelines for cancer patients: minor modifications for COVID-19

There are existing cardiovascular toxicity guidelines for cancer patients.<sup>124,135,136</sup> The wide spectrum of guidance was created with the aim to counteract the risk of cardiotoxicity among this patient group. Aside from the principles and considerations discussed in this article, the guidelines encourage the uptake of consistent baseline and serial assessments including the use of the same imaging tools throughout the evaluation process. Echocardiography might not provide similar or reliable readings when different devices are used, which may lead to misinterpretation of results.<sup>137</sup> Myocardial



**Figure 3. Outlines possible step by step management of cancer patients receiving cardiotoxic anti-cancer agents clinically diagnosed with COVID-19.**



strain imaging is a new approach that has been found to be more sensitive than LVEF for detecting subclinical left ventricular systolic dysfunction.<sup>138</sup> However, validation of biomarkers has not been definitively confirmed yet. To date, only early diagnosis of left ventricular impairment has been studied. Therefore, the only recommendation can be made for early diagnosis of left ventricular dysfunction and no other ECG related abnormalities such as QTc prolongation. According to the guidelines, the use of intensity modulated and 3D conformal radiotherapy are preferred techniques for thoracic radiotherapy as they are associated with a reduced risk of early or late cardiovascular toxicity development. Prophylactic use of ACEIs or ARBs and/or beta blockers and/or statins to reduce the risk of cardiotoxicity is another highlighted recommendation within the guidelines that requires individual patient assessment. As there is still continuing debate related to COVID-19 and anti-hypertensives, the patients should be monitored serially and closely. The use of ACEI can potentially be used to reduce the chance of occurrence of cardiotoxicity but with cautious and close monitoring in COVID-19 patients until the topic is clear. It should also be clearly known that these agents are not interchangeable, and their preventive activity does not support asymptomatic patients.

## Conclusions

COVID-19 has taken the global centre stage in recent months; however, it is important to consider the patients beyond the disease itself and the increased exposure to risk that they may face in light of this current pandemic. Both cancer and COVID-19, as well as their respective therapy options are known to contribute to cardiotoxicity. The long-term cardiac health impact of a previous COVID-19 diagnosis is yet to be understood. For these reasons, a holistic approach to management is essential in supporting cancer patients to achieve the most positive outcomes while navigating the challenge of patient therapy. It is imperative to recognise the overlap in symptoms and treatment side effects associated with both COVID-19 and cancer treatment. In practice and whilst awaiting further evidence, this would come down to understanding the nature of symptoms and toxicity in addition to frequency alongside a holistic clinical history taking including comprehensive screening of drug history at the baseline. Education and training should take place in this regard in order to allow early recognition and timely management. Furthermore, close monitoring and an enhanced multi-disciplinary team are essential in providing optimal care for these patients. A proactive approach in the evaluation of emerging evidence, guidelines and patient case studies will provide the best foundation for effective decision making to ensure patients receive the full benefit from their treatment whilst avoiding cardiotoxicity.

## References

- Dong E, Du H, Gardner L. An interactive web-based dashboard to track COVID-19 in real time. *Lancet Infect Dis* 2020;20:533-4.
- World Health Organization (WHO). Coronavirus disease dashboard; 2020. Available from: <https://COVID19.who.int/> Accessed: 30 October 2020.
- Zhou P, Yang XL, Wang XG, et al. A pneumonia outbreak associated with a new coronavirus of probable bat origin. *Nature* 2020;579:270-3.
- Remuzzi A, Remuzzi G. COVID-19 and Italy: what next?. *Lancet* 2020;395:1225-8.
- Chen N, Zhou M, Dong X, et al. Epidemiological and clinical characteristics of 99 cases of 2019 novel coronavirus pneumonia in Wuhan, China: a descriptive study. *Lancet* 2020;395:507-13.
- Clerkin KJ, Fried JA, Raikhelkar J, et al. COVID-19 and cardiovascular disease. *Circulation* 2020;141:1648-55.
- Guo T, Fan Y, Chen M, et al. Cardiovascular implications of fatal outcomes of patients with coronavirus disease 2019 COVID-19. *JAMA Cardiol* 2020;5:1-8.
- Kuderer NM, Choueiri TK, Shah DP, et al. Clinical impact of COVID-19 on patients with cancer CCC19.: a cohort study. *Lancet* 2020;395:1907-18.
- Santoni M, Guerra F, Conti A, et al. Incidence and risk of cardiotoxicity in cancer patients treated with targeted therapies. *Cancer Treat Rev* 2017;59:123-31.
- Lenneman CG, Sawyer DB. Cardio-oncology: an update on cardiotoxicity of cancer-related treatment. *Circ Res* 2016;118:1008-20.
- Colombo A, Cardinale D. Using cardiac biomarkers and treating cardiotoxicity in cancer. *Future Cardiol* 2013;9:105-18.
- Polk A, Vaage-Nilsen M, Vistisen K, Nielsen DL. Cardiotoxicity in cancer patients treated with 5-fluorouracil or capecitabine: a systematic review of incidence, manifestations and predisposing factors. *Cancer Treat Rev* 2013;39:974-84.
- Yoon GJ, Telli ML, Kao DP, et al. Left ventricular dysfunction in patients receiving cardiotoxic cancer therapies are clinicians responding optimally?. *J Am Coll Cardiol* 2010;56:1644-50.
- Colombo A, Meroni CA, Cipolla CM, Cardinale D. Managing cardiotoxicity of chemotherapy. *Curr Treat Options Cardiovasc Med* 2013;15:410-24.
- Pacher P, Kecskemeti V. Cardiovascular side effects of new antidepressants and antipsychotics: new drugs, old concerns?. *Curr Pharm Des* 2004;10:2463-75.
- Ruane L, Buckley T, Hoo SYS, Hansen PS, et al. Triggering of acute myocardial infarction by respiratory infection. *Intern Med J* 2017;47:522-29.
- Wang D, Hu B, Hu C, et al. Clinical characteristics of 138 hospitalized patients with 2019 novel coronavirus-infected pneumonia in Wuhan, China. *JAMA* 2020;323:1061-9.
- Zheng YY, Ma YT, Zhang JY, Xie X. COVID-19 and the cardiovascular system. *Nat Rev Cardiol* 2020;17:259-60.
- Vakili K, Fathi M, Pezeshgi A, et al. Critical complications of COVID-19: A descriptive meta-analysis study. *Rev Cardiovasc Med* 2020;21:433-42.
- Yonas E, Alwi I, Pranata R, et al. Effect of heart failure on the outcome of COVID-19 - A meta analysis and systematic review. *Am J Emerg Med* 2020;S0735-675720.30602-1.
- Zhang J, Tecson KM, McCullough PA. Endothelial dysfunction contributes to COVID-19-associated vascular inflammation and coagulopathy. *Rev Cardiovasc Med* 2020;21:315-9.
- Zuchi C, Tritto I, Carluccio E, et al. Role of endothelial dysfunction in heart failure. *Heart Fail Rev* 2020;25:21-30.
- Hu H, Ma F, Wei X, Fang Y. Coronavirus fulminant myocarditis saved with glucocorticoid and human immunoglobulin. *Eur Heart J* 2020;ehaa190.
- Zeng JH, Liu YX, Yuan J, et al. First case of COVID-19 complicated with fulminant myocarditis: a case report and insights. *Infection* 2020;1-5.
- O'Laughlin JP, Mehta PH, Wong BC. Life threatening severe QTc prolongation in patient with systemic lupus erythematosus due to hydroxychloroquine. *Case Rep Cardiol*



- 2016;2016:4626279.
26. Zhou F, Yu T, Du R, et al. Clinical course and risk factors for mortality of adult inpatients with COVID-19 in Wuhan, China: a retrospective cohort study. *Lancet* 2020;395:1054-62.
  27. Chorin E, Wadhvani L, Magnani S, et al. QT interval prolongation and torsade de pointes in patients with COVID-19 treated with hydroxychloroquine/azithromycin. *Heart Rhythm* 2020;S1547-5271:30435-5.
  28. Gautret P, Lagier JC, Parola P, et al. Hydroxychloroquine and azithromycin as a treatment of COVID-19: results of an open-label non-randomized clinical trial. *Int J Antimicrob Agents* 2020;56:105949.
  29. Fresse A, Viard D, Romani S, et al. Spontaneous reported cardiotoxicity induced by lopinavir/ritonavir in COVID-19. An alleged past-resolved problem. *Int J Cardiol* 2020 16:S0167-527320.33981-4.
  30. Fan Q, Zhang B, Ma J, Zhang S. Safety profile of the antiviral drug remdesivir: An update. *Biomed Pharmacother* 2020;130:110532.
  31. Fried JA, Ramasubbu K, Bhatt R, et al. The variety of cardiovascular presentations of COVID-19. *Circulation* 2020;141:1930-6.
  32. Huang BH, Wu CH, Hsia CP, Chen CY. Azithromycin-induced torsade de pointes. *Pacing Clin Electrophysiol* 2007;30:1579-82.
  33. Kezerashvili A, Khattak H, Barsky A, et al. Azithromycin as a cause of QT-interval prolongation and torsade de pointes in the absence of other known precipitating factors. *J Interv Card Electrophysiol* 2007;18:243-6.
  34. Mehra MR, Ruschitzka F, Patel AN. Retraction-Hydroxychloroquine or chloroquine with or without a macrolide for treatment of COVID-19: a multinational registry analysis. *Lancet* 2020;395:1820.
  35. Skipper CP, Pastick KA, Engen NW, et al. Hydroxychloroquine in nonhospitalized adults with early COVID-19: a randomized trial. *Ann Intern Med* 2020;173:623-31.
  36. Grein J, Ohmagari N, Shin D, et al. Compassionate use of remdesivir for patients with severe COVID-19. *N Engl J Med* 2020;382:2327-36.
  37. Al-Tawfiq JA, Al-Homoud AH, Memish ZA. Remdesivir as a possible therapeutic option for the COVID-19. *Travel Med Infect Dis* 2020;34:101615.
  38. Olender SA, Perez KK, Go AS, et al. Remdesivir for severe COVID-19 versus a cohort receiving standard of care. *Clin Infect Dis* 2020;ciaa1041.
  39. Wang Y, Zhang D, Du G, et al. Remdesivir in adults with severe COVID-19: a randomised, double-blind, placebo-controlled, multicentre trial. *Lancet* 2020;395:1569-78.
  40. United States National Library of Medicine. Remdesivir COVID-19 trials; 2020. Available from: <https://www.clinicaltrials.gov/ct2/results?cond=COVID19&term=remdesivir&cnt ry=&state=&city=&dist=> Accessed: 20 November 2020.
  41. Cao B, Wang Y, Wen D, et al. A Trial of lopinavir-ritonavir in adults hospitalized with severe COVID-19. *N Engl J Med* 2020;382:1787-99.
  42. Chaubey SK, Sinha AK, Phillips E, et al. Transient cardiac arrhythmias related to lopinavir/ritonavir in two patients with HIV infection. *Sex Health* 2009;6:254-7.
  43. United States National Library of Medicine. Lopinavir/ritonavir COVID-19 trials; 2020. Available from: <https://www.clinicaltrials.gov/ct2/results?cond=COVID19&term=Lopinavir%2Fritonavir&cnt ry=&state=&city=&dist=> Accessed: 20 November 2020.
  44. Shannon A, Selisko B, Le N, et al. Favipiravir strikes the SARS-CoV-2 at its Achilles heel, the RNA polymerase. Preprint. *bioRxiv* 2020;2020.05.15.098731.
  45. Chen C, Huang J, Cheng Z, et al. Favipiravir versus arbidol for COVID-19: a randomized clinical trial. *MedRxiv* 2020 [Epub ahead of print]. <https://doi.org/10.1101/2020.03.17.20037432>.
  46. Cai Q, Yang M, Liu D, et al. Experimental treatment with favipiravir for COVID-19: an open-label control study. *Engine Beijing* 2020 [Epub ahead of print]. <https://doi:10.1016/j.eng.2020.03.007>.
  47. Chinello P, Petrosillo N, Pittalis S, et al. QTc interval prolongation during favipiravir therapy in an Ebola-virus-infected patient. *PLoS Negl Trop Dis* 2017;11:e0006034.
  48. de Salvi Guimarães F, de Moraes WM, Bozi LH, et al. Dexamethasone-induced cardiac deterioration is associated with both calcium handling abnormalities and calcineurin signaling pathway activation. *Mol Cell Biochem* 2017;424:87-98.
  49. Bacchiega BC, Bacchiega AB, Usnayo MJ, et al. Interleukin 6 inhibition and coronary artery disease in a high-risk population: a prospective community-based clinical study. *J Am Heart Assoc* 2017;6:e005038.
  50. Lee DH, Folsom AR, Harnack L, et al. Does supplemental vitamin C increase cardiovascular disease risk in women with diabetes? *Am J Clin Nutr* 2004;80:1194-200.
  51. Guo YR, Cao QD, Hong ZS, et al. The origin, transmission and clinical therapies on coronavirus disease 2019 COVID-19 outbreak - an update on the status. *Mil Med Res* 2020;7:11.
  52. Biran N, Ip A, Ahn J, et al. Tocilizumab among patients with COVID-19 in the intensive care unit: a multicentre observational study. *Lancet Rheumatol* 2020;2:e603-12.
  53. Castagné B, Viprey M, Martin J, et al. Cardiovascular safety of tocilizumab: A systematic review and network meta-analysis. *PLoS One* 2019;14:e0220178.
  54. Ikonomidis I, Pavlidis G, Katsimbri P, et al. Tocilizumab improves oxidative stress and endothelial glycocalyx: A mechanism that may explain the effects of biological treatment on COVID-19. *Food Chem Toxicol* 2020;145:111694.
  55. Sala V, Della Sala A, Hirsch E, Ghigo A. Signaling pathways underlying anthracycline cardiotoxicity. *Antioxid Redox Signal* 2020;32:1098-114.
  56. United States National Library of Medicine. Randomised Evaluation of COVID-19 Therapy RECOVERY. trial NCT04381936; 2020. Available from: <https://clinicaltrials.gov/ct2/show/NCT04381936?cond=NCT04381936&draw=2&rank=1> Accessed: 16 November 2020.
  57. RECOVERY Collaborative Group; Horby P, Lim WS, et al. Dexamethasone in hospitalized patients with COVID-19 - preliminary report. *N Engl J Med* 2020;NEJMoa2021436.
  58. National Health Service NHS. England. COVID-19 therapy: corticosteroids including dexamethasone and hydrocortisone; 2020. Available from: <https://www.england.nhs.uk/publication/COVID-19-therapy-corticosteroids-including-dexamethasone-and-hydrocortisone/> Accessed: 17 November 2020.
  59. Bernal-Mizrachi C, Weng S, Feng C, et al. Dexamethasone induction of hypertension and diabetes is PPAR-alpha dependent in LDL receptor-null mice. *Nat Med* 2003;9:1069-75.
  60. Maxwell SR, Moots RJ, Kendall MJ. Corticosteroids: do they damage the cardiovascular system? *Postgrad Med J* 1994;70:863-70.
  61. Sicard RE, Werner JC. Biochemical correlates of dexamethasone-induced relative cardiomegaly in neonatal rats. *In vivo* 1995;9:75-9.

62. Goodwin JE, Geller DS. Glucocorticoid-induced hypertension. *Pediatr Nephrol* 2012;27:1059-66.
63. Roy SG, De P, Mukherjee D, Chander V, et al. Excess of glucocorticoid induces cardiac dysfunction via activating angiotensin II pathway. *Cell Physiol Biochem* 2009;24:1-10.
64. Souverein PC, Berard A, Van Staa TP, et al. Use of oral glucocorticoids and risk of cardiovascular and cerebrovascular disease in a population based case-control study. *Heart* 2004;90:859-65.
65. Shaikh AY, Shih JA. Chemotherapy-induced cardiotoxicity. *Curr Heart Fail Rep* 2012;9:117-27.
66. Slamon DJ, Leyland-Jones B, Shak S, et al. Use of chemotherapy plus a monoclonal antibody against HER2 for metastatic breast cancer that overexpresses HER2. *N Engl J Med* 2001;344:783-92.
67. Telli ML, Hunt SA, Carlson RW, Guardino AE. Trastuzumab-related cardiotoxicity: calling into question the concept of reversibility. *J Clin Oncol* 2007;25:3525-33.
68. Yeh ET, Bickford CL. Cardiovascular complications of cancer therapy: incidence, pathogenesis, diagnosis, and management. *J Am Coll Cardiol* 2009;53:2231-47.
69. Guglin M, Hartlage G, Reynolds C, et al. Trastuzumab-induced cardiomyopathy: not as benign as it looks? A retrospective study. *J Card Fail* 2009;15:651-7.
70. Seidman A, Hudis C, Pierrri MK, et al. Cardiac dysfunction in the trastuzumab clinical trials experience. *J Clin Oncol* 2002;20:1215-21.
71. Guarneri V, Lenihan DJ, Valero V, et al. Long-term cardiac tolerability of trastuzumab in metastatic breast cancer: the M.D. Anderson Cancer Center experience. *J Clin Oncol* 2006;24:4107-15.
72. Calistri L, Cordopatri C, Nardi C, et al. Sudden cardiac death in a patient with advanced hepatocellular carcinoma with good response to sorafenib treatment: A case report with literature analysis. *Mol Clin Oncol* 2017;6:389-96.
73. Ewer MS, Lippman SM. Type II chemotherapy-related cardiac dysfunction: time to recognize a new entity. *J Clin Oncol* 2005;23:2900-2.
74. Vejpongsa P, Yeh ET. Prevention of anthracycline-induced cardiotoxicity: challenges and opportunities. *J Am Coll Cardiol* 2014;64:938-45.
75. Ewer MS, Ewer SM. Troponin I provides insight into cardiotoxicity and the anthracycline-trastuzumab interaction. *J Clin Oncol* 2010;28:3901-4.
76. Valerio L, Pieruzzi L, Giani C, et al. Targeted therapy in thyroid cancer: state of the art. *Clin Oncol R Coll Radiol* 2017;29:316-24.
77. Porta C, Procopio G, Carteni G, et al. Sequential use of sorafenib and sunitinib in advanced renal-cell carcinoma RCC: an Italian multicentre retrospective analysis of 189 patient cases. *BJU Int* 2011;108:E250-E7.
78. Ellis PM, Coakley N, Feld R, et al. Use of the epidermal growth factor receptor inhibitors gefitinib, erlotinib, afatinib, dacomitinib, and icotinib in the treatment of non-small-cell lung cancer: a systematic review. *Curr Oncol* 2015;22:e183-e215.
79. Hodi FS, O'Day SJ, McDermott DF, et al. Improved survival with ipilimumab in patients with metastatic melanoma. *N Engl J Med* 2010;363:711-23.
80. Robert C, Long GV, Brady B, et al. Nivolumab in previously untreated melanoma without BRAF mutation. *N Engl J Med* 2015;372:320-30.
81. Gettinger SN, Horn L, Gandhi L, et al. Overall survival and long-term safety of nivolumab anti-programmed death 1 antibody, BMS-936558, ONO-4538. in patients with previously treated advanced non-small-cell lung cancer. *J Clin Oncol* 2015;33:2004-12.
82. Orphanos GS, Ioannidis GN, Ardavanis AG. Cardiotoxicity induced by tyrosine kinase inhibitors. *Acta Oncol* 2009;48:964-70.
83. Heinzerling L, Ott PA, Hodi FS, et al. Cardiotoxicity associated with CTLA4 and PD1 blocking immunotherapy. *J Immunother Cancer* 2016;4:50.
84. Kloth JS, Pagani A, Verboom MC, et al. Incidence and relevance of QTc-interval prolongation caused by tyrosine kinase inhibitors. *Br J Cancer* 2015;112:1011-6.
85. Asnani A, Manning A, Mansour M, et al. Management of atrial fibrillation in patients taking targeted cancer therapies. *Cardiooncology* 2017;3:2.
86. Teng AE, Share M, Hsu JJ, et al. Torsades de pointes with pseudo-T wave alternans during rociletinib therapy: A novel manifestation of a rare side effect. *Heart Rhythm Case Rep* 2018;4:490-3.
87. Agarwal M, Thareja N, Benjamin M, et al. Tyrosine kinase inhibitor-induced hypertension. *Curr Oncol Rep* 2018;20:65.
88. Minoia C, Giannoccaro M, Iacobazzi A, et al. Antineoplastic drug-induced bradyarrhythmias. *Expert Opin Drug Saf* 2012;11:739-51.
89. Spechbach H, Morel P, Lorenzini KI, et al. Reversible ventricular arrhythmia induced by dasatinib. *Clin Case Rep* 2013;1:20-5.
90. Sueta D, Suyama K, Sueta A, et al. Lenvatinib, an oral multi-kinases inhibitor, -associated hypertension: potential role of vascular endothelial dysfunction. *Atherosclerosis* 2017;260:116-20.
91. Ghatalia P, Je Y, Kaymakcalan MD, et al. QTc interval prolongation with vascular endothelial growth factor receptor tyrosine kinase inhibitors. *Br J Cancer* 2015;112:296-305.
92. Watanabe H, Ichihara E, Kano H, et al. Congestive heart failure during osimertinib treatment for epidermal growth factor receptor EGFR(-mutant non-small cell lung cancer NSCLC). *Intern Med* 2017;56:2195-7.
93. Maurea N, Spallarossa P, Cadeddu C, et al. A recommended practical approach to the management of target therapy and angiogenesis inhibitors cardiotoxicity: an opinion paper of the working group on drug cardiotoxicity and cardioprotection, Italian Society of Cardiology. *J Cardiovasc Med Hagerstown* 2016;17:S93-S104.
94. Tartarone A, Gallucci G, Lazzari C, et al. Crizotinib-induced cardiotoxicity: the importance of a proactive monitoring and management. *Future Oncol* 2015;11:2043-8.
95. Gettinger SN, Bazhenova LA, Langer CJ, et al. Activity and safety of brigatinib in ALK-rearranged non-small-cell lung cancer and other malignancies: a single-arm, open-label, phase 1/2 trial. *Lancet Oncol* 2016;17:1683-96.
96. Lovly CM, Shaw AT. Molecular pathways: resistance to kinase inhibitors and implications for therapeutic strategies. *Clin Cancer Res* 2014;20:2249-56.
97. Wolchok JD, Hodi FS, Weber JS, et al. Development of ipilimumab: a novel immunotherapeutic approach for the treatment of advanced melanoma. *Ann NY Acad Sci* 2013;1291:1-13.
98. Voskens CJ, Goldinger SM, Loquai C, et al. The price of tumor control: an analysis of rare side effects of anti-CTLA-4 therapy in metastatic melanoma from the ipilimumab network. *PLoS One* 2013;8:e53745.
99. Yun S, Vincelette ND, Mansour I, et al. Late onset ipilimumab-induced pericarditis and pericardial effusion: a rare but life

- threatening complication. *Case Rep Oncol Med* 2015;2015:794842.
100. Geisler BP, Raad RA, Esaian D, et al. Apical ballooning and cardiomyopathy in a melanoma patient treated with ipilimumab: a case of takotsubo-like syndrome. *J Immunother Cancer* 2015;3:4.
  101. Inayat F, Masab M, Gupta S, Ullah W. New drugs and new toxicities: pembrolizumab-induced myocarditis. *BMJ Case Rep* 2018;2018:bcr2017223252.
  102. Semper H, Muehlberg F, Schulz-Menger J, et al. Drug-induced myocarditis after nivolumab treatment in a patient with PDL1-negative squamous cell carcinoma of the lung. *Lung Cancer* 2016;99:117-9.
  103. Yang S, Asnani A. Cardiotoxicities associated with immune checkpoint inhibitors. *Curr Probl Cancer* 2018;42:422-32.
  104. Lancellotti P, Suter TM, López-Fernández T, et al. Cardio-Oncology Services: rationale, organization, and implementation. *Eur Heart J* 2019;40:1756-63.
  105. Al-Shamsi HO, Alhazzani W, Alhurajji A, et al. A practical approach to the management of cancer patients during the novel coronavirus disease 2019 (COVID-19) pandemic: An International Collaborative Group. *Oncologist* 2020;25:e936-e45.
  106. Straus SM, Kors JA, De Bruin ML, et al. Prolonged QTc interval and risk of sudden cardiac death in a population of older adults. *J Am Coll Cardiol* 2006;47:362-7.
  107. Zang J, Wu S, Tang L, et al. Incidence and risk of QTc interval prolongation among cancer patients treated with vandetanib: a systematic review and meta-analysis. *PLoS One* 2012;7:e30353.
  108. Suter TM, Procter M, van Veldhuisen DJ, et al. Trastuzumab-associated cardiac adverse effects in the herceptin adjuvant trial. *J Clin Oncol* 2007;25:3859-65.
  109. Nousiainen, T, Jantunen E, Vanninen E, Hartikainen J. Early decline in left ventricular ejection fraction predicts doxorubicin cardiotoxicity in lymphoma patients. *Br J Cancer* 2002;86:1697-700.
  110. Kumar S, Marfatia R, Tannenbaum S, et al. Doxorubicin-induced cardiomyopathy 17 years after chemotherapy. *Tex Heart Inst J* 2012;39:424-7.
  111. Ewer MS, Ewer SM. Cardiotoxicity of anticancer treatments. *Nat Rev Cardiol* 2015;12:547-58.
  112. Lipshultz SE, Alvarez JA, Scully RE. Anthracycline associated cardiotoxicity in survivors of childhood cancer. *Heart* 2008;94:525-33.
  113. Wojtacki J, Lewicka-Nowak E, Leśniewski-Kmak K. Anthracycline-induced cardiotoxicity: clinical course, risk factors, pathogenesis, detection and prevention—review of the literature. *Med Sci Monit* 2000;6:411-20.
  114. Tassan-Mangina S, Codorean D, Metivier M, et al. Tissue Doppler imaging and conventional echocardiography after anthracycline treatment in adults: early and late alterations of left ventricular function during a prospective study. *Eur J Echocardiogr* 2006;7:141-6.
  115. Tsai HR, Gjesdal O, Wethal T, et al. Left ventricular function assessed by two-dimensional speckle tracking echocardiography in long-term survivors of Hodgkin's lymphoma treated by mediastinal radiotherapy with or without anthracycline therapy. *Am J Cardiol* 2011;107:472-7.
  116. Doctor-approved patient information from American Society of Clinical Oncology (ASCO). *Childhood Cancer: Statistics*; 2020. Available from: <https://www.cancer.net/cancer-types/childhood-cancer/statistics> Accessed: 17 November 2020.
  117. Lipshultz SE, Adams MJ, Colan SD, et al. Long-term cardiovascular toxicity in children, adolescents, and young adults who receive cancer therapy: pathophysiology, course, monitoring, management, prevention, and research directions: a scientific statement from the American Heart Association. *Circulation* 2013;128:1927-95.
  118. van der Pal HJ, van Dalen EC, Hauptmann M, et al. Cardiac function in 5-year survivors of childhood cancer: a long-term follow-up study. *Arch Intern Med* 2010;170:1247-55.
  119. Riphagen S, Gomez X, Gonzalez-Martinez C, et al. Hyperinflammatory shock in children during COVID-19 pandemic. *Lancet* 2020;395:1607-8.
  120. Tay MZ, Poh CM, Rénia L, et al. The trinity of COVID-19: immunity, inflammation and intervention. *Nat Rev Immunol* 2020;20:363-74.
  121. Domercant J, Polin N, Jahangir E. Cardio-oncology: a focused review of anthracycline-, human epidermal growth factor receptor 2 inhibitor-, and radiation-induced cardiotoxicity and management. *Ochsner J* 2016;16:250-6.
  122. Hong RA, Iimura T, Sumida KN, Eager RM. Cardio-oncology/onco-cardiology. *Clin Cardiol* 2010;33:733-7.
  123. He Y, Thummuri D, Zheng G, et al. Cellular senescence and radiation-induced pulmonary fibrosis. *Transl Res* 2019;209:14-21.
  124. Zamorano JL, Lancellotti P, Rodriguez Muñoz D, et al. 2016 ESC Position Paper on cancer treatments and cardiovascular toxicity developed under the auspices of the ESC Committee for Practice Guidelines: The Task Force for cancer treatments and cardiovascular toxicity of the European Society of Cardiology ESC. *Eur Heart J* 2016;37:2768-801.
  125. Ferrario CM, Jessup J, Chappell MC, et al. Effect of angiotensin-converting enzyme inhibition and angiotensin II receptor blockers on cardiac angiotensin-converting enzyme 2. *Circulation* 2005;111:2605-10.
  126. Karram T, Abbasi A, Keidar S, et al. Effects of spironolactone and eprosartan on cardiac remodeling and angiotensin-converting enzyme isoforms in rats with experimental heart failure. *Am J Physiol Heart Circ Physiol* 2005;289:1351-8.
  127. Ishiyama Y, Gallagher PE, Averill DB, et al. Upregulation of angiotensin-converting enzyme 2 after myocardial infarction by blockade of angiotensin II receptors. *Hypertension* 2004;43:970-6.
  128. Danser AHJ, Epstein M, Batlle D. Renin-angiotensin system blockers and the COVID-19 pandemic: at present there is no evidence to abandon renin-angiotensin system blockers. *Hypertension* 2020;75:1382-5.
  129. European Society of Cardiology (ESC). Position statement of the ESC Council on hypertension on ACE-inhibitors and angiotensin receptor blockers; 13 March 2020. Available from: <https://www.escardio.org/Councils/Council-on-Hypertension-CHT./News/position-statement-of-the-esc-council-on-hypertension-on-ace-inhibitors-and-ang> Accessed: 5 August 2020.
  130. International Society of Hypertension ISH. A statement from the International Society of Hypertension on COVID-19; 2020. Available from: <https://ish-world.com/news/a/A-statement-from-the-International-Society-of-Hypertension-on-COVID-19/> Accessed: 5 August 2020.
  131. Grover A, Oberoi M. A systematic review and meta-analysis to evaluate the clinical outcomes in COVID-19 patients on angiotensin-converting enzyme inhibitors or angiotensin receptor blockers. *Eur Heart J Cardiovasc Pharmacother* 2020;pvaa064.
  132. European Society of Cardiology ESC. Council of Cardio-



- Oncology. Routine cardiotoxicity echo screening for chemotherapy patients during COVID-19; 2020. Available from: <https://www.escardio.org/Councils/council-of-cardio-oncology/News/routine-cardiotoxicity-echo-screening-for-chemotherapy-patients-during-COVID-19> Accessed: 10 November 2020.
133. Barros-Gomes S, Herrmann J, Mulvagh SL, et al. Rationale for setting up a cardio-oncology unit: our experience at Mayo Clinic. *Cardio-Oncology* 2016;2:5.
  134. Fradley MG, Brown AC, Shields B, et al. Developing a comprehensive cardio-oncology program at a Cancer Institute: The Moffitt Cancer Center Experience. *Oncol Rev* 2017;11:340.
  135. Virani SA, Dent S, Brezden-Masley C, et al. Canadian Cardiovascular Society Guidelines for Evaluation and Management of Cardiovascular Complications of Cancer Therapy. *Can J Cardiol* 2016;32:831-41.
  136. López-Fernández T, García AM, Beltrán AS, et al. Cardio-Onco-Hematology in Clinical Practice. Position Paper and Recommendations. *Rev Esp Cardiol Engl (Ed)*. 2017;70:474-86.
  137. Jenkins C, Bricknell K, Hanekom L, Marwick TH. Reproducibility and accuracy of echocardiographic measurements of left ventricular parameters using real-time three-dimensional echocardiography. *J Am Coll Cardiol* 2004;44: 878-86.
  138. Kalam K, Otahal P, Marwick TH. Prognostic implications of global LV dysfunction: a systematic review and meta-analysis of global longitudinal strain and ejection fraction. *Heart*. 2014;100:1673-80.

Non-commercial use only