

Clinical Hospital Centre Zagreb, Department of obstetrics and Gynecology

## A CASE OF SEPTATE UTERUS WITH DOUBLE CERVIX AND LONGITUDINAL SEPTUM OF VAGINA

*Držislav Kalafatić, Mihajlo Strelec, Vladimir Banović**Case report**Keywords:* Mullerian anomalies, cervical duplication, vaginal septum, hysteroscopy

**SUMMARY.** The incidence of Mullerian duct anomalies is around 3% in patients with infertility or poor reproductive outcomes. Most Mullerian duct anomalies are associated with a single cervix. However, double cervix can also be associated with bicornuate and septate uterus. We present a rare case of patient with septate uterus, double cervix and longitudinal septum of the vagina, successfully treated by hysteroscopy and laparoscopy with subsequent successful pregnancy outcome.

### Introduction

Mullerian duct anomalies occur as a result of errors in embryogenesis and include uterine, cervical and vaginal anomalies. They result from the improper development and fusion of the embryological Mullerian ducts (1). The incidence of the anomalies, according to literature data, varies from 1 to 10%, although the real incidence is probably around 1% in general population and 3% in patients with infertility or poor reproductive results (2).

Most Mullerian duct anomalies are associated with a single cervix. The classical theory of Mullerian development suggests unidirectional caudal to cephalic fusion of the Mullerian ducts and later absorption of the resulting septum (3). The unidirectional theory therefore suggests that a double cervix should occur only with uterus didelphys. However, double cervix can also be associated with bicornuate and septate uterus which reinforces the alternative bidirectional theory of Mullerian ducts fusion (2, 4–5).

We present a rare case of patient with septate uterus, double cervix and longitudinal septum of the vagina.

### Case report

A 33-year-old nullipara presented with infertility. She also had diabetes mellitus type I and history of one spontaneous abortion in the 9th week of pregnancy. Gynecological examination revealed a large longitudinal vaginal septum with a well-formed cervix on the left and a slightly smaller, hypotrophic cervix on the right side. On examination it was clear that entry into the left hemivagina was favored. Ultrasound and magnetic resonance imaging (MRI) revealed a smooth fundus with a complete uterine septum and cervical duplication (*Figure 1*). No urologic anomalies were noted. The patient underwent surgery, whereby first the thick vaginal septum was resected with harmonic knife. Diagnostic laparoscopy revealed normally placed fallopian tubes and ovaries. A slight concavity on the uterine fundus was

noted and pressure applied with a blunt instrument suggested dense myometrium beneath the concavity. Hysteroscopy was then performed. The uterine cavity was entered through the better-developed left cervix with a Foley catheter inserted through the right cervix into the right uterine cavity. The 9-mm resectoscope was then inserted through the left cervix and uterine septum was perforated at the level of isthmus until the balloon of the Foley catheter was clearly visible. The balloon also served to prevent leakage of the distending fluid through the right cervix during hysteroscopy. The resection of the remaining part of the septum was then continued until the uterine fundus was reached, under continuous laparoscopic control.

The patient conceived spontaneously 3 months after surgery and the healthy eutrophic baby was born by caesarean section in the 39th week of pregnancy.

### Discussion

We described a rare case of an unusual Mullerian duct anomaly, completely septated uterus with a communicating double cervix and a complete longitudinally septated vagina.

When a patient is seen with a double cervix, uterus didelphys is usually considered as the most common Mullerian anomaly (6). However, double cervix can also be diagnosed with septate uterus and rarely with bicornuate uterus (7). Surprisingly, according to Smith et al, a slightly higher frequency of septate uterus (50%) vs uterus didelphys (42%) was found in a series of 64 patients with double cervix (8). In patients with uterus didelphys a true double cervix is usually present, suggesting that each cervix is derived from a separate paramesonephric duct. In patients with septate uterus, one cervix is usually divided into two parts by a septum, although the true double cervix has also been reported in patients with septate uterus (9). We believe that our patient had true double cervix, as we found two thick cervical canals significantly diverging at their inferior margin.

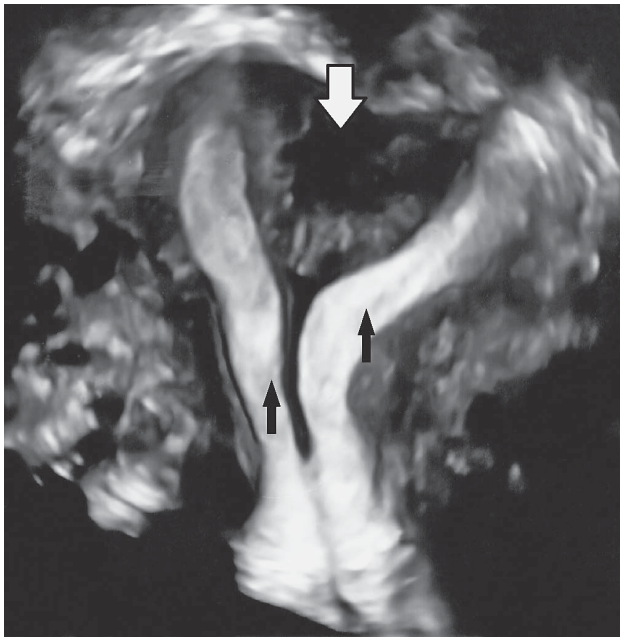


Figure 1. Axial ultrasound image demonstrating double uterine cavities (black arrows) and uterine septum (white arrow)

Magnetic resonance imaging is usually considered as modality of choice for the diagnosis of uterine anomalies, with a high correlation with surgical findings (10). Lin et al. found that MRI correctly differentiated the type of Mullerian anomaly in 96% of patients (11). Jurkovic et al. reported even higher reliability of 3D ultrasonography, reaching the sensitivity and specificity of 100% (12).

There are several challenges regarding treatment of this anomaly. Mullerian anomalies can be associated with both normal and adverse reproductive outcomes. Previous reports have advocated routine resection of uterine septum (13). However, according to Pavone et al, in the absence of a history of poor reproductive outcomes, the risk of uterine perforation, scarring or cervical incompetence did not warrant the additional procedure, except the resection of vaginal septum (14). In a series of 33 patients with uterine septum, Grimbizis et al. reported that 63,6% conceived after hysteroscopic resection of septum (15). Lavergne et al. found that the septate uterus was associated with a lowered rate of embryo implantation and that the implantation rate improves with the resection of uterine septum. The septate uterus can obviously impair normal reproductive performance by increasing the chance of early and late abortions and preterm deliveries, although there are documented cases of full-term vaginal deliveries after resection of vaginal septum only (16).

Since our patient had a history of early pregnancy loss and infertility, we decided to treat her anomaly surgically and spontaneous pregnancy occurred three months later. We believe that operative hysteroscopy with concomitantly performed laparoscopy for better evaluation of uterine morphology, assessment of tubo-

ovarian status and prevention of uterine perforation is a safe surgical procedure that should be offered to patients with this anomaly and previous poor reproductive outcomes, due to its relative simplicity, safety and satisfactory final anatomic result.

## Literature

1. Zlopaša G, Škrablin S, Kalafatić D, Banović V, Lešin J. Uterine anomalies and pregnancy outcome following resectoscopy metroplasty. *Int J Gynaecol Obstet* 2007;98:129–33.
2. Troiano RN, McCarthy SM. Mullerian duct anomalies: imaging and clinical issues. *Radiology* 2004;233:19–34.
3. Crosby WM, Hill EC. Embryology of the Mullerian duct system. *Obstet Gynecol* 1962;20:507–15.
4. Byrne J, Nussbaum-Blask A, Taylor WS, et al. Prevalence of Mullerian duct anomalies detected at ultrasound. *Am J Med Genet* 2000;94:9–12.
5. Hundley AF, Fielding JR, Hoyte L. Double cervix and vagina with septate uterus: an uncommon Mullerian malformation. *Obstet Gynecol* 2001;98:982–5.
6. Chang AS, Siegel CL, Moley KH, Ratts VS, Odem RR. Septate uterus with cervical duplication and longitudinal vaginal septum: a report of five new cases. *Fertil Steril* 2004;81:1133–6.
7. Acien P, Acien M, Sanchez-Ferrer ML. Mullerian anomalies „without a classification“: from the didelphys unicollis uterus to the bicervical uterus with or without septate vagina. *Fertil Steril* 2009;91:2369–75.
8. Smith BC, Brown DL, Carter RE, Famuyide AO. Double cervix: clarifying a diagnostic dilemma. *Am J Obstet Gynecol* 2014;211:26
9. Gant NF, Cunningham FG, Bradshaw KD. Basic gynecology and obstetrics. Norwalk, CT: Appleton & Lange; 1993.
10. Olpin JD, Helbrun M. Imaging of Mullerian duct anomalies. *Clin Obstet Gynecol* 2009;52:40–56.
11. Lin PC, Kunwar PB, Nettleton GS, Nakajima ST. Female genital anomalies affecting reproduction. *Fertil Steril* 2002;78: 899–915.
12. Jurkovic D, Geipel A, Gruboeck K, Jauniaux E, Natucci R, Campbell S. Three-dimensional ultrasound for the assessment of uterine anatomy and detection of congenital anomalies: a comparison with hysterosalpingography and two-dimensional sonography. *Ultrasound Obstet Gynecol* 1995;5:233–7.
13. Wai C, Zekam N, Sanz L. Septate uterus with double cervix and longitudinal vaginal septum. *J Reprod Med* 2001;46: 613–7.
14. Pavone ME, King JA, Vlahos N. Septate uterus with cervical duplication and a longitudinal vaginal septum: a Mullerian anomaly without a classification. *Fertil Steril* 2006;85:494.
15. Grimbizis GF, Camus M, Tarlatzis BC, Bontis JN, Devroey P. Clinical implications of uterine malformations and hysteroscopic treatment results. *Hum Reprod Update* 2001;7: 161–74.
16. Lavergne N, Aristizabal J, Zarka V, Erny R, Hedon B. Uterine anomalies and in vitro fertilization: what are the results? *Eur J Obstet Gynecol Reprod Biol* 1996;68:29–34.

Corresponding address: Držislav Kalafatić, University Hospital Centre Zagreb, Department of Obstetrics and Gynecology, Petrova ulica 13, 10 000 Zagreb, Croatia

Paper received: April 12 2018; accepted: May 15 2018.

Klinika za ženske bolesti i porode, Klinički bolnički centar Zagreb

## **PRIKAZ SLUČAJA PACIJENTICE SA SEPTUMOM MATERNICE, DVOSTRUKIM CERVIKSOM I UZDUŽNIM SEPTUMOM VAGINE**

*Držislav Kalafatić, Mihajlo Strelec, Vladimir Banović*

*Prikaz slučaja*

*Ključne riječi:* prirodene anomalije maternice, septum rodnice, dvostruki vrat maternice, histeroskopija

**SAŽETAK.** Prirodene uterine anomalije nastaju zbog nepravilnog razvoja i spajanja Mullerovih cijevi tijekom embriogeneze. Njihova učestalost u općoj populaciji procjenjuje se na oko 1%, dok je učestalost u populaciji infertilnih pacijentica i pacijentica s nepovoljnim reprodukcijским ishodom čak trostruko viša. U većine anomalija prisutan je jedan vrat maternice, premda je i dvostruki vrat maternice moguće naći u slučajevima dvoroge ili septirane maternice, što dodatno afirmira alternativnu tezu o dvosmjernoj fuziji Mullerovih kanala u embriogenezi. Prikazat ćemo rijedak slučaj pacijentice sa septiranom maternicom, dvostrukim vratom maternice i uzdužnim septumom rodnice, koju smo uspješno liječili histeroskopijom i laparoskopijom, s kasnijim urednim tijekom i uspješnim ishodom trudnoće.