

Left ventricular unloading using a percutaneous paracorporeal left ventricular assist device – University Hospital Centre Zagreb experience

 **Dubravka Šipuš***,
 **Ivo Planinc**,
 **Boško Skorić**,
 **Vedran Velagić**,
 **Daniel Lovrić**,
 **Hrvoje Jurin**,
 **Marijan Pašalić**,
 **Jure Samardžić**,
 **Jana Ljubas Maček**,
 **Hrvoje Gašparović**,
 **Bojan Biočina**,
 **Davor Miličić**,
 **Maja Čikeš**

University of Zagreb School of Medicine, University Hospital Centre Zagreb, Zagreb, Croatia

KEYWORDS: cardiogenic shock, extracorporeal membrane oxygenation, ProtekSolo, left ventricular unloading.

CITATION: *Cardiol Croat.* 2021;16(1-2):31-2. | <https://doi.org/10.15836/ccar2021.31>

***ADDRESS FOR CORRESPONDENCE:** Dubravka Šipuš, Klinički bolnički centar Zagreb, Kišpatičeva 12, HR-10000 Zagreb, Croatia. / Phone: +385-91-7344878 / E-mail: dubravka.sipus@gmail.com

ORCID: Dubravka Šipuš, <https://orcid.org/0000-0002-5631-0353> • Ivo Planinc, <https://orcid.org/0000-0003-0561-6704> • Boško Skorić, <https://orcid.org/0000-0001-5979-2346> • Vedran Velagić, <https://orcid.org/0000-0001-5425-5840> • Marijan Pašalić, <https://orcid.org/0000-0002-3197-2190> • Hrvoje Jurin, <https://orcid.org/0000-0002-2599-553X> • Daniel Lovrić, <https://orcid.org/0000-0002-5052-6559> • Jure Samardžić, <https://orcid.org/0000-0002-9346-6402> • Jana Ljubas Maček, <https://orcid.org/0000-0001-7171-2206> • Hrvoje Gašparović, <https://orcid.org/0000-0002-2492-3702> • Bojan Biočina, <https://orcid.org/0000-0003-3362-9596> • Davor Miličić, <https://orcid.org/0000-0001-9101-1570> • Maja Čikeš, <https://orcid.org/0000-0002-4772-5549>

Background: Venous-arterial extracorporeal membrane oxygenation (VA-ECMO) is widely used in refractory cardiogenic shock and cardiac arrest but is characterized by increased left ventricular (LV) afterload and consequent development of pulmonary oedema (ECMO lungs). The ProtekSolo™ (LivaNova, IT) cannula is inserted via the right femoral vein to the left atrium, by a trans-septal puncture (under the guidance of transesophageal echocardiography and fluoroscopy). This bypasses the LV by draining blood from the left atrium to a paracorporeal pump (eg Rotaflow pump (Maquet, DE)) and returning it via a femoral artery cannula, thus providing direct unloading of LV.¹⁻³ We aimed to demonstrate our experience with the paracorporeal LV assist device using the ProtekSolo cannula and Rotaflow pump (Psp-LVAD).

Patients and Methods: 7 adult patients underwent Psp-LVAD placement in UHC Zagreb from January to December 2020. We divided the patients in two groups: those who required Psp-LVAD to treat ECMO

TABLE 1. Baseline characteristics.

N	7	N	7
Mean age (years)	56±9.3	Heart rate (beats/min)	90 (85-125)
Sex (male %)	7 (100 %)	Urinary output hourly (ml/h)	100 (15-180)
Mean BMI (kg/m ²)	25.5±2.9	Laboratory values	
Aetiology of cardiogenic shock		Lactate (mmol/L)	2.1 (0.4-4.8)
Worsening of chronic heart failure	4 (57.1%)	BUN (mmol/L)	11.5 (1.9-19.7)
Acute coronary syndrome	3 (42.9%)	Creatinine (umol/L)	91 (61-133)
Duration of disease		AST (IU/L)	193 (19-2132)
Cardiomyopathy (years)	8±5.3	ALT (IU/L)	75 (17-566)
Acute coronary syndrome (days)	5±6	NTproBNP (ng/L)	8118 (41-26245)
SAVE score	-3 (-13, 6)	Inotropic or vasopressor therapy before PSp-LVAD placement	
VA-ECMO prior to PSp-LVAD	5 (71.4%)	Dobutamine	4 (57.1%)
ECMO lungs	4 (57.1%)	Milrinone	3 (42.9%)
Infection prior to VA-ECMO	4 (57.1%)	Levosimendan	4 (57.1%)
Mean arterial pressure (mmHg)	76 (60-79)	Norepinephrine	5 (71.4%)

BMI: body mass index, SAVE: Survival After Venous-arterial Ecmo, VA-ECMO: venous-arterial extra corporeal membrane oxygenation, PSp-LVAD: Protek Solo paracorporeal left ventricular assist device, BUN: blood urea nitrogen, AST: aspartate transaminase, ALT alanine transaminase, NTproBNP: N-terminal prohormone of brain natriuretic peptide.

RECEIVED:
December 14, 2020

ACCEPTED:
December 18, 2020



TABLE 2. Outcomes.

	ECMO lungs before PSp-LVAD (N=4)	No ECMO lungs before PSp-LVAD (N=3)
30-day mortality	3 (75%)	1 (33%)
Survival to decannulation	1 (25%)	1 (33%)
Mean PSp-LVAD days	11±5	32.5±12
VA-ECMO prior to PSp-LVAD	4 (100%)	1 (33%)
Removal of oxygenator	2 (50%)	3 (100%)
Durable LVAD implantation	0 (0%)	1 (33%)
Complications		
Infective	4 (100%)	1 (33%)
Bleeding	2 (50%)	1 (33%)

VA-ECMO: veno-arterial extra corporeal membrane oxygenation, PSp-LVAD: Protek Solo paracorporeal left ventricular assist device, LVAD: left ventricular assist device.

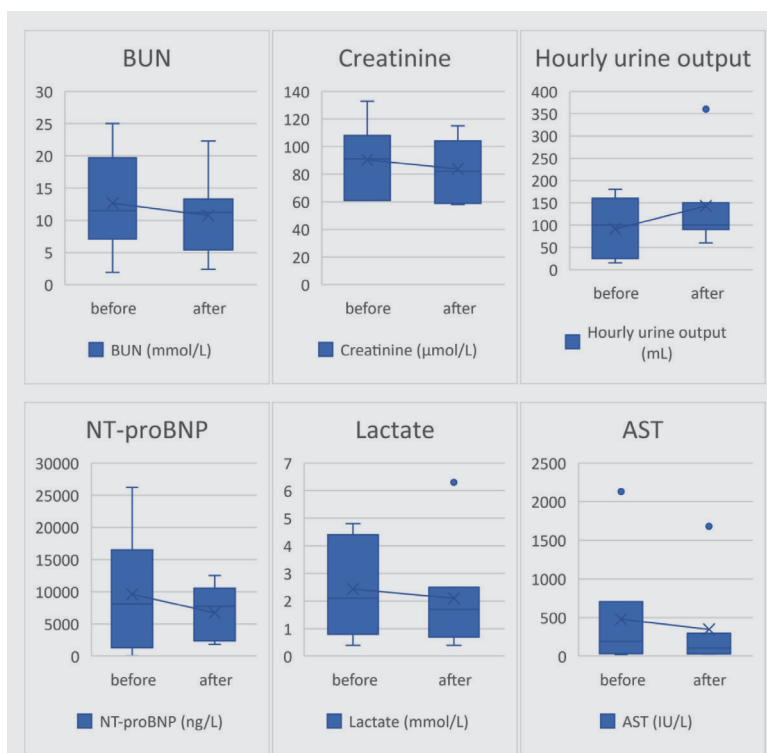


FIGURE 1. Laboratory values before and after Protek Solo paracorporeal left ventricular assist device placement.

BUN: blood urea nitrogen, NTproBNP: N-terminal prohormone of brain natriuretic peptide, AST: aspartate transaminase.

lungs (n=4) and those who received PSp-LVAD implantation prior to developing ECMO lungs (n=3). In addition to the description of the treated patients, we also assessed 30-day all-cause mortality.

Results: The baseline characteristics of patients are shown in **Table 1**. All patients were male, mean age 56±9.3 years. 57.1% of patients underwent PSp-LVAD placement due to worsening of chronic heart failure and 42.9% due to acute coronary syndrome. Concurrent infection was present in 57.1% of patients. 71.4% were first on VA-ECMO support, of those 80% developed ECMO lungs. Laboratory tests (**Figure 1**) show improvement in kidney and liver function after PSp-LVAD placement. Outcomes are shown in **Table 2**; patients in prophylactic group have lower observed 30-day mortality rate (33% vs 75%) and longer VA-ECMO support duration due to lower mortality. Besides 2 patients who are still in active treatment, all others died during initial hospitalization due to infective complications, predominantly those that had a concurrent infection upon institution of the PSp-LVAD.

Conclusion: Pulmonary edema (ECMO lungs) due to increased LV afterload is a major complication of VA-ECMO. Prophylactic LV unloading by PSp-LVAD seems associated with lower 30-days mortality.

LITERATURE

- Russo JJ, Aleksova N, Pitcher I, Couture E, Parlow S, Faraz M, et al. Left Ventricular Unloading During Extracorporeal Membrane Oxygenation in Patients With Cardiogenic Shock. *J Am Coll Cardiol*. 2019 Feb 19;73(6):654-662. <https://doi.org/10.1016/j.jacc.2018.10.085>
- Meani P, Gelsomino S, Natour E, Johnson DM, Rocca HB, Pappalardo F, et al. Modalities and Effects of Left Ventricle Unloading on Extracorporeal Life Support: a Review of the Current Literature. *Eur J Heart Fail*. 2017 May;19 Suppl 2:84-91. <https://doi.org/10.1002/ejhf.850>
- Na SJ, Yang JH, Yang JH, Sung K, Choi JO, Hahn JY, Jeon ES, Cho YH. Left heart decompression at venoarterial extracorporeal membrane oxygenation initiation in cardiogenic shock: prophylactic versus therapeutic strategy. *J Thorac Dis*. 2019 Sep;11(9):3746-3756. <https://doi.org/10.21037/jtd.2019.09.35>