

*Original Article***SEJODR**

# Relationship between the skeletal position of maxilla and rapid maxillary expansion failure

*Fatih Celebi\**; *Sibel Akbulut\***Department of Orthodontics, Faculty of Dentistry, Tokat Gaziosmanpasa University, Tokat, Turkey***ABSTRACT**

**Introduction:** The palatal expansion may be a challenging treatment in late adolescents who has passed the peak of skeletal growth. The success rate of palatal expansion in these patients decreases due to decreased growth potential.

**Aim:** The aim of this study was to determine whether there is a predictor that can be used in the failure of rapid maxillary expansion (RME) among investigated five cephalometric variables (related to maxillary position) and three other variables.

**Materials and methods:** The records of the patients who had undergone RME therapy between 2013-2019 were evaluated. The patients were allocated into two groups according to expansion success: successful (S-RME) and failed (F-RME) RME groups. Fifty systemically healthy patients in the cervical vertebral maturation stage 5/6 were enrolled (35 females, 15 males). Eleven patients were (10 females, one male) in the F-RME group, and 39 patients were (25 females, 14 males) in the S-RME group. Five cephalometric variables (related to maxillary position) and three other variables (age, gender, and CVMS) were evaluated. Variables were subjected to multiple logistic regression analysis for setting a prediction model and detecting predictors.

**Results:** Patients with CVMS-6 had a 16.8-fold higher risk of palatal expansion failure than CVMS-5. 1 mm anterior position of PNS increased the risk of failure 2.9 times. 1 mm reduction in the distance between the PNS and cranial base in the vertical direction increased 60% the risk of RME failure.

**Conclusion:** The CVM stage of the patient, along with the vertical and sagittal position of the PNS, were found to be the possible predictors of RME success in late adolescence.

*F. Celebi, S. Akbulut. Relationship between the skeletal position of maxilla and rapid maxillary expansion failure. South Eur J Orthod Dentofac Res. 2020;7(2):49-54.*

**INTRODUCTION**

Transverse maxillary deficiency is one of the common skeletal disorders. The treatment includes nonsurgical and surgical treatment modalities. Rapid maxillary expansion (RME) is a method for correcting the transverse skeletal deficiency, which involves heavy force application to the maxilla transversally. The response to this force usually results in the separation of the maxillary halves by rupturing the mid-palatine suture.

RME can be successfully achieved in pre-adolescent and

adolescent periods without any surgical intervention due to the immature structure of the sutures. In adulthood, the maturation of the mid-palatal suture, along with the circummaxillary sutures, causes resistance to the expansion.<sup>1,2</sup> The surgical assistance in the RME procedure (SARME) is the valid treatment option for these patients until sufficient evidence occurs that nonsurgical or bone-anchored RME treatments are feasible. However, the surgical approach requirement is a critical decision since the failure of RME without surgery causes further tissue destruction and complications such as mucosal ulceration or necrosis, accentuated buccal tooth tipping, gingival recession and severe pain around the posterior teeth.<sup>3-5</sup> On the other hand, surgery preference in a case that could be treated without surgical assistance would make the patient suffer from an unnecessary operation, which is invasive, costly, and includes surgical risks.

**Corresponding Author:***Fatih Celebi**Department of Orthodontics,**Faculty of Dentistry,**Tokat Gaziosmanpasa University,**60100 Tokat, Turkey**E-mail: fatihcelebi5860@gmail.com*

In clinical practice, chronological age is a commonly used predictor to determine which option (conventional RME or SARME) would be more appropriate. However, there is no consensus in the literature on which age SARME should be performed. In different studies, 14, 16, 20, and 25 years of age were presented as the cut-off point between the conventional RME and SARME.<sup>6-9</sup> Moreover, there are confusing studies showing successful suture opening in advanced age by using conventional RME.<sup>10-12</sup> Instead of age, Revelo and Fishman<sup>13</sup> advised using occlusal radiographs for detecting the ossification degree of the mid-palatal suture. This technique's main disadvantage is that the mid-palatal suture cannot be evaluated correctly due to surrounding bone superposition.<sup>14</sup> On the other hand, the maturation, shape, and density of mid-palatal suture could be detected using CBCT.<sup>15,16</sup> However, CBCT has not yet been included in routine orthodontic practice due to its drawbacks, such as extra radiation dose and cost.<sup>17</sup> Furthermore, determining the ossification degree of the mid-palatal suture may not be a useful tool to predict the success rate of RME since ossification of the mid-palatal suture is not always the case for the resistance.<sup>18</sup>

There is a lack of a valid and reliable method for predicting the success/failure of conventional RME in late adolescence or early adulthood. The purpose of the present study was to investigate possible variables that can be used as a predictor in the failure of the conventional RME.

## MATERIALS AND METHODS

The present study was designed as a retrospective clinical study with the involvement of radiological and clinical evaluations. The study protocol was reviewed and approved by the university's clinical research ethics committee (study number: 83116987-297). The patients referred to the orthodontic clinic between the years 2013-2019 were searched (a total of 3000 patients), and the records of patients who had conventional RME therapy were recruited. The exclusion criteria were; lack of full patient record, presence of any systemically skeletal disease or condition affecting the skeletal development of the patient.

A total of 315 patient records were obtained and subjected to the inclusion criteria as follows: 1) Caucasian ancestry, 2) being between the ages of 13 - 17 years at the beginning of the RME procedure, 3) applied acrylic bonded RME appliance (Figure 1) as an expander, 4) to have an adequate quality of pre-treatment lateral cephalograms.

Written informed consent forms were obtained from the patients fulfilling the inclusion criteria and who accepted the use of their records in the study. As a result, a total of 72 patients were included in the study, and they were divided into two groups regarding the success of RME therapy:-successful RME (S-RME) and failed RME (F-RME). The patients whose maxillary expansion protocol had to be terminated due to

severe pain and severe palatal mucosal ulceration (Figure 2), and in which the sutural resistance was inspected on occlusal radiographs allocated to the F-RME group. RME patients with 35 - 45 quarter-turns screw activation without any complications and in which the sutural opening was confirmed by occlusal radiographs were included in the S-RME group.

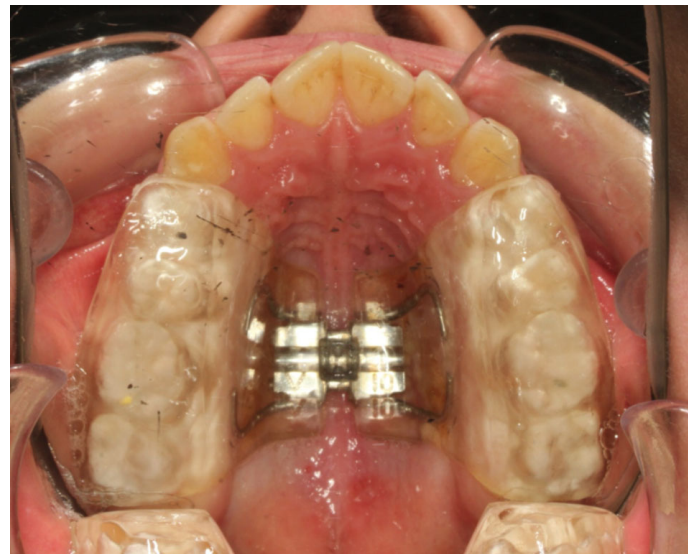

Figure 1. Occlusal view of an acrylic bonded RME appliance.

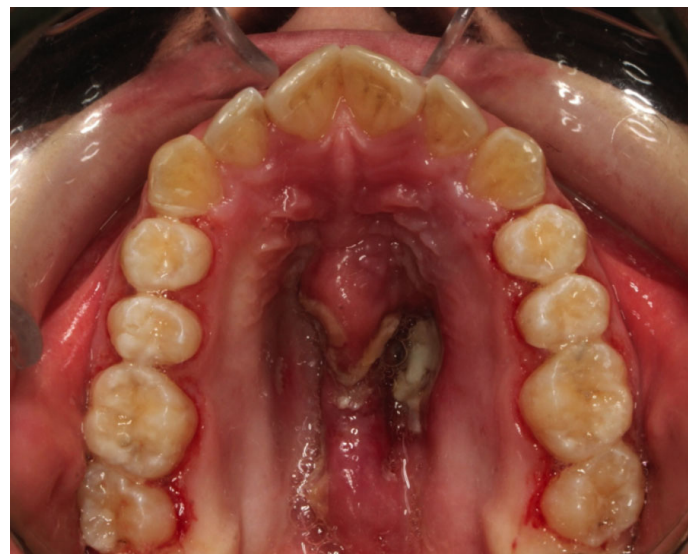

Figure 2. Mucosal ulceration after the activation of the RME screw.

The skeletal maturation of the participants in both groups was examined according to the cervical vertebral maturation (CVM) method<sup>19</sup> using pre-treatment lateral cephalometric radiographs. In the F-RME group, all patients were found to be at the CVM stages 5 and 6. Consequently, to standardize the groups, patients who were not at CVM stages 5 and 6 were excluded from the S-RME group. Finally, the records of 11 patients (10 females,

one male) in the F-RME group and 39 patients (25 females, 14 males) in the S-RME group were evaluated.

Pre-treatment lateral cephalometric radiographs of all participants were traced and analyzed using the Dolphin Imaging software (Dolphin Imaging & Management Solutions, Chatsworth, CA, USA). The lateral cephalometric analysis was performed based on the previously described basicranial reference system<sup>20</sup> comprising two perpendicular lines. The two perpendicular lines were the stable basicranial line (SBL) and the vertical T line. SBL is tangent to the lamina cribrosa of the ethmoid and passes through the superior point of the anterior wall of the sella turcica at the junction with tuberculum sella (point T). Vert T is perpendicular to SBL and passes through point T. In this study, SBL and vertical T line were designated as the horizontal reference plane (HR) and vertical reference plane (VR), respectively (Figure 3). The sagittal and vertical position of the maxilla and the inclination of the palatal plane were evaluated based on these reference planes. The cephalometric variables were described in Table 1.

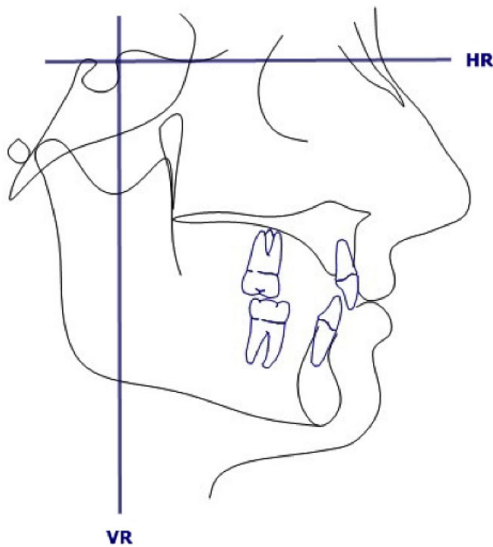


Figure 3. Horizontal (HR) and vertical (VR) reference planes used in the study.

Table 1. The variables which the location and inclination of the maxilla are evaluated.

LATERAL CEPHALOMETRIC MEASUREMENTS	
1. VR-ANS (mm)	Distance between vertical reference plane to ANS
2. VR-PNS (mm)	Distance between vertical reference plane to PNS
3. HR-ANS (mm)	Distance between horizontal reference plane to ANS
4. HR-PNS (mm)	Distance between horizontal reference plane to PNS
5. HR/PP (°)	Angle between horizontal reference plane and palatal plane

### Calibration of examiner

An experienced blind researcher performed all cephalometric analysis. Eight weeks after completing all measurements, 25 randomly selected data sets of patient records were re-evaluated, and measurements were repeated. The evaluation of method error was carried out by using Dahlberg's formula. For the angular and linear measurements, the errors were 0.4° and 0.3-0.8 mm, respectively.

### Statistical analysis

Statistical analysis was performed via software (IBM SPSS Statistics 19, SPSS inc., An IBM Co., Somers, NY). Data of continuous variables were expressed as mean ± standard deviation. The student t-test and chi-square test were used to compare the variables between the groups. Multivariate logistic regression analysis was used to determine the effect of variables on RME failure. The p values less than 0.05 were considered statistically significant.

## RESULTS

The age, gender distribution, and some cephalometric variables were similar in the S-RME and F-RME groups ( $p > 0.05$ ) (Table 2, 3). The statistical difference between the groups was found in the CVM stage. The CVM values of the F-RME group were higher than those of the S-RME ( $p < 0.05$ ) (Table 2).

Multivariate logistic regression analysis results revealed that three parameters were associated with RME failure. The most significant association was found in the CVM stages. Patients with CVMS-6 had a 16.8-fold higher risk of palatal expansion failure than CVMS-5 (Table 4).

The second parameter associated with RME failure was the sagittal position of PNS (VR-PNS distance). A 1-mm increase in the VR-PNS distance increased 2.9 times the risk of failure. (Table 4).

The third parameter was HR-PNS distance. A 1-mm increase in the HR-PNS distance increased 0.3 times the risk of failure. (Table 4).

The age, sex, the vertical and sagittal position of ANS, and palatal plane angle were found not to affect the RME failure risk.

Table 2. Descriptive statistics of the skeletal maturation stage, gender, and age.

Groups	CVM5/CVM6 (n)	Male/Female (n)	Age (Mean±SD)
S-RPE	26/13	14/25	14.26±1.85
F-RPE	2/9	1/10	15.15±1.10
P	0.004 <sup>a</sup>	0.087 <sup>a</sup>	0.083 <sup>b</sup>

S-RPE: Successful Rapid Palatal Expansion Group, F-RPE: Failed Rapid Palatal Expansion Group, CVM5: Cervical Maturation Stage 5, CVM6: Cervical Maturation Stage 6, <sup>a</sup> Results of chi-square test, <sup>b</sup> Results of independent samples t-test, \* P=.05.

**Table 3.** Descriptive statistics of the cephalometric variables.

	Groups		p
	S-RPE Mean±SD	F-RPE Mean±SD	
1. VR-ANS	70.9±8.73	73.04±7.23	0.620
2. VR-PNS	24.38±1.84	24.5±2.6	0.341
3. HR-ANS	45.72±4.05	45.93±5.41	0.761
4. HR-PNS	44.05±3.11	42.78±3.49	0.784
5. HR/PP	6.3±4.33	6.65±5.04	0.647

S-RPE: Successful Rapid Palatal Expansion Group, F-RPE: Failed Rapid Palatal Expansion Group, Results of independent samples *t*-test, \* *P*=.05.

**Table 4.** Association between evaluated variables and RME failure.

	Univariate			Multivariate		
	$\beta$	p	Odds Ratio (%95 CI)	$\beta$	p	Odds Ratio (%95 CI)
1. Sex	-1,723	0,118	0,179(0,021-1,544)	-1.429	0.356	0.240(0.012-4.972)
2. Age	0,519	0,103	1,681(0,901-3,137)	0.281	0.544	1.324(0.534-3.279)
3. CVM stage	2,197	0,010*	9,000(1,693-47,837)	2,822	0.032*	16.810(1.278-221.148)
4. VR-ANS	0,034	0,456	1,05(0,946-1,132)	0.066	0.236	1.068(0.958-1.192)
5. VR-PNS	0,030	0,862	1,030(0,735-1,444)	1.096	0.022*	2.992(1.171-7.646)
6. HR-ANS	0,011	0,886	1,011(0,866-1,181)	0.287	0.093	1.333(0.954-1.863)
7. HR-PNS	-0,138	0,246	0,871(0,690-1,100)	-0.932	0.022*	0.394(0.177-0.875)
8. HR/PP	0,018	0,815	1,018(0,876-1,183)	0.047	0.715	1.048(0.816-1.346)

Results of multivariate logistic regression analysis, Reference categories: CVMS5, Female. \* *P*=.05

## DISCUSSION

In the present study, the association between the sagittal and vertical position of maxilla and RME failure was investigated. CVM stage, sex, and age of the patients, as well as the palatal plane angle, were included in the parameters to evaluate general skeletal maturation and maxillary rotation. The results revealed that three factors were related to the success/failure of the RME, which were the CVM stage and sagittal and vertical position of the PNS. All other parameters failed to show an association with RME success/failure.

The RME success/failure in the literature was generally evaluated by examining the mid-palatal suture maturation.<sup>6,21</sup> Angelieri et al.<sup>16</sup> suggested the classification of the mid-palatal suture according to its morphology. Grunheid et al.<sup>15</sup> introduced the mid-palatal density ratio as a novel predictor of RME success. However, the reliability and validity of these methods have been questioned.<sup>22</sup> It is difficult to precisely conclude from the CBCT images about the histological morphology of the

suture because of the variability in radiographic interpretation. And density measurements were not presented as the sole or definitive indicator of RME outcome.<sup>23</sup> Moreover, the requirement of pre-treatment CBCT is the major disadvantage of these techniques. The indication for the use of CBCT should be well established and should not be preferred in the presence of other techniques with fewer health risks.<sup>24,25</sup> The main reason to perform the current study is to search for a practical and harmless method that does not require additional radiation exposure.

In a histomorphometric study, it was stated that the ossification of mid-palatal suture was not considered to be a valid reason for transverse resistance, especially in patients with

the age of 25 years and younger.<sup>18</sup> Acar et al.<sup>23</sup> evaluated the density of maxillary buttress regions and mid-palatal suture in RME patients and found that the higher density values of both maxillary buttresses and mid-palatal suture caused increased buccal tipping in the molar teeth, which indicates increased resistance to RME. So along with the mid-palatal suture, maturation of the circummaxillary sutures and bones suggested affecting the success of RME.<sup>1,2,23,26</sup> Therefore, in this study, instead of examining only the mid-palatal suture, the general skeletal maturation, which provides information about the maturation of both mid-palatal and facial sutures, was considered.<sup>21,27</sup> In accordance with this purpose, CVM was used to evaluate the skeletal maturation on lateral cephalometric radiographs routinely taken for orthodontic diagnosis.

Because the skeletal effect was more prominent before the CVMS-3, Bacetti et al.<sup>28</sup> recommended performing RME before this stage. However, there is no clear guideline for the patients after the peak period. In the present study, patients

after the peak period (CVMS 5/6) were evaluated, and patients under the age of 16 but at the CVMS of 6 were found to have a 16.8-fold higher risk of RME failure than those with CVMS-5. Nevertheless, although RME treatment had failed in two subjects with CVMS-5, suture opening was successfully achieved in 13 subjects at CVMS-6. Similar to our results, Angelieri et al.<sup>17</sup> found a high correlation between mid-palatal suture opening and CVM stages. However, in their study, only CVM stages 1, 2, and 3 were presented to be reliable indicators for the early mid-palatal suture maturation stages, and CBCT was recommended to more precisely determine the mid-palatal suture maturation stage of postpubertal patients (CVMS4 and above). So, the CVM stage cannot be considered as the only predictor for RME success.

To our knowledge, this study is the first research that has attempted to identify cephalometric predictors, which can be utilized for determining the failure possibility in conventional RME. Therefore, the position of the maxilla in relation to age, sex, and skeletal maturation stage was evaluated in the present study. Along with the CVMS, the sagittal and vertical position of PNS might have a significant effect on RME failure. The primary fusion on the mid-palatal suture is seen in the posterior region, and it proceeds to the anterior. The posterior part of the mid-palatal suture is the region with the highest resistance during RME, and generally, a failure in suture opening is seen in this part. Therefore, the fusion time of the posterior portion of the mid-palatal suture might be considered as another aspect of the RME failure rate. In parallel with this information, it was found that the PNS position affected RME failure instead of ANS.

The anterior cranial base is known to complete most of its growth before other facial skeletal structures. So, the higher position of the PNS can indicate a resistance to the RME forces caused by proximity to the mature structures of the cranium. Accordingly, the present results showed that the smaller the distance between the PNS and the anterior cranial base in the vertical direction, the higher the risk of RME failure. Furthermore, according to vertical growth gradient, growth and development of the body start from the top, and the skull and the brain develop before the other parts of the body. This trend continues downwards, with the maxilla developing just before the mandible. Therefore, a higher position of the PNS may indicate the early maturation of this region.

The present results also revealed that the anterior positioning of PNS might increase the risk of RME failure. A possible reason might be the convergence of the pterygoid processes to the zygomatic buttress region as PNS positioned anteriorly. The posterior maxilla, together with the zygomatic buttress, are two crucial zones of resistance, and their convergence might

further increase resistance to RME. However, it is clear that more precise evidence is necessary to support these findings. Measurement of the distance between RME resistant structures and analysis of the effects of these measurements on RME failure may be the subject of another study.

Within the limitations of the present study, the results suggest that along with the CVMS, position of PNS might contribute to the prediction of conventional or surgical assisted RPE decision. The major limitations of this study are the limited number of patients and the lack of adjunctive analysis of maturation. Therefore, the results should be supported by finite element or prospective clinical studies to make more accurate inferences and put the results into clinical practice.

In addition, although there was no statistically significant difference between the failure and success groups in terms of gender (Table 2), this outcome should be interpreted carefully. Because the S-RME group consisted of 25 females and 14 males and the F-RME consisted of 10 females and one male. When examining the gender distribution between the groups, it will be noticed that almost the entire F-RME group consisted of female participants (10 females/1 males). Therefore, we think that the probability of RME failure in female participants may be higher, but we could not prove this statistically. Future studies are needed to reveal this issue more clearly.

## CONCLUSION

The risk of RME failure in borderline cases is particularly important in the treatment plan. The present study investigated eight different parameters in terms of predicting RME failure. CVM stage, vertical and sagittal positions of PNS were found to affect RME failure. Age, the vertical and sagittal positions of ANS, and the palatal plane angle did not affect RME failure. Although statistical significance could not be determined, we thought that females might have more prone to RME failure. This outcome has predictive value and needs further investigation. It can be concluded that not only the maturation stage but also the position of the maxilla may be significant factors in predicting RME success/failure.

## CONFLICTS OF INTEREST

The authors declare no conflict of interest.

---

## REFERENCES

1. Melsen B. Palatal growth studied on human autopsy material. A histologic microradiographic study. *Am J Orthod.* 1975; 68: 42-54.
  2. Cureton SL, Cuenin M. Surgically assisted rapid palatal expansion: orthodontic preparation for clinical success. *Am J Orthod Dentofacial Orthop.* 1999; 116: 46-59.
  3. Garib DG, Henriques JF, Janson G, Freitas MR, Coelho RA. Rapid maxillary expansion--tooth tissue-borne versus tooth-borne expanders: a computed tomography evaluation of dentoskeletal effects. *Angle Orthod.* 2005; 75: 548-57.
  4. Rungcharassaeng K, Caruso JM, Kan JY, Kim J, Taylor G. Factors affecting buccal bone changes of maxillary posterior teeth after rapid maxillary expansion. *Am J Orthod Dentofacial Orthop.* 2007; 132: 421-8.
  5. Kilic N, Kiki A, Oktay H. A comparison of dentoalveolar inclination treated by two palatal expanders. *Eur J Orthod.* 2008; 30: 67-72.
  6. Timms DJ, Vero D. The relationship of rapid maxillary expansion to surgery with special reference to midpalatal synostosis. *Br J Oral Surg.* 1981; 19: 180-96.
  7. Mossaz CF, Byloff FK, Richter M. Unilateral and bilateral corticotomies for correction of maxillary transverse discrepancies. *Eur J Orthod.* 1992; 14: 110-6.
  8. Mommaerts MY. Transpalatal distraction as a method of maxillary expansion. *Br J Oral Maxillofac Surg.* 1999; 37: 268-72.
  9. Epker BN, Fish LC, Stella JP. *Dentofacial deformities: integrated orthodontic and surgical correction.* Mosby St. Louis; 1986.
  10. Alpern MC, Yurosko JJ. Rapid palatal expansion in adults with and without surgery. *Angle Orthod.* 1987; 57: 245-63.
  11. Capelozza Filho L, Cardoso Neto J, da Silva Filho OG, Ursi WJ. Non-surgically assisted rapid maxillary expansion in adults. *Int J Adult Orthodon Orthognath Surg.* 1996; 11: 57-66.
  12. Handelman CS. Nonsurgical rapid maxillary alveolar expansion in adults: a clinical evaluation. *Angle Orthod.* 1997; 67: 291-305.
  13. Revelo B, Fishman LS. Maturation evaluation of ossification of the midpalatal suture. *Am J Orthod Dentofacial Orthop.* 1994; 105: 288-92.
  14. Wehrbein H, Yildizhan F. The mid-palatal suture in young adults. A radiological-histological investigation. *Eur J Orthod.* 2001; 23: 105-14.
  15. Grunheid T, Larson CE, Larson BE. Midpalatal suture density ratio: A novel predictor of skeletal response to rapid maxillary expansion. *Am J Orthod Dentofacial Orthop.* 2017; 151: 267-76.
  16. Angelieri F, Cevidane LH, Franchi L, Goncalves JR, Benavides E, McNamara JA, Jr. Midpalatal suture maturation: classification method for individual assessment before rapid maxillary expansion. *Am J Orthod Dentofacial Orthop.* 2013; 144: 759-69.
  17. Angelieri F, Franchi L, Cevidane LH, McNamara JA, Jr. Diagnostic performance of skeletal maturity for the assessment of midpalatal suture maturation. *Am J Orthod Dentofacial Orthop.* 2015; 148: 1010-6.
  18. Knaup B, Yildizhan F, Wehrbein H. Age-related changes in the midpalatal suture. A histomorphometric study. *J Orofac Orthop.* 2004; 65: 467-74.
  19. Baccetti T, Franchi L, McNamara JA, Jr. An improved version of the cervical vertebral maturation (CVM) method for the assessment of mandibular growth. *Angle Orthod.* 2002; 72: 316-23.
  20. Franchi L, Baccetti T, Tollaro I. Predictive variables for the outcome of early functional treatment of Class III malocclusion. *Am J Orthod Dentofacial Orthop.* 1997; 112: 80-6.
  21. Persson M, Thilander B. Palatal suture closure in man from 15 to 35 years of age. *Am J Orthod.* 1977; 72: 42-52.
  22. Isfeld D, Lagravere M, Leon-Salazar V, Flores-Mir C. Novel methodologies and technologies to assess mid-palatal suture maturation: a systematic review. *Head Face Med.* 2017; 13: 13.
  23. Acar YB, Motro M, Erverdi AN. Hounsfield Units: a new indicator showing maxillary resistance in rapid maxillary expansion cases? *Angle Orthod.* 2015; 85: 109-16.
  24. Schulze R. Radiation protection vs research interests. *Dentomaxillofac Radiol.* 2013; 42: 20120348.
  25. Aps JK. To beam or not to beam: that is the question. *Dentomaxillofac Radiol.* 2013; 42: 20120375.
  26. Isaacson RJ, Ingram AH. Forces produced by rapid maxillary expansion: II. Forces present during treatment. *The Angle Orthod.* 1964; 34: 261-70.
  27. Bjork A. Sutural growth of the upper face studied by the implant method. *Acta Odontol Scand.* 1966; 24: 109-27.
  28. Baccetti T, Franchi L, Cameron CG, McNamara JA, Jr. Treatment timing for rapid maxillary expansion. *Angle Orthod.* 2001; 71: 343-50.
-