



Title	Retromandibular vein position and course patterns in relation to mandible: anatomical morphologies requiring particular vigilance during sagittal split ramus osteotomy
Author(s) Alternative	Sugahara, K; Matsunaga, S; Yamamoto, M; Noguchi, T; Morita, S; Koyachi, M; Koyama, Y; Koyama, T; Kasahara, N; Abe, S; Katakura, A
Journal	Anatomy & cell biology, 53(4): 444-450
URL	http://hdl.handle.net/10130/5401
Right	This is an Open Access article distributed under the terms of the Creative Commons Attribution Non-Commercial License (http://creativecommons.org/licenses/by-nc/3.0/) which permits unrestricted noncommercial use, distribution, and reproduction in any medium, provided the original work is properly cited.
Description	



Retromandibular vein position and course patterns in relation to mandible: anatomical morphologies requiring particular vigilance during sagittal split ramus osteotomy

Keisuke Sugahara^{1,2}, Satoru Matsunaga^{2,3}, Masahito Yamamoto³, Taku Noguchi³, Sumiharu Morita³, Masahide Koyachi¹, Yu Koyama¹, Takumi Koyama¹, Norio Kasahara⁴, Shinichi Abe^{2,3}, Akira Katakura^{1,2}

¹Department of Oral Pathobiological Science and Surgery, Tokyo Dental College, Tokyo, ²Oral Health Science Center, Tokyo Dental College, Tokyo, ³Department of Anatomy, Tokyo Dental College, Tokyo, ⁴Department of Forensic Odontology and Anthropology, Tokyo Dental College, Tokyo, Japan

Abstract: Major bleeding associated with sagittal split ramus osteotomy (SSRO) involves vessels such as the inferior alveolar, facial, and maxillary arteries and veins, and the retromandibular vein (RMV). The present study aimed to clarify and classify the three-dimensional variations in RMV position and course direction in relation to the mandible. Specimens comprised a total of 15 scientific cadavers, and the relationship between RMV and the mandible lateral and posterior views was observed. We identified 3 patterns on the lateral view, the mean distance between the RMV and the posterior border of the ramus was 3.9 mm at the height of the lingula. A total of five course patterns were identified on the posterior view. In no course pattern, the RMV inferior to the lingula was lateral to its position superior to the lingual. The present findings suggest that it may be possible to predict correlations with intraoperative bleeding risk. Further study is planned using contrast computed tomography in patients with jaw deformity for skeletal classification.

Key words: Retromandibular vein, Blood vessels, Neck dissection, Sagittal split ramus osteotomy, Hemorrhage

Received September 2, 2020; Revised October 15, 2020; Accepted October 29, 2020


Introduction

With the recent development of ultrasonic scalpels and other surgical instruments, and improvements in surgical procedures leading to increased safety, orthognathic surgery is now a widely performed, important specialization within oral and maxillofacial surgery. Diverse surgical approaches are available to meet patients' varied needs regarding func-

tional and cosmetic issues. A nationwide survey on orthognathic treatment in Japan found that approximately 70% of orthognathic surgeries are sagittal split ramus osteotomy (SSRO) [1]. Similarly, SSRO represents the majority of mandibular osteotomies performed at our institution [2].

Intraoperative risks associated with SSRO include unfavorable fracture, inferior alveolar and lingual nerve damage, and major bleeding. Major bleeding involves vessels such as the inferior alveolar, facial, and maxillary arteries and veins, and the retromandibular vein (RMV), and is related to surgical approach [3]. According to Sahoo et al. [4], comparatively few instances of major bleeding in SSRO involve the inferior alveolar and maxillary arteries and veins [5]. Instead, the usual culprit is injury to the various vascular branches running along the medial surface and posterior border of the

Corresponding author:

Satoru Matsunaga 

Department of Anatomy, Tokyo Dental College, 2-9-18, Kandamisaki-cho, Chiyoda-ku, Tokyo 101-0061, Japan
E-mail: matsuna@tdc.ac.jp

Copyright © 2020. Anatomy & Cell Biology

This is an Open Access article distributed under the terms of the Creative Commons Attribution Non-Commercial License (<http://creativecommons.org/licenses/by-nc/4.0/>) which permits unrestricted non-commercial use, distribution, and reproduction in any medium, provided the original work is properly cited.

mandibular ramus. This suggests a greater risk of bleeding when the RMV is adjacent to the posterior border of the ramus or branches are present at the position of the medial cut.

After forming through the joining of the superficial temporal and maxillary veins, the RMV descends posterior to the posterior border of the ramus and then drains into the internal jugular vein [6]. The RMV has no accompanying artery of the same name; however, as the majority of the venous blood in the maxillofacial area flows through the RMV, its importance is undeniable. Touré and Vacher [7] studied cadavers to investigate the positional relationship in the courses of the RMV and facial nerve in the region of the parotid gland and identified six patterns. Furthermore, investigation of the vessels and nerves in the parotid space led Babademez et al. [8] to conclude that the positional relationship between the courses of the RMV and facial nerve is a risk factor for facial nerve palsy that requires particular vigilance during parotidectomy.

Conversely, few studies have focused on RMV position, course pattern, and other factors in the context of surgical procedures, including SSRO, that involve surgical manipulation at the posterior border of the ramus. There is particular need for basic data regarding the three-dimensional (3D) position of the blood vessels in relation to the mandible in order to increase prediction accuracy regarding the bleeding risk in orthognathic and other oral surgeries.

The present study aimed to clarify and classify the 3D variations in RMV position and course direction in relation to the mandible, and identify the unique characteristics of

the RMV with its lack of accompanying artery within the surrounding tissue.

Materials and Methods

Materials

Specimens comprised a total of 15 scientific cadavers (10 male, 5 female; mean age [range], 84.9 [68–102] years) from the collection at the Department of Anatomy, Tokyo Dental College that had been fixed in 10% formalin and preserved in 70% ethanol. The present study was approved by the Ethics Committee of Tokyo Dental College (Ethics Approval No. 781).

First, the platysma muscle was detached from the mandible and reflected and the presence of structures including the superficial temporal and facial veins was confirmed. Next, the surrounding connective tissues were carefully resected together with the parotid gland. An incision was made in the center of the sternocleidomastoid muscle belly to expose the internal jugular vein. Subsequently, the digastric muscle was exposed and the intermediate tendon incised to expose the junction of the internal jugular vein and RMV. At this point, photographs were taken from a lateral and posterior view to record the positional relationship between the RMV and the ramus and the position of the mandibular lingula. A portion of the ramus was then incised and resected and the maxillary vein and pterygoid venous plexus were exposed. Lateral and posterior views were photographed again.

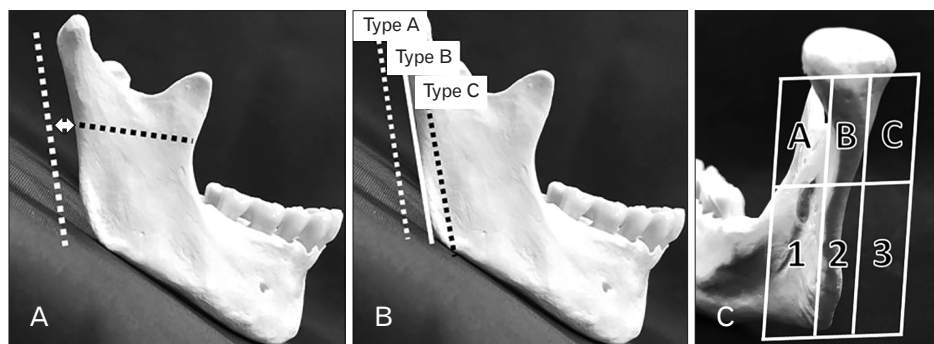


Fig. 1. (A) Measurement distance between the posterior border of the mandibular ramus and RMV at the height of the mandibular lingula. Dotted white line: RMV; dotted black line: height of the mandibular lingula; arrow: measurement distance. (B) Classifications of the positional relationship between RMV and the posterior border of the mandibular ramus from a lateral view. (Type A) RMV positioned posterior to the posterior border of the ramus, (Type B) RMV adjoining the posterior border of the ramus, (Type C) RMV positioned anterior to the posterior border of the ramus. (C) RMV course patterns on the posterior view of the mandibular ramus. Images were divided into three buccolingual sections in relation to the ramus. These were then each divided horizontally at the height of the mandibular lingula. The upper part is divided into three parts (A, B, C), and the lower part is divided into three parts (1, 2, 3). The driving was classified running pattern by combining one each in the upper and lower parts. RMV, retromandibular vein.

RMV course categorization and measurement parameters

After identifying the junction of the superficial temporal and maxillary veins, the presence of the RMV running along the posterior border of the ramus and of the external jugular vein branching off posteriorly midway were identified. Next, the pre- and post-resection photographs of the ramus were superimposed to clarify the positional relationship between the RMV and mandible. On the lateral view, the distances from the posterior border of the ramus to the RMV, the external jugular vein, and the mandibular foramen were measured at the height of the lingula, which forms the reference for the vertical height of the medial cut in SSRO (Fig. 1A). A baseline was created based on Loukota et al.'s classifications [9] of condylar process fractures (Strasbourg Osteosynthesis Research Group Classification) and vertical lines were established; one passing through the lowest point of the mandibular notch and one through the lingula.

Specimens were classified regarding the positional relationship between the RMV and the posterior border of the ramus on the lateral view as follows. Type A: RMV positioned posterior to the posterior border of the ramus; Type B: RMV adjoining the posterior border of the ramus; and, Type C: RMV positioned anterior to the posterior border of the ramus (Fig. 1B).

On the posterior view, images were divided into three buccolingual sections comprising the posterior border and buccal and lingual aspects of the ramus. These were then each divided into superior and inferior sections at the height of the lingula. Based on these sections, RMV course patterns were classified into one of nine possible categories (Fig. 1C).

Results

The RMV and the superior temporal vein (STV) ran posteriorly to the mandibular ramus. The former was located anterior to the latter, which directly connected to the external jugular vein. This pattern was 86.7%. On the other hand, we also found another pattern (13.3%). The RMV was located posterior to the mandibular ramus. The superior (inferior) part of the RMV was continuous with the STV (the internal jugular vein). The superficial temporal vein was not connected to external temporal vein (Fig. 2, Table 1).

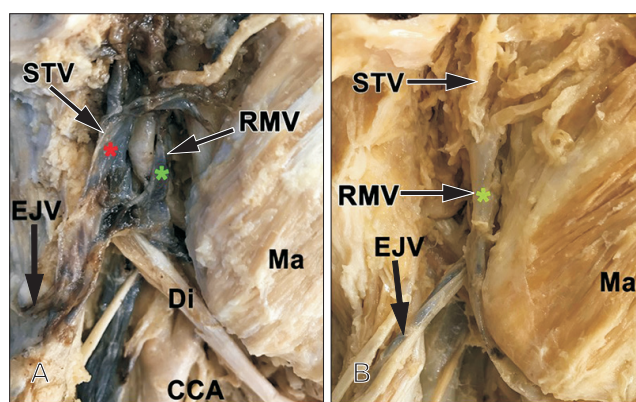


Fig. 2. Topographical anatomy of the retromandibular region. (Panel A) The RMV (green star) and the STV (red star) run posteriorly to the mandibular ramus (86.7%). (Panel B) The superior (inferior) part of the RMV (green star) is continuous with the STV (the internal jugular vein) (13.3%). CCA, common carotid artery; Di, digastric muscle; EJV, external jugular vein; M, mandibular bone; Ma, masseter; RMV, retromandibular vein; STV, superficial temporal vein.

Table 1. Positional relationship between REV and mandibular bone

Specimen (no.)	Sex	Age	PM-RMV (mm)	Class	PM-EJV (mm)	MF-PM (mm)	Pattern
1	Male	88	2	A	8	14	I
2	Male	78	2.1	A	7.7	17.9	I
3	Male	73	3	A	8	12	I
4	Male	102	4	A	12	15	I
5	Female	83	4.5	A	7.9	15.1	I
6	Male	86	5	A	×	13	I
7	Male	79	9.9	A	9.9	9.1	I
8	Female	86	1	A	9	16.4	II
9	Male	87	1.3	A	5.2	16.4	III
10	Female	99	1.5	A	7.9	21	III
11	Female	83	6.4	A	×	14.1	IV
12	Male	87	9.6	A	2.9	13.2	IV
13	Male	68	0.1	B	3	23	V
14	Male	87	0	B	9.7	14	II
15	Female	87	-1.7	C	6.3	13.6	II

REV, retromandibular vein; PM, posterior margin of mandibular ramus; RMV, retromandibular vein; EJV, external jugular vein; MF, mandibular foramen.

Measurements on the lateral view

In terms of positional relationship, the mean distance between the RMV and the posterior border of the ramus was 3.9 mm (range, -1.7-9.9 mm) at the height of the lingula (Table 1). A Type A pattern (RMV positioned posterior to the posterior border of the ramus) was observed in 12 specimens (80.0%); Type B (RMV adjoining the posterior border of the ramus) in 2 specimens (13.3%); and Type C (RMV positioned anterior to the posterior border of the ramus) in 1 specimen (6.7%; Fig. 3, Table 1). The mean distance between the external jugular vein and the posterior border of the ramus in the 13 specimens presenting an external jugular vein was 7.5 mm (range,

3.0-12.0 mm). The mean distance between the mandibular foramen and the posterior border of the ramus was 15.2 mm (9.1-23.0 mm).

Course patterns on the posterior view

On dividing posterior view images into three buccolingual sections comprising the posterior border and buccal and lingual aspects of the ramus that were then each divided into upper and lower sections at the height of the lingula and classifying course patterns into one of nine possible categories, no course patterns included Block 3—inferior to the lingula and lateral to the posterior border of the ramus—re-

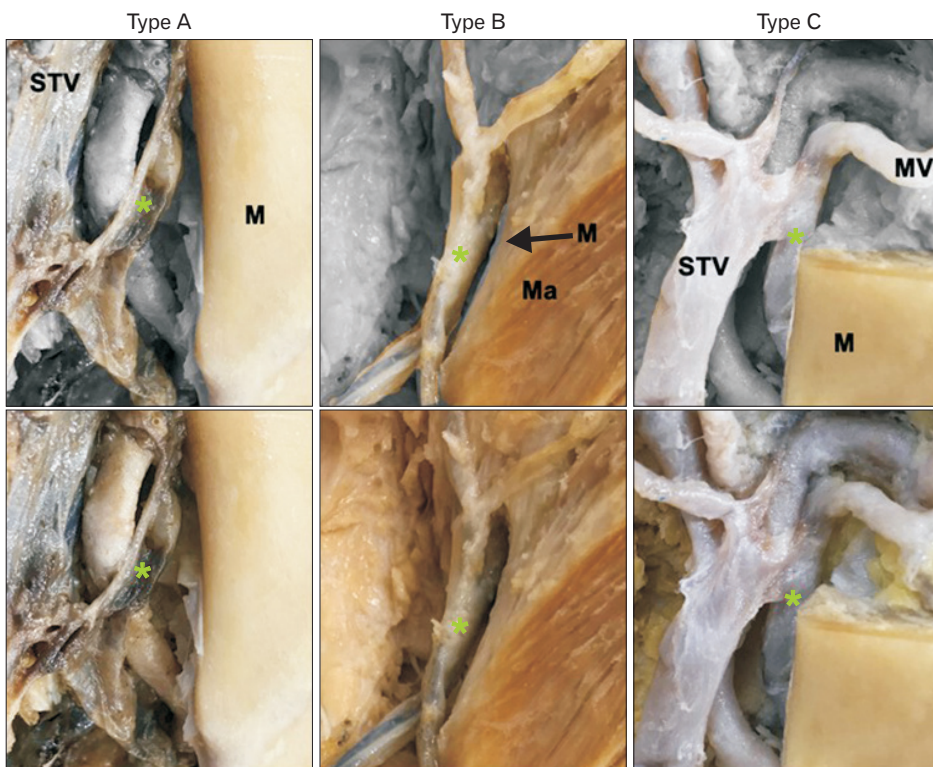


Fig. 3. Positioning of the posterior border of the mandible and posterior veins of the mandible. Panel A-C inverts the vein of Panel A'-C' (original image) and the other than the mandible (or cusp). (Type A) The posterior border of the mandible is separated from the posterior vein of the mandible (Panel A and A'). (Type B) The anterior border of the mandibular posterior vein is in contact with the posterior border of the mandibular branch (Panel B and B'). (Type C) The posterior vein of the mandible is located in front of the posterior border of the mandible and inside the posterior border of the mandible (Panel C and C'). Asterisk, retromandibular vein; M, mandibular bone; Ma, masseter; STV, superficial temporal vein.

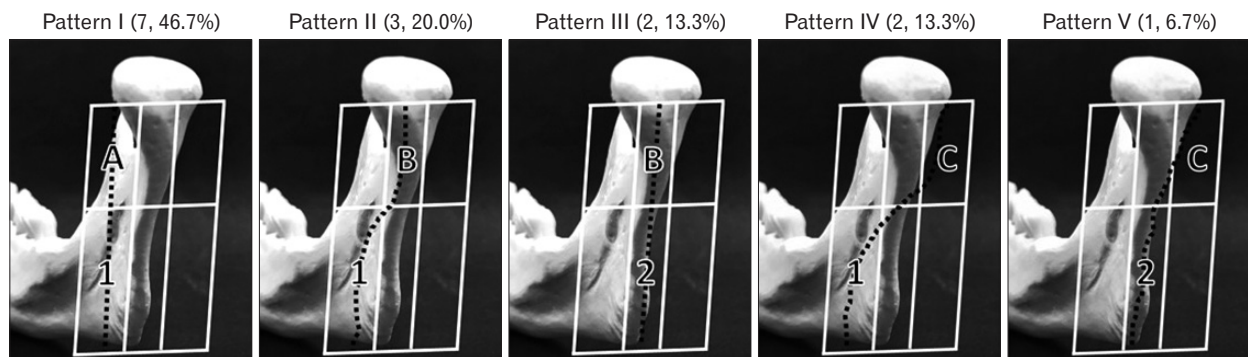


Fig. 4. Course pattern on the posterior view of RMV and the posterior border of the mandibular ramus. RMV, retromandibular vein.

ardless of the position of the course superior to the lingula. A total of five course patterns were identified (Fig. 4).

Pattern I (A-1): rectilinear course running medial to the posterior border of the ramus, n=7 (46.7%).

Pattern II (B-1): diagonal course running medially from immediately posterior to the posterior border of the ramus, n=3 (20.0%).

Pattern III (B-2): rectilinear course running immediately posterior to the posterior border of the ramus, n=2 (13.3%).

Pattern IV (C-1): diagonal course running from lateral to medial in relation to the posterior border of the ramus, n=2 (13.3%).

Pattern V (C-2): diagonal course running from lateral to immediately posterior in relation to the posterior border of the ramus, n=1 (6.7%).

In no course pattern, the RMV inferior to the lingula was lateral to its position superior to the lingula.

No significant differences were observed between male and female for all data items.

Discussion

Jaw deformity can be congenital or acquired. It involves facial asymmetry as well as abnormalities in the maxillo-mandibular relationship and maxillary, mandibular, or maxillomandibular parameters such as size, morphology, and position. The resulting maxillofacial morphological and maxillomandibular occlusal abnormalities create functional issues such as impaired mastication and articulation function and mental and emotional problems stemming from esthetic concerns.

Widely recognized for its treatment efficacy, orthognathic surgery has come to have an important place in the field of oral and maxillofacial surgery in Japan. With advances in treatment techniques and surgical instruments, it is now a standard surgery in the field and widely performed as its safety continues to increase. The most common type of orthognathic surgery is SSRO [1, 2].

The first surgical approach for SSRO was reported by Trauner and Obwegeser [10] in 1957; however, subsequent reports of complications including aseptic necrosis and non-union of the bone segments led to various procedural modifications involving alterations to the line of incision [11-13]. Intraoperative complications such as major bleeding, lower lip paraesthesia, and unfavorable fracture are frequently encountered [3, 14-16]. Pineiro et al. [17] reported a correlation

between surgical time and intraoperative blood loss with SSRO. Thorough preoperative evaluation of surgical risks is important to reduce surgical time and intraoperative blood loss and achieve a favorable outcome. The incidence of unfavorable fracture and inferior alveolar nerve damage can be reduced using preoperative computed tomography (CT). However, as many vessels run through the soft tissue, intraoperative bleeding cannot be preoperatively predicted without contrast CT. With reported incidences in SSRO of 11.4% (5/74) [4] and 2.0% (5/301) [18], major bleeding is an intraoperative complication that will be encountered in a certain percentage of cases. In a previous study conducted at our institution, the average blood loss during SSRO was 160 g and the maximum blood loss was 1,400 g [2]. Major bleeding was caused by inside mandibular ramus blood vessel damage [2]. The desire to avoid complications of allogeneic transfusion due to major intraoperative bleeding in the pursuit of safer orthognathic surgery has spurred various investigations into blood loss reduction. However, the majority of these studies discuss only general anesthesia management or hemostatic agent administration [19, 20].

The present study measured RMV position and course patterns in relation to the posterior border of the ramus using cadavers in order to facilitate preoperative evaluation of the bleeding risk in SSRO.

RMV course patterns have previously been reported; however, the majority of these studies were concerned with the positional relationship with the facial nerve in the context of parotid gland tumor resection [7, 8]. Focusing on orthognathic surgery, the present study examined RMV course patterns lateral and posterior to the ramus. Based on measurements of the distance between the RMV and the posterior border of the ramus, the risk factor levels for intraoperative bleeding were also classified. On the lateral view, while the distance between the RMV and the posterior border of the ramus occasionally approached 10 mm, in the majority of specimens it was within 2–3 mm. In some specimens, the RMV was adjacent while in others it was positioned anterior to the posterior border of the ramus. If the RMV was damaged, it was difficult to stop the bleeding during SSRO. Pressure hemostasis is also ineffective in such situations. This demonstrates the need for a careful, measured approach to medial periosteal elevation and when making the medial cut in SSRO. On the posterior view, the following course patterns were identified: medial to the posterior border of the ramus, lateral, and diagonal from lateral to the ramus toward

the medial aspect at the inferior border of the mandible. Furthermore, no external jugular vein was observed in 2 specimens (13.3%). An RMV course adjacent to the posterior border of the ramus around the height of the lingula carries the greatest risk when making the medial cut in SSRO and this pattern was observed in 8 specimens (53.3%).

No specimens presented a pattern involving the RMV running laterally to the ramus inferior to the lingula, which is the position of the lateral cut in Trauner's method [10]. However, there were some anomalous specimens that diverged from the mean. These were variciform structures with the varicosity positioned at the junction between the RMV and external jugular vein, which was consistent with the position of the lateral cut in Trauner's method [10]. These types of anomaly pose a potential risk for intraoperative bleeding. Furthermore, the reportedly high incidence of vascular variants in patients with jaw deformity [16, 21] necessitates extra care during orthognathic surgery, regardless of the particular approach.

In addition, in cases of mandibular prognathism with a large degree of displacement for which a long split is used for the medial cut during osteotomy, the distal bone segment may be positioned posterior to the posterior border of the ramus during mandibular fixation. In the present study, not only was the RMV adjacent to the posterior border of the ramus at the height of the lingula in some cases, the minimum rectilinear distance between the lingula and the posterior border of the ramus was 9.1 mm. These findings indicate the need to preoperatively consider whether a short split should be used for the medial cut in cases with a large posterior displacement. Giving comprehensive consideration to medial periosteal elevation and cut and bone segment displacement with mandibular setback in SSRO, the present findings suggest that the highest bleeding risk is associated with Type A (Specimen No. 9, 10, and 13) in Patterns III and V.

Aside from orthognathic surgery, RMV position and course pattern are also important in surgeries such as open reduction and internal fixation of condylar process fractures. The condylar process can be approached from various directions, including the intraoral region, submandibular region, and posterior border of the ramus; however, the course of the RMV as well as the path of the facial nerve are extremely important during surgery, particularly when using the Risdon [22, 23] or retromandibular [24, 25] approach. Thus, the present findings suggest novel possibilities for evaluating bleeding risk in surgeries involving manipulation of the pos-

terior border of the ramus, including SSRO.

In conclusion, the present study identified three types of positional relationship between the RMV and the posterior border of the ramus and five RMV course patterns. Combining these findings enabled measurement values to be obtained regarding the anatomical morphology important for SSRO. The findings suggest it may be possible to predict correlations with intraoperative bleeding risk.

Further study is planned using contrast CT in patients with jaw deformity for skeletal classification and to investigate RMV position and course patterns to obtain measurements of more practical surgical use.

ORCID

Keisuke Sugahara:

<https://orcid.org/0000-0002-0260-396X>

Satoru Matsunaga:

<https://orcid.org/0000-0001-7059-8413>

Masahito Yamamoto:

<https://orcid.org/0000-0001-9683-6678>

Taku Noguchi: <https://orcid.org/0000-0003-1923-3958>

Sumiharu Morita:

<https://orcid.org/0000-0003-3837-0763>

Masahide Koyachi:

<https://orcid.org/0000-0002-5003-4386>

Yu Koyama: <https://orcid.org/0000-0002-3093-204X>

Takumi Koyama: <https://orcid.org/0000-0001-5278-0967>

Norio Kasahara: <https://orcid.org/0000-0002-5748-2042>

Shinichi Abe: <https://orcid.org/0000-0003-4632-9736>

Akira Katakura: <https://orcid.org/0000-0002-9761-1267>

Author Contributions

Conceptualization: KS, SM, SA, AK. Data acquisition: SM, MY, TN, NK. Data analysis or interpretation: KS, MY, TN, SM, MK, YK, TK, NK. Drafting of the manuscript: KS, SM. Critical revision of the manuscript: SA, AK. Approval of the final version of the manuscript: all authors.

Conflicts of Interest

No potential conflict of interest relevant to this article was reported.

Acknowledgements

We would like to thank Dr. Manami Michiwaki and Dr. Kento Odaka for analysis of imaging data.

References

- Kobayashi T, Saito C, Inoue N, Ohata N, Kawamura H, Goto S, Goto M, Shiratsuchi Y, Susami T, Tanne K, Hashimoto K, Moriyama K, Amagasa T, Himuro T, Tonoki M. Treatment of jaw deformity: a nationwide survey of the situation in Japan. *Jpn J Jaw Deform* 2008;18:237-50.
- Hamada Y, Sugahara K, Yoshida S, Watanabe A, Bessho H, Kasahara K, Takano M, Saito C, Shibahara T, Katakura A. A 27-year retrospective clinical analysis of 2640 orthognathic surgery cases in the Tokyo Dental College. *J Oral Maxillofac Surg Med Pathol* 2019;31:305-10.
- O’Ryan F. Complications of orthognathic surgery. *Oral Maxillofac Surg Clin North Am* 1990;2:593-613.
- Sahoo NK, Kaur P, Sharma IDRR. Complications of sagittal split ramus osteotomy. *J Oral Maxillofac Surg Med Pathol* 2017;29:100-4.
- Odaka K, Matsunaga S. Course of the maxillary vein and its positional relationship with the mandibular ramus require attention during mandibuloplasty. *J Craniofac Surg* 2020;31:861-4.
- Norton NS. *Netter’s head and neck anatomy for dentistry*. 3rd ed. Philadelphia: Elsevier; 2016.
- Touré G, Vacher C. Relations of the facial nerve with the retro-mandibular vein: anatomic study of 132 parotid glands. *Surg Radiol Anat* 2010;32:957-61.
- Babademez MA, Acar B, Gunbey E, Karabulut H, Karasen RM. Anomalous relationship of the retromandibular vein to the facial nerve as a potential risk factor for facial nerve injury during parotidectomy. *J Craniofac Surg* 2010;21:801-2.
- Loukota RA, Eckelt U, De Bont L, Rasse M. Subclassification of fractures of the condylar process of the mandible. *Br J Oral Maxillofac Surg* 2005;43:72-3.
- Trauner R, Obwegeser H. The surgical correction of mandibular prognathism and retrognathia with consideration of genioplasty. I. Surgical procedures to correct mandibular prognathism and reshaping of the chin. *Oral Surg Oral Med Oral Pathol* 1957;10:677-89; contd.
- Dal Pont G. Retromolar osteotomy for the correction of prognathism. *J Oral Surg Anesth Hosp Dent Serv* 1961;19:42-7.
- Hunsuck EE. A modified intraoral sagittal splitting technique for correction of mandibular prognathism. *J Oral Surg* 1968;26:250-3.
- Epker BN. Modifications in the sagittal osteotomy of the mandible. *J Oral Surg* 1977;35:157-9.
- Panula K, Finne K, Oikarinen K. Incidence of complications and problems related to orthognathic surgery: a review of 655 patients. *J Oral Maxillofac Surg* 2001;59:1128-36; discussion 1137.
- Patel PK, Morris DE, Gassman A. Complications of orthognathic surgery. *J Craniofac Surg* 2007;18:975-85; Quiz 986-8.
- Lanigan DT, Hey JH, West RA. Major vascular complications of orthognathic surgery: false aneurysms and arteriovenous fistulas following orthognathic surgery. *J Oral Maxillofac Surg* 1991;49:571-7.
- Piñeiro-Aguilar A, Somoza-Martín M, Gandara-Rey JM, García-García A. Blood loss in orthognathic surgery: a systematic review. *J Oral Maxillofac Surg* 2011;69:885-92.
- Kim SG, Park SS. Incidence of complications and problems related to orthognathic surgery. *J Oral Maxillofac Surg* 2007;65:2438-44.
- Mei A, Qiu L. The efficacy of tranexamic acid for orthognathic surgery: a meta-analysis of randomized controlled trials. *Int J Oral Maxillofac Surg* 2019;48:1323-8.
- Olsen JJ, Skov J, Ingerslev J, Thorn JJ, Pinholt EM. Prevention of bleeding in orthognathic surgery--a systematic review and meta-analysis of randomized controlled trials. *J Oral Maxillofac Surg* 2016;74:139-50.
- Jackson IT, Jack CR, Aycock B, Dubin B, Irons GB. The management of intraosseous arteriovenous malformations in the head and neck area. *Plast Reconstr Surg* 1989;84:47-54.
- Kallela I, Söderholm AL, Paukku P, Lindqvist C. Lag-screw osteosynthesis of mandibular condyle fractures: a clinical and radiological study. *J Oral Maxillofac Surg* 1995;53:1397-404; discussion 1405-6.
- Handschel J, Rüggeberg T, Depprich R, Schwarz F, Meyer U, Kübler NR, Naujoks C. Comparison of various approaches for the treatment of fractures of the mandibular condylar process. *J Craniomaxillofac Surg* 2012;40:e397-401.
- Devlin MF, Hislop WS, Carton AT. Open reduction and internal fixation of fractured mandibular condyles by a retromandibular approach: surgical morbidity and informed consent. *Br J Oral Maxillofac Surg* 2002;40:23-5.
- Ellis E 3rd, McFadden D, Simon P, Throckmorton G. Surgical complications with open treatment of mandibular condylar process fractures. *J Oral Maxillofac Surg* 2000;58:950-8.