

|             |   |
|-------------|---|
| Title       | Accidental ingestion or aspiration of foreign objects at Tokyo Dental College Chiba Hospital over last 4 years                    |
| Author(s)   | Hisanaga, R; Takahashi, T; Sato, T; Yajima, Y; Morinaga, K; Ohata, H; Hirata, S; Mamiya, H; Kinumatsu, T; Yakushiji, T; Hagita, K |
| Journal     | Bulletin of Tokyo Dental College, 55(1): 55-62  |
| URL         | <a href="http://hdl.handle.net/10130/5332">http://hdl.handle.net/10130/5332</a>   |
| Right       |   |
| Description |   |

## Clinical Report

# Accidental Ingestion or Aspiration of Foreign Objects at Tokyo Dental College Chiba Hospital over Last 4 Years

**Ryuichi Hisanaga<sup>1)</sup>, Toshiyuki Takahashi<sup>2)</sup>, Toru Sato<sup>1)</sup>, Yasutomo Yajima<sup>3)</sup>, Kazuki Morinaga<sup>4)</sup>, Hitoshi Ohata<sup>5)</sup>, SoIchiro Hirata<sup>6)</sup>, Hideki Mamiya<sup>7)</sup>, Takashi Kinumatsu<sup>8)</sup>, Takashi Yakushiji<sup>5)</sup> and Keiko Hagita<sup>9)</sup>**

<sup>1)</sup> *Department of Crown and Bridge Prosthodontics, Tokyo Dental College, 1-2-2 Masago, Mihama-ku, Chiba 261-8502, Japan*

<sup>2)</sup> *Office of General Dentistry, Tokyo Dental College, 1-2-2 Masago, Mihama-ku, Chiba 261-8502, Japan*

<sup>3)</sup> *Department of Oral Implantology, Tokyo Dental College, 1-2-2 Masago, Mihama-ku, Chiba 261-8502, Japan*

<sup>4)</sup> *Department of Endodontics and Clinical Cariology, Tokyo Dental College, 1-2-2 Masago, Mihama-ku, Chiba 261-8502, Japan*

<sup>5)</sup> *Department of Oral and Maxillofacial Surgery, Tokyo Dental College, 1-2-2 Masago, Mihama-ku, Chiba 261-8502, Japan*

<sup>6)</sup> *Department of Social Dentistry, Tokyo Dental College, 1-2-2 Masago, Mihama-ku, Chiba 261-8502, Japan*

<sup>7)</sup> *Department of Dental Anesthesiology, Tokyo Dental College, 1-2-2 Masago, Mihama-ku, Chiba 261-8502, Japan*

<sup>8)</sup> *Department of Periodontology, Tokyo Dental College, 1-2-2 Masago, Mihama-ku, Chiba 261-8502, Japan*

<sup>9)</sup> *Division of Clinical Laboratory, Tokyo Dental College, 1-2-2 Masago, Mihama-ku, Chiba 261-8502, Japan*

Received 31 January, 2013/Accepted for publication 12 July, 2013

## Abstract

The aim of this study was to investigate cases of accidental ingestion or aspiration occurring at Tokyo Dental College Chiba Hospital over the last 4 years in order to determine how the incidence of such events could be reduced. Forty cases of accidents occurring at our hospital over a 4-year period commencing in 2008 (representing 27% of the total number of accidents) included accidental ingestion in 39 patients and aspiration in one. Most of these accidents occurred during the removal or placement of restorations or prosthetics, and the ingested objects were mostly crowns and inlays. Accidental ingestion or aspiration occurred more frequently in the right molar region and when procedures were conducted by practitioners with less than 1 to 7 years of experience, and especially 1 to 3 years only. A higher rate of such accidents was observed in male patients in their 50s to 70s. The conventional safety procedures developed by the Medical Risk Management Team should be adhered to wherever possible. Furthermore, we propose the following measures based on the present results: accident prevention training for students and clinical trainees; improvement of the in-hospital manual;

personal coaching for those breaching the guidelines of the safety manual; and raising awareness of the need for greater care in preventing incidents of accidental ingestion or aspiration at the Tokyo Dental College Chiba Hospital.

**Key words:** Accidental ingestion—Accidental aspiration—  
Medical risk management—Tokyo Dental College Chiba Hospital

## Introduction

The Medical Risk Management Team at Tokyo Dental College was established in 2004 as a subsidiary body of the Medical Risk Management Committee with the remit of conducting surveys and analyses and collecting information related to safety issues. The members of both bodies consist of dentists, nurses, clinical laboratory technicians, and administrative staff. One of their functions is to produce manuals aimed at providing instruction on how to prevent medical accidents and improve post-accident management in order to improve the safety of medical practice at this institute. Medical safety workshops are held on a regular basis to promote health care consciousness among professionals. However, it is difficult to completely avoid accidents. Although the number of accidental ingestions and aspirations has decreased, they still account for a substantial percentage of the total number of medical accidents. To date, no sequelae have been observed following accidental ingestion or aspiration at our hospital. However, they have been reported to cause symptoms related to damage of the digestive organs, and accidental aspiration may cause serious damage such as respiratory impairment or pneumonia<sup>2-8,10,11,13,15-19,21-24</sup>, indicating the need for an appropriate post-accident response. The importance of completely avoiding accidental ingestion or aspiration during dental treatment has been recognized at Tokyo Dental College since 2008, with specific bodies being appointed to tackle the problem. The goal of this study was to investigate the characteristics of recent cases of accidental ingestion or aspiration at Tokyo

Dental College Chiba Hospital. We believe that the results should provide useful information on how such accidents might be prevented in the future.

## Methods

A review was conducted of incidents of accidental ingestion or aspiration reported to the Medical Risk Management Team between April 2008 and March 2012 at the Tokyo Dental College Chiba Hospital. The following items were investigated: rate of accidental ingestion or aspiration; situation in which it occurred; type of item aspirated or swallowed; site of accidental ingestion or aspiration; patient age and sex; number of years of clinical experience of practitioner conducting the procedure involved; response at time of accidental ingestion or aspiration; and post-accident response.

## Results

### 1. Percentage of accidental ingestion or aspiration cases

Among 146 accidents occurring during the period investigated, 40 involved accidental ingestion or aspiration, accounting for 27% of the total number of medical accidents. Among these 40 cases, 39 were accidental ingestion and 1 was accidental aspiration. The number of patients involved in these accidental ingestions or aspirations represented 0.0038% of the annual cumulative number of patients presenting at our hospital during the period investigated.

Table 1 Circumstances surrounding accidental ingestion or aspiration

| Circumstances                                  | Cases (%)  |
|--|------------|
| During the removal of restoration/prosthetic   | 8 (20.0)   |
| During the placement of restoration/prosthetic | 7 (17.5)   |
| After the placement of restoration/prosthetic  | 5 (12.5)   |
| After the placement of orthodontic device      | 4 (10.0)   |
| During tooth extraction                        | 3 (7.5)    |
| During the removal of orthodontic device       | 2 (5.0)    |
| During scaling                                 | 2 (5.0)    |
| During the trial of a screw-pin                | 2 (5.0)    |
| Other  | 7 (17.5)   |
| Total  | 40 (100.0) |

## 2. Circumstances surrounding accidental ingestion and aspiration

Accidental ingestion or aspiration occurred during the removal of restorations or prosthetics in 8 cases; the placement of restorations or prosthetics in 7 cases; after the placement of restorations or prosthetics in 5 cases; and after the placement of orthodontic devices in 4 cases (Table 1). Although placing a gauge in the mouth during insertion or removal of restorations or prostheses is stipulated in the in-hospital manual, this safety procedure was not followed in 13 out of 15 cases.

## 3. Items accidentally ingested or aspirated

The items most frequently aspirated or swallowed were crowns (10 cases), followed by inlays (8 cases). Other swallowed objects included 4 orthodontic attachments, 3 provisional crowns, 2 bridges (portion), 2 metal cores, 2 orthodontic wires, 2 screw pins, and 1 reamer, bur, clasp (portion), tooth, cotton roll, blade of a scaler, and transfer coping each (Table 2).

## 4. Site of accidental ingestion or aspiration

Accidental ingestion or aspiration occurred most frequently in the lower right molar region (10 cases), followed by the upper right molar region (6 cases) (Table 3). Twenty-one accidents involved the mandible, and 19 the maxilla. Sixteen accidents occurred on the left side, and 24 on the right side. Twenty-

Table 2 Type of ingested or aspirated item

| Ingested items         | Cases (%)  |
|------------------------|------------|
| Crown                  | 10 (25.0)  |
| Inlay                  | 8 (20.0)   |
| Orthodontic attachment | 4 (10.0)   |
| Provisional crown      | 3 (7.5)    |
| Bridge (portion)       | 2 (5.0)    |
| Metal core             | 2 (5.0)    |
| Orthodontic wire       | 2 (5.0)    |
| Screw pin              | 2 (5.0)    |
| Reamer                 | 1 (2.5)    |
| Bur                    | 1 (2.5)    |
| Clasp (portion)        | 1 (2.5)    |
| Tooth                  | 1 (2.5)    |
| Cotton roll            | 1 (2.5)    |
| Blade of a scaler      | 1 (2.5)    |
| Transfer coping        | 1 (2.5)    |
| Total                  | 40 (100.0) |

three accidents involved the molars, 13 the premolars, and 4 the front teeth.

## 5. Patient age and sex

The highest age bracket was the 50s and 70s (8 patients), followed by the 60s (7 patients) (Fig. 1). There were 25 male patients and 15 female.

## 6. Number of years of clinical experience of practitioner involved

Accidental ingestion or aspiration occurred most frequently when procedures were conducted by practitioners with less than 1 to

Table 3 Region of origin of ingested or aspirated item

| Location |             | Right     | Left      | Total      |
|----------|-------------|-----------|-----------|------------|
| Maxilla  | Front teeth | 2 (5.0)   | 1 (2.5)   | 3 (7.5)    |
|          | Premolars   | 3 (7.5)   | 3 (7.5)   | 6 (15.0)   |
|          | Molars      | 6 (15.0)  | 4 (10.0)  | 10 (25.0)  |
| Mandible | Front teeth | 1 (2.5)   | 0 (0.0)   | 1 (2.5)    |
|          | Premolars   | 2 (5.0)   | 5 (12.5)  | 7 (17.5)   |
|          | Molars      | 10 (25.0) | 3 (7.5)   | 13 (32.5)  |
| Total    |             | 24 (60.0) | 16 (40.0) | 40 (100.0) |

Cases (%)

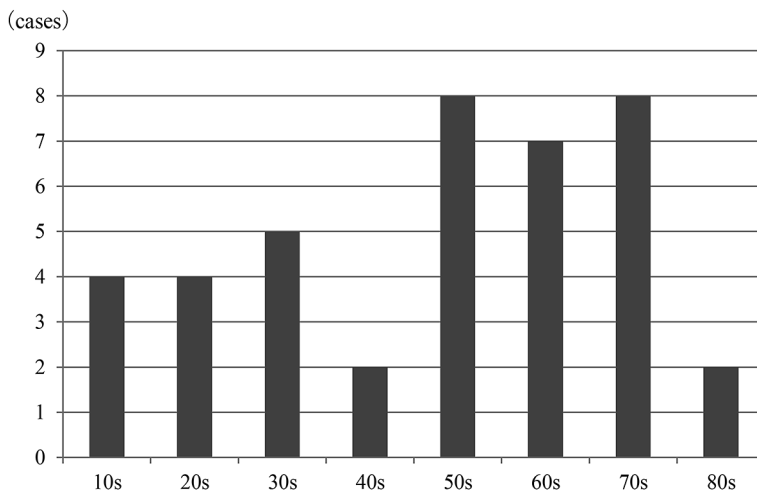


Fig. 1 Patient age

3 years of experience (14 cases), followed by 3 to 5 years, and 5 to 7 years (8 cases each) (Fig. 2).

### 7. Post-accident response to accidental ingestion or aspiration

The locations of the 39 items ingested were identified by chest X-ray as the trachea in 1 case and the stomach in 38 cases. A metal core confirmed on an X-ray was retrieved by a bronchoscopic procedure; a reamer was retrieved by an endoscopic procedure. Among the remaining cases, natural egestion was confirmed by chest X-ray taken at a later date in 28 cases, and the patients were followed up in 9 cases. Since one of the ingested items

was a cotton roll, which cannot be identified by X-ray, its location in the stomach was confirmed by an endoscopic procedure during follow-up (Table 4).

### Discussion

All cases of medical accidents occurring at Tokyo Dental College Chiba Hospital over the last 4 years were investigated. Accidental ingestion or aspiration accounted for 27% of all such accidents. It is believed that it is impossible to completely avoid accidental ingestion or aspiration as most dental procedures are performed with the patient in

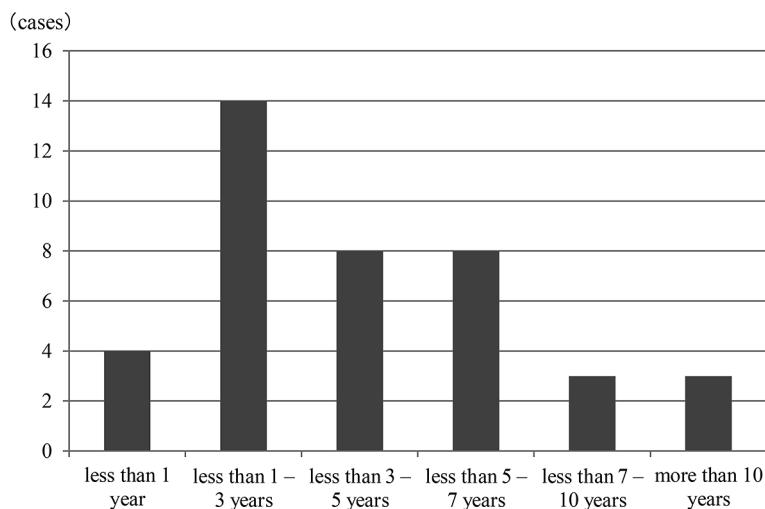


Fig. 2 Number of years of clinical experience of practitioner involved

Table 4 Management during and after accidental ingestion or aspiration

| Management during accidental ingestion or aspiration |            | Management after accidental ingestion or aspiration |            |
|--|------------|---|------------|
| X-ray examination                                    | 39 (97.5)  | Retrieval under bronchoscope                        | 1 (2.5)    |
|  |            | Retrieval under endoscope                           | 1 (2.5)    |
|  |            | X-ray examination                                   | 28 (70.0)  |
|  |            | Follow-up   | 9 (22.5)   |
| Endoscope examination                                | 1 (2.5)    | Follow-up   | 1 (2.5)    |
| Total  | 40 (100.0) | Total   | 40 (100.0) |

Cases (%)

the supine position, making it easier for any dental object or instrument that has been dropped to fall into the pharynx. Generally, it is recommended that the patient be placed in a sitting position during treatment if there is any perceived danger of accidental ingestion or aspiration. The percentage of patients in whom accidental aspiration occurred among the cumulative number of patients visiting our hospital was 0.0038% (average annual incidence for 4 years from 2008). This was lower than the 0.0044% reported at the Tokushima University Hospital Department of Dentistry (average annual incidence for 8 years from 1995)<sup>20</sup>. Taken together, these findings indicate the necessity of offering an

ongoing program of medical safety workshops aimed at raising awareness of how to avoid accidental ingestion or aspiration.

Accidental ingestion or aspiration was more likely to occur during the removal or placement of restorations or prosthetics. Although the in-hospital manual stipulates that a gauge be placed in the mouth during such procedures to prevent restorations or prosthetics from falling into the pharyngeal region, this preventive procedure was not followed in 13 out of the present 15 cases. The reasons for this included the vomit reflex in patients and overconfidence in practitioners. The results also suggested that lack of a predetermined accident prevention strategy markedly

increased the risk of accidental ingestion or aspiration. Extreme caution is required in terms of positioning the patient's face and/or body. This applies whether conventional accident prevention procedures are available or not, simply from the fail-safe perspective. When the established accident prevention procedures have not been employed, the practitioner is given a warning by the Medical Risk Management Team. The second most common situation was accidental ingestion or aspiration at home after the placement of a restoration or orthodontic device. It is important to place the restoration or prosthetic with appropriate care and choose the design of the device with a view to safety should it become detached.

The most frequently ingested items were restorations, prosthetics, and orthodontic devices (85%), particularly crowns and inlays (45%), followed by other restorations and prosthetics (25%) and orthodontic attachments and wires (15%). These results suggest the importance of considering the risk of accidental ingestion or aspiration if such items are dropped into the mouth.

Accidental ingestion or aspiration was most likely to involve objects originating in the lower right molar region, followed by the upper right molar region. There was little difference between the maxilla and mandible, and involvement of the right side was more frequent than that of the left side. In clinical practice, practitioners usually stand to the right of the patient in performing treatments, which means that the visibility of the buccal mucosa on that side is reduced. Accidental ingestion or aspiration occurred more frequently during treatment of the molars (58%), with this incidence decreasing with a more frontal position. We believe that this may be because it is more difficult to perform treatments in the molar area than the frontal region of the oral cavity. Meticulous care is required when performing treatments in the right molar region.

The highest age bracket of the patients was the 50s to 70s. Although particular caution is urged in treating elderly patients in the

safety manual, accidental ingestion or aspiration occurred frequently in patients in their 50s and 60s. There were few cases of such accidents in patients in their 80s due to the small number of such patients. Accidents occurred more frequently in male patients. It is speculated that this was because the pharyngeal cavity is larger in males than in females. These results indicate the need to exercise particular caution in treating patients in their 50s, the elderly, and male patients.

Practitioners with less than 1 year of experience caused few accidents (10%). Since they are all clinical residents, they do not see many patients and work under the supervision of instructors. Practitioners with 1 to 3 years of experience were more likely to be associated with accidental ingestion or aspiration (35%). The risk of accidental ingestion or aspiration is particularly high in this group due to their lower level of experience in treating patients. The percentage of practitioners involved was 20% when including those with 3 to 5 years and 5 to 7 years of experience. Although their level of experience can be expected to grow as the number of patients treated increases, accidents still occur due to negligence. The incidence of such accidents decreased, however, with more than 7 years of experience. This may have been due to an increased awareness of the importance of accident prevention in this group. Most ingested items entering the digestive tract are eventually excreted. However, when sharp objects such as reamers are ingested, as in one of the present cases, complications can include peritonitis, sepsis, and foreign-body granuloma<sup>1,12</sup>). In such cases, it may be necessary to consider endoscopic extraction. One study reported a delay of 6 weeks between the ingestion of a foreign object and its eventual egestion<sup>14</sup>). If the patient develops abdominal symptoms or ingested items are not excreted for an extended period of time, that patient should be referred to a gastroenterologist, as perforation of the digestive tract is a very real danger<sup>14</sup>).

Complications arising with accidental aspiration into the respiratory organs include

lung abscess, pulmonary fistula, serious pneumonia, and sepsis. Although accidental aspiration is often identified by initial symptoms such as coughing and wheezing, patients often remain asymptomatic when an aspirated object enters the bronchial tubes<sup>9)</sup>. Therefore, immediate radiographic examination of the chest to confirm the location, size, and shape of the foreign object is required in such cases, as stipulated in the safety manual at our hospital. Depending on the results of radiographic examination, a decision can then be made on whether or not to retrieve the ingested item immediately, confirm excretion by another radiographic examination, or monitor the patient over time. When ingested items cannot be identified by X-ray, a CT scan may be required<sup>24)</sup>. Ingested cotton rolls may be directly confirmed by endoscopy. The decision as to which modality to employ must be made by the physician or dental anesthetist. In the present 40 cases of accidental ingestion or aspiration, all the problems were resolved without further damage occurring by appropriate post-accident management.

The Medical Risk Management Team regularly analyzes cases of accidental ingestion or aspiration, holds medical safety workshops on a regular basis, re-examines methods of accident prevention, reviews and revises our safety manuals, presents at conferences, and submits its findings to medical journals. Slogans and posters on accident prevention have been requested by each department and weekly in-hospital patrols mounted to develop awareness of accident prevention. One example of such activity over the last 4 years was the adding of a loop to the dental floss used in inlays and crowns to prevent accidental ingestion or aspiration.

We believe that there are four reasons accidental ingestion or aspiration cannot be completely avoided, despite countermeasures. First, it is difficult to create a safety manual that covers all possible scenarios. Indeed, there were cases where accidents occurred, even though treatment was performed according to the manual. This indicates the need for the level of the practitioner's skill to be improved

so as to compensate for any inadequacies in the safety manual. Second, conventional measures aimed at accident prevention stipulated by the in-hospital manual cannot be applied when the vomiting reflex occurs. This suggests the need to review the countermeasures to be taken in such cases and update them in the safety manual. Third, prosthetic and orthodontic appliances sometimes become detached or are partially broken after placement due to insufficient technique or inappropriate design. This finding indicates the necessity of improving treatment skills and knowledge if accidental ingestion or aspiration is to be avoided in a home setting. Fourth, and finally, some dentists ignore the accident prevention measures stipulated in the in-hospital manual during treatment. This appears to result from overconfidence as experience increases or the desire to cut corners to save time. The raising of awareness of the importance of such preventive measures is particularly important in this group. We would like to propose the following specific measures aimed at reducing cases of accidental ingestion or aspiration: 1. best practice in terms of accident prevention should be taught as an integral part of training in each specialty and in initial training for residents; 2. Where the conventional accident prevention measures stipulated in the in-hospital manual cannot be applied, they should be reviewed and new countermeasures added to the in-hospital manual; 3. where a practitioner fails to follow the safety procedures stipulated in the manual, they should have to undergo compulsory personal coaching by a member of the Medical Risk Management Team; and 4. caution should be exercised during the placement or removal of restorations or prostheses, handling of crowns and inlays, treatment of the right molars, and treatment of male patients of over 50 years of age. Furthermore, dentists with less than 1 to 7 years of clinical experience, and especially those with less than 1 to 3 years, must exercise particular care during treatment to avoid accidental ingestion or aspiration. Of course, the conventional measures aimed at preventing accidental ingestion or



aspiration developed by the Medical Risk Management Team still apply and should be adhered to wherever possible.

### References

- 1) Beaumont RH, Johnson S (1987) Retrieval of a swallowed casting 6 weeks after ingestion. *Oral Med Oral Pathol* 64:287–288.
- 2) Brunello DL, Mandikos MN (1995) A denture swallowed. Case report. *Aust Dent J* 40:349–351.
- 3) Cleator IG, Christie J (1973) An unusual case of swallowed dental plate and perforation of the sigmoid colon. *Br J Surg* 60:163–165.
- 4) Colaizzi FA, Chmielarski JJ, Mortellaro ES (1980) Swallowing of central bearing plate. *J Am Dent Assoc* 100:382–383.
- 5) Cooke LD, Baxter PW (1992) Accidental impaction of partial dental prostheses in upper gastrointestinal tract. *Br Dent J* 172:451–452.
- 6) Cottrell SG, Hanley JM (2001) Swallowed partial denture. A case report. *Gen Dent* 49:384–385.
- 7) Drinnan AJ (1967) Dangers of using radiolucent dental materials. *J Am Dent Assoc* 74:446–450.
- 8) Fort S, Batty GM, Wilkins WE (1989) Prolonged pharyngeal impaction of dentures following stroke. *Stroke* 20:1748–1750.
- 9) Gibbons CL, Woodward RT (1988) The aspirated foreign body: an unusual diagnostic marker. *Br Dent J* 165:294–295.
- 10) Giovannitti JA Jr. (1981) Aspiration of a partial denture during an epileptic seizure. *J Am Dent Assoc* 103:895.
- 11) Goodacre CJ (1987) A dislodged and swallowed unilateral removable partial denture. *J Prosthet Dent* 58:124–125.
- 12) Goultschin J, Heling B (1971) Accidental swallowing of an endodontic instrument. *Oral Surg Oral Med Oral Pathol* 32:621–622.
- 13) Govilla CP (1979) Accidental swallowing of an endodontic instrument. *Oral Surg Oral Med Oral Pathol* 47:269–271.
- 14) Grossman LI (1974) *Endodontic practice*, 8th ed., pp.151–158, Lea & Febiger, Philadelphia.
- 15) Hazelrigg CO (1984) Ingestion of mandibular complete denture. *J Am Dent Assoc* 108:209.
- 16) Jacobs LI (1980) Ingestion of partial denture. *J Am Dent Assoc* 101:801.
- 17) McLaughlin MG, Swayne LC, Caruana V (1989) Computed tomographic detection of a swallowed denture. *Comp Med Imaging Graph* 13:161–163.
- 18) Perenack DM (1980) Ingestion of mandibular complete denture. *J Am Dent Assoc* 101:802.
- 19) Pukkula A, Ruotsalainen EM, Jokinen K, Palva A, Nuorviita J (1988) Long-term presence of a denture fragment in the airway. *J Laryngol Otol* 102:190–193.
- 20) Sugawara C, Takahashi A, Maeda N, Kubo M, Kudoh H, Hosoki H, Iwasaki Y (2007) An investigation of accidental aspiration and swallowing during the dental treatment at Tokushima University Dental Hospital. *Shikoku Dent Res* 19:255–262. (in Japanese)
- 21) Szabo M, Szabo I, Buris L (1972) Abbreviated case report. Foreign bodies of dental origin in the esophagus. *Oral Surg Oral Med Oral Pathol* 34:196–198.
- 22) Teska TP, Smith CC (1991) Swallowed partial denture. *Oral Surg Oral Med Oral Pathol* 72:756–757.
- 23) Theodore EDP, Gary LR, Beverly JY (1984) Dental prosthesis as an unsuspected foreign body. *Ann Emerg Med* 13:109–111.
- 24) Zissin R, Shapiro-Feinberg M, Rozenman J, Apter S, Smorjik J, Hertz M (2001) CT findings of the chest in adults with aspirated foreign bodies. *Eur Radiol* 11:606–611.

#### *Reprint requests to:*

Dr. Ryuichi Hisanaga  
 Department of Crown and  
 Bridge Prosthodontics,  
 Tokyo Dental College,  
 1-2-2 Masago, Mihama-ku,  
 Chiba 261-8502, Japan  
 Tel: +81-43-270-3938  
 Fax: +81-43-270-3937  
 E-mail: hisanaga@tdc.ac.jp