

Arthroscopically Assisted Comprehensive Double Cerclage Suture Fixation Technique for Acute Acromioclavicular Joint Separation



Abdul-ilah Hachem, M.D., Rafael Rondanelli S., M.D., Gino Costa, D'O., M.D.,
Iñigo Verdalet, M.D., Hady Ezzeddine, M.D., and Xavier Rius, M.D.

Abstract: Acromioclavicular dislocations are some of the most frequently recorded and controversial injuries in the athletic population. These injuries have historically been a matter of disagreement between surgeons, particularly when it comes to the surgical technique used to treat them, its approach, or its timing. Consensus over the “gold standard” procedure to treat them is yet to be established. Even though numerous surgical techniques have already been described, the number of complications and loss of reduction remains a matter of concern for treating physicians. Here, we present an arthroscopically assisted coracoclavicular and horizontal acromioclavicular fixation technique in a modified figure-of-eight configuration using 2 strong FiberTape Cerclage sutures, with measurable tension, for the comprehensive treatment of acromioclavicular joint dislocations.

Acromioclavicular (AC) joint dislocations (ACJDs) are common injuries mostly seen in young active male patients.¹ The prevalence of this condition is 12% of the total number of injuries of the shoulder girdle, predominantly in patients younger than 35 years of age and with a male-predominant ratio of 8:1.^{2,3} The most common mechanism of AC disruption is a force applied directly over the superolateral border of the shoulder, usually during a fall, with the humerus in an adducted position.⁴ The classification described by Tossy et al.⁵ in 1963 and then modified by Rockwood et al.⁶ in 1996 is the most commonly used system of categorizing these dislocations.

Traditionally, considering Rockwood’s classification, conservative treatment has been recommended for low-grade AC dislocations (Rockwood grade I and II). In contrast, surgical treatment has been proposed for high-grade dislocations such as Rockwood IV to VI and, there still is some debate with regards to Rockwood grade III dislocations.^{7,8} Multiple surgical techniques have been described for the treatment of unstable AC dislocation injuries, but consensus on the most adequate procedure is yet to be established. Similarly, controversy exists regarding the optimal surgical approach (open or arthroscopic), timing of the intervention, and the necessity of AC fixation.¹

In this Technical Note, we present an arthroscopically assisted single-tunnel coracoclavicular fixation using 2 buttons and FiberTape Cerclage sutures (FTC-S; Arthrex, Naples, FL) associated with a minimally invasive percutaneous AC fixation in a transosseous figure-of-eight configuration of the FTC-S, for the comprehensive treatment of unstable ACJDs.

From the Department of Orthopedic and Traumatology Surgery (A.-I.H.H., X.R.M.) and University of Barcelona Shoulder Surgery Master Fellowship (R.R.S., G.C.D., I.V.), Hospital Universitari de Bellvitge (L’Hospitalet de Llobregat) Barcelona; and Hospital Universitari de Bellvitge (H.E.), Barcelona, Spain.

The authors report the following potential conflicts of interest or sources of funding: A.-I.H.H. reports nonfinancial support from Arthrex, outside the submitted work. In addition, he has a patent (Bone Block Cerclage) pending. Full ICMJE author disclosure forms are available for this article online, as supplementary material.

Received April 8, 2020; accepted June 6, 2020.

Address correspondence to Abdul-Ilah Hachem Harake, C/ Feixa Llarga S/ N, Hospital de Bellvitge Pl. 10, Traumatology and Orthopedic Secretary, Hospital Universitari de Bellvitge (L’Hospitalet de Llobregat), Barcelona, Spain, 08907. E-mail: abelhachem@gmail.com

© 2020 by the Arthroscopy Association of North America. Published by Elsevier. This is an open access article under the CC BY-NC-ND license (<http://creativecommons.org/licenses/by-nc-nd/4.0/>).

2212-6287/20628

<https://doi.org/10.1016/j.eats.2020.06.012>

Surgical Technique (With Video Illustration)

The advantages, disadvantages, and possible complications of this technique are described in [Table 1](#). The surgical technique is demonstrated in [Video 1](#).

Preoperative Assessment

All patients with acute ACJDs are radiographically evaluated with bilateral anteroposterior (AP), axillary lateral, and Zanca views (AP with 10-15° of cephalic

Table 1. Advantages and Disadvantages of the Technique**Advantages**

- The acromial and clavicular tunnels are made with a 2.4-mm cannulated drill, reducing the risk of fractures.
- The FiberTape Cerclage suture with a preassembled racking hitch knot maintains AC joint reduction, while the vertical CC construct is being adjusted and vice-versa.
- The tension applied to the constructs is measurable, due to the measurability of the tensions applied to the knots during stabilization of both the AC (horizontal) and the CC (vertical) components of the system.
- A minimally invasive technique.
- Allows for the diagnosis and treatment of concomitant intra-articular lesions.
- An excellent view of the coracoid is achieved with an anterolateral portal using a 30° scope, without the need for a 70° scope.
- The subcoracoid space can be reached from a lateral subacromial portal without damaging the rotator interval.
- Implant removal is not obligatory.
- Both the vertical and horizontal FiberTape Cerclage sutures restore the biomechanical properties of the AC joint.

Disadvantages

- A demanding technique, requiring a considerable learning curve.
- This technique can be more time consuming than open procedures.
- X-ray imaging is required to confirm horizontal acromial and clavicular tunnel placement and to confirm vertical reduction, fixation, and stability.

AC, acromioclavicular; CC, coracoclavicular.

tilt). Outlet and Basamania (cross-body adduction) views also may be taken for a more accurate evaluation. This surgical technique is indicated in acute (less than 2 weeks from traumatic event) high-grade (Rockwood grade IV to VI) AC dislocations in patients participating in high-demand sport activities and overhead workers.

Anesthesia and Surgical Settings

Before the procedure, the patient is placed under general anesthesia and an interscalene block is performed. The patient is then placed in the beach-chair position, keeping free the scapular body. Applying a contralateral tilt inclination of 10-15° to the surgical table can facilitate the procedure and positioning of the C-arm. The bony structures and arthroscopic portals are drawn. A dotted line perpendicular to the clavicular axis is drawn, 1 cm medial to the AC joint, to determine the site of the percutaneous anterior to posterior tunnel of the AC cerclage (Fig 1A). The C-arm also must be positioned, coming in from the contralateral side of the patient.

AC Tunnel Preparation

Two clavicular tunnels are done using a cannulated drill under X-ray guidance. The skin incision is also made under X-ray control, to position the anteroposterior clavicular tunnel at the center of the anterior cortex. Inferior arm traction aids in exposing the subcutaneous clavicle prominence, facilitating the tunneling. First, with a 2.4-mm cannulated drill, a percutaneous AP clavicular tunnel, 1 cm medial to the AC joint, is made (Fig 1 B and C). A percutaneous

incision is then made medial to the acromion and posterior to the clavicle, where the exiting drill is palpated under the skin. This incision needs to be as far from the posterior clavicular border as possible, at the spinoclavicular point known as the Neviasser zone. A looped nitinol wire is passed from anterior to posterior through the cannulated drill and retrieved from the Neviasser zone (Fig 2A). Next, we remove the drill and the looped nitinol wire is replaced with a FiberLink suture to avoid breakage of the nitinol wire during traction. The FiberLink is then replaced with an FTC-S, pulling it from the free tail (Fig 2 B and C).

Another skin incision is made under X-ray control to make a percutaneous transacromial tunnel from the lateral aspect of the acromion using the same 2.4-mm cannulated drill. The direction of this tunnel must be at the center of the bone in the AP view. Using continuous X-ray may help us achieve this. The direction of the tunnel must converge with the posterior clavicular tunnel's exit in the Neviasser incision zone done earlier (Fig 3 A and E).

Using an arthroscopic retriever, the posterior tail of the FTC-S is passed subcutaneously over the acromion from the Neviasser zone to the lateral incision at the entrance of the acromial tunnel. Following that, another nitinol loop is passed through the cannulated drill, and replaced with a FiberLink suture after removing the drill. The loop of the FiberLink must be at lateral aspect of the acromion be able to shuttle the FTC-S through the acromial tunnel from its lateral position to Neviasser zone (Fig 3 B and C).

Next, an arthroscopic retriever is introduced from the anterior clavicular incision and the FTC-S is then passed subcutaneously from the posterior Neviasser zone to the anterior side, over the clavicle (Fig 3D). Traction on the suture tapes should be maintained throughout every step to avoid slacking of the sutures and improve their sliding. Finally, the free ends of the FTC-S—now anterior to the clavicular tunnel and configured in a figure-of-eight shaped cerclage construct—are passed through the pre-assembled racking hitch knot, but not fully tensioned yet (Fig 3F).

Mini-Open Clavicular Approach

A 2-cm skin incision perpendicular to the clavicular axis is performed at 3.5 cm from the AC joint. This is the midpoint between the clavicular insertions of the conoid and trapezoid ligaments of the AC joint. Dissection parallel to the clavicular shaft's axis should be carefully made through the delto-trapezoid fascia to reach the center of the clavicle's superior cortex, completing the optimal vertical tunnel.

Diagnostic Arthroscopy

Initial arthroscopic diagnosis is made through the standard posterior portal, looking for concomitant

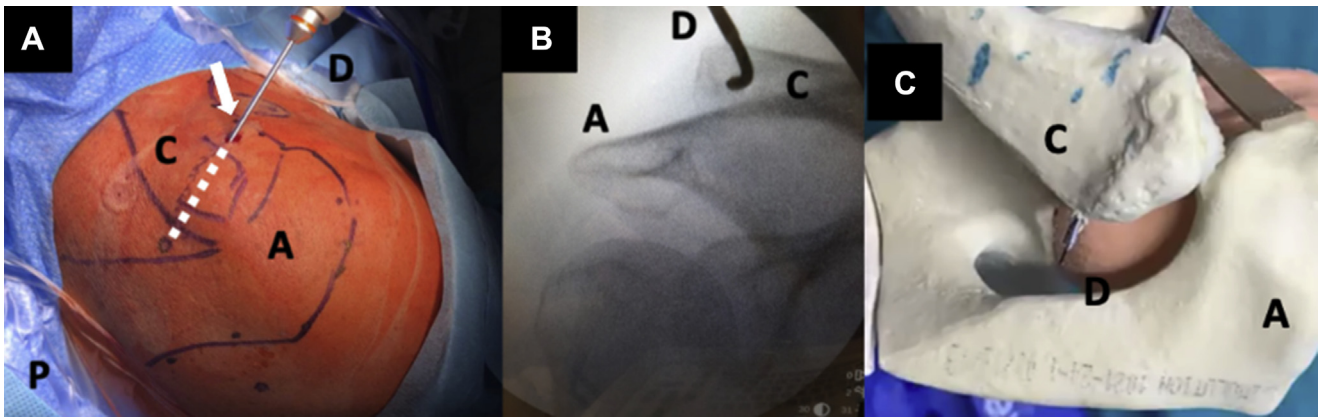


Fig 1. Anteroposterior clavicular tunnel preparation. The patient is in a beach chair position; the right shoulder is shown. (A) Superior view: the bony structures are drawn. A dotted line (white dotted line) determines the site of the percutaneous skin incision of the anterior to posterior tunnel of the acromioclavicular cerclage, 1 cm medial to acromioclavicular joint (ACJ) line, previously determined by radioscopy. (B) Intraoperative fluoroscopic anteroposterior view of the anteroposterior clavicular tunnel; the cannulated drill in the center of the clavicle and 1 cm medial to ACJ line can be noted. (C) Right shoulder superior view (model): a 2.4-mm cannulated drill is passed through the lateral aspect of the clavicle from anterior to posterior. Arrow shows anterior clavicle skin incision. (A, acromion; C, clavicle; D, cannulated drill; P, posterior shoulder.)

pathologies (SLAP lesions, anterior and posterior labral lesions, rotator cuff tears, etc.). A lateral portal in the subacromial space is required to obtain optimal visualization of the coracoid process. To achieve a perfect visualization of the inferior face of the coracoid process, we do not use the anterior transinterval rotator interval approach that requires a 70° arthroscope, but rather we use the 30° universal scope during the entire surgery.

Coracoclavicular Tunnel Preparation

The 30° arthroscope is switched to the subacromial space and the base of the coracoid process is located by following the coracoacromial ligament. An anterolateral portal in line with the anterior border of the acromion is placed. The scope is then switched to this

portal. An anterior portal, located one fingerbreadth lateral to the coracoid tip and very close to the coracoacromial ligament, is made. We then proceed to debride the inferior aspect of the coracoid process using a radiofrequency ablation device passed from the anterior portal, in achieve perfect visualization of its inferior border (Fig 4).

The inferior component of the coracoclavicular drill guide is placed, through the anterior portal, at the center of the inferior aspect of the base of the coracoid process. The superior component of the drill guide is placed at the center of the superior aspect of the clavicle. Here, it is important to avoid eccentricity of the tunnel (Fig 5A). The vertical transclavicular transcoracoid tunnel is made using a 2.4-mm cannulated

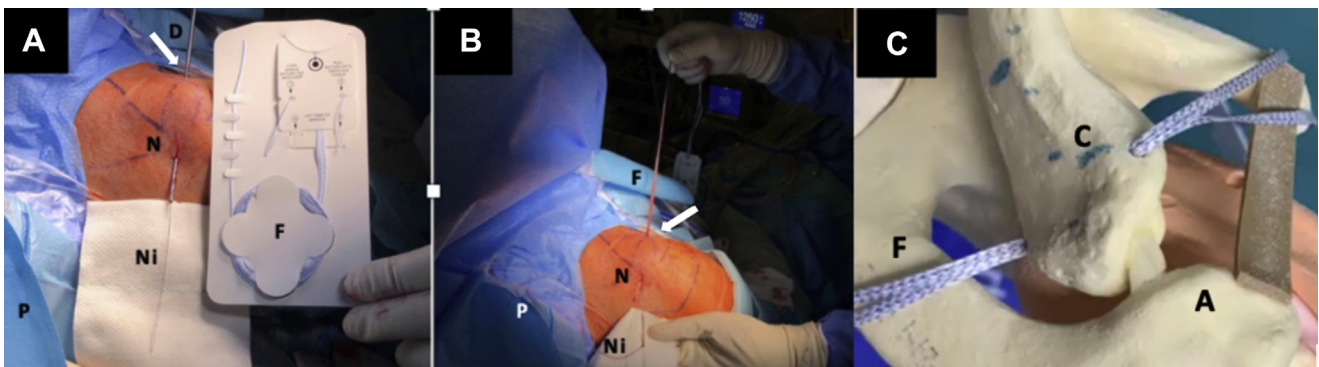


Fig 2. Anteroposterior clavicular tunneling and FiberTape Cerclage sutures (FTC-S) shuttling. The patient is in a beach chair position; the right shoulder is shown. (A) Superior view. A looped nitinol passing through the drilled clavicular tunnel and retrieved percutaneously from the Neviaser zone. The FTC-S are presented. (B) Posterolateral view. After removing the drill, the nitinol is replaced shuttling the FTC-S. (C) Right shoulder, superior view (model), the FTC-S are passed through the clavicular tunnel from the anterior side to the posterior side, using the nitinol loop. Arrow shows anterior clavicle skin incision. (A, acromion; C, clavicle; D, cannulated drill; F, FiberTape Cerclage sutures; N, Neviaser point; Ni, looped nitinol wire; P, posterior right shoulder.)

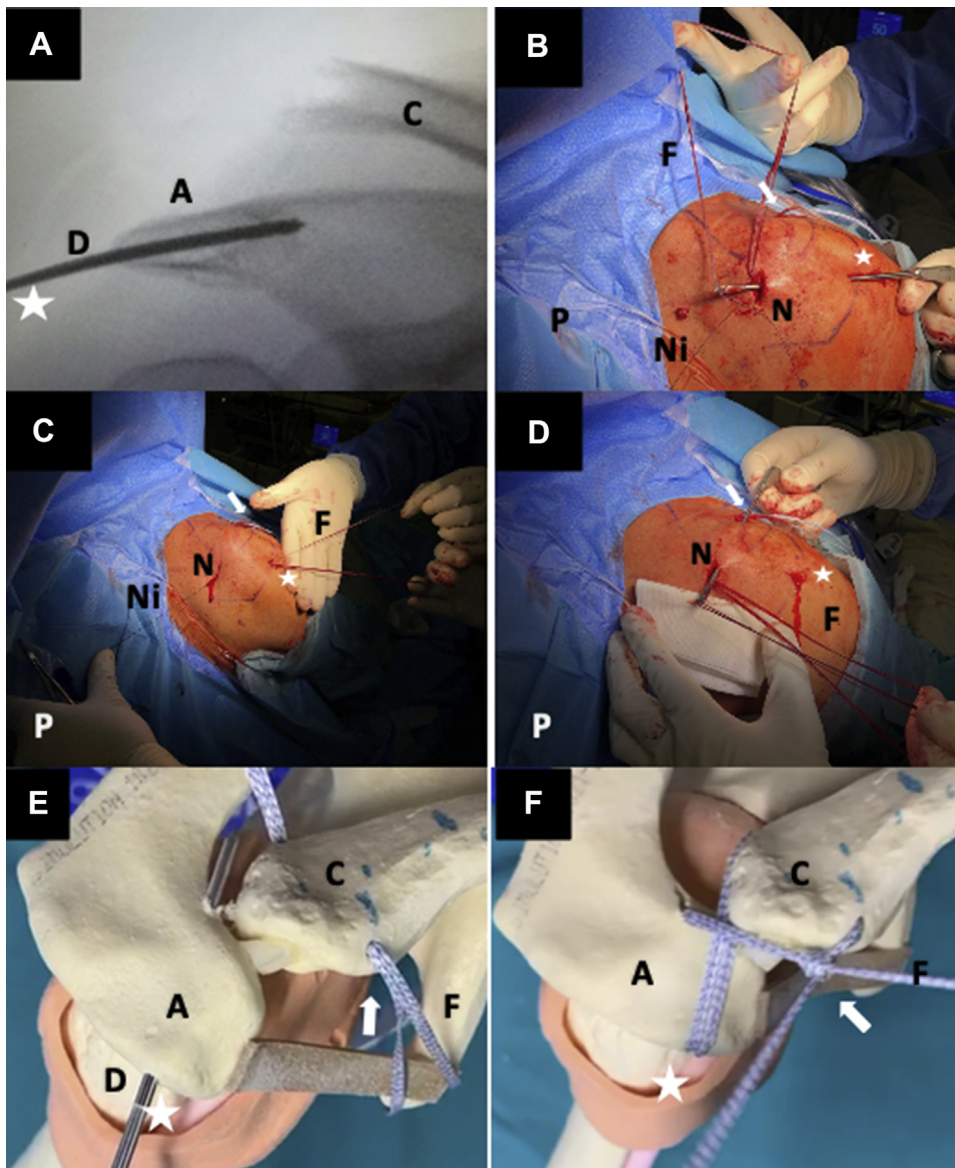


Fig 3. Acromial tunneling and FiberTape Cerclage sutures (FTC-S) shuttling. The patient is in a beach chair position; the right shoulder is shown. (A) Intraoperative fluoroscopic anteroposterior view. Radioscopy of the trans-acromial tunnel made using a cannulated 2.4-mm drill from lateral aspect of the acromion to the Neviasser zone. (B) Superior view. With an arthroscopic retriever introduced from lateral acromial skin incision, the posterior FTC-S tail is passed subcutaneously over the acromion from the Neviasser zone to the lateral entrance of the acromial tunnel and (C) the FTC-S is retrieved by a nitinol loop, from lateral to medial, at the Neviasser through the acromial tunnel after removing the drill. (D) Superior view. With an arthroscopic retriever introduced from the anterior incision of the clavicular tunnel, the posterior tail of the FTC-S is passed subcutaneously, from the posterior Neviasser zone to the anterior side of the clavicle. (E) Right shoulder, superior view (model). The 2.4-mm acromial tunnel is drilled. Note: the FTC-S are passed through clavicular tunnel before acromial tunnel. (F) Final acromioclavicular construct (model) of the FTC-S, which are passed through the preassembled racking hitch knot, creating a figure-of-eight configuration. Arrow indicates anterior clavicle skin incision; Star indicates lateral acromial skin incision. A, acromion; C, clavicle; D, cannulated drill; F: FiberTape Cerclage sutures; N, Neviasser point; Ni, looped nitinol wire; P, posterior right shoulder.)

drill under direct visualization (Fig 5B). A looped nitinol wire is passed through the cannulated drill and retrieved through the anterior portal (Fig 6 A and B). After the drill is removed, it is replaced with a FiberLink to avoid breakage during traction (Fig 6C).

This FiberLink is used to shuttle an FTC-S—folded in half—from the superior side to the inferior side, which is then retrieved through the anterior portal (Fig 6D). A Dog Bone Device (Arthrex) is assembled at the folded middle crease of the FTC-S (Fig 6E). Next, the FTC-S is pulled from the inferior side to the superior side until

the Dog Bone contacts the inferior border of the coracoid process (Fig 7). A second Dog Bone is assembled with the tails of the FTC-S passing through the clavicle and is pushed over the superior cortex. Finally, the tails of the FTCS's are linked.

Reduction and Fixation

Traction should be applied to the FTC-S throughout every step to avoid slacking and improve sliding. Vertical reduction and fixation of the AC joint using progressive tension of the coracoclavicular FTC-S is performed.

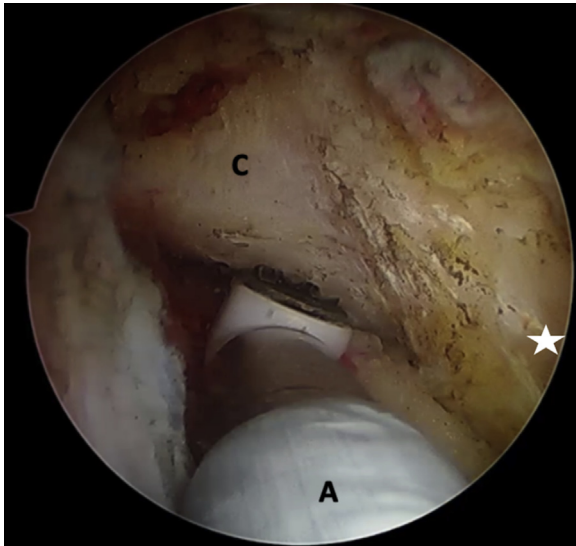
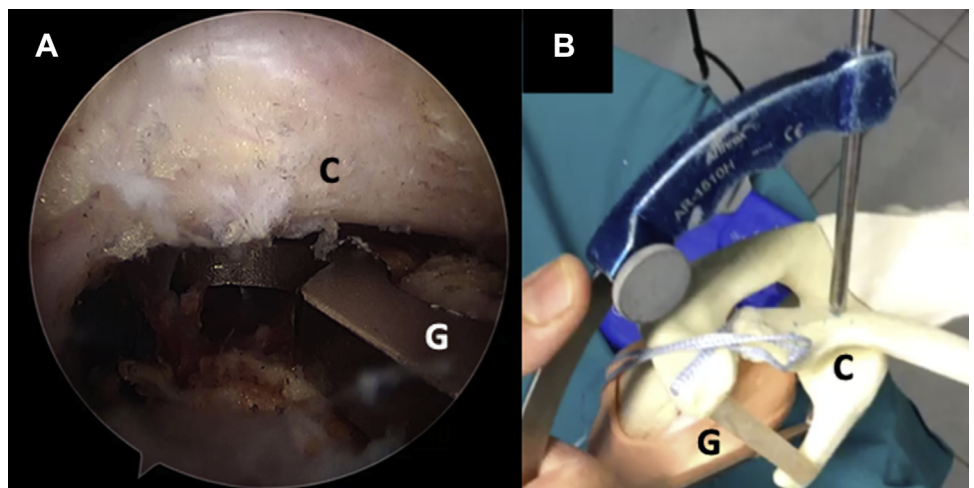


Fig 4. Arthroscopic view of the right shoulder through the anterolateral portal with the patient placed in a beach-chair position, showing debridement of the inferior aspect of the coracoid with an ablator working through the anterior portal located one fingerbreadth lateral to the coracoid tip and very close to the coracoacromial ligament. Star indicates the coracoid tip. (A, ablator; C, inferior aspect of the coracoid process.)

Further tension is added using a tensioner (FiberTape Cerclage Tensioner; Arthrex), under radioscopic control, to achieve a slight over-reduction (Fig 8A).

Following this, horizontal AC joint reduction and fixation is performed by pulling the free ends of the FTC-S anterior to the horizontal clavicular tunnel and is then completed by using the tensioner to avoid dynamic posterior translation (Fig 8 B and C). We can check the anterior ACJ reduction by palpating the anterior acromion and clavicular cortex. While using the tensioner, we can use the C-arm to verify the axial reduction.

Fig 5. Coracoid drilling. (A) Arthroscopic view of the right shoulder from the anterolateral portal with the patient placed in a beach chair position, showing guide insertion through the anterior portal located one fingerbreadth lateral to the coracoid tip and very close to the coracoacromial ligament before coracoid drilling. (B) A vertical transclavicular transcoracoid tunnel is made with a 2.4-mm cannulated drill. The drilling guide position can be seen (model). (C, lateral view of the base of the coracoid; G, inferior subcoracoid component drilling guide.)



Some tips and pitfalls of the actual technique are presented in (Table 2).

Postoperative Care and Rehabilitation

The shoulder is immobilized with a common sling for 3 weeks. Flexion of the elbow and wrist is allowed immediately after the procedure as well as pendulum, passive assisted arm flexion and isometric strengthening of the deltoid and the periscapular musculature. For pain control, oral analgesics and cryotherapy are indicated.

After 3 weeks, the patient can remove the sling and begin full passive and active-assisted exercises. Capsular stretching and strengthening of the rotator cuff and deltoid exercises with an elastic band can be started at 6 weeks postoperatively. When full range of motion is achieved and muscle strength is at least equal to 90% of contralateral side, the patient is allowed to return to sport practice, which is generally at 4 months postoperatively.

Discussion

The treatment of AC dislocations helps avoid joint deformities, persistent pain, secondary AC joint arthritis, and scapular dyskinesia.⁹ Many questions are still left unanswered in the search for the ideal treatment of these dislocations. Despite the existence of more than 150 different described treatment procedures, there is still no consensus on which is the best technique.^{1,10}

Many authors have revealed several benefits associated with the use of arthroscopically assisted techniques in the treatment of ACJDs. In fact, the capacity to diagnose and treat concomitant injuries such as rotator cuff tears, labral lesions, and SLAP lesions and the possibility of having a direct visualization of the inferior aspect of the base of the coracoid makes the use of arthroscopy indispensable.¹¹⁻¹³ Consequently, arthroscopic coracoclavicular suture

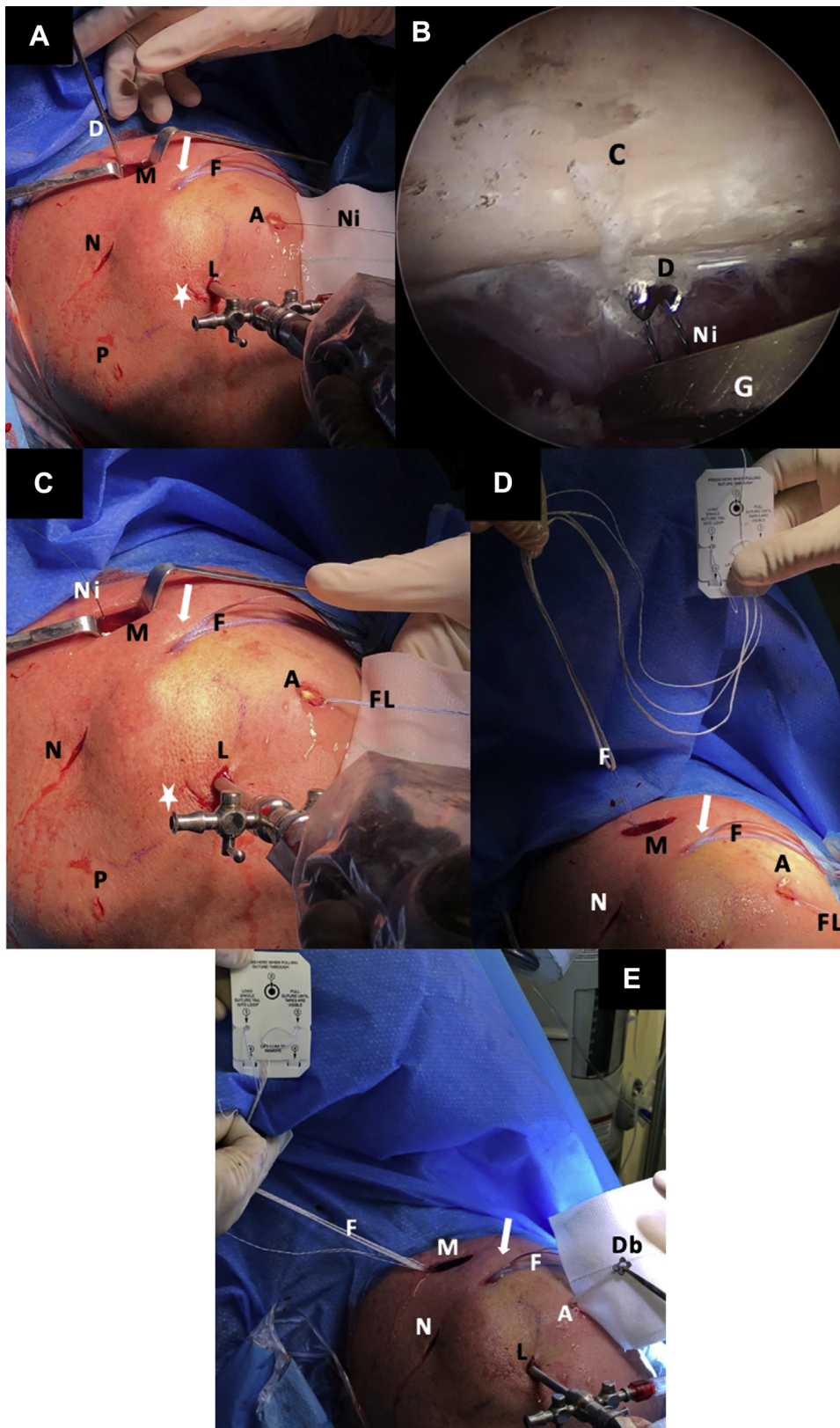


Fig 6. Superior view, right shoulder, beach-chair position. (A) The transclavicular transcoracoid tunnel is made with a 2.4-mm cannulated drill under guided radioscopy and arthroscopic visualization. A looped nitinol wire is passed through the cannulated drill. (B) The looped nitinol is retrieved from the coracoid tunnel's exit, after drilling guide removal, through the anterior portal located one fingerbreadth lateral to the coracoid tip and very close to the coracoacromial ligament (antero-lateral arthroscopic view). (C) Then, it is replaced with a FiberLink to avoid breakage of the nitinol wire. (D) The FiberLink is shuttled with the FiberTape Cerclage sutures through the clavicular tunnel and retrieved through the anterior portal. (E) An inferior Dog Bone Device (Arthrex) is assembled at the inferior tail of the FTC-S. Arrow indicates anterior clavicle skin incision; Star indicates lateral acromial skin incision. (A, anterior portal; C, coracoid; D, cannulated drill; Db, Dog Bone implant; F, FiberTape Cerclage sutures; FL, FiberLink; G, grasper; L, lateral portal; M, mini-open clavicular approach; N, Neviasser zone; Ni, looped nitinol wire; P, posterior arthroscopic portal.)

button fixation through various methods is currently being used.¹⁴ In that context, some authors preconized the use of a single-tunnel technique because, despite the

high success rates of double-tunnel anatomical techniques, it can be a more suitable option to minimize fracture risk.¹⁵⁻¹⁷

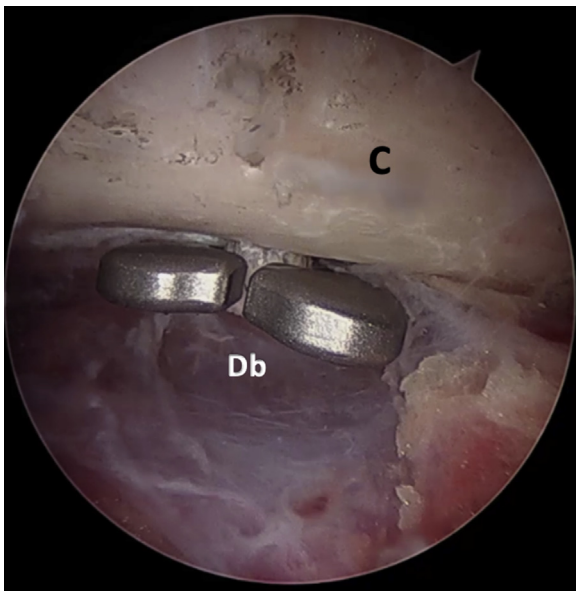


Fig 7. Arthroscopic view of the right shoulder through an anterolateral portal with the patient in the beach chair position. Final position of the inferior subcoracoid Dog Bone implants. (C, coracoid; Db, Dog Bone implant.)

In contrast, one of the most-studied factors with regards to AC dislocation fixation failures is persistent horizontal instability after single coracoclavicular fixation.^{8,18-23} Many surgical treatments have focused on single coracoclavicular fixation, since additional AC fixation can be time-consuming and complicated.²⁴ Nonetheless, biomechanical studies suggest that AC dislocations should not be managed using coracoclavicular fixation alone, but with additional AC augmentation. This is because the significant increase in anteroposterior translation demonstrates that the vertical coracoclavicular ligament cannot effectively restrain against anteroposterior instability.^{25,26}

Some authors have previously described a coracoclavicular fixation using 2 tunnels, transclavicular and transcoracoid, to mimic anatomic coracoclavicular ligaments, with an additional AC tunnel passing a cerclage to treat horizontal instability.²⁷ In these techniques, 3 tunnels are done in the clavicle. Published literature has shown that there is no biomechanical difference between making 1 or 2 tunnels in the clavicle, as done in our technique, with the additional advantage of diminishing the risk of fracture.¹⁸

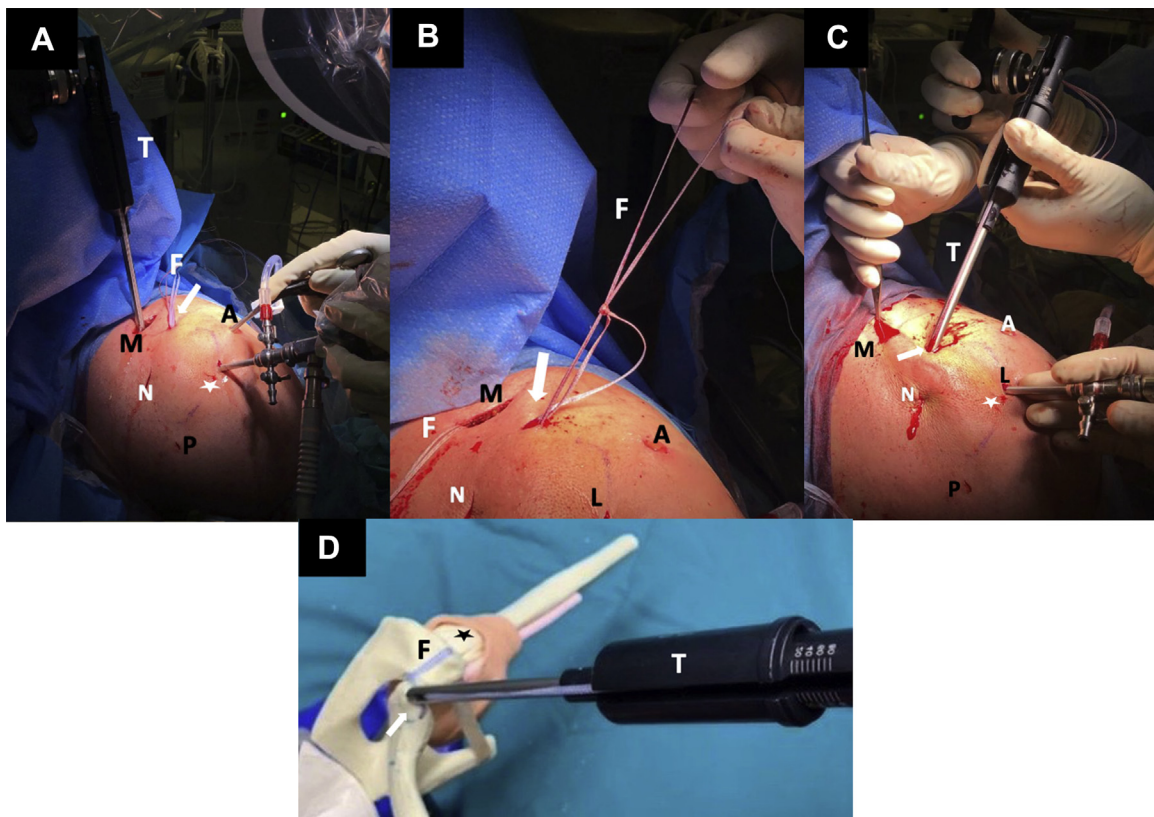


Fig 8. Superior view of the right shoulder; patient is in the beach chair position. Coracoclavicular and acromioclavicular FiberTape Cerclage sutures tying and tensioning. (A) Vertical coracoclavicular tensioning using the tensioner under X-ray anteroposterior view control. (B) Premanual tension on the preassembled racking hitch knot tails. Reduction and fixation of the dynamic posterior clavicle translation with the tensioner. (C) Manual reduction of the posterior AC joint, horizontal displacement with a gentle separator instrument, while the AC joint cerclage sutures are adjusted and tensioned with a tensioner. (D) Final tension of the FTC-s obtained with the tensioner (model). Arrow indicates anterior clavicle skin incision; star indicates lateral acromial skin incision. (A, anterior portal; AC, acromioclavicular; C, coracoid; D, drill; F, FiberTape Cerclage sutures; L, lateral portal; M, mini-open clavicular approach; N, Neviaser zone; Ni, looped nitinol wire; P, posterior arthroscopic portal.)

Table 2. Tips and Pitfalls of the Technique

Tips

- The head is slightly turned in the opposite direction to facilitate work over the clavicle.
- Traction of the arm helps expose the subcutaneous clavicle prominence facilitating anteroposterior clavicular drilling.
- The percutaneous incision for the clavicular and acromial tunnels must be made under radioscopic vision.
- The direction of the acromial tunnel's exit must converge with the posterior clavicular tunnel's exit.
- Use of a high-strength looped suture (FiberLink) to facilitate shuttling of the FiberTape Cerclage sutures through the tunnels, avoiding the risk of nitinol wire breakage.
- With a 30° scope, from the lateral subacromial space, we optimize visualization of the base of the coracoid process, which is found by using the acromion and coracoacromial ligament as a reference.
- Traction of the suture tapes should be done carefully during every step to avoid excessive slack and to improve sliding.
- After vertical CC tensioning, reduction of the AC joint can be maintained with a wide blunt-ended instrument at the mini-open clavicular superior incision, while the AC joint cerclage is adjusted.

Pitfalls

- The position of the C-arm is critical to identify percutaneous clavicle and acromial tunnel drilling.
- The drill guide aiming hook for vertical drilling should be placed through an anterior portal just in front of the tip of the coracoid to comfortably adapt it under the base of the coracoid and in the center of the clavicle, avoiding eccentricity of the tunnel.

AC, acromioclavicular; CC, coracoclavicular.

Taking all these features into account, the rate of complications reported in the literature is as high as 40%. These complications include infection, fractures, residual pain and loss of reduction.¹⁷ Acromial fractures also can be one of the complications seen, particularly when performing horizontal tunnel drilling.²⁸⁻³⁰

In this Technical Note, we present an arthroscopically assisted technique that allows simultaneous reduction and fixation of the coracoclavicular component, using a transcoracoid transclavicular single-tunnel double button Dog Bone and an FTC-S (Arthrex), and the AC component, using an X-ray-assisted transosseous percutaneous fixation with an FTC-S, for the treatment of high-grade ACJDs (Fig 9). The FTC-S had already been used in the treatment of ACJ dislocation and was described in a published open technique for vertical stabilization.³¹ The use of this construct holds many potential benefits. First, the construct is formed of 2 braided high-strength sutures that are linked and slipped through a preconfigured knot. This facilitates horizontal fixation of the modified figure-of-eight configuration of the AC joint construct.

In contrast, the tunnels of the vertical and horizontal constructs are made with 2.4-mm cannulated drills, potentially diminishing the possibility of facing clavicular and coracoid fractures. Also, the suspensory sliding system of vertical fixation composed of 2 Dog Bone buttons with 4 interconnected limbs of FiberTape sutures allows for a strong fixation through a single coracoid tunnel.

Another advantage of this technique is that the FTC-S with its preassembled racking hitch knot maintains AC joint reduction, whereas the vertical coracoclavicular construct is being adjusted and vice-versa. In addition, further tension can be applied after manual tensioning is done to both the vertical and horizontal components using a specific tensioner. Some risks and limitations of this technique are presented in Table 3.

In conclusion, this procedure describes a strong construct and a secure, reliable and reproducible technique with several potential benefits and that could likely decrease the high rate of complications and revision surgeries that remain a primary concern for shoulder surgeons.

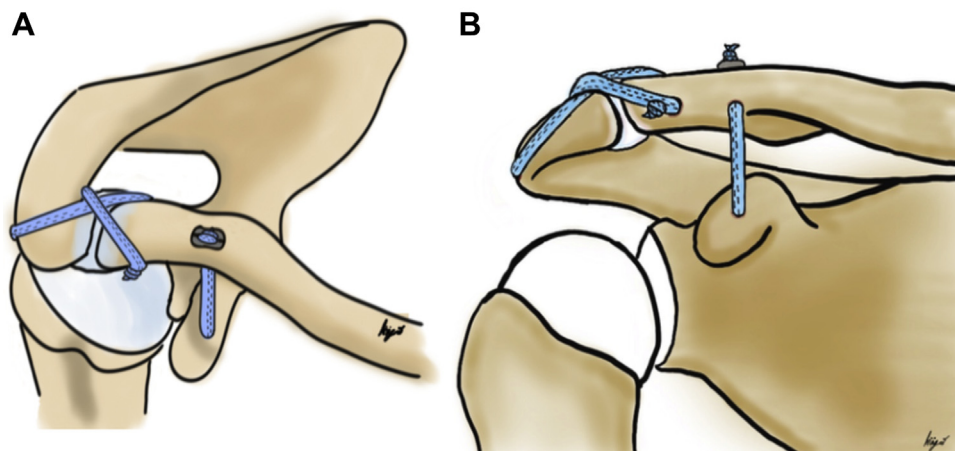


Fig 9. Schematic representation of the final coracoclavicular and acromioclavicular cerclages construct. Vertical and horizontal acromioclavicular fixation technique in a modified figure-of-eight configuration using 2 strong FiberTape Cerclage for the comprehensive treatment of acromioclavicular joint dislocations. (A) Superior view. (B) Anterior view.

Table 3. Risks and Limitations of the Technique

- The operating surgeon must be trained in advanced shoulder arthroscopy.
- Overtensioning may lead to cortical fracture.
- This is time consuming technique.
- This technique involves increased X-ray exposure when compared with open techniques.
- Superior coracoclavicular button and knot palpation can cause tenderness.

References

1. Gowd AK, Liu JN, Cabarcas BC, et al. Current concepts in the operative management of acromioclavicular dislocations: A systematic review and meta-analysis of operative techniques. *Am J Sports Med* 2019;47:2745-2758.
2. Kaplan LD, Flanigan DC, Norwig J, Jost P, Bradley J. Prevalence and variance of shoulder injuries in elite collegiate football players. *Am J Sports Med* 2005;33:1142-1146.
3. Dias JJ, Gregg PJ. Acromioclavicular joint injuries in sport: Recommendations for treatment. *Sport Med* 1991;11:125-132.
4. Phadke A, Bakti N, Bawale R, Singh B. Current concepts in management of ACJ injuries. *J Clin Orthop Trauma* 2019;10:480-485.
5. Tossy JD, Mead NC, Sigmoid HM. Acromioclavicular separations: Useful and practical classification for treatment. *Clin Orthop Relat Res* 1963;28:111-119.
6. Rockwood CA, Jr., Williams GR, Young DC. Injuries of the acromioclavicular joint. In: Rockwood CA, Jr., Green DP, Bucholz RW, Heckmann JD, eds. *Fractures in adults*. Philadelphia, New York: Lippincott-Raven, 1996;1341-1414.
7. Johansen JA, Grutter PW, McFarland EG, Petersen SA. Acromioclavicular joint injuries: Indications for treatment and treatment options. *J Shoulder Elbow Surg* 2011;20:S70-S82 (suppl 2).
8. Beitzel K, Mazzocca AD, Bak K, et al. ISAKOS upper extremity committee consensus statement on the need for diversification of the Rockwood classification for acromioclavicular joint injuries. *Arthroscopy* 2014;30:271-278.
9. Beris A, Lykissas M, Kostas-Agnantis I, Vekris M, Mitsionis G, Korompilias A. Management of acute acromioclavicular joint dislocation with a double-button fixation system. *Injury* 2013;44:288-292.
10. Stucken C, Cohen SB. Management of acromioclavicular joint injuries. *Orthop Clin North Am* 2015;46:57-66.
11. Markel J, Schwarting T, Malcherzyk D, Peterlein CD, Ruchholtz S, El-Zayat BF. Concomitant glenohumeral pathologies in high-grade acromioclavicular separation (type III-V). *BMC Musculoskelet Disord* 2017;18:1-5.
12. Pauly S, Gerhardt C, Haas NP, Scheibel M. Prevalence of concomitant intraarticular lesions in patients treated operatively for high-grade acromioclavicular joint separations. *Knee Surg Sport Traumatol Arthrosc* 2009;17:513-517.
13. Salzmann GM, Walz L, Buchmann S, Glabgyl P, Venjakob A, Imhoff AB. Arthroscopically assisted 2-bundle anatomical reduction of acute acromioclavicular joint separations. *Am J Sports Med* 2010;38:1179-1187.
14. Scheibel M, Dröschel S, Gerhardt C, Kraus N. Arthroscopically assisted stabilization of acute high-grade acromioclavicular joint separations. *Am J Sports Med* 2011;39:1507-1516.
15. Nuzzo MS, Adamson GJ, Lee TQ, McGarry MH, Husak L. Biomechanical comparison of fracture risk created by 2 different clavicle tunnel preparations for coracoclavicular ligament reconstruction. *Orthop J Sport Med* 2014;2:1-6.
16. Banffy MB, Uquillas C, Neumann JA, ElAttrache NS. Biomechanical evaluation of a single- versus double-tunnel coracoclavicular ligament reconstruction with acromioclavicular stabilization for acromioclavicular joint injuries. *Am J Sports Med* 2018;46:1070-1076.
17. Walz L, Salzmann GM, Fabbro T, Eichhorn S, Imhoff AB. The anatomic reconstruction of acromioclavicular joint dislocations using 2 TightRope devices: A biomechanical study. *Am J Sports Med* 2008;36:2398-2406.
18. Hislop P, Sakata K, Ackland DC, Gotmaker R, Evans MC, Orth F. Acromioclavicular joint stabilization: A biomechanical study of bidirectional stability and strength. *Orthop J Sports Med* 2019;7:2325967119836751.
19. Frank RM, Cotter EJ, Leroux TS, Romeo AA. Acromioclavicular joint injuries: Evidence-based treatment. *J Am Acad Orthop Surg* 2019;27:775-788.
20. Maziak N, Audige L, Hann C, Minkus M, Scheibel M. Factors predicting the outcome after arthroscopically assisted stabilization of acute high-grade acromioclavicular joint dislocations. *Am J Sports Med* 2019;47:2670-2677.
21. Lacheta L, Dekker TJ, Elrick BP, Millett PJ. Optimal management of acromioclavicular dislocation: Current perspectives. *Orthop Res Rev* 2020;12:27-44.
22. North AS, Wilkinson T. Surgical reconstruction of the acromioclavicular joint: Can we identify the optimal approach? *Strategies Trauma Limb Reconstr* 2018;13:69-74.
23. Sirin E, Aydin N, Topkar OM. Shoulder & elbow acromioclavicular joint injuries: Diagnosis, classification and ligamentoplasty procedures. *EFORT Open Rev* 2018;3:426-433.
24. Banffy MB, van Eck CF, ElAttrache NS. Clinical outcomes of a single-tunnel technique for coracoclavicular and acromioclavicular ligament reconstruction. *J Shoulder Elbow Surg* 2018;27:S70-S75.
25. Saier T, Venjakob AJ, Minzlaff P, et al. Value of additional acromioclavicular cerclage for horizontal stability in complete acromioclavicular separation: Abiomechanical study. *Knee Surg Sport Traumatol Arthrosc* 2015;23:1498-1505.
26. Beitzel K, Obopilwe E, Apostolakis J, et al. Rotational and translational stability of different methods for direct acromioclavicular ligament repair in anatomic acromioclavicular joint reconstruction. *Am J Sports Med* 2014;42:2141-2148.
27. Hann C, Kraus N, Minkus M, Maziak N, Scheibel M. Combined arthroscopically assisted coraco- and acromioclavicular stabilization of acute high-grade acromioclavicular joint separations. *Knee Surg Sport Traumatol Arthrosc* 2018;26:212-220.
28. Dyrna F, de Oliveira CCT, Nowak M, et al. Risk of fracture of the acromion depends on size and orientation of acromial bone tunnels when performing acromioclavicular

- reconstruction. *Knee Surg Sport Traumatol Arthrosc* 2018;26:275-284.
29. Shin SJ, Kim NK. Complications after arthroscopic coracoclavicular reconstruction using a single adjustable-loop-length suspensory fixation device in acute acromioclavicular joint dislocation. *Arthroscopy* 2015;31:816-824.
 30. Beitzel K, Cote MP, Apostolakos J, et al. Current concepts in the treatment of acromioclavicular joint dislocations. *Arthroscopy* 2013;29:387-397.
 31. Youn GM, Chakrabarti MO, McGahan PJ, Chen JL. Acromioclavicular joint repair using a suture cerclage tensioning system. *Arthrosc Tech* 2019;8:e1555-e1560.