

Title	Retroperitoneal lymphatic malformation causing scrotal swelling- a useful diagnostic work-up with two-phase MRI to differentiate from scrotal lymphatic malformation or abdomino-scrotal hydrocele
Author(s)	Ichijo, Chizue; Takami, Shohei; Suzuki, Kan; Fujishiro, Jun; Watanabe, Miho
Citation	Journal of Pediatric Surgery Case Reports. 64 P.101701
Issue Date	2021-01
Text Version	publisher
URL	http://hdl.handle.net/11094/78335
DOI	10.1016/j.epsc.2020.101701
rights	© 2020 The Authors. This is an open access article under the CC BY-NC-ND license.
Note	

Osaka University Knowledge Archive : OUKA

<https://ir.library.osaka-u.ac.jp/>

Osaka University



Retroperitoneal lymphatic malformation causing scrotal swelling– a useful diagnostic work-up with two-phase MRI to differentiate from scrotal lymphatic malformation or abdomino-scrotal hydrocele

Chizue Ichijo^a, Shohei Takami^a, Kan Suzuki^a, Jun Fujishiro^a, Miho Watanabe^{a,b,*}

^a The Department of Pediatric Surgery, The University of Tokyo, Tokyo, Japan

^b The Department of Pediatric Surgery, Osaka University Graduate School of Medicine, Osaka, Japan

ARTICLE INFO

Keywords:

Laparoscopy

MRI

Retroperitoneal lymphatic malformation

ABSTRACT

Background: Lymphatic malformation (LM) is an abnormal collection of lymphatic fluid within cysts or channels. LM can occur in any part of the body, but LM leading to scrotal swelling is very rare, and this unusual location often leads to diagnostic errors because the most common cause of a scrotal cystic lesion is a hydrocele.

Summary: In the case presented here, a previously healthy 3-year-old boy recently developed a left scrotal swelling clinically mimicking a communicating hydrocele. However, a diagnostic laparoscopy showed a cystic lesion at the left internal inguinal ring with a closed internal inguinal ring, which is not an expected finding of communicating hydrocele. Differential diagnoses at surgery were scrotal LM, retroperitoneal LM, or abdomino-scrotal hydrocele (ASH). Two phase MRI performed both at the time of scrotal swelling and scrotal non-swelling showed a retroperitoneal LM bulging into the scrotum via the inguinal canal. Therefore, the retroperitoneal LM was completely resected using the inguinal approach.

Conclusion: LM causing scrotal cystic lesion is rare, and it requires a high index of suspicion to make the correct diagnosis. Laparoscopy was needed to rule out the communicating hydrocele, and two-phase MRI was very useful to differentiate retroperitoneal LM causing scrotal swelling from scrotal LM or ASH. Both examinations helped with diagnosis and treatment planning.

1. Introduction

Lymphatic malformation (LM) is an abnormal collection of lymphatic fluid within cysts or channels due to errors in formation and development of the lymphatic vessels during fetal development. LM most commonly occurs in the head and neck, but it can involve any area of the body. LM in the inguinoscrotal region is rare, occurring in about 0.2% of patients with groin and scrotal swellings [1].

On the other hand, hydrocele is the most common cause of pediatric groin and/or scrotal fluid collection. Patients with hydrocele are usually assessed by history and clinical examination, and surgical treatment is offered when a hydrocele remains after the age of 2 years.

We present a rare case of a 3-year-old boy with a retroperitoneal LM that was causing scrotal swelling and was clinically mimicking a communicating hydrocele, which was diagnosed by both laparoscopy and two phase MRI at the time of scrotal swelling and scrotal non-swelling.

2. Case report

A previously healthy 3-year-old boy presented to the clinic with a 2-month history of left sided scrotal swelling (Fig. 1). Examination demonstrated a left scrotal swelling, which was reduced by hand in a supine position, but was protruded in a standing position. He was clinically diagnosed with a left communicating hydrocele and was scheduled for laparoscopic repair of hydrocele. However, the laparoscopy demonstrated a retroperitoneal cystic bulge over the testicular vessels at the left internal inguinal ring, and also showed a closed left internal inguinal ring (Fig. 2). These findings suggested either a scrotal LM, a retroperitoneal LM, or possible abdomino-scrotal hydrocele (ASH), with a communicating hydrocele less likely. The surgery was stopped, and Magnetic resonance imaging (MRI) was planned for further evaluation. MRI was performed both at the time of scrotal swelling and scrotal non-swelling. MRI at the time of scrotal swelling demonstrated a massive hourglass shaped cystic lesion surrounding the spermatic cord,

* Corresponding author. The Department of Pediatric surgery, Osaka University Graduate School of Medicine 2-2 Yamadaoka, Suita, Osaka, 565-0871, Japan.
E-mail address: watanabe@ped surg.med.osaka-u.ac.jp (M. Watanabe).

<https://doi.org/10.1016/j.epsc.2020.101701>

Received 1 January 2020; Received in revised form 30 October 2020; Accepted 4 November 2020

Available online 8 November 2020

2213-5766/© 2020 The Authors.

Published by Elsevier Inc.

This is an open access article under the CC BY-NC-ND license

(<http://creativecommons.org/licenses/by-nc-nd/4.0/>).

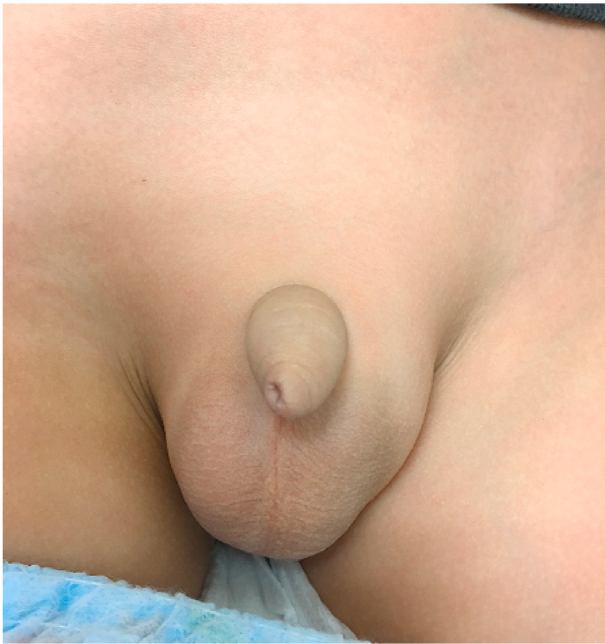

Fig. 1. Clinical picture left scrotal swelling.

extending from the lower retroperitoneum to the bottom of the scrotum via a left inguinal canal (Fig. 3-A). The cystic lesion showed high intensity on T2-weighted imaging and low intensity on T1-weighted imaging. There was no fluid-fluid level in the cystic lesion, and no solid component. Interestingly, MRI at the time of scrotal non-swelling after reducing the fluid in the scrotum demonstrated a localized simple cystic lesion at the lower retroperitoneum (Fig. 3-B). Thus, the radiological diagnosis was retroperitoneal lymphatic malformation extending into the scrotum via the inguinal canal. Since the left scrotal swelling was progressing in size, surgical resection was performed using the inguinal approach. Surgical findings showed the cystic lesion originated in the retroperitoneal space and extended to the bottom of scrotum and was

tightly adherent to the patent processus vaginalis and the spermatic cord. The cystic lesion was carefully dissected off the processus vaginalis and the spermatic cord and it was completely removed sparing the testis and cord. The patent processus vaginalis was highly ligated at the external inguinal ring. The pathological findings were consistent with LM. The postoperative period was uneventful. The patient has been on our follow-up for the past 2 years without any problem.

3. Discussion

The most common cause of a scrotal cystic lesion is hydrocele. Differential diagnosis includes communicating or non-communicating hydrocele, inguinal hernia, spermatocele, spermatic varicocele, and LM. However, LM causing scrotal swelling is very rare, and this unusual location often leads to diagnostic errors. In this case, laparoscopy showed a closed inguinal internal ring, a finding which was very useful to rule out a communicating hydrocele. Laparoscopy also showed a cystic bulge over the testicular vessels at the left internal inguinal ring, which suggested differential diagnoses including a scrotal LM, a retroperitoneal LM, or possible ASH, and proceed with further evaluation. LM is characterized by an abnormal collection of lymphatic fluid and involves any area of the body. However, retroperitoneal LM is rare, accounting for 0.05% of all LM [2], and scrotal LM is even less likely [3]. The closure of the inguinal canal and ring depends on the site and size of LM. The radiological findings of LM are very broad. It can be a monocystic or multicystic mass with homogeneous echo-free components. On the other hand, ASH is usually characterized by a non-communicating dumbbell-shaped two-sac intercommunicating hydrocele extending to the abdominal cavity, representing 0.17–3.1% of all hydroceles. The inguinal canal and ring are mostly dilated due to the pressure effect in ASH, and the abdominal cystic part protrudes into the abdomen and tracks down the inguinal canal [4]. The radiological finding is usually a large intra-abdominal component connecting to the scrotum. It can be a single sac, bilocular, or multilocular sacs [5].

Treatment basically involves complete surgical removal of the lesion in the case of LM and surgical excision after aspiration of fluid in the case of ASH [6]. Therefore, preoperative assessment of the location and the nature of the lesion is critical in order to minimize the recurrence. The

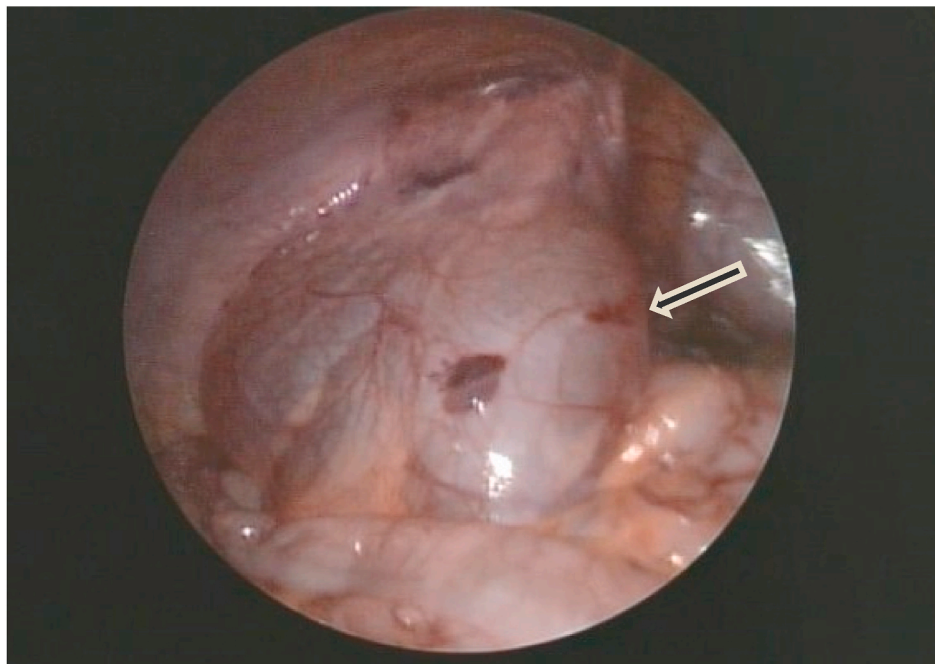


Fig. 2. Laparoscopic findings intraoperative picture at laparoscopy of the patient showing a cystic bulging lesion above the left testicular vessels and an intact internal inguinal ring (Arrow).

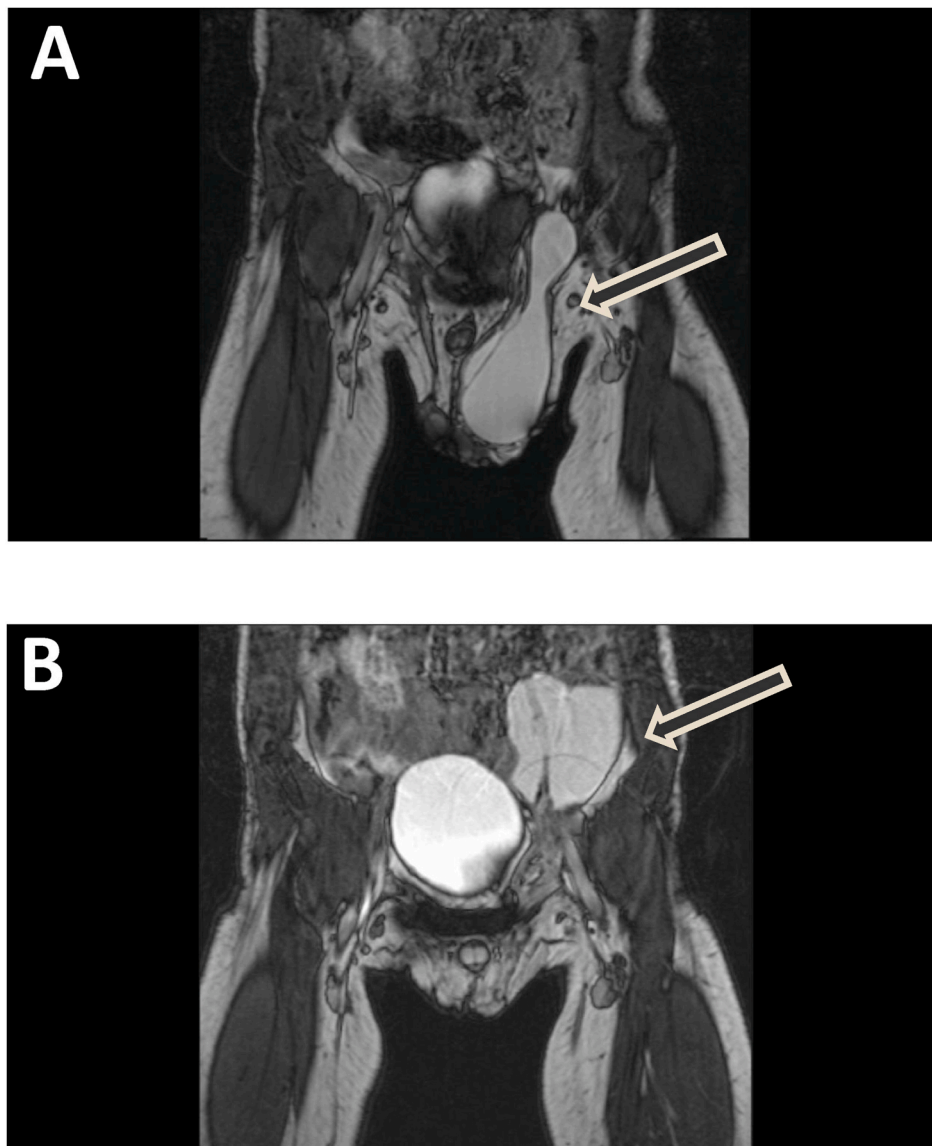


Fig. 3. Abdominal MRI at the time of scrotal swelling and the time of non-scrotal swelling (A) MRI at the time of scrotal swelling displaying abdomen-scrotal connection of cystic lesion. Spermatic cord was seen in the cystic lesion. (B) MRI at the time of scrotal non-swelling after reducing the scrotal swelling by hand showing localized intraabdominal cystic mass located at retroperitoneum.

two-phase evaluation by MRI, taken at the time of scrotal swelling as well as at the time of scrotal non-swelling after reducing the fluid in the scrotum, was very informative. It demonstrated that scrotal fluid diminished after reducing the scrotal cystic lesion while the patient laid on the bed, and that the simple cystic component located at the retroperitoneum. It suggested that the cystic lesion was not scrotal LM, or ASH, but rather a retroperitoneal LM bulging into the scrotum with gravity.

The retroperitoneal LM in this case became symptomatic and gradually progressed in size, which was considered a risk for compression of the spermatic cord and the surgery was planned. Sirolimus and sclerotherapy [7] could be alternative treatments. However, Sirolimus was out of the insurance coverage for LM in Japan, and Sclerotherapy was not considered to be feasible because of a difficulty of needle access in the abdominal approach as well as a risk of spermatic cord injury caused by sclerosing agents in the scrotal approach. Therefore, a complete resection was planned and we chose the inguinal approach rather than laparoscopic approach because inguinal approach could visualize the spermatic vessels and cord easily to avoid injury to them. The inguinal approach was also very effective because the cystic lesion was tightly

adherent to the spermatic cord and the patent processus vaginalis and it required a precise dissection. The laparoscopic approach would not be performed.

4. Conclusion

LM causing scrotal cystic lesion is rare, and it requires a high index of suspicion to make the correct diagnosis. Laparoscopy is needed to rule out the communicating hydrocele, and two-phase MRI was very useful to differentiate retroperitoneal LM causing scrotal swelling from scrotal LM or ASH, which helped with the diagnosis and treatment planning.

Patient consent

Patient consent was obtained in the form of opt-out method on the center's website. This report does not contain any personal information that could lead to the identification of the patient.

Funding

No funding or grant support.

Authorship

All authors attest that they meet the current ICMJE criteria for Authorship.

Declaration of competing interest

The authors declare that they have no known competing financial interests or personal relationships that could have appeared to influence the work reported in this paper.

References

- [1] Abantanga FA. Groin and scrotal swelling in children aged 5 years and below: a review of 535 cases. *Pediatr Surg Int* 2003;19(6):446–50.
- [2] Lal A, Gupta P, Singhal M, et al. Abdominal lymphatic malformation: spectrum of imaging findings. *Indian J Radiol Imag* 2016;26(4):423–8.
- [3] Akaike G, Nozaki T, Makidono A, et al. A case of lymphatic malformation/lymphangioma of the scrotum. *Acta radiologica Short Rep* 2012;1:14.
- [4] Gadelkareem RA. Abdominoscrotal hydrocele: a systematic review and proposed clinical grading. *Afr J Urol* 2008;24(2):83–92.
- [5] Spellman K, Stock JA, Norton KI. Abdominoscrotal hydrocele: a rare cause of a cystic abdominal mass in children. *Urology* 2008;71(5):832–3.
- [6] Hegde S, Jadhav V, Shankar G, et al. Not a hydrocele! *J Pediatr* 2018 Jun;197:311.
- [7] Rassam J, Healey AD, Wood SJ, et al. A challenging abdomino-scrotal hydrocele-successful resolution with the help of interventional radiology guided sclerosis. *J Surg Case Rep* 2018 Sep 11;(9):2018.