



# Helmet Non-invasive Ventilation in a Do-Not-Intubate Patient with Acute Respiratory Failure

著者名	SEINO Yusuke, SAISHU Yumi, NOMURA Takeshi
journal or publication title	Tokyo Women's Medical University Journal
volume	4
page range	104-107
year	2020-12-25
URL	<a href="http://hdl.handle.net/10470/00032755">http://hdl.handle.net/10470/00032755</a>

## Helmet Non-invasive Ventilation in a Do-Not-Intubate Patient with Acute Respiratory Failure

Yusuke Seino, Yumi Saishu, and Takeshi Nomura

Department of Intensive Care Medicine, Tokyo Women's Medical University, Tokyo, Japan

(Accepted September 4, 2020)

(Advance Publication by J-STAGE October 16, 2020)

Non-invasive ventilation (NIV) is occasionally used for management of acute respiratory failure in a do-not-intubate (DNI) patient, when conventional oxygen administration or high-flow nasal cannula fail to improve respiratory distress. In such situations, the duration of NIV may be prolonged and cause complications due to the oro-nasal mask. The helmet can be an alternative interface to the oro-nasal mask for improving tolerability and reducing complications. Although the efficacy of helmet NIV has been demonstrated in patients with acute respiratory distress syndrome, the utility of helmet NIV in DNI patients has not been discussed. We present the case of a DNI patient with acute respiratory failure, in which helmet NIV was used instead of the conventional oro-nasal mask. Helmet NIV proved effective in preventing pressure-induced skin complications associated with oro-nasal mask NIV and relieved discomfort in this patient. Furthermore, the patient's communication ability was retained, thereby respecting the wish of the patient and his family.

**Key Words:** helmet, non-invasive ventilation, do-not-intubate patient, acute respiratory failure

### Introduction

Non-invasive ventilation (NIV) is occasionally used for management of acute respiratory failure in a do-not-intubate (DNI) patient, when conventional oxygen administration or high-flow nasal cannula (HFNC) fail to improve respiratory status. In such situations, the duration of NIV is prolonged and problems caused by the commonly used oro-nasal mask such as skin erosion of the nasal dorsum complicate the continuation of NIV. The helmet can be an alternative to the oro-nasal mask for improving tolerability and reducing complications. Although the efficacy of helmet NIV has been demon-

strated in patients with acute respiratory distress syndrome (ARDS),<sup>1,3</sup> the usefulness of helmet NIV in DNI patients is unknown. We present the case of a DNI patient with acute respiratory failure, in whom helmet NIV was used, after a complication with oro-nasal mask ventilation.

### Case Presentation

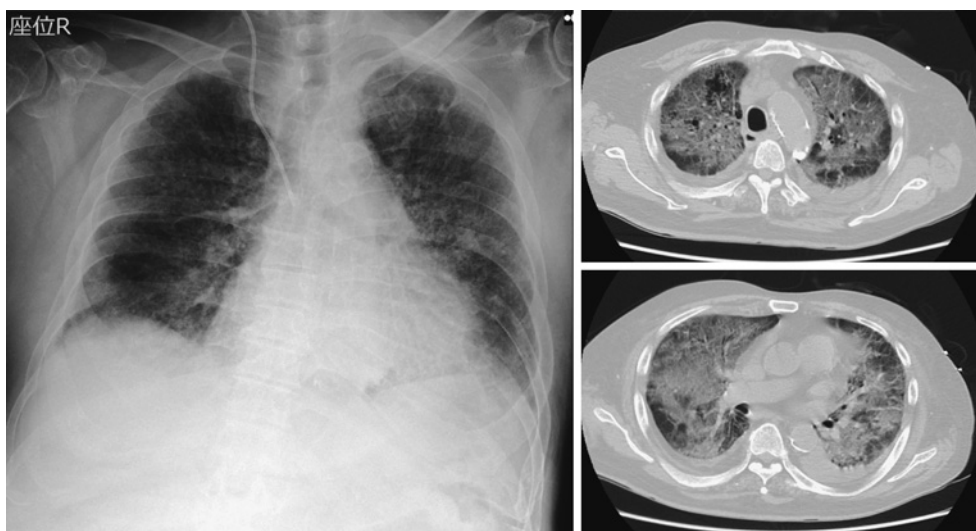
A 72-year-old man with end-stage renal disease due to diabetes mellitus presented with hallux gangrene and osteomyelitis, and was admitted in our hospital for surgical management. He underwent uneventful amputation of the

---

Corresponding Author: Yusuke Seino, Department of Intensive Care Medicine, Tokyo Women's Medical University, 8-1 Kawada-cho, Shinjuku-ku, Tokyo 162-8666, Japan. [yu-seino@twmu.ac.jp](mailto:yu-seino@twmu.ac.jp)

doi: 10.24488/twmuj.2020010

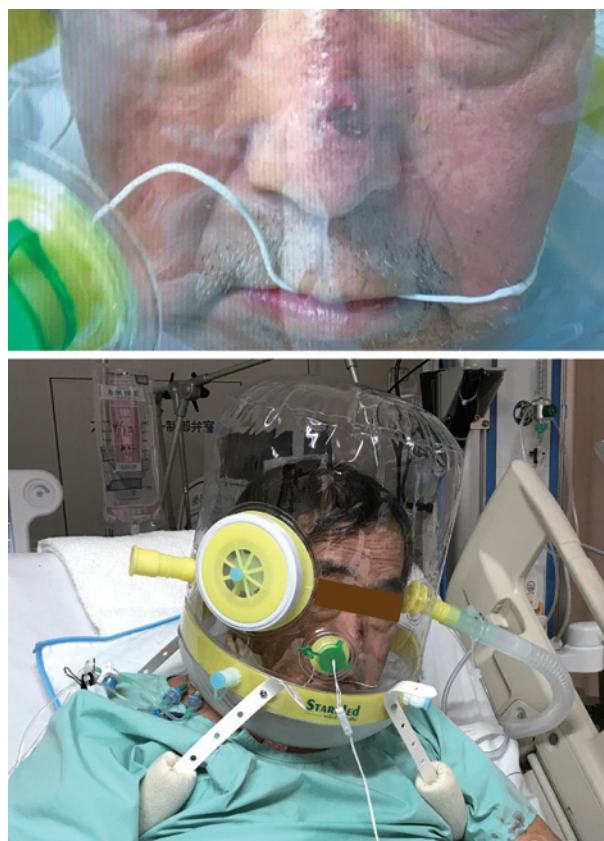Copyright © 2020 Society of Tokyo Women's Medical University. This is an open access article distributed under the terms of Creative Commons Attribution License (CC BY), which permits unrestricted use, distribution, and reproduction in any medium, provided the original source is properly credited.



**Figure 1** Supine chest X-ray (CXR, left) and computed tomography (CT, right) taken on re-admission to the intensive care unit. CXR shows diffuse ground-glass opacity, blunted border of diaphragm, and cardiomegaly. CT also shows diffuse ground-glass opacity, indicating recurrence of pneumonia and pulmonary edema.

right great toe. On the 16th postoperative day, he began complaining of shortness of breath due to hypoxia, and was transferred to our intensive care unit (ICU) after NIV (Respironics V60, Philips Healthcare, The Netherlands) support was initiated. Chest X-ray (CXR) and computed tomography (CT) revealed diffuse ground-glass opacity and consolidation. The patient was diagnosed with pneumonia and pulmonary edema. Although respiratory management by endotracheal intubation was recommended in view of the need for long-term and effective respiratory support, the patient and his family clearly declined the procedure. Therefore, NIV (S/T mode, FIO<sub>2</sub> 0.5, IPAP 10 cmH<sub>2</sub>O, EPAP 6 cmH<sub>2</sub>O) was continued. Fortunately, his respiratory status improved gradually with antibiotics and haemodialysis; consequently, he was able to wean from NIV. He was discharged from the ICU on the 10th day.

However, the patient was re-admitted to the ICU on the 12th day after discharge due to relapse of hypoxia. CXR and CT revealed diffuse ground-glass opacity (**Figure 1**). Although NIV using an oro-nasal mask was initiated immediately after re-admission, pain caused by skin erosion of the nasal dorsum, which had developed during the previous treatment, made continuation of ventilation impossible (**Figure 2, upper**). The patient also strongly complained about the discomfort caused by tight fixation of the headband. In spite of the relatively low degree of support provided by the ventilator, continuation of ther-



**Figure 2** A skin erosion of the nasal dorsum, which developed during the first admission to the intensive care unit (upper). Helmet non-invasive ventilation (StarMed CaStar R, Intersurgical, Italy, lower).

apy was essential due to quick desaturation on removal of the mask. As a result of the discussion of the treatment

strategy at a multidisciplinary conference, the interface of NIV was changed from oro-nasal mask to helmet (StarMed CaStar R, Intersurgical, Italy) on the third ICU day (**Figure 2, lower**). The helmet relieved the pain caused by the oro-nasal mask, and facilitated continuation of ventilation. Although the patient complained of noise and dry mouth, this did not pose a problem for the continuation of helmet NIV. Dexmedetomidine, a sedative-analgesic agent, was administered only at night. Hypercapnia did not occur during helmet NIV. The patient was able to wean from NIV using HFNC. He was discharged from the ICU after 10 days. However, he died due to progression of hypoxia without re-admission to the ICU. The patient's family was sincerely content to have been able to communicate with him until the end of his life owing to a treatment which was in line with his wishes.

## Discussion

In recent times, NIV has been used frequently in DNI patients with acute respiratory failure as a last resort. Reportedly, the percentage of DNI patients receiving total NIV therapy is from 9.4 to 18.9%.<sup>4,5</sup> Although currently, NIV plays a major role in respiratory management, there are many complications in its long-term use, despite maintenance of good respiratory support. The incidence of complications has been reported as 10-20%.<sup>4,6</sup> Among the complications, discomfort and pain due to pressure of the mask are serious problems that may hinder NIV therapy. Therefore, the helmet interface was introduced to overcome the problems associated with use of the oro-nasal mask.

Helmet interface of NIV has some benefits and drawbacks compared to the conventional oro-nasal mask. The benefits include no direct skin compression, ease of communication, good visual field of the patient, easy management, reduction of leakage, and application of adequate positive pressure.<sup>7,8</sup> These benefits could contribute to favourable results in patients who require long-term ventilatory support. However, the drawbacks are re-breathing through large volume of air within helmet, patient-ventilator asynchrony by high compliance of helmet, air inflow noise, and high cost.<sup>9,10</sup>

Compared to face mask NIV, the use of helmet NIV in

patients with ARDS has been reported to reduce the rate of tracheal intubation, 90-day mortality, duration of hospitalisation, and the prevalence of ICU-acquired weakness and delirium.<sup>1,2</sup> Furthermore, helmet NIV facilitated early mobilisation and contributed to shorter hospitalisation.<sup>2</sup>

Although there are limited reports on the application of helmet NIV in DNI patients, given that it is efficient in patients with ARDS, it has been suggested that this procedure can extend the tolerable duration of ventilation, and contribute to maintenance of the patient's quality of life. In our opinion, helmet NIV is an acceptable procedure considering the prevention of further complications and maintenance of good communication in the patient. In case of failure of NIV due to the above complications, palliative therapy without ventilation might have been required.<sup>11</sup>

However, in retrospect, continuation of helmet NIV in the present case could be controversial, as the patient may be considered to be in the end-of-life phase. Prolonging the terminal stage of the patient might seem unnecessary, and the medical expenses would increase, as the NIV helmet is expensive (helmet, JPY29,800; oro-nasal mask, JPY12,000-26,000). In this patient, pulmonary edema, a good indication for ventilatory support, might have been the cause of hypoxia, which encouraged the use of NIV even in a DNI patient. In addition, the patient and his family strongly desired recovery from respiratory failure without the use of invasive mechanical ventilation such as tracheal intubation. Generally, when such patients become intolerant of oro-nasal mask NIV, NIV should be discontinued and changed to palliative care using narcotics to relieve dyspnea.<sup>11</sup> However, given that the transition to palliative care may have been difficult for him to accept, helmet NIV might be a good option for respecting the wish of the patient and his family.

## Conclusion

In a DNI patient with acute respiratory failure, helmet NIV was effective in preventing complications associated with mask ventilation, relieving discomfort, and providing continual NIV, thereby respecting the patient's and family's wishes. Although helmet NIV was able to fulfil the family's demands, unnecessary prolongation of the

terminal stage of a patient with NIV should be avoided.

**Conflicts of Interest:** The authors declare that there are no conflicts of interest regarding the publication of this article.

### References

1. Patel BK, Wolfe KS, Pohlman AS et al: Effect of noninvasive ventilation delivered by helmet vs face mask on the rate of endotracheal intubation in patients with acute respiratory distress syndrome: A randomized clinical trial. *JAMA* 315: 2435–2441, 2016
2. Patel BK, Wolfe KS, MacKenzie EL et al: One-year outcomes in patients with acute respiratory distress syndrome enrolled in a randomized clinical trial of helmet versus facemask noninvasive ventilation. *Crit Care Med* 46: 1078–1084, 2018
3. Redondo Calvo FJ, Madrazo M, Gilsanz F et al: Helmet noninvasive mechanical ventilation in patients with acute postoperative respiratory failure. *Respir Care* 57: 743–752, 2012
4. Levy M, Tanios MA, Nelson D et al: Outcomes of patients with do-not-intubate orders treated with noninvasive ventilation. *Crit Care Med* 32: 2002–2007, 2004
5. Azoulay E, Kouatchet A, Jaber S et al: Noninvasive mechanical ventilation in patients having declined tracheal intubation. *Intensive Care Med* 39: 292–301, 2013
6. Corral-Gudino L, Jorge-Sánchez RJ, García-Aparicio J et al: Use of noninvasive ventilation on internal wards for elderly patients with limitations to respiratory care: a cohort study. *Eur J Clin Invest* 41: 59–69, 2011
7. Hui DS, Chow BK, Lo T et al: Exhaled air dispersion during noninvasive ventilation via helmets and a total facemask. *Chest* 147: 1336–1343, 2015
8. BaHammam AS, Singh TD, Gupta R et al: Choosing the proper interface for positive airway pressure therapy in subjects with acute respiratory failure. *Respir Care* 63: 227–237, 2018
9. Cavaliere F, Conti G, Costa R et al: Noise exposure during noninvasive ventilation with a helmet, a nasal mask, and a facial mask. *Intensive Care Med* 30: 1755–1760, 2004
10. Taccone P, Hess D, Caironi P et al: Continuous positive airway pressure delivered with a “helmet”: effects on carbon dioxide rebreathing. *Crit Care Med* 32: 2090–2096, 2004
11. Curtis JR, Cook DJ, Sinuff T et al: Noninvasive positive pressure ventilation in critical and palliative care settings: understanding the goals of therapy. *Crit Care Med* 35: 932–939, 2007