



Swallowing Impairment in Patients with Cerebral Small Vessel Disease

著者名	SEKI Misa, YOSHIZAWA Hiroshi, KUBOTA Megumi, TOI Sono, KITAGAWA Kazuo
journal or publication title	Tokyo Women's Medical University Journal
volume	4
page range	24-32
year	2020-12-25
URL	http://hdl.handle.net/10470/00032743

Swallowing Impairment in Patients with Cerebral Small Vessel Disease

Misa Seki, Hiroshi Yoshizawa, Megumi Kubota,
Sono Toi, and Kazuo Kitagawa

Department of Neurology, Tokyo Women's Medical University School of Medicine, Tokyo, Japan

Tokyo Women's Medical University, Tokyo, Japan

(Accepted January 15, 2020)

(Advance Publication by J-STAGE April 3, 2020)

Background: Dysphagia is the important complication related to cerebral small vessel disease (CSVD) including lacunar infarcts (LIs), white matter hyperintensity (WMH), cerebral microbleeds (CMBs) and perivascular spaces (PVS). The aim of this study was to investigate the relationship between swallowing function and CSVD.

Methods: This study is based on the authors' prospective registry between 2015 and 2017. We enrolled 352 patients and signs of CSVD on magnetic resonance imaging (MRI). Swallowing function was evaluated using the Repetitive Saliva Swallowing Test and the Modified Water Swallow Test. On MRI, the severity of WMH including deep WMH (DWMH), the number of LIs, CMBs and PVS were assessed.

Results: Seventy-nine out of 352 (24.4%) patients exhibited swallowing impairment. Mean age was 70.4 ± 10.6 years and 218 were male (63.4%). Those with dysphagia had higher WMH scores and a greater number of LIs than those without. The severity of whole WMH, frontal and parietal DWMH were associated with dysphagia. After adjustment for age, sex, vascular risk factors, and Mini Mental State Examination, whole WMH severity still associated with dysphagia.

Conclusions: WMH, particularly frontal and parietal DWMH, was associated with swallowing impairment.

Key Words: deglutition, deep white matter hyperintensity, stroke

Introduction

Post-stroke dysphagia has long been considered one of several serious complications because it may lead to aspiration pneumonia, malnutrition and mortality.¹ Cerebral small vessel disease (CSVD) has attracted attention because it is believed to be associated not only with stroke but also with dementia, gait disturbance, movement disorders, urinary problems, dysphagia and mood disor-

ders.²⁻⁷ However, despite substantial information regarding concomitant CSVD in dysphagia in acute and chronic stroke,^{1,8} few studies have examined the relationship between asymptomatic CSVD and swallowing problems. We investigate to clarify the association between each CSVD subtype and swallowing impairment in apparently healthy subjects including those with a history of stroke.

Corresponding Author: Misa Seki, Department of Neurology, School of Medicine, Tokyo Women's Medical University, 8-1 Kawada-cho, Shinjuku-ku, Tokyo 162-8666, Japan. seki.misa@twmu.ac.jp

doi: 10.24488/twmuj.2019102

Copyright © 2020 Society of Tokyo Women's Medical University. This is an open access article distributed under the terms of Creative Commons Attribution License (CC BY), which permits unrestricted use, distribution, and reproduction in any medium, provided the original source is properly credited.

Materials and Methods

1. Subjects

Subjects with CSVD were recruited as part of the prospective study known as the Tokyo Women's Medical University Cerebral Vessel Disease Registry. Consecutive outpatients >40 years of age, with any cerebrovascular risk factor(s), including history of stroke, arterial hypertension, diabetes mellitus, hyperlipidemia, coronary artery disease or smoking, were recruited. Each subject was able to independently perform activities of daily living. Individuals with aphasia, impaired comprehension, dementia, degenerative disorders, current stroke or unable to walk were excluded.

Enrolled participants underwent cranial magnetic resonance imaging (MRI), Mini Mental State Examination (MMSE) (score range 0 to 30)⁹ and the Japanese version of the Montreal Cognitive Assessment (MoCA-J) (score range 0 to 30)¹⁰ to assess cognitive function. At enrollment, we examined both cognitive function and swallowing test at the same day. A total of 419 subjects were recruited from October 2015 to July 2017. Of these participants, 352 underwent the Repetitive Saliva Swallowing Test (RSST) and the Modified Water Swallowing Test (MWST) to detect swallowing impairment. The 67 patients could not undergo the swallowing tests. We got informed consents from all of subjects. The clinical trial registration number; UMIN000026671.

2. MRI

All subjects underwent 1.5 Tesla or 3 Tesla brain MRI within 1 year from being recruited to the registry. The MRI protocol included the following sequences: T1-weighted imaging; T2-weighted imaging; T2*-weighted imaging; fluid-attenuated inversion recovery (FLAIR) imaging; and diffusion-weighted imaging.

White matter hyperintensity (WMH) severity consisted of periventricular hyperintensity (PVH) and deep WMH (DWMH), and were rated visually on axial FLAIR images using the modified Fazekas scale (0 = none; 1 = mild; 2 = moderate; 3 = severe)¹¹ (**Figure 1**) and the Scheltens rating scale, in which scores 0 to 6 are assigned to 13 subcortical regions (subcortical white matter, based ganglia, and infratentorial region), and scores 0 to 2 for 3

periventricular regions.¹²

At first, we assessed each lateral hemisphere WMH by original Fazekas and Scheltens scale. After that, we assessed bilateral hemisphere WMH by addition of the right and left scale. Bilateral Fazekas scale scores were arranged into two or three groups: PVH or DWMH Fazekas score was divided into two groups (0 to 2 = mild; 3 to 6 = severe); and whole Fazekas score (PVH+DWMH) was divided into three groups (0 to 3 = mild; 4 to 6 = moderate; and 7 to 12 = severe). On the other hand, bilateral subcortical Scheltens scores ranged from 0 to 12 and were divided into three groups (0 = none; 1 to 6 = moderate; and 7 to 12 = severe) at each lobe (frontal, temporal, parietal and occipital) WMH. To identify lacunar infarcts (LIs), FLAIR, T2 images and T1 images were used. The size of the LIs were defined from 3 mm to 15 mm, and located in the surrounding white matter, subcortical gray matter, thalamus, and brainstem. LIs were also defined as hyperintensity on T2 images, hypointensity on T1 images, and a hyperintense rim around the cavity in FLAIR images, which could distinguish from perivascular spaces (PVS). The number of whole LIs were recorded as 0, 1, or > 2. Cerebral microbleeds (CMBs) were identified in T2* images as size < 10 mm low intensity and not with edema. The number of whole CMBs was recorded as 0, 1, or > 2. PVS were similar shape to LIs with hyperintensity on T2-images, but could be distinguished from smaller LIs (< 3 mm), following the vessel, shape resembling a spot or line, and without a hyperintense rim on FLAIR. The number of PVS were grouped as follows: none = 0; mild = 1 to 10; and severe > 11. The CSVD subtypes were assessed by trained two neurologists.

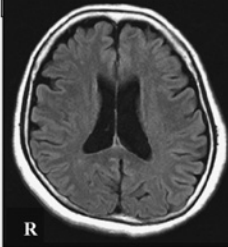
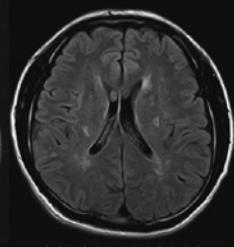
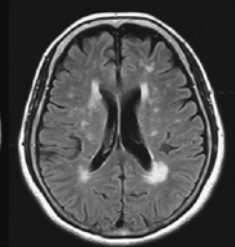
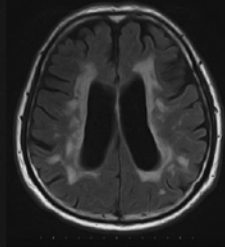
3. Swallowing function assessment

1) Repetitive Saliva Swallowing Test

The RSST is a screening test for swallowing function proposed by Oguchi et al. in Japan.¹³ In the sitting position, subjects are asked to swallow their own saliva as many times as possible for 30 s. The examiner palpates the subject's larynx and counts the number of swallows. Fewer than 3 swallows for the 30 s period is considered to abnormal. The sensitivity and specificity of the RSST was reported to be 0.98 and 0.66, respectively.

2) Modified Water Swallow Test

Scale of periventricular hyperintensity

0	1	2	3
Absence	“cap” or pencil-thin lining	smooth “halo”	Irregular PVH extending into the deep white matter
			

Scale of deep white matter hyperintensity

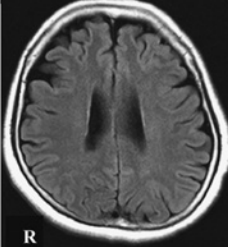
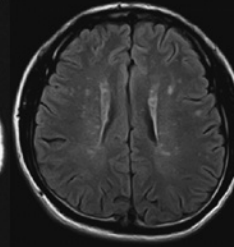
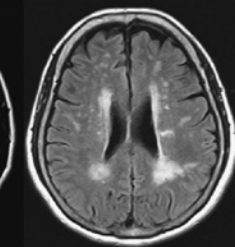
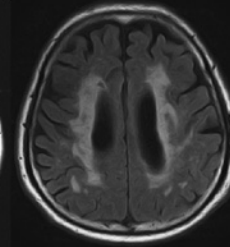
0	1	2	3
Absence	Punctate foci	Beginning confluence of foci	Large confluent areas
			

Figure 1 Fazekas scale.
PVH, periventricular hyperintensity.

The MWST is another screening test for dysphagia. Cold water (3 ml) was placed on the floor of the mouth and the subject was instructed to swallow. If the subject was unable to swallow, or experienced dyspnea, coughing, or wet-hoarse dysphonia after swallowing, a score was recorded (1 for inability to swallow, 2 for dyspnea, and 3 for cough or dysphonia) and the test was terminated. (Dyspnea was, defined as any complaint or observation of difficulty breathing in association with the swallowing test.) Otherwise, the subject was asked to perform two dry (saliva) swallows. If the subject was able to swallow the water but unable to perform either of the two dry swallows, a score of 4 was recorded. If the patient was able to complete the water and both dry swallows within 30 s, a score of 5 was recorded. The entire procedure was repeated twice more. The final score was defined as the lowest score on any trial.¹⁴⁻¹⁶ The sensitivity and specificity of the MWST was reported to be 0.55 and 0.81, respectively.¹⁷

4. Statistical analysis

Statistical analysis was performed using JMP version 13 (SAS Institute Inc., Cary, NC, USA); $p < 0.05$ was considered to statistically significant. Demographic variables between patients with and without dysphagia were compared using the Mann-Whitney U test or the χ^2 test, as appropriate. Multivariate logistic regression analysis adjusted for age, sex, and any vascular risk factor obtained in the univariate analysis, was performed to reveal associations with dysphagia and MRI findings.

Results

Among the 352 patients, 218 were male (63.4%) and 134 were female (36.6%). The mean (\pm SD) age of the patients was 70.4 ± 10.6 years, the median interval between MRI imaging and swallowing test was 4 months and 3 (0.9%) were receiving anticholinergic drug with risk of xerostomia but none of them complained of dry mouth or

swallowing problem.

Seventy-nine (22.4%) of subjects exhibited swallowing impairment, including 63 (17.9%) in RSST, 19 (5.3%) in MWST, and 3 (0.85%) in both. Patients with swallowing impairment were older, had a higher systolic blood pressure and glycated hemoglobin level, lower estimated glomerular filtration rate and more history of diabetes mellitus than those without swallowing impairment. The incidence of swallowing impairment was higher in patients with a history of stroke (49/181 [27.1%]) compared to those without a history of stroke (30/171 [17.6%]). Both the MMSE and MoCA-J scores were significantly lower in patients with swallowing problems. In terms of each swallowing test, mean MMSE were 26.3 ± 2.6 and 27.6 ± 2.6 ($p < 0.001$) and mean MoCA-J were 21.6 ± 3.9 and 23.6 ± 3.6 ($p < 0.001$) in patients with and without swallowing impairment in RSST, respectively. In MWST test, mean MMSE were 25.6 ± 3.7 and 27.4 ± 2.5 ($p = 0.024$) and mean MoCA-J were 20.4 ± 4.0 and 23.4 ± 3.6 ($p = 0.001$) in those with and without swallowing impairment, respectively. In MRI findings, the total score of WMH lesions, DWMH, and the number of LIs were significantly higher in those with swallowing impairment than those without (**Table 1**). Median score of total WMH lesions in subjects with normal swallowing ($n = 273$), positive only for RSST ($n = 60$) and positive only for MWST ($n = 16$) were 4(4, 5), 4(4, 6) and 4(4, 6) respectively ($p = 0.003$). The difference between normal and positive only for RSST was significant ($p = 0.001$) but MWST was not significant ($p = 0.112$). The difference between positive only for RSST and MWST was not significant ($p = 0.786$). However, the number of CMB and PVS were similar between those with and without swallowing impairment. The severity and number of WMHs, LIs, CMB and PVS in relation to swallowing impairment are shown in **Figure 2** and **Figure 3**. The grade of total WMH (PVH+DWMH) score and DWMH score was significantly associated with swallowing impairment (**Figure 2**). The association between PVH grade and swallowing impairment demonstrated borderline significance ($p = 0.058$). However, no association was found between the grade of LIs, CMBs, PVS and the prevalence of swallowing impairment (**Figure 3**).

The association between WMH grade in various loca-

tions and swallowing impairment is shown in **Figure 4**. A significant association was found between frontal and parietal DWMH grade and swallowing impairment; however, no association was observed in the temporal and occipital DWMH.

The relationship between grade of WMH and DWMH and swallowing impairment was assessed using logistic regression analysis (**Table 2**). In the univariate model, whole PVH+DWMH, DWMH, and DWMH in the frontal and parietal lobes, increased the risk for swallowing impairment. After adjustment for sex, age, diabetes, history of stroke and MMSE score, only whole PVH+DWMH remained significantly associated.

Discussion

The two major findings of the present study were that > 20% of patients with any CSVD findings on MRI, who had subclinical dysphagia; and, among the CSVD subtypes, only the severity of WMH, particularly DWMH in the frontal and parietal lobes, was closely associated with swallowing impairment.

Previous studies have examined the incidence of dysphagia, but mostly in stroke patients.⁸ Although the present study also included 181 (52.3%) patients with a history of stroke, it was surprising that approximately 20% of apparent healthy individuals without a history of stroke, but with any sign of CSVD on MRI, exhibited a swallowing impairment. Given that dysphagia is closely related to aspiration pneumonia, malnutrition and mortality, swallowing impairment should warrant significant attention in the management of patients with CSVD.

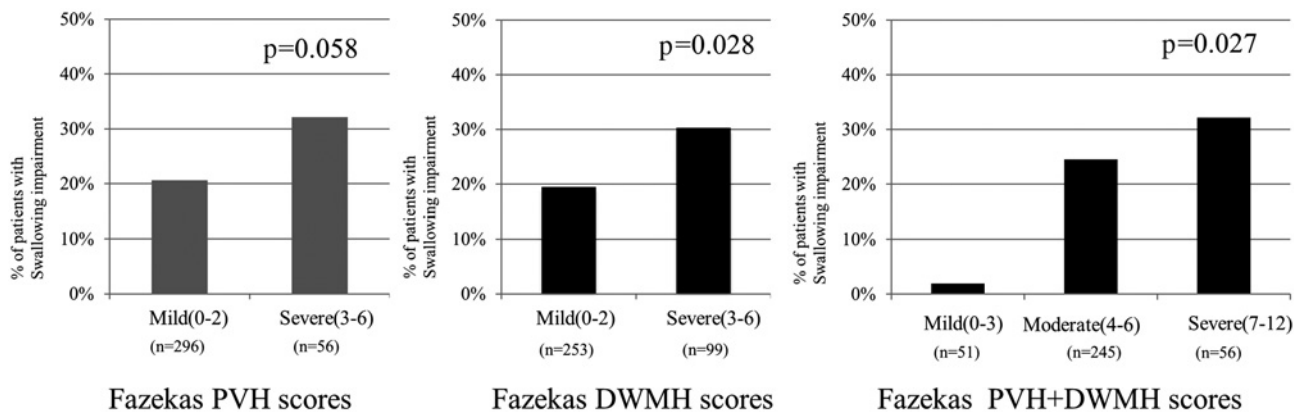
Among the CSVD subtypes, only WMH was independently associated with swallowing impairment. The number of LIs tended to reflect swallowing impairment, but neither number of CMBs or PVS were related to swallowing disorders. Fandler et al. reported that only WMH—not CMBs or number of LIs—was related to dysphagia in patients with recent small subcortical infarcts.¹⁸

Several previous studies have also reported that WMH grade influences deglutition disorder(s). Kim et al. reported that both brain stem abnormalities and paraventricular WMH are associated with dysphagia.¹⁹ Both Moon et al. and Levine et al. showed that prolonged oral

Table 1 Baseline characteristics and MRI findings of subjects with and without swallowing impairment.

	Study population (n=352)	Swallowing normal (n=273)	Swallowing impairment (n=79)	p value
Age (mean \pm SD)	70.4 \pm 10.6	69.1 \pm 10.6	74.6 \pm 9.21	<0.001
Female (n, (%))	134 (36.6)	102 (37.4)	28 (8.0)	0.801
BMI, kg/m ²	23.3 \pm 3.5	23.3 \pm 3.5	23.4 \pm 3.7	0.980
Hypertension, %	232 (65.9)	177 (64.8)	55 (69.6)	0.426
Systolic blood pressure, mmHg	134 \pm 17.7	133.3 \pm 17.5	137.0 \pm 18.3	0.037
Diastolic blood pressure, mmHg	73.8 \pm 12.0	74.4 \pm 12	72.0 \pm 12.0	0.118
Dyslipidemia, %	176 (50)	143 (52.4)	33 (41.8)	0.097
LDL cholesterol, mmol/l	2.76 \pm 0.69	2.59 \pm 1.00	2.47 \pm 0.97	0.234
HDL cholesterol, mmol/l	1.59 \pm 0.53	1.52 \pm 0.57	1.48 \pm 0.78	0.095
TG, mmol/l	1.38 \pm 0.75	1.30 \pm 0.70	1.51 \pm 0.89	0.273
Diabetes, %	106 (30.1)	74 (27.1)	32 (40.5)	0.022
FBS, mg/dl	120 \pm 43.8	117.8 \pm 40.1	127.1 \pm 54.0	0.233
HbA1c, %	6.6 \pm 5.6	6.2 \pm 1.0	6.5 \pm 1.1	0.012
Chronic kidney disease, %	37 (10.5)	31 (11.4)	6 (7.6)	0.337
Serum creatinin, mg/dl	1.0 \pm 0.7	1.0 \pm 0.8	1.0 \pm 0.3	0.097
eGFR, ml/min/1.73 m ²	59.8 \pm 16.3	60.9 \pm 17.6	56.1 \pm 12.4	0.006
Proteinuria, %	43 (15.6)	28 (14.5)	13 (16.5)	0.268
Atrial fibrillation, %	35 (9.9)	27 (9.9)	8 (10.1)	0.951
Current smoking, %	23 (6.7)	16 (6.0)	7 (9.3)	0.312
History of stroke, %	181 (52.3)	132 (49.3)	49 (62.8)	0.035
Ischemic stroke, %	156 (44.3)	114 (41.7)	42 (53.2)	0.072
Transient ischemic attack, %	27 (7.7)	22 (8.1)	5 (6.3)	0.611
Cerebral hemorrhage, %	9 (2.6)	6 (2.2)	3 (3.8)	0.428
Previous history of pneumonia, %	5 (1.4)	4 (1.5)	1 (1.4)	0.902
Use of anticholinergic drugs	3 (0.9)	2 (0.7)	1 (1.3)	0.650
MMSE (pt)	27.3 \pm 2.6	27.7 \pm 2.4	26.2 \pm 2.9	<0.001
MoCA-J (pt)	23.2 \pm 3.7	23.8 \pm 3.4	21.3 \pm 4.0	<0.001
MRI findings				
Fazekas-PVH+DWMH (median, IQR)	4 (4,6)	4 (4,5)	4 (4,6)	<0.001
Fazekas-PVH (median, IQR)	2 (2,3)	2 (2,2)	2 (2,2)	0.046
Fazekas-DWMH (median, IQR)	2 (2,3)	2 (2,3)	2 (2,4)	<0.001
Lacuna infarcts (n, median, IQR)	0 (0,1)	1 (0,2)	1 (0,3)	0.041
Cerebral microbleeds (n, median, IQR)	2.5 (0,6)	0 (0,1)	0 (0,1)	0.968
Perivascular space (n, median, IQR)	1 (0, 2)	2 (0,6)	3 (1,8)	0.194
RSST (median, IQR)	4 (3,6)	5 (4,7)	2 (2,2)	<0.001
MWST (pt median, IQR)	5 (5,5)	5 (5,5)	4 (4,5)	<0.001

BMI, body mass index; TG, triglyceride; FBS, fasting blood sugar; HbA1c, hemoglobin A1c; eGFR, estimate glomerular filtration. Data represent no. (%), mean (SD) or median (interquartile range).

**Figure 2** Relation of Fazekas score and swallowing impairment.

PVH, periventricular hyperintensity; DWMH, deep white matter hyperintensity.

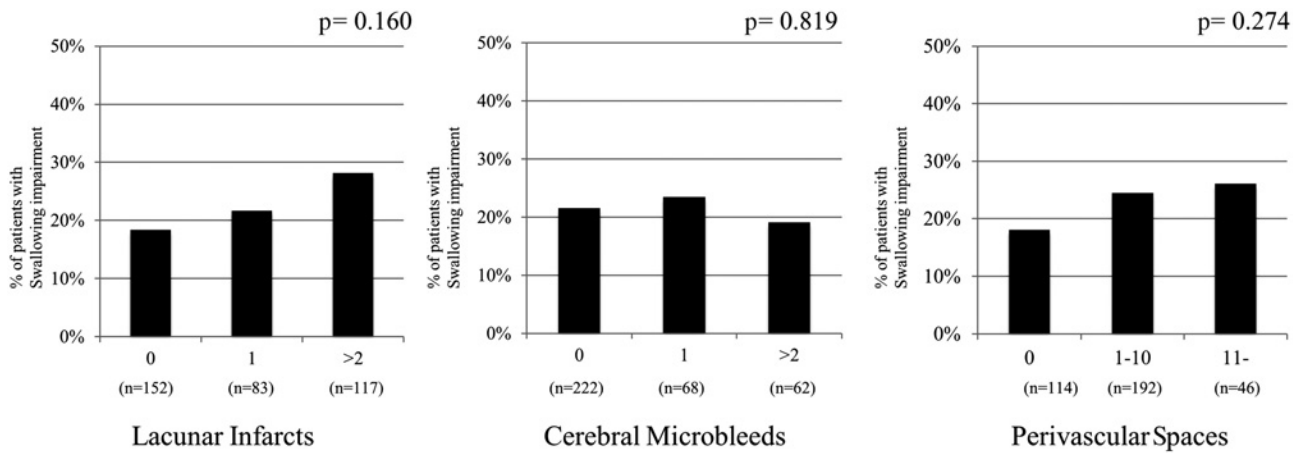


Figure 3 Relation of dysphagia and lacunar infarcts (LI), cerebral microbleeds (CMBs) and perivascular spaces (PVS).

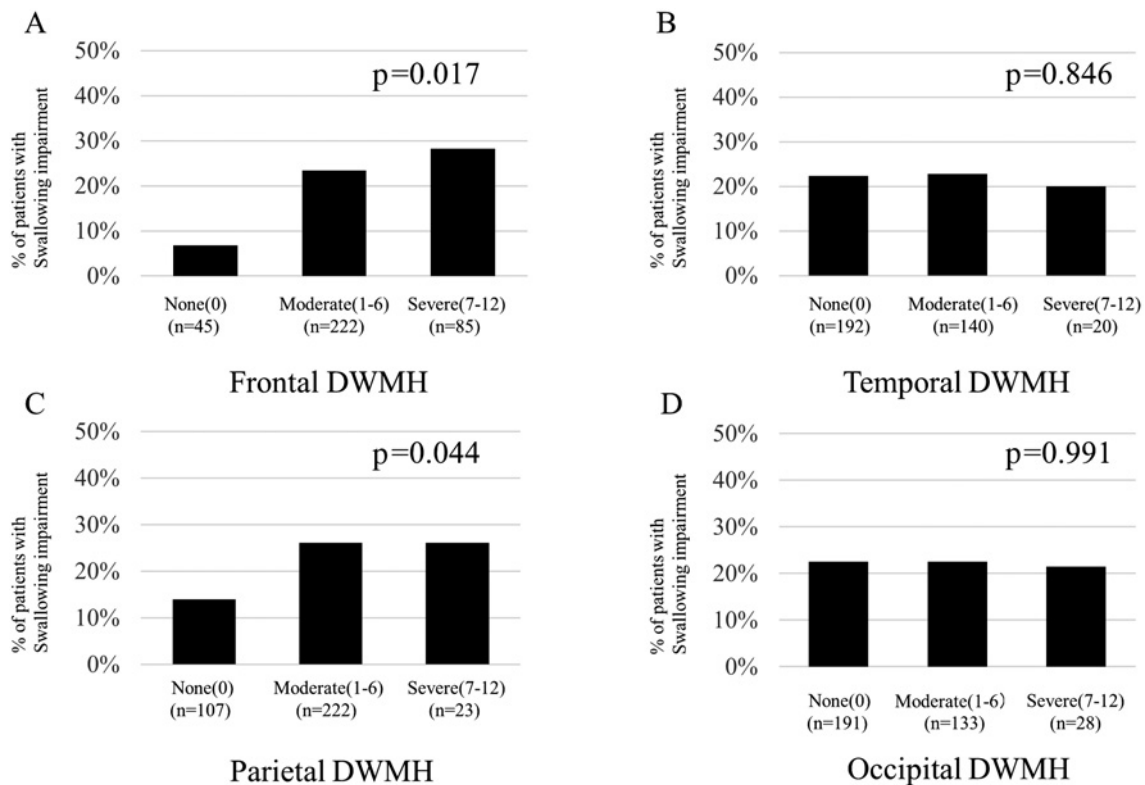


Figure 4 Relation of dysphagia and Scheltens WMH score. WMH, white matter hyperintensity; DWMH, deep WMH.

transit duration in elderly patients was related to the severity of Fazekas PVH grade.^{20,21} They speculated that severe PVH led to dysphagia due to insufficient function of the neural network and cognitive decline.²² Results of our study also suggest that cognitive function is related to swallowing impairment (**Table 1**).

Our study showed that DWMH in the frontal and parietal lobe may be involved in swallowing impairment.

To discuss any relationship between lesion location and swallowing, however, it is important to consider swallowing physiology and anatomical circuitry.

Swallowing is a complex, controlled, sensory-motor system consisting of 3 phases: the oral phase; the oral preparatory and transfer phase, the pharyngeal and esophageal phase. In the oral preparatory phase, foods and/or drinks are recognized by the visual and olfactory

Table 2 Odds ratio of unadjusted and adjusted for age, sex, diabetes mellitus, presence of stroke and MMSE.

WMH score	n	Unadjusted		Adjusted	
		OR (95% CI)	p value	OR (95% CI)	p value
Fazekas PVH+DWMH					
0-3	51	1.00 (reference)		1.00 (reference)	
4-6	245	16.2 (2.19-119.91)	0.006	11.49 (1.52-86.81)	0.018
7-12	56	23.68 (3.03-185.33)	0.003	11.42 (1.39-93.56)	0.023
Fazekas DWMH					
0-2	252	1.00 (reference)		1.00 (reference)	
3-6	99	1.80 (1.06-3.06)	0.030	1.38 (0.78-2.45)	0.274
Frontal-DWMH score					
0	44	1.00 (reference)		1.00 (reference)	
1-6	222	4.28 (1.27-14.39)	0.019	3.30 (0.93-11.70)	0.065
7-12	85	5.51 (1.56-19.5)	0.008	3.10 (0.92-13.00)	0.067
Parietal-DWMH score					
0	107	1.00 (reference)		1.00 (reference)	
1-6	222	2.17 (1.16-4.04)	0.015	1.55 (0.81-3.03)	0.183
7-12	23	2.16 (0.74-6.37)	0.161	1.16 (0.32-3.46)	0.925

MMSE, mini mental status examination; WMH, white matter hyperintensity; PVH, periventricular hyperintensity; DWMH, deep WMH.

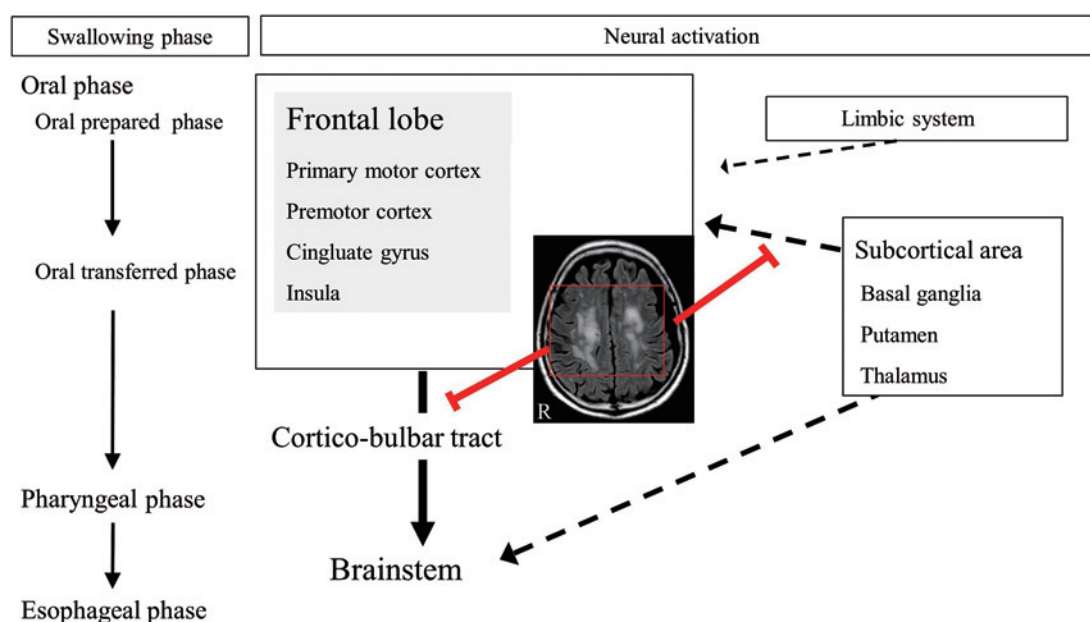


Figure 5 Neural activation of swallowing proceeds frontal lobe in oral phase, cortico-bulbar tract and brainstem in pharyngeal and esophageal phase. Subcortical areas and limbic system influence frontal lobe activation. Frontal DWMH may inhibits these neural activation circuit. DWMH, deep white matter hyperintensity.

senses. They are taken into the mouth, chewed, and mixed with saliva to prepare for swallowing. In the oral transfer phase, the tongue transfers chewed foods and drinks to the pharynx. Some areas of the cortex and limbic system are more activated in the oral phase and control the pharyngeal phase.²³ The brainstem controls the involuntary pharyngeal and esophageal phases through several complex neuromuscular movements. The acti-

vated area of the brain is different among the normal swallowing phases.

Several studies have demonstrated the involvement of the cortico-bulbar tract,²⁴ primary motor cortex, corona radiata, internal capsule, and cerebral peduncle^{25,26} in dysphagia. Other cortical areas, such as the insula, premotor gyrus, inferior frontal gyri, frontal operculum, and anterior/posterior cingulate cortex, are also activated dur-

ing swallowing to control the oral preparatory and oral transfer phases of normal deglutition.^{27, 28} These numerous neural circuits activated during swallowing are in the frontal lobe. This may explain why DWMH severity in the frontal lobe influenced swallowing impairment in the present study (**Figure 5**). Our study found that the severity of parietal DWMH was also associated with swallowing impairment. Because patients with higher parietal DWMH score also had higher frontal DWMH scores ($p < 0.001$), the analysis between the parietal DWMH and dysphagia may be similar in analysis of frontal DWMH.

There were several limitations to our study. First, the RSST and the MWST could not detect which stage of swallowing was impaired in individual patients. Other deglutition tests such as videofluoroscopic study or Toronto Swallow Assessment, Yale Swallow Screen or the Barnes Dysphagia Assessment have been employed for detail assessment of dysphagia in stroke patients.²⁹ Because individuals enrolled in this study are all outpatients and swallow normally, we employed RSST and MWST as easy, quick and noninvasive swallowing screening tests. Second, the interval between MRI imaging and swallowing tests was long. Third, it remains unclear whether swallowing impairment detected in our study could be a risk for future aspiration or pneumonia; however, our prospective follow-up study may clarify this point.

Conclusion

In conclusion, WMH severity, especially DWMH in the frontal and parietal lobes, was associated with swallowing impairment. Problems with swallowing represent some of the most important symptomatic aspects found in patients with CSVD.

Conflicts of Interest: None.

Disclaimer: Kazuo Kitagawa is one of the Associate Editors of Tokyo Women's Medical University Journal and on the journal's Editorial Board. He was not involved in the editorial evaluation or decision to accept this article for publication at all.

References

1. Cohen DL, Roffe C, Beavan J et al: Post-stroke dysphagia: a review and design considerations for future trials. *Int J Stroke* 11: 399–411, 2016
2. Hachinski V, Iadecola C, Petersen RC et al: National Institute of Neurological Disorders and Stroke-Canadian Stroke Network vascular cognitive impairment harmonization standards. *Stroke* 37: 2220–2241, 2006
3. Debette S, Markus HS: The clinical importance of white matter hyperintensities on brain magnetic resonance imaging: systematic review and meta-analysis. *BMJ* 341: c3666, 2010
4. Vermeer SE, Longstreth WT Jr, Koudstaal PJ: Silent brain infarcts: a systematic review. *Lancet Neurol* 6: 611–619, 2007
5. Yilmaz P, Ikram MK, Niessen WJ et al: Practical small vessel disease score relates to stroke, dementia, and death. *Stroke* 49: 2857–2865, 2018
6. van der Flier WM, van Straaten EC, Barkhof F et al: Small vessel disease and general cognitive function in nondisabled elderly: the LADIS study. *Stroke* 36: 2116–2120, 2005
7. Camarda C, Torelli P, Camarda R et al: Isolated, subtle, neurological abnormalities in neurologically and cognitively healthy aging subjects. *J Neurol* 262: 1328–1339, 2015
8. Cola MG, Daniels SK, Corey DM et al: Relevance of subcortical stroke in dysphagia. *Stroke* 41: 482–486, 2010
9. Li H, Jia J, Yang Z: Mini-mental state examination in elderly chinese: a population-based normative study. *J Alzheimers Dis* 53: 487–496, 2016
10. Fujiwara Y, Suzuki H, Yasunaga M et al: Brief screening tool for mild cognitive impairment in older Japanese: validation of the Japanese version of the Montreal Cognitive Assessment. *Geriatr Gerontol Int* 10: 225–232, 2010
11. Fazekas F, Chawluk JB, Alavi A et al: MR signal abnormalities at 1.5 T in Alzheimer's dementia and normal aging. *AJR Am J Roentgenol* 149: 351–356, 1987
12. Scheltens P, Barkhof F, Leys D et al: A semiquantitative rating scale for the assessment of signal hyperintensities on magnetic resonance imaging. *J Neurol Sci* 114: 7–12, 1993
13. Oguchi K, Saitoh E, Mizuno M et al: The Repetitive Saliva Swallowing Test (RSST) as a screening test of functional dysphagia. (1). Normal values of RSST. *Jpn J Rehabil Med* 37: 375–382, 2000 (in Japanese)
14. Tohara H, Saitoh E, Mays KA et al: Three tests for predicting aspiration without videofluorography. *Dysphagia* 18: 126–134, 2003
15. Horiguchi S, Suzuki Y: Screening tests in evaluating swallowing function. *JMAJ* 54: 31–34, 2011
16. Maeshima S, Osawa A, Yamane F et al: Association between microbleeds observed on T2*-weighted magnetic resonance images and dysphagia in patients with acute supratentorial cerebral hemorrhage. *J Stroke Cerebrovasc Dis* 23: 2458–2463, 2014
17. Osawa A, Maeshima S, Tanahashi N: Water-swallowing test: screening for aspiration in stroke patients. *Cere-*

- brovasc Dis 35: 276–281, 2013
18. Fandler S, Gattringer T, Eppinger S et al: Frequency and predictors of dysphagia in patients with recent small subcortical infarcts. *Stroke* 48: 213–215, 2017
 19. Kim JT, Yoon GJ, Park MS et al: Lesion patterns of small deep infarcts have different clinical and imaging characteristics. *Eur Neurol* 63: 343–349, 2010
 20. Levine R, Robbins JA, Maser A: Periventricular white matter changes and oropharyngeal swallowing in normal individuals. *Dysphagia* 7: 142–147, 1992
 21. Moon HI, Nam JS, Leem MJ et al: Periventricular white matter lesions as a prognostic factor of swallowing function in older patients with mild stroke. *Dysphagia* 32: 480–486, 2017
 22. Parker C, Power M, Hamdy S et al: Awareness of dysphagia by patients following stroke predicts swallowing performance. *Dysphagia* 19: 28–35, 2004
 23. Hamdy S, Mikulis DJ, Crawley A et al: Cortical activation during human volitional swallowing: an event-related fMRI study. *Am J Physiol* 277: G219–G225, 1999
 24. Ko EJ, Choi KH, Kwon SU: The relationship between leukoaraiosis involving contralateral corticobulbar tract and dysphagia in patients with acute unilateral corona radiata infarction with corticobulbar tract involvement. *Dysphagia* 34: 654–664, 2019. <https://doi.org/10.1007/s00455-018-9963-y> (Accessed November 15, 2018)
 25. Liégeois FJ, Butler J, Morgan AT et al: Anatomy and lateralization of the human corticobulbar tracts: an fMRI-guided tractography study. *Brain Struct Funct* 221: 3337–3345, 2016
 26. Moon HI, Kim GS, Lee E: Is the location of white matter lesions important in the swallowing function of older patients with mild stroke? *Dysphagia* 34: 407–414, 2019. <https://doi.org/10.1007/s00455-018-9955-y> (Accessed April 5, 2018)
 27. Martin RE, Goodyear BG, Gati JS et al: Cerebral cortical representation of automatic and volitional swallowing in humans. *J Neurophysiol* 85: 938–950, 2001
 28. Ertekin C, Aydogdu I, Tarlaci S et al: Mechanisms of dysphagia in suprabulbar palsy with lacunar infarct. *Stroke* 31: 1370–1376, 2000
 29. Fedder WN: Review of evidenced-based nursing protocols for dysphagia assessment. *Stroke* 48: e99–e101, 2017
-