

5-1-1942

## Fibrotic thickening of the ligamentum flavum

Wilbur W. Overmiller  
*University of Nebraska Medical Center*

This manuscript is historical in nature and may not reflect current medical research and practice. Search [PubMed](#) for current research.

Follow this and additional works at: <https://digitalcommons.unmc.edu/mdtheses>



Part of the [Medical Education Commons](#)

---

### Recommended Citation

Overmiller, Wilbur W., "Fibrotic thickening of the ligamentum flavum" (1942). *MD Theses*. 941.  
<https://digitalcommons.unmc.edu/mdtheses/941>

This Thesis is brought to you for free and open access by the Special Collections at DigitalCommons@UNMC. It has been accepted for inclusion in MD Theses by an authorized administrator of DigitalCommons@UNMC. For more information, please contact [digitalcommons@unmc.edu](mailto:digitalcommons@unmc.edu).

FIBROTIC THICKENING  
OF THE LIGAMENTUM FLAVUM

\*\*\*\*\*

by  
Wilbur C. Overmiller

Senior Thesis

\*\*\*\*\*

Presented to the College of Medicine  
University of Nebraska, Omaha

1942

TABLE OF CONTENTS

Introduction . . . . .	1
History . . . . .	2
Incidence . . . . .	6
Anatomy . . . . .	8
Pathology . . . . .	13
Etiology . . . . .	20
Symptomatology . . . . .	23
Findings . . . . .	28
Differential Diagnosis . . . . .	38
Treatment . . . . .	39
Prognosis . . . . .	41
Summary . . . . .	42
Bibliography . . . . .	43

## INTRODUCTION

The study of low back-ache with or without sciatica has for many years aroused much interest, but it was not until recently that attention has been focused on intraspinal lesions of the intervertebral disk (with its nucleus pulposus) and of the ligamentum flavum. In this country, although protrusion or herniation of the intervertebral disk into the vertebral canal is now being recognized quite often, little attention has yet been paid to abnormalities of the ligamentum flavum and it has been and is being recognized rarely. Fibrotic thickening, hyperlasia, or, as it is usually called hypertrophy of the ligamentum flavum, with compression of the cauda equina is a condition that must be suspected in low back-ache and/or sciatica not responding to ordinary forms of therapy, and its often coincidental relationship to herniated intervertebral disk is one that must be realized.

## HISTORY

The earliest mention of pathology of the ligamentum flavum was made by Elsberg (1) in 1913. A woman forty-nine years of age had been thrown out of an automobile ten months previously. She had had stiffness of the back since that time. Six weeks before the operation she had pain in the distribution of the fourth lumbar root on the left side, rapidly growing very severe. Old fracture and thickening of the arches of the fourth and fifth lumbar vertebrae was demonstrated by x-ray. Upon operation the swollen ligament presented in the wound as soon as the spines and laminae had been removed. This mass was about two cm. thick and the manner in which it was forced out showed that there must have been considerable pressure in the canal. The mass was removed. Examination of the mass proved it to be a much thickened ligamentum flavum which had evidently been torn loose at the time of the accident some ten months before. The patient made a complete recovery. Elsberg (2, 3), in 1916 and 1941 mentioned briefly two cases of enlarged ligamentum flavum.

In 1931, Towne and Reichert (4) reported two cases of enlargement of the ligamentum flavum without antecedent trauma. One pair of the ligaments had blocked the circulation of the cerebral spinal fluid. Upon the removal of the ligaments a marked indentation of the dura was found, which was taken to indicate long continued pressure upon it.

An article by Puusepp (5) appeared in the Esthonian litera-

ture in 1932, reporting three cases of enlarged ligamentum flavum in two of which trauma might have been a factor.

Abbott (6) in 1936, reported the case of a woman who had, in getting out of a car, tripped and fallen, lighting on her left buttock and suffering a severe contusion. Upon operation an enlarged ligamentum flavum was found. Its removal was followed by recovery.

In 1937, Spurling, Mayfield, and Rogers (7) reported seven cases of enlarged ligamentum flavum. The symptoms of the seven cases were present from three months to two years. In six of the cases there had been one or more periods during which there had been a recession of symptoms. Each of the patients had been incapacitated for at least three months prior to the operation. The chief complaint by all was low back pain which radiated into one extremity in six cases and into both extremities in one. There was complete sexual impotence in three patients. Five patients noted sensory loss in the lower lumbar and sacral segments. In only one was there urinary incontinence. Muscle weakness in one leg was described by two patients and in two others weakness in both legs was noticed. There was a postural deformity in all patients. The achilles tendon reflex was abolished or diminished in six of the seven cases. Trauma appeared to be the etiological agent in each case.

In the same year, 1937, Brown (8) reported seven cases. Six of these gave a history of trauma. The patient usually described a snapping sensation in the spine followed by pain low in the back and

some time later varying from a few hours to several months, extending into the thigh, leg and foot. This injury usually occurred during the act of lifting in association with flexion and torsion of the spine. Recovery followed operation in all seven of these cases.

Meredith and Lehman (9) in 1938, reported four cases of enlarged ligamentum flavum. In one of these cases the location of the lesion was unique inasmuch as it was in the thoracic region, while all other cases reported have had lesions occurring in the lumbar or lumbosacral region. These authors do not stress direct trauma as a cause of this condition and state that in two of their cases there was no history of trauma.

Naffziger, Inman and Saunders (10) in 1938, wrote a very comprehensive article on both the intervertebral disk and the ligamentum flavum. They showed that it is quite possible for any swelling of the ligamentum flavum, particularly in the lumbar region, to cause pressure on the nerve roots. These men were the first to stress the pathology of the enlarged ligamentum flavum and its relation to trauma as an etiological agent. They demonstrated that the enlargement was due to a fibrosis of the torn ligaments.

In 1939, Spurling and Bradford (11) reported thirteen cases in seven of which there was an antecedent history of trauma. In this same year Timmes reported one case in which there appeared to be no antecedent trauma. Morton, also in 1939, reported three cases, all of which appeared to be the direct result of trauma.

In 1939, Craig (12) emphasized for the first time the great

frequency with which both enlarged ligamentum flavum and herniated disk are found in the same patient when he reported that in his last one hundred and seventy-five cases of posterior protrusion of the intervertebral disks, enlargement of the ligamentum flavum occurred in one hundred and fifty-five. Love (23) further emphasized this when in reporting a consecutive series of one hundred and seventy-five cases of protruded disks, he made a note in the surgical cards of one hundred and fifty-five cases that there was a definite abnormal thickening or hypertrophy of the contiguous ligamentum flavum.

Horwitz (13) in 1939, reported the study of the spines in seventy-five women cadavers. From his study he determined the normal anatomical variations in the thickness of the ligamentum flavum. Dockerty and Love (14) in 1940, studied ligamenta flava from autopsy and operative specimens to further substantiate the work done by Horwitz (13).



## INCIDENCE

A survey of the literature seems to show that fibrotic thickening of the ligamentum flavum is on the increase, but this is probably not true. The condition is being recognized more frequently and with greater certainty than before and there has consequently been an ever increasing number of cases reported. Thickening of the ligamentum flavum is more common among persons doing hard manual labor than it is among those persons who lead a sedentary life. The period between 16 and 50 years of age is probably the most active time in an individual's life span. This period of great activity is reflected in the age incidence of the occurrence of thickened ligamentum flavum. The earliest case of ligamentum flavum thickening reported was in a 16 year old boy (11), while the oldest patient who has been operated on for this condition was 59 (11). It is, however, in the fourth and fifth decades of life that the condition occurs most frequently, and statistics agree that men are affected much more frequently than women (1, 2, 4, 5, 6, 7, 9, 17, 20, 21, 22, 11, 18, 19): of 53 cases reported and summarized, 45 (85 per cent) occurred in men and 8 (15 per cent) occurred in women.

In determining the frequency with which fibrotic thickening of the ligamentum flavum occurs, it is interesting to cite a survey of the patients who entered the University Hospital with the complaint of low back pain and "sciatica". Out of 40 such cases, 17 were operated. Herniated intervertebral disk, alone was reported in 15 of these cases.

Herniated disk and thickening of the ligamentum flavum was found in one case. In only one case was a thickened ligamentum flavum alone found. Love (25) however, reported a much higher incidence, for in a consecutive series of 175 cases of protruded disk, he found a definite thickening of the contiguous ligamentum flavum in 155 cases. In their last 175 cases of posterior protrusion of the intervertebral disks, Craig and Walsh (12) found 155 cases with thickening of the ligamentum flavum. Brown (8) in emphasizing that this is not an uncommon condition states, "I have operated on seven patients during the last seven months, in whom this condition caused symptoms of root compression."

Finally, with the steadily rising incidence recorded in vital statistics, it seems unquestionably true that many cases of hypertrophy of the ligamentum flavum have been and are being overlooked (26).

## ANATOMY

The ligamenta flava are composed normally of yellow elastic tissue and connect the laminae of adjacent vertebrae. The normal ligaments are 2-3 mm. thick; (13, 14, 15) they are the only predominantly elastic ligaments in the human body, and, in virtue of their elasticity, can accommodate themselves to the separation and approximation of the laminae in forward and backward flexion of the vertebral column (15). Whereas the ligamentum flavum is a continuous structure, it is convenient both for descriptive and clinical reasons to subdivide it into two portions. The medial half, the broader and thicker part of the ligament, is attached to the contiguous laminae and may with advantage be called the interlaminar portion. The thinner lateral half is less wide and tapers off as it extends laterally. It is attached predominantly to the articular processes and is related to the interarticular joint and capsule. This part will be referred to as the capsular portion. This division into interlaminar and capsular portions is suggested by some difference in direction of the fibers of the two parts. The fibers of the interlaminar part are vertical in position, whereas those of the capsular portion run obliquely downward and laterally. (10).

Inferiorly, the interlaminar portion is attached to the upper border of the lamina below. On the bony specimen, this

attachment is indicated by a well defined groove, the anterior margin of which variously exhibits sharp, thin plaques or spiculed of bone which extend up into the anterior face of

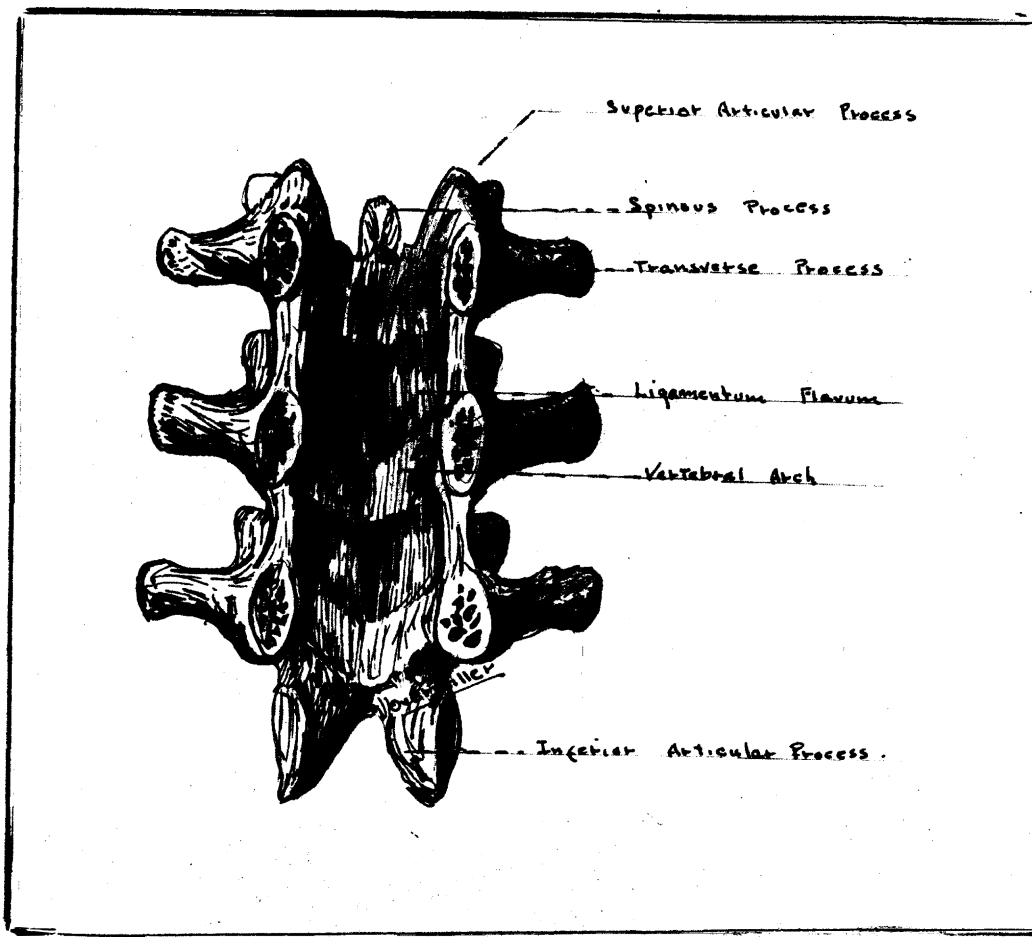


Fig 1. The ligamenta flava of the lumbar region. Anterior Aspect.

the corresponding ligament. These spicules are variable in size, number and position and may perhaps be regarded as ossification in the ligamentum flavum, but it has been noted that they are attached to the lamina and are more in the nature of an ossific extension from the bony attachment (10). Calcareous matter has

been observed in the ligamentum flavum removed at operation, and has been regarded by Meredith and Lehman (9) as calcium deposited secondary to injury to the ligamentum. In the opinion of Naffziger et. al. (10) this calcareous matter is nothing but ossific matter derived from those spicules which must necessarily be fractured from their attachments when the ligament is surgically removed.

The interlaminar portion is attached superiorly to a well defined irregular and rough area, which occupies the lower half of the lamina (10). This area is separated from the smooth upper half of the lamina by a sharp ridge. Characteristically, the ridge exhibits a small bony spicule at the junction of the attachments of the interlaminar and capsular portions, but the bony plaques found below have not been observed at the upper attachment. Owing to this arrangement, the inferior half of each lamina is excluded anteriorly from the neural canal and the upper smooth half of the lamina alone is directly related to the spinal dura. In the midline at the base of the spinous process, the medial end of the interlaminar portion blends with its fellow of the opposite side. Laterally, each interlaminar portion is continuous with, and almost inseparable from, the capsular moiety, except for the difference in direction of the fibers of the two parts. The interlaminar portion is for the most part a direct posterior relation of the spinal dura.

The capsular portion is attached below to a groove which

extends along the periphery of the inferior articular process to a point a little beyond the intervertebral foramen (10). The ligament is attached, above, to the inferior border of the pedicle and lies just below the groove for the spinal nerve which is found on the inferior aspect of the structure. Laterally the ligament, considerably attenuated, blends with the capsule of the interarticular joint, some little distance lateral to the intervertebral foramen. This portion of the ligament excludes the joint from the neural canal and from the lower half of the intervertebral foramen.

Walsh and Love in their writing upon protrusion of the intervertebral disks attempt to explain the sites at which protrusion of the disks occur by calling attention to the anatomical shape of the spinal column. They classified one hundred cases and found them to occur only at the points of greatest convexity of concavity; namely, in the fifth, sixth, or seventh cervical, fifth, sixth, tenth or eleventh thoracic, or the third, fourth, or fifth lumbar interspaces (16). This same line of reasoning can be followed in regard to injury to the ligamentum flavum. Craig and Walsh report that they found enlargement of the ligamentum in 155 of the last 175 cases of posterior protrusion of the intervertebral disks and conclude that the enlargement in these cases is most likely due to the trauma that produced the protrusion of the disks (12).

After grouping together 53 cases reported by various

authors (1, 2, 4, 5, 6, 7, 9, 11, 17, 18, 19, 20, 21, 22), I found that 46 of the enlarged ligamenta flava occurred in the lumbar region, 7 in the lumbosacral region and one in the thoracic region of the spine. This predominance of lesions in the lumbar concavity of the spine almost to the exclusion of the other curvatures may be explained by the fact that it is this portion of the spine that receives the greatest amount of trauma and strain in body support and activity. Naffziger, et al, emphasize this fact when they estimate that the various force factors at work (e.g., in lifting a 50 lb. weight) are multiplied about ten times and sometimes, especially in sudden effort, to an even greater degree, with a resultant pressure upon the lower lumbar disks of some 500 lbs. or more. Similarly, great strain is put on the ligamenta flava and the other vertebral ligaments (10).

## PATHOLOGY

Descriptions of the enlarged ligamentum flavum are somewhat variable. The first account of pathological enlargement of the ligamentum flavum was made by Elsberg (1). He described the ligament as a firm whitish colored mass about 2 cm. thick bulging into the spinal canal and compressing the fourth lumbar nerve root. Meredith and Lehman describe one as a yellow mass that was found lying over the dorsum of the dura. "It was 15 mm. in thickness. It was cartilagenous in consistency and attached to the periosteum. The tissue was bright yellow in color and was easily brushed away from the dura. When the mass was removed, a curved impression in the dura resulting from the overlying mass was evident" (9). An enlarged ligament discovered by Naffziger, et al., was reported by them as "considerably enlarged, rough, irregular and nodular. It protruded forward impinging on the first sacral nerve" (10). Dickson and Twort (15) reported in one case "The ligaments which formed a single thickened transverse band were tough and pale pinkish-red and had lost most of their normal yellow color. The thickening extended on both sides, partly encircling and compressing the immediate subjacent theca. The thickened and coalesced ligaments were adherent to the subjacent dura, from which they were readily dissected." Flothow (26) reported finding an enlarged ligamentum flavum which he described as extending down from under the lumbar lamina to the sacral arch. In the same area he found that



the spinal canal was small in diameter, being compressed by the thickened ligamentum flavum.

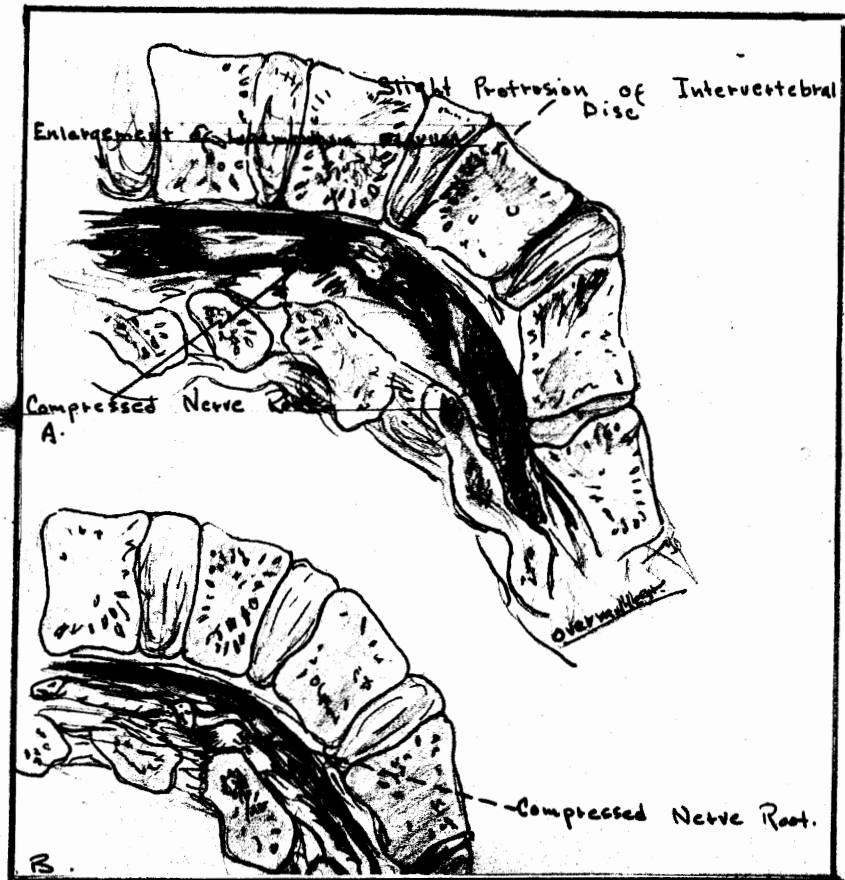


Fig. 3. Sagittal section of the lumbosacral spine. This drawing was made from a specimen with an enlarged ligamentum flavum to show the mechanism of compression of the nerve root. The dura has been removed.

A. Lateral View

B. The specimen has been rotated to demonstrate the point of compression of the nerve root.

Copy after H. A. Brown (19).

Most of the investigators are now agreed that thickening of the ligamentum flavum is a definite entity, amenable to surgical treatment, but very few have tried to answer the question, "What is the nature of this thickening?" The term "hypertrophy" has consequently come into use in descriptions of these lesions, without, in many cases, much degree of justification. Abbott (24) reported thickening due to fibrosis which he interpreted in the light of posttraumatic scarring. Towne and Reichert (4) reported two cases in which they found some degree of calcification but were of the opinion that the thickening was due to simple hypertrophy. Naffziger, Inman & Saunders (10) reported finding calcareous matter in some enlarged ligaments but they believed this in part to be spicules fractured from their attachment when the ligament was surgically removed. Spurling, Mayfield, Rogers, (7) and Horwitz (13) described fibrosis of the ligamentum flavum and mentioned the additional factor of thickening in the walls of the blood vessels. Love (22, 25) observed thickening and gross scarring of the ligaments in frequent association with protruded intervertebral disks. Meredith and Lehman (9) reported enlargement of the ligament as a simple hypertrophy with no neoplastic or inflammatory element. In general the pathological changes in the ligamentum flavum had received little attention until Dockerty and Love (14) reported their study of the lumbar ligamenta flava from seventy-five cases. Twenty-five of these (series A) were used as normal controls and were obtained

at autopsy, and fifty, (series B) consisted of lumbar ligaments removed at operation because of the syndrome of backache and "sciatica". In series A, the ligaments were uniformly yellowish in color both on surface and on section. The average thickness of these ligaments was 2.8 mm. with extremes of 2 and 4 mm. Horwitz (13) in his series of seventy-five cadavers reported an average ligamental thickness of 3.7 mm. In series B, forty-five of the fifty ligaments were not uniformly yellow in color but presented whitish lines and bands which were more prominent on sectional views. In ten of the cases this change was so marked that little of the original normal yellowish color remained; the ligaments consisted almost entirely of scar-like tissue. The average thickness of the ligaments in this group was 5.1 mm. with extremes of 2.5 and 9.5 mm.

Microscopically, it was found that in series A the tissue was made up of coarse elastic fibers with practically no cellular elements (Fig. 4a). These fibers ran parallel and were interrupted at irregular intervals, but they were rarely frayed or "fibrillated". Here and there these elastic fibers were separated to allow for the passage of thin-walled blood vessels. No definite lymphatics or nerves were observed. In minimal lesions there appeared a longitudinal splitting, fraying and fibrillation of the elastic fibers which occurred in isolated patches or in longitudinal bands. These fibers had taken on the staining characteristics of connective tissue. This fibrotic

change varied from minimal to almost complete replacement of the normal elastic tissue of the ligament (Fig. 4b). Another change




Fig. 4a. Normal ligamentum flavum: One may note slightly wavy elastic tissue fibers; no fibrosis is present: stained with elastin stain (x190).

4b. Grade 1 fibrosis in patchy distribution; one may note fragmentation and hyalinization of elastic fibrils: stained with elastin stain (x45). After Dockerty and Love (14).

change varied from minimal to almost complete replacement of the normal elastic tissue of the ligament (Fig. 4b). It was because of these findings that Dockerty and Love (14) suggested that the term "hypertrophy" should be replaced by the more accurate descriptive designation of "thickening with fibrosis." Another change observed in series B, almost constantly was a hyaline

thickening in the walls of the blood vessels as had been reported previously by other workers (7, 13). The lumina were



Fig 5a. Marked fibrosis: Most of the normal elastic tissue has been replaced by fibrous connective tissue.

5b. Blood vessel of pathologic ligament. Note hyalinization of wall and almost complete occlusion of lumen; stained with elastin stain (x200). After Dockerty and Love (14).

nearly always narrowed, in many instances to the point of occlusion (Fig 5b.). In about a third of the ligaments in series B the blood vessels appeared to be increased in number in addition to being hyalinized. Calcification was noted in three of the ligaments in the B series.

The question now arises, "Why do we have this

fibrotic replacement of the elastic fibers of the ligamentum flavum?" The explanation, most widely accepted is that of a posttraumatic fibrosis (7, 9, 13, 14, 15, 17, 18, 23, 24). The elastic fibres of the ligamenta flava are normally under tension. Torn from their attachments or ruptured, they contract and thicken. Tears heal by the formation of scar tissue, and a ligament in which such changes have taken place may be 9 mm. or more in thickness (14) and is usually adherent to the dura. This fibrotic hyperplasia may be unilateral or bilateral, the histological changes being a replacement of the normal yellow elastic tissue by collagenous white fibrous tissue in which there may be calcareous deposits (4, 14). The site of election for the lesion is, as has been previously stated, in the lower lumbar region, affecting most commonly the ligaments between the fourth and fifth lumbar vertebrae.

## ETIOLOGY

When considering the causative factors of enlargement of the ligamentum flavum, the most constant agent by all odds appears to be trauma (1, 9, 14, 15, 17, 18, 20, 24, 27). The elastic fibres of the ligamenta flava are normally under tension (15). When torn from their attachments or ruptured, repair in such specialized elastic tissue is completed by tissue of a lower order - fibrous connective tissue - and acute or chronic trauma appears to cause the pathological thickening. The trauma, however, may be of various types and result from a multitude of causes. The most frequent trauma, however, is produced by lifting in association with flexion and torsion of the spine, or possibly a fall on the back or buttocks (17). In Elsberg's case (1) the thickening of the ligamentum flavum was incident to an automobile accident in which the woman was thrown from her car. Spurling (7) stated that it was most common in his seven cases for the patient to give the history of "while lifting a heavy object, I felt a snap and then a severe pain in the lower part of my back." In a report of nine cases, Crosthwait (27), reports the trauma as being due to several causes, including hyperflexion of the spine, active or passive; or slipping while the spine is hyperflexed; and lifting while in flexed or strained position; diving, athletics, automobile, railroad, and obstetric accidents. In one of the cases reported at the Uni-

versity Hospital, the trauma, in an obstetrical patient resulted from delivery while the patient was up in stirrups. This patient noticed no symptoms until about the tenth day after delivery, when she began having low back pain and found that she was unable to move her left leg.

After grouping together 53 cases reported by various authors (1, 2, 4, 5, 6, 7, 9, 18, 11, 19, 20, 21, 22), I found that there was a history of direct trauma in 14 cases, a history of indirect trauma in 19 cases, and there was no reported history of trauma in 18 of the cases. No mention of the causative factor was made in 2 cases. In this series, then, trauma was the etiological factor in 67 per cent of the cases while there was no history of trauma in 35 per cent of the cases. The fact that there is no history of trauma in this large a percentage of the cases possibly is due to the fact that the trauma causing these lesions may be, and often is of a relatively slight degree and the onset of symptoms is frequently not immediate so that the patient has forgotten or has not particularly noticed the injury (18).

Skinner (20) believes that many of these patients may have a weak back to start with and that this may explain why many cases occur either without trauma or with only a minor insult.

Abbott (24) believes that trauma is the most plausible etiological factor because of the association of a ruptured



intervertebral disk as seen by Brown (8), Hampton (28), and Abbott (24), but a possible inflammatory process must be borne in mind.

## SYMPTOMATOLOGY

The outstanding subjective symptom which leads the patient to consult his doctor in most cases is pain (1, 4, 5, 7, 11, 17, 18, 19, 20, 21, 24). This pain is usually low in the back with sciatic radiation. Love (29) terms this root pain. He defines root pain as pain which begins within or near the spinal cord and is projected peripherally to that part of the body or extremity innervated by the nerve fibers which leave the spinal cord through the spinal nerve root emerging at that level.

In order to emphasize the importance of pain, it may be noted that it was the chief complaint in twelve out of thirteen cases reported by Spurling and Bradford (11), and in all seven cases reported by Spurling, Mayfield and Rogers (7).

Pain in the legs and back is usually unilateral, but it is sometimes bilateral (9). The pain too is characteristically intermittent (18). The case of Mrs. M. R. reported at the University Hospital had pain extending into her left lower back region and down her left leg. Less severe pain extended into her right leg and back. There were periods of remission and exacerbation in her pain.

There is usually a low backache (15, 18) that characteristically becomes aggravated by sneezing, coughing, and straining, especially at time of defecation, whereupon it

radiates over the thigh and the posterior or lateral portion of the calf of the leg. The patients with thickened ligamentum flavum center their complaint of pain in the lower spine while protruding disk cases center their complaint to pain in their hip and leg (20).

The distribution of the pain along the course of the sciatic nerve in such a large percentage of cases explains why this condition is so often confused with the many others that also produce or are associated with "sciatica". A history of onset of pain immediately following some type of trauma is valuable, especially since a tearing of the ligamentum with subsequent thickening may occur in a patient who has suffered sciatic pain from other causes prior to the injury. The onset of pain following ligamental trauma is most often sudden but may be gradual, and there is commonly an interval between the onset of the pain in the back and the pain of sciatic distribution.

The wide variation, that is possible in the location and the extent to which the thickened ligamentum flavum compresses the cord or the nerve roots, makes it evident at once that there is necessarily a great variability in the location, radiation, degree, and constancy of the pain.

The lesion may be so extensive and so located as to cause a paraplegia in some cases; however, in most instances there is no paralysis, but merely motor weakness

which is found usually to occur in the anterior tibial muscles (18). Meredith and Lehman (9) reported one case of thickened ligamentum flavum in which the only complaint was weakness of the legs of three months' duration and in which there was no pain or sensory disturbance.

The sensory changes are usually quite variable or even vague. These changes in sensation may be present over the buttocks, perineum, posterior thigh, calf and foot (18). Bradford and Spurling (11) reveal a useful differential point between herniated nucleus pulposus and thickened ligamentum flavum in their statistical summary of their patients. They found that in 60 per cent of their cases of herniated nucleus pulposus there was hypesthesia or anesthesia limited to the lateral aspect of the leg or foot or both. In contrast to this, they found that the cases of hypertrophied ligamentum flavum showed areas of hypesthesia elsewhere, but in only 11 per cent of the cases was the hypesthesia limited to these areas. This wider spread of hypesthesia in the case of enlarged ligamentum flavum may have been due to the fact that the ligaments when enlarged involved by compression more nervous tissue. In studying sensory disturbances reported in 53 cases presented in the literature (1, 2, 4, 5, 6, 7, 9, 11, 17, 18, 19, 20, 21, 22) I found that hyperesthesia was present in 16 cases, hypesthesia in 16 cases and anesthesia in 16 cases.

Patients with severe damage to the cauda equina or medullary conus have a loss of sphincter control. Dickson and Twort (15) state that incontinence is rare, In patients with enlarged ligamentum

flavum, but that sexual impotence is common. The first of these statements is borne out by my survey of the literature, in which out of the 53 cases reported there was sphincter disturbance reported in only 4 cases, but there were only 6 cases reported in which there was impotence, a figure that does not support the second statement. (Fig.6)

<b>Age--</b>		
Extremes		16-59 years
Average		38.2 years
<b>Sex--</b>		
Male		36 cases
Female		8 cases
<b>History of Trauma--</b>		
Direct		14 cases
Indirect		19 cases
No history		18 cases
<b>Symptoms--</b>		
Pain in back or legs		50 cases
Weakness of legs		15 cases
Sphincter disturbance		4 cases
Impotence		6 cases
<b>Signs--</b>		
Hyperesthesia		16 cases
Hypesthesia		16 cases
Anesthesia		16 cases
Motor weakness		21 cases
Absent or diminished ankle jerks		32 cases
Atrophy		10 cases
<b>Queckenstedt Test--</b>		
Normal		18 cases
Block Demonstrated		9 cases
Not done or recorded		35 cases
<b>Spinal Fluid Protein--</b>		
Normal		11 cases
Elevated (above 45 mg. per cent)		29 cases
Not recorded		13 cases
<b>Lipiodol--</b>		
Defect or block		23 cases
Not reported or not done		30 cases
<b>Location--</b>		
Lumbar spine		23 cases
Lumbosacral spine		7 cases
Dorsal spine		1 case
<b>Postoperative Course--</b>		
Relieved		35 cases
Slight residual pain or weakness		12 cases
Recurrence		1 case
Postoperative deaths (meningitis)		2 cases

Fig. 6.

A summary of 53 Typical cases recorded in the literature to date, to show similarity of findings. (Elsberg, 1 case; Towne and Reichert, 2 cases; Puusepp, 3 cases; Abbott, 1 case; Spurling, Mayfield and Rogers, 7 cases; Meredith and Lehman, 2 cases; Meyerding, Baker and Cameron, 1 case; Skinner, 7 cases; Brown, 3 cases; Spurling, Bradford, 13 cases; Timmes, 1 case; Morton, 3 cases; University Hospital, 2 cases.)

## FINDINGS

When the patient is first seen, it is often noted that he moves cautiously to prevent any jarring that would aggravate his symptoms (30). A general restriction of the movements of the back is commonly seen (18). Often there is a flattening of the lumbar concavity, the so called "poker spine", and a scoliosis in the same region, with a tilting of the pelvis usually to the same side as the lesion, although sometimes toward the opposite side (15). This tilting of the pelvis, scoliosis and flattening of the lumbar concavity results from a protective spasm of the back muscles.

Dickson and Twort (15) believe that percussion and palpation are of some value in diagnosing these cases. They have found that there may or may not be tenderness or pressure over the spinous processes of the lower lumbar vertebrae and tenderness of the sciatic nerve to pressure in the buttock or thigh.

Muscle fibrillation is occasionally found. This along with motor weakness, which is so frequently found, is an indication of degenerative changes taking place in the muscle. The muscle in which motor weakness is most often found is the anterior tibial (18, 9).

The sensory findings are not in themselves characteristic of thickening of the ligamentum flavum, but their presence in conjunction with other findings is often quite significant. The variability of the sensory changes is quite remarkable for one may find paresthesia, hyperesthesia, hypesthesia or anesthesia. Any of these changes or

combinations of them may be found involving the buttocks, perineum, posterior thigh, or calf and foot (18). In some instances of the patients with hypertrophied ligamentum flavum, the lesion may be predicted by the widespread signs of the sacral root compression (11).

The most constant objective finding in these patients has been reported to be an alteration in the Achilles-tendon reflex (18, 15). Brown (8) reported a diminished or absent ankle jerk in all three of his cases. Bradford and Spurling (11) found a diminution or absence of the ankle jerk in eight of the thirteen cases that they reported. Out of the three cases reported by Morton (17), two were found to have had an altered Achilles reflex. There is another objective finding that is not so constantly found. There may or may not be a limitation of flexion at the hip when the leg is straight (18, 15).

Love and Walsh (16) attempted to determine the exact location of the pathological lesion in the spinal canal in a series of one hundred cases by studying only the reflex changes, muscular weakness, and segmental sensory loss whenever present. They found that it was impossible to accurately do so but concluded that such findings did give excellent evidence as to the general region of the spinal column in which the protrusion might be found.

Lumbar puncture should be carried out when neurological examination suggests the presence of a lesion within the vertebral canal or theca, or when the condition proves intractable to ordinary treatment. In fibrotic thickening of the ligamentum flavum, the



total coagulable protein of the cerebrospinal fluid is commonly but not invariably raised above the normal upper limits of 25 to 30 or 35 mg. per 100 cc., these normal figures varying with the age of the patient (15, 11, 17, 18). An obstructive lesion in the vertebral canal is characteristically associated with a rise in total protein in the spinal fluid both above and below the lesion. If the lumbar puncture is made at or below the fourth lumbar interspace (the common site of obstruction in hyperplasia of the ligamentum flavum) a partial or complete spinal block may be demonstrated. Spinal block, either partial or complete is not a common finding in these cases, for out of 53 typical cases reported in the literature, only 9 demonstrated a positive Queckenstedt Test (1, 2, 4, 5, 6, 7, 9, 11, 17, 18, 20, 21, 22). Certainly, then, a negative result would not disprove the presence of an enlarged ligament.

Dickson and Twort (15) often use an epidural injection of saline as a diagnostic aid in doubtful cases. The injection of even a few cubic centimeters of saline solution will, according to them, cause an exacerbation of pain if there is already any degree of compression of the cauda equina.

Myelography is essential to diagnosis. There is at the present time great controversy as to just what medium should be used for visualizing pathology along the spinal canal. Iodized oil has been favored in the past, and is still the most used medium, but there is increasing evidence in the literature of the value and advantages of air or oxygen.

It is evident that, if no operation is to be performed for the removal of the iodized oil, it would be unwise to inject it and leave it there, even though evidence seems to indicate that it does not produce an inflammatory reaction in every case (12, 15, 30, 31). There is one feature that is of considerable importance, especially in compensation cases. It is the presence of the opaque oil revealed in every subsequent roentgenogram which the patient or unscrupulous attorneys and doctors may use to unfair advantage in obtaining excessive compensation for the patient. This opaque oil will be found months or years later distributed along nerve roots along the spinal canal and even up around the brain. Since this substance is a foreign body, often irritating to the cord, roots and meninges, practically all neurosurgeons are agreed that lipiodol should not be injected unless an exploratory operation has been previously decided upon (12, 15, 27, 30, 31). Even when a laminectomy is done and the dura is opened and a large part of the lipiodol is removed, it is usually impossible to remove it all (30, 31).

The technique for examination of the spinal column with iodized oil has been well described by Dickson and Twort (15). Lipiodol should never be injected in the presence of a suspected inflammatory lesion. The temperature of the oil must not be above that of the body. It should not be used if it has become cloudy. Opinions differ as to the quantity of iodised poppy-seed oil which should be used. With the patient in the erect posture, some five cubic centimeters is required to fill the lower spinal theca to the level of the third

lumbar vertebra. This amount is therefore required in order to be sure of showing up any filling-defects due to protruded intervertebral disks or thickened ligamenta flava in the lower lumber region, if diagnosis depends on straight films and cannot be assisted by fluoroscopy. Antero-posterior films with the patient prone, and lateral films, are taken with the tilting-table at an angle of forty degrees. If the fluoroscope can be employed along with a tilting-table, two cc. of oil may be enough (15, 32) for this can be run up and down the lower theca and films taken when the oil is seen to be at the site of any notching or obstruction in the flow. The smaller amount is less likely to be followed by urinary troubles and arachnoiditis. Irritation of the roots of the cauda equina from the oil may sometimes be relieved by draining it off by repeated lumbar punctures, but this is not always effective. If an obstructive lesion is diagnosed and laminectomy performed the theca is opened at operation and the oil evacuated then. Otherwise, if myelography proves negative, the oil should be drained from the theca after sacral trephining.

There is no infallible means of differentiating the cause of a filling defect as viewed by x-ray picture or fluoroscopic examination (27). It may be produced by hypertrophied ligamentum flavum, ruptured disk, nucleus pulposus, cord tumor, or though rarely, a new growth in bony tissue. According to Bee and Spurling (32) the commonest abnormality found on myelography in cases of thickening of the ligamentum flavum is a unilateral filling defect or notching of the column of oil. This is because the thickening of the ligament is usually predominantly

unilateral. A similar defect is the common finding in cases of protrusion of an intervertebral disk. Theoretically, one should be able to distinguish between a displaced nucleus and an hypertrophied ligament by lateral films. However, this is seldom the case, for nuclei usually herniate lateralward beneath the nerve root, and the ligaments frequently thicken more on one side than the other (32). Myelography will not therefore always distinguish between these lesions, but fortunately the same surgical approach is required for both (15). When the thickening of the ligaments is bilateral a symmetrical hour glass constriction of the dural sac and the enclosed column of oil is demonstrated. A complete hold-up of the oil is still more rare, both in protruded intervertebral disk and in hyperplasia of the ligamenta flava (32).

Berens (30) has summarized the important points in favor of and against the use of iodized oil in diagnosis of deformities of the spinal canal.

**FOR:**

1. One can obtain clearer pictures when using oil.
2. The use of oil is more accurate on small lesions.
3. Myelography with the use of oil is easy to perform.

The use of oil is not painful and requires no use of anesthetic.

5. Oil as an opaque substance is useful in any part of the spinal canal.

AGAINST.

1. An operation is necessary for the removal of the oil.
2. Oil that is not removed gives rise to an inflammatory reaction.
3. It is impossible to remove all of the oil; subsequent roentgenograms always show its presence.
4. Occasionally oil is accidentally placed extradurally where it remains as a foreign substance.
5. It furnishes material for a malpractice suit.

Bosworth and Hare (33) believe that the value of lipiodol more than balances its disadvantages inasmuch as it gives definite proof of the diagnosis and permits the surgeon to find the lesion by removal of only one vertebral lamina.

Craig and Walsh (12) have well described the technique for examination of the spinal column by using air. They combine their spinal punctures and spinograms. The procedures are carried out in the x-ray room with the patient lying on the fluoroscopic table. A lumbar puncture is made in the usual manner, manometric readings are obtained and 15 cc. of fluid is removed for study. The table is then tilted to an angle of about 40 degrees with the patient's head down (27) and the fractional introduction of air is carried out. Between 30 and 40 cc. of air is introduced, care being taken that the lumbar sac is emptied of fluid. Baker has suggested that shaking the pelvis or jolting the hips helps dislodge any fluid that would obscure the picture. Following the injection of air, stereoscopic anterior, posterior and lateral films are made. The evidence of narrowing of

the lumbar canal, the protrusion of intervertebral disks or thickening of the ligamentum flavum is not so convincing as in roentgenograms taken after the injection of radiopaque oil but with practice the reading of the films becomes much easier (12).

Air or oxygen have one great natural advantage over iodized oil in that they are absorbed within a few hours and leave no after effect. They are especially valuable when an attempt is being made to diagnose a borderline case, since air injections may be done several times, if necessary to verify the presence and localization of a pressure producing mass; and if it is eventually decided that there is no existing deformity, there are no foreign bodies left in the patient such as remain when lipiodol is injected and none or only part of it is removed (30).

Berens (30) emphasizes that one of the disadvantages of air is that the roentgen plates are obtained by overexposure at rapid speed, such as can be obtained by the use of rotating anode tube apparatus at 300 milliamperes and one-half second exposure. Equipment of this kind is not available for all patients and physicians who wish to do this type of diagnostic work. Another disadvantage of air, he points out, is that it is somewhat painful and strong sedatives, or some type of anesthetic such as intravenous pentathol sodium, is usually required. In favor of it, it may be stated the experience of those who have used air a great deal and have found that, if a positive diagnosis is made with it, there is rarely a case where the pathology will not be found at the time of operation (30).

The important points in favor of ~~the~~ against the use of air or oxygen in diagnosis of deformities of the spinal canal have been summarized by Berens (30).

FOR AIR OR OXYGEN:

1. They will reveal all medium sized or large deformities of the dural sac, such as would unquestionably require surgery.
2. There are no after-effects from the use of air or oxygen. The head is kept lowered about 30 degrees until the air absorbs (three to four hours) (27).
3. There is nothing to be revealed later by examination or roentgenogram if the case test is negative.
4. There is no material for malpractice suits.
5. One has the fluid to check for total protein.
6. This procedure may be performed several times if necessary.

AGAINST USE OF AIR OR OXYGEN:

1. Their use requires powerful roentgen apparatus.
2. The visualization is not always so clear.
3. Their use is not as accurate for small lesions as is the use of lipiodol.
4. Their use is painful and requires the use of a sedative or anesthetic.
5. They are most useful in lumbar, sacral and lower dorsal deformities.
6. Their use is more time consuming and more difficult to perform.

A new diagnostic procedure, myeloscapy, for determining the nature of spinal canal pathology seems to have great practical possibilities. Pool (35) presents this as a means of visualizing the cauda equina through a spinal endoscope called myeloscope. Myeloscapy is usually performed under local anesthesia with the patient in sitting

posture - this gives rise to a hydrostatic distention of the arachnoidal membrane - and is carried out in much the same manner as an ordinary lumbar puncture. Specimens of cerebrospinal fluid may be collected, manometric studies may be done and gas myelography may be performed through the myeloscope. By use of the myeloscope the presence of a thickened ligamentum flavum has been frequently detected by finding an unusually large epidural space, with secondary narrowing of the subarachnoid space (35). Pool has also recognized this lesion in a man suffering from an acute unilateral "sciatica" by the presence of greatly distended looped, root vessels obviously due to compression of that nerve at a lower level. This procedure, then, may in the future afford the means of making a differential diagnosis between an operable and inoperable lesion of the lower spinal cord and it may also serve as a means of sparing many a patient an exploratory laminectomy or lipiodol injection.



## DIFFERENTIAL DIAGNOSIS

Many conditions must be considered in the differential diagnosis of thickening of the ligamentum flavum.

The most important ones are probably an intraspinal neoplasm and herniation of the intervertebral disk. These however do not cause much concern since their treatment is the same; namely, laminectomy and operative removal.

Some of the other common conditions which most closely resemble thickened ligamentum flavum lesions are: low back pain from any cause, lumbosacral strain, sacro-iliac disease, spondylitis and hypertrophic conditions involving the spine.

Some cases may resemble the clinical picture of syringomyelia or of multiple sclerosis. Sciatic neuritis and fibrositis may also be troublesome in making a differential diagnosis.

It is suggested by Love and Camp (29) that whenever any patient considered to be suffering from any of the above conditions has had sufficient conservative treatment and is not responding favorable, the possibility of a protruded intervertebral disk should be seriously considered as the cause of his disability. Certainly it should be considered in any case of intractable and recurrent sciatica.

## TREATMENT

The modern treatment of fibrotic thickening of the ligamentum flavum is very much the same as that used in the first case reported by Elsberg in 1913 (1). However, since the use of iodized oil, and air in localizing the lesion, has become an accepted method of diagnosis, the number of laminae removed has been decreased.

The essential factor in the treatment of thickening of the ligamentum flavum is the wide lateral removal of the protruding mass which is pressing on the spinal cord or nerve roots and producing symptoms of extradural compression. This mass is reached by removing the lamina. As the lamina is removed, the ligament is seen immediately beneath it, and if there is generalized enlargement the constriction of the dural sac is often very marked. A wide lateral excision of the ligaments is made. Most often the ligaments are not adherent to the dura, but they are sometimes quite adherent (17). If they are adherent they must be carefully separated from the dura and removed. A thorough examination should always be made at operation in these cases to determine the presence of an associated dislocation of an intervertebral disk as any undue prominence of the disk serves to decrease the size of the passage for the nerve root, so that even a moderate enlargement of the ligament would compress the root against it (17). If the dislocation is sufficient to compress a nerve root it should of course be removed and this is also true of a nucleus pulposus when found.

An important consideration in connection with the laminectomy usually performed in these cases is whether the patient will ultimately have a strong back. Many surgeons have advised spinal fusion at the time of removal of the thickened ligamentum flavum in order to insure the patient of as strong a back as possible. Love, Adson, and Craig (34), however, feel that the spinal fusion is not necessary. When not done, they maintain that no complications arise. It is Skinner's (20) contention however, that these cases have a weak back to begin with and that they can be benefited greatly by a fusion at the time that the laminectomy is performed.

Love (34) keeps his patients in bed twelve days following the operation. He allows them to leave the hospital on the fourteenth day if there are no postoperative complications. Skinner (20) does not allow his patients, after they leave the hospital, to do heavy labor or engage in dangerous occupations where they are likely to suffer an injury to their back, for a sixty day period. He follows up his cases carefully in regard to the type of exercise they should take, and watches their posture.

## PROGNOSIS

The results of operation for the removal of the thickened ligamenta flava are in most cases very good. By far the majority of patients are completely relieved of their pain and disability. Usually the relief from pain is noticed immediately following operation. Since most of the cases have been treated in the last five years, the permanent results are still undetermined. However, the results of Bradford and Spurling (11) in their eight cases reported is typical of most clinics. In this series there were no post-operative deaths. Nine of the patients have been completely relieved of their symptoms while four have only slight residual pain or weakness. All three of the patients reported by Brown (8) gained complete relief from their symptoms following surgery. In most cases the longer the symptoms have been present, the less the relief obtained by operation because of more severe damage to the nervous system.

Recurrence of symptoms following operation is extremely rare. There has been only one case reported in which there was a recurrence. Meredith and Lehman (9) reported this case in which there appeared to be an operative cure after a laminectomy and removal of a thickened ligamentum flavum, but there was, 9 months later, a complete return of disability and it was found that the patient had a similar lesion at a level one vertebra above the original site.

## SUMMARY

Enlargement of the ligamentum flavum is a definite anatomical and pathological condition which is rapidly gaining in importance.

The condition usually results from trauma which may be either slight or severe.

The most common symptom is root pain, usually of sciatic type, which characteristically undergoes remissions and recurrences.

Diagnosis has been most successful after instillation of lipiodol into the subarachnoid space followed by roentgenographic examination of the spinal canal. There is, at present however, a swing toward the replacement of lipiodol by injections of air into the subarachnoid space, thus avoiding the hazard of a non absorbable and irritating substance within this space.

The treatment by laminectomy with removal of the enlarged ligamentum flavum has been highly satisfactory.

This treatment is followed by complete or partial recovery in nearly all cases and the risk to the patient is minimal.

## BIBLIOGRAPHY

1. Elsberg, Charles A.: Experiences in Spinal Surgery Observations Upon 60 Laminectomies for Spinal Disease, Surg. Gynecology and Obstetrics 16: 117, 1913.
2. Elsberg, Charles A.: Diagnosis and Treatment of Surgical Diseases of the Spinal Cord and Its Membranes, W. B. Saunders Co., Philadelphia, 231, 1916.
3. Elsberg, Charles A.: Diseases of the Spinal Cord, P. B. Hoeber Inc., New York, 473, 1941.
4. Towne, E. B. and Reichert, F. L.: Compression of the Roots and Cord by Thickened Ligamentum Flavum, Annals of Surgery 94: 327-336, September, 1931.
5. Puusepp, L.: Compression of Cauda Equina Causing Tumor-Like Symptoms. Recovery After Surgery, Folia Neuropath. Estonia 12: 38-48, 1932.
6. Abbott, W. D.: Compression of the Cauda Equina by the Ligamentum Flavum, J. A. M. A. 106: 2129-2130, June 20, 1936.
7. Spurling, R. G., Mayfield, F. H. and Rogers, J. B.: Hypertrophy of the Ligamentum Flavum as a Cause of Low Back Pain, J. A. M. A. 109: 928-933, September 18, 1937.
8. Brown, H. A.: Low Back Pain with Special Reference to Dislocation of the Intervertebral Disk and Hypertrophy of the Ligamentum Flavum, West Journal of Surgery Gynecology and Obstetrics 45: 527-531, October 1937.
9. Meredith, J. M. and Lehman, E. P.: Hypertrophy of the Ligamentum Flavum. A Report of Two Atypical Cases, Surgery 4: 587-596, October 1938.
10. Naffziger, H. C., Inman, V. and Saunders, J. B. de C. M.: Lesions of the Intervertebral Disks and Ligamenta Flava, Clinical and Anatomical Studies, Surgery Gynecology and Obstetrics 66: 288-299, February 1938.
11. Bradford, Keith F. and Spurling, G. R.: Intraspinal Causes of Low Back Pain, Surgery Gynecology and Obstetrics 69: 446, 1939.

12. Craig, W. M. and Walsh, M. N.: Diagnosis and Treatment of Low Back and Sciatic Pain Caused by Herniated Intervertebral Disk and Hypertrophied Ligamentum Flavum, Minnesota Medicine 22: 511-517, August 1934.
13. Horwitz, Thomas: Lesions of the Intervertebral Disk and Ligamentum Flavum of the Lumbar Vertebrae. An Anatomic Study of 75 Human Cadavers, Surgery 6: 410, 1939.
14. Dockerty, M. B. and Love, J. G.: Thickening and Fibrosis (So-called Hypertrophy) of the Ligamentum Flavum: A Pathologic Study of Fifty Cases, Proceedings Staff Meetings of the Mayo Clinic 15: 161-166, March 13, 1940.
15. Dickson, W. E. C. and Twort, R. J.: Thickened Ligamenta Flava - In Low Back-Ache and Sciatica, Lancet 1: 1113-1116, June 22, 1940.
16. Walsh, H. N. and Love, J. G.: Protruded Intervertebral Disk As A Cause of Intractable Pain, Proceedings Staff Meetings of the Mayo Clinic 13: 203-205, March 30, 1938.
17. Morton, A. P.: Laminectomy for Low Back Pain, With Case Reports, U. S. Naval Medical Bulletin 37: 523-538, October, 1939.
18. Timmes, J. J.: Hypertrophied Ligamentum Flavum (With Complete Block of Spinal Canal), U. S. Naval Medical Bulletin 37: 538-541, October, 1939.
19. Brown, H. A.: Enlargement of the Ligamentum Flavum, A Cause of Low-Back Pain with Sciatic Radiation, Journal of Bone and Joint Surgery 20: 325-338, April, 1938.
20. Skinner, H. L.: Ruptured Intervertebral Disk and Hypertrophied Ligamentum Flavum Follow-Up Study, Virginia Medical Monthly 67: 490-494, August, 1940.
21. Meyerding, H. W., Baker, G. S., Love, J. G. and Cameron, D. M.: Spondylolisthesis With Protrusion of Intervertebral Disk and Hypertrophied Ligamentum Flavum Associated with Multiple Loose Bodies of Right Shoulder Joint (Report of a Case), Proceedings Staff Meetings of the Mayo Clinic 14: 801-806, December 20, 1939.
22. Love, J. G.: Intractable Low Back and Sciatic Pain Due to Protruded Intervertebral Disks; Diagnosis and Treatment, Minnesota Medicine 21: 832, December, 1938.

23. Love, J. Grafton: Protruded Intervertebral Disks with a Note Regarding Hypertrophy of Ligamenta Flava, J. A. M. A. 113: 2029-2034, November 23, 1939.
24. Abbott, W. D.: Hypertrophy of the Ligamentum Flavum As a Factor in the Production of Low Back and Sciatic Pain, Journal Iowa Medical Society 28: 266-271, July 1938.
25. Love, J. G.: Protrusion of the Intervertebral Disk into the Spinal Canal, Proceedings Staff Meetings of the Mayo Clinic 11: 529-534, August 19, 1936.
26. Flothow, P. G.: Nucleus Pulposus and Hypertrophy of the Ligamentum Flavum (Case Reports), Northwest Medicine 37: 14-18, January 1938.
27. Crosthwaite, W. L.: Injuries of the Spine with Special References to the Ligamentum Flavum, Southern Surgeon 9: 872-877, December 1940.
28. Hampton, A. O. and Robinson, J. M.: The Roentgenographic Demonstration of Rupture of the Intervertebral Disk into the Spinal Canal After Injection of Lipiodol, American Journal Roentgenology 36: 782, 1936.
29. Love, J. G. and Camp, J. D.: Root Pain Resulting From Intra-spinal Protrusion of the Intervertebral Disks; Diagnosis and Surgical Treatment, Journal of Bone and Joint Surgery 19: 776-804, 1937.
30. Berens, S. N.: Lipiodol Versus Air as an Aid in Diagnosis of Protrusion of Intervertebral Disk (and Hypertrophy of Ligamentum Flavum), Northwest Medicine 39: 160-163, May 1940.
31. Scott, M. and Young, B. R.: Sciatic and Low-Back Pain Diagnostic Value of Air Myelography (Special Reference to Herniated Disk), Journal Medical Society, New Jersey 38: 24-26, January 1941.
32. Bell, J. C. and Spurling, R. G.: The Diagnosis of Lesions in the Lower Spinal Canal, Radiology 31: 473-480, October, 1938.
33. Hare, C. C. and Bosworth, D. M.: Herniation of the Nucleus Pulposus and Hypertrophied Ligamenta Flava, New York State Journal of Medicine 39: 1739-1748, September 15, 1939.



34. Love, J. G., Adson, A. W. and Craig, W. M.: Chronic Recurring Sciatic Pain Due to Protruded Intervertebral Disks, Journal Lancet 58: 479-481, November 1938.
35. Pool, J. Lawrence: Myelography: Intraspinal Endoscopy, Surgery 169-182, February 1942.

