

# We are IntechOpen, the world's leading publisher of Open Access books Built by scientists, for scientists

5,800

Open access books available

142,000

International authors and editors

180M

Downloads

Our authors are among the

154

Countries delivered to

TOP 1%

most cited scientists

12.2%

Contributors from top 500 universities



WEB OF SCIENCE™

Selection of our books indexed in the Book Citation Index  
in Web of Science™ Core Collection (BKCI)

Interested in publishing with us?  
Contact [book.department@intechopen.com](mailto:book.department@intechopen.com)

Numbers displayed above are based on latest data collected.  
For more information visit [www.intechopen.com](http://www.intechopen.com)



# Paraumbilical/Umbilical Hernia

*Andrea Sanna and Luca Felicioni*

## Abstract

Umbilical hernia is a common pathology that occurs in around 2% of the population. About 10% of abdominal hernias are umbilical hernias and umbilical hernia repair is among the most commonly performed surgeries in adults. The diagnosis is straightforward when tissues or organs such as the omentum or a bowel segment bulge out through an opening in the muscles of the abdominal wall in the umbilical region. The treatment options for umbilical hernia include non-operative and operative management strategies via open or minimally invasive techniques. This chapter provides a comprehensive review of umbilical hernias in adults.

**Keywords:** hernias, abdominal hernia, umbilical hernia, mesh, surgery

## 1. Introduction

Hernias constitute a broad spectrum of a well-known clinical entity and run throughout the whole history of humankind. One of the first illustrations that describe an umbilical hernia (UH) is seen in a Phoenician terracotta sculpture from the 4th–5th century B.C. Abdominal hernias are defined as a protrusion of structures through a defect of the abdominal wall that normally contains it. An umbilical hernia is a primary ventral hernia with the defect located in the midline at-or within 3 cm around the umbilicus. [1, 2] This is a common type of hernia in the adult population and is exceeded only by the inguinal hernia. Approximately up to 166,000 primary umbilical hernia repairs are performed annually in the United States. [3]

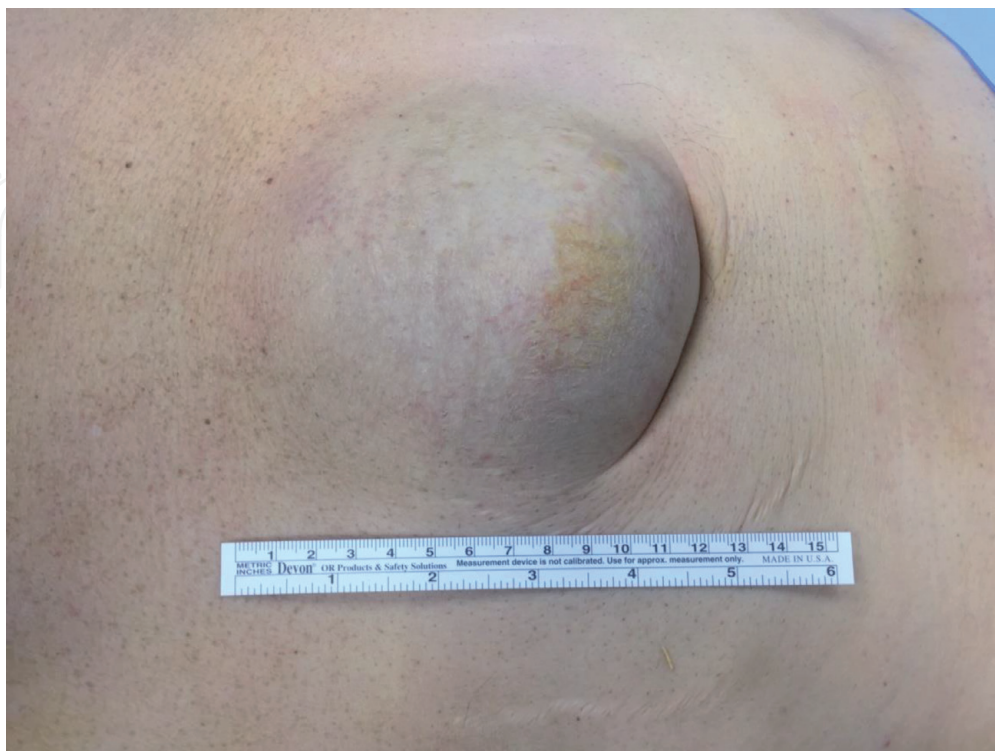## 2. Epidemiology

It was estimated that about 2% of adult population have an umbilical hernia that is clinically demonstrable [1–5]. The results of a study performed by a radiologist on the ultrasound examination of the anterior abdominal wall examination wall done, for reasons other than hernia, showed that asymptomatic UH may be present with an incidence of 25% in females and 23% in males. [4, 5] The incidence rate of UH varies substantially with age and gender. The age-specific prevalence is typically higher for men (61–70 years), compared to women (31–40 years); adipose deposition differs between men and women, this may contribute to the gender differences in the development of UH. Furthermore, the overall numbers of UH repairs are higher in men than in women. [4–8]

### 3. Etiology and pathophysiology

There are several risk factors for the development of umbilical/paraumbilical hernia, some are congenital and others are acquired (90% of cases). (Figure 1). [1–3, 8, 9] Congenital UH is related to an incomplete closure of the umbilical ring, which usually, closes spontaneously within three to five years after birth; in cases of umbilical hernia development, the ring does not close and the muscles which should unite during development fail to form a strong union. A large portion of umbilical hernias labeled as “acquired hernias” because they are diagnosed in adulthood, knowing that some of these may be present from birth but have gone undetected. Despite many studies involving UH, there is lack of data on its development; commonly documented causes for acquired UH include the following: connective tissue disorder (lower type I collagen), overweight, pregnancy (frequent or multiple gestation pregnancies), obesity, ascites, cirrhosis, rectus diastase, peritoneal dialysis, large abdominal tumor, and trisomy 21 syndrome. [8, 9] All conditions that may cause an increase in the intra-abdominal pressure that results in stretching of the abdominal muscles and separate muscle bundles which weaken the fascial layer strength and favor the occurrence of UH. [1, 2, 8, 9] Another factor that has been evaluated over the past decade is the rising rates of obesity in adolescents and adult population. Sports hernia is one particular form of this disease addressed in athletes. Despite the higher prevalence of inguinal hernias in athletes, the anatomical and biomechanical considerations of the central abdominal wall theoretically makes the umbilical are at risk for hernia formation in this group of individuals. That may be due to disproportionate pull of abdominal rectus muscles as the proposed mechanism for creation of inguinal hernias in athletes. [7–9]

In adults, the abdominal wall usually has sufficient strength to resist rising abdominal pressure to prevent herniation of intra-abdominal contents. In certain abdominal wall weakening conditions, such as chronic abdominal distension the rising pressure from within may be responsible for the occurrence of UH. [10]



**Figure 1.**  
*Umbilical hernia strangulated.*

Hernia development is more common in pregnancy due to two main components, hormonally induced increased laxity of the pelvic ligaments and high abdominal pressure. It is also more common in the elderly due to degenerative weakness of muscles and fibrous tissue. [1, 2, 7, 8]

#### 4. Clinical history and presentation

The presentation of UH is variable, from asymptomatic to requiring emergency surgery (4% after 5 years). [1, 2, 4, 8] Small-size hernia with incarcerated omentum could produce intermittent or constant pain, sometimes associated with general symptoms. Larger hernias may be asymptomatic. Patients often present with mild symptoms, some degree of discomfort usually appears first. UH typically, presents with protrusion or bulging under the skin at the umbilical ring, one should determine whether the hernia reduces spontaneously or needs to be reduced manually. Progressively, the hernia (fascial) defect enlarges and in most cases becomes tender or irreducible with time. Severe pain should alert the surgeon to a high risk of strangulation: compromised blood supply to herniated tissues/organs. This is a serious complication with signs of skin color changes and, intestinal obstruction if the sac contains a loop of small bowel (**Figure 1**). It is important to remember that UH can lead to complications many of which can be fatal if not properly treated. Strangulation can occur in irreducible, also known as incarcerated hernias, and can lead to peritonitis, septic shock and a rapid deterioration in the patient's condition. Some reports show that older age, female gender, umbilical hernia defects between 2 and 7 cm are potential risk factors for the development of acute complications. [1, 2, 7, 9]

The European Hernia Society and Americas Hernia Society (EHS and AHS) classification for umbilical/epigastric hernia is a clinically relevant system based on defect diameter (**Table 1**). [8]

Primary Umbilical Hernia size	Dimension
Small	1.1 cm
Medium	More than 1 cm up to 4 cm
Large	Over 4 cm

**Table 1.**  
*The European and Americas hernia society classification for umbilical/epigastric.*

#### 5. Diagnosis and investigations

Umbilical hernia is usually diagnosed by inspection and palpation with the patient lying down and standing, as this will usually make the hernia bulge more apparent and demonstrable. The patient is asked to cough or make a Valsalva's maneuver, this can cause an occult hernia to be more evident. It is important to estimate both the fascial defect size and hernia content. Careful examination of the entire abdominal wall is crucial in order to evaluate for hernia complications or the presence of multiple defects. Skin must be evaluated, the appearance of bruises suggests venous engorgement of the hernia contents; this may be due to underlying complications such as incarceration or strangulation. Local and generalized abdominal pain, irreducible hernia, fever, leucocytosis and signs of bowel obstruction are signs that warrant immediate attention and management as they may potentially be related to significant complications.

When a patient has symptoms but no hernia demonstrated on meticulous and detailed physical exam, or there is clinical uncertainty, imaging may be helpful to establish the diagnosis. In these patients, abdominal ultrasound and/or computed tomography are very useful in establishing the diagnosis as well as preoperatively planning, for instance, they can influence surgical decision making in terms of choosing open versus laparoscopic approaches [3].

## **6. Management**

There are two main treatment options for patients with umbilical hernia, non-operative management and surgical repair. Non-operative management can be divided into three categories:

1. Non-operative management except for acute presentations suitable for high-risk patients.
2. Initial non-operative management: in symptomatic or patients who desire to have the hernia repaired but have modifiable risk factors such as smoking, uncontrolled diabetes, BMI > 30 Kg/m<sup>2</sup>).
3. Watchful waiting and “wait for symptoms to appear”: suitable in patients with acceptable surgical risks but have few hernia symptoms or signs [1, 2, 4, 7–9, 11].

Outcomes of patients treated non-operatively and the risk of delayed acute presentation are unclear. However data from a retrospective study showed that within 5 years of follow-up 4% of cases underwent surgical procedures in emergency settings. Little is known about the results of watchful waiting approach in patients with UH but this strategy seems safe.

The common risks of non-operative management include increasing discomfort or pain (worsening during coughing and defecation), increasing hernia size, skin complications, constipation due to worsening abdominal function and acute presentations such as sharp pain and irreducibility.

Typically, adult symptomatic umbilical hernias need to be fixed to reduce the potential risk of complications. Umbilical hernia repair can be achieved with either sutured or mesh repair. The latest guidelines by SAGE and EHS-AHS (European Hernia Society-American Hernia Society) recommended the mesh usage in order to reduce hernia recurrences. Sutured repair can be considered for small-size hernia defects of less than one cm [9].

Umbilical hernia repair can be achieved either via an open procedure or minimally invasive surgery as laparoscopic or robotic technique.

### **6.1 Open umbilical hernia repair, suture alone**

Mayo technique has been considered for many years to be the standard technique for primary umbilical hernia repair. This technique, described in 1901, involves a fascial closure using two suture lines: some interrupted permanent sutures and some running absorbable sutures; the author found that the transverse direction of closure may be advantageous. [11] The recurrence rates with this technique has remained high over time. The modified technique used today is a simple defect closure with a single line of sutures. It is recommend to use non-absorbable sutures in order to reduce hernia recurrence (low level of

evidence). [8] It is important to remember that sutured repair of primary small umbilical hernia (<1 cm) with the presence of muscles diastasis is a significant risk factor for recurrence, hence prosthetic reinforcement, using a mesh, for clean cases is recommended. [12]

## **6.2 Open umbilical hernia mesh repair**

An infra-umbilical incision is usually used (transverse and vertical incision shave similar outcomes) and then the umbilical stalk is dissected. The hernia sac is dissected down to the fascia. Reduction of hernia sac and its content into abdominal cavity is done. Fascial edges should be refurbished by incising at least 2 mm margins from the umbilical ring. Gentle blunt dissection to the posterior rectus sheath is done to prepare the posterior field. A space of 5 cm in all directions should be developed. The mesh generally can be placed in either the sublay position (retrorectus space) or the underlay pre-peritoneal position. Moreover, there are commercially available umbilical hernia patches with mesh coated by tissue-separating layer designed to allow for intra-peritoneal mesh placement. The defect can be closed with absorbable or non-absorbable sutures [13, 14]. The skin closure is done with material based on the surgeon's preferences.

## **6.3 MIS: Intraperitoneal Onlay mesh (IPOM)**

To be able to perform the IPOM repair, preparation of the needed laparoscopic instruments is imperative. These include: camera port, one 11 mm blunt trocar, one 5 mm trocar, 30° endoscope, bipolar coagulation clamp, monopolar coagulation scissor. The patient is placed in the supine position with bilateral arms tucked to the sides on a flexed table. The monitor is placed in front of the surgeon. Pneumoperitoneum is then established with the surgeon's preferred technique (Verres needle, open approach, optically trocar). A 12 mmHg CO<sub>2</sub> pressure creates the working space. Once a good working space is established, either an 11 or 5-mm trocars are placed on the left lateral side. The hernia ring is dissected with reduction of the contents and the hernia sac. Usually peritoneal fat and falciform ligament are dissected to expose the fascia. This is important in order to improve mesh fixation which is done using tacs to anchor and prevent the mesh from sliding [15]. Hernia defect closure is a good practice and can be performed using absorbable barbed sutures either laparoscopically or using Reverdin needle techniques, based on surgeon's preferences, may be used. Based on the published literature, it is reasonable to cover the hernia defect with 3–5 cm mesh overlap to avoid hernia recurrences (primary UH repair open or MIS technique). The coated mesh is then secured to the abdominal wall using double crown absorbable or non-absorbable. [16–20] The procedure may be performed either laparoscopically or robotically with some variations pertaining to docking and positioning. [20]

## **6.4 MIS: retro-rectus repair (Rives-Stoppa)**

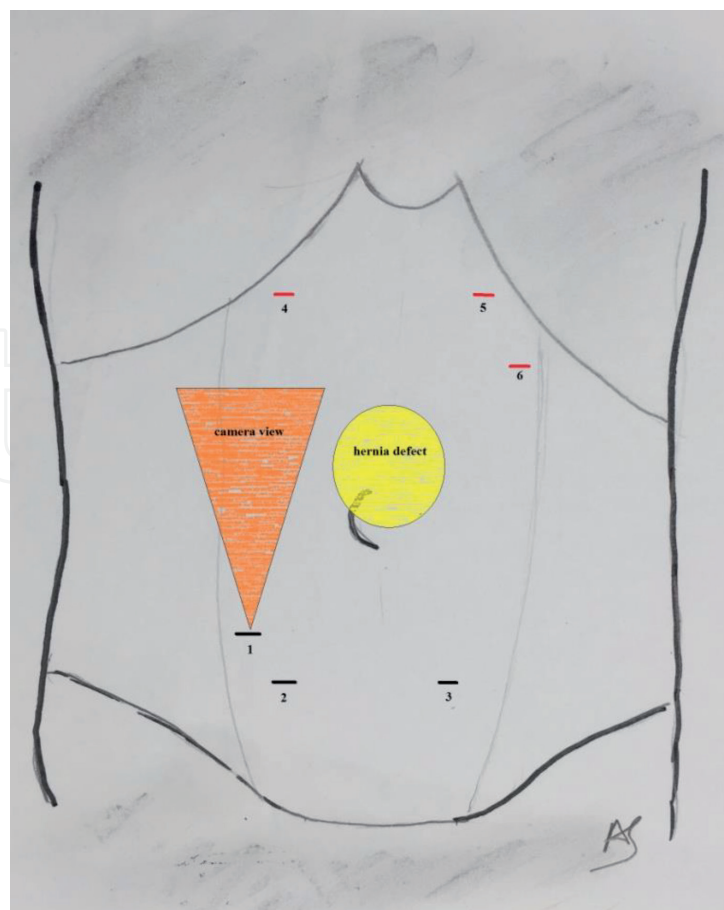
Several advances brought about by the prosthetics mesh industry, allowed for an effective intraperitoneal mesh placement for UH repair. However, safety problems have been raised and were reported in some cases series. In these series, late complication that emerged included adhesions, fistula formation, mesh migrations, and further damage to the abdominal viscera. In an attempt to reduce the incidence of these complications many authors proposed the placement of the prosthesis between the recto-muscle and posterior rectus fascia (retro-muscular) or between the posterior rectus sheath and the peritoneum when possible.

Several methods have been suggested by different authors to achieve the retro-muscle or preperitoneal mesh placement. These techniques include the TEP (enhanced-view Totally Extra-Peritoneal), MILOS (Minimally Invasive Less Open Sublay), Emilos, (Endoscopic/MILOS), Costa “the Brazilian technique”, TARUP (Robotic Transabdominal Retromuscular Umbilical Prosthetic) [15–22]. Moreover, some of these surgical techniques can be performed using minimally invasive approaches as posterior component separation technique (advancement of rectus-muscle), to allow reconstruction of large abdominal wall defects.


### 6.5 MIS: enhanced-view totally extraperitoneal (eTEP) retromuscular hernia repair

We describe eTEP technique popularized by Dr. Jorge Daes in 2012 and Belyansky in 2017 (used in inguinal hernia repair and in incisional ventral hernia repair), this technique enlarges the surgical field in comparison with the conventional TEP procedure, this approach can be performed either laparoscopically or robotically. Equipment for laparoscopic instrumentation, as we have previously described, included: camera port, one 12 mm blunt trocar, one 5 mm trocars (all with balloon), 30° endoscope, bipolar coagulation clamp, monopolar coagulation scissor, articulating radio frequency device [17, 22]. The patient is placed supine with bilateral arms tucked by the sides.

Foley catheter is placed in all cases. Operating room table is flexed as indicated by Belyansky. [16] The monitor is placed in front of the surgeon. The key elements of port placement depend on defect extension, lower midline umbilical hernia defects or upside midline umbilical hernia defect (**Figures 2, 3**). [16–21] The eTEP



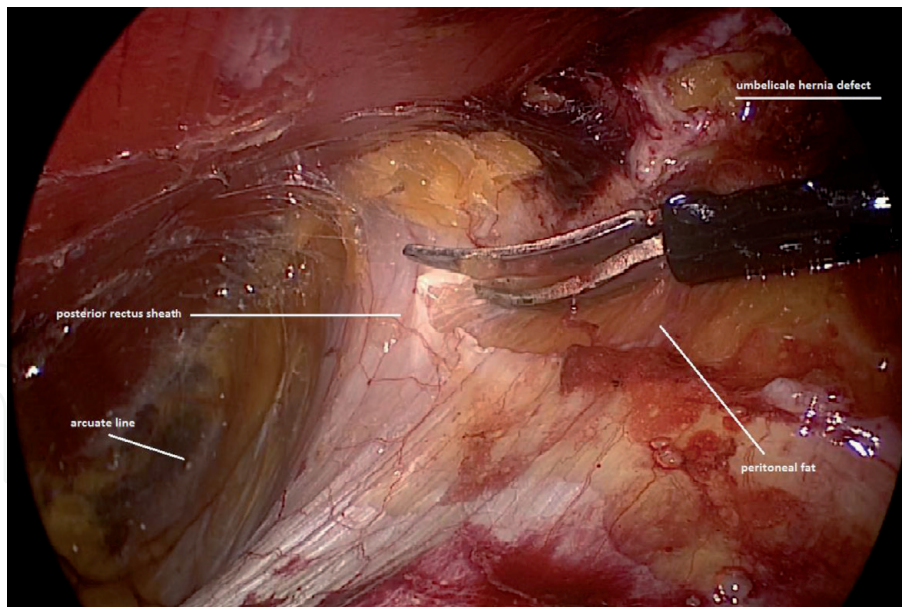
**Figure 2.**  
*Port position for upper side defects (black line; red line trocars additional).*



**Figure 3.**  
*Port position for lower side defects (red line; black line trocars additional).*

umbilical hernia repair technique begins with a one side retro-rectus dissection. The first incision is indicated with by the camera view as in **Figures 2, 3**. The anterior rectus sheath is incised. The rectus muscle fibers are opened and working space is created with a balloon dissector. Carbon dioxide is used as in laparoscopic techniques to establish pneumoperitoneum. A 6–8 mmHg CO<sub>2</sub> pressure is set inside the working space. Dissection of one retro-rectus space is made with energy source (bipolar articulating tissue sealer or radio frequency device). Other trocars are placed as described in **Figures 2, 3**. Extra trocars can be placed if deemed necessary. Then crossing over to the contralateral retrorectus space, the two space are joined. Gentle dissection of the tissue is performed without violating the peritoneum. Then the, right posterior sheath is dissected to achieve the right retro-rectus space. Dissection of right retro-rectus space is made and the right and left posterior sheath are divide both until arcuate line (**Figure 4**). Laterally the dissection is limited by the linea semilunaris. The hernia ring is dissected with reduction of the contents and hernia sac. Posterior defect is closed using 2–0 absorbable barbed sutures. The hernia defect is closed too with number 0 absorbable barbed suture. Mesh is positioned to cover umbilical hernia defect with 5 cm of overlap. The mesh is secured with cyanoacrylate.





**Figure 4.**  
*Left posterior rectus sheath is incised from cephalad to caudal direction.*

## 7. Surgical complications

Umbilical hernia repair is associated with good outcomes and a lower rates of hernias recurrences and overall complications. The hernia size and the fascial defect are important risk factors predicting surgical complications. There is still a spectrum of complications within each of these categories including minor wound separation and complete wound separation both of which would be categorized as wound dehiscence. The leading complications include wound complications (seroma, haematoma, infections), bowel injury and hernia recurrences. [2, 7]. The disadvantage of synthetic mesh placement must be considered; however, no significant differences in complication rates when comparing mesh to suture repair.

Recent studies have shown lower rate of mesh complications. [8] Mesh infection complicates in most cases open ventral hernia repairs than laparoscopic repairs. Mesh erosion into the gastro-intestinal tract is published and likely an underreported late complication of mesh placement particularly the intra-peritoneal mesh position which has been associated with erosion and the development of late fistula.

## 8. Conclusions

Since the original description by Mayo in 1901, a wide variety of options became available for the repair of umbilical hernias, in order to reduce surgical morbidity and improve the patient's quality of life. Umbilical hernia is a disease process that requires the general surgeon to have a wide armamentarium of repair techniques. An understanding of anatomy is key for tailored treatment. Utilization of advanced techniques requires careful patient selection, knowledge of abdominal wall anatomy and technical details in order to reduce the need for reoperations. Several of these innovations, including either minimally invasive techniques and the uses of different types and positions of meshes to be used in reinforcement. Despite this, it is clear that mesh repair of incisional and inguinal hernias reduces recurrence rates, the impact of mesh for umbilical hernia repair remains a subject of debate. To date, some prospective randomized controlled trials have addressed this question. These studies found lower recurrence rates after mesh versus primary suture repair,

without a significant increase in the risk of wound-related infectious complications. Based on current evidence, primary hernia repair remains reasonable and appropriate only for small (1 cm) umbilical hernias. As always, in abdominal wall reconstruction we believe that the specific technique for repair should be tailored to the individual patient.

## **Acknowledgements**

The authors are grateful to Dr. B. Mantovan drafted the manuscript.

## **Conflict of interest**

The authors: A. Sanna have no conflicts of interest or financial ties to disclose. L. Felicioni has received grants from Company, for others studies (2018 BARD, 2019 GEM and AB Medica).

## **Author details**

Andrea Sanna<sup>1\*</sup> and Luca Felicioni<sup>2</sup>

1 Department of General Surgery, Ospedali Riuniti Padova Sud, Padova, Italy

2 Department of General and Robotic Surgery, Ospedale della Misericordia, Grosseto, Italy

\*Address all correspondence to: [and\\_sanna@yahoo.it](mailto:and_sanna@yahoo.it)

## **IntechOpen**

© 2021 The Author(s). Licensee IntechOpen. This chapter is distributed under the terms of the Creative Commons Attribution License (<http://creativecommons.org/licenses/by/3.0>), which permits unrestricted use, distribution, and reproduction in any medium, provided the original work is properly cited. 

## References

- [1] Dabbas N, Adams K, Pearson K, Royle G. Frequency of abdominal hernias: is classical teaching out of date? *JRSM Short Rep.* 2011 Jan 19;2(1):5.
- [2] Coste AH, Jaafar S, Parmely JD. Umbilical Hernia. 2020 Jul 21. In: *StatPearls [Internet]*. Treasure Island (FL): StatPearls Publishing; 2020 Jan-. PMID: 29083594.
- [3] Bedewi MA, El-Sharkawy MS, Al Boukai AA, Al-Nakshabandi N. Prevalence of adult paraumbilical hernia. Assessment by high-resolution sonography: a hospital-based study. *Hernia.* 2012 Feb;16(1):59-62. doi: 10.1007/s10029-011-0863-4. Epub 2011 Jul 28. PMID: 21796449.
- [4] T.J.Swope. Umbilical Hernia options. *The sages manual of hernia.* Springer 2019:157-172.
- [5] Hope W, Cobb WS, Adrales GL, *Textbook of hernia.* Springer, 2017
- [6] Shankar DA, Itani KMF, O'Brian WJ, Sanchez VM. Factors associated with long-term outcomes of umbilical hernia repair. *Jama Surg.* 2017 May 01;152(5):461-466.
- [7] Venclauskas L, Joukubasuskas M, Zilinskas J, Zviniene K, Kiidelis M. Long-term follow-up results umbilical hernia repair. *Wideochir Inne Tech Maloinwazyjne.* 2017 Dec;12(4):350-356
- [8] Williams N, Rononan o'Connel P, McCaskie A. *Short Prattice of surgery* 27<sup>th</sup> Edition .Bailey & Love's.2017
- [9] Henriksen NA, Montgomery A, Kaufmann R, Berrevoet F, East B, Fischer J, Hope W, Klassen D, Lorenz R, Renard Y, Garcia Urena MA, Simons MP; European and Americas Hernia Societies (EHS and AHS). Guidelines for treatment of umbilical and epigastric hernias from European Hernia Society and American Hernia Society. *Br J Surg.* 2020 Feb;107(3):171-190. doi: 10.1002/bjs.11489. Epub 2020 Jan 9.
- [10] Farber AJ, Wilckens JH. Sports hernia: diagnosis and therapeutic approach. *J Am Acad Orthop Surg.* 2007;15(8):507-14. doi:10.5435/00124635-200708000-00007
- [11] Kokotovic D, Sjølander H, Gögenur I, Helgstrand F. Watchful waiting as a treatment strategy for patients with a ventral hernia appears to be safe. *Hernia.* 2016;20(2):281-7.
- [12] Mayo WJ. VI. An Operation for the Radical Cure of Umbilical Hernia. *Ann Surg.* 1901 Aug;34(2):276-80. doi: 10.1097/00000658-190107000-00021. PMID: 17861015; PMCID: PMC1425538.
- [13] Heidi J. Miller, Yuri W. Novitsky. *Ventral Hernia and Abdominal Release Procedures. Shackelford's Surgery of the Alimentary Tract, 2 Volume Set (Eighth Edition),* 2019
- [14] Belyansky I, Daes Köhler G, Luketina RR, Emmanuel K Sutured repair of primary small umbilical and epigastric hernias: concomitant rectus diastasis is a significant risk factor for recurrence. *World J Surg* 2015. 39(1):121-126
- [15] Muysoms F, Vander Mijnsbrugge G, Pletinckx P, Boldo E, Jacobs I, Michiels M, Ceulemans R (2013) Randomized clinical trial of mesh fixation with "double crown" versus "sutures and tackers" in laparoscopic ventral hernia repair. *Hernia* 17:603-612
- [16] Gonzalez AM, Romero RJ, Seetharamaiah R, Gallas M, Lamoureux J, Rabaza JR (2015) Laparoscopic ventral hernia

repair with primary closure versus no primary closure of the defect: potential benefits of the robotic technology. *Int J Med Robot* 11:120-125

[17] Belyansky J, Radu VG, Balasubramanian R, Reza Zahiri H, Weltz AS, Sibia US, Park A, Novitsky Y. A novel approach using the enhanced-view totally extraperitoneal (eTEP) technique for laparoscopic retromuscular hernia repair. *Surg Endosc*. 2018 Mar;32(3):1525-1532. doi: 10.1007/s00464-017-5840-2. Epub 2017 Sep 15.

[18] Schroeder AD, Debus ES, Reinpold WM et al Laparoscopic transperitoneal sublay mesh repair: a new technique for the cure of ventral and incisional hernias. *Surg Endosc* 2013.27(2):648-654

[19] W Reinpold , M Schröder , C Berger , W Stoltenberg , F Köckerling MILOS and EMILOS repair of primary umbilical and epigastric hernias Hernia. 2019 Oct;23(5):935-944. doi: 10.1007/s10029-019-02056

[20] Costa TN, Abdalla RZ, Santo MA et al Transabdominal midline reconstruction by minimally invasive surgery: technique and results. *Hernia* 2016. 20(2):257-265

[21] Muysoms F, Van Cleven S, Pletinckx P et al Robotic transabdominal retromuscular umbilical prosthetic hernia repair (TARUP): observational study on the operative time during the learning curve. *Hernia* 2018. 2(6):1101-1111

[22] Sanna A, Felicioni L, Cecconi C, Cola R. Retromuscular Mesh Repair Using Extended Totally Extraperitoneal Repair Minimal Access: Early Outcomes of an Evolving Technique—A Single Institution Experience. *J Laparoendosc Adv Surg Tech A*. 2020 Mar;30(3):246-250. doi: 10.1089/lap.2019.0661.