

We are IntechOpen, the world's leading publisher of Open Access books Built by scientists, for scientists

5,600

Open access books available

137,000

International authors and editors

170M

Downloads

Our authors are among the

154

Countries delivered to

TOP 1%

most cited scientists

12.2%

Contributors from top 500 universities



WEB OF SCIENCE™

Selection of our books indexed in the Book Citation Index
in Web of Science™ Core Collection (BKCI)

Interested in publishing with us?
Contact book.department@intechopen.com

Numbers displayed above are based on latest data collected.
For more information visit www.intechopen.com



Management of Brain Tumors in Eloquent Areas with Awake Patient

José Luis Navarro-Olvera, Gustavo Parra-Romero, Stephani Dalila Heres-Becerril, David Trejo-Martínez, José D. Carrillo Ruiz, Kleber Gonzalez Echeverría and Gustavo Aguado-Carrillo

Abstract

This chapter aims to provide an overview of the transdisciplinary work of the Neurosurgeon, Neuroanesthesiologist and Neuropsychologist before, during and after the resection of a neoplasm in eloquent areas with the patient conscious under the 3A anesthesia modality (asleep, awake, asleep). The diagnostic approach and the logistics to carry out this procedure and achieve better results will be shown. At present there is growing evidence regarding the benefits of surgery in awake patients, with application in the treatment of epilepsy, abnormal movements and oncological surgery. The benefits of awake craniotomy are increased lesion removal, with improved survival benefit, whilst minimizing damage to eloquent cortex and resulting postoperative neurological dysfunction. Other advantages include a shorter hospitalization time, hence reduced cost of care, and a decreased incidence of postoperative complications. This approach has allowed to achieve a higher degree of resection with less morbidity and a higher quality of life.

Keywords: brain tumors, eloquent areas, neurosurgery, awake craniotomy

1. Introduction

This chapter aims to provide an overview of the transdisciplinary work of the Neurosurgeon, Neuroanesthesiologist and Neuropsychologist before, during and after the resection of a neoplasm in eloquent areas with the patient conscious under the 3A anesthesia modality (asleep, awake, asleep). The diagnostic approach and the logistics to carry out this procedure and achieve better results will be shown.

At present there is growing evidence regarding the benefits of surgery in awake patients, with application in the treatment of epilepsy, abnormal movements and neurooncological surgery [1]. The benefits of awake craniotomy are increased lesion removal, with improved survival benefit, whilst minimizing damage to eloquent cortex and resulting postoperative neurological dysfunction. Other advantages include a shorter hospitalization time, hence reduced cost of care, and a decreased incidence of postoperative complications [2, 3]. This approach has allowed to achieve a higher degree of resection with less morbidity and a higher quality of life [2, 3].

1.1 History of brain surgery with awake patient

Throughout the history of neurosurgery it is known from archeological findings that therapeutic trepanation has existed since the Neolithic period between 8,000–500 BC, this type of treatment was performed for headaches, fractures, localized cranial deformity, mental changes, infections or seizures [4].

The earliest descriptions in the modern era of neurosurgery date back to descriptions in the treatment of epilepsy in the 17th century. However, the most identifiable antecedent dates back to the beginning of the last century with Penfield's descriptions in the 1920s of intractable epilepsy surgery in awake patients and later in 1937 with the exposure of the intraoperative electrical stimulation technique used for the treatment of epileptogenic foci close to the language area [5, 6].

It was not until 1970 that the intraoperative cortical mapping technique began to be used for the resection of neoplastic lesions by Whitaker and Ojemann, who perfected the technique and published the first series that demonstrated the usefulness of this technique, describing it as safe, simple and adequately tolerated by most patients [5–7]. Later, in the last decade of the 20th century, Berger began to treat infiltrating neoplasms in eloquent cortical areas, improving the cortical mapping technique with the posterior publication of his experience [5, 8, 9]. Finally, in recent decades, new neuroanatomical studies and the popularization of the cortical mapping technique have led to a better understanding of the cortical and subcortical anatomy, improving the technique and prognosis of patients with infiltrating CNS lesions [10, 11].

For centuries there has been an incessant search to associate specific neurological functions with specific areas of the nervous system. At the beginning of the 19th century, explanatory models of functional neuroanatomy were built. The first to develop a model was Franz Joseph Gall (1776–1832) and his disciple Spurzheim. Dr. Gall is the founder of phrenology, based on the interpretation of the different neurological functions, on the basis that the greater development of a certain function resulted in hypertrophy of a specific brain region and that this hypertrophy conditioned a variation in the external configuration of the skull. This ability of the nervous system to “hypertrophy”, erroneously in the past, is now one of the main properties of the central nervous system used by modern radiology, such as the BOLD effect (increased blood supply to an area that is developing functional activity) or PET (increased glucose metabolism) [12, 13].

Walter Moxon (1836–1886) published the first cases that exposed the principle of hemispheric lateralization, associating the right hemiplegia with aphasia and, therefore, breaking the principle of hemispheric symmetry and locating language in the dominant left hemisphere. Later, Paul Broca presented the case of Monsieur Leborgne a patient suffering from septic gangrene in the lower limb. He was admitted to the Salpêtrière hospital in Paris with a clinical presentation described by Broca as “expressive aphemia”, that is, he did not present facial motor deficit or comprehension problems, but the patient was unable to articulate words. An autopsy study identified the lesion in the posterior part of the lower left frontal gyrus. Pierre Marie (1853–1940), reexamined the brain of M. Leborgne, despite confirming the anatomical - functional association made by Broca 50 years earlier, he also concluded that the lesion was not limited to Broca's area only, but it extended subcortically to the striatum and posterior to the angular gyrus [12–14].

Carl Wernicke in 1874 gave name and anatomical location to sensory aphasia that he located in the primary auditory cortex, in the posterior part of the superior left temporal gyrus. Decades later Theodore Meynert (1833–1892) was the first to associate auditory aphasia with the posterior part of the superior left temporal gyrus. Wernicke not only correlated the types of aphasia with different areas, but

also established the term conduction aphasia (inability to repeat words) for those syndromes of disconnection between the sensory and motor areas of language, associated with the lesion of the arcuate fascicle (AF) [13, 15].

Geschwind succeeded in introducing one more level into the theory of language: the fundamental idea of networking and interconnection of the central nervous system. There are some basic Broca - Wernicke nodes and their main connection, which is the arcuate fascicle, but they do not work in isolation [16].

Damasio published the implication of the associative areas of the left medial frontal gyrus and the premotor area when performing tasks of understand words when related to animals, tools, or people. Also the implication of the inferotemporal cortex in the assimilation of the semantic concept of language, regardless of the stimulus pathway through which the word, visual (reading) or auditory information arrives, the precise implication of the dominant temporal pole in the memory-language association with the name of famous faces or places. He also characterized the difference between the pure primary auditory cortex in the transverse gyrus of Heschl and the posterior temporal area in T1 proper language, establishing the high regional cortical specialization for language understanding and he introduced the participation of the right hemisphere in the assimilation of concepts [17, 18].

1.2 Anatomy of brain eloquent areas

Once the historical review of the intraoperative cortical mapping has been carried out, it is important to emphasize that it is an evolving paradigm. Nowadays the vision of functions dependent on a specific anatomical cortical site has given way to a new dynamic and integrative paradigm with structural and functional connectivity and reciprocal influence, in this manner a lesion in a given site does not affect only one function, but the system as a whole [19, 20]. For this reason, pre-surgical functional studies are not superior to intraoperative mapping.

Although it is accepted that the mapping should be directed towards the area where the lesion is located, the wide anatomical and functional variability between individuals, limitations in presurgical neuroimaging, and functional modifications caused by the tumor must be considered [21, 22]. Usually, the evaluation of 8 main domains is accepted, which are adapted to the location of the lesion, activity of each patient and the evaluation of the benefit of a broad resection against the loss of functionality/neuroplasticity [20, 22]:

1. Movement.
2. Somatosensory function.
3. Visual Function.
4. Vestibular/auditory function.
5. Language (spontaneous, nominate, understand, repeat, read, write).
6. Higher functions (calculation, memory, attention, cognitive control, judgment).
7. Spatial orientation.
8. State of consciousness (**Table 1**).

Function	Cortical Areas	Subcortical pathways
Motor function	Central region, SMA, premotor cortex	Pyramidal pathways (corona radiata, internal capsule, mesencephalic peduncles)
Somatosensory	Central region (primary and secondary somatosensory areas), insula	Thalamocortical pathways
Oral language		
Ventral semantic stream	Posterior temporal regions, orbitofrontal and dorsolateral prefrontal areas (dorsal and ventral)	Inferior occipital fasciculus
Dorsal phonological stream	Posterosuperior temporal cortex, inferior frontal gyrus	Direct SLF (arcuate fasciculus)
Articulatory loop	Supramarginalis gyrus, ventral premotor cortex	Indirect SLF III (lateral, anterior)
Speech production	Dominant anterior insula (articulatory planning), ventral premotor cortex, primary sensorimotor area of the mouth	Operculo-insular fibers, descending pathways from the ventral premotor cortex, pyramidal tract and lentiform nucleus.
Writing	Inferior and superior parietal lobules, insula, second and third frontal convolutions, SMA	SLF
Reading	Visual cortex, visual object (word) form area	Inferior longitudinal fasciculus
Visuospatial cognition		
Visual	Temporo-parieto-occipital junction, visual cortex	Optic radiations
Spatial awareness	Right supramarginal gyrus, right superior temporal cortex	Right SLF
Vestibular	Right inferior parietal cortex, posterior insula, superior temporal cortex	Right SLF
Higher cognitive / executive functions		
Language switching	Left inferior frontal gyrus, posterosuperior temporal area	SLF
Working memory	Inferior frontal gyrus, dorsal premotor cortex, supramarginal gyrus	SLF
Syntactic processing	Left inferior frontal gyrus, left inferior temporal gyrus	SLF
Judgment, decision making, understanding	Left dominant prefrontal cortex, Left posterior temporal cortex.	Inferior occipitofrontal fasciculus
Selection, inhibition, attention	SMA, cingulum, frontal eye fields.	Subcallosal medialis fasciculus, head of the caudate nucleus

SLF: superior longitudinal fasciculus.
SMA: supplementary motor area.
 From: De Benedictis A, Duffau H. Brain hodotopy: From esoteric concept to practical surgical applications. Neurosurgery 2011;68:1709–23.

Table 1. Cortical and subcortical structures involved in major brain functions as detected by direct cerebral stimulation.

The cortical mapping must be adapted in each patient, according to location of the lesion. The following paragraphs review the main tasks and effects of cortical stimulation.

1.2.1 Frontal lobe

The main functions to evaluate correspond to the motor paradigm, which traditionally has an anatomical correlate in the primary motor cortex in the precentral gyrus, and surrounding subcortical regions, therefore it is necessary to map this area to avoid contralateral paresis or plegia. Corona radiata is considered the posterior subcortical limit of a frontal lesion resection. Cortical mapping is performed by asking the patient to perform movements while stimulating the specific area with respect to the Penfield homunculus, which will lead to its inhibition, or in a patient at rest the stimulation will cause involuntary movement [21, 22] (**Vignette 1**).

Vignette 1. Intraoperative cortical electrical stimulation

It is the most widely used technique in awake patient surgery to delimit essential brain regions for some functions such as movement and language. It consists of the administration of an electric current in milli-amperes directly on the cerebral cortex (authors recommend bipolar stimulation, short train, 1 ms duration and 200 Hz frequency, with 5-20 mA intensity) in order to cause depolarization of a group of neurons belonging to a cerebral system to produce a positive symptom (such as a muscle contraction) or negative (such as the arrest during number counting).

Thanks to this technique, the organization of the representation of the body in the cerebral cortex was described by the eminent neurosurgeon Wilder Penfield in the 1950s and later important contributions were made on the organization of language in the brain by George Ojemann.

Among the most important advantages is the speed with which a wide region of the cerebral cortex can be mapped, in cases where the neoplasm delimited in the cortex can be observed, the edges of the lesion can be delimited. In the same way, it is possible to stimulate subcortically in the white matter.

Among the most important limitations is the little time available to carry out a cognitive task. For example, it is ideal to explore the denomination since the electrical stimulus can be administered immediately after asking the patient for the name of an object represented in a slide (several seconds), however it would not be possible to administer an electrical stimulus during the elaboration of a narration (**Figures 1–3**).

The supplementary motor cortex (SMA) is responsible for preparation, initiation, and monitoring movement, and it is located anterior to the cortical representation of the lower limb of precentral circumvolution. In the dominant hemisphere it exerts a function in the articulation of language, so its stimulation can cause alterations in the fluency of language when asking to name pictures. [22, 23].

The frontal premotor cortex (PMC) has a ventrolateral division responsible for the articulation of language, which when stimulated can cause anarthria; while the dorsolateral division is involved in the naming network, causing anomia when stimulated, this mainly in the dominant hemisphere. This location is where the intensity values of the stimulation are determined to obtain responses in the rest of the areas to explore [22, 23].

The cortex of the inferior and middle frontal gyri, when stimulated, causes impairment in writing.

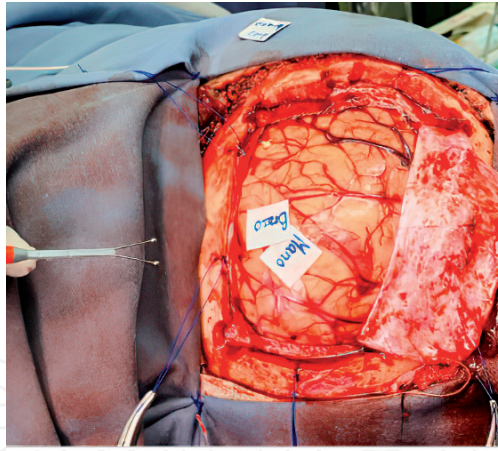


Figure 1.
Cortical stimulation with bipolar.

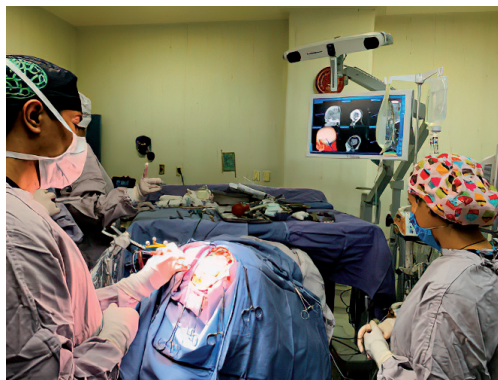

Figure 2.
Use of cortical stimulation guided by navigation.

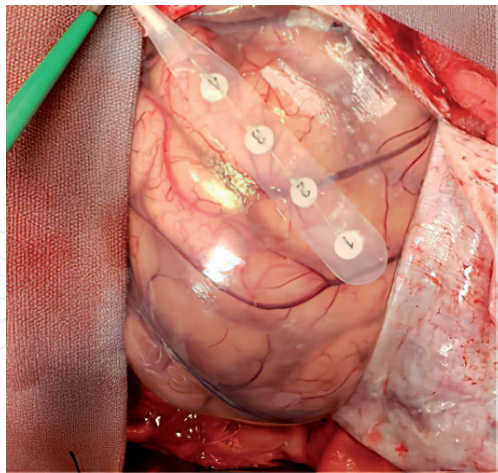


Figure 3.
Cortical stimulation using various contacts.

Regarding the frontal subcortical mapping, these fasciculi are evaluated by counting, naming, and reading tasks, the main tracts to evaluate in this area are:

- a. *Superior Longitudinal Fasciculus (SLF)*: it has the cortical projections of the frontal, temporal and inferior parietal lobe. SLF stimulation through the arcuate fasciculus (AF), can cause problems in the production of language, memory alterations and phonemic paraphasia.

- b. *Subcallosal fasciculus*: it links the frontomesial structures with the striatum, so its stimulation causes a decrease in fluency or difficulty in initiating language.
- c. *Anterior part of Inferior Frontooccipital fascicle (aIFOF)*: projects the orbitofrontal and dorsolateral prefrontal cortex with the temporooccipital cortex. aIFOF stimulation causes semantic paraphasia and failures in facial recognition. aIFOF represents the lower limit of resection of frontoorbital lesions [22–24].

Executive functions, working memory, attention, control, judgment and decision-making, functions related to perisylvian and prefrontal areas are also evaluated.

1.2.2 Parietal lobe

The primary somatosensory cortex is located posterior to the primary motor cortex and, if necessary, it is possible to resect it without significant alterations in the sensory function, since other association areas can supply its function. However, the thalamocortical radiation must be preserved, representing the anterior limit of resection of parietal lesions [22–24].

The cortical region of the inferior parietal lobe, the supramarginal and angular gyrus, affect language in the dominant hemisphere and spatial awareness in the non-dominant hemisphere. Writing and calculation tests should be done to avoid iatrogenic Gertsman's syndrome. In the subcortical region of the dominant inferior parietal lobe (Geschwind territory), there are continuity of the pathways that communicate Broca's area (inferior frontal cortex) with Wernicke's area (posterior temporal cortex), the AF and SLF, therefore the stimulation of these areas can cause paraphasia and alteration in the production of language [22, 25].

1.2.3 Temporal lobe

In the temporal cortex, the main function to identify is language, especially in lesions of the dominant hemisphere. The posterior limit of a temporal pole resection is the arcuate fasciculus, which when stimulated causes paraphasia. Other temporal cortical and subcortical functions are visual recognition and dependent language, which is assessed with picture recognition. Likewise, temporary optic radiation should be evaluated in periventricular lesions in this region, in order to avoid postsurgical hemianopia [23].

1.2.4 Occipital lobe

The primary visual cortex is the main area to be explored, which when stimulated can produce phosphenes, blurred vision, visual hallucinations, and scotomas. Regarding the subcortical mapping, the final portion of the IFOF can produce alteration in the recognition and conceptualization of objects, so semantic paraphasia can be found [22, 23].

1.2.5 Insular lobe

The insular cortex and its corresponding subcortical tracts are considered unresectable, since they represent an important anatomical seat of essential functions of sensory, motor, limbic, vestibular and language integration. It is explored using a picture naming test [22, 26].

In a report, Ius et al., were able to identify sites considered unresectable after cortical mapping and resection of the lesion; in the dominant hemisphere the primary sensory and motor areas for the upper and lower extremities, the ventral premotor cortex, Wernicke's area in the posterior part of the superior temporal gyrus, and the supramarginal and angular gyrus; while in the non-dominant hemisphere the primary motor and sensory cortex and the angular gyrus. In certain cases it was possible to excise the rest of the association areas under the principle of maximum resection without greatly affecting the function [20–22]. Likewise, regarding the tracts, the following were considered unresectable: the cortico-spinal tract, posterior limit in patients with frontal lesion; thalamic-cortical radiations, anterior limit in patients with parietal lesions; the stratum sagittale, medial border of temporo-parietal lesions; anterior part of IFOF and perisylvian network [21, 22].

1.3 Brain lesions affecting the eloquent areas and surgical criteria

In general, neoplastic intracranial lesions can displace or invade brain structures. The first group of lesions are not usually candidates for awake resection, since the symptoms are produced by the effect of mass on the cortex and tracts, but their resection does not involve functional areas. Unlike the second group of neoplasms that can infiltrate or even originate in functional areas, and whose resection without the appropriate quality of life approach, can have unacceptable consequences for the functioning of patients. Also, since the patient should be comfortable as much as possible for resection of the lesions, the awake and cortical mapping approaches usually involve convexity or superficial, intra-axial, supratentorial lesions [1, 27].

In a review of several reported series of awake cortical mapping, gliomas are the neoplasms that are most frequently approached by this technique, up to 60%. High-grade astrocytomas such as OMS GIV glioblastoma is the most frequent glioma reported, followed by oligodendrogliomas, oligoastrocytomas, and low-grade astrocytomas [2, 28, 29]. The second group in frequency are brain metastases, mainly pulmonary and mammary origin. Finally, non-neoplastic lesions such as cavernous angiomas are usually reported as accessible lesions using this technique [30].

Although it is true that all the lesions described in the previous paragraph benefit from a wide resection, at present special emphasis has been placed in low-grade gliomas since these are lesions that usually occur in young adults, and it migrates through white matter tracts at an average rate of 4 mm/year [23, 31]. This raises new paradigms in which a supramarginal resection has been proposed even at the cost of function, hoping that brain plasticity in young patients improves the prognosis and quality of life in the long term [32].

1.3.1 Surgical criteria

The main criteria that are considered in neurosurgery to determine that a patient is considered for this type of procedure can be consulted in **Figure 4** in the form of a flow chart. Some of the most important criteria will be mentioned below according to the purpose of this chapter:

- a. The lesion should be located intra-axial (typical of the brain parenchyma), in a brain region that implies a high risk of post-surgical neurological and/or cognitive alterations. Generally, cortical and/or subcortical sensorimotor and peri-insular regions of the dominant hemisphere. However, other “highly specialized areas” should be considered according to the profession of each patient.
- b. In relation to the radiological characteristics of the tumor, ideally with little cerebral edema, without significant midline deviation.

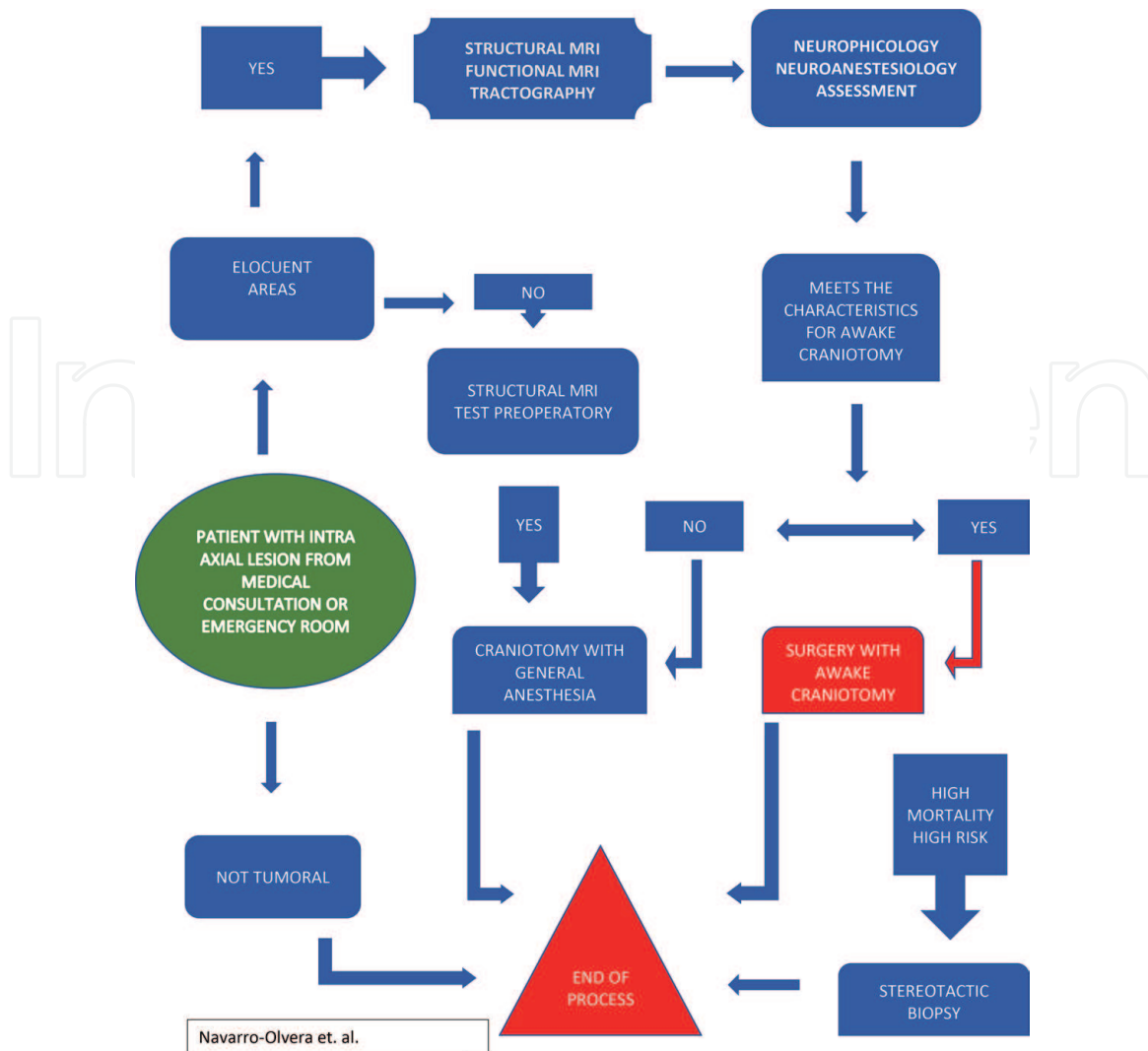


Figure 4. Diagram showing the flow of neurosurgical conditions that must be considered to determine that a patient is a candidate for awake surgery (red line). Patient admitted to neurosurgery, from the outpatient or emergency department with an intra-axial lesion, located in a highly specialized area. Candidate for structural, functional and tractography MRI. Neuropsychological assessment confirmed the possibility of surgery with a conscious patient. Surgery is scheduled with a navigation method for resection of the lesion.

- c. Degree of malignancy. Previously it was considered that the tumor should be low grade (histologically) since having a good survival prognosis, the benefit of keeping it neurologically intact was essential. However, nowadays it is currently considered that it should also be for patients with a high-grade, to promote quality of life.
- d. Patient can decide to accept the procedure and agree to collaborate once he knows the type of surgery that is proposed.
- e. Patient with no history of anxiety or impulsivity disorder because these may be exacerbated during surgery (e.g. refusing to cooperate or presenting psychogenic symptoms that make evaluation difficult) (Table 2).

1.4 Pre-operative evaluation

Once the patient has been selected for resection of the lesion with cortical mapping, extension studies should be carried out to bring us more evidence regarding the patient and their environment through neuropsychological and

neuro-anesthesiology assessment. In addition, to plan the intraoperative mapping, it is advisable to perform:

- a. Diffusion tensor tractography (DTI): identifies the main tracts of white fibers (corticospinal, superior longitudinal fasciculus, arcuate fasciculus, uncinate fasciculus, inferior orbitofrontal fasciculus, optic pathways) their location and infiltration or displace. However, the variability between imaging and the effect of medical treatment on the injury and associated vasogenic edema must be taken into consideration.
- b. Functional MRI: it helps to locate functional cortical areas through dependent sequences of blood oxygenation, which detects the increase in cerebral perfusion to certain areas when specific tasks are performed. The most studied paradigms are motor, sensory and speech (**Vignette 2**).

Vignette 2. Functional Magnetic Resonance (fMRI)

The functional Magnetic Resonance images are based on the changes in the oxygen levels in the blood related to an activity by the subject. It is an indirect measure of brain functionality since the equipment detects changes in signal intensity caused by vascular changes (demand for oxygen supply through the blood). Since the construction of the images depends on the use of complex mathematical algorithms, it is not possible to completely eliminate the noise sources that may occur, causing false positives, that is, activations in some brain region that are not real.

Prior Concerns	Current Solutions
Significant mass effect (>2-cm midline shift) despite preoperative diuretics & steroid	Staged internal debulking (asleep) using functional imaging (MEG/MSI) followed by reoperation w/ awake mapping or LMA
Obese patient (BMI >30)/obstructive apnea	LMA before & after mapping (limits subcortical mapping during resection if LMA is used)
Psychiatric history/emotional instability	Treated mood disorders no longer a contraindication
Age (yrs)	
>10	Awake
<10	2-stage procedure w/ implanted grid
Intraop seizures	Iced Ringers solution, propofol IV 6 inches from vein
Smoker	Cough suppressants w/ or w/o light sedation
Intraop nausea	Preop medication w/ antiemetic drugs (ondansetron hydrochloride, scopolamine) & high-dose dexamethasone (10 mg)
Reop (dural scar)	Focused craniotomy w/ negative mapping is acceptable
Severely impaired preoperative function*	Attempt to improve function w/ up to 5 days of preoperative high-dose steroids w/ or w/o diuretics
Tumor location presumed to be w/in functional cortical or subcortical pathways on preop imaging	The decision to offer surgery is not made based on preop anatomical or functional imaging (attempt is always made to map, identify, & preserve functional sites).

BMI = body mass index; IV = intravenous; MEG = magnetoencephalography; MSI = magnetic source imaging. *Motor function <2/5 or baseline naming/reading errors.
 From: Hervey-Jumper SL, Li J, Lau D, Molinaro AM, Perry DW, Meng L, et al. Awake craniotomy to maximize glioma resection: Methods and technical nuances over a 27-year period. *J Neurosurg* 2015;123:325–39.

Table 2.
Relative contraindications and solutions for awake craniotomy patients.

In the same way, false positives can occur due to the pathology of the brain tissue itself due to the pathological vasculature.

It is currently one of the most common methods in cognitive neurosciences due to its safety in healthy subjects.

Figure 5 shows motor paradigm during evaluation of a patient with a supratentorial glioma.

Other functional extension studies such as positron emission tomography (PET) or magnetoencephalography allow planning the procedure but none of them is superior to intraoperative cortical mapping, which is considered the gold standard.

1.5 Anesthetic management

1.5.1 Neuroanesthetic perioperative management

Benefits of awake craniotomy are greater resection of the lesion, with improvement in survival, while the damage to the eloquent cortex, which generates postoperative neurological dysfunction, is minimized. Other advantages include shorter hospitalization times, hence a reduction in care costs, and a decrease in the incidence of postoperative complications.

The term “awake craniotomy” is misleading as the patient is not fully awake during the entire procedure. The most painful moments of surgery require different levels of sedation or anesthesia, nonetheless, patient is fully awake while mapping or during resection [33].

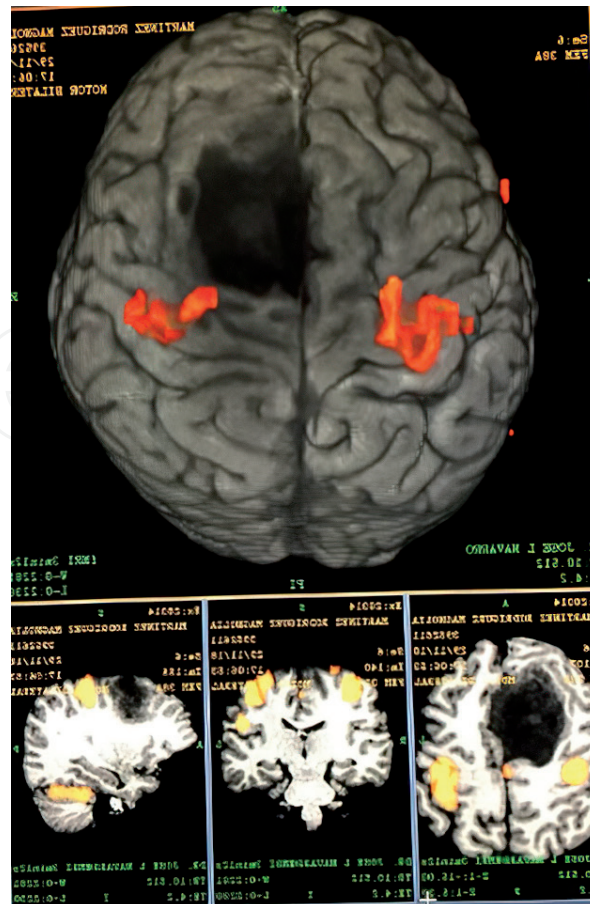


Figure 5.
Functional MRI with motor paradigm.

1.5.2 Preoperative evaluation

A very important aspect in an awake craniotomy is the adequate selection and full preparation of the patient by a multidisciplinary team in order to avoid intraoperative failures [34].

All patients should have consultations with the neurosurgeon and neuroanesthesiologist to assess whether the patient is a good candidate for this technique (see Table 3) and to prepare the patient for the procedure. This includes a complete evaluation of patient's comorbidities, which must be optimized before surgery, in or Patients in whom a difficult airway is anticipated may have problems during the intraoperative period that possess the neuroanesthesiologist to a very difficult airway scenario. Children are not psychologically fit to undergo this procedure although individual development of each child must be considered.

Preoperative evaluation includes getting detailed information from the patient, in turn the patient must know what to expect and know the risks inherent to anesthesia. Usually this includes verbal and written informed consent [34, 35].

Pre-operative consultations provide an invaluable opportunity for the multidisciplinary team to create a rapport with the patient and therefore encourage trust.

1.5.3 Operating room preparation

The layout of the operating room and the position of the patient must be taken into account. The ability to communicate with the patient must be maintained at all times and access to the patient during adverse events is of equal importance.

As in every surgery, the operating table should be as comfortable as possible, since the patient is going to be lying in the same position for several hours. The operating room temperature should be comfortable for the patient, and the number of people should be minimized to reduce unnecessary noise and reduce patient anxiety [36].

The position of the patient is determined by the location of the lesion. (Figure 6) This is usually a lateral or supine position, in the case of occipital lesions and evaluation of the visual cortex, a sitting position may be used. In either position, it's important that when patient is fully awake during mapping, he can see and communicate with the neuroanesthesiologist or neuropsychologist. Sterile drapes used should not invade the patient's face, as this may cause claustrophobia and difficulty in communicating [37].

Absolute
Patient refusal
Inability to lay still for any length of time
Inability to co-operate, for example confusion
Mental retardation
Anticipated difficult intubation
Obstructive sleep apnea
Children <10 years
Relative
Patient cough
Learning difficulties
Inability to lay flat
Patient anxiety
Language barriers
Obese patients

Table 3.
Anesthetic contraindications.

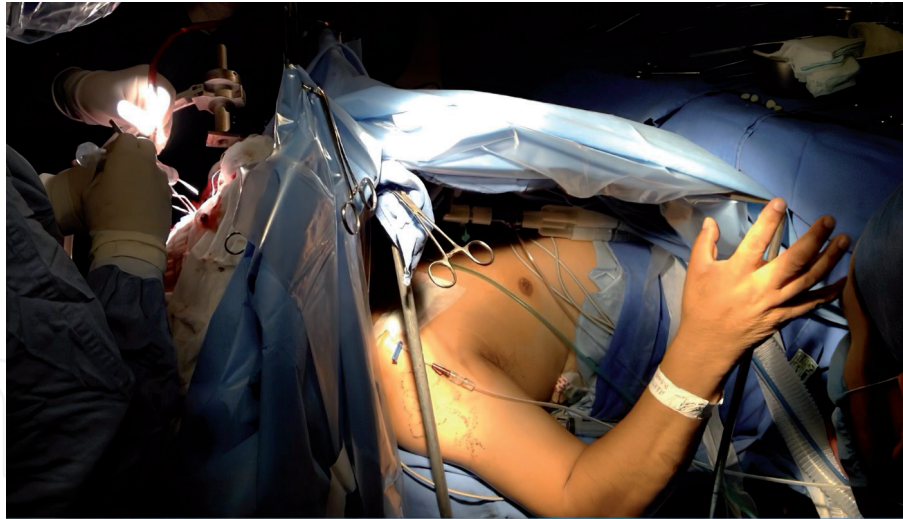

Figure 6.
Position of the patient and the evaluator during the surgical procedure to carry out the neuropsychological and movement evaluation.

1.5.4 Anesthetic generalities

The choice of the anesthetic agent even within a preferred anesthetic technique varies, but the general principles are common to all of them; the need to maximize patient comfort, prevention of nausea and vomiting that may increase intracranial pressure, the need for hemodynamic stability, and the use of short-acting drugs that allow acute control of the patient's level of consciousness.

Premedication is not common, but reflux prophylaxis should be considered, patients should continue their prescribed medication such as steroids, antiepileptic drugs, or antihypertensives. Prophylactic antibiotics and usually one or more antiemetics are administered in every patient before the incision. The most common options are ondansetron and dexamethasone. Dexamethasone can also be used to diminish brain edema during the operation.

Standard anesthetic monitoring is used. Depth of anesthesia monitors, for example Bispectral Index Monitoring (BIS™), are sometimes used to reduce the dose of anesthetic agents administered and thus time required for patient emergence and cortical mapping cooperation [37, 38].

Capnography under general anesthesia is considered basic monitoring, but carbon dioxide monitoring for sedated or awake patients during mapping is also a common practice. Although carbon dioxide levels may be inaccurate, it is used to confirm ventilation [39].

A large-bore intravenous access is obtained and most neuroanesthesiologist place also an arterial line, usually sedated or asleep. The use of other forms of monitoring is variable.

1.5.5 Anesthetic techniques

There is not a recognized consensus on the best anesthetic approach for awake craniotomy. This is because neuroanesthesiologists vary the technique depending on neurosurgeon's preferences, pathology, duration of the surgery and patient's factors.

There are two dominant anesthetic approaches to solving this problem: monitored anesthetic care (MAC) and asleep-awake-asleep (AAA).

The goal of the MAC approach is to decrease the sedative dose to avoid an abrupt transition from sleep to awakening, which can lead to hypoactive or hyperactive delirium upon emergence and to decrease the reliability of mapping.

MAC technique for awake craniotomy involves spontaneous ventilation and low doses of sedative drugs [38].

The AAA technique involves induction of general anesthesia and control of the airway with a supraglottic device such as laryngeal mask airway (LMA) or intubation. When neurocognitive testing and intraoperative mapping need to be started, anesthetic drugs are reduced or stopped, and the device is removed from the airway. Once resection of the lesion is complete, return to general anesthesia and reintroduction of the airway device is done. Advantages of this technique include the ability to control ventilation and thus control carbon dioxide concentrations and prevent airway obstruction and hypoventilation. It also facilitates a greater anesthetic depth during the most painful moments of surgery. Anesthetic drugs used for this technique are varied, but propofol and remifentanyl TCI are the most common, followed by the use of a volatile anesthetic and remifentanyl infusion. The use of dexmedetomidine has also been reported with this technique, and it's generally used during the awake stage of surgery and closure [39].

1.5.6 Scalp block

The cornerstone of awake craniotomy analgesia is regional scalp block along with infiltration of the incision line. A scalp block also provides hemodynamic stability and decreases the stress response to painful stimuli [40].

The scalp block technique includes infiltration of local anesthetic into seven nerves on each side. This is an anatomical block and not just a ring block. A ring block will require large volumes of local anesthetic, increase the risk of toxicity, and will not provide deep anesthesia to the temporal fascia.

Most neuroanesthesiologists place a bilateral scalp block before pinning of the head with Mayfield skull clamp. Occasionally, a scalp blocker is not applied and relies on local anesthetic infiltration by the surgeon.

The total dose of local anesthetic with and without epinephrine must be calculated individually for each patient. Studies have shown that the rise in plasma concentration of levobupivacaine and ropivacaine is faster compared to other local anesthetics and similar in all patients. Despite the quick rise in plasma levels, there were no signs of cardiovascular or central nervous system toxicity. The use of bupivacaine, levobupivacaine, and ropivacaine in varying concentrations with and without epinephrine has been described for use in a blockage of the scalp. The addition of epinephrine, usually 1:200,000, increases the total amount of local anesthetic that can be used, decreases localized bleeding, and maximizes duration. However, systemic absorption may cause tachycardia and hypertension, and intraarterial injection into the superficial temporal artery is possible when the auriculotemporal nerve is blocked [37].

1.5.7 Adverse events

Awake craniotomy is generally a well-tolerated procedure with a low conversion rate to general anesthesia and a low complication rate. One of the most common complications is intolerance of the patient to the procedure, often due to urinary catheter or prolonged positioning and intraoperative seizures.

Seizures, focal or generalized, are more likely to occur during cortical mapping. The frequency of seizures during awake craniotomy ranges widely from 2.9–54%. These are treated by irrigating the brain tissue with ice-cold saline, they usually stop with this treatment, but sometimes benzodiazepines, antiepileptic drugs or re-sedation with airway control are required [41].

The efficacy of prevention of intraoperative seizures with anticonvulsants remains doubtful. The latest systematic review on this topic revealed no benefit of prophylaxis. However, it should be noted that most of seizure prevention trials are based on the use of phenytoin or valproate. On the other hand, there are new data that support the superiority of levetiracetam in the prophylaxis of seizures. However, there are insufficient data to recommend its routine use in awake craniotomy.

An emergency plan for airway control must be in place at all times and this can be challenging as the patient's head is fixed on the clamp and often away from the ventilator. Options include insertion of an LMA which may be easier than endotracheal intubation.

1.5.8 Closure and postoperative

Once resection is complete, patient may be re-sedated or re-anesthetized with reattachment of the airway device, even if in the lateral position. Dura, bone flap, and scalp are then closed, pins are removed, and patient is awakened.

If remifentanyl has been used, it can be given at low infusion rates to aid for a "soft" awakening and prevent coughing.

It is imperative that close neurological monitoring continues as postoperative hematomas may develop, especially in the first 6 h after operating. This may require an urgent evacuation of the clot.

After scalp block has worn off, systemic pain relief is used. The use of postoperative pain relief can be decreased in patients who have received a scalp block. Regular paracetamol and opioids are used.

1.6 Neuropsychological management

Some generalities of intraoperative neuropsychological evaluation will be mentioned in the light of new neurocognitive technological and theoretical tools that allow us to carry out current forms of evaluation, always outlined based on the objectives of the surgical plan of the transdisciplinary group of the treating physician, as well as the type of tumor, location and extension.

The selection of the methodology for the intraoperative neuropsychological evaluation is described in detail in accordance with the current literature on a recent vision of Functional Neurosurgery in brain tumors called hodology [19], which implies a radical change to the classical view on a rigid and exclusively cortical cerebral organization of brain functions. (**Vignette 3**) The advances that have occurred in recent decades on neurocognitive aspects in patients with brain tumors allow the more specific evaluation of some aspects of language, for example the name by visual confrontation has been a very important way of assessing an aspect of language in the operating room [9] but until recently attention has been paid to the type of stimuli that are presented and how to do it, that is, we currently know that the findings may be different if they are presented for the naming, an image or drawing in black and white compared to a color image with three-dimensional properties, in addition to the control of psycholinguistic variables of the words [13]. The same can be mentioned in other cognitive domains, for example the advance in the knowledge of the participation of subcortical structures in cognition, the participation of the right hemisphere in language at the narrative level, social cognition, brain reorganization in the recovery process, participation of the insula in cognitive aspects, to name a few [41].

Vignette 3 - Brain Hodotopy

This term refers to a current vision in functional neurosurgery in which the classic trend of localize functions in the cerebral cortex is changed by a concept called

hodological mechanism (from the Greek *hodos*, path or path) related to the cognitive alteration caused by affection in anatomical connectivity rather than a lesion in the cerebral cortex.

This approach conceives the Central Nervous System as a comprehensive system integrated by a plastic network made up of functional cortical epicenters connected by short and long fibers of white matter. Thus, brain functions are the result of the confluence of parallel information pathways, dynamically modulated in a widely distributed, interactive and multimodal circuit.

This view is of great relevance, especially in brain tumor neurosurgery due to the brain plasticity that is induced by the neoplasm itself. This phenomenon makes the dissociation between anatomy and functional delimitation especially valid, that is, to determine anatomically an area (for example the precentral gyrus) does not guarantee that it functionally corresponds to motor regions. This new perspective opens the possibility of contemplating the performance of surgical procedures in regions that were previously considered inoperable. Broca's area is an example of this new vision, since if it is considered inoperable, different brain mapping techniques such as cortical electrical stimulation can currently be used to functionally delimit this region through naming tasks. Broca's area is also a good example to show the brain plasticity that the hodological approach considers, since we frequently observe neoplasms in these regions with a patient without deficit (dynamic, not rigid system), and it is well known that in order to present an alteration compatible with Broca's aphasia, the lesion must include cortical and subcortical regions (cortical epicenters and connectome), since a lesion limited only to the cerebral cortex corresponding to Brodmann's area 44 and 45 is associated with a transitory alteration less severe.

Transoperatively evaluating a cognitive domain with all the theoretical complexity that we currently have can take a long time, bringing an apparent contradiction, since on the one hand we require time to assess details of the domains, however, during surgical procedures with the patient awake, only they have several seconds and in some cases minutes. This leads to apparently unrelated cognitive areas that will be evident in the postoperative period. To exemplify this, we can take the case of the famous patient HM, one of the best known cases in the history of modern neurosciences who was operated awake during the bilateral resection of hippocampal structures in 1953. At that time, it was only considered important to explore the understanding and expression of language, without considering the exploration of other cognitive domains, resulting in the tragic history of memory loss that we all know. Without devaluing the merit of surgery in the context of the time, this story teaches us that it is essential to carry out a broader neuropsychological evaluation in terms of cognitive domains, apparently little related to the intervened brain region, so that the consideration of the activities to perform during the intraoperative is essential in order to optimize the time and tasks to be performed.

Among the most important neuropsychological criteria is that the patient wishes to cooperate and his neurological and psychological condition allows it, that is, the patient must understand why the suggestion of this surgery modality so that he openly expresses that he wants awake modality, knowing that it can be stressful to a certain extent and that your participation is essential. A second important criterion is not to present alterations that may obstruct the intraoperative neuropsychological evaluation. In this sense, the patient could find conditions that allow him to have a functional daily life, however, it may be that for the surgical procedure it is not suitable, for example a tumor in prefrontal regions that could affect uninhibited behavior. This could be dangerous because the integrity of the patient could be compromised by refusing to participate during surgery. Another example could be the difficulty in understanding long sentences or marked slowness when carrying out the instructions. These examples show that, even though the patient understands

the importance of the procedure and shows the willingness to cooperate, it should be considered, since in the last example it could be determined that it would be enough to be able to carry out the monitoring of gross motor aspects, so it could be done.

An important aspect is to know, through anxiety, depression and impulsivity scales, the degree that the patient can manifest in the face of stress, since the procedure can facilitate the appearance of behaviors that could hardly be observed in daily life.

In our experience, awake surgery involves a series of stages prior to the intraoperative that the patient must undergo to guarantee a greater chance of success. That is, if it is true that success depends largely on what happens in the operating room, it is also true that a lot has to do with the preparation of the patient, the collection of neuropsychological and psychological data, and in some cases the family dynamics before the surgery, as it must be remembered that patient participation is essential, so that an inadequate preparation (eg, lack of understanding of the purpose of the procedure) could turn into limited cooperation and vulnerable to fatigue due to the small discomforts that could present.

In the same way, follow-up is important to guide the family and the patient about neuropsychological or personality changes that may occur, some of them may require neuropsychological intervention or orientation to primary caregivers.

The entire conventional neuropsychological clinical interview is conducted paying attention to traits or probable personality disorders, how to manage stress in the daily life and impulse management. It should be remembered that surgery can represent a time of stress in which the patient can behave differently from the way they do it in their daily life (explain with appropriate psychological terms that it can be psychologically unstructured), in addition to the use of medications that they could contribute for that moment. (If you are in stress, you can request to be put to sleep or decide not to cooperate, making the procedure considerably more difficult).

A conventional neuropsychological evaluation is performed. In brain tumors, large batteries are used in terms of functions, e.g. The Comprehensive Neuropsychological Exploration Program Test Barcelona completes and complementary tests.

One of the purposes is to detect qualitatively and quantitatively. All this to detect obvious or subtle alterations that the neoplasm is already causing and think about the possibility that these alterations are highlighted.

Psychological approach in which the patient's real expectations and fantasies must be detected. Anxiety and depression must be identified. Follow-up is encouraged for the next stages, gives an overview of what might happen if the tumor is malignant or non-malignant. This stage is mixed with the Psychological intervention and the intervention plan must begin here.

Other aspects that influence this stage are:

the carving explanation of the procedure, beginning, end, when waking up, when sleeping, when to sedate it, activities to perform, activities to perform, possible discomfort, procedure simulation, stereotactic frame simulation. As far as possible, visit the operating room from the outside, explanation of a video of a patient with a similar tumor.

1.6.1 Family involvement

This gives you a lot of neuropsychological material to ask questions during surgery, e.g. If so, a description of the coffee harvest can already be requested (since he is involved in the process in his place of origin). This constitutes a great deal of material to use in assessing spontaneous language.

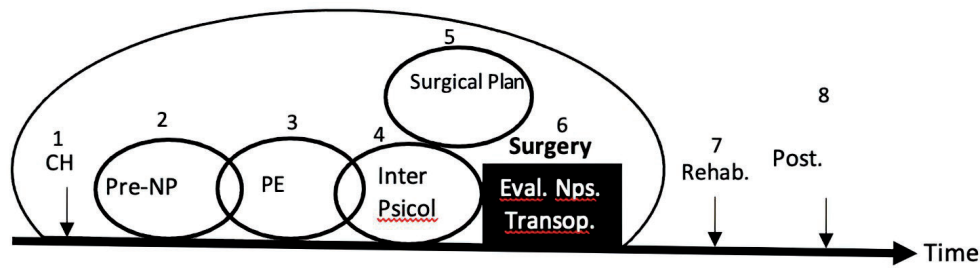


Figure 7.

General diagram (timeline) of the transdisciplinary treatment and location of the intraoperative neuropsychological evaluation. The steps prior to the neuropsychological assessment represented by interconnected circles represent the independence of each step, but the close relationship between them. CH: Clinical History, Pre-NP: Preoperative Neuropsychological Evaluation, PE: Psychoeducation, Inter Psicol - Psychological Intervention, Post: Postoperative neuropsychological follow-up, Rehab: Neuropsychological rehabilitation.

Activities are designed according to the neuropsychological profile and the surgical plan. This stage can be better understood in the section on the intraoperative neuropsychological evaluation plan.

Ecological evaluation plan, what the patient requires for her daily life.

Neuropsychological rehabilitation and orientation to the family on apparently permanent and transitory alterations, including personality changes.

Follow-up at 6 months and 1 year. **Figure 7.**

2. Conclusions

The most important objective of this surgical modality is the cognitive preservation and neurological function of the patient and at the same time achieving the greatest amount of tumor resection, that is, the removal of the greatest amount of brain tumor with the least amount of sequelae. This is especially valid for those patients who have a low-grade tumor with an adequate prognosis for life, recently also for those with a tumor with a higher grade of malignancy that will limit survival to several months. In both cases, the amount of pathological tissue that can be removed is of vital importance since the success of the rest of the complementary postsurgical treatments such as radio or chemotherapy depends largely on this.

The most serious intra-surgical complications include seizures, respiratory depression, air embolism, cerebral edema, and the cardiac trigeminal reflex. The total reported complication rate is about 16.5%, and in 6.4% of patients it is not possible to complete the mapping procedure.

The main causes of failure are the appearance of seizures and the loss of cooperation of the patient due to severe drowsiness, agitation, or the development of mixed dysphasia. Failed craniotomies are associated with a lower incidence of gross total resections, greater speech impairment after the procedure, and a longer hospital stay.

The application of awake craniotomy has continually evolved. The key to the success of this procedure is to pay attention to each of the components, such as careful patient selection, prior psychological preparation, building a solid relationship, ensuring the solid position of the patient, optimal regional anesthesia, the correct selection of agents and anesthetic technique, preparation and timely management of crises, and constant communication between group members.

IntechOpen

Author details

José Luis Navarro-Olvera^{1*}, Gustavo Parra-Romero¹,
Stephani Dalila Heres-Becerril³, David Trejo-Martínez², José D. Carrillo Ruiz¹,
Kleber Gonzalez Echeverría¹ and Gustavo Aguado-Carrillo¹

¹ Functional Neurosurgery, Stereotactic and Radiosurgery Department, Mexico
General Hospital “Dr. Eduardo Liceaga”, Mexico

² Neuropsychology Department, Mexico General Hospital “Dr. Eduardo Liceaga”,
Mexico

³ Neuroanesthesiology Department, Mexico General Hospital “Dr. Eduardo
Liceaga”, Mexico

*Address all correspondence to: luiginavarro97@hotmail.com

IntechOpen

© 2021 The Author(s). Licensee IntechOpen. This chapter is distributed under the terms of the Creative Commons Attribution License (<http://creativecommons.org/licenses/by/3.0>), which permits unrestricted use, distribution, and reproduction in any medium, provided the original work is properly cited. 

References

- [1] Ibrahim GM, Bernstein M. Awake craniotomy for supratentorial gliomas: why, when and how? *CNS Oncol* 2012;1:71-83. <https://doi.org/10.2217/cns.12.1>.
- [2] Sacko O, Lauwers-Cances V, Brauge D, Sesay M, Brenner A, Roux FE. Awake craniotomy vs surgery under general anesthesia for resection of supratentorial lesions. *Neurosurgery* 2011;68:1192-8. <https://doi.org/10.1227/NEU.0b013e31820c02a3>.
- [3] Lu VM, Phan K, Rovin RA. Comparison of operative outcomes of eloquent glioma resection performed under awake versus general anesthesia: A systematic review and meta-analysis. *Clin Neurol Neurosurg* 2018;169:121-7. <https://doi.org/10.1016/j.clineuro.2018.04.011>.
- [4] Bulsara KR, Johnson J, Villavicencio AT. Improvements in brain tumor surgery: the modern history of awake craniotomies. *Neurosurg Focus* 2005;18:5-7. <https://doi.org/10.3171/foc.2005.18.4.6>.
- [5] Kobayakov GL, Lubnin AY, Kulikov AS, Gavrilov AG, Goryaynov SA, Poddubskiy AA, et al. Awake craniotomy. *Zh Vopr Neurokhir Im N N Burdenko* 2016;80:107-16. <https://doi.org/10.17116/engneuro201680188-96>.
- [6] July J, Manninen P, Lai J, Yao Z, Bernstein M. The history of awake craniotomy for brain tumor and its spread into Asia. *Surg Neurol* 2009;71:621-4. <https://doi.org/10.1016/j.surneu.2007.12.022>.
- [7] Surbeck W, Hildebrandt G, Duffau H. The evolution of brain surgery on awake patients. *Acta Neurochir (Wien)* 2015;157:77-84. <https://doi.org/10.1007/s00701-014-2249-8>.
- [8] De Witt Hamer PC, Robles SG, Zwinderman AH, Duffau H, Berger MS. Impact of intraoperative stimulation brain mapping on glioma surgery outcome: A meta-analysis. *J Clin Oncol* 2012;30:2559-65. <https://doi.org/10.1200/JCO.2011.38.4818>.
- [9] Haglund M, Berger MS, Shamseldin M, Lettich E, Ojemann G. Cortical Localization of Temporal Lobe Language Sites in Patients with Gliomas. Clinical Study. *Neurosurgery* 1994;34:1689-99.
- [10] Duffau H. Contribution of cortical and subcortical electrostimulation in brain glioma surgery: Methodological and functional considerations. *Neurophysiol Clin* 2007;37:373-82. <https://doi.org/10.1016/j.neucli.2007.09.003>.
- [11] Duffau H. Stimulation Mapping of Myelinated Tracts in Awake Patients. *Brain Plast* 2016;2:99-113. <https://doi.org/10.3233/bpl-160027>.
- [12] Buckingham HW. The Marc Dax (1770-1837)/Paul Broca (1824-1880) controversy over priority in science: Left hemisphere specificity for seat of articulate language and for lesions that cause aphemia. *Clin Linguist Phonetics* 2006;20:613-9. <https://doi.org/10.1080/02699200500266703>.
- [13] Tate MC, Herbet G, Moritz-Gasser S, Tate JE, Duffau H. Probabilistic map of critical functional regions of the human cerebral cortex: Broca's area revisited. *Brain* 2014;137:2773-82. <https://doi.org/10.1093/brain/awu168>.
- [14] Iwata M. Anatomical Error of Pierre Marie's "zone Lenticulaire." *Front Neurol Neurosci* 2019;44:23-9. <https://doi.org/10.1159/000494948>.
- [15] Rahimpour S, Haglund MM, Friedman AH, Duffau H. History

of awake mapping and speech and language localization: From modules to networks. *Neurosurg Focus* 2019;47:7-12. <https://doi.org/10.3171/2019.7.FOCUS19347>.

[16] Nasios G, Dardiotis E, Messinis L. From Broca and Wernicke to the Neuromodulation Era: Insights of Brain Language Networks for Neurorehabilitation. *Behav Neurol* 2019;1-10. <https://doi.org/10.1155/2019/9894571>.

[17] Damasio AR. Brain and language: what a difference a decade makes. *Curr Opin Neurol* 1997;10:177-8.

[18] Damasio H, Grabowski TJ, Tranel D, Ponto LLB, Hichwa RD, Damasio AR. Neural correlates of naming actions and of naming spatial relations. *Neuroimage* 2001;13:1053-64. <https://doi.org/10.1006/nimg.2001.0775>.

[19] De Benedictis A, Duffau H. Brain hodotopy: From esoteric concept to practical surgical applications. *Neurosurgery* 2011;68:1709-23. <https://doi.org/10.1227/NEU.0b013e3182124690>.

[20] Duffau H. Hodotopy, neuroplasticity and diffuse gliomas. *Neurochirurgie* 2017;63:259-65. <https://doi.org/10.1016/j.neuchi.2016.12.001>.

[21] Ius T, Angelini E, Thiebaut de Schotten M, Mandonnet E, Duffau H. Evidence for potentials and limitations of brain plasticity using an atlas of functional resectability of WHO grade II gliomas: Towards a “minimal common brain.” *Neuroimage* 2011;56:992-1000. <https://doi.org/10.1016/j.neuroimage.2011.03.022>.

[22] Coello AF, Moritz-Gasser S, Martino J, Martinoni M, Matsuda R, Duffau H. Selection of intraoperative tasks for awake mapping based on relationships between tumor location and functional networks: A review. *J*

Neurosurg 2013;119:1380-94. <https://doi.org/10.3171/2013.6.JNS122470>.

[23] Duffau H. New concepts in surgery of WHO grade II gliomas: Functional brain mapping, connectionism and plasticity - A review. *J Neurooncol* 2006;79:77-115. <https://doi.org/10.1007/s11060-005-9109-6>.

[24] Duffau H. Stimulation mapping of white matter tracts to study brain functional connectivity. *Nat Rev Neurol* 2015;11:255-65. <https://doi.org/10.1038/nrneurol.2015.51>.

[25] Vanacôr CN, Isolan GR, Yu YH, Telles JPM, Oberman DZ, Rabelo NN, et al. Microsurgical anatomy of language. *Clin Anat* 2020;1-15. <https://doi.org/10.1002/ca.23681>.

[26] Duffau H, Capelle L, Lopes M, Faillot T, Sichez JP, Fohanno D. The insular lobe: Physiopathological and surgical considerations. *Neurosurgery* 2000;47:801-11. <https://doi.org/10.1097/00006123-200010000-00001>.

[27] Dziedzic T, Bernstein M. Awake craniotomy for brain tumor: Indications, technique and benefits. *Expert Rev Neurother* 2014;14:1405-15. <https://doi.org/10.1586/14737175.2014.979793>.

[28] Brown T, Shah AH, Bregy A, Shah NH, Thambuswamy M, Barbarite E, et al. Awake Craniotomy for Brain Tumor Resection. *J Neurosurg Anesthesiol* 2013;25:240-7. <https://doi.org/10.1097/ana.0b013e318290c230>.

[29] Hervey-Jumper SL, Li J, Lau D, Molinaro AM, Perry DW, Meng L, et al. Awake craniotomy to maximize glioma resection: Methods and technical nuances over a 27-year period. *J Neurosurg* 2015;123:325-39. <https://doi.org/10.3171/2014.10.JNS141520>.

[30] Chua TH, See AAQ, Ang BT, King NKK. Awake Craniotomy for

Resection of Brain Metastases: A Systematic Review. *World Neurosurg* 2018;120:e1128-35. <https://doi.org/10.1016/j.wneu.2018.08.243>.

[31] Duffau H. Diffuse low-grade glioma, oncological outcome and quality of life: A surgical perspective. *Curr Opin Oncol* 2018;30:383-9. <https://doi.org/10.1097/CCO.0000000000000483>.

[32] Duffau H. Higher-Order Surgical Questions for Diffuse Low-Grade Gliomas: Supramaximal Resection, Neuroplasticity, and Screening. *Neurosurg Clin N Am* 2019;30:119-28. <https://doi.org/10.1016/j.nec.2018.08.009>.

[33] Akay A, Islekel S. Awake craniotomy procedure: Its effects on neurological morbidity and recommendations. *Turk Neurosurg* 2018;28:186-92. <https://doi.org/10.5137/1019-5149.JTN.19391-16.1>.

[34] Kulikov A, Lubnin A. Anesthesia for awake craniotomy. *Curr Opin Anaesthesiol* 2018;31:506-10. <https://doi.org/10.1097/ACO.0000000000000625>.

[35] Eseonu CI, ReFaey K, Garcia O, John A, Quiñones-Hinojosa A, Tripathi P. Awake Craniotomy Anesthesia: A Comparison of the Monitored Anesthesia Care and Asleep-Awake-Asleep Techniques. *World Neurosurg* 2017;104:679-86. <https://doi.org/10.1016/j.wneu.2017.05.053>.

[36] Osborn I, Sebeo J. "Scalp block" during craniotomy: A classic technique revisited. *J Neurosurg Anesthesiol* 2010;22:187-94. <https://doi.org/10.1097/ANA.0b013e3181d48846>.

[37] Özlü O. Anaesthesiologist's approach to awake craniotomy. *Turk Anesteziyoloji ve Reanimasyon Dern Derg* 2018;46:250-6. <https://doi.org/10.5152/TJAR.2018.56255>.

[38] Stevanovic A, Rossaint R, Veldeman M, Bilotta F, Coburn M. Anaesthesia management for awake craniotomy: Systematic review and meta-analysis. *PLoS One* 2016;11:12-23. <https://doi.org/10.1371/journal.pone.0156448>.

[39] Jones H, Smith M. Awake craniotomy. *Contin Educ Anaesthesia, Crit Care Pain* 2004;4:189-92. <https://doi.org/10.1093/bjaceaccp/mkh051>.

[40] Hill CS, Severgnini F, McKintosh E. How I do it: Awake craniotomy. *Acta Neurochir (Wien)* 2017;159:173-6. <https://doi.org/10.1007/s00701-016-3021-z>.

[41] Duffau H. The error of Broca: From the traditional localizationist concept to a connectomal anatomy of human brain. *J Chem Neuroanat* 2018;89:73-81. <https://doi.org/10.1016/j.jchemneu.2017.04.003>.