

We are IntechOpen, the world's leading publisher of Open Access books Built by scientists, for scientists

5,600

Open access books available

137,000

International authors and editors

170M

Downloads

Our authors are among the

154

Countries delivered to

TOP 1%

most cited scientists

12.2%

Contributors from top 500 universities



WEB OF SCIENCE™

Selection of our books indexed in the Book Citation Index
in Web of Science™ Core Collection (BKCI)

Interested in publishing with us?
Contact book.department@intechopen.com

Numbers displayed above are based on latest data collected.
For more information visit www.intechopen.com



Chapter

The Influence of Sagittal Plane Spine Alignment on Neurophysiology and Sensorimotor Control Measures: Optimization of Function through Structural Correction

Paul A. Oakley, Ibrahim M. Moustafa and Deed E. Harrison

Abstract

Increasingly, there is more attention being directed to the role that full spine sagittal alignment plays in causing or exacerbating a variety of musculoskeletal disorders. Similarly, spinal displacements, termed subluxation, are thought to cause dysfunctions in the entire neuromusculoskeletal system that may lead to altered neurophysiological function, abnormal sensorimotor control, and altered autonomic nervous system function. Abnormalities in neutral upright spine alignment (sagittal translation or flexion deformities) are known to increase mechanical loads (stresses and strains) on the central nervous system. These increased mechanical loads may subtly or overtly impair neurophysiological function as measured with evoked potentials in terms of latency and amplitudes of potentials. Proprioceptive afferentation from spine ligaments, muscles and discs are considered a major component of sensorimotor control. The voluminous mechanoreceptors in spinal muscles, ligaments, and discs plays an intimate role, providing the necessary neurophysiological input in a feed forward and feedback system for sensorimotor control via connections to the vestibular, visual and central nervous systems. Of particular interest, a network of neurophysiological connections between spine mechanoreceptors and the sympathetic nervous system has been documented. This chapter explores the hypothesis and evidence that restoring normal posture and spine alignment has important influences on neurophysiology, sensorimotor control and autonomic nervous system functionality. There is limited but high-quality research identifying that sagittal spine alignment restoration plays an important role in improving neurophysiology, sensorimotor control, and autonomic nervous system function. Accordingly, in the current chapter, we review this work in hopes of stimulating further investigations into structural rehabilitation of the spine and posture.

Keywords: spinal deformity, sensorimotor control, sagittal plane alignment, sympathetic skin resistance, dermatomal somatosensory evoked potentials, spine rehabilitation

1. Introduction

A normal spine alignment including coronal and sagittal balance is essential for optimal biomechanical function [1–7]. The spine, which allows for simultaneous stability and mobility, also has the inherent role of housing and protecting the brain and spinal cord. The alignment of the spine is critical in the context of allowing normal function of the central nervous system (CNS); that is, by not impeding its function by various loading mechanisms (i.e. overstretching the nervous tissues) [8, 9]. Clinical trials [10–16] and case reports [17–25] have demonstrated that corrections in patient posture have resulted in relief of neurological symptoms including for example, cervical spondylotic and discogenic radiculopathy, cervical spondylotic myelopathy (CSM), lumbosacral discogenic radiculopathy, trigeminal neuralgia (TN), dystonia, Parkinson's disease (PD), carpal tunnel syndrome (CTS), and Tourette's syndrome (TS). Although the precise mechanisms underlying improved neurological function in patients having improved postural alignment are not fully understood, they are thought to lie in the biomechanics of the CNS and in normalization of load sharing across tissues innervated by mechanoreceptors which are integral in sensorimotor control through somatosensory potentials.

In 1960, a monograph was published by Alf Breig documenting for the first time, the most comprehensive illustrative demonstrations of the biomechanics of the central nervous system (CNS) [8]. This seminal work laid the groundwork for the comprehensive understanding of how spine movement affects the CNS; that is, how physiologic deformation of the cord and brainstem simultaneously accompanies normal postural movements of the spine (i.e. 'neurodynamics'). In 1978, Breig published a second book expanding on the concepts outlined in 1960, and focused on 'adverse mechanical tension' in the CNS and how this produces common neurological symptoms and signs [9]. An exciting development by Breig was his invention of the 'cervicordodesis' surgical procedure that increased the cervical lordosis and prevented cervical flexion to relieve tension within the cord, brainstem and nerve roots demonstrating dramatic improvements of neurological disorders including nerve root compression syndromes, TN, multiple sclerosis (MS) and other neuromusculoskeletal conditions [26].

A second prevailing theory on how normalization of spine/posture alignment can dramatically alter patient pain, disability, function, and neurophysiology is through cervical spine sensory afferent input (so called afferentation) and its influence on the motor system termed sensorimotor control. As a result of activation of mechanoreceptors contained in the various ligaments, discs, muscles and skin, changes in spine position-alignment has a major influence on motor control [27]. Intimate connections exist between afferent input (from the proprioceptive, visual and vestibular systems) and stable upright postures of the head and neck [28]. The mechanoreceptors in the cervical spine soft tissues provide necessary neurophysiological input in a feed forward and feedback system for sensorimotor control via connections to the vestibular, visual and central nervous systems [29]. Furthermore, a complex network of neurophysiological connections between cervical spine mechanoreceptors and the sympathetic nervous system exists [30–32]. Though the effects of autonomic system activity on musculoskeletal function has been extensively studied, there is a paucity of research demonstrating that the autonomic nervous system is intimately responsive to changes in the afferent articular input due to spine joint dysfunction [33]. Alterations in afferent articular input driven by spine joint aberrant movement (altered kinematics) and subtle or overt tissue damage is generally referred to as 'dysafferentation' in the literature. The assumption that restoring normal posture and cervical spine alignment is important for a better afferentation process and improved autonomic nervous system function has some preliminary evidence in the recent literature [10, 34].

Today there are non-surgical evidence-based techniques known to improve posture and spine alignment; in essence to accomplish what Breig was able to do, only without surgery (e.g. increase cervical lordosis). One of these methods is Chiropractic BioPhysics[®] (CBP[®]) technique which is a full-spine and posture treatment that utilizes mirror image[®] (i.e. 'corrective') exercises, adjustments and spinal traction procedures to restore normal spine alignment [35–39]. Due to the implicit interconnectedness of spine alignment and neurologic function, these methods are proving to be particularly effective in treating patients with neurological and sensorimotor control disorders, where perhaps unknowingly, poor spine alignment is a causative factor in patients suffering from neurologic ailments in which their symptoms are exacerbated and/or directly caused by the adverse nerve tensions placed upon them and by dysafferentation caused by spine and postural deviations (i.e. adult spinal deformity/subluxation).

This chapter reviews the Harrison normal spinal model [40–47] that is used to assess a patient's spine alignment as compared to the normal/ideal position (i.e. gold standard), how the central nervous system is housed in and biomechanically functions within the skeletal structure under normal and pathologic conditions, including mechanisms for neurologic symptom generation under pathologic biomechanical tensions, and altered sensorimotor control from dysafferentation driven by altered load sharing and spine kinematics. Simultaneously, the CBP structural rehabilitation approach to realigning the spine and postural position in order to treat patients who present with spinal subluxation that is suspected to be pathognomonic for their pain, disability, and generalized neurologic sensorimotor disorders will be a main theme.

2. The Harrison normal spinal model

Any contemporary discussion about the normal/ideal human spinal configuration is regarding its precise orientation (i.e. precise shape of the different spinal regions). Although many research groups have attempted to model the shape of the normal human spine, few have done so as comprehensively and systematically as the Harrison group [40–47]. In a series of studies, elliptical shape modeling of the path of the posterior longitudinal ligament was performed on radiograph samples of asymptomatic subjects. Computer iterations of spine shape modeling was used to determine a best-fit geometric spinal shape by fitting various ellipses of altered minor-to-major axis ratios to the digitized posterior vertebral body corners of the cervical [40–42], thoracic [43, 44], and lumbar spinal regions [45–47] (**Figure 1**).

The Harrison normal spine model (**Figure 1**) features a circular cervical lordosis, and portions of an elliptical curve for both the thoracic kyphosis (more curvature cephalad), and lumbar lordosis (more curvature caudad). Consequently, features of the normal human spine reveal that the opposite thoracic and lumbar curves meet together at the thoraco-lumbar junction being essentially straight; the upper, deeper curve of the upper thoracic spine reflects oppositely at the cervico-thoracic junction (between T1 and T2) and continues into the cervical lordosis; the lower lumbar spine increases its lordotic alignment having two-thirds of its curve between L4-S1 as it meets the forward tilted sacral base. The spine is modeled as vertical in the front view. The spine alignment is easily quantified by repeatable and reliable methods from measuring its position from standing X-rays [48–52] (**Figure 2**).

The Harrison normal spine model has been validated in several ways. Simple analyses of alignment data of normal asymptomatic populations have been done [40–47, 53]. Comparison studies between normal samples to symptomatic samples [40, 41, 53]; as well as between normal samples to theoretical ideal models have

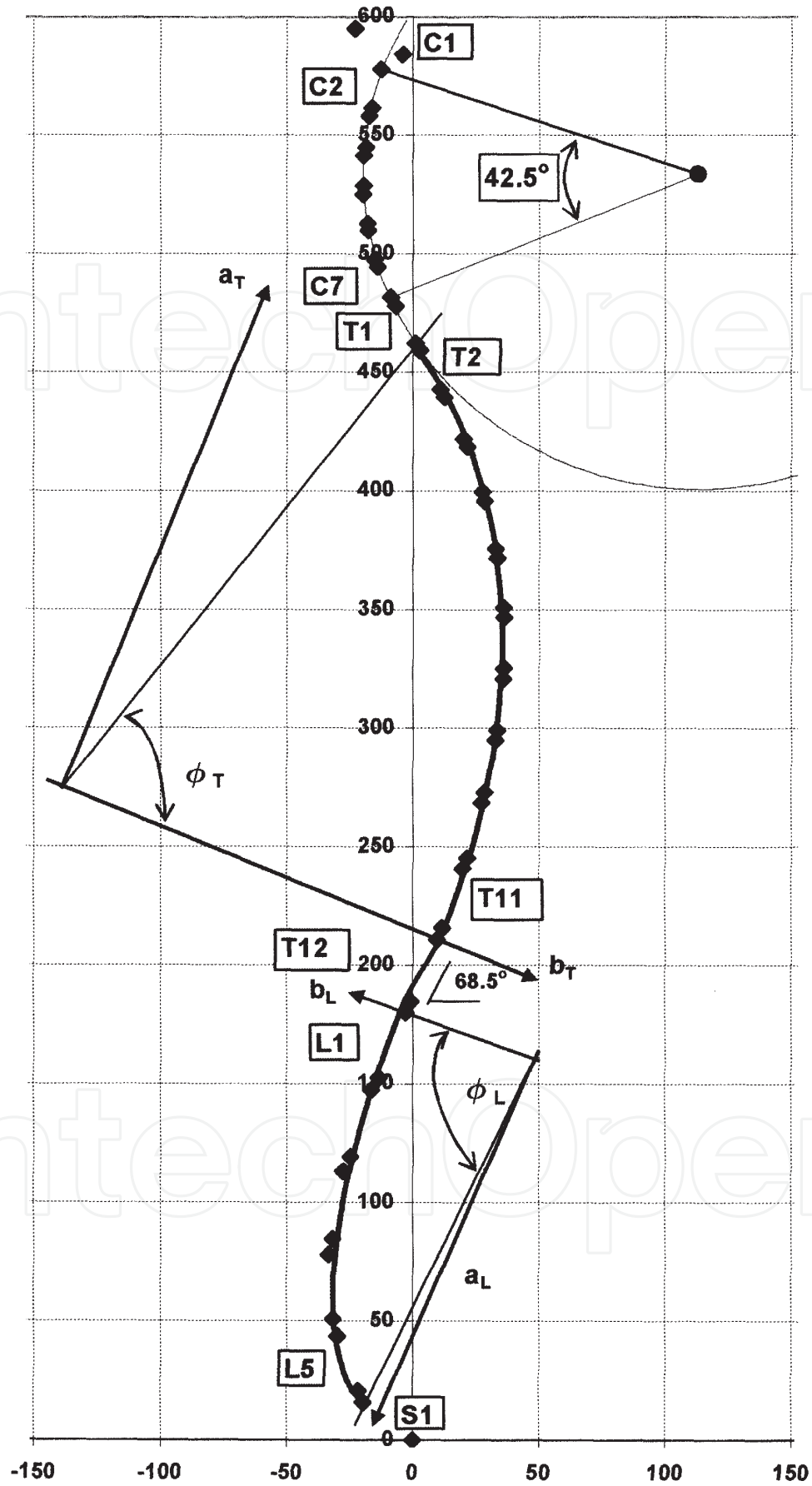


Figure 1. The Harrison normal sagittal spine model as the path of the posterior longitudinal ligament. The cervical, thoracic and lumbar curves are all portions of an elliptical curve having a unique minor-to-major axis ratio. The cervical curve is circular meaning the minor and major axes are equal.

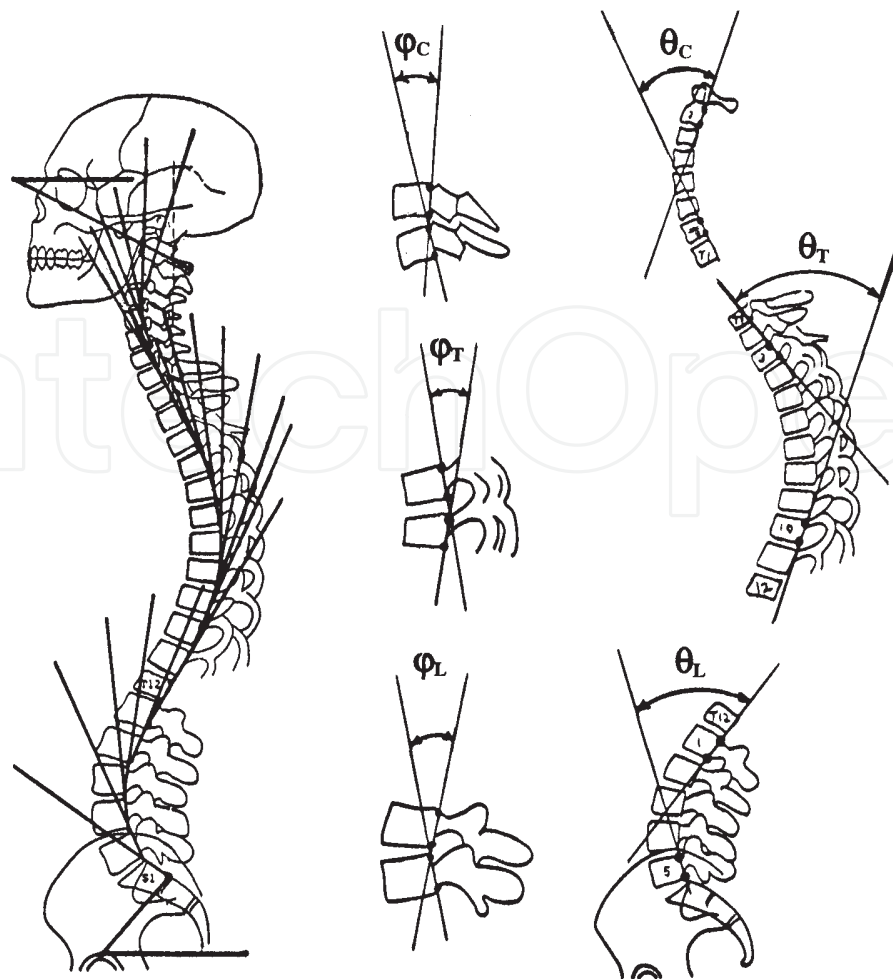


Figure 2.

Harrison posterior tangent method involves lines drawn contiguous with the posterior vertebral body margins. Intersegmental as well as regional sagittal curves are easily quantified having a standard error of measurement within about 2° (Courtesy CBP seminars).

been done [40, 41, 43–46]. The statistical differentiation of asymptomatic subjects from symptomatic pain group patients based on alignment data have been performed [42, 47]. The demonstration of paralleled spine alignment improvements with reduction in pain and disability, versus no change in untreated control groups in pre-post clinical trials have been performed [54–59]. The demonstration in randomized clinical trials that only patient groups achieving lordosis improvement (lumbar or cervical) and hyper-kyphosis (thoracic) reduction achieve long-term improvements in various outcome measures versus comparative treatment control groups not getting spine alignment improvement who experience regression in multiple outcome measures at follow-up have also been done [10–16, 60–64].

Chiropractors practicing Chiropractic BioPhysics® (CBP®) structural rehabilitation techniques have used this spine model as the goal of care for over 20 years; and more recently physical therapists and other manual medicine rehabilitation specialists have adopted components of this system as well. It is noted that this model serves as the baseline for patient comparison; specific patient comparisons, however, must include patient-specific considerations related to thoracic inlet parameters [65] as well as pelvic morphology [66] as these may dictate a structural modification to the model for a given patient. There are software programs (i.e. PostureRay Inc., Trinity FL, USA) that aid in the ability for practitioners to assess spine alignment quickly in daily practice (**Figure 3**). It must also be mentioned

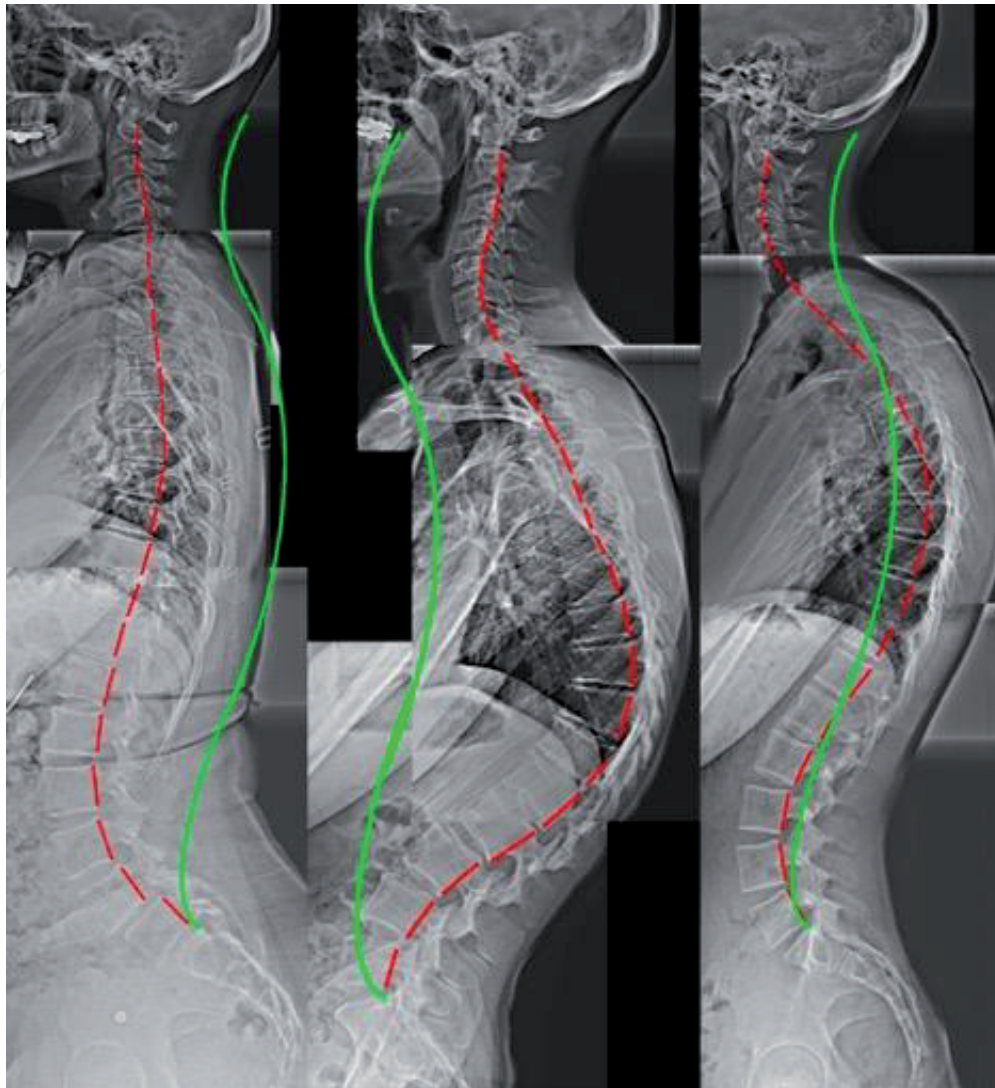


Figure 3. Three patients demonstrating dramatically different spine alignment patterns. Left: Excessive lumbar hyperlordosis, L4 anterolisthesis, and excessive anterior sagittal balance in a mid-aged female with disabling low back pain; Middle: Excessive thoracolumbar kyphosis and early degenerative changes in a mid-aged male; Right: Excessive thoracic hyperkyphosis in a young male with Scheuermann's disease. Red line is contiguous with posterior vertebral body margins; green line represents Harrison normal spinal model (Courtesy PAO).

that proper assessment of the spine includes the whole spine, that is, the cervical, thoracic and lumbar regions and femur heads. This is because spine balance and compensation mechanisms involve the whole spine; thus, regional X-rays to the 'problem area' can mislead treatment and not account for distal spinopelvic compensations that need to be considered prior to initiating a trial of spine care by these methods.

3. Biomechanics of the central nervous system

The brainstem (mesencephalon, pons, medulla oblongata), cranial nerves V-XII, spinal cord, cauda equina, and nerve roots may collectively be referred to as the pons-cord tissue tract. The static and dynamic characteristics of the pons-cord tract constitutes a self-contained compartment of biomechanics [8, 9, 67]. This results from the way the cord is maintained within the canal by its many attachments: from above (being continuous with the brainstem), from below (sacral and coccyx attachment through the cauda equina and filum terminale), as well as throughout its length (intermittent dural attachments to the posterior longitudinal ligament,

ventral attachments of the nerve root sleeves exiting the intervertebral foramina, and bilateral dentate ligament attachments ranging from the upper cervical region down to the level of L1). Under relatively normal static posture without pathological processes, spine dynamics produce normal or 'physiologic' tension as transmitted by its constraining elements, and without neurological compromise (**Figure 4**) [8, 9, 68].

Only when normal neurodynamic aspects of the so-called pons-cord tract are understood can neuropathology from adverse tensions be fully understood. As Breig states "Internal deformation of the tissue cannot be ruled out as a factor in any disease of the nervous system even in inflammatory and degenerative conditions of the hindbrain, cord and associated nerves, and in some cases it will be of primary pathologic significance" [8] (p. 12). A key concept is that under normal circumstances, normal movements of the spine involve physiologic unfolding and folding of the cord and nerve roots. Head flexion causes instantaneous unfolding and normal elasticity of the neural tissues and head extension causes elastic rebound and a re-folding of the cord and nerve roots (**Figure 4**). In this way the CNS can preserve normal function while accommodating differing spinal positions. Breig also found that movements of the cord occur at the location of movement as well as throughout the entire pons-cord tract; cervical motions produce strains (deformations) caudally down to the cauda equina and movements of the lower spine cause strains as far up as the cervical cord and brainstem. In fact, deformation of the brain tissue below the tentorium (which can affect cranial nerves V-XII [8]) within the cerebellum occurs to accommodate spine movements (particularly maximal functional positions).

All ventral flexion movements throughout the spine (i.e. cervical, thoracic, lumbar) cause a lengthening of the spinal canal, and therefore, a transmission of axial tension onto the cord. Pathological processes, such as disc herniations and bone spurs, if severe enough, interfere with the pons-cord tract biomechanics [69, 70], where the normal tension transmitted by the pons-cord restraining elements may then be referred to as 'pathological' tension [71]. Independent but equally as significant, abnormal spinal postures may create adverse tension within the neural elements as well. For instance, Stein found that "in a deformed kyphotic cervical spine, even a 'normal' amount of movement in the cervical spine may cause compression of the spinal cord" [72]. This is because the spinal cord adopts the length of the bony canal [73].

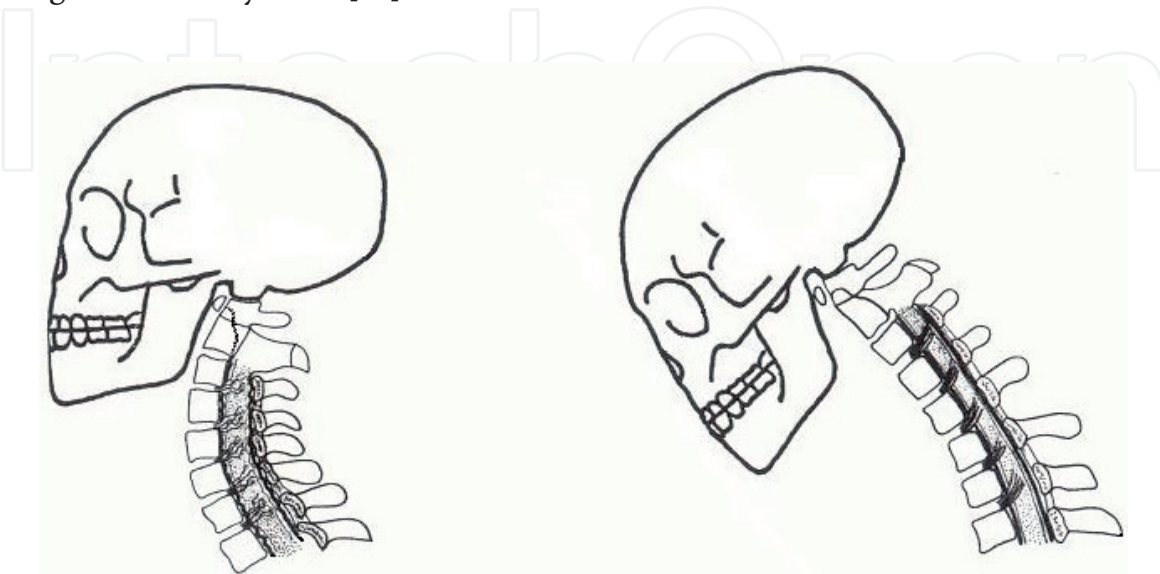


Figure 4. *Left: Physiologic folding of the cord and nerve roots in normal lordosis. Right: A forward flexion in those with normal lordosis causes normal unfolding and elasticity of the pons, cord and nerve roots that remain 'physiologic' or within tolerable tensions that do not overload the nervous system (Courtesy CBP Seminars).*

Further, as suggested by Harrison et al. [74] static neutral postures or dynamically adopted combinations of postures; that is, rotations and translations of the head, thorax, or pelvis (**Figures 5 and 6**) [36], exert larger stresses and strains onto the pons-cord tissue tract. Thus, it can be deduced that the combination of pathological processes (bone spurs, disc herniations, etc.) and aberrations in posture (forward head posture, thoracic hyperkyphosis, etc.) may disrupt normal CNS biomechanics, and at levels below that at which either factor acting alone would elicit neurological symptoms. As it can be presumed when a patient has an accumulation of forward flexed spine positions, such as severe thoracic hyperkyphosis (THK) posture for example, the amount of spinal canal lengthening can be great and supersede the 'normal' or physiologic amount of unfolding and elastic deformation available within the pons-cord system. In this situation, normal physiologic tensions transition to become pathologic tensions causing intermittent over-stretching and over-straining of the tissues and ultimately, causing or exacerbating neurologic symptoms.

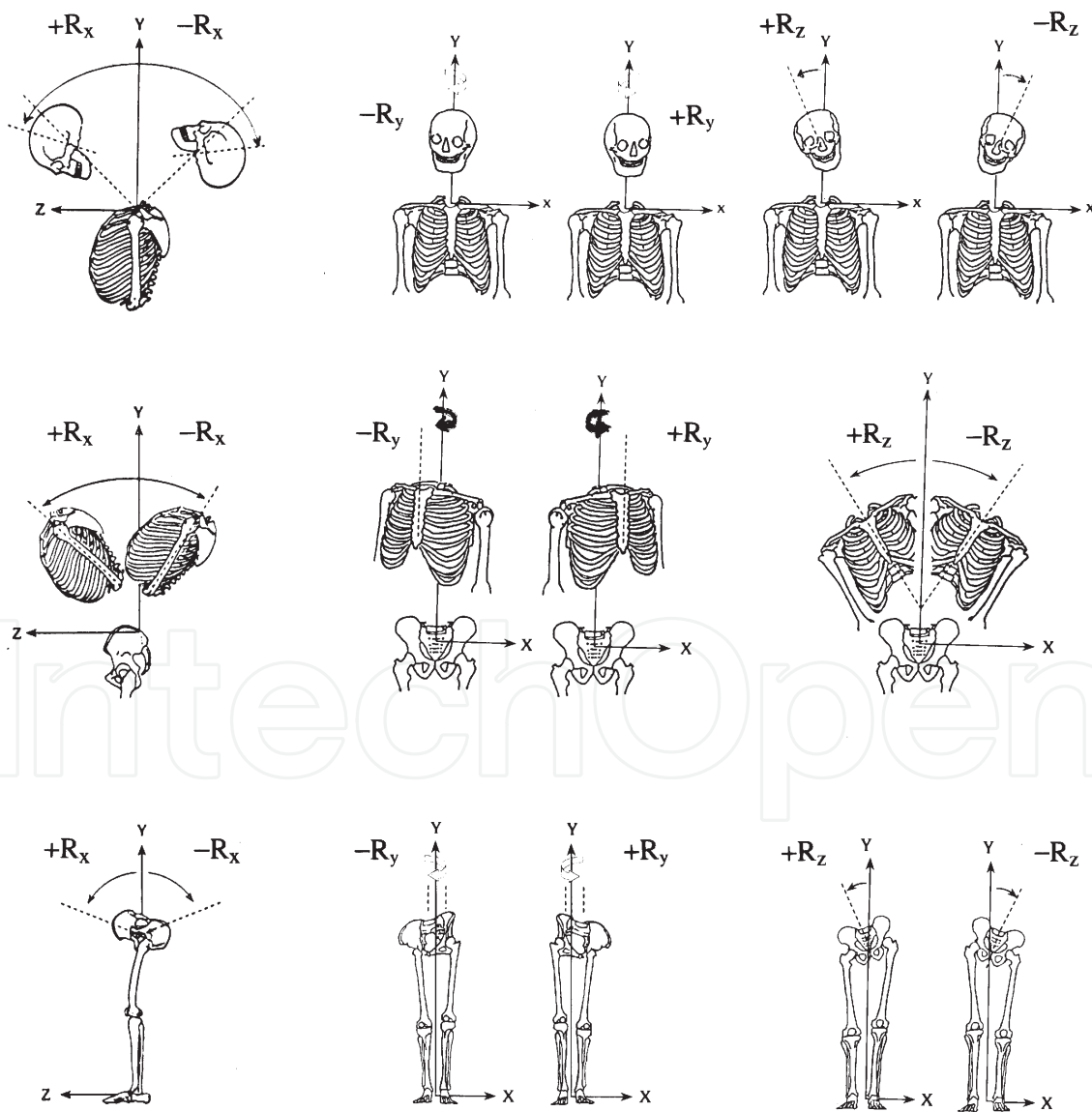


Figure 5. If the head, thoracic cage, and pelvis are considered rigid bodies, then the possible rotations in 3-dimensions are illustrated. Flexion and extension are rotations on the x-axis, axial rotation is about the y-axis, and lateral flexion is rotation about the z-axis (Courtesy CBP Seminars).

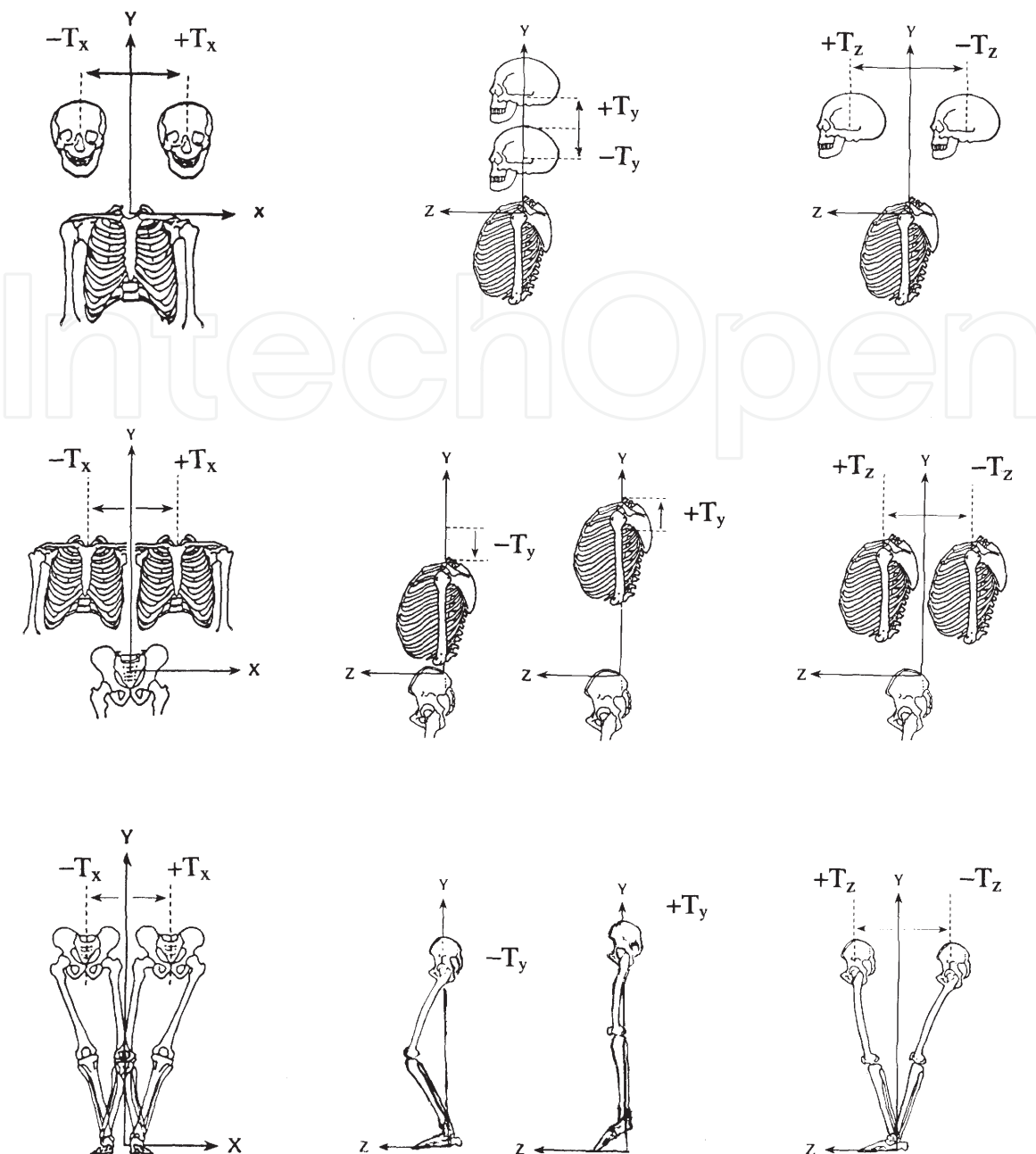


Figure 6. If the head, thoracic cage, and pelvis are considered rigid bodies, then the possible translations in 3-dimensions are illustrated. Lateral translations occur along the x-axis, vertical translations occur along the y-axis, and anterior-posterior translations (protraction-retraction) occurs along the z-axis (Courtesy CBP Seminars).

4. Pathophysiologic mechanisms from adverse CNS tension

Understanding the normal biomechanics of the CNS lays the foundation for the understanding of postural-induced neurological signs and symptoms. As discussed, two main events may individually, or in combination, lead to excessive stresses (longitudinal, torsional, pure bending, shear) and strains (longitudinal cross-sectional) that are sufficient to produce symptoms. In words, poor postures (lengthened spinal canal via forward flexed spinal positions) and space occupying lesions (bone spurs, intervertebral disc prolapse, etc.) combine to produce symptomatology. The greater the spinal canal is flexed, or as discussed, the presence of combinations of rotations and translations in posture, the greater the forced

unfolding and elastically stretched pons-cord tract (**Figure 7**). With the addition of space occupying lesions, patients having deviations in postural alignment become much more likely to succumb to various pressure mechanisms, or how the nervous tissue is compressed upon certain positions and movements.

It is important to realize that those patients with poor spinal posture may at times be in positions that are tolerable by the pons-cord tract (i.e. not over-stretched), and at other times perform movements that dynamically lengthen the spinal canal causing a pivotal transition to over-stress and over-strain the system (i.e. dynamic stress and strain). Therefore, successful symptomatic relief resulting from postural correction to a patient suffering from neurological complaints may be elucidated. Although some spinal pathologies will not change (e.g. bone spurs), the reduction of forward flexion of the neutral postural position (e.g. increasing cervical/lumbar hypo-lordosis; reducing thoracic hyper-kyphosis) will change the resting, and therefore the dynamic tensions throughout the pons-cord tract sufficiently enough to reduce the tensions from surpassing some pathological tension threshold (maintaining physiologic or normal tensions), and therefore alleviate neurologic symptomatology [74, 75].

How does adverse mechanical tensions within the CNS produce symptoms? Ultimately, pathological CNS tensions affect the vascular supply and therefore the perfusion of the neural tissues or they may affect the actual nerve conduction ability of the nerve cells (causing hyper or hypo function). Mathematically, perfusion = mean arteriole pressure (MAP) – cord interstitial pressure (CIP) [76]. Thus, for perfusion to remain adequate, the MAP must remain greater than CIP. However, as discussed by Harrison et al. [77], an increase in CIP can be caused by at least two forces, a longitudinal force causing unfolding and elastic elongation of the cord, and a transverse force usually by the cord being thrust into the posterior margin of the vertebral body at the anterior portion of the spinal canal. As stated, Stein found that cervical kyphosis, posture subluxation alone is enough to interfere with cord conduction [72], but with an accompanying space occupying lesion the likelihood for a transverse cord/nerve compression pressure mechanism to limit perfusion and compromise neural function is much greater.

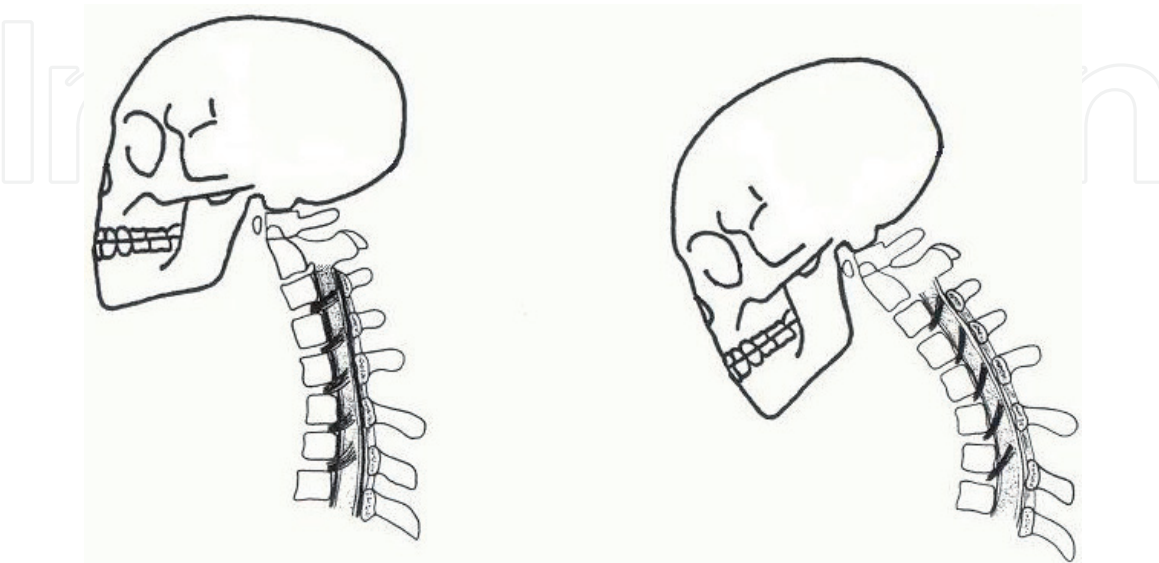


Figure 7.

Left: Cervical kyphosis subluxation in neutral posture results in the unfolding and elastic pre-tension present prior to flexion. Right: Forward flexion of a kyphotic neck may result in 'pathologic' or pons-cord-nerve root tensions that exceed physiologic limits and results in neurologic symptoms; particularly in the presence of a space-occupying lesion such as a bone spur or intervertebral disc prolapse (Courtesy CBP Seminars).

5. Postural correction to treat neurologic disorders by reducing pons-cord tensions

There have been several clinical controlled trials documenting the association with improved postural parameters (e.g. increasing cervical lordosis, increasing lumbar lordosis, decreasing thoracic hyperkyphosis) translating into improved physiological measures including specific tests indicative of neurologic function [10–16]. These measures include:

- Central somatosensory conduction time N13-N20 (**Figure 8**);
- Dermatomal somatosensory evoked potentials (DSSEPs) (**Figures 9 and 10**);
- H-reflex;
- Sensorimotor control measures (**Figures 11 and 12**);
- Sympathetic skin resistance response (**Figure 13**).

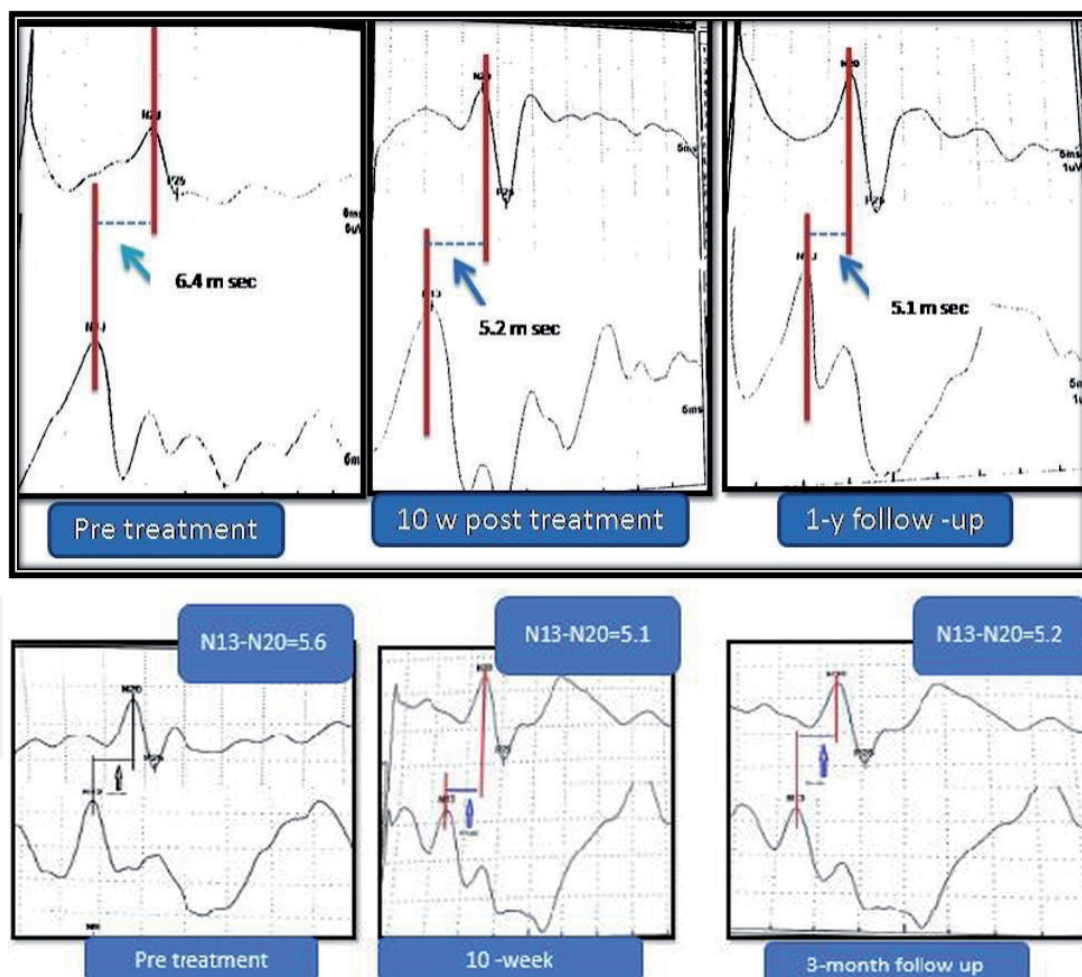


Figure 8.

Central conduction time (N13-N20) also known as spinal cord velocity. In the top figure, a representative example of central conduction time (N13-N20) at three intervals of measurement: baseline, following 10-weeks of treatment, and 1-year follow-up. This is from the study by Moustafa et al. [13] on symptomatic patients with cervical spine disc herniation. Follow correction of the cervical lordosis, a 20% change in central conduction speed is shown in milliseconds (m sec) indicating a faster more efficient response. In the bottom graph a representative sample from the study of Moustafa et al. [78] is shown. Here, in asymptomatic participants, correction of the cervical lordosis and anterior head posture was found to result in a 10% faster response in the central conduction time potential. Comparative and placebo control groups not attaining spine correction showed no improvement in central conduction time.

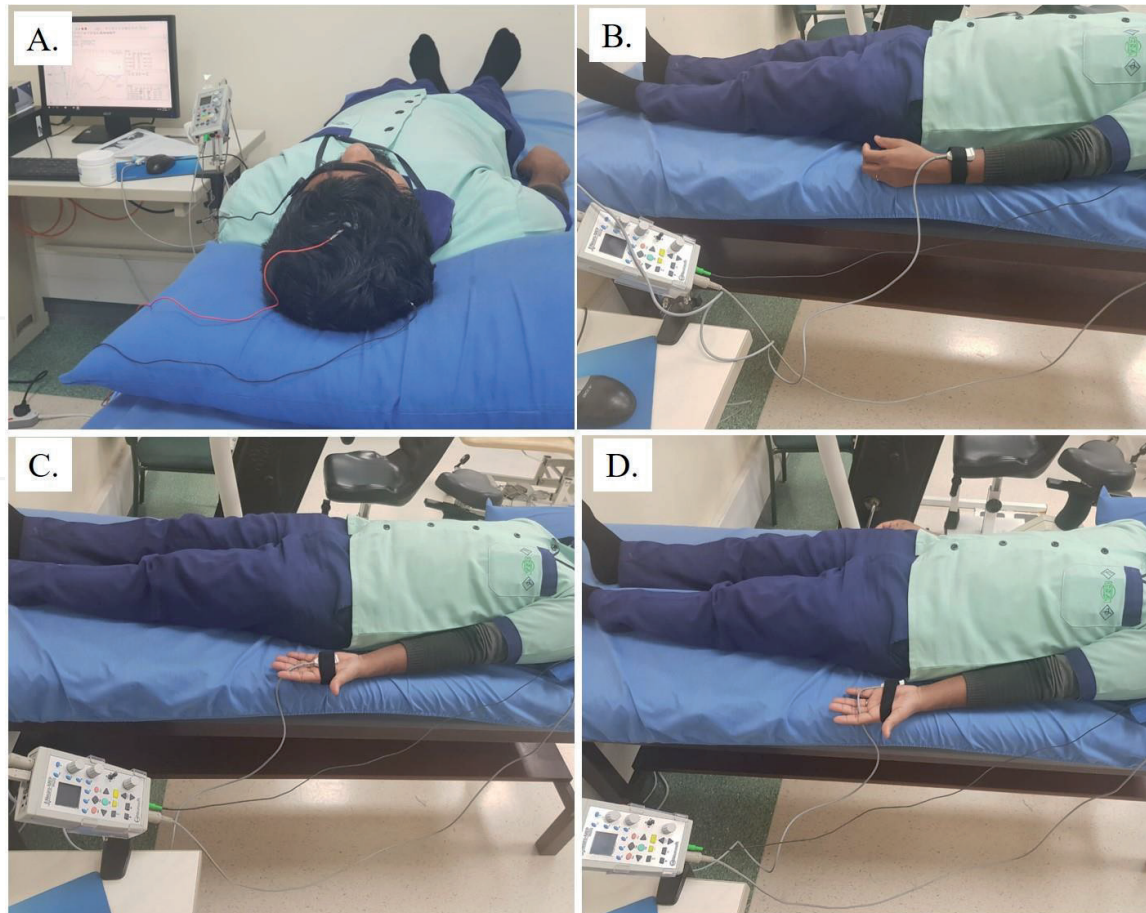

Figure 9. *Dermatomal somatosensory evoked potential (DSSEPs) set up for C6, C7, and C8 nerve root assessment. In (A) Sites of recording: (1) active recording electrode at c3, (2) reference electrode at Fz, and (3) grounding electrode at Fbz. Location of stimulation sites are indicated above: (B) for C6 dermatome, (C) for C7 dermatome, (D) C8 dermatome. Sites of recording. Courtesy of Moustafa et al. [16].*

Here we briefly summarize the particulars of exemplary trials that demonstrate how improvement in targeted spinal and postural parameters have led to improved neurophysiological outcomes.

5.1 Central somatosensory conduction time N13-N20

Using standardized clinical procedures for median nerve stimulation at the wrist, a subjects' central somatosensory conduction time measurement, N13-N20, can be determined. Differences in peak latencies between N13 and N20 is measured as central conduction time or similarly called 'cervical spinal cord velocity'. In 2016, Moustafa et al. reported on a randomized controlled trial using a cervical extension traction orthotic device (Denneroll™; Denneroll Pty, limited, Sydney, Australia) in a multi-modal rehabilitation program for treating patients with discogenic radiculopathy [13]. Sixty patients were randomized to a treatment and comparison (control) group where both groups received TENS, thoracic spine manipulation, soft tissue mobilization and strengthening exercises. Only the treatment group performed the additional Denneroll orthotic device to increase cervical lordosis and reduce forward head posture. After 30 treatment applications over the course of 10-weeks, only the treatment group demonstrated significant improvements in N13-N20 (20% gain in velocity). Also, at a 1-year follow-up without further intervention, again only the treatment group demonstrated a statistically improved N13-N20 potential. Importantly, only the treatment group receiving the Denneroll had statistically improved cervical lordosis and reduced forward head posture at the 10-week and 1-year follow-up. **Figure 8** (top) demonstrates the improvement in the N13-N20 potential in this trial.

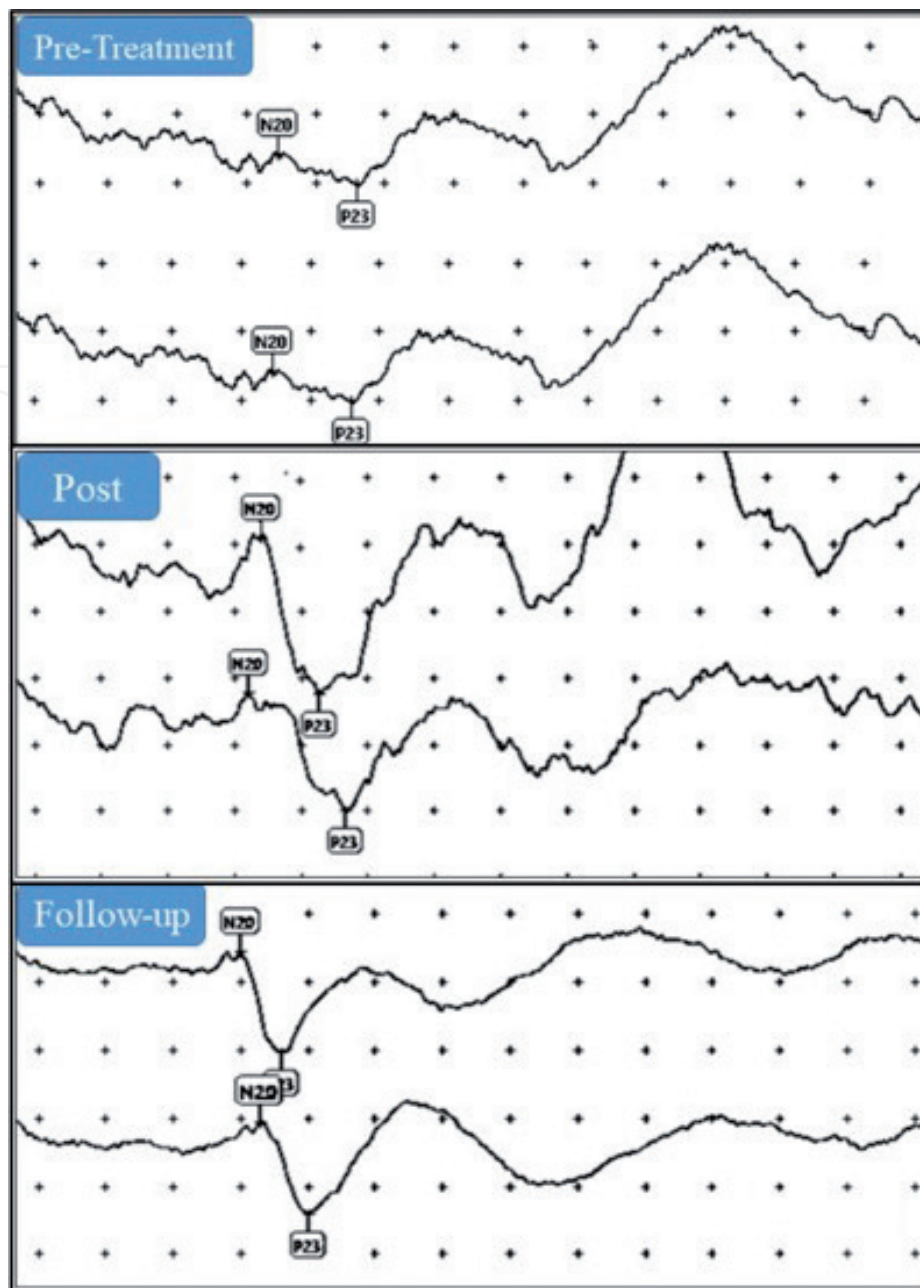


Figure 10. Example of Dermatome somatosensory evoked potential (DSSEPs) of C6 dermatome at three intervals of measurement. Courtesy of Moustafa et al. [16]. The Pre-treatment DSSEPs from the RCT by Moustafa et al. [16] is shown. In the 10-week post treatment (Follow-up), the DSSEPs following cervical curve correction is shown. Finally, the 3-month (Post) follow-up, DSSEPs are shown where correction was stable over time.

In another trial, Moustafa et al. reported on the unique treatment of asymptomatic volunteers who had strictly defined anterior head translation and cervical hypolordosis [78]. Eighty persons were randomized into a treatment group who performed cervical extension traction on the Denneroll traction orthotic or a control group who lied on a rolled hydrocollator towel (placebo control). Both groups were treated for 30 sessions over 10-weeks and were then re-assessed after 12 further weeks of no further treatment. Central somatosensory conduction time latency (N13-N20) and amplitudes of spinal (N13), brainstem (P14), parietal (N20 and P27), and frontal (N30) potentials were measured at baseline (prior to treatment), 10-weeks and 22-weeks. After the 10-weeks of treatment, the treatment group had significantly better amplitudes of N13, P14, N20, N27 and N30 as well as central conduction time (10% faster conduction velocity of N13-N20). All significant differences between groups favouring the treatment group remained at the 12-week post-treatment follow-up. Lastly, a statistically significant multiple

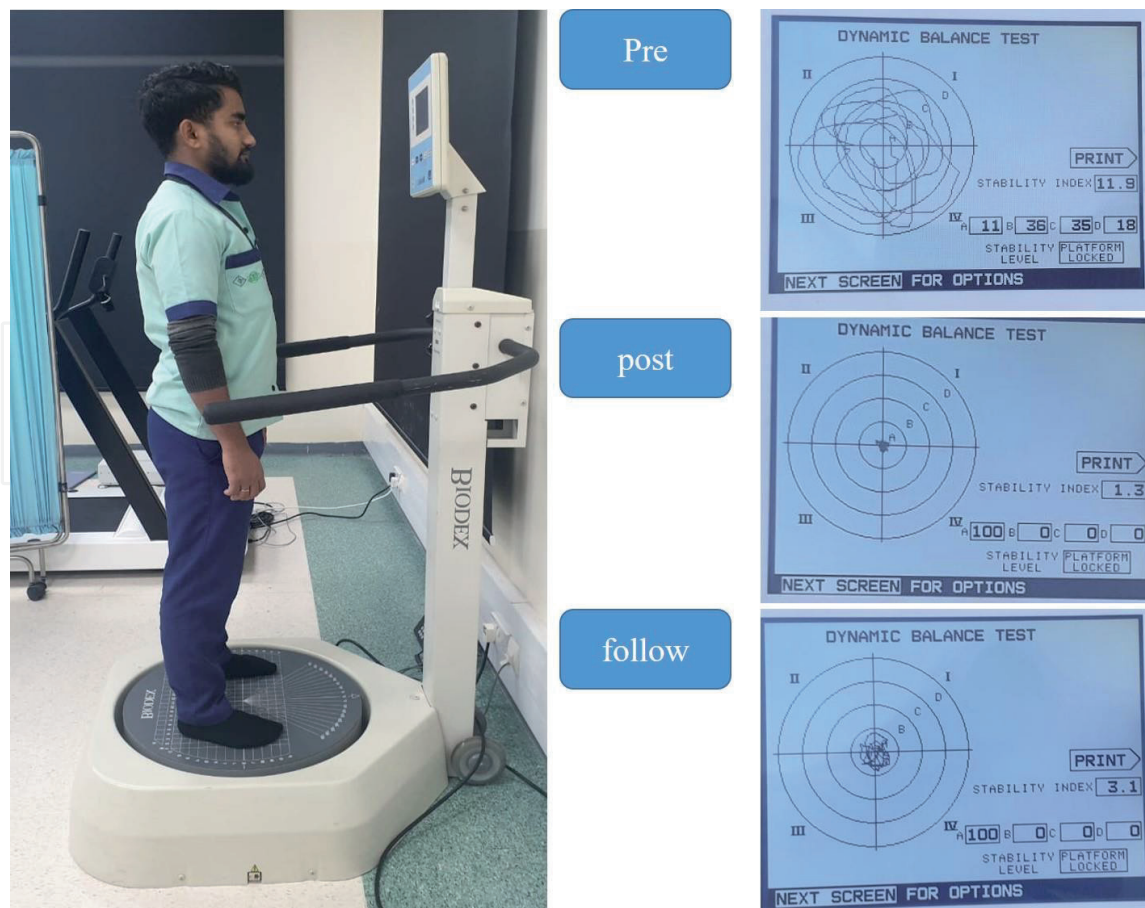

Figure 11.

Postural stability characteristics were evaluated with a Biodex Balance System SD (BBS) (Biodex Medical Systems, Inc., Shirley, NY). Dynamic balance testing was performed on the unlocked platform to allow free movement concurrently both in the anterior–posterior (AP) and medial-lateral (ML) directions. The platform permits variable levels of resistance to movement perturbation ranging from one to eight (1 being the most restrictive). BBS measures the deviation of each axis during dynamic balance assessments. The BBS software measures an overall stability index (OSI) and is a representative index of balance performance. OSI is the best indicator of the overall ability of the subject to balance the platform whereby a reduced balance or stability correlates with large variation or large value of OSI [79] [80]. From the RCT by Moustafa et al. [10] participants randomized to and achieving cervical spine correction obtained statistically significant improvements in the OSI compared to a standard care group (Pre vs. 10-weeks post vs. 1-year follow up). Courtesy of Moustafa et al. [10, 34].

regression model to predict central conduction time changes, N13-N20, from correction in cervical lordosis and anterior head translation (AHT) was identified for the intervention group receiving the Denneroll orthotic at both the 10-week mark ($p < .001$) and the 3-month follow-up ($p < .001$) [78]. **Figure 8** (bottom) demonstrates the improvement in the N13-N20 potential in this trial.

5.2 Dermatomal somatosensory evoked potentials (DSSEPs)

In 2011, Moustafa et al. reported on the results of a pilot trial that showed patients with cervical spondylotic radiculopathy randomized to a rehabilitation program including cervical spine stretching exercises, infrared radiation and 3-point bending cervical extension traction had significantly improved peak-to-peak amplitude measures of DSSEPs after both 10-weeks of treatment (30 treatment sessions) and at a 12-week follow-up [16]. The comparison (control) group receiving the same treatment less the neck traction did show an initial improvement in DSSEPs after the 10-week treatment period, however, this difference disappeared at the 12-week follow-up. Only the treatment group showed a statistically significant increase in cervical lordosis. Most importantly, Moustafa et al. identified a linear correlation between initial

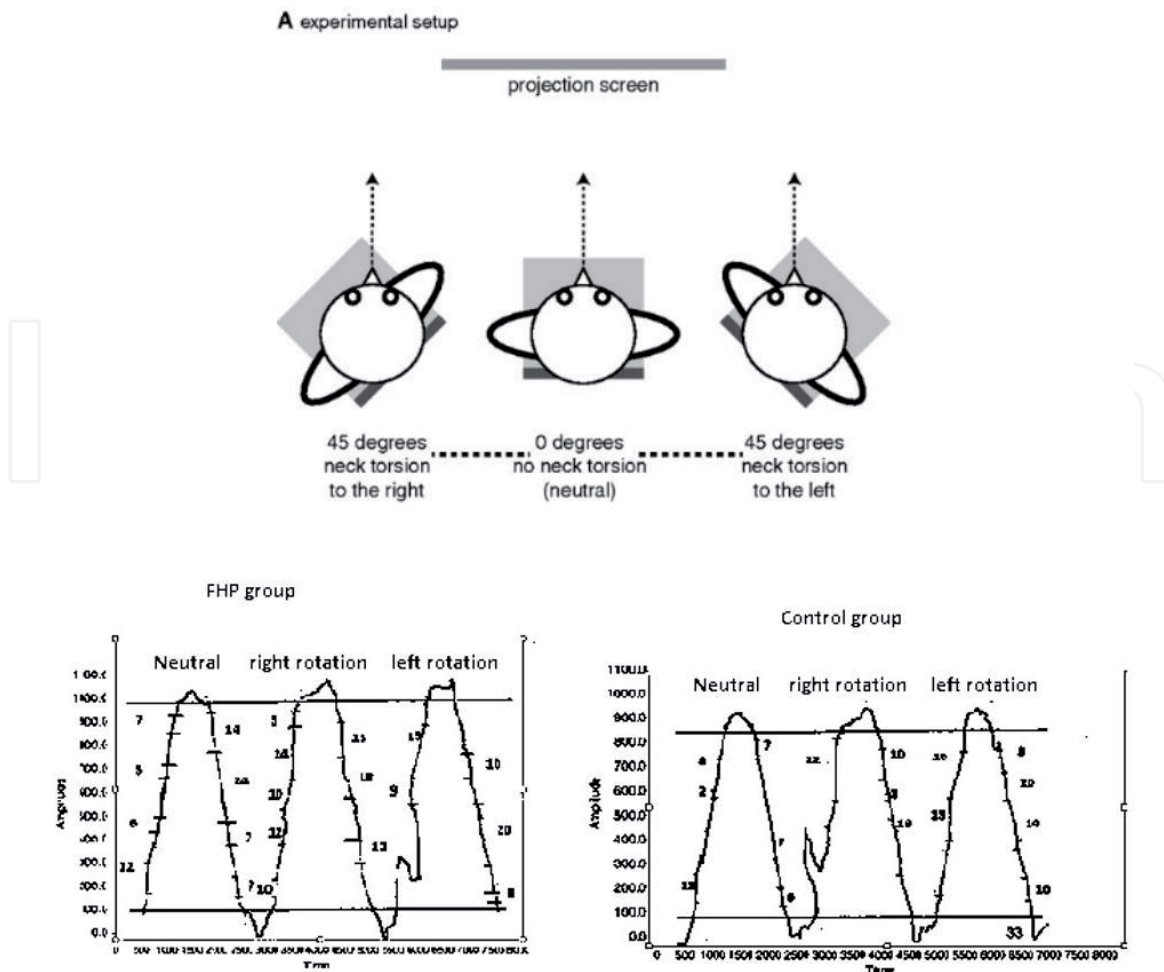


Figure 12.

In A, an example of the smooth pursuit neck torsion test (SPNT) is shown neutral, right turn, and left turn of the head indicated by the 45° torso rotated position. Middle and right image: A SPNT test eye velocity is shown as the uneven high amplitude curves. The ciphers indicate the length of the vertical part of the curve between two marks, i.e., the saccades. The forward head posture group (FHP group) has larger errors (≈30%) as compared to a match control group with normal head alignment (10% average error). Courtesy of Moustafa et al. [34].

DSSEPs and cervical lordosis magnitude for both groups ($r = .65$; $p < 0.0001$), whereas this relationship was only maintained in the study group receiving 2-way traction at final follow-up ($r = .55$; $p = 0.033$). This indicates that cervical spine lordotic correction linearly correlates to improvements in DSSEPs [16]. **Figures 9** and **10** depict the experimental setup for the DSSEPs of C6, C7, and C8 as well as the changes in C6 DSSEPs in the study group receiving the curve corrective traction.

As reported in the previous section (5.1), the 2016 trial reported by Moustafa et al. [13] treating patients with discogenic radiculopathy, both groups showed improvements in latency of DSSEPs at the 10-week post-treatment assessments, however only the treatment group showed statistically improved amplitude of DSSEPs. At a 1-year follow-up without intervention, only the treatment group demonstrated statistically improved latency and amplitude of DSSEPs. Also, only the treatment group had improved cervical lordosis and reduced forward head posture at the 10-week and 1-year follow-up.

5.3 H-reflex

In a unique randomized trial, Moustafa and colleagues [14] investigated the hypothesis that improving the cervical lordosis and reducing forward head translation would improve low back pain, disability, and neurophysiology in a sample of

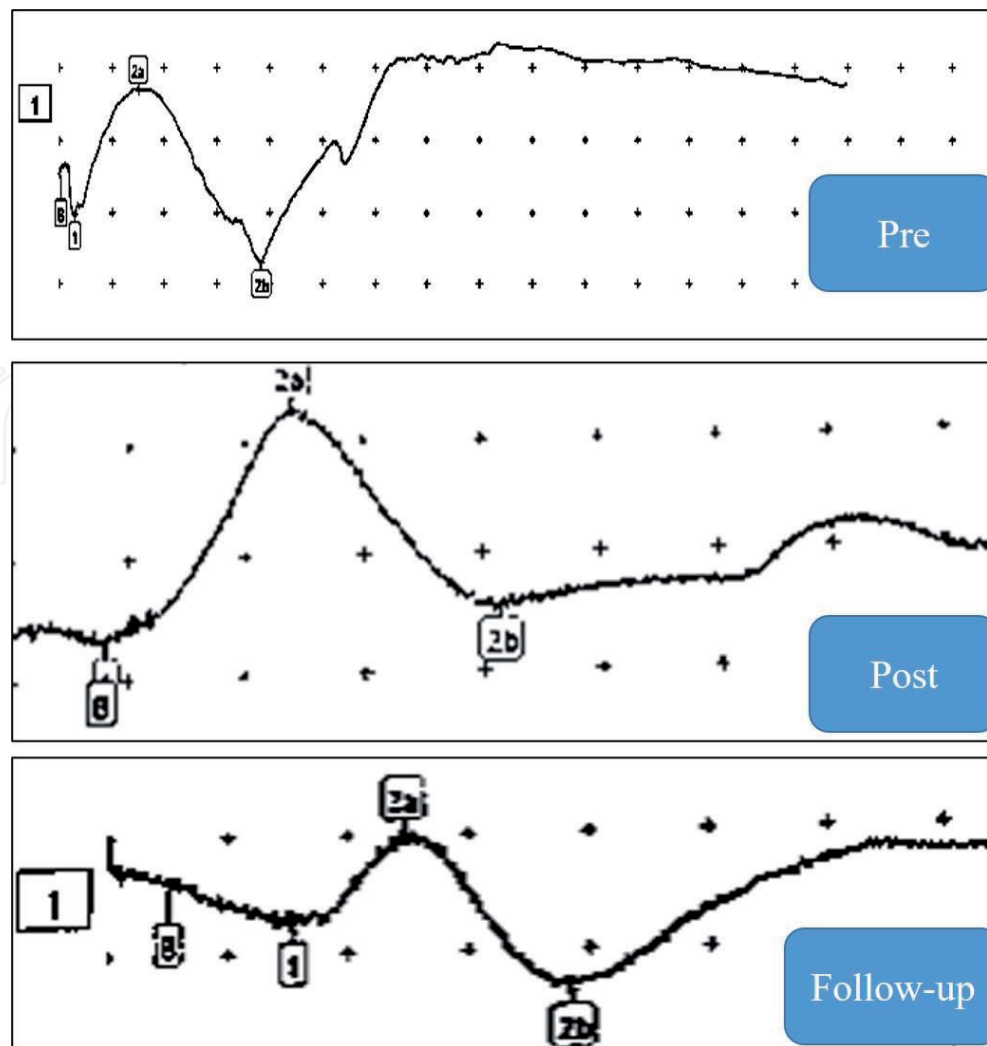


Figure 13.

Sympathetic skin resistance response (SSR). For measurement of the SSR, EMG equipment was used [10]. Active surface electrodes were attached on the palmar side, and the references were placed on the dorsum of the hand. The stimulus was given at the wrist contralateral to the recording side. Measurements were taken from left and right arms. Latencies were measured from the stimulation artifact to the first deflection from the baseline. The amplitude is measured from the peak of the first deflection to the peak of the next one (peak to peak) as shown. Depicted are the results for the study group receiving cervical spine correction (lordosis and forward head posture). On the Top: the study group receiving spine corrective extension traction is shown at pre-study; Middle: after 10 weeks of treatment (30 sessions); and Bottom: at 1-year follow up with no further treatment. Only the group receiving extension traction obtained sagittal plane cervical correction and statistically significant improvement in SSR latency and amplitude. Courtesy of Moustafa et al. [10].

80 (35 female) patients between 40 and 55 years suffering signs and symptoms from chronic discogenic lumbar radiculopathy (CDLR). Both groups received TENS therapy and hot packs; additionally, the study group received the Denneroll cervical traction orthotic. All treatment interventions were applied at a frequency of 3 x per week for 10 weeks. Both groups were followed for 6 months after their 10-week re-evaluation. Statistically significant differences between the study groups and the control group's postural measures were found favouring improved posture in the Denneroll group for: lumbar lordotic curve ($p = .002$), thoracic kyphosis ($p = .001$), trunk inclination ($p = .01$) and imbalance ($p = .001$), pelvic inclination ($p = .005$), and surface rotation ($p = 0.01$). The two radiographic measures of cervical lordosis ($p = .001$) and forward head posture ($p = .002$), and H reflex amplitude ($p = .007$) and H reflex latency ($p = .001$) were likewise statistically different between the groups at 10 weeks favoring improvement in the Denneroll study group. Restoring cervical lordosis and reduction of forward head posture with Denneroll traction was found to have a positive impact on 3D posture parameters, leg and back pain

scores, back disability, and H reflex latency and amplitude. Thus, improvement of sagittal cervical spine posture and alignment benefited the pain, disability, and postural imbalances in patients with CDLR.

In 2013, Moustafa et al. reported the results of a trial employing lumbar extension traction to increase the lumbar lordosis in patients suffering from MRI-verified lumbosacral radiculopathy [15]. Sixty-four patients were randomly allocated to the treatment or comparison (control) group who both received hot packs and interferential therapy; only the treatment group received the lumbar extension traction. After 30 treatment sessions over 10-weeks, only the treatment group showed statistically improved latency and amplitude of the H-reflex. At the 6-month follow-up, again, only the treatment group showed statistically improved H-reflex outcomes. Only the treatment group demonstrated improved lumbar lordosis after the 10-week treatment period and at the 6-month follow-up.

5.4 Sensorimotor control measures

5.4.1 Cervicocephalic kinesthetic sense measured as head repositioning accuracy

Improvement in head repositioning accuracy (HRA) as a result of sagittal plane spine alignment correction has been assessed in three recent randomized trials by the Moustafa et al. group; two of these trials assessed cervical lordotic correction and anterior head translation reduction [10, 79], whereas, one trial assessed improvement in thoracic hyper-kyphosis [11]. In 2017, Moustafa et al. reported on the improvement in HRA, a measurement of cervicocephalic kinesthetic sensibility [79]. Seventy-two patients suffering from cervicogenic dizziness were randomized to a treatment or comparison (control) group and received TENS, hot packs, mobilization, myofascial and suboccipital release, and therapeutic functional exercises. Only the treatment group also received the Denneroll cervical extension traction orthotic device. The cervical range of motion (CROM) device was used to assess cervicocephalic kinesthetic sensibility by measuring the head repositioning average error (HRA). The participants (blindfolded) started with their head in the neutral head position (NHP) and were asked to actively move to the midpoint of their maximum rotation range, which was called the “target position.” After returning to the NHP, they were then asked to rotate their head to the target position. The difference between the target position and the achieved position was recorded 3 times and averaged. The midpoint position was used rather than the NHP because it was considered a non-learned position. The CROM device has good criterion validity ($r = 0.89-0.99$) and reliability (intra-class correlation coefficient [ICC] = $0.92-0.96$) [80].

After 30 treatment session over 10-weeks, both groups improved on the HRA test [79]. However, at the 1-year follow-up, the treatment group's HRA to the left and right was statistically significantly better than the comparison group. Again, only the treatment group had a statistically improved cervical lordosis and improved forward head posture at both the 10-week and 1-year follow-up. In their more recent [10] randomized trial similar results were identified where improved HRA resulted from improved cervical lordosis and forward head translation reduction; herein, the improvement in the HRA was identified to be linearly correlated to the improvement in both cervical lordosis and reduction in forward head posture. The linear correlation between improved HRA and improved forward head posture magnitude is further supported by the results of a cross-sectional case control investigation which found a linear relationship between worsening HRA and increased magnitudes of forward head posture [34].

In 2020, Moustafa et al. reported on the improvements in various sensorimotor control measures in patients treated for thoracic hyper-kyphosis [11]. Eighty patients with thoracic hyper-kyphosis were randomized to a treatment or comparison (control) group. Both groups were treated for 30 treatment sessions over a 10-week time period with TENS and hot packs, soft tissue mobilization, thoracic spine manipulation, and functional exercises. Only the treatment group also performed the Denneroll thoracic traction orthotic designed to reduce the thoracic curve. At the 10-week post-treatment assessment, no significant differences were found for left-sided HRA whereas, significant differences favouring the treatment group were found for the right sided HRA. At the 1-year follow-up without intervention, sensorimotor control measurement of HRA, bilaterally, was significantly superior for the intervention group. Also, only the treatment group experienced a reduction in thoracic hyper-kyphosis at the 10-week assessment that was maintained at the 1-year follow-up [11].

5.4.2 Biodex balance and stability measurement

Posture stability efficiency is a key measurement or performance variable of sensorimotor control. In recent randomized trials [10, 11] and case control [34] investigations by Moustafa and colleagues, postural stability characteristics were evaluated with a Biodex Balance System SD (BBS) (Biodex Medical Systems, Inc., Shirley, NY) (**Figure 11**). Dynamic balance testing was performed on the unlocked platform to allow free movement concurrently in both the anterior–posterior (AP) and medial-lateral (ML) directions. The platform permits variable levels of resistance to movement perturbation ranging from one to eight (1 being the most restrictive). BBS measures the deviation of each axis during dynamic balance assessments. The BBS software measures an overall stability index (OSI) and is a representative index of balance performance. OSI is the best indicator of the overall ability of the subject to balance the platform whereby a reduced balance or stability correlates with large variation or large value of OSI [81, 82]. From the RCT by Moustafa et al. [10], participants randomized to and achieving correction of both cervical lordosis and anterior head posture obtained statistically significant improvements in the OSI compared to a standard care group (pre vs. 10-weeks post vs. 1-year follow up). Likewise, in the RCT looking at thoracic hyper-kyphosis reduction, it was found that OSI was statistically improved only in the group achieving reduction of thoracic kyphosis and that this result was stable at 1-year follow-up [11].

The fact that posture stability, as measured with OSI, improves due to correction of the sagittal cervical and thoracic spine alignments seems to make sense; as previously a linearly correlation between worsening OSI and increased magnitudes of forward head posture has been found [34].

5.4.3 Smooth pursuit neck torsion test or SPNT

The smooth pursuit neck torsion test (SPNT) is used to quantify alterations in and improvement in a person's visual-motor control using electro-oculography equipment [83]. **Figure 12** demonstrates the SPNT procedure. First, participants perform the SPNT with the head and trunk in the neutral, forward facing posture. Next, while keeping the head facing forward, the torso is placed in a 45° rotation (about a vertical y-axis) position to each side in a consecutive manner. Participants typically perform three blinks of their eyes and are instructed to follow the path of a light source as close as possible with their eyes without movement of their head or neck. The accuracy of the SPNT is determined as the difference between the

average increase/decrease in the participants NHP vs. the torsioned positions; errors are termed 'corrective saccades' and are reported as a percentage difference from perfect. In a recent case control cohort sample, Moustafa et al. [34] identified that the forward head posture group (FHP group) had larger SPNT errors ($\approx 30\%$) as compared to a matched control group with normal head alignment (10% average error). In fact, a linear correlation was identified between the magnitude of forward head posture subluxation and the percent error in SPNT.

Importantly, in the Moustafa et al. RCTs [10, 11], SPNT test eye velocity was shown to improve in the group receiving spine correction as compared to the comparison group not receiving and not achieving spine correction. The average SPNT errors in both the cervical spine [10] and the thoracic spine [11] correction groups improved down to bench-mark values for healthy persons ($\approx 10\%$).

5.5 Dysafferentation, altered sensorimotor control and autonomic nervous system

Sympathetic skin resistance response (SSR) is a measurement of autonomic nervous system function or dysfunction. For measurement of the SSR, EMG equipment is typically used [10, 34]. Active surface electrodes are attached on the palmar side, and the references are placed on the dorsum of the hand. A stimulus is given at the wrist contralateral to the recording side. Measurements should typically be taken from left and right arms. The SSR is assessed as: (1) a latency measurement from the stimulation artifact to the first deflection from the baseline; and (2) an amplitude is measured from the peak of the first deflection to the peak of the next one (peak to peak). **Figure 13** depicts a typical measurement of SSR latency and amplitude.

In a recent case-control cohort investigation of 160 asymptomatic volunteers, Moustafa and colleagues [34] investigated the SSR and its relationship to the severity of forward head posture; a strong linear correlation was identified between the magnitude of forward head posture and increased amplitude and latency of the SSR evoked potentials. Thus, increased magnitudes of forward head posture have a negative impact on the autonomic nervous system in essence leading to a state of hyperactivity or increased excitability. Only one RCT on the effects of spine correction on SSR latency and amplitude could be identified. In the study by Moustafa et al. [10], the group receiving spine corrective extension traction obtained sagittal plane cervical correction and statistically significant improvement in SSR latency and amplitude; the results indicated a linear correlation between the amount of correction of the cervical lordosis and FHP and the concomitant improvement of the SSR potentials [10].

6. Strengths, applications, and perspectives

The above review of sagittal plane spine alignment and its impact on neurophysiology has several strengths. First, there is strong biomechanical evidence indicating that altered and sustained sagittal plane spine and posture alignment results in increasing the stresses and strains acting on the pons-cord tract system and that this impairs directly or indirectly neurophysiology; this evidence has existed since 1960 [8, 9, 26, 68, 69, 71–75, 77]. Second, considering the results of the recent randomized trials reviewed above, it is clear, that rehabilitation techniques that increase the cervical lordosis and lumbar lordosis, have a profound and sustained effect of improving measurements of neurophysiology as measured with DSSEP's, H-Reflex, and central conduction times [12–16, 78, 79]. Similarly, reducing the magnitudes

of thoracic hyper-kyphosis [11] and FHP [12–16, 78, 79] has been found in RCT's to result in improved neurophysiological measurements. Finally, clinical management and improvement of several complex neurological disorders have been documented in multiple case reports where spine correction was suggested to be the important variable which improved the patient's neurophysiological disorder [17–25]. Thus, considering the facts that biomechanics studies, randomized trials, and case reports all point to the same finding, clinically and scientifically one would need to concede that improved neurophysiology following correction of the abnormal spine towards normal values is an evidence-based and logical approach to pursue with appropriate patients.

Similarly, the known intimate connections between afferent input (from the proprioceptive, visual and vestibular systems) and stable upright postures of the head and neck [28] and the fact that there exists a plethora of mechanoreceptors in the cervical spine soft tissues providing necessary neurophysiological input in a feed forward and feedback system provides a strong fundamental physiological basis for the concept that altered spine alignment can have a profound effect on sensorimotor control via connections to the vestibular, visual and central nervous systems [29]. Furthermore, and as explicitly stated in the introduction to this chapter, a complex network of neurophysiological connections between cervical spine mechanoreceptors and the sympathetic nervous system exists [30–32]. This information coupled with the findings of both case control investigations [34] and randomized trials [10, 11, 63, 79] provides strong clinical evidence that restoring normal sagittal plane posture and cervical spine alignment is important for a better afferentation process, improved sensorimotor control, and improved autonomic nervous system function.

Clinically, the astute reader should recognize the need to radiographically assess the full spine alignment, in particular the sagittal plane, to identify if a patient is a candidate and in need of true spine correction; that is, structural rehabilitation of the spine and posture. A comparison of the patient's spine and posture should be made against tested normal alignment values such as the Harrison full spine model and posture displacement models discussed herein. Furthermore, the addition of fundamental neurophysiological testing and the basic parts of sensorimotor control measurements should be considered as important assessments during patient evaluations. Once an indication for corrective care has been identified, the clinical administration of specific spine mirror image corrective exercises and extension traction methods should be employed. Previously, we have discussed the techniques, indications and contraindications, timing of, and applications for several known spine corrective methods and the clinician should be willing to add these to their armamentarium for patient care; we refer the reader to this source [35]. Adding the goal and methods of true spine correction to the clinical outcomes of patient care should not be foreign, it should not be in disregard to traditional strength and functional conditioning; it should simply be part of the basic, fundamental treatment approach for abnormalities of the human frame in the effort to improve a variety of spine related and neurophysiological disorders.

7. Conclusion

This chapter has explored the hypothesis and evidence that restoring normal posture and spine alignment has important influences on neurophysiology, sensorimotor control and autonomic nervous system functionality. There is limited but high-quality research identifying that sagittal spine alignment restoration plays an important role in improving neurophysiology, sensorimotor control, and autonomic

nervous system function. Within the limitations of the fact that only a handful of clinical trials exist on the topics discussed in this chapter, the unique contribution and importance of this review is that it demonstrates that radiographic determined re-alignment of the sagittal spine and posture plays a significant role in long-term management outcomes in people suffering from a variety of musculoskeletal, and health related disorders. Improved neurophysiological function as measured via dermatomal somatosensory evoked potentials, spinal cord velocity (N13-N20 potential), sensorimotor control, and sympathetic nervous system activity is directly influenced by and improved by full spine sagittal alignment in general and, more specifically, to cervical posture and spine alignment. This review identifies main issues that warrant further investigations to elucidate primary interactions and to identify ideal populations that would benefit from structural rehabilitation of the spine and posture techniques as discussed herein.

Conflict of interest

PAO is a paid consultant to CBP; DEH teaches spine rehabilitation methods and sells products related to the treatment of spine deformities. IMM has nothing to declare.

Nomenclature

AP	Anterior–posterior
BBS	Biodex Balance System SD
CBP	Chiropractic BioPhysics®
CDLR	Chronic discogenic lumbar radiculopathy
CIP	Cord interstitial pressure
CNS	Central nervous system
CROM	Cervical range of motion
CSM	Cervical spondylotic myelopathy
CTS	Carpal tunnel syndrome
DSSEPs	Dermatomal somatosensory evoked potentials
EMG	Electromyography
FHP	Forward head posture
HRA	Head repositioning accuracy
MAP	Mean arteriole pressure
ML	Medial-lateral
MRI	Magnetic resonance imaging
NHP	Neutral head position
N13-N20	Central conduction time
OSI	Overall stability index
PD	Parkinson's disease
RCT	Randomized controlled trial
SPNT	Smooth pursuit neck torsion
SSR	Sympathetic skin resistance
TENS	Transcutaneous electrical nerve stimulation
THK	Thoracic hyper-kyphosis
TN	Trigeminal neuralgia
TS	Tourette's syndrome

IntechOpen

Author details

Paul A. Oakley^{1*}, Ibrahim M. Moustafa^{2,3} and Deed E. Harrison⁴

1 Private Practice, Newmarket, Ontario, Canada

2 Department of Physiotherapy, College of Health Sciences, University of Sharjah, Sharjah, UAE

3 Basic Science Department, Faculty of Physical Therapy, Cairo University, Naser City, Cairo, Egypt

4 CBP NonProfit, Inc., Eagle, Idaho, USA

*Address all correspondence to: docoakley.icc@gmail.com

IntechOpen

© 2021 The Author(s). Licensee IntechOpen. This chapter is distributed under the terms of the Creative Commons Attribution License (<http://creativecommons.org/licenses/by/3.0>), which permits unrestricted use, distribution, and reproduction in any medium, provided the original work is properly cited. 

References

- [1] Le Huec JC, Thompson W, Mohsinaly Y, Barrey C, Faundez A. Sagittal balance of the spine. *Eur Spine J.* 2019 Sep;28(9):1889-1905.
- [2] Shah AA, Lemans JV, Zavatsky J. Spinal Balance/Alignment - Clinical Relevance and Biomechanics. *J Biomech Eng.* 2019; May 2. doi: 10.1115/1.4043650. [Epub ahead of print]
- [3] Ling FP, Chevillotte T, Leglise A, Thompson W, Bouthors C, Le Huec JC. Which parameters are relevant in sagittal balance analysis of the cervical spine? A literature review. *Eur Spine J.* 2018;27(Suppl 1):8-15.
- [4] Patwardhan AG, Khayatzadeh S, Havey RM, Voronov LI, Smith ZA, Kalmanson O, Ghanayem AJ, Sears W. Cervical sagittal balance: a biomechanical perspective can help clinical practice. *Eur Spine J.* 2018;27(Suppl 1):25-38.
- [5] Le Huec JC, Saddiki R, Franke J, Rigal J, Aunoble S. Equilibrium of the human body and the gravity line: the basics. *Eur Spine J.* 2011;20 Suppl 5:558-563.
- [6] Roussouly P, Pinheiro-Franco JL. Biomechanical analysis of the spino-pelvic organization and adaptation in pathology. *Eur Spine J.* 2011;20 Suppl 5:609-618.
- [7] Harrison DE, Harrison DD, Troyanovich SJ, Harmon S. A normal spinal position: It's time to accept the evidence. *J Manipulative Physiol Ther.* 2000;23:623-644.
- [8] Breig A. *Biomechanics of the central nervous system.* Stockholm, Almquist & Wicksell, 1960.
- [9] Breig A. *Adverse mechanical tension in the central nervous system.* Stockholm, Almquist & Wicksell, 1978.
- [10] Moustafa IM et al. Demonstration of autonomic nervous system function and cervical sensorimotor control after cervical lordosis rehabilitation in patients with chronic nonspecific neck pain: A randomized controlled trial. *J Athletic Training.* 2021; In Press.
- [11] Moustafa IM, Walton LM, Raigangir V, Shousha TM, Harrison D. Reduction of posture hyperkyphosis improves short- and long-term outcomes in patients with neck pain. Abstract In *J Orthop Sports Phys Ther.* 2020;50(1):CSM143.
- [12] Moustafa IM, Diab AAM, Hegazy FA, Harrison DE. Does rehabilitation of cervical lordosis influence sagittal cervical spine flexion extension kinematics in cervical spondylotic radiculopathy subjects? *J Back Musculoskelet Rehabil.* 2017, 30: 937-941.
- [13] Moustafa IM, Diab AA, Taha S, Harrison DE. Addition of a Sagittal Cervical Posture Corrective Orthotic Device to a Multimodal Rehabilitation Program Improves Short- and Long-Term Outcomes in Patients with Discogenic Cervical Radiculopathy. *Arch Phys Med Rehabil.* 2016, 97: 2034-2044.
- [14] Moustafa IM, Diab AA, Harrison DE. Does improvement towards a normal cervical sagittal configuration aid in the management of lumbosacral radiculopathy: A randomized controlled trial Proceedings of the 13th World Federation of Chiropractic Biennial Congress / ECU Convention, Athens, Greece, May 13-16, 2015. Paper #184 Mediterranean Region Award Winning Paper.
- [15] Moustafa IM, Diab AA. Extension traction treatment for patients with discogenic lumbosacral radiculopathy: a randomized controlled trial. *Clin Rehabil.* 2012; Jan;27(1):51-62.

- [16] Moustafa IM, Diab AM, Ahmed A, Harrison DE. The efficacy of cervical lordosis rehabilitation for nerve root function, pain, and segmental motion in cervical spondylotic radiculopathy. *PhysioTherapy* 2011; 97 Supplement: 846-847.
- [17] Berry RH, Oakley PA, Harrison DE. Is one cause of trigeminal neuralgia subluxation of craniocervical posture? A CBP® case report. *J Contemporary Chiro.* 2020;3:28-35.
- [18] Haas JW, Oakley PA, Harrison DE. Cervical pseudo-scoliosis reduction and alleviation of dystonia symptoms using Chiropractic BioPhysics® (CBP®) technique: A case report with a 1.5-year follow-up. *J Contemp Chiropr.* 2019; 2:131-137.
- [19] Anderson JM, Oakley PA, Harrison DE. Improving posture to reduce the symptoms of Parkinson's: a CBP® case report with a 21 month follow-up. *J Phys Ther Sci.* 2019 Feb;31(2):153-158.
- [20] Breton PY, Oakley PA, Harrison DE. Complete resolution of carpal tunnel syndrome after relieving the 'first crush' in 'double crush syndrome' by improving the cervical spine posture: A CBP® case report. *J Contemp Chiropr.* 2018; 2:49-53.
- [21] Oakley PA, Harrison DE, Haas JW, Listenmaa SK. Positive Outcome with Tourette Syndrome and Chronic Tic Disorder Following Chiropractic Intervention: a Chiropractic Biophysics® (CBP) Case Report with a 13-year follow-up. *Chiropr J Australia.* 2017; 45(4):368-376.
- [22] Oakley P, Harrison D. Restoration of barefoot gait in a 75-year old female with cervical spondylotic myelopathy: A case report utilizing Chiropractic BioPhysics (CBP®) technique. *Chiropr J Australia.* 2017; 45(1):16-27.
- [23] Berry RH, Oakley P, Harrison D. Alleviation of radiculopathy by structural rehabilitation of the cervical spine by correcting a lateral head translation posture (-TxH) using Berry translation traction as a part of CBP methods: A case report. *Chiropr J Australia.* 2017; 45(1):63-72.
- [24] Wickstrom BM, Oakley PA, Harrison DE. Non-surgical relief of cervical radiculopathy through reduction of forward head posture and restoration of cervical lordosis: a case report. *J Phys Ther Sci.* 2017 Aug;29(8):1472-1474.
- [25] Oakley PA, Harrison DE. Lumbar extension traction alleviates symptoms and facilitates healing of disc herniation/sequestration in 6-weeks, following failed treatment from three previous chiropractors: a CBP® case report with an 8 year follow-up. *J Phys Ther Sci.* 2017 Nov;29(11):2051-2057.
- [26] Breig A. Skull traction and spinal cord injury. A new approach to improved rehabilitation. New York, Springer-Verlag. 1989.
- [27] Artz NJ, Adams MA, Dolan P. Sensorimotor function of the cervical spine in healthy volunteers. *Clin Biomech.* 2015;30: 260-268.
- [28] Treleaven J. Sensorimotor disturbances in neck disorders affecting postural stability, head and eye movement control. *Man Ther.* 2008; 13: 2-11.
- [29] Riemann BL, Lephart SM. The Sensorimotor System, Part II: The Role of Proprioception in Motor Control and Functional Joint Stability. *J Athl Train.* 2002; 37: 80-84.
- [30] Hellström F, Roatta S, Thunberg J, Passatore M, Djupsjöbacka M. Responses of muscle spindles in feline dorsal neck muscles to electrical stimulation of the cervical sympathetic nerve. *Exp brain Res.* 2005; 165: 328-342.

- [31] Corneil BD, Olivier E, Munoz DP. Neck Muscle Responses to Stimulation of Monkey Superior Colliculus. II. Gaze Shift Initiation and Volitional Head Movements. *J Neurophysiol.* 2002; 88: 2000-2018.
- [32] Bolton PS, Kerman IA, Woodring SF, Yates BJ. Influences of neck afferents on sympathetic and respiratory nerve activity. *Brain Res Bull.* 1998; 47: 413-419.
- [33] Budgell BS. Reflex effects of subluxation: the autonomic nervous system. *J Manipulative Physiol Ther.* 2000; 23: 104-106.
- [34] Moustafa IM, Youssef A, Ahbouch A, Tamim M, Harrison DE. Is forward head posture relevant to autonomic nervous system function and cervical sensorimotor control? Cross sectional study. *Gait Posture.* 2020; 77:29-35.
- [35] Oakley PA, Moustafa IM, Harrison DE. Restoration of cervical and lumbar lordosis: CBP® methods overview. In: Bettany-Saltikov J. *Spinal Deformities in Adolescents, Adults and Older Adults.* IntechOpen Publishers. 2020; Pp.1-19.
- [36] Harrison DD, Janik TJ, Harrison GR, et al. Chiropractic biophysics technique: a linear algebra approach to posture in chiropractic. *J Manipulative Physiol Ther.* 1996, 19: 525-535.
- [37] Oakley PA, Harrison DD, Harrison DE, Haas JW. Evidence-based protocol for structural rehabilitation of the spine and posture: review of clinical biomechanics of posture (CBP) publications. *J Can Chiropr Assoc.* 2005; 49(4):270-296.
- [38] Harrison DE, Harrison DD, Hass JW. *Structural rehabilitation of the cervical spine.* Evanston, WY: Harrison CBP® Seminars, Inc., 2002.
- [39] Harrison DE, Betz JW, Harrison DD, et al. *CBP structural rehabilitation of the lumbar spine: Harrison Chiropractic Biophysics Seminars,* 2007.
- [40] Harrison DD, Janik TJ, Troyanovich SJ, Holland B. Comparisons of Lordotic Cervical Spine Curvatures to a Theoretical Ideal Model of the Static Sagittal Cervical Spine. *Spine.* 1996;21(6):667-675.
- [41] Harrison DD, Janik TJ, Troyanovich SJ, Harrison DE, Colloca CJ. Evaluations of the Assumptions Used to Derive an Ideal Normal Cervical Spine Model. *J Manipulative Physiol Ther.* 1997;20(4):246-256.
- [42] Harrison DD, Harrison DE, Janik TJ, Cailliet R, Haas JW, Ferrantelli J, Holland B. Modeling of the Sagittal Cervical Spine as a Method to Discriminate Hypo-Lordosis: Results of Elliptical and Circular Modeling in 72 Asymptomatic Subjects, 52 Acute Neck Pain Subjects, and 70 Chronic Neck Pain Subjects. *Spine.* 2004;29:2485-2492.
- [43] Harrison DE, Janik TJ, Harrison DD, Cailliet R, Harmon S. Can the thoracic kyphosis be modeled with a simple geometric shape? The results of circular and elliptical modeling in 80 asymptomatic subjects. *J Spinal Disord.* 2002;15(3):213-220.
- [44] Harrison DE, Harrison DD, Janik TJ, Cailliet R, Haas JW. Do alterations in vertebral and disc dimensions affect an elliptical model of the thoracic kyphosis? *Spine.* 2003;28(5):463-469.
- [45] Troyanovich SJ, Cailliet R, Janik TJ, Harrison DD, Harrison DE. Radiographic mensuration characteristics of the sagittal lumbar spine from a normal population with a method to synthesize prior studies of lordosis. *J Spinal Disord.* 1997;10(5):380-386.

- [46] Janik TJ, Harrison DD, Cailliet R, Troyanovich SJ, Harrison DE. Can the Sagittal Lumbar Curvature be Closely Approximated by an Ellipse? *J Orthop Res.* 1998;16(6):766-770.
- [47] Harrison DD, Cailliet R, Janik TJ, Troyanovich SJ, Harrison DE, Holland B. Elliptical Modeling of the Sagittal Lumbar Lordosis and Segmental Rotation Angles as a Method to Discriminate Between Normal and Low Back Pain Subjects. *J Spinal Disord.* 1998;11(5):430-439.
- [48] Harrison DE, Harrison DD, Cailliet R, Troyanovich SJ, Janik TJ, Holland B. Cobb method or Harrison posterior tangent method: which to choose for lateral cervical radiographic analysis. *Spine.* 2000;25(16):2072-2078.
- [49] Harrison DE, Cailliet R, Harrison DD, Janik TJ, Holland B. Centroid, Cobb or Harrison posterior tangents: which to choose for analysis of thoracic kyphosis? *Spine.* 2001;26(11):E227-E234.
- [50] Harrison DE, Cailliet R, Harrison DD, Janik TJ, Holland B. Radiographic analysis of lumbar lordosis: Cobb method, centroidal method, TRALL or Harrison posterior tangents? *Spine.* 2001;26(11):E235-E242.
- [51] Harrison DE, Holland B, Harrison DD, Janik TJ. Further reliability analysis of the Harrison radiographic line drawing methods: Crossed ICCs for lateral posterior tangents and AP Modified-Riser Ferguson. *J Manipulative Physiol Ther.* 2002;25:93-98.
- [52] Harrison DE, Harrison DD, Colloca CJ, et al. Repeatability over time of posture, radiograph positioning, and radiograph line drawing: An analysis of six control groups. *J Manipulative Physiol Ther.* 2003;26:87-98.
- [53] McAviney J, Schulz D, Bock R, Harrison DE, Holland B. Determining the relationship between cervical lordosis and neck complaints. *J Manipulative Physiol Ther.* 2005;28(3):187-193.
- [54] Harrison DD, Jackson BL, Troyanovich S, Robertson G, de George D, Barker WF. The efficacy of cervical extension-compression traction combined with diversified manipulation and drop table adjustments in the rehabilitation of cervical lordosis: a pilot study. *J Manipulative Physiol Ther.* 1994;17(7):454-464.
- [55] Harrison DE, Harrison DD, Cailliet R, Janik TJ, Holland B. Changes in sagittal lumbar configuration with a new method of extension traction: non-randomized clinical control trial. *Arch Phys Med Rehab.* 2002;83(11):1585-1591.
- [56] Harrison DE, Cailliet R, Harrison DD, Janik TJ, Holland B. New 3-Point bending traction method of restoring cervical lordosis combined with cervical manipulation: non-randomized clinical control trial. *Arch Phys Med Rehab.* 2002;83(4):447-453.
- [57] Harrison DE, Harrison DD, Betz J, Colloca CJ, Janik TJ, Holland B. Increasing the cervical lordosis with seated combined extension-compression and transverse load cervical traction with cervical manipulation: non-randomized clinical control trial. *J Manipulative Physiol Ther.* 2003;26(3):139-151.
- [58] Harrison DE, Harrison DD, Haas JW, Betz JW, Janik TJ, Holland B. Conservative methods to correct lateral translations of the head: a non-randomized clinical control trial. *J Rehab Res Devel.* 2004;41(4):631-640.
- [59] Harrison DE, Cailliet R, Betz JW, Harrison DD, Haas JW, Janik TJ, Holland B. Harrison mirror image methods for correcting trunk list: a non-randomized clinical control trial. *Eur Spine J.* 2005;14(2):155-162.

- [60] Diab AA, Moustafa IM. Rehabilitation for pain and lumbar segmental motion in chronic mechanical low back pain: a randomized trial. *J Manipulative Physiol Ther.* 2012;35(4):246-253.
- [61] Diab AA, Moustafa IM. The efficacy of lumbar extension traction for sagittal alignment in mechanical low back pain. a randomized trial. *J Back Musculoskeletal Rehabil.* 2013;26(2):213-222.
- [62] Moustafa IM. Does improvement towards a normal cervical configuration aid in the management of fibromyalgia. A randomized controlled trial. *Bull Fac Phys Ther Cairo Univ.* 2013;18(2):29-41.
- [63] Moustafa IM, Diab AA, Hegazy F, Harrison DE. Does improvement towards a normal cervical sagittal configuration aid in the management of cervical myofascial pain syndrome: a 1- year randomized controlled trial. *BMC Musculoskeletal Disord.* 2018;19(1):396.
- [64] Moustafa IM, Diab AA, Harrison DE. The Effect of Normalizing the Sagittal Cervical Configuration for the Management of Cervicogenic Headaches: A 2-Year Pilot Randomized Controlled Trial. *J Rehabilitation Med.* 2021; In Press.
- [65] Lee SH, Kim KT, Seo EM, Suk KS, Kwack YH, Son ES. The influence of thoracic inlet alignment on the craniocervical sagittal balance in asymptomatic adults. *J Spinal Disord Tech.* 2011;25(2):E41-E47.
- [66] Vrtovec T, Janssen MM, Likar B, Castelein RM, Viergever MA, Pernuš F. Evaluation of pelvic morphology in the sagittal plane. *Spine J.* 2013;13(11):1500-1509.
- [67] Panjabi MM, White III AA. *Biomechanics in the musculoskeletal system.* New York: Churchill Livingstone, 2001.
- [68] McCormick PC, Stein BM. Functional anatomy of the spinal cord and related structures. *Neurosurgery Clinics of North America.* 1990;1:469-489.
- [69] Panjabi MM, White III AA. Biomechanics of nonacute cervical spinal cord trauma. *Spine.* 1988;13:838-842.
- [70] Raynor RB, Koplik B. Cervical cord trauma. the relationship between clinical symptoms and force of injury. *Spine.* 1985;10:193-197.
- [71] Breig A. Overstretching of and circumscribed pathological tension in the spinal cord: A basic cause of symptoms in cord disorders. *J of Biomech.* 1970;3:7-9.
- [72] Stein JS. Failure of magnetic resonance imaging to reveal the cause of a progressive cervical myelopathy related to postoperative spinal deformity. *Am J Phys Med Rehab.* 1997;76:73-75.
- [73] Breig A, Turnbull I, Hassler O. Effects of mechanical stresses on the spinal cord in cervical spondylosis: A study on fresh cadaver material. *J Neurosurg.* 1966;25:45-56.
- [74] Harrison DE, Cailliet R, Harrison DD, Troyanovich SJ, Harrison SO. A review of biomechanics of the central nervous system Part II: Spinal cord strains from postural loads. *J Manipulative Physiol Ther.* 1999;22:322-332.
- [75] Breig A, Marions O. Biomechanics of the lumbosacral nerve roots. *Acta Radiologica Diagnosis* 1963;1: 1141-1160.
- [76] Jarzem PF, Quance DR, Doyle DJ, Begin LR, Kostuik JP. Spinal cord tissue pressure during spinal cord distraction in dogs. *Spine.* 1992 Aug;17(8 Suppl): S227-S234.

[77] Harrison DE, Cailliet R, Harrison DD, Troyanovich SJ, Harrison SO. A review of biomechanics of the central nervous system-- Part III: spinal cord stresses from postural loads and their neurologic effects. *J Manipulative Physiol Ther.* 1999;22(6):399-410.

[78] Moustafa IM, Diab AAM, Taha S, Harrison DE. Demonstration of central conduction time and neuroplastic changes after cervical lordosis rehabilitation in asymptomatic subjects: A randomized, placebo-controlled trial. Proceedings of the 14th biennial congress of the World Federation of Chiropractic, March 15-18, 2017.

[79] Moustafa IM, Diab AA, Harrison DE: The effect of normalizing the sagittal cervical configuration on dizziness, neck pain, and cervicocephalic kinesthetic sensibility: a 1-year randomized controlled study. *Eur J Phys Rehabil Med.* 2017, 53: 57-71.

[80] Tousignant M, Duclos E, Laflèche S, Mayer A, Tousignant-Laflamme Y, Brosseau L, et al. Validity study for the cervical range of motion device used for lateral flexion in patients with neck pain. *Spine.* 2002; 27: 812-817.

[81] Testerman C, Vander Griend R. Evaluation of ankle instability using the Biodex Stability System. *Foot Ankle Int.* 1999;20:317-321.

[82] Schmitz R, Arnold B. Intertester and Intratester Reliability of a Dynamic Balance Protocol Using the Biodex Stability System, *J Sport Rehabil.* 1998; 7: 95-101.

[83] Tjell C, Rosenhall U. Smooth pursuit neck torsion test: a specific test for cervical dizziness. *Am J Otol.* 1998; 19: 76-81.