

We are IntechOpen, the world's leading publisher of Open Access books Built by scientists, for scientists

5,800

Open access books available

142,000

International authors and editors

180M

Downloads

Our authors are among the

154

Countries delivered to

TOP 1%

most cited scientists

12.2%

Contributors from top 500 universities



WEB OF SCIENCE™

Selection of our books indexed in the Book Citation Index
in Web of Science™ Core Collection (BKCI)

Interested in publishing with us?
Contact book.department@intechopen.com

Numbers displayed above are based on latest data collected.
For more information visit www.intechopen.com



Pleural Effusion Secondary to Multiple Myeloma: Is Daratumumab an Effective Treatment? A Case Report

*Giulia Palazzo, Lara Aprile, Giacomo Cecere,
Vito Pier Gagliardi, Alessandro Maggi,
Antonella Prudeniano and Patrizio Mazza*

Abstract

Extramedullary (EM) plasmacytoma disease is an aggressive presentation at diagnosis and relapse for multiple myeloma (MM) patients. EM plasmacytoma is divided into two groups: the first group comprises tumors that extend directly from osteolytic bone lesions, while the second results from plasmacytoma infiltration into soft tissues, with no relation to the bone. Despite new therapies and monoclonal antibodies, the survival for patients with EM plasmacytoma is poor. The involvement of pleural effusion is uncommon in multiple myeloma.

Keywords: daratumumab, pleural effusion, extramedullary plasmacytoma, multiple myeloma, CD 38, PET/TC

1. Introduction

Solitary plasmacytoma (SP) is an infrequent form of plasma cell neoplasm according to literature data, accounting for between 5 and 10% of all plasma cell neoplasms.

It is characterized by the presence of neoplastic monoclonal plasma cells that do not have systemic distribution but gather in limited locations even if there is no systemic proliferative plasma cell disease.

We can divide it into two groups: solitary bone plasmacytoma (SBP) and extramedullary plasmacytoma (EMP).

When the localization is prevalent in the bones of the axial skeleton, skull type, vertebrae, etc., we speak of solitary plasmacytoma of the bone (SBP), while EMP, as a localization, is frequent in the nasal cavities and in the nasopharynx.

The mean age of patients with SBP or EMP, with a male–female ratio of SP 2:1, is 55 years.

With advancing age, the incidence rate increases exponentially while maintaining a lower incidence compared to multiple myeloma (MM).

In the black population, the impact of the SP is about 30% higher than that in the white population [1].

A better definition of the tumor mass can be obtained with the fluorodeoxyglucose-positron emission tomography (FDG-PET) or positron emission tomography-computed tomography (PET-CT) [2] that allows direct visualization of the tumor burden; combining the morphological images of the CT scan with a particular molecular process (depending on the radiopharmaceutical injected such as a glucose analogue, which is the most widely used) allows to evaluate the response to treatment and the prognosis of different cancers.

The limit of the skeletal X-ray investigation of the whole body (WBXR) is represented by showing only osteolysis related to the presence of MM cells, while the FDG-PET allows to view the tumor load.

Obviously, this investigation is not without limitations; one of which is the false-negative or false-positive result, which is possible if inflammatory or infectious processes are in progress or if subcentimetric lesions cannot be detected by FDG-PET.

Aid is provided by the combined CT component, which provides higher resolution bone images than those obtained with normal radiography.

Through a direct anatomical correlation of FDG uptake foci.

The systematic review reported by Van Lammeren-Venema et al. [3] also compared FDG-PET and FDG-PET/CT with WBXR and CT.

The detection rate of FDG-PET/CT, compared with WBXR, ranged from 1.27 to 1.45; specificity was low (29–50%) and sensitivity ranged from 67 to 100% when using WBXR as a reference test. Regelin et al. mentioned that FDG-PET underestimates rib lesions, as they could be detected by low-dose CT integrated into PET.

A limitation, to date not resolved, is the detection of cranial lesions that FDG-PET/CT does not detect due to the high absorption of FDG in the brain, while the identification of extramedullary disease was satisfactory with FDG-PET; this has been reported consistently in studies comparing FDG-PET/CT with WBXR.

In addition to FDG that is specific to glucose metabolism, other PET radiopharmaceuticals have been developed to visualize various biological processes; among these, we can mention ¹⁸F fluoride being reevaluated for skeletal imaging and the ¹¹C-methionine amino acid analogue and ¹¹C-choline, an analogue precursor of phosphatidylcholine, one of the main constituents of membrane lipids, which to date have only been evaluated in small series of patients with MM.

Multiple myeloma [4] is a clonal malignant plasma cell neoplasm that despite the development of new therapies that have improved the depth and duration of responses as well as survival, to date, remains incurable in most cases for many patients.

Understanding the biology of disease, technological advances, such as next-generation sequencing techniques, have shown that the disease is genetically extremely heterogeneous, and this has allowed us to stratify patients, based on risk, into different disease groups. This can significantly translate into the choice of therapy and clinical results.

Simultaneously with these new acquisitions, the therapeutic scenario has been completely revolutionized by the discovery of new therapeutic agents, including immunomodulatory drugs (IMiDs) such as lenalidomide and pomalidomide; proteasome inhibitors (PIs) including bortezomib, carfilzomib and ixazomib; monoclonal antibodies (MAbs) including daratumumab and elotuzumab; and histone deacetylase inhibitors such as panobinostat, which have helped improve the overall survival of patients with this disease.

The use of many new therapeutic agents, in addition to increasing therapeutic choices, has also changed our therapeutic reference models; in fact, over the years, the treatment of patients with this pathology has mainly been based on high-dose radiation, but today, in consideration of the new drugs available to us, studies are needed to evaluate their use and benefit also in this category of high-risk patients.

2. Case introduction

A 58-year-old woman was diagnosed asymptomatic Multiple Myeloma Ig G K, stage II (International staging system - ISS).

She first presented in March 2018 because about 15 days before she was admitted to the nephrology department for acute renal failure, macrohematuria, hydronephrosis, and renal colic.

For confirmation during hospitalization, the laboratory tests of the monoclonal component was sent to our clinic.

Physical examination was negative.

Blood chemistry tests revealed that protein electrophoresis showed a monoclonal spike (M spike) 1 g/dl; IgG tests 1000 mg/dl, IgM 34 mg/dl, IgA 44 mg/dl, serum kappa light chains 294 mg/dl, serum lambda light chains 24 mg/dl, urine kappa light chains 187 mg/L, urine lambda light chains <4.7 mg/dl, FLC ratio 58, beta 2 microglobulin: 4.3 mg/L, Hb 13 g/dl, normal creatinine and calcium, proteinuria 0.8 g/24 h, and microalbuminuria 68 mg/L.

At the evaluation of the bone biopsy, plasma cell clonality was equal to 10–40%. At the phenotypic analysis and morphological examination, plasma cell infiltrate was equal to 24% (**Table 1**).

The karyotype analysis was 46 XX normal karyotype, and the FISH study showed TP53 in 35% of the nuclei analyzed.

Whole-body MRI showed no bone lesions, and the total body CT was negative.

Therefore, we asked the patient to visit the clinic for periodic checks.

After one year from diagnosis, in May 2019, she reported back pain for which blood tests and instrumental tests TB CT and MRI were performed.

The total body CT showed the following: “In a context of widespread reduction in calcium content, suspicious osteostructural alterations due to secondary disease localization of the skeletal segments included in the study volume are not appreciated. Apex cuneiform deformation of the anterior trunk of D12, widespread spondyloarthrosis manifestations. No focal tomodensitometric alterations of current pathological significance affecting the lung parenchyma bilaterally. Non-ilo-mediastinal and laterocervical lymphadenomegaly. Non-pleural-pericardial effusion. No gross changes affecting the abdominal parenchymatous organs, distended bladder with regular walls, no adenomegaly at the level of the main abdominal-pelvic lymph node stations, no free abdominal fluid.”

Unlike the CT, the MRI of the abdomen showed the following: “collapse of D12 and pathological tissue with a paravertebral site with abdominal tissue formation that concentrically englobes the aorta and pleural effusion.”

The MRI of dorsal and lumbar spine showed the following: “at the level of the interbody space D11–D12, presence of posterior median disc protrusion, at the level of the interbody space D12–L1, presence of protrusion of the annulus fibrosus with posterior median expression.”

The spinal cord presents regular morphology and no pathological signal.

Immunophenotypic study in flow cytometry

Method used direct immunofluorescence

Antigens studied: CD19, CD38, CD 138, CD 56, CD 45

Result

Clonal myeloma plasma cells: CD 138+ CD 38++ CD19-CD56+ bright CD 45 neg = 24%

Table 1.
Phenotypic analysis of bone biopsy.

At the level of the interbody space L3-L4 and L5-S1, there was the presence of disc protrusion.

The body of D12 appears crushed and deformed into a wedge; the vertebral body itself exhibits a hypointense signal in the images in T1 as from the presence of spongiosa edema in vertebral distress, probably of a recently established post traumatic type; also, at the dorsal level, it is possible to document the presence of a sleeve that seems to envelop the vertebral structures, in the front and in the antero-lateral position bilaterally, and that extends from D12 to D5.

From the blood tests, the following data were gathered: lipase increase 995 U/L, monoclonal component: 2.6 gr/dl, creatinine 1 mg/dl, calcium 9.8 mg/dl, LDH 172 U/l, HB 12.49 g/dl, protein in the urine: 1, 4 g/24/h, urine kappa light chains 604 mg/L, beta 2 microglobulin 5.2 mg/dl, creatinine clearance 68 mm/h, serum K light chains 570 mg/dl, creatinine clearance 63 ml/min, microalbuminuria 98 mg/L, immunoglobulins IgG 1950 mg/dl, IgA immunoglobulins 20 mg/dL, IgM immunoglobulins 22 mg/dL.

The radiotherapy evaluation did not indicate treatment and she was treated with VTD (bortezomib 1.3 mg/m² days 1, 4, 8, 11, thalidomide 100 mg/day, and dexamethasone 40 mg days 1, 4, 8, 11) for six cycles, obtaining only temporary biochemical partial response but extramedullary progression with increased pleural effusion.

The total body PET/CT that was performed (3.12.19) highlighted the following: “presence of a very large area of net and inhomogeneous pathological hyperaccumulation of radio glucose coinciding with dense tissue on the co-registration CT, which is extended, in front of the rachis, from the first dorsal metamers (D3/D4) to the upper limiting of the soma of L5, displacing and, at times, partially incorporating the posterior mediastinal structures (esophagus) along its course, and, more completely, the large thoraco-abdominal vessels up to the aorto-iliac “carrefour,” with SUV max up to 9.7”

A circumscribed and apparently more isolated area of pathological hyperaccumulation is observed at the height of the right lung apex, in the paravertebral, at the level of D2.

Isolated pathological hyperaccumulations of radioglucose are found in the anterior mediastinum, coinciding with pleuro-pericardial pseudonodulation, at the height of the posterior aspect of the xiphoid, in the right parasternal in the context of the chest wall, in the form of two circumscribed areas of which the most voluminous with standardized uptake value max up to 7.0 and the other smaller max up to 5.7.

On an ancillary basis, the coregistration CT images include extensive pleural effusion on the right and relatively more modest on the left (**Table 2**).

We also decided to perform the phenotypic analysis on peripheral blood that showed plasma cell equal to 1.6%* (**Table 3**).

She repeated bone marrow biopsy that showed plasma cell infiltration on morphological examination equal to 70%, while the phenotypic analysis on bone marrow blood showed plasma cell CD138+ CD38++ CD19- CD56+ bright CD45 low with clonal kappa restriction of intracytoplasmic = 13%* (**Table 4**).

Therefore, we decided to subject the patient to therapy with cyclophosphamide (1.5 gr/die, day 1 and day 3) for debulking plus evacuative thoracentesis; unfortunately, we did not perform phenotypic study of the pleural fluid, and subsequently, we started therapy with daratumumab, lenalidomide, and dexamethasone (daratumumab was initiated at the standard dose of 16 mg/kg for week IV for 4 infusions plus lenalidomide 25 mg daily for 21 of 28 days, and dexamethasone 40 mg on week (Dara Rd).

The treatment was well tolerated and no pulmonary or hematological adverse events occurred.

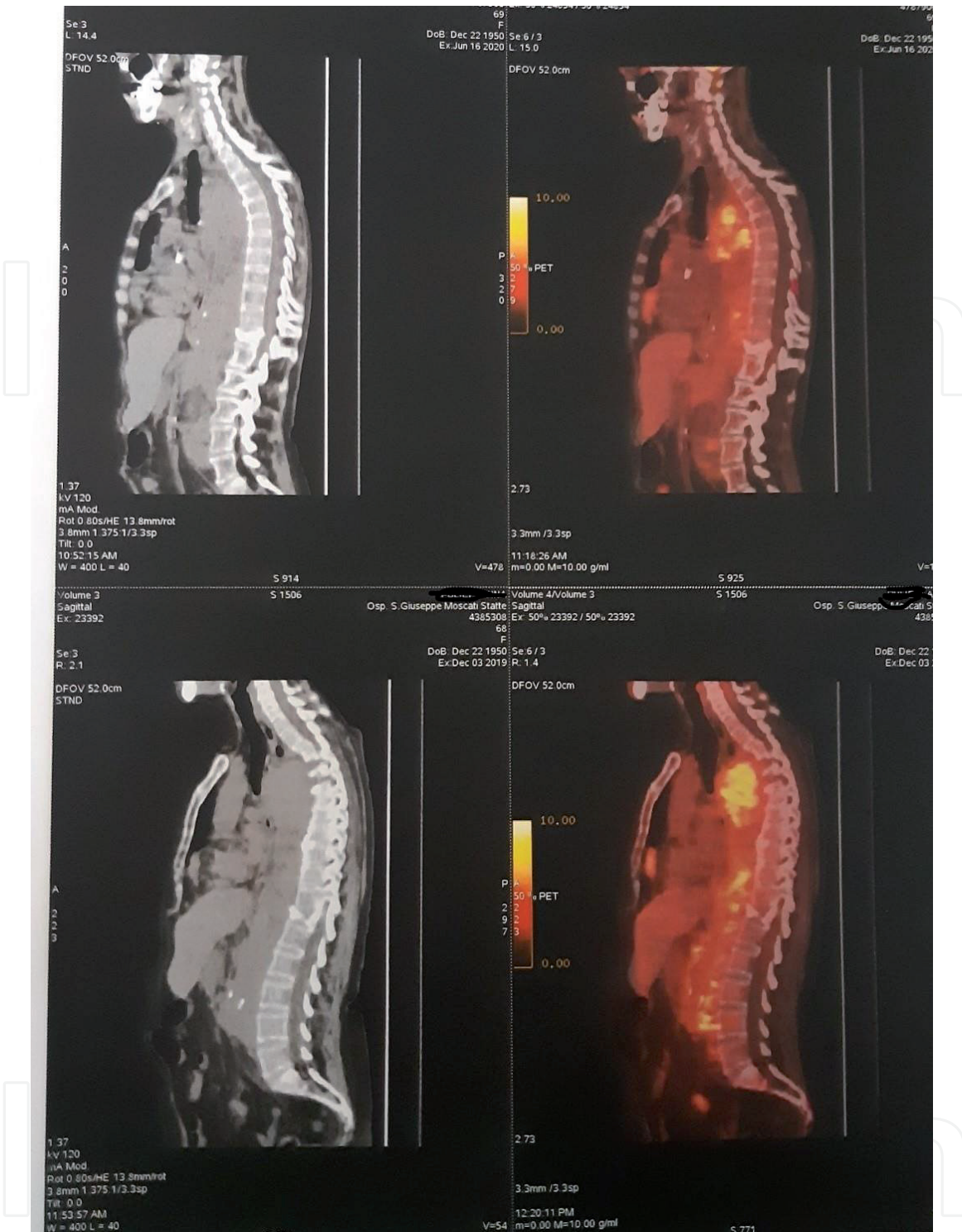


Table 2.
Image of PET.

Immunophenotypic study in flow cytometry
Method used direct immuno-fluorescence
Antigens studied: CD19, CD 20, CD 138, CD38, CD 56, CD 45, intracytoplasmatic chains kappa and lambda
Result
Mature lymphocytes = 8,6%
Clonal myeloma plasma cells: CD 138+ CD 38++CD19-CD56+ bright, CD 45 low with kappa clonal restriction = 1.6%

Table 3.
Phenotypic analysis on peripheral blood.

Immunophenotypic study in flow cytometry Method used direct immunofluorescence Antigens studied: CD19, CD 138, CD38, CD 56, chains kappa and lambda Result Mature lymphocytes = 20% Clonal myeloma plasma cells: CD 138+ CD 38++CD19-CD56+ bright, CD 45 low with kappa clonal restriction = 13%

Table 4.
Phenotypic analysis on bone marrow blood.

Immunophenotypic study in flow cytometry Method used direct immunofluorescence Antigens studied: CD3, CD3/4, CD 3/CD8, CD19, CD16–56, CD117, CD 138, CD38, CD45, intracytoplasmatic chains kappa and lambda Result Mature lymphocytes = 60% Clonal myeloma plasma cells: CD 138+ CD 38-, CD56+, CD 45 + heterogeneous, cy kappa + = 10%
--

Table 5.
Phenotypic analysis of pleural effusion.

Immunophenotypic study in flow cytometry Method used direct immunofluorescence Antigens studied: CD 19, CD 56, CD 138, CD38, CD45, cyVS38c. RESULT Mature lymphocytes = 40% Clonal myeloma plasma cells: CD 138+ CD 38-*, CD56 + bright, cyvs38c+, CD 19- = 7.5% *Therapy with Daratumumab
--

Table 6.
Phenotypic analysis of pleural effusion.

After one cycle of Dara Rd. therapy, for new reappearance of pleural effusion, the patient underwent thoracentesis, this time by performing the phenotypic analysis (**Table 5**).

While the plasma cells are absent for the reevaluation of the phenotypic study on peripheral blood, we continued the treatment until the fourth cycle.

After four cycles of therapy, we repeated PET/CT that was unfortunately compatible with persistence of disease.

The PET/CT showed persistence of a large area of hyperaccumulation of the tracer in coincidence of pathological tissue from D3 to L5 that incorporates the posterior mediastinal structures in its course.

Persistence of pathological accumulation in the anterior mediastinum, in the pleuro-pericardial region in increase compared to the previous examination, extending from the xiphoid to the anterior costophrenic recess, area of hyperaccumulation in the right parasternal and at the level of the mediastinal pleura close to the ascending aorta.

Despite the progression of disease, the CD38 negativity remained to the phenotypic reevaluation of the pleural fluid (**Table 6**).

3. Discussion

CD38 [5] is a transmembrane glycoprotein that is highly expressed on multiple myeloma cells and on normal lymphoid and myeloid cells albeit at low levels.

The mechanism of action is that of an ectoenzyme involved in the regulation of the intracytoplasmic concentration of calcium and of the catabolism of extracellular nucleotides.

The anti-CD38 fully human IgG1-k monoclonal antibody, daratumumab, carries out its cytotoxic effect through a series of mechanisms following binding to CD38, including antibody-dependent cell-mediated cytotoxicity (ADCC), complement-dependent cytotoxicity (CDC), antibody-dependent cell-mediated phagocytosis (ADCP), and direct induction of apoptosis, which are its main mechanisms of action.

Another effect of daratumumab recently described is its immunomodulatory action.

A phase I/II dose escalation study in 104 patients with relapsed or refractory multiple myeloma evaluated the safety of daratumumab.

The most common adverse events were grade 3 or 4 pneumonia and thrombocytopenia.

Two phase [5] III studies are evaluating patients with relapsed or refractory disease; one of these studies is comparing daratumumab plus bortezomib and dexamethasone versus bortezomib and dexamethasone and the other is comparing daratumumab plus lenalidomide and dexamethasone versus lenalidomide and dexamethasone.

Pending the final results of these studies, however, we want to underline how the CASTOR study (Velcade/dex vs. Dara/Velcade/dex) was interrupted early because at an interim analysis the study reached its final point with a ratio of very impressive risk of 0.39 in favor of the daratumumab arm. The POLLUX study (Rev/dex vs. Dara/Rev/dex) also showed similarly impressive results with a hazard ratio of 0.37 in favor of the Dara arm. Two further phase III studies are ongoing in patients with previously untreated multiple myeloma; one is comparing daratumumab plus bortezomib, melphalan, and prednisone with bortezomib, melphalan, and prednisone), and the other is evaluating daratumumab plus lenalidomide and dexamethasone with lenalidomide and dexamethasone.

We wanted to report this clinical case only to hypothesize a possible role of daratumumab in the treatment of extramedullary recurrences and above all its possible overcoming of the pleural barrier.

The selection of resistant clones is known in the course of myeloma recurrence, but the negativity/masking of CD 38 in the pleural fluid could demonstrate the overcoming of the pleural barrier by daratumumab.

Obviously we have no previous data, but the phenotypic analysis of the marrow and peripheral blood is the same for the other antigens evaluated.

Most likely, we should have performed a PET/CT at the onset of staging for a better evaluation of any extramedullary localization and perhaps choose different or more aggressive therapeutic treatments.

Molecular biology studies certainly in the near future will help us better understand which forms are most at risk and perhaps will guide us better in therapeutic choices.

But to date, the treatment of extramedullary plasmacytoma remains a therapeutic challenge even in the era of new drugs.

4. Conclusion

Despite significant progress in the treatment of multiple myeloma, the disease remains incurable in a vast majority of patients.

The approval of promising new agents will undoubtedly improve outcomes for myeloma patients.

Daratumumab is a monoclonal antibody that is now approved for treatment of multiple myeloma patients and has shown significant response in the real-world setting.

Our case illustrates the potential to overcome the pleural membrane and therefore a possible role also in the treatment of extramedullary localizations of multiple myeloma.

Acknowledgements

We thank the nursing staff of the Department of Hematology, Hospital San Giuseppe Moscati, Taranto, Italy, who collaborated in the production of this work and especially:

Luciana Angela Talo for the patient management and Elisabetta Leggieri and Tamburrano Addolorata for the therapy management.

Conflict of interest

The authors declare no conflict of interest.

Author details

Giulia Palazzo^{1*}, Lara Aprile¹, Giacomo Cecere¹, Vito Pier Gagliardi¹, Alessandro Maggi¹, Antonella Prudenzano² and Patrizio Mazza¹

¹ Department of Hematology, Hospital San Giuseppe Moscati, Taranto, Italy

² Laboratory of Hematology and Molecular Biology, Hospital San Giuseppe Moscati, Taranto, Italy

*Address all correspondence to: giuliapalazzo@libero.it

IntechOpen

© 2021 The Author(s). Licensee IntechOpen. This chapter is distributed under the terms of the Creative Commons Attribution License (<http://creativecommons.org/licenses/by/3.0>), which permits unrestricted use, distribution, and reproduction in any medium, provided the original work is properly cited. 

References

[1] Kilciksiz S, Karakoyun-Celik O, Agaoglu FY, Haydaroglu A. A review for solitary plasmacytoma of bone and extramedullary plasmacytoma. *The Scientific World Journal* [Internet]. Hindawi Limited; 2012;2012:1- 6. Available from: <http://dx.doi.org/10.1100/2012/895765>

[2] Zamagni E, Nanni C, Patriarca F, Englaro E, Castellucci P, Geatti O, et al. A prospective comparison of 18F-fluorodeoxyglucose positron emission tomography-computed tomography, magnetic resonance imaging and whole-body planar radiographs in the assessment of bone disease in newly diagnosed multiple myeloma. *Haematologica* [Internet]. Ferrata Storti Foundation (Haematologica); 2007 Jan 1;92(1):50-55. Available from: <http://dx.doi.org/10.3324/haematol.10554>

[3] Van Lammeren-Venema D, Regelink JC, Riphagen II, Zweegman S, Hoekstra OS, Zijlstra JM. 18F-fluorodeoxyglucose positron emission tomography in assessment of myeloma-related bone disease: A systematic review. *Cancer* [Internet]. Wiley; 2011 Sep 1;118(8):1971-1981. Available from: <http://dx.doi.org/10.1002/cncr.26467>

[4] Dingli D, Ailawadhi S, Bergsagel PL, Buadi FK, Dispenzieri A, Fonseca R, et al. Therapy for Relapsed Multiple Myeloma. *Mayo Clinic Proceedings* [Internet]. Elsevier BV; 2017 Apr;92(4):578-598. Available from: <http://dx.doi.org/10.1016/j.mayocp.2017.01.003>

[5] Husnain M, Kurtin S, Barkett N, Riaz IB, Agarwal A. Refractory IgD multiple myeloma treated with daratumumab: A case report and literature review. *Case Reports in Oncological Medicine* [Internet]. Hindawi Limited; 2016;2016:1-4. Available from: <http://dx.doi.org/10.1155/2016/2490168>