

We are IntechOpen, the world's leading publisher of Open Access books Built by scientists, for scientists

5,500

Open access books available

136,000

International authors and editors

170M

Downloads

Our authors are among the

154

Countries delivered to

TOP 1%

most cited scientists

12.2%

Contributors from top 500 universities



WEB OF SCIENCE™

Selection of our books indexed in the Book Citation Index
in Web of Science™ Core Collection (BKCI)

Interested in publishing with us?
Contact book.department@intechopen.com

Numbers displayed above are based on latest data collected.
For more information visit www.intechopen.com



Cerebrovascular Disease; A Leading Cause of Epilepsy

*Kaoru Obata, Kazuaki Sato, Hiroya Ohara
and Masako Kinoshita*

Abstract

Various types of cerebrovascular diseases can result in epilepsy in any age, especially in the elderly. Besides well-known cause of epilepsy as large cerebral infarction involving cerebral cortex and intracerebral hemorrhage, there are growing evidences of roles of subcortical infarction, chronic subdural hematoma, and superficial siderosis of the central nervous system in the pathogenesis of epilepsy. We review here the epidemiology and possible predictors of epilepsy in each type of cerebrovascular lesions and summarize the characteristics of semiology and electroencephalography findings in order to take early treatment strategy. Additionally, relevance of acute-symptomatic seizures and status epilepticus to epilepsy is discussed.

Keywords: epilepsy, cerebrovascular diseases, cerebral infarction, intracranial hemorrhage, stroke, provoked seizures, acute symptomatic seizures, early seizures, late seizures

1. Introduction

Various kinds of brain insults are associated with an increased risk for development of seizures and epilepsy. In adults, a probable etiology of approximately 50% of new-onset seizures can be determined. Cerebrovascular diseases are the most common risk factors of epilepsy (21%), followed by tumors (11%) and traumatic brain injury (7%) [1]. In children and adolescents of 0–19 years of age, the leading epilepsy etiologies are static encephalopathies (38.2%), stroke (12.1%), traumatic brain injury (11.4%), and infection (8.6%) [2].

The traditional definition of stroke is based on clinical characteristics of the sudden onset of loss of focal neurological dysfunction due to infarction or hemorrhage in the relevant part of the brain, retina, or spinal cord, lasting longer than 24 hours [3]. Stroke is classified into cerebral infarction, intracerebral hemorrhage, and subarachnoid hemorrhage (SAH).

Post-stroke seizures have been classified as either early seizures or late seizures, depending on the interval from stroke onset to seizure onset. In the field of stroke, the latent period of two weeks has been most commonly used to distinguish between early seizures and late seizures [4]. Approximately 5–10% of patients with stroke present early seizures within the first two weeks and about half of them occur during the first day after the stroke [5, 6]. In the field of epilepsy, the International League Against Epilepsy (ILAE) proposes a recommendation to define

acute symptomatic seizures as seizures occurring within one week subsequent to acute damage to the brain, caused by such as stroke, traumatic brain injury, anoxic encephalopathy, and intracranial surgery [7]. Seizures occurring at least two weeks after stroke are called late or remote symptomatic seizures [4, 8]. Epilepsy is a brain disorder with an enduring preposition to generate epileptic seizures, usually applicable to patients having two or more unprovoked seizures occurring at least 24 hours apart. In addition, ILAE updated the practical definition of epilepsy in 2014 to apply also to a condition of one unprovoked (or reflex) seizure and a probability of further seizures similar to the general recurrence risk (at least 60%) after two unprovoked seizures, occurring over the next 10 years [9]. Therefore, occurrence of an unprovoked late seizure is necessary and sufficient for the diagnosis of post-stroke epilepsy (PSE) because of a high risk of recurrence; such patients are recommended to be treated with antiepileptic medication under the diagnosis of epilepsy [9].

Depending on the type of underlying cerebrovascular disease, 3–30% of patients who experience stroke may develop PSE [10]. The risk to develop epilepsy after stroke is the highest during the first two years, but still elevated even 10 years after stroke [11].

Status epilepticus is a medical emergency that has high mortality rate (approximately 20%) [12]. Classically status epilepticus was defined as a condition characterized by an epileptic seizure sufficiently prolonged or repeated at sufficiently brief intervals so as to produce an unvarying and enduring epileptic condition. In 2015, ILAE proposed the new definition of status epilepticus as follows. Status epilepticus is a condition resulting either from the failure of the mechanisms responsible for seizure termination or from the initiation of mechanisms, which lead to abnormally, prolonged seizures (after time point t_1). It is a condition, which can have long-term consequences (after time point t_2), including neuronal death, neuronal injury, and alteration of neuronal networks, depending on the type and duration of seizures. Because of incomplete evidence, each time point should be considered as the best estimates currently available. In the case of convulsive status epilepticus, t_1 at 5 minute and t_2 at 30 minutes are suggested based on animal experiments and clinical research [13]. Patients with status epilepticus rarely recover spontaneously; therefore they should be treated with antiepileptic drugs as soon as possible.

Status epilepticus occurs in 1.5–2.8% of stroke patients [14, 15]. In the older adults (≥ 65 years of age), 52.3% of status epilepticus are caused by stroke [16]. In the older adults (≥ 60 years of age), semiology of status epilepticus is less frequently generalized tonic–clonic seizures compared to younger adults (33% vs. 63%, $p = 0.001$); on the other side, non-convulsive status epilepticus with coma are exclusively seen in older patients (10.3% vs. 0%, $p = 0.02$) [17]. In this chapter, we reviewed the epidemiology and possible predictors of epilepsy in each type of cerebrovascular diseases. The characteristics of semiology and electroencephalography (EEG) findings which enable us to take early treatment strategy are summarized. Relevance of acute-symptomatic seizures and status epilepticus to epilepsy is also discussed.

2. What kinds of vascular lesions can cause epilepsy?

2.1 General risk factors of poststroke seizures and epilepsy

Cerebrovascular disease is the most common etiology of acute symptomatic seizures and secondary epilepsy in adults, accounting for approximately 11% of epilepsy diagnosis [18].

All types of cerebrovascular diseases can cause early or late seizures. Among them, the common causes of epilepsy are cerebral infarction, intracerebral hemorrhage, and SAH (**Table 1**). As a genetic risk factor of PSE, the relationship between PSE and the ALDH2 (aldehyde dehydrogenase 2) rs671 polymorphism is known [48].

The risk factors for early seizures after stroke include intracerebral hemorrhage, cerebral infarction with hemorrhagic transformation, stroke severity, and alcoholism [49].

The risk factors for PSE include cortical involvement (visual neglect, dysphagia, field defect, and so on), stroke severity indices at presentation, including low Glasgow Coma Scale, incontinence, or poor Barthel Index, hemorrhagic lesions, young age (< 65 years), and stroke subtype, particularly total anterior circulation infarcts [11]. Abaira et al. pointed that NIHSS score more than 4 at the stroke presentation and post-stroke status epilepticus duration more than 16 hours might predict of PSE in patients with early-onset post-stroke status epilepticus [50].

2.2 Cerebral infarction

Cerebral infarction can occur at any age, with the greatest risk being during the first week after birth. In adults, about 70–85% of cerebrovascular diseases are ischemic. Etiological subtypes of cerebral infarction are classified according to the TOAST classification (**Table 2**) [51], the ASCOD phenotyping system [52], and the Causative Classification System [53]. Most cases of PSE are due to arterial ischemic stroke [54], accounting for up to 9% of incident cases of epilepsy [55].

In ASCOD, every patient should be graded using 5 categories: A (atherosclerosis); S (small-vessel disease); C (cardiac pathology); O (other cause), and D (dissection) [52]. With the Causative Classification System classification of ischemic stroke etiology, ischemic stroke is classified as the following; large artery atherosclerosis, cardio-aortic embolism, small artery occlusion, other causes, and undetermined causes [53].

	Early seizure	Late seizure	Epilepsy
Cerebral infarction	4.8% [6]	3.8% [6]	2.0–4.0% [5, 19–21]
Intracerebral hemorrhage	31% [22]	4.0–11.8% [23, 24]	8.1–13.5% [4, 25]
Subarachnoid hemorrhage	Up to 20% [26]	2.0–5.5% [27]	3.1–25% [28–30],
Acute subdural hematoma ^a	24–36% [31–33]	42–44% [31–33]	58.3% [34]
Chronic subdural hematoma	3.6–42% [33]	1.6–30.7% [33, 35, 36]	4.3–6.9% [37, 38]
Acute epidural hematoma ^a	41% [39]	0% [39]	71.4% [34]
Cerebral venous thrombosis	34.0–46.7% [40–42]	11% [43]	5.2% [42]
Arteriovenous malformation	26.2% ^b [44]	26–35% [44]	67–72% [44]
Arteriovenous fistula	NA	NA	2.7% ^c [45]
Cavernous angioma	NA	NA	32.1% ^d [46]
Moyamoya disease	NA	NA	7.7% [47]

NA: not available.

^aPost-traumatic seizure/epilepsy.

^bSeizures with hemorrhage at presentation.

^cRatio of convulsion.

^dRatio of seizures.

Table 1.
 Prevalence of early seizure, late seizure, and epilepsy in each cerebrovascular disease.

Large-artery atherosclerosis (embolus/thrombosis) [*]
Cardioembolism
Small-vessel occlusion (lacune) [*]
Stroke of other determined etiology
Stroke of undetermined etiology
a. Two or more causes identified
b. Negative evaluation
c. Incomplete evaluation
[*] Possible or probable depending on results of ancillary studies.

Table 2.
The TOAST classification of subtypes of acute ischemic stroke [51].

Early seizure occurrence is associated with hemorrhagic transformation and stroke severity. Late seizure is associated with cortical involvement and stroke severity [56]. The SeLECT score is proposed to predict the risk of late seizures after ischemic stroke, using only five well-defined parameters (Severity of stroke, Large-artery atherosclerotic etiology, Early seizures, Cortical involvement, and Territory of middle cerebral artery involvement) [57]. The overall risk of late seizures was 4% at 1 year and 8% at 5 years after stroke. Based on the estimation, patients with the SeLECT value of 7 points or more have more than 60% risk of seizures within 5 years after stroke, which is higher than the practical definition of epilepsy by ILAE (at least 60% over the next 10 years) [9], even though the patients have no unprovoked seizures. The risk factors for epilepsy after ischemic stroke include early seizures, stroke severity, stroke subtype, stroke location (anterior circulation infarct and cortical involvement), stroke recurrence, artery dissection and established coronary disease [56, 58]. Patients receiving thrombolytic or intra-arterial reperfusion therapies for acute ischemic stroke are at higher risk of epilepsy [59]. Post-stroke seizures can be sometimes associated with small vessel disease. The risk of developing seizures is more strongly related to the localization of lacunar infarctions in the hemispheric white matter (leukoaraiosis) than in the basal ganglia or in the brain stem [60]. Branch atheromatous disease could also have an association with late seizures [61].

2.3 Intracerebral hemorrhage

Early seizures were seen in 31% of patients with spontaneous intracerebral hemorrhage who were evaluated with continuous electroencephalographic monitoring and over half had purely electrographic seizures only [22]. The incidence of PSE after intracerebral hemorrhage is between 8.1 and 13.5% [4, 25]. Seizures secondary to intracerebral hemorrhage are relatively common like this and likely underdiagnosed event that may have little impact on in-hospital mortality and morbidity [62]. Nonconvulsive electrographic seizures may be associated with hematoma expansion [22].

The risk factors for seizures following intracerebral hemorrhage are associated with hemorrhage volume, hemorrhage location within the cerebrum, cortical involvement and the severity of neurological deficits [10]. Surgery for an intracerebral hemorrhage is an additional risk for the development of late seizures [63].

For patients with spontaneous intracerebral hemorrhage, clinical early seizures should be treated with antiepileptic drugs [64]. When the patients have a change in mental status, the evaluation with EEG is recommended. If the patients have electrographic seizures on EEG, they should be treated with antiepileptic drugs [64].

Current clinical guidelines do not recommend the routine use of prophylactic antiepileptic drugs for spontaneous intracerebral hemorrhage [64] because there is no evidence to improve neurological function [65].

Periodic discharges on EEG could be associated with cortical intracerebral hemorrhage and poor outcome [22].

2.4 Subarachnoid hemorrhage

Early seizures may be seen in up to 20% of patients after aneurysmal SAH, and more commonly in association with intracerebral hemorrhage, hypertension, and middle cerebral and anterior communicating artery aneurysms [26]. Early seizures after SAH occur most commonly in the first 24 hours [26]. The actuarial risk of epilepsy after SAH was 18% by the first year, 23% by the second year, and 25% by the fifth year in the survivors of SAH [28]. Aneurysm location most associated with the development of SAH-related epilepsy is middle cerebral artery at the M1 branch and artery bifurcation [66]. The risk factors for epilepsy after aneurysmal SAH include the rupture of aneurysms in the anterior circulation, a young age, intracerebral hemorrhage, a poor neurological outcome, and hemosiderosis [29, 66]. Severe Hunt and Hess score as well as intraventricular hemorrhage elevate the risk of having a seizure after SAH [67]. The degree of neurological impairment and presence of an early seizure soon after the time of SAH have been identified as a risk factor for post-SAH epilepsy [68].

Nonconvulsive seizures following SAH cause transient brain hypoxia, increased intracranial pressure, and increased blood pressure [69]. Although evidence is not sufficient yet, guidelines recommend to consider the prophylactic use of antiepileptic medication except phenytoin (PHT) in the immediate post-hemorrhagic period and to consider the routine use of antiepileptic medication for patients with known risk factors for late seizures such as prior seizure, intracerebral hematoma, intractable hypertension, infarction, or aneurysm at the middle cerebral artery, though long-term use is not recommended [26]. Importantly, PHT should be avoided for the prophylaxis of early seizure following aneurysmal SAH because of known association with vasospasm, worsening of cognitive outcomes, and infarctions [70]. Recently, levetiracetam (LEV) is increasingly used for the prophylaxis of early seizures [26, 70].

2.5 Cerebral venous thrombosis

In patients with cerebral venous thrombosis (CVT), early seizures were seen in 6.9–76% [71], status epilepticus in 6% [40], late seizures in 11% [43], and post-CVT epilepsy in 4–16% [71]. Risk factors for early seizures following cerebral sinus thrombosis include brain parenchymal lesions, focal neurological deficits, supratentorial parenchymal lesions, intracerebral hemorrhage, focal edema/ischemic infarction, superior sagittal sinus thrombosis, cortical venous thrombosis, and pregnancy/puerperium [72–77]. Known risk factors for late seizures after CVT are early seizures, baseline intracerebral hemorrhage, decompressive hemicraniectomy, sigmoid sinus thrombosis, loss of consciousness at presentation, and genetic thrombophilia [43, 75, 78].

In the absence of previous early seizure following cerebral venous thrombosis, there is no evidence to prescribe prophylactic antiepileptic drugs during acute phase [40]. European and American guidelines recommend antiepileptic drug treatment on CVT for patients with early seizures and supratentorial lesions in order to prevent further seizures [79, 80].

Due to the high recurrence risk of late seizures, epilepsy diagnosis and commencement of antiepileptic drugs following a first late seizure after CVT is reasonable [43].

3. How vascular lesions acquire epileptogenicity?

3.1 Epileptogenicity

Epileptogenicity is the development and extension of tissue capable of generating spontaneous seizures, resulting in the development of an epileptic disorder or progression after the disorder is established [81]. In general, there are three phases to acquire epileptogenicity. First, brain-damaging insult (stroke, traumatic brain injury and central nervous system infections etc.) occurs (acute phase). Second, brain acquires epileptogenicity during a certain period of time (latent period), and third, as a result spontaneous recurrent seizures occur (chronic phase). In order to elucidate the mechanism of acquiring epileptogenicity, it is very important to study what occurs in the brain during latent period.

Risk factors, especially relevant to clinical practice, for acquiring epileptogenicity and subsequent development of PSE are summarized in **Table 3**.

PSE: post-stroke epilepsy, PET: positron emission tomography.

Animal experiment of stroke model is very helpful to elucidate epileptogenicity. Several studies directly evaluate neuronal and glial activities after stroke by using electrophysiological and histological measures. Early seizures evoked by traumatic brain injury and stroke can be suppressed by short-term prophylactic administration of antiepileptic drugs but it doesn't alter the incidence of PSE [83]. Therefore, targeting only neurons may be insufficient to prevent epileptogenicity; the glial involvement in the process of epileptogenesis after experimental stroke should be reviewed. Changes in neuro-glial syncytium during the course of acquiring epileptogenesis are shown in **Figure 1**.

Astrocytes form extensive gap junctions composed of connexin (Cx) 43 with other astrocytes and play a central role of neuron–glia syncytium [84]. Astrocyte regulates neural activities by removing excessive extracellular potassium at synapses and transports them into regions of low potassium concentration via gap junction [85]. Cx 43 also forms hemichannels in the astrocyte. Hemichannels allow the exchange of ions and molecules between the cytoplasm and the

Symptom severity	Clinical stroke severity is a major factor in the development of PSE
Lesion size	Post-stroke seizures were more likely to develop in patients with larger lesions involving multiple lobes of the brain than in those with single lobar involvement Total anterior circulation infarct is a particularly strong risk factor for PSE compared with other ischemic stroke subtypes
Lesion location	Extent of cortical involvement is a significant risk factor for PSE Involvement of the parieto-temporal cortex, supramarginal gyrus, and superior temporal gyrus associates with post-stroke epileptogenesis
Stroke subtype	PSE occurred more frequently with hemorrhagic stroke than with ischemic stroke, with about 10–20% of patients developing PSE after hemorrhagic stroke compared with 2–14% after ischemic stroke
Cortical blood flow	A PET study revealed reduced cortical blood flow and oxygen consumption are related to late-onset epilepsy in patients with leukoaraiosis
Vascular risk factors	Vascular risk factors including history of myocardial infarction, peripheral vascular disease, hypertension, total serum cholesterol, and left ventricular hypertrophy, are associated with PSE
Other factors	Genetic factors, peri-injury exposome, etc.

Table 3.

Risk factors for acquiring epileptogenicity after stroke [7, 10, 25, 31, 32, 82].

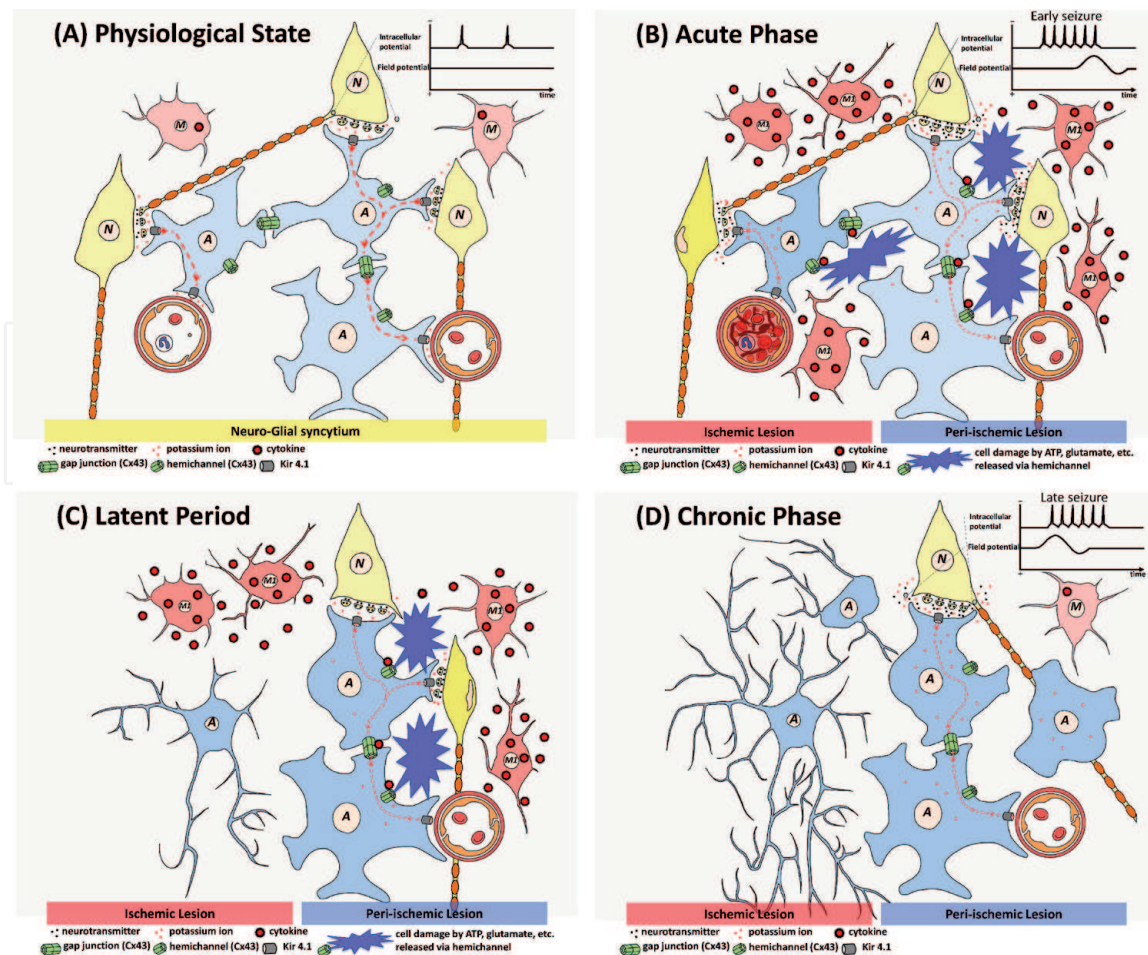


Figure 1. Neuro-glia syncytium in the course of acquiring epileptogenesis. (A) Physiological state. A neuron generates physiological action potentials in neuro-glia syncytium. As a result of neural firing, extracellular potassium concentration is elevated. Kir 4.1 channels in the astrocyte mediate spatial potassium buffering and regulates neural activities by transporting them into regions of low potassium concentration such as blood vessels. (B) Acute phase. In the acute phase of ischemic stroke, ischemic changes of neuron and glia gradually appear in the ischemic lesion. Neurons and astrocyte/microglia cells in the peri-ischemic lesion are activated. Activated microglia called M1 secretes cytokines (e.g. TNF- α , IL-1 β), which in turn inhibit gap junctional communication and increase hemichannel activity in astrocytes. The release of molecules, such as ATP and glutamate, damages adjacent neurons and glia cells. Inhibition of gap junction leads to dysfunction of spatial potassium buffering, which further provokes neural firing. Electrophysiologically, neuronal activities lead to increase of spatial potassium, and DC shifts appear as a result of exceeding the capacity of buffering. (C) Latent period. Necrotic region in the ischemic lesion is cleaned by microglia and gliosis occurs in per-ischemic lesion. Inflammation, mainly caused by M1 phenotype, continues in this period and further damages neurons and astrocytes. (D) Chronic phase. In the chronic phase of ischemic stroke, inflammation subsides, and epileptogenicity is acquired. Ischemic lesion is replaced by fibrillary astrocyte and peri-ischemic lesion is occupied by gliosis. Dysfunction of neuro-glia syncytium reaches the pathological state which generates spontaneous epileptic activities. Electrophysiologically, DC shifts precede neural firing. N: neuron, A: astrocyte, M: microglia, TNF- α : tumor necrosis factor-alpha, IL-1 β : interleukin 1 beta, ATP: adenosine triphosphate, DC: direct current, Cx43: connexin 43.

extracellular medium, which physiologically regulate neuronal activity as well as synaptic strength and plasticity [86] and also pathologically be activated by inflammation [87].

3.2 Acute phase

Epileptiform activities after middle cerebral artery (MCA) occlusion were first recorded using surface conventional EEG in the rat experiment by Hartings et al. [88]. 55–90% of animals had epileptiform activities 33–50 minutes after stroke which exacerbated brain injury [89–91]. High frequency oscillations (HFOs) are involved with epileptogenic region in intractable epileptic patients (e.g. focal

cortical dysplasia) and rat pilocarpine model of temporal lobe epilepsy [92]. In rat stroke model, HFOs were also observed 5–15 seconds before run of theta activities consisted of sharp positive spikes followed by longer negative waves and terminated at the onset of the discharge after ischemia [93]. Direct current (DC) shifts are associated with a steady increase of the extracellular potassium concentration, which matches to the intracellular voltage variations of glial cells [94]. In rat MCA occlusion model, a highly significant linear correlation is reported between the number of depolarization and the infarct size at peri-infarct region, and DC shifts are also recorded [95], which may indicate exceeding of potassium concentration to the buffering capacity of astrocyte.

Histological changes immediately after stroke are reported by Ramírez-Sánchez et al. [96]. When rats were subjected to 90 minutes MCA occlusion followed by 23 hours of reperfusion, neuronal cells in the peri-infarct cortex, cornu ammonis (CA) 1, and dentate gyrus (DG) areas were decreased, and widespread reactive astrogliosis in both of the cortex and the hippocampus (CA1, CA3, and DG areas) was observed 24 hours after ischemia.

Therefore, in acute phase of epileptogenesis, stroke immediately damages neurons and glia cells, and provokes neuronal epileptic activity. Furthermore, as a result of destruction of cells and excessive neural firing, the extracellular potassium concentration increases beyond glial potassium buffering capacity, which may lead to a vicious circle of further neural firing.

3.3 Latent period and chronic phase

Chronic phase of the aged rat post-stroke brain is reported by Titova et al. [97]. They evaluated ischemic lesions at 28 days induced by 50 minutes right MCA occlusion in aged rat (18 month-old). In ischemic lesion, extensive glial scar and apoptotic neurons were found and phagocytic macrophages/microglia cells were seen in the peri-lesional rim. The brain irradiation possibly affects normal post-stroke microglia signaling and prevents following activation of inflammatory cascade mechanisms [98]. When proton irradiation was performed at the heads of aged rat ten days prior to right MCA occlusion, chronic phagocytosis and T-lymphocyte infiltration in the brain were reduced, and formation of glio-vascular complexes, neuronal viability, neovascularization were improved in the peri-lesional zone, and neurological severity scoring were improved [97]. These data clearly demonstrated that, in addition to direct damage to brain by stroke itself, subsequent inflammation also damages neuron, astrocyte, vessel and neural function.

In the central nervous system, microglia is a major player in the brain inflammation. Stroke activates microglia which is called M1 phenotype, which secretes inflammatory cytokine like interleukin (IL) and tumor necrosis factor (TNF)- α [99]. Astrocyte also secretes inflammatory cytokines (e.g. TNF- α , IL-1 β) via Cx43-hemichannel in the MCA occlusion model [100], whereas Gap19, a selective Cx43-hemichannel inhibitor, exhibits neuroprotective effects on cerebral ischemia/reperfusion via suppression of the expression of Cx43 and toll-like receptor 4 pathway-relevant proteins, and prevention of the overexpression of TNF- α and IL-1 β in astrocyte. An obvious improvement in neurological scores and infarct volume reduction were observed in Gap19-treated mice after brain ischemia induced by MCA occlusion [100].

Inflammatory cytokines, specifically IL-1 β and TNF- α , are involved in inhibition of gap junctional communication and increase of hemichannel activity in astrocytes [87]. Inhibition of gap junction communication impedes potassium buffering which promotes neural firing. Increased hemichannel activity allows the release of molecules such as adenosine triphosphate, glutamate, nicotinamide adenine

dinucleotide, glutathione, and prostaglandin E2 [101–105]. These molecules are toxic to adjacent cells and finally lead to neuronal and glial death [106, 107]. These insults to the central nervous system tissue trigger a range of molecular, morphological, and functional changes of astrocytes called reactive gliosis [108], which is one of the most important pathogenic steps of spontaneous seizure [92].

As for electrophysiological study of PSE model, few data are available because only 10–20% of post-stroke rats develop spontaneous seizure [109]. Brain damage induced by brain injury, axotomy, or toxic substance in addition to stroke also activates microglia [99], therefore, electrophysiological pathology induced by inflammation of other causes is probably plausible as that is induced by stroke. The mechanism of epileptogenesis after status epilepticus model is well studied. Pilocarpine, a muscarinic acetylcholine agonist, induces status epilepticus, and after a certain latent period surviving rats acquire epileptogenesis [110]. This rat model also shows HFOs and DC shifts during seizure at acute phase [92]. Gliosis occurs in 8–12 weeks after pilocarpine injection [111], and spatial potassium buffering function at hippocampus is impaired [112]. EEG recording during epileptic seizures at chronic phase of this model rat showed DC shifts preceding HFOs and conventional ictal EEG patterns, which may be the result of dysfunction of astrocyte extracellular potassium buffering [92]. Minocycline is a second-generation tetracycline and has potent anti-inflammatory effects independent of its antimicrobial action. Minocycline attenuates spontaneous recurrent seizures following pilocarpine-induced status epilepticus, and inhibits the status epilepticus-induced microglial activation and overproduction of IL-1 β and TNF- α in the hippocampal CA1 and the adjacent cortex, without affecting astrocyte activation. In addition, minocycline prevents the status epilepticus-induced neuronal loss [113].

4. Neurological examination, electroencephalography, and imaging findings

4.1 Neurological examination

Post-stroke epilepsy is common among the elderly. Nonconvulsive seizures are common in elderly patient with epilepsy, and clinical presentation of elderly patients with epilepsy differs considerably from younger patients; less common and nonspecific auras (e.g. dizziness); less frequent automatisms; prolonged post-ictal confusion; common complaints with altered mental status, confusion, and memory disturbance [114].

These characteristics hinder and delay the diagnosis of epilepsy in the elderly. Co-morbid diseases such as hypertension, dementia, transient ischemic attack (TIA), and cardiac diseases can mislead to attribute these symptoms as one of the manifestations of pre-existing conditions in an elderly patient with new-onset epilepsy [114]. It is necessary and important, for example, to evaluate stroke or TIA immediately for patient with new-onset motor aphasia with brain imaging examinations; however, the symptom can be of aphasic seizures per se or in association with various neurological emergencies, especially if the duration of aphasia is brief, severity of aphasia is fluctuating, or other concomitant neurological findings exist. Clinical presentation of elderly patients with new-onset epilepsy is commonly nonspecific, and thus, EEG should be utilized for the diagnosis of epilepsy in the elderly.

Status epilepticus occurs in 9–19% of patients with post-stroke seizures, while status epilepticus following stroke accounted for 14–27% of all status epilepticus in adults [115]. Tomari et al. reported that 24% of post-stroke seizures with status

epilepticus are nonconvulsive status epilepticus [115]. The initiation of treatments for nonconvulsive status epilepticus is commonly delayed compared with convulsive status epilepticus because the diagnosis is often difficult without EEG. The evaluation with EEG is mandatory for patients with nonspecific symptoms such as depressed level of consciousness. Subtle neurological manifestations (e.g. myoclonus, rigidity/spasticity, saccadic eye movement, eye/head turning, abnormal reflexes), their fluctuation, and repetitions of their combination (e.g. myoclonus - > rigidity/spasticity - > paresis - > hyperreflexia, tachypnea - > eyelid twitch - > eye open - > pupil dilation - > eye/head turning) are worthwhile to further evaluation for status epilepticus.

4.2 Electroencephalography

Epileptiform discharges (spikes and sharp waves) in conventional EEG are highly specific to seizure recurrence but not sensitive enough in adult patients (sensitivity 17.3%, specificity 94.7%) [116]. Therefore, lack of epileptiform discharges does not simply exclude the possibility of epileptic seizures. Other nonspecific findings represent both neuronal damage and epileptic activities; amplitude decrease of background activities (e.g. posterior dominant rhythm, fast waves, sleep spindles) and presence of focal slow activities should be serially evaluated.

Recently, long-term, continuous EEG monitoring with video record is increasingly utilized in intensive care unit for early diagnosis of nonconvulsive status epilepticus. Besides conventional EEG seizure patterns (i.e. rhythmic activities with evolution in frequency and amplitude), lateralized periodic discharges, evolving/fluctuating activities, and abnormal rhythmic fast activities superimposed to rhythmic/periodic activities should be evaluated [117–119]. The Salzburg EEG criteria for diagnosis of nonconvulsive status epilepticus include improvement of EEG after intravenous antiepileptic drugs [120].

4.3 Brain imaging

Brain computer tomography is a well-established measure to evaluate intracranial hemorrhage, edema, and mass lesions, and has been utilized for deciding the indication of thrombolytic therapy in acute ischemic stroke.

Initial use of brain magnetic resonance imaging is useful not only to detect cerebrovascular disorders and other neurological conditions but also to evaluate seizure foci and spread of seizures via neural network. Hyperintensity of diffusion-weighted imaging especially in the cortex and hyperperfusion of arterial spin labeling can help early diagnosis of nonconvulsive status epilepticus [118, 119, 121, 122].

5. Treatment strategy: adults in general, and in elderly

5.1 Prevention of post-stroke seizures and epilepsy

The prevalence of post-stroke early seizure is high; 4.8% for ischemic stroke and 7.9% for hemorrhagic stroke [5]. Current clinical guidelines recommend against the routine use of prophylactic antiepileptic drugs for spontaneous intracerebral hemorrhage [64], because primary prevention of seizures with antiepileptic drugs does not improve neurological function during follow up (up to 90 days) [65]. For SAH, guidelines state that a short course (3 to 7 days) of prophylaxis with antiepileptic drugs may be started in the immediate post-bleeding period, although this prophylaxis has a low level of evidence [70]. PHT, which can cause worse cognitive

outcomes, vasospasm, and infarctions, should be avoided to use for prophylaxis after SAH, and LEV is increasingly being used [70].

The prevalence of post-stroke late seizure is 3.8% for ischemic stroke and 2.6% for hemorrhagic stroke [5]. As the risk of recurrence after a first unprovoked late seizure can be as high as 71.5% over the next 10 years, the occurrence of a single late post-stroke seizure is consistent with a diagnosis of epilepsy. The risk factors for seizures after ischemic stroke were cortical involvement of infarction and stroke disability. For hemorrhagic stroke, the risk factor of seizures was cortical location. The risk factors in general for post-stroke early seizures during the first 48 hours include advanced age, confusional syndrome, hemorrhagic stroke, large lesions, involvement of parietal and temporal lobes, and occurrence of neurologic and medical complications [6].

None of the currently available antiepileptic medication has been shown to prevent PSE [123–125]. Immediate initiation of continuous antiepileptic medication treatment of the first early seizure after cerebral infarctions decreased the risk of recurrent seizure during the first 2 years but has no influence on the development of recurrent seizures after discontinuing antiepileptic medication in 2 years [124].

As mentioned in Chapter 4, anti-inflammatory therapy is the most expected strategy in order to prevent epileptogenesis. Statins, 3-hydroxy-3-methylglutaryl coenzyme A (HMG-CoA) reductase inhibitors, which are approved for cholesterol reduction, may also be beneficial in the treatment of inflammatory diseases. In animal experiment, atorvastatin reverses paralysis in central nervous system autoimmune disease via suppressing secretion of type 1 helper T cell (Th1) cytokines (IL-2, IL-12, interferon- γ , and TNF- α) and promoting secretion of Th2 cytokines (IL-4, IL-5 and IL-10) and transform of growth factor- β , in Th1-mediated central nervous system demyelinating disease model of multiple sclerosis [126]. In patients with epilepsy, statin use, especially in the acute phase of ischemic stroke, may reduce the risk of post-stroke early-onset seizures [127]. Adequate statin treatment after ischemic stroke may lower the risk of PSE [128].

In the future, periodic measurement of inflammatory biomarker in the stroke patients having the risk factors as mentioned above and evaluation of the effect of anti-inflammatory agents such as statin to epileptogenicity are warranted.

5.2 Treatment of post-stroke seizures and epilepsy

The decision to initiate antiepileptic medication treatment after a first unprovoked seizure should be individualized and based on age, preference of a patient, and clinical, legal, and socio-cultural factors [129]. Upon commencement of treatment with antiepileptic medication, monotherapy is recommended, among various kinds of antiepileptic medication available. For patients with PSE especially with cerebral infarction, possible adverse event of lipid abnormalities should be avoided to prevent recurrent stroke. High tolerability, which is associated with minimum side effects such as sleepiness or dizziness, is important in elderly patients in terms of safety against falling as well as adherence improvement. In addition, drug interaction is a matter of concern in patients undergoing polypharmacy.

Patients who are treated with enzyme-inducing antiepileptic drugs such as carbamazepine (CBZ), PHT, and phenobarbital (PB) show higher levels of total cholesterol, triglycerides and LDL-cholesterol, although the effects of valproate (VPA) on lipid profiles remain unclear [130]. On the other hand, patients who are treated with enzyme-inhibiting antiepileptic drugs and non-enzyme-inducing antiepileptic drugs are not significantly affected their lipid profile, whereas several reports showed LEV could be associated with higher LDL-cholesterol levels [130]. Due to the side effects of antiepileptic drugs, treatment with non-enzyme-inducing

antiepileptic drugs such as lamotrigine (LTG) and LEV is a reasonable treatment strategy in terms of lipid control [130]. In post-stroke seizures and epilepsy, LEV and LTG show higher tolerability than controlled-release CBZ [131].

Weight gain and obesity are associated with hypertension and atherosclerosis. It is well known that VPA, CBZ, PHT, gabapentin, vigabatrin, and pregabalin are associated with weight gain [132–134] while LTG and LEV are not [135, 136], and felbamate, topiramate (TPM), and zonisamide cause weight loss [137, 138].

Carotid-artery intima media thickness (CA-IMT) is an early marker of cerebral atherosclerosis [139]. The old-generation antiepileptic drugs such as CBZ, PHT and VPA are associated with significant increase of CA-IMT in adult patients with epilepsy [139, 140]. On the other hand, the new-generation antiepileptic drugs such as LTG and oxcarbazepine (OXC) have no effects on CA-IMT in adults and children [140, 141].

Hyperhomocysteinemia is an independent risk factor for stroke [142]. OXC, TPM, CBZ, and PB are associated with higher plasma total homocysteine level; adult epilepsy patients treated with LTG and LEV as monotherapy had normal total homocysteine level [143].

Currently, patients with PSE are rarely underwent pre-surgical evaluation even though their seizures are intractable. Good seizure outcome is reported in young generation under 50 years old whose epilepsy onset is at age 20 years or younger, who underwent tailored hemispherectomy based on the findings of stereoelectroencephalography recordings [144]. Approximately 3% of patients with cerebral dural arteriovenous fistula experience seizures [45]. Although status epilepticus is not common among patients with cerebral dural arteriovenous fistula, there is a case report that endovascular intervention improved the seizure control of patients with cerebral dural arteriovenous fistula who present with status epilepticus [145].

Conflict of interest

The authors declare no conflict of interest.

IntechOpen

IntechOpen

Author details

Kaoru Obata¹, Kazuaki Sato², Hiroya Ohara³ and Masako Kinoshita^{4*}

¹ Kurashiki Central Hospital, Okayama, Japan

² Department of Neurology, Ijinkai Takada General Hospital, Kyoto, Japan

³ Department of Neurology, Minaminara General Medical Center, Nara, Japan

⁴ Department of Neurology, National Hospital Organization Utano National Hospital, Kyoto, Japan

*Address all correspondence to: machak@kuhp.kyoto-u.ac.jp

IntechOpen

© 2020 The Author(s). Licensee IntechOpen. This chapter is distributed under the terms of the Creative Commons Attribution License (<http://creativecommons.org/licenses/by/3.0>), which permits unrestricted use, distribution, and reproduction in any medium, provided the original work is properly cited. 

References

- [1] Herman ST. Epilepsy after brain insult: targeting epileptogenesis. *Neurology*. 2002 Nov 12;59(9 Suppl 5):S21-S26. DOI: 10.1212/wnl.59.9_suppl_5.s21
- [2] Thurman DJ, Faught E, Helmers S, Kim H, Kalilani L. New-onset lesional and nonlesional epilepsy in the US population: Patient characteristics and patterns of antiepileptic drug use. *Epilepsy Research*. 2019 Nov;157:106210. DOI: 10.1016/j.eplepsyres.2019.106210
- [3] Hankey GJ. Stroke. *Lancet*. 2017 Feb 11;389(10069):641-654. DOI: 10.1016/S0140-6736(16)30962-X
- [4] Camilo O, Goldstein LB. Seizures and epilepsy after ischemic stroke. *Stroke*. 2004 Jul;35(7):1769-1775. DOI: 10.1161/01.STR.0000130989.17100.96
- [5] Bladin CF, Alexandrov AV, Bellavance A, Bornstein N, Chambers B, Cote R, et al. Seizures after stroke: a prospective multicenter study. *Archives of Neurology*. 2000 Nov;57(11):1617-1622. DOI: 10.1001/archneur.57.11.1617
- [6] Arboix A, Comes E, Massons J, García L, Oliveres M. Relevance of early seizures for in-hospital mortality in acute cerebrovascular disease. *Neurology*. 1996 Dec;47(6):1429-1435. DOI: 10.1212/wnl.47.6.1429
- [7] Beghi E, Carpio A, Forsgren L, Hesdorffer DC, Malmgren K, Sander JW, et al. Recommendation for a definition of acute symptomatic seizure. *Epilepsia*. 2010 Apr;51(4):671-675. DOI: 10.1111/j.1528-1167.2009.02285.x
- [8] Annegers JF, Rocca WA, Hauser WA. Causes of epilepsy: contributions of the Rochester epidemiology project. *Mayo Clinic Proceedings*. 1996 Jun;71(6):570-575. DOI: 10.4065/71.6.570
- [9] Fisher RS, Acevedo C, Arzimanoglou A, Bogacz A, Cross JH, Elger CE, et al. ILAE official report: a practical clinical definition of epilepsy. *Epilepsia*. 2014 Apr;55(4):475-482. DOI: 10.1111/epi.12550
- [10] Zhao Y, Li X, Zhang K, Tong T, Cui R. The progress of epilepsy after stroke. *Current Neuropharmacology*. 2018;16(1):71-78. DOI: 10.2174/1570159X15666170613083253
- [11] Graham NS, Crichton S, Koutroumanidis M, Wolfe CD, Rudd AG. Incidence and associations of poststroke epilepsy: the prospective South London Stroke Register. *Stroke*. 2013 Mar;44(3):605-611. DOI: 10.1161/STROKEAHA.111.000220
- [12] Betjemann JP, Lowenstein DH. Status epilepticus in adults. *Lancet Neurology*. 2015 Jun;14(6):615-624. DOI: 10.1016/S1474-4422(15)00042-3
- [13] Trinka E, Cock H, Hesdorffer D, Rossetti AO, Scheffer IE, Shinnar S, et al. A definition and classification of status epilepticus--Report of the ILAE Task Force on Classification of Status Epilepticus. *Epilepsia*. 2015 Oct;56(10):1515-1523. DOI: 10.1111/epi.13121
- [14] Veliöğlu SK, Özmenöğlu M, Boz C, Alioğlu Z. Status epilepticus after stroke. *Stroke*. 2001 May;32(5):1169-1172. DOI: 10.1161/01.str.32.5.1169
- [15] Afsar N, Kaya D, Aktan S, Sykut-Bingol C. Stroke and status epilepticus: stroke type, type of status epilepticus, and prognosis. *Seizure*. 2003 Jan;12(1):23-27. DOI: 10.1016/s1059131102001437
- [16] Legriél S, Brophy GM. Managing status epilepticus in the older adult. *Journal of Clinical Medicine*. 2016 May 11;5(5):53. DOI: 10.3390/jcm5050053

- [17] Malter MP, Nass RD, Kaluschke T, Fink GR, Burghaus L, Dohmen C. New onset status epilepticus in older patients: Clinical characteristics and outcome. *Seizure*. 2017 Oct;51:114-120. DOI: 10.1016/j.seizure.2017.08.006
- [18] Hauser WA, Annegers JF, Kurland LT. Incidence of epilepsy and unprovoked seizures in Rochester Minnesota: 1935-1984. *Epilepsia*. May-Jun 1993;34:453-468. doi: 10.1111/j.1528-1157.1993.tb02586.x.
- [19] Lamy C, Domigo V, Semah F, Arquizán C, Trystram D, Coste J, et al. Early and late seizures after cryptogenic stroke in young adults. *Neurology*. 2003 Feb 11;60(3):400-404. DOI: 10.1212/wnl.60.3.400
- [20] Burn J, Dennis M, Bamford J, Sandercock P, Wade D, Warlow C. Epileptic seizures after a first stroke: the Oxfordshire Community Stroke Project. *BMJ*. 1997 Dec 13;315(7122):1582-1587. DOI: 10.1136/bmj.315.7122.1582
- [21] So EL, Annegers JF, Hauser WA, O'Brien PC, Whisnant JP. Population-based study of seizure disorders after cerebral infarction. *Neurology*. 1996 Feb;46(2):350-355. DOI: 10.1212/wnl.46.2.350
- [22] Claassen J, Jetté N, Chum F, Green R, Schmidt M, Choi H, et al. Electrographic seizures and periodic discharges after intracerebral hemorrhage. *Neurology*. 2007 Sep 25;69(13):1356-1365. DOI: 10.1212/01.wnl.0000281664.02615.6c
- [23] Haapaniemi E, Strbian D, Rossi C, Putaala J, Sipi T, Mustanoja S, et al. The CAVE score for predicting late seizures after intracerebral hemorrhage. *Stroke*. 2014 Jul;45(7):1971-1976. DOI: 10.1161/STROKEAHA.114.004686
- [24] Rossi C, De Herdt V, Dequatre-Ponchelle N, Hénon H, Leys D, Cordonnier C. Incidence and predictors of late seizures in intracerebral hemorrhages. *Stroke*. 2013 Jun;44(6):1723-1725. DOI: 10.1161/STROKEAHA.111.000232
- [25] Lahti AM, Saloheimo P, Huhtakangas J, Salminen H, Juvela S, Bode MK, et al. Poststroke epilepsy in long-term survivors of primary intracerebral hemorrhage. *Neurology*. 2017 Jun 6;88(23):2169-2175. DOI: 10.1212/WNL.0000000000004009
- [26] Connolly ES Jr, Rabinstein AA, Carhuapoma JR, Derdeyn CP, Dion J, Higashida RT, et al. Guidelines for the management of aneurysmal subarachnoid hemorrhage: A guideline for healthcare professionals from the American Heart Association/American Stroke Association. 2012 Jun;43(6):1711-1737. DOI: 10.1161/STR.0b013e3182587839
- [27] Murphy-Human T, Welch E, Zipfel G, Diringner MN, Dhar R. Comparison of short-duration levetiracetam with extended-course phenytoin for seizure prophylaxis after subarachnoid hemorrhage. *World Neurosurgery*. 2011 Feb;75(2):269-274. DOI: 10.1016/j.wneu.2010.09.002
- [28] Boling W, Kore L. Subarachnoid hemorrhage-related epilepsy. *Acta Neurochirurgica Supplement*. 2020;127:21-25. DOI: 10.1007/978-3-030-04615-6_4
- [29] Hirano T, Enatsu R, Iihoshi S, Mikami T, Honma T, Ohnishi H, et al. Effects of hemosiderosis on epilepsy following subarachnoid hemorrhage. *Neurologia Medico-Chirurgica (Tokyo)*. 2019 Jan 15;59(1):27-32. DOI: 10.2176/nmc.oa.2018-0125
- [30] Choi KS, Chun HJ, Yi HJ, Ko Y, Kim YS, Kim JM. Seizures and epilepsy following aneurysmal subarachnoid hemorrhage: Incidence and risk factors. *Journal of Korean Neurosurgical Association*. 2009 Aug;46(2):93-98. DOI: 10.3340/jkns.2009.46.2.93

- [31] Jennett B. Epilepsy and acute traumatic intracranial haematoma. *Journal of Neurology, Neurosurgery, and Psychiatry*. 1975 Apr;**38**(4):378-381. DOI: 10.1136/jnnp.38.4.378
- [32] Temkin NR. Risk factors for posttraumatic seizures in adults. *Epilepsia*. 2003;**44**(s10):18-20. DOI: 10.1046/j.1528-1157.44.s10.6.x
- [33] Won SY, Konczalla J, Dubinski D, Cattani A, Cuca C, Seifert V, et al. A systematic review of epileptic seizures in adults with subdural haematomas. *Seizure*. 2017 Feb;**45**:28-35. DOI: 10.1016/j.seizure.2016.11.017
- [34] Kim JA, Boyle EJ, Wu AC, Cole AJ, Staley KJ, Zafar S, et al. Epileptiform activity in traumatic brain injury predicts post-traumatic epilepsy. *Annals of Neurology*. 2018 Apr;**83**(4):858-862. DOI: 10.1002/ana.25211
- [35] Neshige S, Sekihara Y, Ishii N, Sato M, Ota S, Kuriyama M. Clinical and radiological studies of seizure in chronic subdural hematoma--case control study. *Rinshō Shinkeigaku*. 2014;**54**(11):869-875. DOI: 10.5692/clinicalneuro.54.869. (Japanese)
- [36] Yoon SY, Choi YJ, Park SH, Hwang JH, Hwang SK. Traumatic brain injury in children under age 24 months: Analysis of demographic data, risk factors, and outcomes of post-traumatic seizure. *Journal of Korean Neurosurgical Association*. 2017 Sep;**60**(5):584-590. DOI: 10.3340/jkns.2016.0707.008
- [37] Rubin G, Rappaport ZH. Epilepsy in chronic subdural haematoma. *Acta Neurochirurgica*. 1993;**123**(1-2):39-42. DOI: 10.1007/BF01476283
- [38] Kotwica Z, Brzeński J. Epilepsy in chronic subdural haematoma. *Acta Neurochirurgica*. 1991;**113**(3-4):118-120. DOI: 10.1007/BF01403195
- [39] Beslow LA, Licht DJ, Smith SE, Storm PB, Heuer GG, Zimmerman RA, et al. Predictors of outcome in childhood intracerebral hemorrhage: a prospective consecutive cohort study. *Stroke*. 2010 Feb;**41**(2):313-318. DOI: 10.1161/STROKEAHA.109.568071
- [40] Lindgren E, Silvis SM, Hiltunen S, Heldner MR, Serrano F, de Scisco M, et al. Acute symptomatic seizures in cerebral venous thrombosis. *Neurology*. 2020 Sep 22;**95**(12):e1706-e1715. DOI: 10.1212/WNL.0000000000010577
- [41] Kalita J, Chandra S, Misra UK. Significance of seizure in cerebral venous sinus thrombosis. *Seizure*. 2012 Oct;**21**(8):639-642. DOI: 10.1016/j.seizure.2012.07.005
- [42] Preter M, Tzourio C, Ameri A, Boussier MG. Long-term prognosis in cerebral venous thrombosis. Follow-up of 77 patients. *Stroke*. 1996 Feb;**27**(2):243-246. DOI: 10.1161/01.str.27.2.243
- [43] Sánchez van Kammen M, Lindgren E, Silvis SM, Hiltunen S, Heldner MR, Serrano F, et al. Late seizures in cerebral venous thrombosis. *Neurology*. 2020 Sep 22;**95**(12):e1716-e1723. DOI: 10.1212/WNL.0000000000010576
- [44] Josephson CB, Bhattacharya JJ, Counsell CE, Papanastassiou V, Ritchie V, Roberts R, et al. Seizure risk with AVM treatment or conservative management: prospective, population-based study. *Neurology*. 2012 Aug 7;**79**(6):500-507. DOI: 10.1212/WNL.0b013e3182635696
- [45] Hiramatsu M, Sugiu K, Hishikawa T, Haruma J, Tokunaga K, Date I, et al. Epidemiology of dural arteriovenous fistula in Japan: Analysis of Japanese Registry of Neuroendovascular Therapy (JR-NET2). *Neurologia*

Medico-Chirurgica (Tokyo).
2014;**54**(1):63-71. DOI: 10.2176/nmc.
st.2013-0172

[46] Kang K, Ju Y, Wang D, Li H, Sun L, Ma K, et al. Cerebral venous malformations in a Chinese population: Clinical manifestations, radiological characteristics, and long-term prognosis. *World Neurosurgery*. 2018 Dec;**120**:e472-e479. DOI: 10.1016/j.wneu.2018.08.106

[47] Tamogami R, Oi S, Nonaka Y, Miwa T, Abe T. Clinical prognosis and therapeutic aspects in management of pediatric moyamoya disease. *Nihon Rinsho*. 2010 Jan;**68**(1):45-52. (Japanese)

[48] Yang H, Song Z, Yang GP, Zhang BK, Chen M, Wu T, et al. The ALDH2 rs671 polymorphism affects post-stroke epilepsy susceptibility and plasma 4-HNE levels. *PLoS One*. 2014 Oct 14;**9**(10):e109634. DOI: 10.1371/journal.pone.0109634

[49] Zhang C, Wang X, Wang Y, Zhang JG, Hu W, Ge M, et al. Risk factors for post-stroke seizures: a systematic review and meta-analysis. *Epilepsy Research*. 2014 Dec;**108**(10):1806-1816. DOI: 10.1016/j.epilepsyres.2014.09.030

[50] Abaira L, Toledo M, Guzmán L, Sueiras M, Quintana M, Fonseca E, et al. Long-term epilepsy after early post-stroke status epilepticus. *Seizure*. 2019 Jul;**69**:193-197. DOI: 10.1016/j.seizure.2019.04.022

[51] Adams HP Jr, Bendixen BH, Kappelle LJ, Biller J, Love BB, Gordon DL, et al. Classification of subtype of acute ischemic stroke. Definitions for use in a multicenter clinical trial. TOAST. Trial of Org 10172 in Acute Stroke Treatment. *Stroke*. 1993 Jan;**24**(1):35-41. DOI: 10.1161/01.str.24.1.35

[52] Amarenco P, Bogousslavsky J, Caplan LR, Donnan GA, Wolf ME, Hennerici MG. The ASCOD phenotyping of ischemic stroke (Updated ASCO Phenotyping). *Cerebrovascular Diseases*. 2013;**36**(1): 1-5. DOI: 10.1159/000352050

[53] Ay H, Benner T, Arsava EM, Furie KL, Singhal AB, Jensen MB, et al. Computerized algorithm for etiologic classification of ischemic stroke: The causative classification of stroke system. *Stroke*. 2007 Nov;**38**(11):2979-2984. DOI: 10.1161/STROKEAHA.107.490896

[54] Feigin VL, Lawes CMM, Bennett DA, Barker-Collo SL, Parag V. Worldwide stroke incidence and early case fatality reported in 56 population-based studies: a systematic review. *Lancet Neurology*. 2009 Apr;**8**(4):355-369. DOI: 10.1016/S1474-4422(09)70025-0

[55] Adelow C, Andersson T, Ahlbom A, Tomson T. Prior hospitalization for stroke, diabetes, myocardial infarction, and subsequent risk of unprovoked seizures. *Epilepsia*. 2011 Feb;**52**(2):301-307. DOI: 10.1111/j.1528-1167.2010.02757.x

[56] Wang JZ, Vyas MV, Saposnik G, Burneo JG. Incidence and management of seizures after ischemic stroke: systematic review and meta-analysis. *Neurology*. 2017 Sep 19;**89**(12):1220-1228. DOI: 10.1212/WNL.0000000000004407

[57] Galovic M, Döhler N, Erdélyi-Canavese B, Felbecker A, Siebel P, Conrad J, et al. Prediction of late seizures after ischaemic stroke with a novel prognostic model (the SeLECT score): a multivariable prediction model development and validation study. *Lancet Neurology*. 2018 Feb;**17**(2):143-152. DOI: 10.1016/S1474-4422(17)30404-0

- [58] Redfors P, Holmegaard L, Pedersen A, Jern C, Malmgren K. Long-term follow-up of post-stroke epilepsy after ischemic stroke: Room for improved epilepsy treatment. *Seizure*. 2020 Jan 21;**76**:50-55. DOI: 10.1016/j.seizure.2020.01.009
- [59] Naylor J, Thevathasan A, Churilov L, Guo R, Xiong Y, Koome M, et al. Association between different acute stroke therapies and development of post stroke seizures. *BMC Neurology*. 2018 May 3;**18**(1):61. DOI: 10.1186/s12883-018-1064-x
- [60] Schreiner A, Pohlmann-Eden B, Schwartz A, Hennerici M. Epileptic seizures in subcortical vascular encephalopathy. *Journal of the Neurological Sciences*. 1995 Jun;**130**(2):171-177. DOI: 10.1016/0022-510x(95)00020-3
- [61] Obata K, Kinoshita M, Sato K, Chin M, Yamagata S, Ikeda A, et al. Branch atheromatous disease has a stronger association with late-onset epileptic seizures than lacunar infarction in Japanese patients. *The Journal of International Medical Research*. 2020 Jan;**48**(1):300060519831572. DOI: 10.1177/0300060519831572
- [62] Mehta A, Zusman BE, Choxi R, Shutter LA, Yassin A, Antony A, et al. Seizures After Intracerebral Hemorrhage: Incidence, Risk Factors, and Impact on Mortality and Morbidity. *World Neurosurgery*. 2018 Apr;**112**:e385-e392. DOI: 10.1016/j.wneu.2018.01.052
- [63] Pohlmann-Eden B, Bruckmeier J. Predictors and dynamics of posttraumatic epilepsy. *Acta Neurologica Scandinavica*. 1997 May;**95**(5):257-262. DOI: 10.1111/j.1600-0404.1997.tb00206.x
- [64] Hemphill JC 3rd, Greenberg SM, Anderson CS, Becker K, Bendok BR, Cushman M, et al. Guidelines for the management of spontaneous intracerebral hemorrhage: A guideline for healthcare professionals from the American Heart Association/American Stroke Association. *Stroke*. 2015 Jul;**46**(7):2032-2060. doi: 10.1161/STR.0000000000000069.
- [65] Angriman F, Tirupakuzhi Vijayaraghavan BK, Dragoi L, Lopez Soto C, Chapman M, Scales DC. Antiepileptic drugs to prevent seizures after spontaneous intracerebral hemorrhage. *Stroke*. 2019 May;**50**(5):1095-1099. DOI: 10.1161/STROKEAHA.118.024380
- [66] Huttunen J, Kurki MI, von Und Zu Fraunberg M, Koivisto T, Ronkainen A, Rinne J, et al. Epilepsy after aneurysmal subarachnoid hemorrhage: A population-based, long-term follow-up study. *Neurology*. 2015 Jun 2;**84**(22):2229-2237. DOI: 10.1212/WNL.0000000000001643
- [67] Panczykowski D, Pease M, Zhao Y, Weiner G, Ares W, Crago E, et al. Prophylactic antiepileptics and seizure incidence following subarachnoid hemorrhage: A propensity score-matched analysis. *Stroke*. 2016 Jul;**47**(7):1754-1760. DOI: 10.1161/STROKEAHA.116.013766
- [68] Olafsson E, Gudmundsson G, Hauser WA. Risk of epilepsy in long-term survivors of surgery for aneurysmal subarachnoid hemorrhage: a population-based study in Iceland. *Epilepsia*. 2000 Sep;**41**(9):1201-1205. DOI: 10.1111/j.1528-1157.2000.tb00326.x
- [69] Claassen J, Perotte A, Albers D, Kleinberg S, Schmidt JM, Tu B, et al. Nonconvulsive seizures after subarachnoid hemorrhage: Multimodal detection and outcomes. *Annals of Neurology*. 2013 Jul;**74**(1):53-64. DOI: 10.1002/ana.23859
- [70] Rouanet C, Silva GS. Aneurysmal subarachnoid hemorrhage:

current concepts and updates.
Arquivos de Neuro-Psiquiatria.
2019 Nov;**77**(11):806-814. DOI:
10.1590/0004-282X20190112

[71] Mehvari Habibabadi J, Saadatnia M, Tabrizi N. Seizure in cerebral venous and sinus thrombosis. *Epilepsia Open*. 2018 Jun 8;**3**(3):316-322. DOI: 10.1002/epi4.12229

[72] Masuhr F, Busch M, Amberger N, Ortwein H, Weih M, Neumann K, et al. Risk and predictors of early epileptic seizures in acute cerebral venous and sinus thrombosis. *European Journal of Neurology*. 2006 Aug;**13**(8):852-856. DOI: 10.1111/j.1468-1331.2006.01371.x

[73] Ferro JM, Canhao P, Bousser MG, Stam J, Barinagarrementeria F, Investigators I. Early seizures in cerebral vein and dural sinus thrombosis: risk factors and role of antiepileptics. *Stroke*. 2008;**39**(4):1152-1158. DOI: 10.1161/STROKEAHA.107.487363

[74] Ferro JM, Correia M, Rosas MJ, Pinto AN, Neves G. Cerebral Venous Thrombosis Portuguese Collaborative Study Group [Venoport]. Seizures in cerebral vein and dural sinus thrombosis. *Cerebrovascular Diseases*. 2003;**15**(1-2):78-83. DOI: 10.1159/000067133

[75] Davoudi V, Keyhanian K, Saadatnia M. Risk factors for remote seizure development in patients with cerebral vein and dural sinus thrombosis. *Seizure*. 2014 Feb;**23**(2):135-139. DOI: 10.1016/j.seizure.2013.10.011

[76] Mahale R, Mehta A, John AA, Buddaraju K, Shankar AK, Javali M, et al. Acute seizures in cerebral venous sinus thrombosis: What predicts it? *Epilepsy Res*. Jul. 2016;**123**:1-5. DOI: 10.1016/j.epilepsyres.2016.01.011

[77] Li H, Cui L, Chen Z, Chen Y. Risk factors for early-onset seizures

in patients with cerebral venous sinus thrombosis: A meta-analysis of observational studies. *Seizure*. 2019 Nov;**72**:33-39. DOI: 10.1016/j.seizure.2019.09.006

[78] Ferro JM, Canhao P, Stam J, Bousser MG, Barinagarrementeria F, Investigators I. Prognosis of cerebral vein and dural sinus thrombosis: results of the International Study on Cerebral Vein and Dural Sinus Thrombosis (ISCVT). *Stroke*. 2004 Mar;**35**(3):664-670. DOI: 10.1161/01.STR.0000117571.76197.26

[79] Ferro JM, Bousser MG, Canhão P, Coutinho JM, Crassard I, Dentali F, et al. European Stroke Organisation guideline for the diagnosis and treatment of cerebral venous thrombosis - endorsed by the European Academy of Neurology. *European Journal of Neurology*. 2017 Oct;**24**(10):1203-1213. DOI: 10.1111/ene.13381

[80] Saposnik G, Barinagarrementeria F, Brown RD Jr, Bushnell CD, Cucchiara B, Cushman M, et al. Diagnosis and management of cerebral venous thrombosis: a statement for healthcare professionals from the American Heart Association/American Stroke Association. *Stroke*. 2011 Apr;**42**(4):1158-1192. DOI: 10.1161/STR.0b013e31820a8364

[81] Pitkänen A, Nehlig A, Brooks-Kayal AR, Dudek FE, Friedman D, Galanopoulou AS, et al. Issues related to development of antiepileptogenic therapies. *Epilepsia*. 2013 Aug;**54** Suppl 4(0 4):35-43. doi: 10.1111/epi.12297.

[82] Pitkänen A, Roivainen R, Lukasiuk K. Development of epilepsy after ischaemic stroke. *Lancet Neurology*. 2016 Feb;**15**(2):185-197. DOI: 10.1016/S1474-4422(15)00248-3

[83] Temkin NR. Antiepileptogenesis and seizure prevention trials with antiepileptic drugs: meta-analysis

of controlled trials. *Epilepsia*. 2001 Apr;**42**(4):515-524. DOI: 10.1046/j.1528-1157.2001.28900.x

[84] Altevogt BM, Paul DL. Four classes of intercellular channels between glial cells in the CNS. *The Journal of Neuroscience*. 2004 May 5;**24**(18):4313-4323. DOI: 10.1523/JNEUROSCI.3303-03.2004

[85] Walz W. Role of astrocytes in the clearance of excess extracellular potassium. *Neurochemistry International*. 2000 Apr;**36**(4-5):291-300. DOI: 10.1016/S0197-0186(99)00137-0

[86] Haydon PG, Carmignoto G. Astrocyte control of synaptic transmission and neurovascular coupling. *Physiological Reviews*. 2006 Jul;**86**(3):1009-1031. DOI: 10.1152/physrev.00049.2005

[87] Mème W, Calvo C, Froger N, Ezan P, Amigou E, Koulakoff A, et al. Proinflammatory cytokines released from microglia inhibit gap junctions in astrocytes: potentiation by beta-amyloid. *The FASEB Journal*. 2006 Mar;**20**(3):494-496. DOI: 10.1096/fj.05-4297fje

[88] Hartings JA, Williams AJ, Tortella FC. Occurrence of nonconvulsive seizures, periodic epileptiform discharges, and intermittent rhythmic delta activity in rat focal ischemia. *Experimental Neurology*. 2003 Feb;**179**(2):139-149. DOI: 10.1016/S0014-4886(02)00013-4

[89] Williams AJ, Bautista CC, Chen RW, Dave JR, Lu XC, Tortella FC, et al. Evaluation of gabapentin and ethosuximide for treatment of acute nonconvulsive seizures following ischemic brain injury in rats. *The Journal of Pharmacology and Experimental Therapeutics*. 2006 Sep;**318**(3):947-955. DOI: 10.1124/jpet.106.105999

[90] Williams AJ, Tortella FC, Gryder D, Hartings JA. Topiramate reduces non-convulsive seizures after focal brain ischemia in the rat. *Neuroscience Letters*. 2008 Jan 3;**430**(1):7-12. DOI: 10.1016/j.neulet.2007.09.052

[91] Williams AJ, Tortella FC, Lu XM, Moreton JE, Hartings JA. Antiepileptic drug treatment of nonconvulsive seizures induced by experimental focal brain ischemia. *The Journal of Pharmacology and Experimental Therapeutics*. 2004 Oct;**311**(1):220-227. DOI: 10.1124/jpet.104.069146

[92] Ikeda A, Takeyama H, Bernard C, Nakatani M, Shimotake A, Daifu M, et al. Active direct current (DC) shifts and “Red slow”: two new concepts for seizure mechanisms and identification of the epileptogenic zone. *Neuroscience Research*. 2020 Jul;**156**:95-101. DOI: 10.1016/j.neures.2020.01.014

[93] Srejjic LR, Valiante TA, Aarts MM, Hutchison WD. High-frequency cortical activity associated with postischemic epileptiform discharges in an in vivo rat focal stroke model. *Journal of Neurosurgery*. 2013 May;**118**(5):1098-1106. DOI: 10.3171/2013.1.JNS121059

[94] Amzica F, Steriade M. Neuronal and glial membrane potentials during sleep and paroxysmal oscillations in the neocortex. *The Journal of Neuroscience*. 2000 Sep 1;**20**(17):6648-6665. DOI: 10.1523/JNEUROSCI.20-17-06648.2000

[95] Mies G, Iijima T, Hossmann KA. Correlation between peri-infarct DC shifts and ischaemic neuronal damage in rat. *Neuroreport*. 1993 Jun;**4**(6):709-711. DOI: 10.1097/00001756-199306000-00027

[96] Ramírez-Sánchez J, Pires ENS, Meneghetti A, Hansel G, Nuñez-Figueroa Y, Pardo-Andreu GL, et al. JM-20 treatment after MCAO reduced astrocyte reactivity and neuronal death on peri-infarct regions of the

rat brain. *Molecular Neurobiology*. 2019 Jan; **56**(1):502-512. DOI: 10.1007/s12035-018-1087-8

[97] Titova EM, Ghosh N, Valadez ZG, Zhang JH, Bellinger DL, Obenaus A. The late phase of post-stroke neurorepair in aged rats is reflected by MRI-based measures. *Neuroscience*. 2014 Dec 26; **283**:231-244. DOI: 10.1016/j.neuroscience.2014.09.028

[98] Titova E, Ostrowski RP, Adami A, Badaut J, Lalas S, Ghosh N, et al. Brain irradiation improves focal cerebral ischemia recovery in aged rats. *Journal of the Neurological Sciences*. 2011 Jul 15; **306**(1-2):143-153. DOI: 10.1016/j.jns.2011.02.034

[99] Block ML, Hong JS. Microglia and inflammation-mediated neurodegeneration: Multiple triggers with a common mechanism. *Progress in Neurobiology*. 2005 Jun; **76**(2):77-98. DOI: 10.1016/j.pneurobio.2005.06.004

[100] Chen Y, Wang L, Zhang L, Chen B, Yang L, Li X, et al. Inhibition of connexin 43 hemichannels alleviates cerebral ischemia/reperfusion injury via the TLR4 signaling pathway. *Frontiers in Cellular Neuroscience*. 2018 Oct 17; **12**:372. DOI: 10.3389/fncel.2018.00372

[101] Bruzzone S, Guida L, Zocchi E, Franco L, De Flora A. Connexin 43 hemichannels mediate Ca²⁺-regulated transmembrane NAD⁺ fluxes in intact cells. *The FASEB Journal*. 2001 Jan; **15**(1):10-12. DOI: 10.1096/fj.00-0566fje

[102] Stout CE, Costantin JL, Naus CC, Charles AC. Intercellular calcium signaling in astrocytes via ATP release through connexin hemichannels. *The Journal of Biological Chemistry*. 2002 Mar 22; **277**(12):10482-10488. DOI: 10.1074/jbc.M109902200

[103] Ye ZC, Wyeth MS, Baltan-Tekkok S, Ransom BR. Functional

hemichannels in astrocytes: a novel mechanism of glutamate release. *The Journal of Neuroscience*. 2003 May 1; **23**(9):3588-3596. DOI: 10.1523/JNEUROSCI.23-09-03588.2003

[104] Cherian PP, Siller-Jackson AJ, Gu S, Wang X, Bonewald LF, Sprague E, et al. Mechanical strain opens connexin 43 hemichannels in osteocytes: a novel mechanism for the release of prostaglandin. *Molecular Biology of the Cell*. 2005 Jul; **16**(7):3100-3106. DOI: 10.1091/mbc.e04-10-0912

[105] Rana S, Dringen R. Gap junction hemichannel-mediated release of glutathione from cultured rat astrocytes. *Neuroscience Letters*. 2007 Mar 19; **415**(1):45-48. DOI: 10.1016/j.neulet.2006.12.043

[106] Orellana JA, Froger N, Ezan P, Jiang JX, Bennett MV, Naus CC, et al. ATP and glutamate released via astroglial connexin 43 hemichannels mediate neuronal death through activation of pannexin 1 hemichannels. *Journal of Neurochemistry*. 2011 Sep; **118**(5):826-840. DOI: 10.1111/j.1471-4159.2011.07210.x

[107] Chen CJ, Liao SL, Kuo JS. Gliotoxic action of glutamate on cultured astrocytes. *Journal of Neurochemistry*. 2000 Oct; **75**(4):1557-1565. DOI: 10.1046/j.1471-4159.2000.0751557.x

[108] Pekny M, Pekna M. Reactive gliosis in the pathogenesis of CNS diseases. *Biochimica et Biophysica Acta*. 2016 Mar; **1862**(3):483-491. DOI: 10.1016/j.bbdis.2015.11.014

[109] Löscher W, Brandt C. Prevention or modification of epileptogenesis after brain insults: experimental approaches and translational research. *Pharmacological Reviews*. 2010 Dec; **62**(4):668-700. DOI: 10.1124/pr.110.003046

[110] Turski WA, Cavalheiro EA, Schwarz M, Czuczwar SJ, Kleinrok Z,

Turski L. Limbic seizures produced by pilocarpine in rats: behavioural, electroencephalographic and neuropathological study. *Behavioural Brain Research*. 1983 Sep;**9**(3):315-335. DOI: 10.1016/0166-4328(83)90136-5

[111] Nagao Y, Harada Y, Mukai T, Shimizu S, Okuda A, Fujimoto M, et al. Expressional analysis of the astrocytic Kir4.1 channel in a pilocarpine-induced temporal lobe epilepsy model. *Frontiers in Cellular Neuroscience*. 2013 Jul 5;**7**:104. doi: 10.3389/fncel.2013.00104.

[112] Heinemann U, Gabriel S, Jauch R, Schulze K, Kivi A, Eilers A, et al. Alterations of glial cell function in temporal lobe epilepsy. *Epilepsia*. 2000;**41**(Suppl 6):S185-S189. DOI: 10.1111/j.1528-1157.2000.tb01579.x

[113] Wang N, Mi X, Gao B, Gu J, Wang W, Zhang Y, et al. Minocycline inhibits brain inflammation and attenuates spontaneous recurrent seizures following pilocarpine-induced status epilepticus. *Neuroscience*. 2015 Feb 26;**287**:144-156. DOI: 10.1016/j.neuroscience.2014.12.021

[114] Ramsay RE, Rowan AJ, Pryor FM. Special considerations in treating the elderly patient with epilepsy. *Neurology*. 2004 Mar 9;**62**(5 Suppl 2):S24-S29. DOI: 10.1212/wnl.62.5_suppl_2.s24

[115] Tomari S, Tanaka T, Matsubara S, Fukuma K, Ihara M, Nagatsuka K, et al. Risk factors for nonconvulsive status epilepticus after stroke. *European Neurology*. 2018;**80**(5-6):256-260. DOI: 10.1159/000496512

[116] Bouma HK, Labos C, Gore GC, Wolfson C, Keezer MR. The diagnostic accuracy of routine electroencephalography after a first unprovoked seizure. *European Journal of Neurology*. 2016 Mar;**23**(3):455-463. DOI: 10.1111/ene.12739

[117] Yoshimura H, Matsumoto R, Ueda H, Ariyoshi K, Kawamoto M,

Ishii J, et al. Status epilepticus in the elderly: Prognostic implications of rhythmic and periodic patterns in electroencephalography and hyperintensities on diffusion-weighted imaging. *Journal of the Neurological Sciences*. 2016 Nov 15;**370**:284-289. DOI: 10.1016/j.jns.2016.09.062

[118] Yoshimura H, Matsumoto R, Ueda H, Ariyoshi K, Ikeda A, Takahashi R, et al. Status epilepticus in the elderly: Comparison with younger adults in a comprehensive community hospital. *Seizure*. 2018 Oct;**61**:23-29. DOI: 10.1016/j.seizure.2018.07.013

[119] Hirsch LJ, LaRoche SM, Gaspard N, Gerard E, Svoronos A, Herman ST, et al. American Clinical Neurophysiology Society's Standardized Critical Care EEG Terminology: 2012 version. *Journal of Clinical Neurophysiology*. 2013 Feb;**30**(1):1-27. DOI: 10.1097/WNP.0b013e3182784729

[120] Leitinger M, Trinkka E, Gardella E, Rohracher A, Kalss G, Qerama E, et al. Diagnostic accuracy of the Salzburg EEG criteria for non-convulsive status epilepticus: a retrospective study. *Lancet Neurology*. 2016 Sep;**15**(10):1054-1062. DOI: 10.1016/S1474-4422(16)30137-5

[121] Shimogawa T, Morioka T, Sayama T, Haga S, Kanazawa Y, Murao K, et al. The initial use of arterial spin labeling perfusion and diffusion-weighted magnetic resonance images in the diagnosis of nonconvulsive partial status epilepticus. *Epilepsy Research*. 2017 Jan;**129**:162-173. DOI: 10.1016/j.epilepsyres.2016.12.008

[122] Takahara K, Morioka T, Shimogawa T, Haga S, Kameda K, Arihiro S, et al. Hemodynamic state of periictal hyperperfusion revealed by arterial spin-labeling perfusion MR images with dual postlabeling delay. *eNeurologicalSci*. 2018 Jun 26;**12**:5-18. DOI: 10.1016/j.ensci.2018.06.001

- [123] Trinká E, Brigo F. Antiepileptogenesis in humans: disappointing clinical evidence and ways to move forward. *Current Opinion in Neurology*. 2014 Apr;27(2):227-235. DOI: 10.1097/WCO.0000000000000067
- [124] Gilad R, Lampl Y, Eschel Y, Sadeh M. Antiepileptic treatment in patients with early postischemic stroke seizures: a retrospective study. *Cerebrovascular Diseases*. 2001;12(1):39-43. DOI: 10.1159/000047679
- [125] Marson A, Jacoby A, Johnson A, Kim L, Gamble C, Chadwick D; Medical Research Council MESS Study Group. Immediate versus deferred antiepileptic drug treatment for early epilepsy and single seizures: a randomised controlled trial. *Lancet*. 2005 Jun 11-17;365(9476):2007-2013. doi: 10.1016/S0140-6736(05)66694-9.
- [126] Youssef S, Stüve O, Patarroyo JC, Ruiz PJ, Radosevich JL, Hur EM, et al. The HMG-CoA reductase inhibitor, atorvastatin, promotes a Th2 bias and reverses paralysis in central nervous system autoimmune disease. *Nature*. 2002 Nov 7;420(6911):78-84. DOI: 10.1038/nature01158
- [127] Guo J, Guo J, Li J, Zhou M, Qin F, Zhang S, et al. Statin treatment reduces the risk of poststroke seizures. *Neurology*. 2015 Aug 25;85(8):701-707. DOI: 10.1212/WNL.0000000000001814
- [128] Vitturi BK, Gagliardi RJ. The influence of statins on the risk of post-stroke epilepsy. *Neurological Sciences*. 2020 Jul;41(7):1851-1857. DOI: 10.1007/s10072-020-04298-5
- [129] Leone MA, Giussani G, Nolan SJ, Marson AG, Beghi E. Immediate antiepileptic drug treatment, versus placebo, deferred, or no treatment for first unprovoked seizure. *Cochrane Database of Systematic Reviews*. 2016 May 6;2016(5):CD007144. DOI: 10.1002/14651858.CD007144.pub2
- [130] Jin J, Chen R, Xiao Z. Post-epilepsy stroke: A review. *Expert Review of Neurotherapeutics*. 2016;16(3):341-349. DOI: 10.1586/14737175.2016.1151355
- [131] Brigo F, Lattanzi S, Zelano J, Bragazzi NL, Belcastro V, Nardone R, et al. Randomized controlled trials of antiepileptic drugs for the treatment of post-stroke seizures: A systematic review with network meta-analysis. *Seizure*. 2018 Oct;61:57-62. DOI: 10.1016/j.seizure.2018.08.001
- [132] Katsiki N, Mikhailidis DP, Nair DR. The effects of antiepileptic drugs on vascular risk factors: a narrative review. *Seizure*. 2014 Oct;23(9):677-684. DOI: 10.1016/j.seizure.2014.05.011
- [133] Isojärvi JI, Laatikainen TJ, Knip M, Pakarinen AJ, Juntunen KT, Myllylä VV. Obesity and endocrine disorders in women taking valproate for epilepsy. *Annals of Neurology*. 1996 May;39(5):579-584. DOI: 10.1002/ana.410390506
- [134] Verrotti A, Manco R, Agostinelli S, Coppola G, Chiarelli F. The metabolic syndrome in overweight epileptic patients treated with valproic acid. *Epilepsia*. 2010 Feb;51(2):268-273. DOI: 10.1111/j.1528-1167.2009.02206.x
- [135] Zeng K, Wang X, Xi Z, Yan Y. Adverse effects of carbamazepine, phenytoin, valproate and lamotrigine monotherapy in epileptic adult Chinese patients. *Clinical Neurology and Neurosurgery*. 2010 May;112(4):291-295. DOI: 10.1016/j.clineuro.2009.12.014
- [136] Biton V. Effect of antiepileptic drugs on bodyweight: overview and clinical implications for the treatment of epilepsy. *CNS Drugs*. 2003;17(11):781-791. DOI: 10.2165/00023210-200317110-00002

- [137] Apovian CM, Aronne LJ. Zonisamide for weight reduction in obese adults. *Journal of the American Medical Association*. 2013 Aug 14;**310**(6):637-638. DOI: 10.1001/jama.2013.101049
- [138] Janousek J, Barber A, Goldman L, Klein P. Obesity in adults with epilepsy. *Epilepsy & Behavior*. 2013 Sep;**28**(3):391-394. DOI: 10.1016/j.yebeh.2013.05.012
- [139] Talaat FM, Kamel T, Rabah AM, Ahmed SM, El-Jaafary SI, Abdelaziz GH. Epilepsy and antiepileptic drugs: risk factors for atherosclerosis. *The International Journal of Neuroscience*. 2015;**125**(7):507-511. DOI: 10.3109/00207454.2014.949704
- [140] Chuang YC, Chuang HY, Lin TK, Chang CC, Lu CH, Chang WN, et al. Effects of long-term antiepileptic drug monotherapy on vascular risk factors and atherosclerosis. *Epilepsia*. 2012 Jan;**53**(1):120-128. DOI: 10.1111/j.1528-1167.2011.03316.x
- [141] Yiş U, Doğan M. Effects of oxcarbazepine treatment on serum lipids and carotid intima media thickness in children. *Brain & Development*. 2012 Mar;**34**(3):185-188. DOI: 10.1016/j.braindev.2011.05.009
- [142] Ashjazadeh N, Fathi M, Shariat A. Evaluation of homocysteine level as a risk factor among patients with ischemic stroke and its subtypes. *Iranian Journal of Medical Sciences*. 2013 Sep;**38**(3):233-239
- [143] Belcastro V, Striano P, Gorgone G, Costa C, Ciampa C, Caccamo D, et al. Hyperhomocysteinemia in epileptic patients on new antiepileptic drugs. *Epilepsia*. 2010 Feb;**51**(2):274-279. DOI: 10.1111/j.1528-1167.2009.02303.x
- [144] Marchi A, Pennaroli D, Lagarde S, McGonigal A, Bonini F, Carron R, et al. Epileptogenicity and surgical outcome in post stroke drug resistant epilepsy in children and adults. *Epilepsy Research*. 2019 Sep;**155**:106155. DOI: 10.1016/j.eplesyres.2019.106155
- [145] Lee CY, Yeh SJ, Tsai LK, Tang SC, Jeng JS. Dural arteriovenous fistula presenting with status epilepticus treated successfully with endovascular intervention. *Acta Neurologica Taiwanica*. 2015 Jun;**24**(2):52-56