

# We are IntechOpen, the world's leading publisher of Open Access books Built by scientists, for scientists

5,600

Open access books available

137,000

International authors and editors

170M

Downloads

Our authors are among the

154

Countries delivered to

TOP 1%

most cited scientists

12.2%

Contributors from top 500 universities



WEB OF SCIENCE™

Selection of our books indexed in the Book Citation Index  
in Web of Science™ Core Collection (BKCI)

Interested in publishing with us?  
Contact [book.department@intechopen.com](mailto:book.department@intechopen.com)

Numbers displayed above are based on latest data collected.  
For more information visit [www.intechopen.com](http://www.intechopen.com)



# Approach to the Newborn with Disorders of Sex Development

*Pierre Sinajon, Riyana Babul-Hirji and David Chitayat*

## Abstract

The birth of a baby with atypical external and/or internal genitalia is a family crisis that requires the interaction between multidisciplinary group physicians including pediatric urologists, pediatric endocrinologists, medical geneticists, genetic counsellors, gynecologists, psychologists/psychiatrists and social workers with expertise in this field. Following each of the specialists' assessment the findings, plan for investigations, the psychosocial situation and gender assignment and treatment should be reviewed among the group members prior to meeting the family. Following the group discussion the information should be presented to the parents using easy to understand language with visual aids and their questions should be answered so that they can make an informed decision regarding gender assignment, surgical options, where medically indicated, and hormone treatment. Potential for sexual relationships and fertility preservation should be discussed. The birth of a baby with abnormalities may be associated with mother/parental guilt feeling and the point that there is nothing that they did or did not do that caused the newborn's condition. Disorder of sex development (DSD) can be divided into isolated and non-isolated according to the finding on physical examination and should be further classified into abnormalities of chromosomal abnormalities, gonadal defect, internal and external genital abnormalities. Investigations should be directed by the physical examination findings and the results of the radiological, endocrine and genetic investigation including FISH analysis, microarray analysis, DNA analysis using a variety of DSD panels and, when required, whole exome/genome sequencing.

**Keywords:** sex development, sex differentiation, gonadal differentiation, genital abnormalities, congenital adrenal hyperplasia, androgen secretion, androgen action, androgen insensitivity, gender assignment, psychosocial status

## 1. Introduction

Sex development involves many autosomal and X-linked genes acting and interacting along a short duration in a precise synergy. The process of sex determination includes 4 layers:

1. Determination of the chromosome sex
2. Determination of the gonadal sex

3. Development of the internal genitalia

4. Determination of the external genitalia

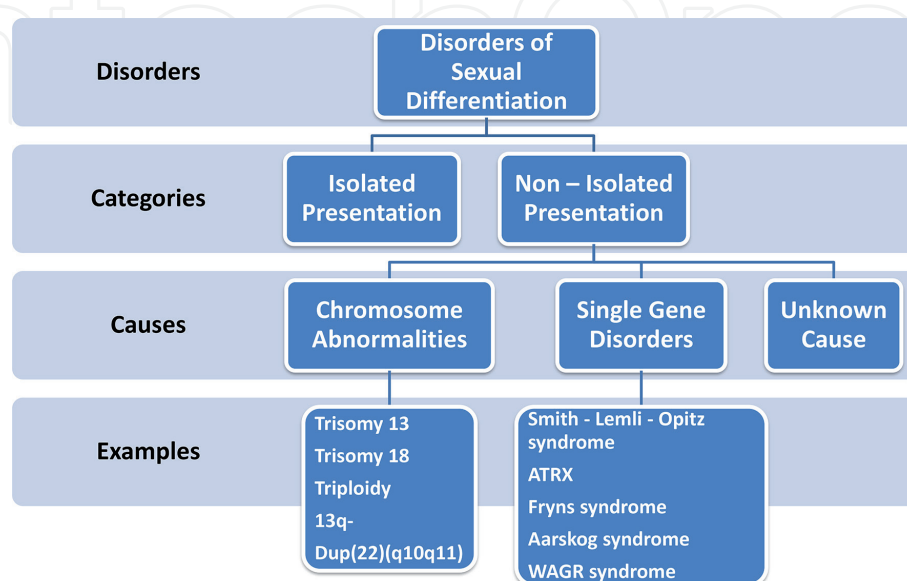
DSD is a heterogeneous group of congenital abnormalities associated with atypical development of the external and internal genitalia with an estimated incidence of 1:200–1:4500 [1]. Some of the abnormalities seem to have increased in incidence along the years with hypospadias reported to reach an incidence of 1:125 newborn males and cryptorchidism reaching an incidence as high as 3% of full-term male newborns.

The nomenclature used to describe the genital abnormalities was initially descriptive, and on many occasions offensive. The advances in genetics and genomics knowledge substantially improved our understanding of the etiology of these conditions and resulted in a need to change the nomenclature. Thus, a new concept was introduced at the Chicago Consensus Conference 2005 [2] which defined the DSD as a congenital condition in which the development of chromosomal, gonadal or anatomical sex is atypical (instead of abnormal or ambiguous).

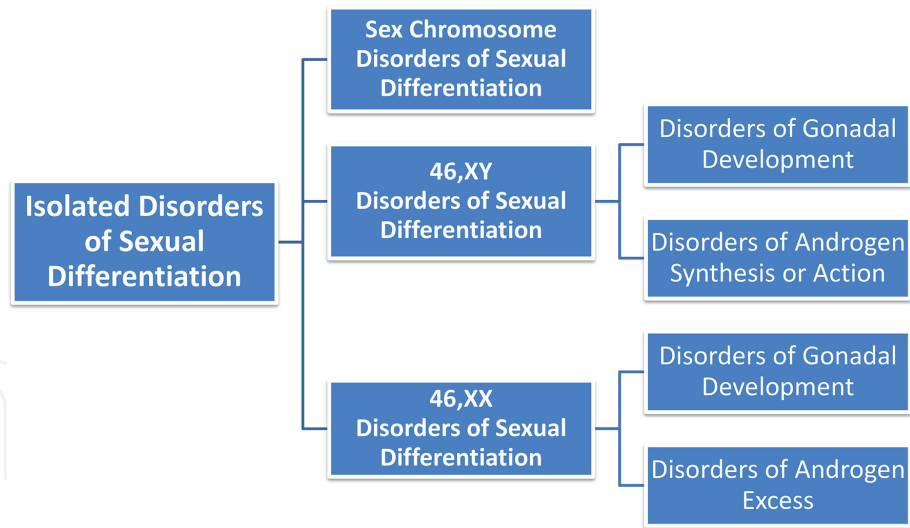
DSD can be divided into isolated or non-isolated/associated with other major abnormalities (**Figure 1**). When non-isolated they are usually associated with a variety of chromosome abnormalities, single gene or developmental field disorders which involve different body organ and systems (**Figure 2**). This review will mainly highlight the isolated/non-syndromic group of disorders of sex development.

In humans, the gonads are populated by primordial germ cells, deriving from the yolk sac wall early in week five post conception. Normally, it is the presence or absence of the of the SRY gene in the Y chromosome in the germ cells that starts the chain of events which cause the gonadal determination as testis in males. The secretion of testicular hormones in males and their attachment to their action through receptors results in normal development of the male internal and external genitalia (**Figures 3 and 4**). The absence of the SRY gene or function and the expression of genes induced by them will result in the development of ovaries. The lack of hormones produced by the testis will determine the normal formation of female internal and external genitalia (**Figures 3 and 4**).

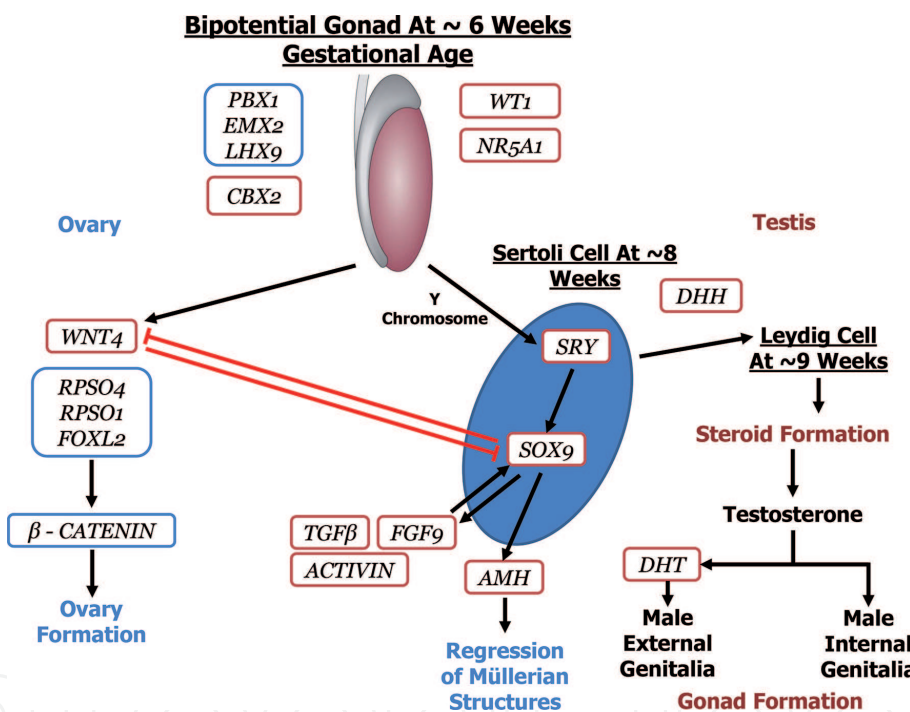
It was previously thought that the absence of SRY gene in the gonadal ridge will result in ovarian differentiation while the existence of the SRY gene will result in



**Figure 1.** Disorders of sex development—initial assessment.



**Figure 2.**  
 Differential diagnosis in isolated disorders of sex development.

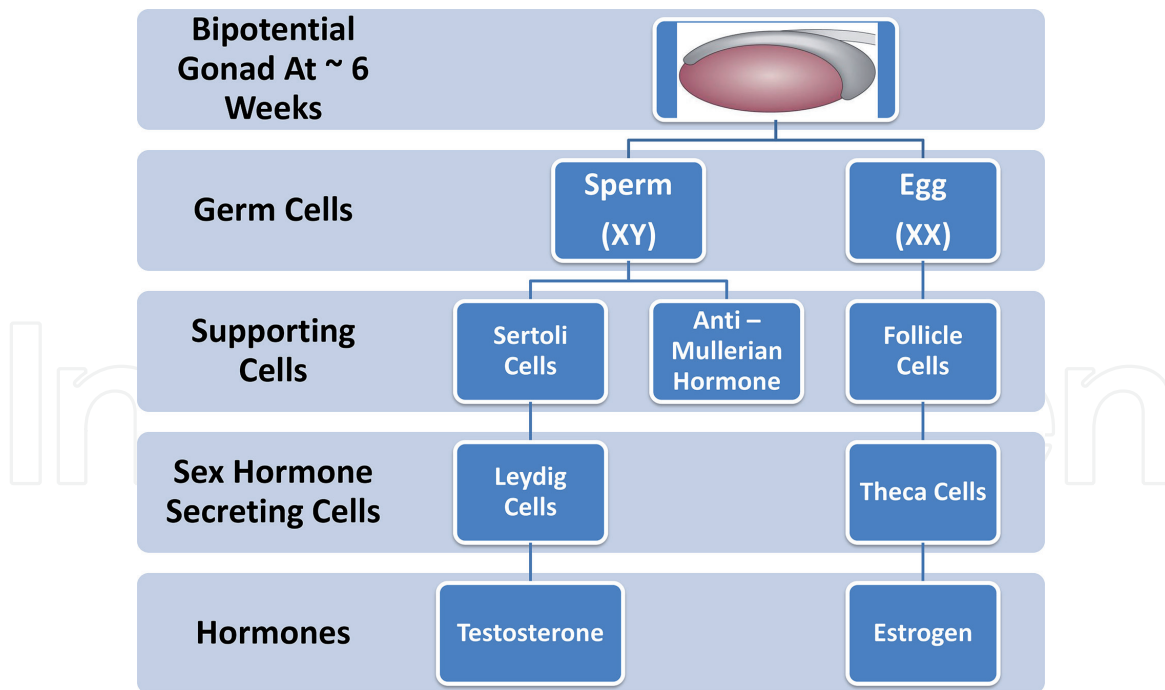


**Figure 3.**  
 Gonadal differentiation and function.

testicular development. However it is currently clear that gonadal sex is determined by antagonistic actions of ovarian and testicular cascades [5, 6] around week six post conception. In the female embryo, high levels of retinoic acid around the germ cells induces the STRA8 gene expression, resulting in germ cell meiosis and formation of oocytes. The absence of retinoic acid in the developing testis, results in formation of gonocytes which differentiate into spermatogonia and proliferate through mitosis with the meiosis happening after puberty [7].

There are three main differences between ovarian and testicular activities (**Figure 3**):

1. The testes produce testosterone early in embryogenesis which induce the formation of the male external genital while the ovaries produce hormones only from puberty



**Figure 4.**  
Diagram of the known major genes involved in testicular and ovarian differentiation and function (adapted from [3, 4]).

2. Oogenesis starts and ends prior to 20 weeks gestation while spermatogenesis starts only at puberty
3. The ovarian hormonal production/function is linked to the process of follicle development and/or maintenance. The testes on the other hand can continue producing testosterone even in the lack of spermatogenesis.

The management of a newborn with abnormal genitalia has to be individualized taking into account the specific genital abnormalities as well as the parental and family as a whole. The decision regarding the sex of rearing should take into account the, surgical and non-surgical treatment, future pubertal development and fertility. This should be considered an urgent clinical situation and requires immediate assessment and counselling, and if possible, involvement of the DSD multidisciplinary core team including endocrinology, clinical genetics, genetic counselling, urology, obstetrics and gynecology, social work and psychology/ psychiatry among others.

## 2. Sex chromosome disorders of sex development

Although the majority of sex chromosome abnormalities do not have genital differences as a clinical finding, some do. At conception 2% of all pregnancies are Turner syndrome and is one of the most common chromosome abnormality associated with first trimester miscarriages. The condition is highly lethal in-utero and thus the incidence at birth is 1:2500 female newborn. In almost 2/3 of cases, i.e. 60%, the karyotype is 45,X while in 15%, the condition is associated with mosaicism, i.e. 45, X/47,XXX, 45,X/46, XX/47,XXX, 45,X/46, XY, and 45,X/46, XX. Other chromosome abnormalities associated with Turner syndrome include structural abnormalities involving the X chromosome, e.g., 46,X,r(X), 46,X,Xp-, and

46,X,i(Xq) in 10% of cases, structural abnormality of the X chromosome in mosaic state in 10% of cases, with 5% in the other [8]. The condition can be detected prenatally, due to abnormalities in the lymphatic system, with the fetus presenting with heart lesions, specifically left-sided, hydrops fetalis, increased nuchal translucency or cystic hygroma. Postnatally, female babies can present with typical facial features, including epicanthic folds, droopy eyelids, down slanting palpebral fissures, micrognathia, and low set and prominent ears. The neck is often webbed and short with a nuchal hairline that is low, as well as swelling (lymphedema) of the feet and hands, and deep set nails. Left-sided cardiac anomalies are seen in 50% of the cases (hypoplastic left heart, coarctation of the aorta, bicuspid aortic valve, and aortic stenosis) with an increased risk for aortic dissection during pregnancy and the puerperal period if they decide to conceive using a donor egg. It is also associated with horseshoe kidneys as well as short stature, streak gonads and thus lack of spontaneous puberty. However, they can conceive using a donor egg.

Genetic analysis for Y chromosome material, including in a mosaic state can be picked up by chromosome microarray analysis and is important since girls with mosaicism for 46, XY [45,X/46,XY] have an increased risk for gonadoblastoma and dysgerminoma and may have absent uterus. A large British series in the literature, looking at women with Turner syndrome, showed an increased incidence not only of gonadoblastoma, but also uterine cancer, as well as possibly pediatric brain cancers. This study also demonstrated a lower incidence of breast cancer [9–11].

The incidence of Klinefelter syndrome, i.e. 47, XXY is approximately 1 in 500 males. Clinically, they can present with testes on the smaller end of the spectrum, which can impact production of testosterone and normal sperm. Otherwise, they do not have genital differences. They have normal appearing facies but can be taller in height than average and about 50% develop gynecomastia at puberty. Boys with Klinefelter syndrome can present with neurodevelopmental/neurobehavioral issues; however encouraging results, for behavioral as well as for the physical features described above, have been seen with early administration of testosterone. The optimal timing and dosage of hormonal therapy has not been established and further studies and long term follow-up are needed prior to this becoming standard treatment [12].

Mosaicism for 45,X/46, XY, also previously called mixed gonadal dysgenesis, is a rare condition with an approximate incidence reported in Denmark of less than 1/15,000 live births [8]. It has been suggested that transformation of the indifferent gonad to testes [13–15] is due to the existence of Y chromosome in the gonadal ridge. The spectrum of genital differences with this karyotype is varied, ranging from females presenting with Turner syndrome, to males with ambiguous genitalia, to phenotypically normal males. Gonadal function in most 45,X/46, XY males, even those with genital ambiguity, seems sufficient for spontaneous puberty and patients appear to benefit from GH treatment when needed [16].

### **3. 46, XY disorders of sex development**

46, XY DSD can be divided into categories;

1. Disorders of testicular (gonadal) development
2. Disorders of androgen synthesis

Both categories lead to feminization or abnormal genitalia.

### 3.1 Disorders of testicular (gonadal) development

Disorders of testicular (gonadal) development are characterized by absent or small testes on palpation and/or ultrasound. Müllerian structures (uterus and fallopian tubes) can be present with the external genitalia feminized to varying degrees along with decreased levels of testosterone, dehydroepiandrosterone and androstenedione [17].

At approximately 6 weeks, the gonads can form ovaries or testis [3]. The process of testicular differentiation involves multiple genes (**Figure 4**). Mutations causing haploinsufficiency with a loss of function and duplication with gain of function are known to be associated with 46, XY gonadal DSD. The *SRY* gene encodes a transcription factor that causes a cascade effect allowing the bipotential gonad to form testis [18]. Pathogenic variants and deletions involving the *SRY* gene lead to complete gonadal dysgenesis or 46, XY pure gonadal dysgenesis. Approximately 15% of individuals with Swyer syndrome have this finding. Swyer Syndrome is also known as 46, XY complete gonadal dysgenesis or 46, XY pure gonadal dysgenesis. Patients with Swyer Syndrome present with female internal and external genitalia.

The *SRY* and *NR5A1* genes activate *SOX9* and the anti-Müllerian hormone (AMH) formation and lead to secretion by the Sertoli cells [19]. Mutations in the *SOX9* gene [OMIM # 608160] presents with campomelic dysplasia and sex reversal in 50% of the cases with 46, XY. A heterozygous deletion of approximately 240 kb (between 405 kb – 645 kb upstream of the *SOX9* transcription start site) was reported with 46,XY with a normal external female phenotype and severe ambiguous and asymmetric external genitalia [20]. Another case presenting as 46, XX male resulted from a heterozygous duplication upstream of the *SOX9* gene on chromosome 17 [21].

The ligand *FGF9* and the signaling molecule *WNT4* are expressed in the undifferentiated gonad. Further in development they continue to be expressed in the ovary and the testis providing opposing signals that determine gonadal differentiation. *FGF9* promotes testicular differentiation and the Wnt family member (*WNT*)/R-spondin 1 signaling and forkhead box L2 (*FOXL2*) drive female sex determination in XX gonads and promotes ovarian differentiation. Testicular formation is established when the *SRY* gene initiates a feed-forward loop. *SRY* interacts with *SOX9* and *FGF9* leading to upregulation of *FGF9* and repression of *WNT4*. The receptor for the *FGF9* in the developing testis is *FGFR2* [22]. *NR5A1* gene (also known as *SF-1*) (OMIM 184757) is another important gene for the bipotential gonad. This orphan nuclear receptor is expressed in multiple locations including hypothalamus, pituitary, gonads and adrenal glands [3]. Pathogenic variants in this gene can lead to females with premature ovarian failure. They can also present in 46,XY DSD ranging from ambiguous genitalia to female external genitalia with complete to incomplete regression of the Müllerian duct derivatives [23–25]. Various mutations including p.G35D, p.G35E, p.R92Q and p.R255L have been seen to cause adrenal insufficiency combined with gonadal dysfunction. *DAX1* is another important orphan nuclear receptor with roles in the hypothalamus, pituitary, gonads and adrenal glands [26].

The Wilms tumor factor 1 (*WT1*) pathogenic gene mutations are commonly associated with Denys–Drash and Frasier syndrome along with an increased risk for nephroblastoma. Denys–Drash classically presents with a triad of symptoms including genitourinary abnormalities, renal impairment and Wilms tumor [27]. Frasier syndrome classically presents with focal segmental glomerulonephritis (typically presenting as later onset renal impairment) and an increased risk for Wilms tumor. This risk is not as high compared to other *WT1* related conditions. Other genes of interest include *CBX2* and *DHH*. *CBX2* is involved in both the regulation of

homeotic genes and of the bipotential gonad [3]. Pathogenic variants in the *CBX2* gene have presented as a normal female (internal and external genitalia). These studies suggest that *CBX2* could be responsible for repression of ovarian development [28]. In XY individuals with *MAP3K1* pathogenic variants are associated with suppressing *SOX9* and shifting the signaling pathway to promote ovarian differentiation [29]. At approximately 9 weeks of embryonic development Leydig cell differentiation occurs involving *DHH* [3]. Pathogenic variants in *DHH* can cause complete or partial gonadal dysgenesis. They can also be found in minifascicular neuropathy (OMIM 605423) [30]. Pathogenic variants in *DAX1* can cause congenital adrenal hypoplasia and hypogonadotropic hypogonadism (OMIM 300473) and complete or partial gonadal development with ambiguous external genitalia [4]. Other genes associated with XY gonadal dysgenesis include *DMRT1*, *DMRT2*, *SOX3* and *SOX8* among others [31].

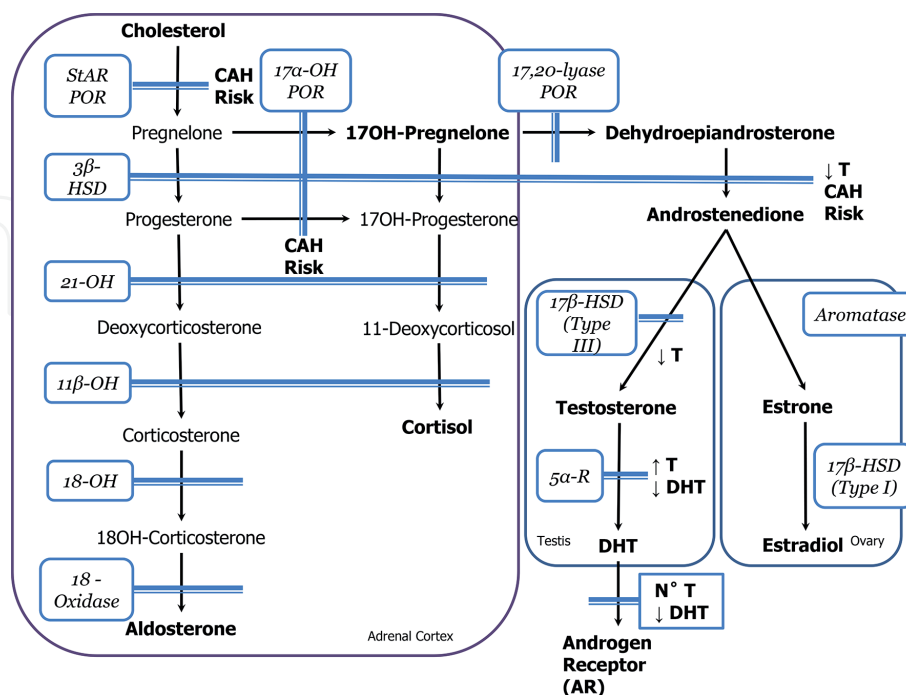
### 3.2 Disorders of androgen synthesis

Disorders of androgen synthesis are characterized by a lack of Müllerian structures. The testes in 46, XY individuals produce Anti-Müllerian hormone and have genital abnormalities including normal female external genitalia.

Two categories can be used to describe Disorders of Androgen Synthesis:

1. Congenital adrenal hyperplasia (CAH) in patients with female chromosome sex
2. Associated with normal adrenal function.

Seven enzymes involved in the production of testosterone and dihydrotestosterone, responsible for 46, XY disorders of sex differentiation have been identified (Figure 5).



**Figure 5.** Steroid hormone synthesis pathway and associated biochemical abnormalities in 46, XY DSD. POR: P450 oxidoreductase; StAR: steroid acute regulatory protein; 17 $\alpha$ -OH: 17 $\alpha$ -hydroxylase; 3 $\beta$ -HSD: 3 $\beta$ -hydroxysteroid dehydrogenase; 21-OH: 21-hydroxylase; 18-OH: 18-hydroxylase; 11 $\beta$ -OH: 11 $\beta$ -hydroxylase; 17 $\beta$ -HSD: 17 $\beta$ -hydroxysteroid dehydrogenase; 5 $\alpha$ -R: 5 $\alpha$ -reductase; CAH: congenital adrenal hyperplasia (adapted from [17]).



### *3.2.1 Disorders of androgen synthesis associated with adrenal dysfunction*

Defects early in the pathway result in congenital adrenal hyperplasia and adrenal insufficiency. These enzymes are present in both the adrenal cortex and the gonads.

The first enzymatic step involves the steroidogenic acute regulatory (*StAR*) protein and p450 oxidoreductase (*POR*) (**Figure 5**), these enzymes cause the cleavage of cholesterol to pregnenolone. Pathogenic mutations in the *StAR* gene lead to an autosomal recessive lipid congenital adrenal hyperplasia (OMIM 201710). The condition is characterized by lipid accumulation, severe salt wasting and genital ambiguity. This genital involvement ranges from hypospadias to complete female external genitalia. P450 oxidoreductase defects are commonly associated with Antley-Bixler syndrome with genital anomalies and disorders in steroidogenesis (OMIM 201750). P450 oxidoreductase defects have been found with a non-syndromic presentation (OMIM 613571) with a similar picture to *StAR* mutations but lacking CAH [32].

3 $\beta$ -hydroxysteroid dehydrogenase (3 $\beta$ -HSD) is the next major enzyme involved in multiple steps including converting pregnenolone to progesterone, 17 $\alpha$ -OH pregnenolone to 17 $\alpha$ -OH progesterone and DHEA to androstenedione. Defects in 3 $\beta$ -HSD enzyme activity result in salt wasting and decreased testosterone production resulting in genital abnormalities in males. The findings include hypospadias, micropenis and bifid scrotum (OMIM 201810).

17 $\alpha$ -hydroxylase is involved in the conversion pregnenolone and progesterone to their 17 $\alpha$  hydroxylated forms. Defects to this enzyme pathway also present with increased risk for adrenal insufficiency and ambiguous genitalia. Patients presenting with a combined deficiency in 17 $\alpha$ -hydroxylase and 17,20-lyase present similarly to isolated 17 $\alpha$ -hydroxylase deficiency. Patients with isolated 17,20-lyase deficiency have normal adrenal function and variable abnormalities of male phenotype. This is because 17,20-lyase is present in the gonads only.

### *3.2.2 Disorders of androgen synthesis not associated with adrenal dysfunction*

17 $\beta$ -hydroxysteroid dehydrogenase type III (**Figure 5**) leads to the conversion of androstenedione into testosterone, this occurs within the gonads. Pathogenic variants cause an autosomal recessive disorder (OMIM 264300) with female external genitalia in 46, XY individuals, male gonadal derivatives, absent Müllerian structures, infertility and decreased testosterone [33]. These patients are sometimes difficult to distinguish from 5 $\alpha$ -reductase deficiency and partial androgen insensitivity syndrome [34]. Further biochemical testing with ACTH stimulation or hCG stimulation may be needed [17] although DNA analysis is probably the easiest to perform.

Testosterone and dihydrotestosterone (DHT) are the end products for testis steroid hormone synthesis. Pathogenic variants occurring in the 5 $\alpha$ -reductase gene (*SRD5A2*) lead to various biochemical changes including low levels of DHT, normal/increased levels of testosterone and high testosterone/DHT levels. Patients present with undermasculinization of the external genitalia due to low levels of DHT [34]. The presentation ranges from a female phenotype to a small phallus with severe hypospadias. These patients have normal male internal genitalia and some patients may have normal sperm production.

## **3.3 Disorders of androgen response**

The most common cause of 46, XY DSD are the androgen insensitivity syndromes (AIS) [OMIM # 300068]. The androgen receptor (AR) is unable to activate due to the inability of testosterone or DHT to bind to the receptor [35]

(Figure 5). Androgens have a lack of effect on genital development. These conditions are X-linked inherited and present with a wide range in phenotypes. Complete Androgen Insensitivity Syndrome (CAIS) has an estimated prevalence of at least 1:99,000 [36] presenting with normal female genitalia and blind ending vaginal pouch. Partial Androgen Insensitivity Syndrome (PAIS) has an estimated prevalence of 1:8000. This condition occurs when there is residual AR receptor function and hypospadias are the common finding. Mild Androgen Insensitivity Syndrome (MAIS) is the least severe. MAIS usually presents with no genital abnormalities. This condition can be suspected in the context of pubertal gynecomastia or unexplained infertility [33]. Pathogenic variants in AR have been associated with AIS. These pathogenic variants can be located outside of the coding region [37, 38]. There have been some cases where no pathogenic variants in AR have been detected. This suggests other proteins located beyond AR that influence testosterone signaling [39].

#### 4. 46, XX disorders of sex development

46, XX DSD can occur due to:

1. Abnormal ovarian development.
2. Excess androgen levels due to abnormal synthesis or androgen exposure.

##### 4.1 Ovarian development

There are two types of abnormal development that can cause XX sex reversal:

1. Patients who have the presence of the *SRY* gene. This can be caused by a translocation of the *SRY* gene to another chromosome, usually the X chromosome. In some rare cases a translocation to an autosome occurs.
2. Patients who are XX males and *SRY* – negative

Loss of function mutations in genes coding for ovarian formation and function are associated with ovarian dysgenesis and/or accelerated loss of primordial follicles. This can cause premature ovarian failure (POF) and/or premature menopause.

The gene responsible for the differentiation of the bipotential gonad into ovaries is the *WNT4* gene (Figure 4). The *WNT4* gene is a member of the WNT family of secreted molecules. This family of genes function in a paracrine manner. The WNT proteins are ligands to members of the Frizzled (FZ) family of cell surface receptors. They are also possibly ligands to the single-pass transmembrane protein LDL-receptor-related proteins 5 and 6 (*LRP5* and *LRP6*) [40]. The binding of WNT to FZ leads to reduced degradation of  $\beta$ -catenin. This causes  $\beta$ -catenin-dependent activation of T-cell factor/lymphocyte enhancer factor transcription factors that lead to the induction of WNT – responsive genes [41]. *WNT4* is produced in ovarian pre-granulosa cells. *WNT4* up-regulates the gene *DAX1* [42], which antagonizes *NR5A1*, and inhibits steroidogenic enzymes. *WNT4* – knockout XX mice have been shown to have no Müllerian duct derivatives, have present Wolffian ducts and masculinized with the expression of the steroidogenic enzymes, namely  $3\beta$  hydroxy steroid dehydrogenase and  $17\alpha$  hydroxylase. They are critically important in the production of testosterone. Conversely, they are normally suppressed in the developing female ovary. Mice models showed ovaries with a decreased number of oocytes. This demonstrates the important role of *WNT4* in maintaining the female

germ cells and thus normal ovarian function [43]. This is contrasted by testicular function which continues in the absence of sperm.

In humans, duplication of chromosome 1p31-p35 causes a duplication of the *WNT4* gene. This duplication has been associated with male to female sex reversal exhibiting ambiguous genitalia, severe hypospadias, streak gonads and remnants of both Müllerian and Wolffian ducts [42]. Homozygotes with pathogenic variants in *WNT4* results in SERKAL (SEx Reversion, Kidneys, Adrenal and Lung dysgenesis) syndrome [44]. Pathogenic variants in this gene have also been found in women with absent Müllerian structures with clinical signs of androgen excess. Pathogenic variants have also presented with findings resembling Mayer-Rokitansky-Küster-Hauser syndrome [45].

Another important gene is the *FOXL2* gene which is responsible in the formation and function of the ovaries. Pathogenic variants in this gene result in BPES (blepharophimosis, ptosis, and epicanthus inversus) syndrome (OMIM # 110100). There are two types of the condition; in BPES I it is associated with premature ovarian failure (POF) and in BPES type II it is not associated with POF.

In mice models the continued expression of *FOXL2* is essential in maintaining ovarian function. Loss of gene expression leads to reprogramming of granulosa and theca cells into cells that are similar to Sertoli and Leydig cells, respectively [4, 46–49]. *FOXL2* also stimulates the expression of the gonadotropin releasing hormone (GnRH) receptor. This expression precedes glycoprotein hormone  $\alpha$ -subunit, this is a common subunit to FSH, LH, and TSH in the pituitary gland [50].

*RSPO1* [roof plate-specific spondin-1] is an important gene in ovarian development. Its role is to act as a regulator of female sex differentiation by activating the canonical WNT/ $\beta$ -catenin pathway. This pathway opposes testis formation, with *WNT4* playing a prominent role as a key ligand [51, 52]. During sex differentiation significantly higher expression of *RSPO1* was detected in the ovaries compared to testis [52], supporting the genes importance in female sex differentiation.

Other genes associated with ovarian dysgenesis and premature ovarian failure include: *LHX8*, *MCM8*, *MCM9*, *NOBOX*, and *FSHR* [46–48].

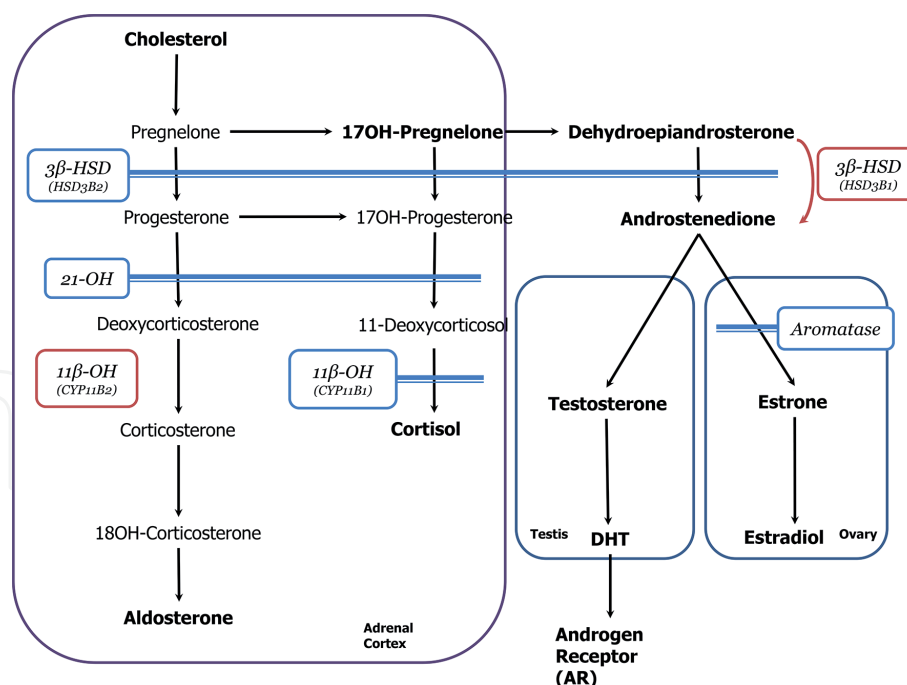
## 4.2 Exposure or overproduction of androgens

In 46,XX female, increased fetal androgen synthesis or prenatal exposure to androgen leads to masculinization of the female external genitalia (**Figure 6**) [26].

### 4.2.1 Exposure to androgens of non-fetal origin

Maternal androgen producing tumors can cause virilization of a female infant. These include adrenal tumors and ovarian tumors. There have been reports including a maternal luteoma of pregnancy which caused virilization of both mother and child [53]. There are also various drugs with androgenic activity. These include androgens, danazol, progestins and potassium sparing diuretics that are known to cause virilization [17, 53].

Placental Aromatase Deficiency is another cause of virilization in a female. This is a rare autosomal recessive condition caused by mutations in *CYP19A1* on chromosome 15q21.2 and less than 20 cases have been described in literature. Aromatase converts androstenedione to estrone in the female ovaries (**Figure 6**) providing protection for the fetus from high circulating levels of androgens. Sources of androgens include the fetal adrenal glands and androgens of maternal origin [54]. Cases present with maternal virilization in the 3rd trimester and abnormal genitalia in the affected females [54, 55]. Biochemically cases have intact cortisol and aldosterone production and are not at risk for salt wasting.



**Figure 6.** Steroid hormone synthesis pathway in 46, XX DSD. 3β-HSD: 3β-hydroxysteroid dehydrogenase; 21-OH: 21-hydroxylase; 11β-OH: 11β-hydroxylase (adapted from [17]).

#### 4.2.2 Steroid synthesis defects – overproduction of androgens

Steroid synthesis defects leading to congenital adrenal hyperplasia with androgen excess cause clitoral enlargement, partial or complete fusion of the labia majora and a short vagina [26] with virilization Prader stage above III [55].

The most common cause of 46, XX disorders of sexual differentiation (**Figure 6**) is 21-hydroxylase (21-OH) deficiency. This occurs in 90% of cases [55] and has a prevalence of 1:14,000–1:15,000 worldwide [54, 55]. This autosomal recessive condition is caused by mutations in the 21-OH gene (*CYP21A2*) on chromosome 6p21.1. The severity of the disease correlates generally to the degree of enzyme activity with classic 21(OH) deficiency having less than 5% activity. These patients present with congenital adrenal hyperplasia and in utero virilization of the external genitalia in females. Non-classic 21(OH) deficiency have >15% residual activity. These patients present with androgen excess in adolescence and early adulthood [54].

Patients with classic 21(OH) deficiency are at high risk (approximately 70%) for neonatal salt wasting [17]. These patients present with high 17α-hydroxyprogesterone, androstenedione and testosterone levels (**Figure 6**) and decreased sodium, elevated potassium and elevated renin at the end of the first week of life [17]. The high androgens levels result in virilization of the female external genitalia in female fetuses. This can be seen as early as 12 weeks gestation [54] and varies from mild clitoromegaly to complete male external genitalia with rugated and pigmented labioscrotal folds and a phallic structure [17].

Non-classic 21(OH) deficiency is more common than the classic form. The world wide incidence is 1:300, the Ashkenazi Jewish population has a higher incidence described as 1:27 [54]. They generally present in adolescence with a presentation is similar to Polycystic Ovarian Syndrome, namely premature pubarche, acne, hirsutism and irregular menses.

11β-OH is present in the adrenals and coded by the *CYP11B1* gene. Defects lead to congenital adrenal hyperplasia which present with a similar picture to classical CAH. This is the second most common cause of congenital adrenal hyperplasia

with an incidence of less than 1:100,000 births. The condition is inherited in an autosomal recessive manner and homozygote or compound heterozygote mutations in the *CYP11B1* gene (mapped to chromosome 8q21-q22) results in a loss of enzyme function [54]. The most common mutation in the *CYP11B1* gene is the R448H mutation, which is also the founder mutation identified in Moroccan Jews who has a high prevalence of the condition [54]. Patients with 11 $\beta$ -OH deficiency present with virilization of the external genitalia due androgen excess; biochemically this is seen as elevated 11-deoxycortisol and 17 $\alpha$ -hydroxypregnelone (**Figure 6**) [17]. These patients have normal aldosterone production and thus a decreased risk of salt wasting. Aldosterone synthesis is mediated by the *CYP11B2* gene, which is homologous to *CYP11B1* and located within 40 kb [54]. This results in normal levels of deoxycorticosterone and aldosterone and a wide range of blood pressure phenotypes have been reported [26, 54].

There are rare forms of defects in steroid synthesis causing CAH. These include 3 $\beta$ -hydroxysteroid dehydrogenase (3 $\beta$ -HSD) deficiency and 11 $\beta$ -hydroxylase (11 $\beta$ -OH) deficiency. There are two enzymes that mediate 3 $\beta$ -HSD. The type 1 enzyme (*HSD3B1*) is present in the skin, liver, peripheral tissues and placenta and the high levels of dehydroepiandrosterone are converted to androstenedione and then to testosterone and DHT [54]. The degree of virilization is moderate compared to 21-OH deficiency. Patients present with mild to moderate clitoromegaly and rarely fusion of the labioscrotal folds (**Figures 5 and 6**) [54, 55].

Type 2 (*HSD3B2*) deficiency is a rare condition occurring in 1:1,000,000 births. This condition presents with severe salt wasting similar to 21-OH deficiency and less severe virilization [54, 55]. This is an autosomal recessive condition caused by mutations in the *HSD3B2* gene, located on chromosome 1p13. As with other forms of CAH, the severity of the disease correlates with the degree of enzyme activity [54, 55]. Type 2 deficiency leads to impaired aldosterone and cortisol production presenting biochemically with elevated pregnenolone, 17(OH) pregnenolone and elevated dehydroepiandrosterone (**Figure 6**) [17, 55]. This leads to salt wasting, hyperkalemia and volume depletion similar to 21(OH) deficiency. Virilization occurs in a similar fashion to 11 $\beta$  (OH) deficiency.

## 5. Investigations

The initial investigation should include a careful physical examination to determine if the presentation is isolated or non-isolated (**Figure 1**). In view of the association between IUGR and undervirilization in chromosomal male fetuses, results of maternal serum screening, placental growth factor and detailed fetal ultrasound findings and biophysical profile as well as the birth weight should be obtained.

Examination of the external genitalia should include:

- a. Assessment of the labioscrotal folds—the labioscrotal folds should be assessed for pigmentation, rugation, asymmetry and fusion. High insertion of the labioscrotal folds (above the penis) as well as “buried penis” should be differentiated from micropenis.
- b. Assessment of the phallic structure, the length, breadth, urogenital openings—the phallic structure should be assessed for length, breadth, chordee and relationship with the labioscrotal folds looking for complete or incomplete penoscrotal transposition. The normal penile length at term is 3.5 cm with 2.5 cm being at  $-2SD$ . The normal clitoral length at term is 2–8.5 mm and breadth 2–6 mm [56].

- c. Location, structure and volume of the gonads—gonads located in the inguinal canal and labioscrotal folds are always testes although ovotestes is also a possibility.

The perineum should also be examined for the number and position of the openings and then compared to the Prader scale [57].

Investigations should be targeted to identify:

1. The chromosome sex
2. The gonadal sex
3. The internal genitalia [using ultrasound and/or MRI to find if], is there is a uterus, is the uterus normal and are there intrabdominal gonads
4. The external genitalia

Since gonads in the inguinal canal and labioscrotal folds are almost always testis finding them on palpation usually indicates the existence of the SRY gene. However, the chromosome sex should be determined using quantitative fluorescent PCR (QF-PCR) or fluorescent in-situ hybridization (FISH) analysis. Microarray analysis should be completed, looking for submicroscopic deletion or duplication involving the *SRY* gene as well as other chromosome abnormalities [58].

Unique situations to be aware of include the most severe cases (46,XY with complete feminization and 46,XX with complete masculinization) it is difficult to diagnose an abnormal phenotype. Other scenarios include isolated grade 1 (glandular) and 2 (penile shaft) hypospadias, especially when associated with intrauterine growth restriction (IUGR) the investigative yield is low. Most cases are the result of the IUGR – Placental dysfunction – abnormal genitalia syndrome [59]; however, since this is a diagnosis by exclusion and there is no objective way of differentiating the condition from PAIS and mild 5 $\alpha$  reductase deficiency, DNA analysis using 46,XY panel or for these conditions is recommended. Further investigations are also indicated with hypospadias associated with bilateral or unilateral undescended testes, micropenis, clitoromegaly, posterior fusion of the labia majora.

The most common cause of abnormal genitalia in female is CAH. When initial investigations show XX karyotype, 17-hydroxyprogesterone (17-OH) and renin at 48 hours of age (after the surge of adrenal hormones at birth) should be done. The abnormal sodium and potassium blood levels will present only in the second week of life.

In cases with XY karyotype, the testosterone, LH and FSH levels should be measured looking for low testosterone and dihydrotestosterone (DHT) levels. Answering the above four questions will guide further investigations which include assessment of adrenal function, testicular function and internal genitalia using ultrasound, MRI and/or genitogram or laparoscopy [17].

Genetic testing plays an important role in finding the etiology and thus providing genetic counselling regarding the recurrence risks and the prenatal/preimplantation options in future pregnancies. The use of DSD genetic panels can investigate multiple genes simultaneously and accelerate the diagnostic process. Using massive parallel sequencing looking at a variety of genes causing DSD in a cohort of 278 patients with 46, XY DSD and 48 with 46, XX DSD of an unknown etiology, Eggers et al., found a likely genetic diagnosis in 43% of patients with 46, XY DSD and 17% of patients with 46, XX DSD [60]. If no gene mutation is identified, whole exome/genome sequencing is recommended.

## **6. Gender assignment**

When a newborn presents with ambiguous genitalia, a thorough physical examination, as well as various genetic (e.g. karyotype, microarray) and non-genetic investigations are ordered. From this, the health care team is able to have discussions with parents regarding the gender for sex of rearing. With regards to genital surgery, the current suggestion is that if genital surgery is not medically indicated, then to wait until the patient him/herself is able to make this decision. In cases with substantial ambiguity such as in PAIS, mixed gonadal dysgenesis, ovotesticular DSD and females with CAH and severe masculinization, a multidisciplinary DSD team including pediatric endocrinologists, geneticists, genetic counsellors, urologists, gynecologists, social workers and psychologists/psychiatrists with expertise in this field should be part of the care team. The findings, plan for investigations, gender assignment and treatment should be discussed among the group members prior to meeting the parents. Factors which have to be taken into consideration include type of gonads and potential function of these, present or future treatment with hormones, including for inducing puberty or for fertility if this can be predicted, as well as any medically necessary surgical treatment. When meeting with the parents, the team should present this information at a level that the parents can understand, using visual aids to facilitate the discussion. At the same time, if information is known from the literature about certain conditions that parents should be aware of, e.g. female babies with CAH and exposure to high and early levels of androgen levels prenatally can show more behaviors attributable to the male personality and sexual orientation [61–64], and the challenges in repairing severe hypospadias in patients diagnosed with PAIS [65], then this should be shared with them. In this way, the parents, together with the healthcare team's input can come to an informed decision about sex of rearing.

## **7. Gonadal cancer risk**

Dysgenetic gonads with a Y chromosome material are associated with an increased risk for malignancy, mainly gonadoblastoma, dysgerminoma and germ cell tumors, including seminoma, non-seminoma, juvenile granulosa cell and germ cell neoplasia in situ [66, 67]. Gonadoblastoma (GB) presents with a mixture of germ cells and stromal elements as well as immature Sertoli cells and may contain calcifications with pure gonadoblastomas being not metastatic. About 80% of patients with GB are phenotypic females and 20% are phenotypic males, many of them with hypospadias and bilateral or unilateral cryptorchidism. The incidence of GB in dysgenetic gonads varies from 4.7% to as high as 25%. Germ cell neoplasia in-situ cells are found lining the seminiferous tubules in dysgenetic testes and resemble immature germ cells. Thus, they cannot be diagnosed before puberty when they are normally present. However, when found in the testes in late childhood or post puberty they are pathological and are capable of transforming into seminomas in males and dysgerminoma in females and this tumor can metastasize. Removal of the gonad prior to puberty in patients with complete androgen insensitivity is controversial in view of the data indicating low risk for malignancy until early adult years [68, 69]. In these patients, if the testes are located in the labia majora, they are amenable to ultrasound surveillance and biopsies, if needed which makes post-pubertal monitoring simpler. When the testes are undescended, laparoscopic gonadopexy to bring them near the anterior abdominal wall to allow surveillance may be an option for patients who decide to avoid gonadectomy [68, 69]. Delayed surgery can help in involving the patient in the decision making [67, 70, 71].

Persistent Mullerian Duct Syndrome is associated with the usual cancer risk associated with cryptorchidism as well as an unknown incidence of a possible tumor risk of the Mullerian duct structures.

## **8. Genetic counseling and DSD**

In 2006, a new definition of genetic counseling was published in the *Journal of Genetic Counseling*, by a task force that was convened by the National Society of Genetic Counselors (NSGC). The definition is as follows: “Genetic counseling is the process of helping people understand and adapt to the medical, psychological and familial implications of genetic contributions to disease. This process integrates the following:

- a. Interpretation of family and medical histories to assess the chance of disease occurrence or recurrence.
- b. Education about inheritance, testing, management, prevention, resources and research.
- c. Counselling to promote informed choices and adaptation to the risk or condition” [72].

Genetic counselling has an important role in the management of DSD patients and their families. In most cases, counselling involves the woman/couple, following the birth of a child with DSD and/or in discussing the implications of their future reproductive plans. Genetic counselling can also be extended to other family members and the implications to themselves and their future pregnancies. Discussions with other family members require consent from the parents of the index patient or the index patient himself/herself if of age of maturity. Other indications for genetic counselling include an adolescent or young adult with DSD who wishes to learn more about their own diagnosis and the implications for her/his reproductive plans as well a woman/couple during their pregnancy when discordance between the genotypic and phenotypic sex is identified.

Following the birth of a child with DSD, parents are often overwhelmed and confused by their child’s condition. Although gender assignment and naming of the child are pressing issues for the parents, these actions should not be unduly rushed. Parents should be provided with information so as to help them in making informed decisions, together with their healthcare team. Adequate counseling and support for parents includes education regarding sexual development in utero (including brain imprinting of gender identity), genetic counseling, ethical considerations of the child’s rights to make decisions regarding gender, and information regarding current guidelines and recommendations.

A three generation family history should be obtained with careful inquiry. Information about family history of infertility, women with no menstrual periods, stillbirth, recurrent miscarriages, neonatal death, congenital abnormalities, intellectual disabilities and consanguinity should be obtained. When drawing the family history, it should be kept in mind that chromosome sex and phenotypic sex may be interpreted differently by the family; for the family, it is the phenotypic sex that identifies the family members as male or female (versus chromosome sex). Furthermore, in X-linked conditions the phenotypic infertile female may be chromosomally male (such as in androgen insensitivity or ATRX).



When a diagnosis is established from genetic investigations, then the family can be provided with information regarding the clinical manifestations and natural history, mode of inheritance, medical management recommendations, if any, recurrence risk for future pregnancies, implications to their other children/other family members, as well as information regarding appropriate patient support groups. Cultural differences need to be respected and taken into consideration during the counselling process [73].

In some cases, a DSD is diagnosed incidentally during pregnancy, with no previous family history. This could be following the finding of fetal abnormal external genitalia or finding of discrepancy between the phenotypic sex as determined by fetal ultrasound and the genotypic sex as determined by chorionic villus sampling, amniocentesis or non-invasive prenatal testing (NIPT) done for other reasons. The differential diagnosis for the cases detected incidentally is broad but it should be kept in mind that in a 46,XX fetus, the most likely diagnosis is congenital adrenal hyperplasia. In a 46,XY fetus, the differential diagnosis includes a variety of conditions including androgen insensitivity syndrome, 46,XY gonadal dysgenesis and testosterone biosynthesis defects, when no other abnormalities are identified. When other abnormalities are detected, such as on ultrasound, more rare conditions such as campomelic dysplasia and Smith-Lemli-Opitz syndrome should be considered [74]. Following prenatal diagnosis of a DSD the family may choose to continue with the pregnancy with no further investigations, they may decide to terminate the pregnancy based on the information provided or they may decide to further investigate the etiology of the abnormalities identified. Prior to this however, the genetics health care team should facilitate a discussion with the family outlining each option with the pros/cons of each, including what to expect from a procedure, if applicable, as well as the impact on puberty and fertility and the potential psychosocial perspective. This information is important to allow an informed decision to be made in keeping with their value and belief system. The family should be made aware that the genetics health care team will support whatever decision they make. In situations where the family decides to terminate the pregnancy and the etiology of the condition is not known, the benefits of a fetal autopsy and molecular analysis should be reviewed with the family.

Genetic counselling should be made available to couples who are planning to have more children, following the birth of a child with DSD. The provision of genetic counselling in these cases, in addition to providing psychosocial support, includes information regarding their recurrence risk and their available reproductive options:

1. Accepting the risk of having another affected child and have no prenatal/preimplantation genetic diagnosis.
2. Deciding not to have any more biological children and choosing instead to use donor gametes, donor embryos or adoption.
3. Conceive naturally and have pre-natal diagnosis with the option of either continuing or terminating an affected pregnancy.
4. Pre-implantation genetic diagnosis (PGD).

Patients with DSD may be infertile. For these patients, conception using donor gametes and/or surrogate mother may be possible and should be discussed. However, to lower the recurrence risk, when applicable, the donor should not be a genetic relative/carrier of the condition.

## 9. Conclusion

Normal sex development includes determination of chromosome sex, gonadal sex, development of internal and external genitalia as well as the psychosocial sex. This is a complex process involving genetic and non-genetics components, many of them are yet unknown. Disorder of sex development is an etiologically a heterogeneous group of disorders with a major lifelong impact on the patients and their families.

In view of the complexity of these group of patients they should be seen by a DSD team including but not limited to pediatric endocrinologist, pediatric urologist, medical geneticist, genetic counsellor, psychologist/psychiatrist and social worker and the findings and current knowledge should be presented to the parents so that they can make an informed decision regarding the gender, when appropriate. The child with DSD should continue be followed into puberty and adulthood to achieve optimal treatment, psychosocial well-being, sexual satisfaction, and fertility in view of the patients gender role and identity [75].

## 10. Resources

### 10.1 Web based resources

Web-based educational resources for families include:  
[www.aboutkidshealth.ca/En/HowTheBodyWorks/SexDevelopmentAnOverview](http://www.aboutkidshealth.ca/En/HowTheBodyWorks/SexDevelopmentAnOverview)

This website provides detailed graphically illustrated explanations of sex development and DSDs that health professionals can use when working with families.

### 10.2 Support groups

Androgen Insensitivity Syndrome: Differences of Sex Development Support Group.

<http://aisdsd.org/>

CARES foundation: Congenital Adrenal Hyperplasia Research, Education and Support.

<http://www.caresfoundation.org>

Hypospadias and Epispadias Association.

<http://heainfo.org>

IntechOpen

## **Author details**

Pierre Sinajon<sup>2,3</sup>, Riyana Babul-Hirji<sup>4</sup> and David Chitayat<sup>1,2,4\*</sup>

1 Department of Obstetrics and Gynecology, Mount Sinai Hospital, University of Toronto, Toronto, ON, Canada

2 The Prenatal Diagnosis and Medical Genetics Program, Department of Obstetrics and Gynecology, Mount Sinai Hospital, University of Toronto, Toronto, ON, Canada

3 Department of Pediatrics, Division of Genetics, University of Rochester Medical Center, United States

4 Division of Clinical Genetics and Metabolism, Departments of Pediatrics and Genetic Counselling, The Hospital for Sick Children, University of Toronto, Toronto, ON, Canada

\*Address all correspondence to: david.chitayat@sinaihealth.ca

## **IntechOpen**

© 2021 The Author(s). Licensee IntechOpen. This chapter is distributed under the terms of the Creative Commons Attribution License (<http://creativecommons.org/licenses/by/3.0>), which permits unrestricted use, distribution, and reproduction in any medium, provided the original work is properly cited. 

## References

- [1] Hughes IA, Nihoul-Fékété C, Thomas B, Cohen-Kettenis PT. Consequences of the ESPE/LWPES guidelines for diagnosis and treatment of disorders of sex development. Best Practice & Research. Clinical Endocrinology & Metabolism. 2007;**21**(3):351-365
- [2] Hughes IA, Houk C, Ahmed SF, Lee PA. Consensus statement on management of intersex disorders. Journal of Pediatric Urology. 2006;**2**(3):148-162
- [3] Rey R, Josso N, Racine C. Sexual Differentiation. In: Feingold KR, Anawalt B, Boyce A, Chrousos G, Dungan K, Grossman A, et al., editors. Endotext. South Dartmouth (MA): MDText.com, Inc. Copyright © 2000-2020, MDText.com, Inc.; 2000.
- [4] Ahmed SF, Bashamboo A, Lucas-Herald A, McElreavey K. Understanding the genetic aetiology in patients with XY DSD. British Medical Bulletin. 2013;**106**:67-89
- [5] Yao HH. The pathway to femaleness: current knowledge on embryonic development of the ovary. Molecular and Cellular Endocrinology. 2005;**230**(1-2):87-93
- [6] Zhao F, Franco HL, Rodriguez KF, Brown PR, Tsai MJ, Tsai SY, et al. Elimination of the male reproductive tract in the female embryo is promoted by COUP-TFII in mice. Science. 2017;**357**(6352):717-720
- [7] Childs AJ, Cowan G, Kinnell HL, Anderson RA, Saunders PT. Retinoic Acid signalling and the control of meiotic entry in the human fetal gonad. PLoS One. 2011;**6**(6):e20249
- [8] Nielsen J, Wohler M. Chromosome abnormalities found among 34,910 newborn children: results from a 13-year incidence study in Arhus, Denmark. Hum Genet. 1991;**87**(1):81-83
- [9] Cameron-Pimblett A, La Rosa C, King TFJ, Davies MC, Conway GS. The Turner syndrome life course project: Karyotype-phenotype analyses across the lifespan. Clinical Endocrinology. 2017;**87**(5):532-538
- [10] Gravholt CH, Andersen NH, Conway GS, Dekkers OM, Geffner ME, Klein KO, et al. Clinical practice guidelines for the care of girls and women with Turner syndrome: proceedings from the 2016 Cincinnati International Turner Syndrome Meeting. European Journal of Endocrinology. 2017;**177**(3):G1-g70
- [11] Schoemaker MJ, Swerdlow AJ, Higgins CD, Wright AF, Jacobs PA. Cancer incidence in women with Turner syndrome in Great Britain: a national cohort study. The Lancet Oncology. 2008;**9**(3):239-246
- [12] Flannigan R, Patel P, Paduch DA. Klinefelter Syndrome. The Effects of Early Androgen Therapy on Competence and Behavioral Phenotype. Sex Med Rev. 2018;**6**(4):595-606
- [13] Telvi L, Lebbar A, Del Pino O, Barbet JP, Chaussain JL. 45,X/46,XY mosaicism: report of 27 cases. Pediatrics. 1999;**104**(2 Pt 1):304-308
- [14] Tho SP, Jackson R, Kulharya AS, Reindollar RH, Layman LC, McDonough PG. Long-term follow-up and analysis of monozygotic twins concordant for 45,X/46,XY peripheral blood karyotype but discordant for phenotypic sex. Am J Med Genet A. 2007;**143a**(21):2616-22.
- [15] Tosson H, Rose SR, Gartner LA. Description of children with 45,X/46,XY karyotype. Eur J Pediatr. 2012;**171**(3):521-9.

- [16] Lindhardt Johansen M, Hagen CP, Rajpert-De Meyts E, Kjærgaard S, Petersen BL, Skakkebaek NE, et al. 45,X/46,XY mosaicism: phenotypic characteristics, growth, and reproductive function--a retrospective longitudinal study. *The Journal of Clinical Endocrinology and Metabolism* 2012;**97**(8):E1540–E1549.
- [17] Wherrett DK. Approach to the Infant with a Suspected Disorder of Sex Development. *Pediatric Clinics of North America*. 2015;**62**(4):983-999
- [18] Berta P, Hawkins JR, Sinclair AH, Taylor A, Griffiths BL, Goodfellow PN, et al. Genetic evidence equating SRY and the testis-determining factor. *Nature*. 1990;**348**(6300):448-450
- [19] Sekido R, Lovell-Badge R. Sex determination involves synergistic action of SRY and SF1 on a specific Sox9 enhancer. *Nature*. 2008;**453**(7197):930-934
- [20] Benko S, Gordon CT, Mallet D, Sreenivasan R, Thauvin-Robinet C, Brendehaug A, et al. Disruption of a long distance regulatory region upstream of SOX9 in isolated disorders of sex development. *Journal of Medical Genetics*. 2011;**48**(12):825-830
- [21] Vetro A, Ciccone R, Giorda R, Patricelli MG, Della Mina E, Forlino A, et al. XX males SRY negative: a confirmed cause of infertility. *Journal of Medical Genetics*. 2011;**48**(10):710-712
- [22] Bagheri-Fam S, Bird AD, Zhao L, Ryan JM, Yong M, Wilhelm D, et al. Testis Determination Requires a Specific FGFR2 Isoform to Repress FOXL2. *Endocrinology*. 2017;**158**(11):3832-3843
- [23] Song Y, Fan L, Gong C. Phenotype and Molecular Characterizations of 30 Children From China With NR5A1 Mutations. *Frontiers in Pharmacology*. 2018;**9**:1224
- [24] Tantawy S, Mazen I, Soliman H, Anwar G, Atef A, El-Gammal M, et al. Analysis of the gene coding for steroidogenic factor 1 (SF1, NR5A1) in a cohort of 50 Egyptian patients with 46,XY disorders of sex development. *European Journal of Endocrinology*. 2014;**170**(5):759-767
- [25] Yagi H, Takagi M, Kon M, Igarashi M, Fukami M, Hasegawa Y. Fertility preservation in a family with a novel NR5A1 mutation. *Endocrine Journal*. 2015;**62**(3):289-295
- [26] Barbaro M, Wedell A, Nordenström A. Disorders of sex development. *Seminars in Fetal & Neonatal Medicine*. 2011;**16**(2):119-127
- [27] Firth HV, Hurst JA. *Oxford Desk Reference* 2017.
- [28] Biason-Lauber A, Konrad D, Meyer M, DeBeaufort C, Schoenle EJ. Ovaries and female phenotype in a girl with 46,XY karyotype and mutations in the CBX2 gene. *American Journal of Human Genetics* 2009;**84**(5):658-663.
- [29] Loke J, Pearlman A, Radi O, Zuffardi O, Giussani U, Pallotta R, et al. Mutations in MAP3K1 tilt the balance from SOX9/FGF9 to WNT/beta-catenin signaling. *Human molecular genetics*. 2014;**23**(4):1073-1083
- [30] Sugie K, Futamura N, Suzumura A, Tate G, Umehara F. Hereditary motor and sensory neuropathy with minifascicle formation in a patient with 46XY pure gonadal dysgenesis: a new clinical entity. *Annals of Neurology*. 2002;**51**(3):385-388
- [31] Yatsenko SA, Witchel SF. Genetic approach to ambiguous genitalia and disorders of sex development: What clinicians need to know. *Seminars in Perinatology*. 2017;**41**(4):232-243
- [32] Hershkovitz E, Parvari R, Wudy SA, Hartmann MF, Gomes LG,

- Loewental N, et al. Homozygous mutation G539R in the gene for P450 oxidoreductase in a family previously diagnosed as having 17,20-lyase deficiency. *The Journal of Clinical Endocrinology and Metabolism*. 2008;**93**(9):3584-3588
- [33] Yang Z, Ye L, Wang W, Zhao Y, Wang W, Jia H, et al. 17beta-Hydroxysteroid dehydrogenase 3 deficiency: Three case reports and a systematic review. *The Journal of Steroid Biochemistry and Molecular Biology*. 2017;**174**:141-145
- [34] Massanyi EZ, Dicarolo HN, Migeon CJ, Gearhart JP. Review and management of 46,XY disorders of sex development. *Journal of Pediatric Urology*. 2013;**9**(3):368-379
- [35] Mongan NP, Tadokoro-Cuccaro R, Bunch T, Hughes IA. Androgen insensitivity syndrome. *Best Practice & Research. Clinical Endocrinology & Metabolism*. 2015;**29**(4):569-580
- [36] Boehmer AL, Brinkmann O, Brüggewirth H, van Assendelft C, Otten BJ, Verleun-Mooijman MC, et al. Genotype versus phenotype in families with androgen insensitivity syndrome. *The Journal of Clinical Endocrinology and Metabolism*. 2001;**86**(9):4151-4160
- [37] Hornig NC, de Beaufort C, Denzer F, Cools M, Wabitsch M, Ukat M, et al. A Recurrent Germline Mutation in the 5'UTR of the Androgen Receptor Causes Complete Androgen Insensitivity by Activating Aberrant uORF Translation. *PLoS One*. 2016;**11**(4):e0154158
- [38] Käsäkoski J, Jääskeläinen J, Jääskeläinen T, Tommiska J, Saarinen L, Lehtonen R, et al. Complete androgen insensitivity syndrome caused by a deep intronic pseudoexon-activating mutation in the androgen receptor gene. *Scientific Reports*. 2016;**6**:32819
- [39] Hornig NC, Ukat M, Schweikert HU, Hiort O, Werner R, Drop SL, et al. Identification of an AR Mutation-Negative Class of Androgen Insensitivity by Determining Endogenous AR Activity. *The Journal of Clinical Endocrinology and Metabolism*. 2016;**101**(11):4468-4477
- [40] He X, Semenov M, Tamai K, Zeng X. LDL receptor-related proteins 5 and 6 in Wnt/beta-catenin signaling: arrows point the way. *Development*. 2004;**131**(8):1663-1677
- [41] Nusse R. Wnts and Hedgehogs: lipid-modified proteins and similarities in signaling mechanisms at the cell surface. *Development*. 2003;**130**(22):5297-5305
- [42] Jordan BK, Mohammed M, Ching ST, Délot E, Chen XN, Dewing P, et al. Up-regulation of WNT-4 signaling and dosage-sensitive sex reversal in humans. *American Journal of Human Genetics*. 2001;**68**(5):1102-1109
- [43] McLaren A. Meiosis and differentiation of mouse germ cells. *Symposia of the Society for Experimental Biology*. 1984;**38**:7-23
- [44] Mandel H, Shemer R, Borochowitz ZU, Okopnik M, Knopf C, Indelman M, et al. SERKAL syndrome: an autosomal-recessive disorder caused by a loss-of-function mutation in WNT4. *American Journal of Human Genetics*. 2008;**82**(1):39-47
- [45] Biason-Lauber A, Konrad D. WNT4 and sex development. *Sexual Development*. 2008;**2**(4-5):210-218
- [46] Desai S, Wood-Trageser M, Matic J, Chipkin J, Jiang H, Bachelot A, et al. MCM8 and MCM9 Nucleotide Variants in Women With Primary Ovarian Insufficiency. *The Journal of Clinical Endocrinology and Metabolism*. 2017;**102**(2):576-582

- [47] Katari S, Wood-Trageser MA, Jiang H, Kalynchuk E, Muzumdar R, Yatsenko SA, et al. Novel Inactivating Mutation of the FSH Receptor in Two Siblings of Indian Origin With Premature Ovarian Failure. *The Journal of Clinical Endocrinology and Metabolism*. 2015;**100**(6):2154-2157
- [48] Ren Y, Suzuki H, Jagarlamudi K, Golnoski K, McGuire M, Lopes R, et al. Lhx8 regulates primordial follicle activation and postnatal folliculogenesis. *BMC Biology*. 2015;**13**:39
- [49] Uhlenhaut NH, Jakob S, Anlag K, Eisenberger T, Sekido R, Kress J, et al. Somatic sex reprogramming of adult ovaries to testes by FOXL2 ablation. *Cell*. 2009;**139**(6):1130-1142
- [50] Ellsworth BS, Egashira N, Haller JL, Butts DL, Cocquet J, Clay CM, et al. FOXL2 in the pituitary: molecular, genetic, and developmental analysis. *Molecular Endocrinology*. 2006;**20**(11):2796-2805
- [51] Pannetier M, Chassot AA, Chaboissier MC, Pailhoux E. Involvement of FOXL2 and RSPO1 in Ovarian Determination, Development, and Maintenance in Mammals. *Sexual Development*. 2016;**10**(4):167-184
- [52] Tomaselli S, Megiorni F, Lin L, Mazzilli MC, Gerrelli D, Majore S, et al. Human RSPO1/R-spondin1 is expressed during early ovary development and augments beta-catenin signaling. *PLoS One*. 2011;**6**(1):e16366
- [53] Spitzer RF, Wherrett D, Chitayat D, Colgan T, Dodge JE, Salle JL, et al. Maternal luteoma of pregnancy presenting with virilization of the female infant. *Journal of Obstetrics and Gynaecology Canada*. 2007;**29**(10):835-840
- [54] Auchus RJ, Chang AY. 46,XX DSD: the masculinised female. *Best Practice & Research. Clinical Endocrinology & Metabolism*. 2010;**24**(2):219-242
- [55] Paris F, Gaspari L, Philibert P, Maïmoun L, Kalfa N, Sultan C. Disorders of sex development: neonatal diagnosis and management. *Endocrine Development*. 2012;**22**:56-71
- [56] Oberfield SE, Mondok A, Shahrivar F, Klein JF, Levine LS. Clitoral size in full-term infants. *American Journal of Perinatology*. 1989;**6**(4):453-454
- [57] Allen L. Disorders of sexual development. *Obstetrics and Gynecology Clinics of North America*. 2009;**36**(1):25-45
- [58] Tannour-Louet M, Han S, Corbett ST, Louet JF, Yatsenko S, Meyers L, et al. Identification of de novo copy number variants associated with human disorders of sexual development. *PLoS One*. 2010;**5**(10):e15392
- [59] Yinon Y, Kingdom JC, Proctor LK, Kelly EN, Salle JL, Wherrett D, et al. Hypospadias in males with intrauterine growth restriction due to placental insufficiency: the placental role in the embryogenesis of male external genitalia. *Am J Med Genet A*. 2010;**152a**(1):75-83.
- [60] Eggers S, Sadedin S, van den Bergen JA, Robevska G, Ohnesorg T, Hewitt J, et al. Disorders of sex development: insights from targeted gene sequencing of a large international patient cohort. *Genome Biology*. 2016;**17**(1):243
- [61] Mathews GA, Fane BA, Conway GS, Brook CG, Hines M. Personality and congenital adrenal hyperplasia: possible effects of prenatal androgen exposure. *Hormones and Behavior*. 2009;**55**(2):285-291
- [62] Nordenström A, Servin A, Bohlin G, Larsson A, Wedell A.

Sex-typed toy play behavior correlates with the degree of prenatal androgen exposure assessed by CYP21 genotype in girls with congenital adrenal hyperplasia. *The Journal of Clinical Endocrinology and Metabolism*. 2002;**87**(11):5119-5124

[63] Frisé L, Nordenström A, Falhammar H, Filipsson H, Holmdahl G, Janson PO, et al. Gender role behavior, sexuality, and psychosocial adaptation in women with congenital adrenal hyperplasia due to CYP21A2 deficiency. *The Journal of Clinical Endocrinology and Metabolism*. 2009;**94**(9):3432-3439

[64] Meyer-Bahlburg HF, Dolezal C, Baker SW, New MI. Sexual orientation in women with classical or non-classical congenital adrenal hyperplasia as a function of degree of prenatal androgen excess. *Archives of Sexual Behavior*. 2008;**37**(1):85-99

[65] Lucas-Herald A, Bertelloni S, Juul A, Bryce J, Jiang J, Rodie M, et al. The Long-Term Outcome of Boys With Partial Androgen Insensitivity Syndrome and a Mutation in the Androgen Receptor Gene. *The Journal of Clinical Endocrinology and Metabolism*. 2016;**101**(11):3959-3967

[66] Cools M, Looijenga L. Update on the Pathophysiology and Risk Factors for the Development of Malignant Testicular Germ Cell Tumors in Complete Androgen Insensitivity Syndrome. *Sexual Development*. 2017;**11**(4):175-181

[67] Wünsch L, Holterhus PM, Wessel L, Hiort O. Patients with disorders of sex development (DSD) at risk of gonadal tumour development: management based on laparoscopic biopsy and molecular diagnosis. *BJU Int*. 2012;**110**(11 Pt C):E958-65.

[68] Chaudhry S, Tadokoro-Cuccaro R, Hannema SE, Acerini CL, Hughes IA.

Frequency of gonadal tumours in complete androgen insensitivity syndrome (CAIS): A retrospective case-series analysis. *J Pediatr Urol*. 2017;**13**(5):498.e1-e6.

[69] Döhnert U, Wünsch L, Hiort O. Gonadectomy in Complete Androgen Insensitivity Syndrome: Why and When? *Sexual Development*. 2017;**11**(4):171-174

[70] Mouriquand PD, Gorduzza DB, Gay CL, Meyer-Bahlburg HF, Baker L, Baskin LS, et al. Surgery in disorders of sex development (DSD) with a gender issue: If (why), when, and how? *Journal of Pediatric Urology*. 2016;**12**(3):139-149

[71] Patel V, Casey RK, Gomez-Lobo V. Timing of Gonadectomy in Patients with Complete Androgen Insensitivity Syndrome-Current Recommendations and Future Directions. *Journal of Pediatric and Adolescent Gynecology*. 2016;**29**(4):320-325

[72] Resta R, Biesecker BB, Bennett RL, Blum S, Hahn SE, Strecker MN, et al. A new definition of Genetic Counseling: National Society of Genetic Counselors' Task Force report. *Journal of Genetic Counseling*. 2006;**15**(2):77-83

[73] Chitayat D, Babul-Hirji R. Genetic counselling in prenatally diagnosed non-chromosomal fetal abnormalities. *Current Opinion in Obstetrics & Gynecology*. 2000;**12**(2):77-80

[74] Chitayat D, Glanc P. Diagnostic approach in prenatally detected genital abnormalities. *Ultrasound in Obstetrics & Gynecology*. 2010;**35**(6):637-646

[75] Raveenthiran V. Neonatal Sex Assignment in Disorders of Sex Development: A Philosophical Introspection. *J Neonatal Surg*. 2017;**6**(3):58