

# We are IntechOpen, the world's leading publisher of Open Access books Built by scientists, for scientists

5,500

Open access books available

136,000

International authors and editors

170M

Downloads

Our authors are among the

154

Countries delivered to

TOP 1%

most cited scientists

12.2%

Contributors from top 500 universities



WEB OF SCIENCE™

Selection of our books indexed in the Book Citation Index  
in Web of Science™ Core Collection (BKCI)

Interested in publishing with us?  
Contact [book.department@intechopen.com](mailto:book.department@intechopen.com)

Numbers displayed above are based on latest data collected.  
For more information visit [www.intechopen.com](http://www.intechopen.com)



# Diagnosis and Management of Mandibular Condyle Fractures

*Kasi Ganesh Sriraam and K. Rajendran Arun Vignesh*

## Abstract

In the maxillofacial region, mandibular condyle fracture accounts for about 10–40% of the trauma spectrum. This chapter deals with the etiology, classification, clinical features, diagnosis, and contemporary management of mandibular condyle fractures. Along with the regular management strategies, treatment protocols for geriatric and pediatric patients have also been discussed. The indications and contraindications of closed as well as open reduction and fixation of condyle fractures are analyzed in detail.

**Keywords:** mandible, condyle, trauma, clinical features, diagnosis, management, ORIF, closed reduction, edentulous, pediatric, complications

## 1. Introduction

Mandible is the second most commonly fractured after nasal bone, though it is the largest and strongest bone. Mandibular condyle fractures accounts for about 10–40% when compared to other anatomical sites of mandible [1]. The proportion of condylar fractures is higher in children than adults, and has been reported to account for 40–67% of mandibular fractures [2]. According to Widmark and Santler, condylar fracture is the most common fracture in the maxillofacial region [1]. Direct or indirect trauma can lead to fracture of the condyle; the degree of displacement depends on the direction and magnitude of the force. Falls, road traffic accident, sports injuries, work-related injuries and assault are frequently related to condylar fracture [3].

## 2. Anatomy

Condyle develops from Meckel's cartilage and it is intramembranous in ossification. The secretion of bone matrix directly within the connective tissue without any intermediate cartilage leads to bone formation. The condensation of mesenchyme just lateral to the Meckel's cartilage forms the primitive condyle.

Condyle is a knuckle like structure. It is a strong upward projection from the postero-superior part of the ramus. The condyle has a backward angulation of 15–33° to the frontal plane and is elliptical in shape. The condyle has an angulation of 145–160° at the region where it meets at the anterior ligament of foramen magnum on basion. The medio-lateral width is 15–20 mm and the antero-posterior width is 8–10 mm. The condyle has a roughened, bluntly pointed lateral pole and a rounded medial pole which extends from the plane of ramus. Superficial temporal artery, posterior tympanic artery, posterior deep temporal artery and transverse facial artery provides the arterial

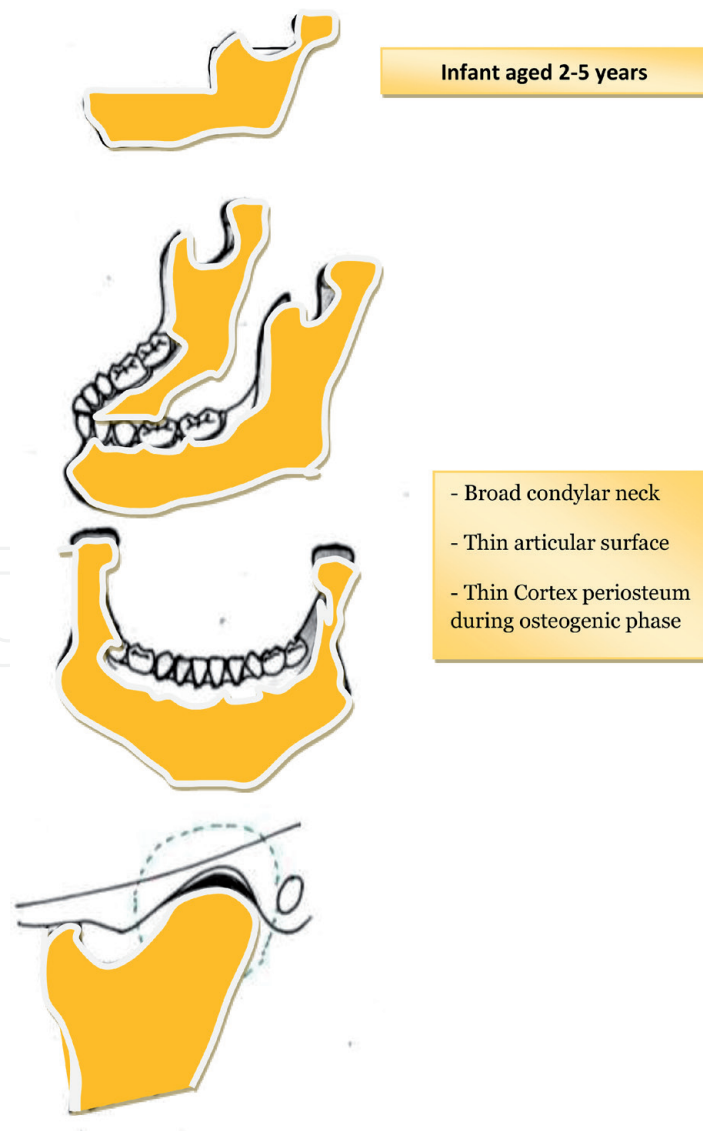
supply to the condyle. Venous drainage is by the corresponding tributaries. Nerve supply is from facial and auriculotemporal nerves. Lateral pterygoid muscle is attached at the pterygoid fovea which is helpful in protrusive and lateral excursive movements [4].

The bifurcation of facial nerve lies 1.5–2 cm away from the bony external auditory canal. The Temporal branch of the facial nerve lies 8–35 mm from the bony external auditory canal. The marginal mandibular branch of the facial nerve lies 1.2 cm away from the inferior border.

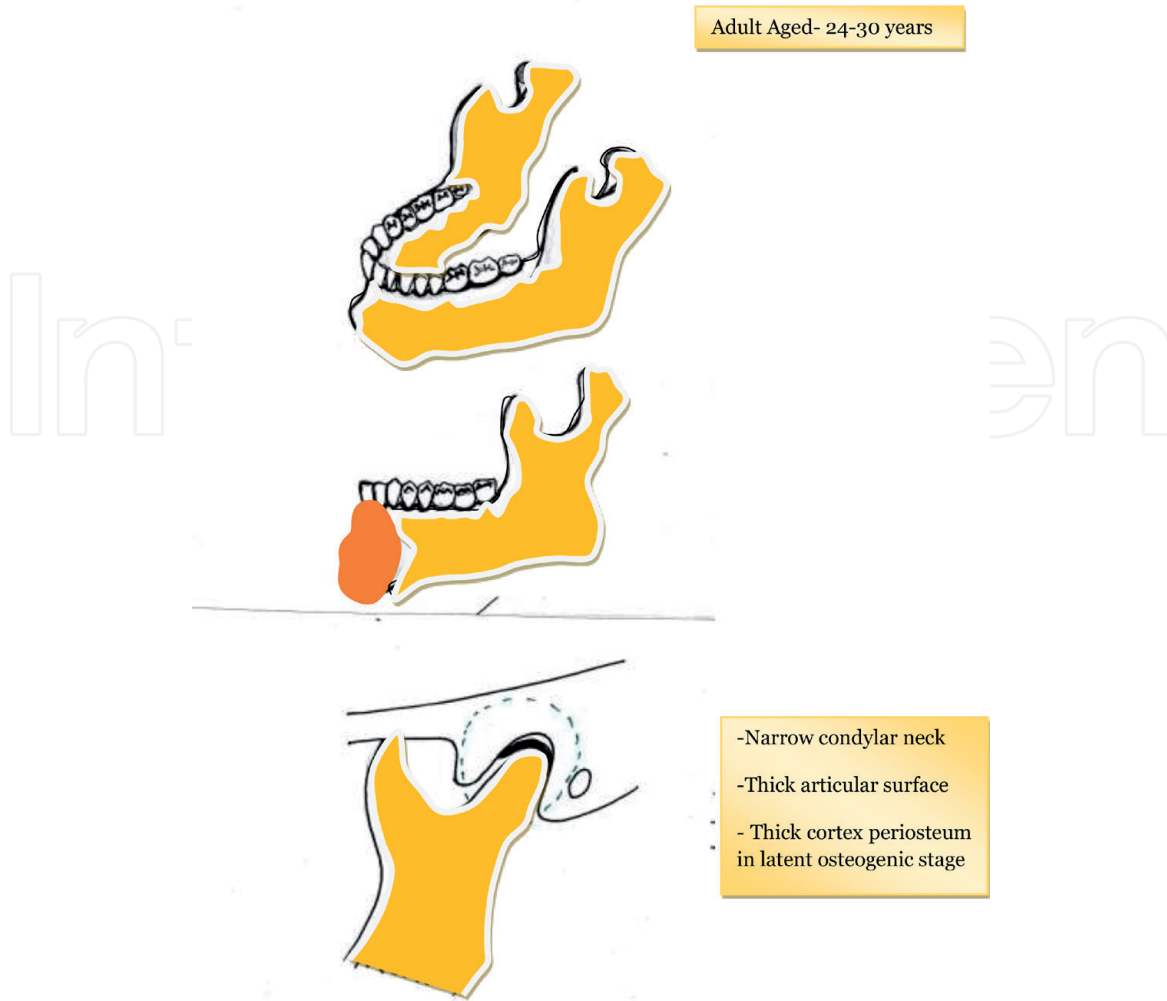
The anatomical variations between an adult and a pediatric condyle are given in **Table 1** (Figures 1 and 2).

Anatomical structure	Child	Adult
Cortical bone	Thin	Thick
Condylar neck	Broad	Thin
Articular surface	Thin	Thick
Capsule	Highly vascular	Less vascular

**Table 1.**  
*Differences between pediatric and adult condyle.*



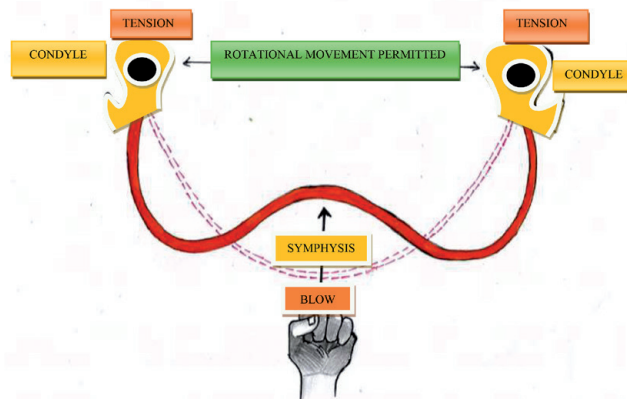
**Figure 1.**  
*Anatomy of Paediatric condyle.*



**Figure 2.**  
*Anatomy of adult condyle.*

### 3. Biomechanics of injury (Hunting bow concept)

The Mandible resembles a Hunting bow which is weak at the ends and strong in the midline and the condyles are enclosed by the glenoid fossa. So any blow to the midline of the mandible can cause bilateral condylar fracture and any blow to the parasymphysis may cause a contralateral fracture. This is based on the impact of the force (**Figure 3**) [5].



**Figure 3.**  
*Hunting bow concept.*

The fracture of condyle following trauma to the chin is an example of contre-coup injury. This is commonly found in soldiers who remain standing for a long time and hence referred to as Parade ground/Guardsman fracture.

#### 4. Classification of condylar fractures

Numerous classifications of condylar fractures are found in literature based on clinical and radiographic features.

##### 4.1 Wassmund 1927

Based on:

- a. Comminuted head fractures
- b. Chip fractures
- c. Condylar neck fractures
  - i. Vertical neck fractures secondary to shearing
  - ii. Transverse neck fractures secondary to bending
  - iii. Oblique neck fractures caused by a combination/bending [6]

##### 4.2 Wassmund 1934

Based on dislocated fractures of the condyle:

Type I: bony contact between the fractured fragments with 10–40° angulation of the condylar head.

Type II: bony contact between the fractured fragments with 50–90° angulation of the condylar head.

Type III: no bony contact with severe medial displacement [6].

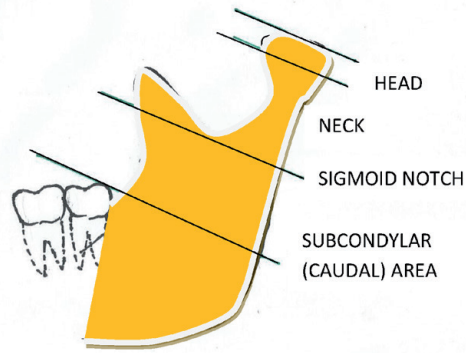
##### 4.3 Lindahl 1977

Based on the fracture location, deviation, and/or displacement and position of the condylar head within the articulating fossa:

- Sub condylar fracture: fracture line extends from the sigmoid notch to the posterior border of the mandible.
- Condylar neck fracture: fracture located below the level of condylar head at the condylar process.
- Condylar head fracture: fracture enclosed by the capsule of the temporomandibular joint (**Figure 4**)

##### 1. Fracture level

- a. Condylar head
- b. Condylar neck
- c. Sub condylar/condylar base



**Figure 4.**  
*Lindahl classification.*

## 2. Deviation and displacement

- a. Medial overlapping with bending or deviation
- b. Lateral overlapping with bending or deviation
- c. No overlapping with bending or displacement
- d. No deviation or displacement

## 3. Relation between condylar head and fossa

- a. Absence of dislocation
- b. Mild dislocation
- c. Moderate dislocation
- d. Complete or severe dislocation

## 4. Condylar head fracture

- a. Horizontal
- b. Vertical
- c. Compression fracture [6]

### 4.4 Loukota 2005

This Classification described “Line A,” which is a perpendicular line that extends from the deepest part of the coronoid notch to the posterior border of mandibular ramus.

- Diacapitular fracture: involves the articular surface and may extend outside the capsule of the temporomandibular joint
- Condylar neck: more than half of the fracture line is above line A

- Condylar base: more than half of the fracture line is below line A originating behind the mandibular foramen
- Minimal displacement: less than 10 mm of displacement or less than 2 mm of overlap by the bony edges or both [6]

#### **4.5 The AO 2010**

Based on:

- The first line parallels the posterior border of the mandible.
- The sigmoid notch line runs perpendicular to the first line at the deepest portion of the sigmoid notch.
- There is a line below the lateral pole of the condylar head that is also perpendicular to the first line.
- A line is drawn half way between the lateral pole line and the sigmoid notch line.
- A “high-neck” fracture is above this line, whereas a “low-neck” fracture is below [6].

#### **4.6 Neff 2014**

Based on the disc and condylar head:

- Condylar head: the condylar head reference line runs perpendicular to the posterior ramus below the lateral pole of the condylar head.
- Condylar neck: the sigmoid notch line running through the deepest point of the sigmoid notch perpendicular to the ramus line extending superiorly to the condylar head.
- Base of the condylar process: the sigmoid notch line running through the deepest point of the sigmoid notch perpendicular to the ramus line extending inferiorly [7].

#### **4.7 Ying 2017**

Classification of condylar head fracture based on vertical height of the ramus and disc displacement:

- Type A— no disc displacement or decrease in vertical height of the ramus
- Type B—disc displacement without decrease in vertical height of the ramus
- Type C—decrease in vertical height of the ramus with/without disc displacement [8]



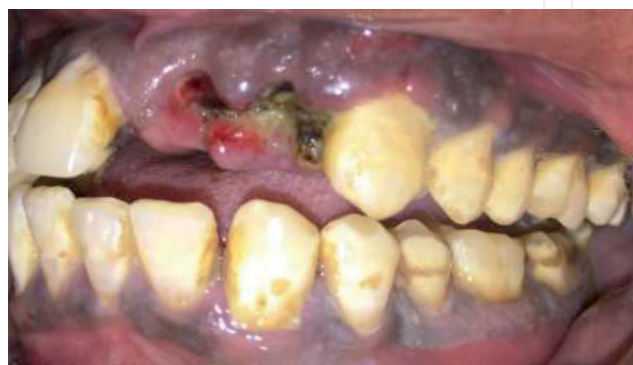## 5. Clinical examination

Condyle fractures are diagnosed with the help of both clinical and radiological assessment. Condylar fractures are most commonly missed on clinical examination. Extracapsular condylar fractures are frequent and may be associated with displacement of the condylar head. The condylar head may be in contact with the ramus or can be displaced laterally or medially. Anteromedial displacement is more common due to the pull of lateral pterygoid and weak medial capsule.

### 5.1 On inspection

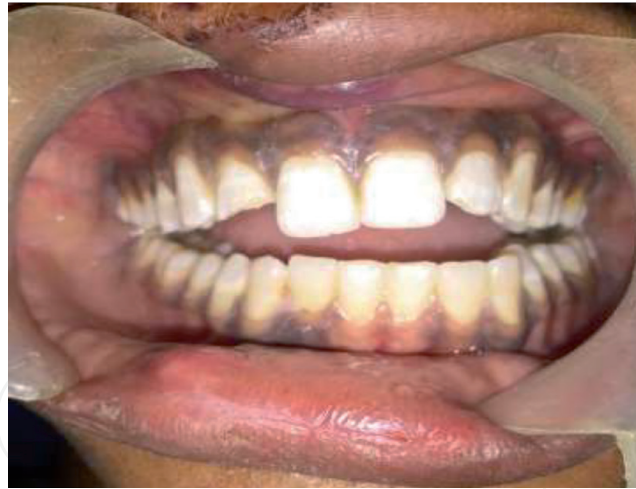#### a. Unilateral condylar fracture:

- Swelling over the temporomandibular joint, may be associated with hemorrhage from the external ear (due to laceration of external acoustic meatus by the violent impact of condyle on the skin).
- Proper examination with an autoscope/auriscope is essential to differentiate bleeding from external auditory canal and middle ear. Temporal bone may be accompanied by cerebrospinal fluid leak which is termed as otorrhea.
- Hematoma surrounding the fractured condyle
- Hematoma in the mastoid region called the Battle's sign
- If the condylar head is displaced medially, characteristic hollow in the region of condylar head can be observed once the edema subsides.
- Ear bleed will persist if the head of the condyle is impacted in the glenoid fossa.
- Deviation of mandible toward the side of fracture
- Decreased range of movements, pain and deviation toward the contra-lateral side while mouth opening.
- Gapping of occlusion on the ipsilateral side due to telescoping of fracture fragments on the contralateral side due to contraction of the masseter, temporalis and medial pterygoid and upward pull of the ramal segment (**Figure 5**)



**Figure 5.**  
*Ipsilateral open bite.*





**Figure 6.**  
*Anterior open bite.*

b. Bilateral condylar fracture:

- Overall mandibular movements are usually more restricted
- If the condyle is displaced bilaterally, shortening of ramus occurs resulting in derangement of occlusion
- Overriding of the fractured segments result in anterior open bite (**Figure 6**)
- Associated fracture of symphysis or para-symphysis can also be present; thus careful examination is mandatory (Contre-coupe fracture)

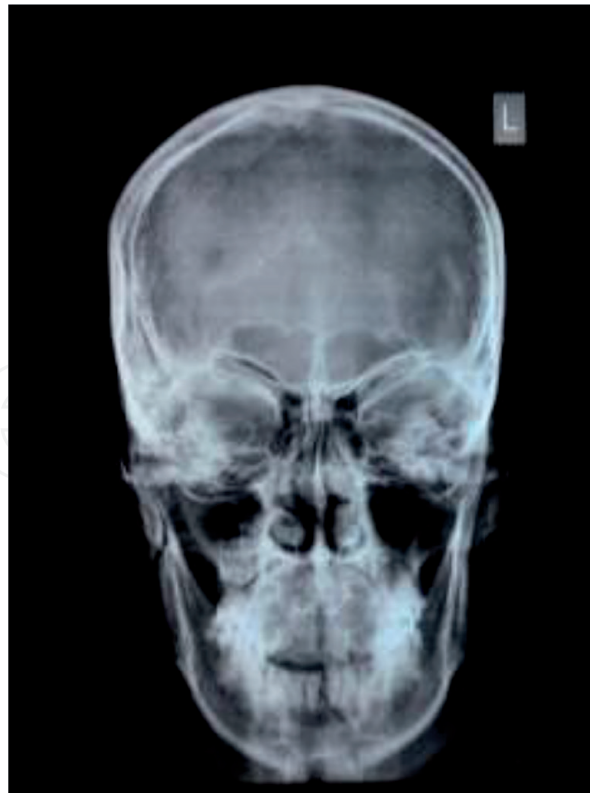## 5.2 On palpation

- The condyles are palpated by standing in front of the patient. The little fingers are placed inside the external auditory canal and the patient is asked to open and close their mouth, by this method the position and movement of the condyles are determined.
- Tenderness over the condylar area
- Displacement of the condylar head within the external auditory meatus.
- Paresthesia of the lips may be present as the hemorrhage from the condylar region tracks across the base of skull and exerts pressure on the mandibular division of the trigeminal nerve as it emerges from the foramen ovale.

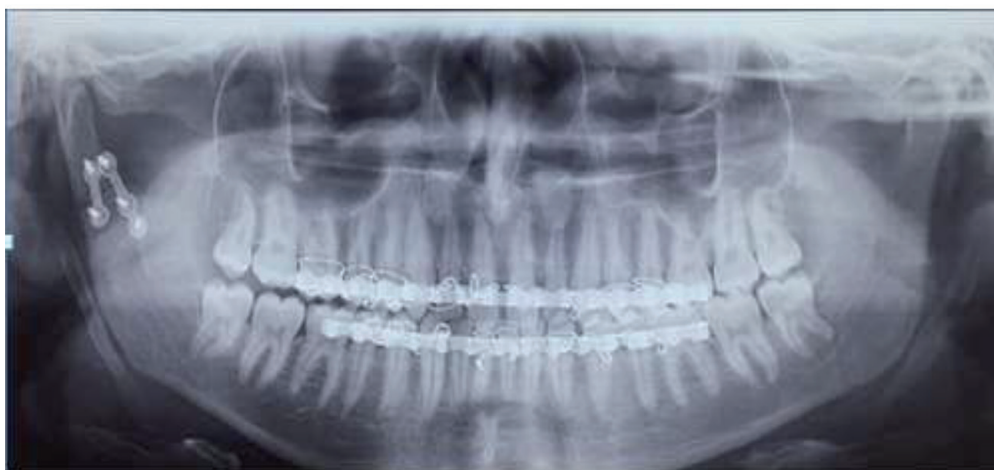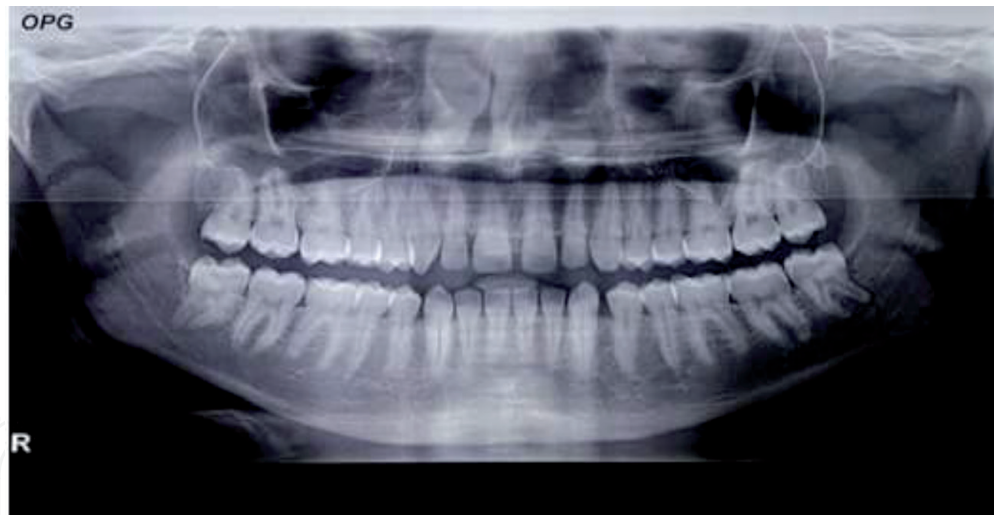## 6. Radiographic assessment

Routine radiological investigations that aids in the diagnosis of condylar fracture are:

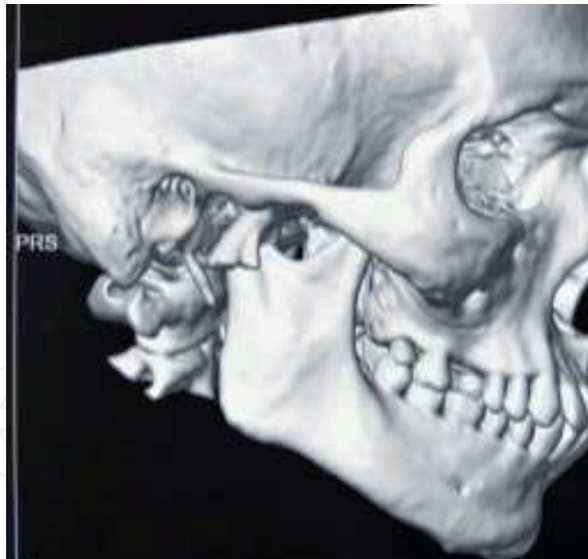- Posteroanterior skull projection or Reverse Towne's (**Figure 7**)
- Oblique-lateral X-ray
- Orthopantomographic radiograph (**Figure 8**)



**Figure 7.**  
*Posterior anterior skull view.*



**Figure 8.**  
*Orthopantomogram.*



**Figure 9.**  
*Computed tomography.*

- TMJ tomography
- Waters projection or Para nasal sinus view
- Clementschitsch view or occipital
- Nasal projection [9]

CT in all three planes, i.e., coronal, axial, and sagittal remains a gold standard for the diagnosis of mandibular condyle fractures. 3D CT provides better orientation of the fractured fragments in relation to the normal anatomic structures (**Figure 9**) [10].

Determining the degree of dislocation, relationship between the fractured fragments and the direction of dislocation remains a challenge in the diagnosis of mandibular condyle fractures. It may be difficult to ascertain position and rotation of the articular head of the condyle with the use of conventional imaging techniques. MRI may provide a better outlook in assessing both the hard tissue and soft tissue part of the condylar head. One must remember that re-establishing only the bony component of the joint is not sufficient and the soft tissue anatomy (Articular disc) must also be restored to achieve satisfactory functional outcomes [11].

## 7. Management of condylar fractures

Aims of treatment includes

1. Restoration of form
2. Restoration of function

This is achieved by proper repositioning and immobilization of the fractured fragments.

Treatment options for mandibular condyle fractures can be divided into conservative treatment and surgical management [9].

## 8. Conservative treatment of condylar fractures

Conservative therapy remained the primary mode of treatment of mandibular condyle fracture for many years. This is now overshadowed by surgical therapy due to increase in surgical expertise and the advent of new technological advances in both instrumentation and radiological diagnosis. But there exist certain scenarios where conservative treatment is preferred.

In closed reduction achievement of good occlusal relationship acts as the guidance for proper reduction. The upper and lower jaws are fixed together in occlusal relationship by means of intermaxillary fixation or maxillomandibular fixation done using wires or splints. The wires that pass through the embrasure space of the adjacent teeth of the same arch are called interdental wires. These are later engaged during intermaxillary wiring.

Various modalities of intermaxillary fixation used commonly for condylar fracture are:

### 1. Wiring:

- Ivy loop wiring
- Continuous ivy loop wiring
- Gilmer wiring

### 2. Arch bars:

- Erich's arch bar

### 3. Splints:

- Cap splint in pediatric patients
- Gunning splints in edentulous patients

Indications for conservative treatment:

- Minimally displaced fracture (Not more than 30°),
- Pediatric fractures,
- Presence of systemic comorbidities which may be an absolute contraindication for surgery,
- Condylar head fracture where there is an increased risk of injury to the joint and the adjoining structures. (Vascularity of the fragment may also be compromised by osteosynthesis).
- Minimal pain complaints and no occlusal discrepancies with acceptable range of movements.
- Diacapitular fracture of the condyle [9].

Conservative treatment consists of maxillo-mandibular fixation by means of arch bars, IMF screws or dental splints (cap splint or gunning splint) and inter-maxillary traction using elastics or wires. Immobilization of the joints are done for a period of 4–6 weeks in case of adults whereas 7–10 days for children. Antegrade physiotherapy is mandatory until full adhesion of the fractured fragments [9]. The treatment span is shortened in the pediatric population as they have an increased growth potential and prolonged immobilization may lead to ankylosis of the joint [12].

### 8.1 Advantages and disadvantages of closed treatment

Advantages:

- Noninvasive, simple, easy to master
- Does not require exposure to general anesthesia
- Economical
- Less chance of infection [13]

Disadvantages:

- Immobilization might not be adequate which delays healing. Especially in subcondylar fractures where control over proximal segments is not established, unfavorable muscle pull can cause displacement of fragments.
- Increases patient morbidity
- Not safe in epileptic patients [13]

## 9. Surgical treatment of condylar fractures

Conservative treatment using maxillo-mandibular fixation does not always provide satisfactory outcomes. Persistent malocclusion may be present where the necessity for open reduction and internal fixation.

Open reduction and internal fixation helps in faster restoration of both form and function unlike conservative treatment. The patient is rehabilitated in a shorter period of time unlike conservative treatment. Some of the indications for open reduction and internal fixation of mandibular condyle fracture includes.

- a. Severe displacement of the condyle
- b. Mal-united fracture
- c. Bilateral condylar fractures with severe displacement or dislocation affecting the occlusion
- d. Associated fractures of the mandible
- e. Multifragmented fracture of the condylar head

Zide and Kent's criteria for open reduction are as follows.



Closed reduction	Open reduction
1. Undisplaced or displaced condylar or comminuted fracture (in growing children) where form and function can be restored	1. Dislocated condyle and where there is mechanical interferences with the mandibular function
2. No medical contraindications for MMF	2. Loss of anterior-posterior and vertical dimension that cannot be managed by closed reduction (ex-panfacial and in edentulous fracture)
3. Medical and anesthetic contraindications for open reduction	3. Compound fracture
	4. Displacement of condyle into middle cranial fossa
	5. Patient and surgeon preference for early or immediate mobilization of function

**Table 2.**  
*Indications for open and closed reduction of mandibular condyle fracture AAOMS 2017 guidelines [12].*

**Absolute indications:**

- Displacement of condyle into the middle cranial fossa
- Impossibility of restoring occlusion
- Invasion of foreign body
- Lateral extracapsular displacement

**Relative indications:**

- When intermaxillary fixation is contraindicated for medical reasons
- Bilateral fracture with open bite deformity
- Bilateral fracture with associated comminuted mid face fracture
- Periodontal problems and loss of teeth
- Unilateral condylar fracture with unstable base [14]

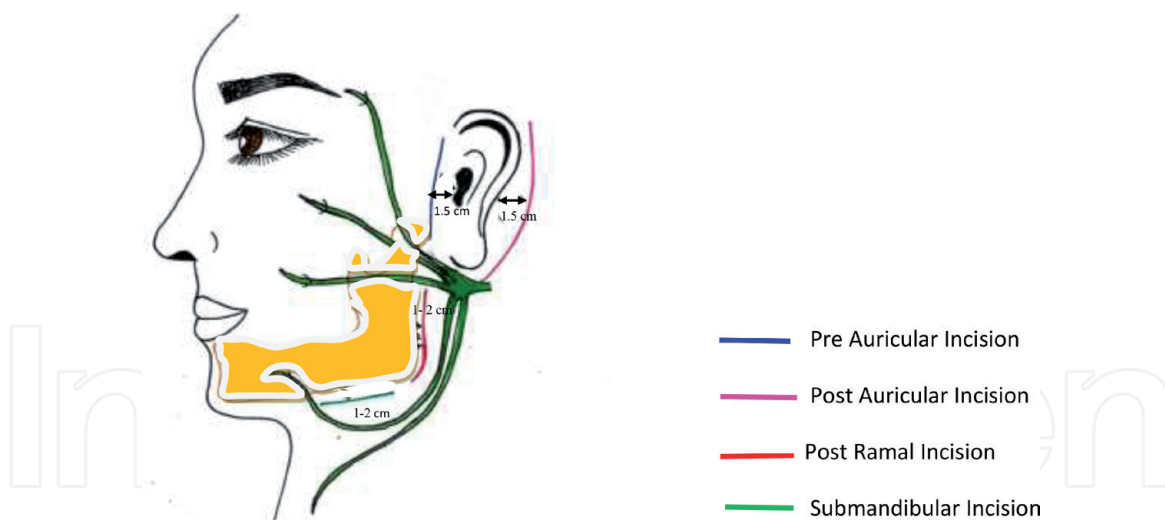
According to AAOMS 2017 the indications for closed and open reduction of condylar fractures are tabulated in **Table 2** [15].

**10. Surgical approaches to TMJ**

A variety of incisions to approach the TMJ have evolved over the years with each one having their own advantages and disadvantages. These incisions have been categorized into [16]

1. Preauricular and its modification (**Figure 10**)
2. Post-auricular and modification (**Figure 10**)





**Figure 10.**  
*Approaches to condylar fracture.*

3. Endaural and modifications
4. Submandibular (Risdon) (**Figure 10**)
5. Retromandibular or post ramal (**Figure 10**)
6. Rhytidectomy (Face-Lift)
7. Intraoral approach

Approach is based on the level of fracture [17].

The approaches for different levels of fractures with minimal complications are listed below.

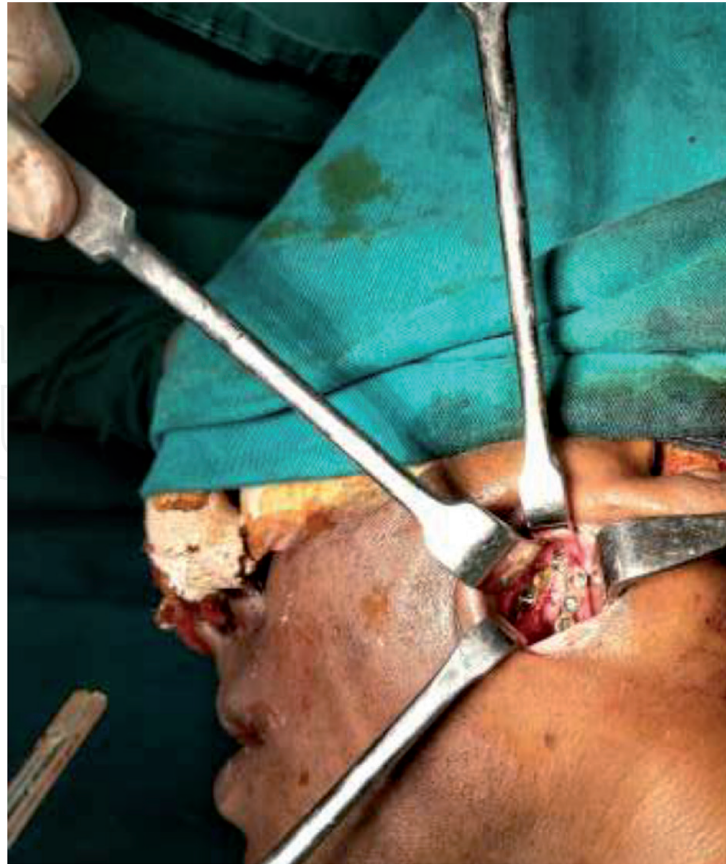- Condylar head fracture—pre-auricular approach or retroauricular approach
- Condylar neck fracture—retromandibular approach with preauricular extension
- Condylar base fracture—submandibular, retromandibular and intra-oral approach

## 11. Reduction

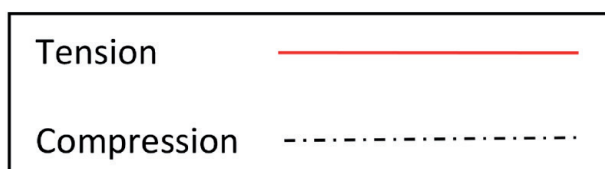
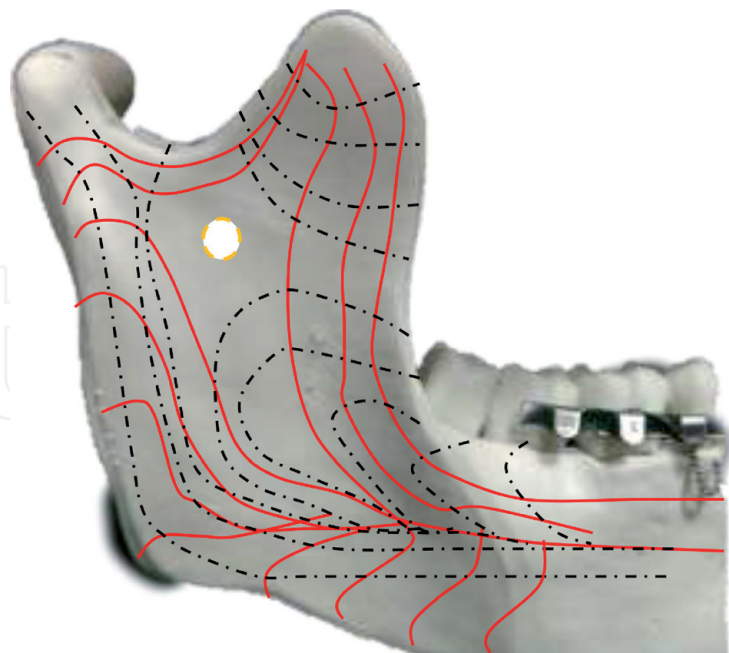
Reduction is the procedure done for restoring the functional alignment of the fractured bone fragments. Reduction is done to bring the fractured fragments together close to their previous anatomical position so that healing is proper and rapid. Once access is gained to the surgical site reduction is done with the help of bone clamps, forceps, screw and wire and towel clips [13].

## 12. Fixation

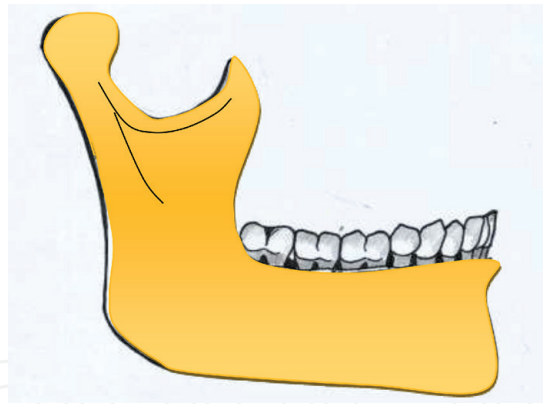
Fixation is the surgical procedure that is done to stabilize and join the ends of fractured bones by mechanical devices such as metal plates, pins, rods, wires, or screws (**Figure 11**).



**Figure 11.**  
*Miniplate fixation.*



**Figure 12.**  
*Zone of tension and compression.*



**Figure 13.**  
*Ideal line of osteosynthesis.*

### 12.1 Ideal lines of osteosynthesis

The condyles are subjected to major stress during mastication. Meyers gave the ideal lines of osteosynthesis for the mandibular condyle through his research works as follows:

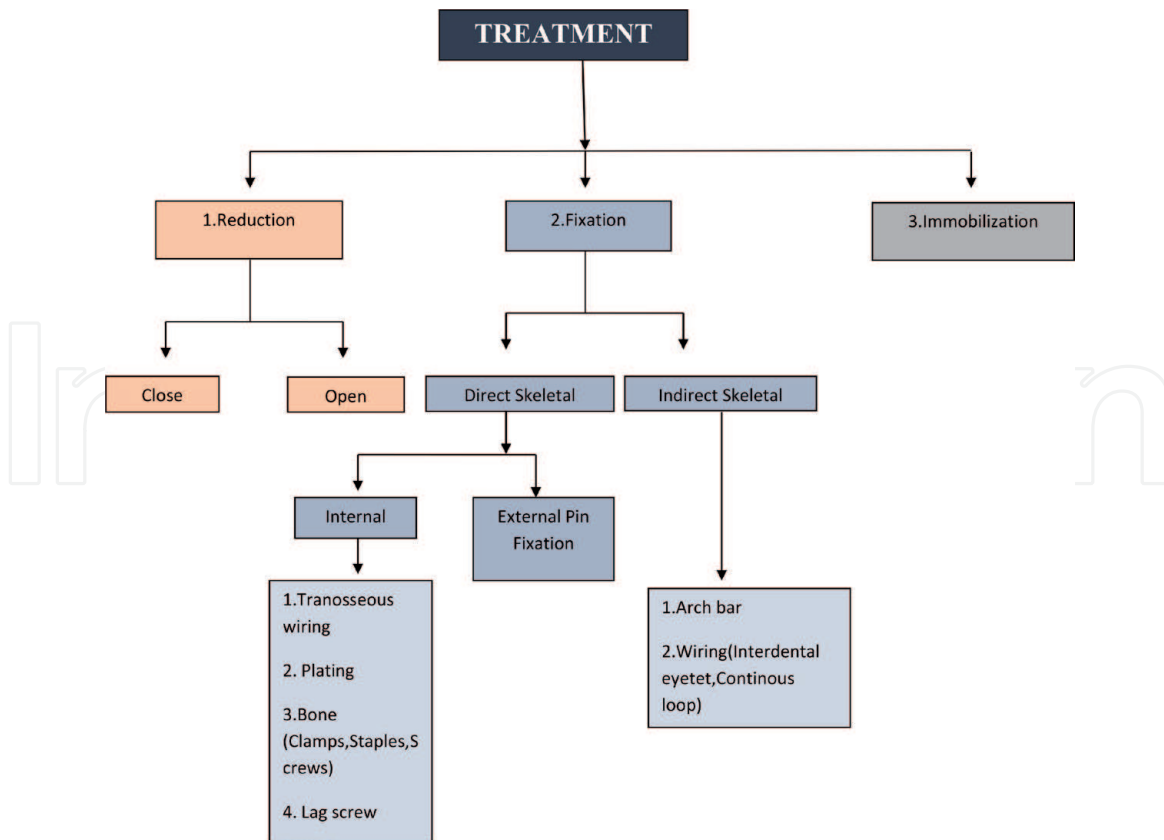
1. Zone of tension: lies along the anterior border of the condyle and the sigmoid notch
2. Zone of compression: lies along the posterior border of the ramus

The long axis of the condylar neck acts as a beam which is subjected to flexion in the sagittal plane. All these biomechanical properties must be taken into consideration while fixation of the fracture pertained to the region (**Figures 12 and 13**) [18].

### 13. Different fixation options

Fixation is done after ensuring anatomic reduction and normal occlusion.

- a. **Single plate**—in a single miniplate the fracture must be stabilized using two screws on each side of the fracture line. The drawback of this plating has showed the greatest peak displacement of fracture.
- b. **Two plates**—application of these two plates at the anterior and posterior aspects of the condylar neck which helps in resisting the torsional force that may not be opposed with a single plate [19].
- c. **Geometric plate**—a single L, Y plate, triangular plate, trapezoidal plate, delta plate or 3 D plates are used. Among all plates geometric plates provide the better stability and outcome, because it fulfills the criteria of functionally stable osteosynthesis in the fracture segments [20].
- d. **Resorbable plate**—prevents the need for re-operation and has shown good results in the treatment of condylar fractures. They are not very stable when compared to titanium plates in the treatment of condylar fractures [19].
- e. **Lag screw**—good clinical results can be obtained especially in diacapitular/sagittal head fractures [21].
- f. **Extra corporeal reduction and fixation**—the condyle is explanted from the glenotemporal fossa, reduced and fixed in desired position. The drawback of



**Figure 14.**  
*Treatment algorithm for adult condylar fracture.*

this type of fixation will lead to avascular necrosis related to detachment of soft tissue [22].

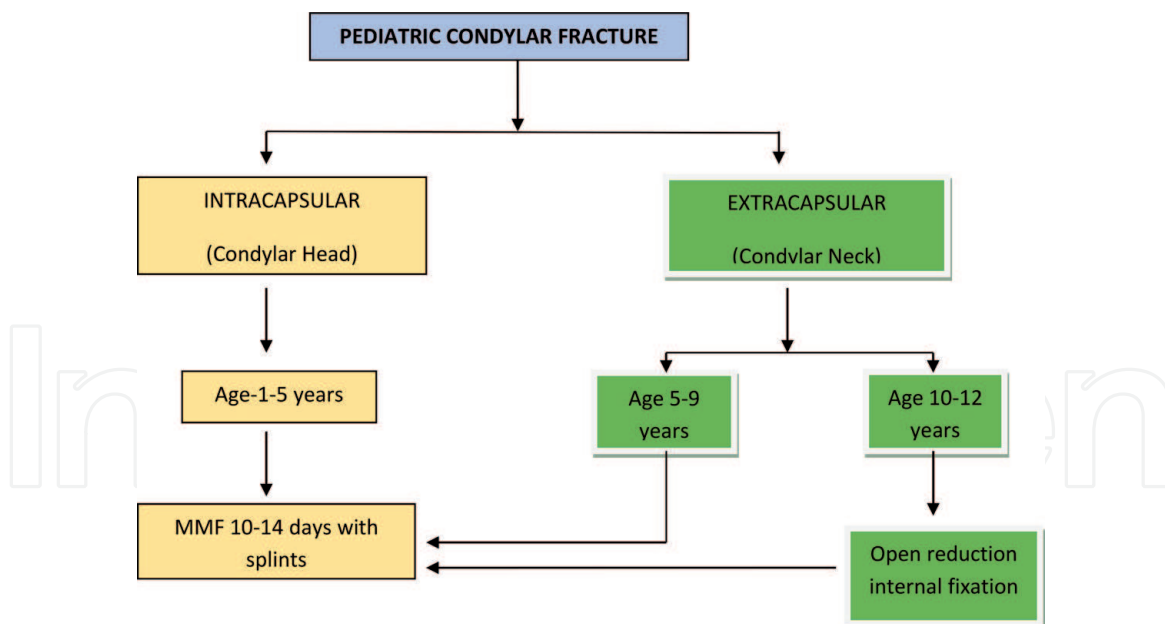
The treatment plan is summarized and depicted in a flow chart (**Figure 14**) [13].

## 14. Pediatric condylar fractures

In children displacement of the fractured condyle is uncommon and it is mostly a greenstick fracture. This is due to the fact that the facial bone in children is enclosed by thick soft tissues; the bone is elastic in nature, presence of a large amount of immature trabecular bone and thin cortical bone. Fractures in the pediatric population can easily be overlooked and if untreated may lead to delayed complications like:

1. Ankylosis
2. Poor development of the body and ramus of the mandible on the affected side
3. Gross facial asymmetry
4. Bird face and microgenia in case of bilateral condylar fractures [12]

Treatment in children differs from adults taking the growth and development into consideration. There are certain conditions where surgical treatment is mandatory. Surgical treatment is indicated under the following conditions:



**Figure 15.**  
*Treatment algorithm for pediatric condylar fracture.*

1. Complex or open fractures
2. Severe displacement
3. Sub condylar fractures with associated facial or calvarial fractures
4. Multiple fractures of the condyle

Surgical treatment may affect the normal growth of the mandible due to the surgical trauma to the soft tissue and the rigidly fixed bony fragments. Moreover, due to the risk of damage to the facial nerve and the invasiveness of surgery conservative treatment is mostly preferred. Maxillomandibular fixation is preferred for a period of 7–10 days followed by physiotherapy (**Figure 15**) [23].

## 15. Management of geriatric condylar fracture

The cross-sectional area of an atrophic mandible is usually decreased when compared to a mandible with dentition. The vascularity of the bone is decreased and the bone is sclerotic in nature which will hinder or delay the normal healing of the mandible following open reduction. Due to the lack of dentition the fractured fragments are easily displaced. The poor quality of the bone is not suitable for plating the fracture. Conservative treatment with a Gunning splint is advantageous as it provides a stable maxillomandibular fixation and also preserves the periosteal vascularity. Thomas brain gunning designed the “Gunning splint” for maxillomandibular fixation of edentulous or partially edentulous jaw. It consists of two dentures held together in a mono-block. It holds the fracture fragments together and immobilizes the jaw. There is no means of retention or stabilization in an edentulous patient therefore the maxillary denture is secured to the maxilla through per alveolar wiring and the mandibular denture is secured to the mandible with circum-mandibular wiring. The two splints are connected with wire loops or elastics and intermaxillary fixation is achieved [24].



## 16. Rehabilitation

Rehabilitation can be begun just on the first day of operation in patients who are treated surgically. It mainly consists of exercises which adduces and disadduces the mandible. The exercise is done in front of the mirror so that the mandible is adducted in the correct position. The exercise is done for about 3 to 5 times a day for a timing of 5–10 minutes. In patients who are treated nonsurgically rehabilitation starts at the end of removal of maxillomandibular fixation. Majority of the authors recommend shortening the period of immobilization for 10 to 14 days to prevent the risk of ankylosis. Zaccharides recommends removal of the maxillomandibular fixation once a week during the treatment, the patient should practice opening and closing for half an hour to 1 hour before re-installation of MMF [12]. After conservative treatment physiotherapy is recommended for 3–4 weeks. Rehabilitation is finished when the patient is able to open and close the mouth similar to pre-trauma [9].

## 17. Complications

Complications in the management of mandibular condyle fractures depends on the severeness of trauma, fracture type, degree of fracture displacement, presence of associated fractures, the type of management (open/closed) and the timing of intervention.

### a. Common complications [12]

- Joint motility disorders
- Occlusal discrepancies
- Ipsilateral asymmetry on the side of trauma
- Ankylosis (0.2–0.4%)

### b. Rare complications

- Articular head necrosis which is related with surgical method

### c. Surgical complications

- Transient or permanent facial palsy
- Marginal mandibular nerve palsy
- Ear lobe hypoesthesia
- Post-surgical scarring
- EAC stenosis
- Formation of sialocele and salivary fistulas
- Auriculotemporal nerve syndrome or Frey's syndrome
- Masseter myotonia



- Mini plate fracture
- Condylar head resorption

The surgical complications are temporary and may persist for about 12 months from the time of operation. Adjunctive pharmacotherapy can be prescribed during this phase (Vitamin B and Vitamin B12 preparations) [9].

## **18. Conclusion**

An appropriate treatment, that is, either a conservative treatment or an open reduction and internal fixation must be considered weighing the advantages and disadvantages, respectively. The treatment must also be based on various factors involved such as age, systemic status, affordability, type of fracture, etc. When a surgical treatment is planned, soft tissue (articular disc) repair must also be considered rather treating the bony component alone as it may lead to delayed temporomandibular joint disorders.

## **Acknowledgements**

We would like to thank Dr. Krishna Kumar Raja, M.D.S. Professor and Head of the Department of Oral and Maxillofacial Surgery, SRM Dental College, for providing us this opportunity.

We would also like to thank Dr. Elavenil Panneerselvam, M.D.S., Reader, Department of Oral and Maxillofacial Surgery, SRM Dental College, for encouraging and guiding us through the entire process.

We would also like to thank Dr. Z.H. Husna Sofia, B.D.S, for providing technical support in the form of diagrams and flowcharts.

## **Conflict of interest**

The authors declare no conflict of interest.

## **Author details**

Kasi Ganesh Sriraam\* and K. Rajendran Arun Vignesh  
Department of Oral and Maxillofacial Surgery, SRM Dental College and Hospital,  
Chennai, India

\*Address all correspondence to: [sriraamkg@gmail.com](mailto:sriraamkg@gmail.com)

## **IntechOpen**

© 2020 The Author(s). Licensee IntechOpen. This chapter is distributed under the terms of the Creative Commons Attribution License (<http://creativecommons.org/licenses/by/3.0>), which permits unrestricted use, distribution, and reproduction in any medium, provided the original work is properly cited. 

## References

- [1] Sawazaki R, Júnior SM, Asprino L, Moreira RW, De Moraes M. Incidence and patterns of mandibular condyle fractures. *Journal of Oral and Maxillofacial Surgery*. 2010;**68**(6):1252-1259
- [2] Nørholt SE, Krishnan V, Sindet-Pedersen S, Jensen IB. Pediatric condylar fractures: A long-term follow-up study of 55 patients. *Journal of Oral and Maxillofacial Surgery*. 1993;**51**(12):1302-1310
- [3] Barde D, Mudhol A, Madan R. Prevalence and pattern of mandibular fracture in Central India. *National Journal of Maxillofacial Surgery*. 2014;**5**(2):153
- [4] Rozylo-Kalinowska I, Orhan K. *Imaging of the Temporomandibular Joint*. Switzerland: Springer Nature Switzerland AG; 2019
- [5] Hupp J, Tucker M, Ellis E. *Contemporary Oral and Maxillofacial Surgery*. Philadelphia: Elsevier; 2019
- [6] Powers DB. Classification of mandibular condylar fractures. *Atlas of the Oral and Maxillofacial Surgery Clinics of North America*. 2017;**25**(1):1-10
- [7] Neff A, Cornelius CP, Rasse M, Torre D, Audigé L. The comprehensive AOCMF classification system: Condylar process fractures-level 3 tutorial. *Craniofacial Trauma & Reconstruction*. 2014;**7**(S01):S044-S058
- [8] Ying BB, Zhang QQ, Zhu SS, Li YF. Outcomes of treatment for intracapsular fractures of the mandibular condyle: Recommendation for a new classification. *The British Journal of Oral & Maxillofacial Surgery*. 2018;**56**(2):139-143
- [9] Niedzielska I, Tomczyk-Wziątek A, Borowski B. Fractures of the mandibular condylar processes—Literature review. *Open Medicine*. 2013;**8**(2):244-249
- [10] Naeem A, Gemal H, Reed D. Imaging in traumatic mandibular fractures. *Quantitative Imaging in Medicine and Surgery*. 2017;**7**(4):469
- [11] Ren R, Dai J, Si J, Cai B, Shi J. Changes of disc status in adult patients with condylar head fracture who did or did not undergo disc anchoring operation. *Journal of Cranio-Maxillofacial Surgery*. 2018;**46**(12):2248-2255
- [12] Zachariades N, Mezitis M, Mourouzis C, Papadakis D, Spanou A. Fractures of the mandibular condyle: A review of 466 cases. Literature review, reflections on treatment and proposals. *Journal of Cranio-Maxillofacial Surgery*. 2006;**34**(7):421-432
- [13] Banks P, Killey H. *Killey's Fractures of the Mandible*. Oxford, England: Wright; 1991
- [14] Brandt MT, Haug RH. Open versus closed reduction of adult mandibular condyle fractures: A review of the literature regarding the evolution of current thoughts on management. *Journal of Oral and Maxillofacial Surgery*. 2003;**61**(11):1324-1332
- [15] Ochs M, Chung W, Powers D. Trauma surgery. *Journal of Oral and Maxillofacial Surgery*. 2017;**75**(8):e151-e194
- [16] Quinn P, Granquist E. *Atlas of Temporomandibular Joint Surgery*. 2nd ed. New Jersey, United states: John Wiley & Sons; 2015
- [17] Al-Moraissi EA, Louvrier A, Colletti G, et al. Does the surgical approach for treating mandibular condylar fractures affect the rate of seventh cranial nerve injuries? A

systematic review and meta-analysis based on a new classification for surgical approaches. *Journal of Cranio-Maxillo-Facial Surgery*. 2018;**46**(3):398-412

handling of mandibular fractures in edentulous patients. *Indian Journal of Dental Sciences*. 2020;**12**:36-39

[18] Meyer C, Martin E, Jean-Luc KA, Simone ZI. Development and biomechanical testing of a new osteosynthesis plate (TCP®) designed to stabilize mandibular condyle fractures. *Journal of Cranio-Maxillofacial Surgery*. 2007;**35**(2):84-90

[19] Bischoff EL, Carmichael R, Reddy LV. Plating options for fixation of condylar neck and base fractures. *Atlas of the Oral and Maxillofacial Surgery Clinics of North America*. 2017;**25**(1):69-73

[20] Bhowmick RS, Bhowal K, Ghosh S. Plating systems for 3D stability of subcondylar fracture: A research article with review of literature. *International Journal of Orthopaedics*. 2019;**5**(2):681-683

[21] Kallela I, Söderholm AL, Paukku P, Lindqvist C. Lag-screw osteosynthesis of mandibular condyle fractures: A clinical and radiological study. *Journal of Oral and Maxillofacial Surgery*. 1995;**53**(12):1397-1404

[22] Park JM, Jang YW, Kim SG, et al. Comparative study of the prognosis of an extracorporeal reduction and a closed treatment in mandibular condyle head and/or neck fractures. *Journal of Oral and Maxillofacial Surgery*. 2010;**68**(12):2986-2993

[23] Choi KY, Yang JD, Chung HY, Cho BC. Current concepts in the mandibular condyle fracture management part II: Open reduction versus closed reduction. *Archives of Plastic Surgery*. 2012;**39**(4):301

[24] Sharma B, Sharma P, Goswami R, Jain S, Samra RK. Construction of a gunning splint; case report on the