

The First Molecular Detection and Genotyping of *Encephalitozoon cuniculi* in Rabbit's Eye in Turkey

Ozcan OZKAN ^{1,a} Alper KARAGOZ ^{2,b} Nadir KOCAK ^{3,c} Mehmet Eray ALCIGIR ^{4,d}

¹ Çankırı Karatekin University, Faculty of Science, Department of Biology, TR-18100 Çankırı - TURKEY

² Public Health General Directorate, Molecular Laboratory, TR-06100 Ankara - TURKEY

³ Selcuk University, Faculty of Medicine, Department of Medical Genetic, TR-42130 Konya - TURKEY

⁴ Kırıkkale University, Faculty of Veterinary Medicine, Department of Pathology, 71450, Ankara - TURKEY

^a ORCID: 0000-0002-5216-8361; ^b ORCID: 0000-0002-8178-223X; ^c ORCID: 0000-0002-1727-1582; ^d ORCID: 0000-0002-8178-223X

Article Code: KVFD-2018-19696 Received: 03.03.2018 Accepted: 22.05.2018 Published Online: 23.05.2018

How to Cite This Article

Ozkan O, Karagoz A, Kocak N, Alcigir ME: The first molecular detection and genotyping of *Encephalitozoon cuniculi* in rabbit's eye in Turkey. *Kafkas Univ Vet Fak Derg*, 24 (4): 607-611, 2018. DOI: 10.9775/kvfd.2018.19696

Abstract

Encephalitozoon cuniculi was first recognized as the disease agent in rabbits in 1922. The genotype of *E. cuniculi* isolated from laboratory rabbits with the neurologic disease was described as genotype I. In the eye, this parasite causes damage to the lens, causing phacoclastic uveitis and cataracts. Intraocular infection often occurs in cases of transplacental transmission. There has been no report on the molecular diagnosis of the parasite in Turkey. The current study is the first report on the detection of *E. cuniculi* spores using the molecular method in Turkey. In our previous study, a rabbit breeding facility was determined seropositive for *E. cuniculi* infection monitored for five years in terms of clinical symptoms. An autopsy was performed for a definite diagnosis of the infection. Samples were stained according to the hematoxylin-eosin (H&E) staining after tissue processing procedure and histopathologic analysis was performed. In addition to, the samples for DNA extraction were also taken during the autopsy. ECUNF and ECUNR species-specific primer pairs were used for amplification and genotyping of *E. cuniculi*. The animals were observed no clinical symptoms except ocular lesion (n=9). Therefore, one of these rabbits was used in the autopsy to definite diagnosis and determination of the damage to the eye. As histopathological, the lesions in the eye were found in the initial or middle stage of progressive infection. The DNA sequence showed that *E. cuniculi* examined in the present study were genotype I. Possible cause of the visible white mass in the rabbit's eye may be the parasite infection. Therefore, clinicians may consider *E. cuniculi* as one of the possible causes of ocular lesions in rabbits during daily inspection or ophthalmological examination.

Keywords: Rabbit, Eye, Molecular diagnosis, *Encephalitozoon cuniculi*, Phylogenetic analysis, Turkey

Türkiye'de Tavşan Gözünde *Encephalitozoon cuniculi*'nin İlk Moleküler Tayini ve Genotiplenmesi

Öz

Encephalitozoon cuniculi tavşanlarda hastalık ajanı olarak ilk kez 1922 yılında tanınmıştır. Nörolojik hastalıklı laboratuvar tavşanlarından izole edilen *E. cuniculi* genotipi, genotip I olarak tanımlanmıştır. Bu parazit, gözde lens hasarına, bu da fakoklastik üveite ve katarakta neden olur. İntraoküler enfeksiyon sıklıkla transplasental bulaşma vakalarında ortaya çıkar. Türkiye'de parazitin moleküler tanısı hakkında herhangi bir rapor bulunmamaktadır. Bu çalışma, Türkiye'de moleküler yöntem kullanılarak *E. cuniculi* sporlarının saptanmasıyla ilgili ilk rapordur. Önceki çalışmamızda *E. cuniculi* enfeksiyonu seropozitif belirlenen bir yetiştirme tesisindeki tavşanlar, klinik semptomlar açısından beş yıl boyunca izlenildi. Enfeksiyonun kesin tanısı için otopsi yapıldı. Doku işleme prosedüründen sonra, doku örnekleri hematoksilin-eozin (H & E) boyamasına göre boyandı ve histopatolojik analiz yapıldı. Bununla birlikte, DNA ekstraksiyonu için otopsi sırasında örnekler alındı. *E. cuniculi*'nin amplifikasyonu ve genotiplenmesi için ECUNF ve ECUNR türe özgü primer çifti kullanıldı. Hayvanlarda oküler lezyon (n=9) dışında klinik semptom görülmedi. Bu nedenle, bu tavşanlardan biri, kesin tanı koymak ve göze verilen zararı belirlemek için otopside kullanıldı. Histopatolojik olarak, gözdeki lezyonlar enfeksiyonun ilerleyici ilk veya orta evresinde bulundu. Bu çalışmada sunulan *E. cuniculi*'nin DNA dizisi, genotip I olduğunu göstermiştir. Tavşan gözündeki görünür beyaz kitlenin olası bir nedeni parazit enfeksiyonu olabilir. Bu nedenle klinisyenler, *E. cuniculi*'yi, günlük muayenede veya oftalmolojik muayenede tavşanlardaki göz lezyonlarının olası nedenlerinden biri olarak görebilirler.

Anahtar sözcükler: Tavşan, Göz, Moleküler tanı, *Encephalitozoon cuniculi*, Filogenetik analiz, Türkiye



İletişim (Correspondence)



+90 376 2189537 Fax: +90 376 2189541



ozcanozkan@karatekin.edu.tr

INTRODUCTION

Encephalitozoon cuniculi is an obligatory spore-forming, intracellular parasite belonging to the phylum Microsporidia. *E. cuniculi* was identified as a pathogen in rabbits for the first time by Wright and Craighead^[1]. Presently, various reports of *E. cuniculi* infestation have been increasing in the fields of human and veterinary medicine. Therefore, the disease is well-documented, particularly in Lagomorphs. Moreover, molecular analysis has shown that *E. cuniculi* is divided into four genotypes according to the number of GTTT repeats in the internal transcribed spacer of the rDNA gene. Consequently, hitherto, these strains have been termed as the rabbit (genotype I), mouse (genotype II), dog (genotype III) and human (genotype IV) strains^[2,3].

Diagnosis of encephalitozoonosis is difficult because most rabbits do not have clinical signs. Nonetheless, the infection has been diagnosed using different methodologies, such as microscopic identification, antibody detection or polymerase chain reaction (PCR). In pet, farm and laboratory rabbits, encephalitozoonosis is a problem affecting their health status. An opportunistic and zoonotic pathogen can have a significant impact on the results of experiments^[4].

In Turkey, *E. cuniculi* infection in rabbits has been first reported histopathologically and later serologically using the carbon immunoassay test and histopathological test as diagnostic tools^[5-8]. In addition, to the best of our knowledge, there has been no report on the molecular diagnosis of the parasite in Turkey. Therefore, this is the first molecular study on genotyping of *E. cuniculi* in Turkey.

MATERIAL and METHODS

Animals and Clinical Evaluation

The present study has been assessed and approved by the National Animal Experiment Central Ethics Board in accordance with the ethical regulation (2018/111334). According to our study^[8] previously serologically reported the infection in the rabbit breeding facility licensed by the Ministry of Food, Agriculture and Livestock, therefore, the facility clinically monitored to prevent *E. cuniculi* infection throughout five years. The rabbits aged 6 to 28 months with a body weight of 1.5-2.5 kg in the colony were examined in terms of body condition, daily food, and water intake, appetite, and behaviour, in addition, was observed to the most common clinical symptoms such as torticollis, ataxia, aggressiveness, seizures, swaying, paralysis, ocular lesion. The animals were housed in the individual cages in standard room conditions. They were given ad libitum commercial diet and water.

Pathological Evaluation

In the case of any clinical symptoms in rabbits, as a further

analysis, histopathological examination was performed to determine definitive diagnosis of the infection. For this reason, autopsy was performed to show the definite diagnosis of a rabbit infection according to clinical symptoms. Therefore, the rabbit was autopsied and organs were macroscopically examined after euthanasia with the high dose anesthetic protocol (xylazine hydrochloride 60 mg/kg and ketamine hydrochloride 100 mg/kg via intramuscular injection). Tissues fixed in buffered 10% formalin for 24 h. Following routine procedures, the tissue samples were embedded in paraffin blocks. The sections 4 µm in thickness and were stained according to the Hematoxylin-Eosin (H&E) staining method and were examined under digital light microscope (Euromex). The slides were photographed.

DNA Extraction and PCR Amplification

The protozoan spores for positive control were obtained from the Department of Biology and Genetics, University of Veterinary Medicine in Kosice, Slovakia. The DNA extraction procedures for the spore and sample were run in parallel. Samples of aqueous humor and lens material were taken from the affected rabbit's eye during postmortem examination. Next, suitable specimens were homogenised with a ceramic bead in phosphate buffered saline (PBS) solution under sterile conditions. Subsequently, this suspension of PBS (200 µL) was exposed to mechanical microwave (600 W) disruption three times for 20 sec each. At this time, for the DNA extraction, tissue lysis buffer (Qiagen, Hilden, Germany) and 25 µL proteinase K (25 mg/mL) were used, and the specimens were incubated for one h at 56°C. Then, the specimens were processed in accordance with the manufacturer's instructions. In the last step of DNA purification, water was used to resuspend the DNA to use in PCR. The specific primer pairs ECUNF (5'-ATG AGA AGT GAT GTG TGT GCG-3') and ECUNR (5-TGC CAT GCA CTC ACA GGC ATC-3') were used for the amplification of 550-base pair (bp) small subunit ribosomal RNA product^[9]. The standard PCR protocol was performed as described previously by Valencakova et al.^[9]. The DNA yield obtained in a PCR reaction was analysed by electrophoresis in 1% agarose gel and stained with ethidium bromide.

DNA Sequence and Phylogenetic Tree

In accordance with the manufacturer's instructions, PCR amplicons were sequenced using the BigDye Terminator v3.1 Cycle Sequencing Kits (Applied Biosystems, Foster City, CA, USA) on the ABI PRISM 3700 Genetic Analyzer (Applied Biosystems). The phylogenetic tree was constructed using the neighbour-joining method with MEGA 4.0 software with the sequences chosen from GenBank records. The result of sequence analysis also verified DNA sequence data of the protozoan parasite by Basic Local Alignment Search Tool software (BLAST) analysis.

RESULTS

Animals and Clinical Evaluation

Feed and water consumption of the animals and general health conditions were normal. No neurological clinical signs and no mortalities were seen because of the parasite, however, ocular lesions with a visible white mass in nine rabbits was observed during clinical examination.

Histopathological Evaluation

One of nine animals showing ocular lesions was examined histopathologically to determine the damage in the eye and make a definite diagnosis of the infection. For this reason, the routine method was used to open the skull. Then, eye globes were removed from the orbital fossa based on techniques used for the species and cleaned from peripheral ligaments and other tissues. The changes in the outside and inside of eye globes were examined according to general macroscopic evaluation criteria. The sagittal sections of whole eyes were cut into sections and mounted with a nonaqueous mounting medium.

According to result of histopathological examination, ocular discharge, shown by a yellowish colour and corneal opacity, was predominant in the left eye. The contralateral eye was observed to be normal in terms of opacity. In gross examination, corneal opacity was predominant in the left eye, in which the iris could not be detected due to opacity in contrast to the contralateral eye (Fig. 1A). In this animal, after sagittally sectioning the right eye globe, iridocorneal sites appeared normal, although corneal thickness was increased in the left eye. The lens was also opaque in appearance and partially emulsified from the central side (Fig. 1B). Other lesions were increased in corneal thickness in the left eye section. However, there were no other findings except corneal and lens lesions in both eye globes. Histopathologically, the anterior capsules of the ocular lens partially lost their lens epithelial cells (LECs) and were surrounded by a thick capsule. In particular, the central LECs were degenerated and disorganized. Many *E. cuniculi* parasites were attached to the anterior lens capsule and the capsule was ruptured or thinned in some areas (Fig. 1C). The change in the left eye was diagnosed as cataract. Another prominent lesion was subacute keratitis.

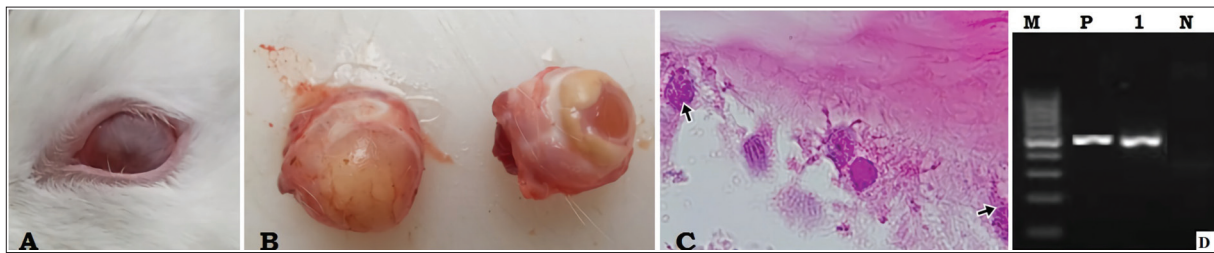


Fig 1. A- Clinical view of corneal opacity in left eye, B- After removing of eye bulbs, fully covered corneal opacity in the left eye, C- *Encephalitozoon cuniculi* spores (arrows) and rupture in fibrous lens capsule, D- Polymerase chain reaction was conducted on eye specimen of the rabbit using specific primer pairs. The sample was generated amplicons approximately 550 bp. In lanes 1, DNA sequences of amplicons produced and verified as *E. cuniculi* genotype I based on BLASTn analysis. Molecular weight (100bp repeat) ladder (M); Positive *E. cuniculi* control (P); Negative control (N)

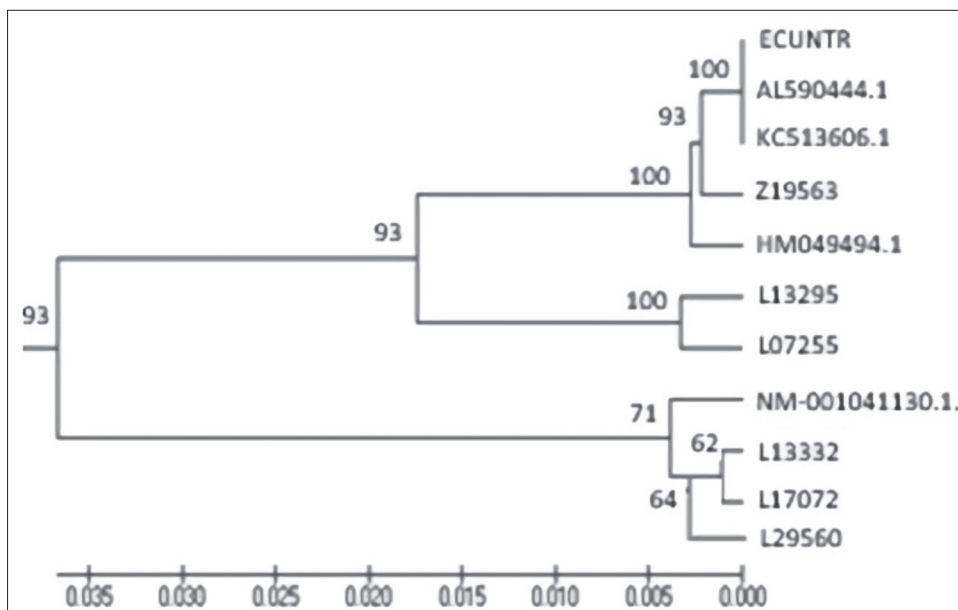


Fig 2. The phylogenetic tree was constructed with our sequence data (ECUNTR) from the NCBI database (L13295; L29560; L17072; L13332; L07255; Z19563; KCS13606.1; HM049494.1; AL590444.1 and NM-001041130.1)

Bowman's capsule and Descemet's membranes had lost their epithelial integrities. The stroma showed numerous neutrophils and mononuclear cell infiltrations, including macrophage and lymphocyte infiltrations. However, there were no parasitic infestations here.

Molecular Evaluation

In the present study, ECUNF and ECUNR species-specific primer pairs were used for amplification and genotyping of *E. cuniculi*. The sizes of fragments of the PCR products were compared using the standard 100 bp DNA ladder. Electrophoresis showed that the amplified products had 550 bp in *E. cuniculi* (Fig. 1D). Database homology searching was performed with BLAST software (available in the public domain at https://blast.ncbi.nlm.nih.gov/Blast.cgi?PROGRAM=blastn&PAGE_TYPE=BlastSearch&LINK_LOC=blasthome). Furthermore, the partial DNA sequence was sequenced to BLASTn analysis, and blasted with *E. cuniculi* (GenBank accession numbers L13295; L29560; L17072; L13332; L07255; Z19563; KC513606.1; HM049494.1; AL590444.1 and NM-001041130.1) and identified as genotype I. The phylogenetic tree was constructed with DNA sequences from the NCBI database. The phylogenetic tree was constructed using the neighbour-joining method and the percentage of replicate trees in which the associated taxa clustered together in the bootstrap test (1000 replicates) is shown Fig. 2. Our sequence data (ECUNTR-550 bp) was blasted with *E. cuniculi* (GenBank accession numbers KC513606.1, HM049494.1 and NM-001041129.1). In addition to the sequence data blasted 99% homology with accession numbers AL590444.1 and NM-001041130.1 (Fig. 2).

DISCUSSION

Four decades ago, the first record related to *E. cuniculi* was reported accidentally and characterised by focal granulomas in the brain of rabbits in Turkey [7]. In later years, the infection was identified serologically and histopathologically using diagnostic methods in rabbits [10]. This eukaryotic organism can be found in renal, eye and central nervous tissues of infected rabbits [6,12]. Transmission of the parasite occurs through the ingestion or inhalation of spores present in secretions or body exudates and transplacentally [11]. In the kidney, infection is usually asymptomatic. In the eye, this agent causes damage to the lens, causing phacoclastic uveitis, loss of vision, hypopyon and cataracts, particularly in cases of transplacental transmission [10,12-14].

In this study, the prominent lesions are seen in lens tissue, but how parasites access and infest the tissue could not fully be elucidated. In fact, an adult lens tissue comprises lens LECs and a thick fibrous capsule. Therefore, this avascular tissue does not permit infections in older animals. However, animals can be infected in utero (during the course of lens development) and in the early period of

life, and parasites can settle on the thinner capsule with a richer vascular structure on the lens. As the animal grows (getting) older, the lesions can develop progressively in the lens. As a result of the infestation, cataract, uveitis and hypopyon can occur. Uveitis usually occurs as a result of spontaneous rupture of the anterior lens capsule after lens material, including proteins, is released into the anterior chamber. Cataracts also can develop as a result of disruption of the lens fibres. This situation frequently leads to granulomatous uveitis and a posterior synechia [11-14]. In particular, phacoclastic uveitis progresses in the intraocular lesions secondary to lens rupture in animals infested with *E. cuniculi* [12-14]. However, in our study, phacoclastic uveitis was not seen although lens fibre disorganisation and parasitic attachments on the thinned lens capsule. There were only focal lens ruptures in relation to disorganized fibrous structure and degenerated or necrotic LECs.

This situation was commented as progression of the infestation in the eye and being found initial or middle stage during ocular infestation. It was reported that ongoing stages of parasitic infestation, the lens materials in fibres lost their integrities. On the other hand, granulomatous inflammation in the affected ruptured area in the lens and uvea could be seen easily. Mainly, granulocytes, macrophages and foreign body giant cells cause the rupture of the lens capsule. In addition, plasma cells and lymphocyte infiltrations can develop in the iris and ciliary body. Diffuse lens fibre necrosis and degeneration and posterior lens epithelial cell migration can occur [11-13].

In our study, there was no granulomatous reaction in lens but only some granulocytes and macrophage infiltrations in the ruptured area. Sometimes, granulocytes and macrophages infiltrate fully into the posterior chamber and cause a series of results, including anterior iris displacement, anterior lens luxation, anterior synechia, and secondary corneal lesions in relation to endothelial-epithelial necrosis or ulceration and stromal thinning and focal corneal perforation in some cases [13,14].

In the present study, endothelial and epithelial integrities were lost in some areas. In addition, Bowman's capsule and Descemet's membranes lost their epithelial integrities. The stroma showed numerous neutrophils and mononuclear cell infiltrations, including macrophage and lymphocyte infiltration. Neither stromal thinning nor any perforation in the cornea was encountered. In contrast to this finding, there was focal thickness in some areas due to inflammatory infiltration. Another outstanding finding is the lack of any parasitic infestation in the cornea. Therefore, we believe that corneal lesions can be resourced from secondary lesions after lens lesions. And, parasitic infestation was not evaded to cornea although lesions in the eye were found in initial or middle stage of progressive infestation.

Encephalitozoon cuniculi may be a possible reason for the ocular lesions, such as a visible white mass in the eye,

cataract and uveitis. Therefore, a clinician can observe ocular lesion formations in rabbits during daily inspection or ophthalmological examination. Presently, PCR has been accepted as a highly specific and sensitive molecular diagnostic tool for the detection of *E. cuniculi* spores^[4,10]. Even though our previous study (unpublished data) reported on ocular lesions due to the infection, to our knowledge there has been no report on the molecular diagnosis of the parasite to date in Turkey. Therefore, this is the first report on the the detection of *E. cuniculi* spores using PCR in Turkey. The partial DNA sequence (ECUNTR-550 bp) was matched 100% homology with *E. cuniculi* (GenBank accession numbers KC513606.1, HM049494.1 and NM-001041129.1) whereas the ECUNTR sequence blasted 99% homology with accession numbers AL590444.1 and NM-001041130.1 (Fig. 2). The homology between our sequence data (ECUNTR) and the GeneBank sequences confirmed the presence of *E. cuniculi* and verified it as genotype I.

In conclusion, the present study is the first report on the molecular diagnosis of the parasite in Turkey. Particularly eye affected from the parasite, therefore, clinicians are considered *Encephalitozoon cuniculi* as one of the possible causes of ocular lesion formation in rabbits.

CONFLICT OF INTEREST

We declare that we have no conflict of interest.

ACKNOWLEDGMENTS

We would like to thank Prof. Valenckova for providing *E. cuniculi* spore samples.

REFERENCES

1. Pelin A, Moteshareie H, Sak B, Selman M, Naor A, Eyahpaise MÈ, Farinelli L, Golshani A, Kvac M, Corradi N: The genome of an *Encephalitozoon cuniculi* type III strain reveals insights into the genetic diversity and mode of reproduction of a ubiquitous vertebrate pathogen. *Heredity*, 116 (5): 458-465, 2016. DOI: 10.1038/hdy.2016.4
2. Reetz J, Nöckler K, Reckinger S, Vargas MM, Weiske W, Broglia A: Identification of *Encephalitozoon cuniculi* genotype III and two novel genotypes of *Enterocytozoon bieneusi* in swine. *Parasitol Int*, 58 (3): 285-292, 2009. DOI: 10.1016/j.parint.2009.03.002
3. Talabani H, Sarfati C, Pillebout E, Van Gool T, Derouin F, Menotti J: Disseminated infection with a new genovar of *Encephalitozoon cuniculi* in a renal transplant recipient. *J Clin Microbiol*, 48, 2651-2653, 2010. DOI: 10.1128/JCM.02539-09
4. Csokai J, Joachim A, Gruber A, Tichy A, Pakozdy A, Künzel F: Diagnostic markers for encephalitozoonosis in pet rabbits. *Vet Parasitol*, 163 (1-2): 18-26, 2009. DOI: 10.1016/j.vetpar.2009.03.057
5. Berkin S, Kahraman MM: Türkiye'de tavşanlarda *Encephalitozoon (Nosema) cuniculi* enfeksiyonu. *Ankara Univ Vet Fak Derg*, 30, 397-406, 1983. DOI: 10.1501/Vetfak_0000000181
6. Eroksuz Y, Eroksuz H, Metin N, Ozer H: Morphologic examinations of cases of naturally acquired encephalitozoonosis in a rabbit colony. *Turk J Vet Anim Sci*, 23, 191-195, 1999.
7. Eroksuz H, Eroksuz Y, Ozer H, Cevik A, Unver O: A survey of *Encephalitozoon cuniculi* infection in rabbit colonies in Elazığ, Turkey: pathomorphologic and serologic (Carbonimmunoassay test) studies. *Isr J Vet Med*, 54 (3): 73-77, 1999.
8. Ozkan O, Ozkan AT, Karaer Z: Encephalitozoonosis in New Zealand rabbits and potential transmission risk. *Vet Parasitol*, 179 (1-3): 234-237, 2011. DOI: 10.1016/j.vetpar.2011.02.007
9. Valencáková A, Bálent P, Novotný F, Cisláková L: Application of specific primers in the diagnosis of *Encephalitozoon* spp. *Ann Agric Environ Med*, 12 (2): 321-323, 2005.
10. Künzel F, Fisher PG: Clinical signs, diagnosis, and treatment of *Encephalitozoon cuniculi* infection in rabbits. *Vet Clin North Am: Exot Anim Pract*, 21 (1): 69-82, 2018. DOI: 10.1016/j.cvex.2017.08.002
11. Baneux PJR, Pognan F: In utero transmission of *Encephalitozoon cuniculi* strain type I in rabbits. *Lab Anim*, 37, 132-138, 2003. DOI: 10.1258/00236770360563778
12. Williams D: Rabbit and rodent ophthalmology. *EJCAP*, 17 (3): 242-252, 2007.
13. Giordano C, Weigt A, Vercelli A, Grilli M, Giudice C: Immunohistochemical identification of *Encephalitozoon cuniculi* in phacoclastic uveitis in four rabbits. *Vet Ophthalmol*, 8, 271-275, 2005. DOI: 10.1111/j.1463-5224.2005.00394.x
14. Jeklova E, Leva L, Kovarcik K, Matiasovic J, Kummer V, Maskova J, Skoric M, Faldyna M: Experimental oral and ocular *Encephalitozoon cuniculi* infection in rabbits. *Parasitology*, 137 (12): 1749-1757, 2010. DOI: 10.1017/S0031182010000648