

Laparoscopic treatment of morgagni hernia: Two case reports

 Emrah Akin,¹  Fatih Altıntoprak,²  Muhammet Burak Kamburoğlu,²

 Metin Ertem,³  Fehmi Çelebi²

¹Department of General Surgery, Sakarya Training and Research Hospital, Sakarya, Turkey

²Department of General Surgery, Sakarya University Faculty of Medicine, Sakarya, Turkey

³Department of General Surgery, Cerrahpasa Faculty of Medicine, Istanbul, Turkey

ABSTRACT

Morgagni hernias account for only 2–3% of all diaphragmatic hernias, and most of them (91%) are right-sided. Most Morgagni hernias are diagnosed in childhood, but rarely diagnosis may be late because they can be asymptomatic or present nonspecific-nonrespiratory symptoms. Thus, Morgagni hernia diagnosis is incidental in the majority of adulthood cases. The defect arises from a fusion failure of the diaphragm with the central arches. Surgery is the main treatment modality of the Morgagni hernia due to defect enlargement and strangulation- incarceration risks. In this paper, we present two Morgagni hernia cases treated with laparoscopic surgery. Minimal invasive techniques can be used in Morgagni hernia with all advantages.

Keywords: Laparoscopy; morgagnihernia; minimallyinvasivesurgery.

Introduction

Diaphragmatic hernias are rare abdominal hernias and they can be congenital or posttraumatic. Morgagni hernia accounts for only 2–3% of all diaphragmatic hernias and its 91% right, 5% left side, and only %4 are bilateral of the sternum through of a muscle free space.^[1] Antero-medial diaphragmatic defect was first described by an Italian anatomist and pathologist Giovanni Batista Morgagni^[2] in his 1769 treatise “the sets and causes of diseases investigated by anatomy”. Due to most Morgagni hernias are diagnosed and repaired in childhood, only 5% are diagnosed in adults. Also, adult Morgagni hernias are diagnosed too late due to the fact that they may be asymptomatic or may be present non-respiratory symptoms. Various surgical approaches have been described in the literature including

thoracic repairs by way of median sternotomy, thoracotomy, thoracoscopy in addition to abdominal approaches via laparotomy and laparoscopy.^[3] There seems to be no consensus on the best technique but after the first laparoscopic repair reported by Kuster et al.^[4] in 1992, now minimal invasive technique is started to became gold standard.

In this paper, we aimed that present and share of technical details of laparoscopic Morgagni hernia repair.

Case Report

Case 1 – 71 year old female patient was admitted the emergency service with the complaints of sudden onset abdominal pain and dyspnea. The patient had no previous abdominal surgery and abdominal trauma history. In



Received: 27.07.2019 Accepted: 17.02.2020

Correspondence: Emrah Akin, M.D., Department of General Surgery,
Sakarya Training and Research Hospital, Sakarya, Turkey
e-mail: emrahakin@sakarya.edu.tr



This work is licensed under a Creative Commons Attribution-NonCommercial 4.0 International License.

physical examination, there was only mildly tenderness on upper abdominal region. Laboratory parameters were normal. Intrathoracic colonic hydro-aero levels were detected on chest X-Ray (Fig. 1).

On abdominal computed tomography (CT), a right-sided Morgagni hernia was seen and hernia defect was containing transverse colon and omentum without signs of strangulation. Laparoscopic treatment was planned. After creating pneumoperitoneum with Veress needle, 3 port were placed in direct vision (two 10 mm and one 5 mm). In laparoscopic exploration, a right sided diaphragmatic defect was detected, transverse colon and omentum were detected into the hernia defect and these were reduced to the abdominal cavity. Hernia sac was not removed and diaphragmatic defect was closed with intermittent extra-abdominal trans fascial 2/0 non-absorbable sutures via endoclose® (Fig. 2). Sutures passed intermittent vertical mattress distanced 1 to 2 cm cranio-caudal axis and hernia defect was closed. Knots were tied extra-corporeally so laid in the subcutaneous tissue.

No appropriate material was used, no need to the drain application. Oral intake was started postoperative 6.

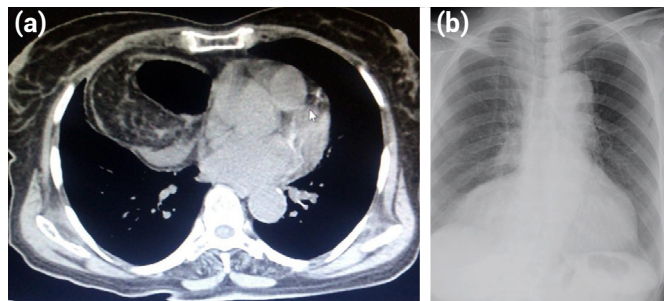


Figure 1. (a) A right sided Morgagni hernia on abdominal CT. (b) Colonic hydro-aero levels on chest X-Ray.

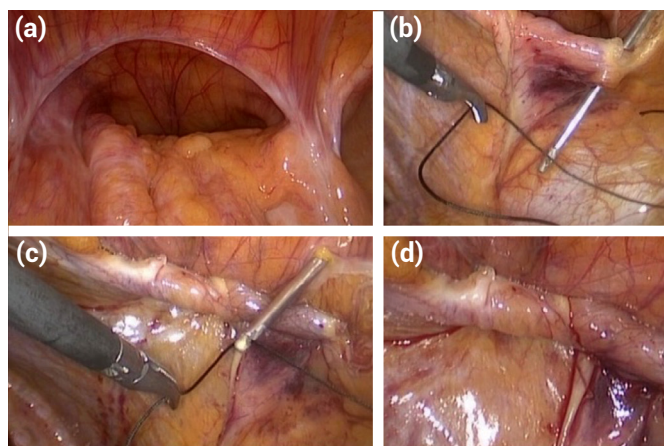


Figure 2. Stages of trans fascial extra-abdominal hernia defect closing (a) hernia defect (b) suture passing (c) Endoclose® suture catcher (d) After defect closed.

hours, and the patient was discharged on postoperative 1.day uneventfully. There were no complications at 6 month follow up.

Case 2 – 56 year old male patient was admitted to general surgery policlinic with the complaints of gastro-esophageal reflux and pyrosis symptoms. The patient had no previous abdominal surgery and abdominal trauma history. Physical examination and laboratory parameters were normal. In upper gastrointestinal system endoscopy we have seen cardia-esophageal insufficiency and laparoscopic surgery was planned because of sliding hiatal hernia diagnosis. After creating pneumoperitoneum with Veress needle, laparoscopic exploration was performed and detected bilateral Morgagni hernia at anterior diaphragmatic rim incidentally. A 10 mm and 5 mm trocar was applied with direct vision and the omentum and the transvers colon gently released and pulled back to the abdominal cavity (Fig. 3a, b). Diaphragmatic defect was exposed and hernia sac was nor excised. Hernia defects measured about 13x10 cm and the decision was closing the defect with 15x20 cm dual mesh. Intracorporeal 2/0 polypropylene sutures and absorbable tacks used to fix material to diaphragm (Fig. 3c, d). There is no need to the drain application. Oran intake was started postoperative 6. hours and the patient was discharged on postoperative 1. day uneventfully. There were no complications at 9 month follow up.

Discussion

Radiologic methods play an important role in the diagnosis of Morgagni hernia and abdominal CT examinations give detailed information:^[5] However, since Morgagni hernias

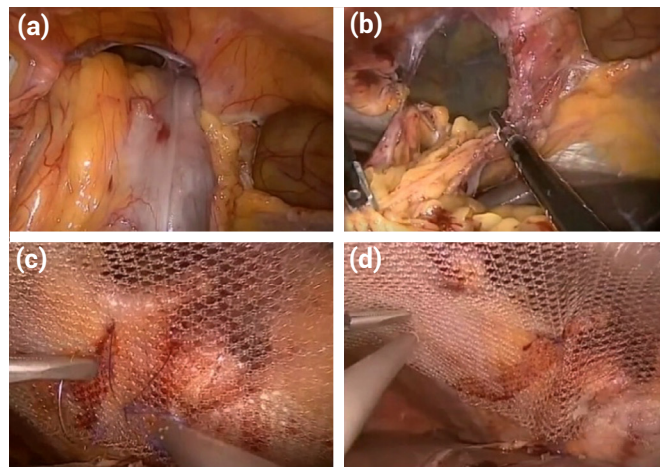


Figure 3. Stages of closing bilateral antero-medial hernia defect with mesh (a) Transverse colon in hernia (b) After colonic reduction (c) Fixed mesh with suture (d) Fixed mesh with tack.

can be asymptomatic, they can be detected incidentally during abdominal exploration in patients who are scheduled for surgery due to another pathology.^[6] Tarcoueanu et al.^[7] reported that 5 of 8 cases were detected as incidental. We detected the disease in the first case abdominal CT scan that is major importance in diagnosis confirmation and allowing a good anatomical detail and also in the second case had no symptoms associated with Morgagni hernia in the perioperative period and was noticed incidentally during intraoperative abdominal exploration.

Open methods have been used for many years for repair of Morgagni hernia, but with the development of minimally invasive surgical techniques, laparoscopic or thoracoscopic methods have become more prominent in recent years.^[8] Young et al.^[9] reported 43 patients results retrospectively and they showed that laparoscopy, laparotomy and thoracotomy was similar about surgical results and recurrent rate. Hernia sac excision and closure techniques of defect closure were also discussed in the literature. Primary repair with non-absorbable suture or the use of appropriate material are both valid options reported in worldwide literature. Horton et al reported 298 cases with Morgagni hernias, 46 of them treated laparoscopically and they described 29% primary repair, 31% resection of hernia sac and 64% had mesh graft interposition in the article.^[10] There are no data available supporting better results after hernia sac excision in fact removing it can result circulatory and respiratory complications. We didn't exclude hernia sac in both cases.

Morgagni hernia does not include an anterior rim so defect closure may be difficult as technically. So that there have been produced two different solutions; fixation of the posterior rim of the diaphragm with intracorporeal sutures to the anterior abdominal wall muscles or with full-thickness extra abdominal sutures to the anterior abdominal wall.^[11] With a separated or continuous suture small defects can be easily repaired, but bigger defects can be treated with only a mesh or combination of two options is also possible. The main goal of this procedures is achieve tension free repair. Since the defect in our first cases was unilateral and suitable for primary suture, whereas mesh repair was preferred because of bilateral defect.

Conclusion

Laparoscopic techniques are safe and useful for treatment of Morgagni hernia due to contain all advantages of minimal invasive surgery.

Disclosures

Informed Consent: Written informed consent was obtained from the patient for the publication of the case report and the accompanying images.

Peer-review: Externally peer-reviewed.

Conflict of Interest: None declared.

Authorship Contributions: Concept – E.A.; Design – E.A.; Supervision – F.Ç.; Materials – M.E.; Data collection &/or processing – B.K.; Analysis and/or interpretation – M.E.; Literature search – E.A.; Writing – E.A.; Critical review – F.C.

References

- HARRINGTON SW. Clinical manifestations and surgical treatment of congenital types of diaphragmatic hernia. *Rev Gastroenterol* 1951;18:243–56.
- Morgagni GB. *The Seats and Causes of Diseases Investigated by Anatomy*. Vol 3. London, England: Millar&Caddell; 1769. p. 205.
- Hassan A, Alabdrabalmeeer M, Alealiwi M, Danan OA, Alshomimi S. Incidental Morgagni hernia found during laparoscopic repair of hiatal hernia: Case report & review of literature. *Int J Surg Case Rep* 2019;57:97–101.
- Kuster GG, Kline LE, Garzo G. Diaphragmatic hernia through the foramen of Morgagni: laparoscopic repair case report. *J Laparoendosc Surg* 1992;2:93–100.
- Sutro WH, King SJ. Computed tomography of Morgagni hernia. *N Y State J Med* 1987;87:520–1.
- Costa Almeida C, Caroço TV, Nogueira O, Infuli A. Laparoscopic repair of a Morgagni hernia with extra-abdominal transfascial sutures. *BMJ Case Rep* 2019;12:e227600.
- Târcoveanu E, Georgescu Ş, Vasilescu A, Andronic D, Dănilă N, Lupaşcu C, et al. Laparoscopic Management in Morgagni Hernia - Short Series and Review of Literature. *Chirurgia (Bucur)* 2018;113:551–7.
- Soldo I, Baća I, Sever M, Zoričić I, Grbavac M, Troskot Perić R, et al. Laparoscopic Treatment of Morgagni Hernia: Report of Three Cases. *Acta Clin Croat* 2017;56:318–22.
- Young MC, Saddoughi SA, Aho JM, Harmsen WS, Allen MS, Blackmon SH, et al. Comparison of Laparoscopic Versus Open Surgical Management of Morgagni Hernia. *Ann Thorac Surg* 2019;107:257–61.
- Horton JD, Hofmann LJ, Hetz SP. Presentation and management of Morgagni hernias in adults: a review of 298 cases. *Surg Endosc* 2008;22:1413–20.
- Ryan JM, Rogers AC, Arumugasamy M. Reply to comment to: 'Technical description of laparoscopic Morgagni hernia repair with primary closure and onlay composite mesh placement.'. *Hernia* 2018;22:709–10.