

University of Texas Rio Grande Valley
ScholarWorks @ UTRGV

School of Medicine Publications and
Presentations

School of Medicine

11-2-2018

Emergency general surgery in pregnancy

Jeffrey J. Skubic

The University of Texas Rio Grande Valley

Ali Salim

Brigham and Women's Hospital

Follow this and additional works at: https://scholarworks.utrgv.edu/som_pub

 Part of the [Medicine and Health Sciences Commons](#)

Recommended Citation

Skubic JJ, Salim A Emergency general surgery in pregnancy *Trauma Surgery & Acute Care Open* 2017;2:e000125. doi: 10.1136/tsaco-2017-000125

This Article is brought to you for free and open access by the School of Medicine at ScholarWorks @ UTRGV. It has been accepted for inclusion in School of Medicine Publications and Presentations by an authorized administrator of ScholarWorks @ UTRGV. For more information, please contact justin.white@utrgv.edu, william.flores01@utrgv.edu.

Emergency general surgery in pregnancy

Jeffrey J Skubic, Ali Salim

Division of Trauma, Burn and Surgical Critical Care, Harvard Medical School, Brigham and Women's Hospital, Boston, Massachusetts, USA

Correspondence to

Ali Salim, Division of Trauma, Burn and Surgical Critical Care, Harvard Medical School, Brigham and Women's Hospital, Boston, MA 02115, USA; asalim1@bwh.harvard.edu

Received 25 July 2017

Revised 20 August 2017

Accepted 28 August 2017

SUMMARY

It is often that the acute care surgeon will be called on to evaluate the pregnant patient with abdominal pain. Most of the diagnostic and management decisions regarding pregnant patients will follow the usual tenets of surgery; however, there are important differences in the pregnant patient to be aware of to avoid pitfalls which can lead to complications for both mother and fetus. This review hopes to describe the most common emergencies facing the surgeon caring for the pregnant patient and the latest management options.

INTRODUCTION

There are more than 8000 urgent non-obstetrical surgical procedures performed each year, impacting up to 2% of all pregnancies.¹ The evaluation of the pregnant patient must weigh the risks and benefits of diagnostic methodology and therapy on the mother, and the fetus as well. Complicating care is the fact that the normal physiologic and anatomic changes that occur in pregnancy may make it difficult to interpret signs usually used in early diagnosis of emergency conditions. The delay in diagnosis and treatment of the surgical abdomen in the pregnant patient because of fear of unnecessary procedures and tests contributes to the high complication rate in this patient population. Attention to detail, heightened suspicion, serial physical examination, clinical awareness and systematic evaluation can help avert unnecessary maternal complications and fetal loss from emergency surgical conditions. This review will highlight the more common causes of the acute abdomen in pregnancy with suggested treatment options. Appropriate diagnostic tests or procedures should never be avoided or delayed simply because of pregnancy; never penalize a patient for being pregnant.

NORMAL PHYSIOLOGIC AND ANATOMIC CHANGES IN PREGNANCY

The physiologic changes that comprise maternal adaptation to pregnancy involve almost every organ system. The plasma volume in pregnancy increases by almost 50%, whereas the red cell mass increases by only 20%, resulting in the 'physiologic anemia of pregnancy'. It is not uncommon to see a baseline hematocrit of 31%–33%.² The increased plasma volume allows the pregnant patient to withstand a significant amount of blood loss before any overt manifestations of shock appear. Cardiac output increases beginning in the second trimester. Uterine blood flow also increases as the fetus grows, comprising 20% of cardiac output by term. This system is highly regulated and extremely sensitive to external agents such as catecholamine

and maternal intravascular volume loss. Maternal hemorrhage can be compensated by decreased uterine flow. Maternal hypovolemia may be marked by fetal distress before any evidence of maternal tachycardia or hypotension is present.

Oxygen consumption and resting ventilation increase in pregnancy as a result of an increase in tidal volume caused by rising progesterone levels. This results in a respiratory alkalosis with a pCO₂ of approximately 30 mm Hg and a metabolic compensation with bicarbonate levels in the 19–20 mEq/L range.³ Gastrointestinal motility is decreased, and in addition to the reduction in resting lower esophageal pressure, pregnant patients are more likely to experience gastroesophageal reflux and have an increased risk of aspiration with general anesthesia.

Hematologically, in addition to the decrease in hemoglobin levels seen from the physiologic anemia, there is a relative leukocytosis. Typically, the white cell count will range from 12 000/mm³ to 15 000/mm³ and can reach as high as 25 000/mm³, often complicating the diagnosis of infection.³ The state of relative hypercoagulability in pregnant patients is well known to increase the risk for thromboembolic complications.⁴

Anatomically, the uterus becomes an intra-abdominal organ at approximately 12 weeks of gestation. At 20 weeks the uterus can be palpated at the umbilicus, and by 36 weeks the uterus reaches the costal margin. The growing uterus can complicate invasive procedures such as port placement in laparoscopic surgery. As the uterus enlarges, maternal organs are displaced upwards; in the late stages of pregnancy the majority of the gastrointestinal tract may be found above the inferior costal margins. The diaphragm may also be elevated by as much as 4 cm. Finally, as the pregnancy progresses, uterine compression of the vena cava decreases venous return, resulting in a 30% drop in cardiac output. This 'supine hypotensive syndrome' can be alleviated by displacing the uterus from the vena cava by positioning the patient in the left lateral decubitus position or at least placing pillows under the patient's right side to elevate it slightly.⁴

Pregnancy is associated with reduced ureteral tone and peristalsis, which can lead to a dilated ureter and hydronephrosis. This is due in part to mechanical compression on the ureters as the uterus enlarges, with the rate of right-sided hydronephrosis significantly higher than the left side.⁵ These changes can lead to infection or urolithiasis.⁶

RADIOLOGICAL ISSUES IN THE PREGNANT PATIENT

The key concern regarding imaging during pregnancy is the effect of ionizing radiation on the growing fetus. The risks of radiation include fetal

To cite: Skubic JJ, Salim A. *Trauma Surg Acute Care Open* 2017;**2**:1–5.

death, growth retardation, microcephaly, malformations, mental retardation and childhood cancers.⁷ Knowledge of the effects of radiation on fetal development has been extrapolated from animal studies and observations of exposed human populations, particularly those of Hiroshima and Nagasaki.^{8,9} While the American College of Obstetricians and Gynecologists states that exposure of <5 rads has not been associated with an increase in fetal anomalies or pregnancy loss,¹⁰ clinically, the fetal dose of concern for teratogenesis is probably in the range of 10–20 rads.¹¹ When deciding on the appropriate workup for any pregnant patient, always remember the principle that a ‘pregnant patient should not be penalized for being pregnant’.

A typical ‘PanScan’ (CT imaging of the head, cervical spine, chest, abdomen and pelvis) usually delivers <5 rads. An abdominal CT scan can be performed to evaluate abdominal pathology with only 0.3 rads.⁷ Ultrasound is useful in identifying appendicitis, cholecystitis and free fluid after abdominal trauma, and poses no known risk to the growing fetus. MRI is emerging as a useful test to evaluate the abdomen in pregnant patients.^{12,13}

Radiation exposure during endoscopic retrograde cholangiopancreatography (ERCP) can be reduced to a level significantly below 5 rads. In several series that measured the amount of radiation exposure during ERCP, pregnant patients were exposed to anywhere from 0.04 to 0.18 rads, without any short-term complications to the pregnancy and newborns.^{14,15} There has been noted to be a clear correlation between the lengths of fluoroscopy time with radiation exposure. Precautions such as using lead shielding (placed underneath the pregnant patient), maximizing distance between the patient and the X-ray source, and decreasing fluoroscopy times are recommended to minimize exposure.¹⁶ The technique of ERCP without using any radiation for pregnant patients has been described.¹⁷ Magnetic resonance cholangiopancreatography (MRCP), choledochoscopy and endoscopic ultrasound have all been used to confirm clearance of the biliary system without the use of radiation following ERCP.¹⁸

LAPAROSCOPY IN PREGNANCY

Laparoscopy has emerged as a diagnostic and therapeutic tool in the care of the pregnant patient with abdominal pain.¹⁹ Laparoscopy is well tolerated by both mother and fetus with minimal adverse effects in all trimesters.^{20,21} Although a 2012 meta-analysis of 11 studies found low-grade evidence that laparoscopic compared with open appendectomy was associated with a higher rate of fetal loss,²² a more recent Nationwide Inpatient Sample study of 20 000 patients found a three times higher risk of an adverse obstetrical outcome associated with open surgery.²³ Our preference is to favor the laparoscopic approach as long as it appears safe for trochar insertion depending on the body habitus and degree of pregnancy. Open trochar placement (Hasson technique) or insertion of the Veress needle into an alternate site (Palmer’s point) is recommended to avoid injury to the uterus during entry.^{24,25} Palmer’s point is described in the left upper quadrant, 3 cm below the costal margin in the midclavicular line.²⁶ In the late second trimester and beyond, laparoscopy becomes technically difficult and an open incision (vertical or over the point of maximal tenderness) can be used. The surgeon should avoid manipulation of the uterus during the procedure. Immediate preoperative and postoperative fetal monitoring should be used in all viable pregnancies of 24 weeks and older.^{27,28}

ACUTE ABDOMEN IN THE PREGNANT PATIENT

Approximately 1 in 635 women require non-obstetrical abdominal surgery during pregnancy.²⁹ Making the diagnosis is often

problematic for the following reasons: the expanding uterus, which displaces other intra-abdominal organs and thus makes physical exam difficult³⁰; the high prevalence of nausea, vomiting and abdominal pain routinely encountered in the normal obstetric patient³¹ and the general reluctance to operate unnecessarily on a gravid patient.¹ Acute appendicitis and cholecystitis are the most common non-obstetrical emergencies requiring surgery during pregnancy.²⁴

Appendicitis

A case of acute appendicitis during pregnancy was first reported in the literature by Hancock in 1848.³² It is the most common non-obstetric surgical emergency during pregnancy.¹ It occurs in about 1 in 1000–2000 pregnancies and may occur at any time during the pregnancy.^{33–35} The diagnosis is more frequently missed in pregnant than in non-pregnant patients, because signs and symptoms of appendicitis, such as leukocytosis, nausea and vomiting, are also commonly seen during pregnancy. There is a question of reliability of the abdominal examination in pregnant patients suspected of having appendicitis. The classical teaching is that the location of pain from appendicitis moves progressively upward as the pregnancy progresses based on Baer’s 1932 study of barium images of 78 pregnant patients.³⁶ More recent retrospective studies have failed to corroborate this hypothesis showing roughly 90% of patients having pain in the right lower quadrant regardless of trimester.^{37,38} Maternal morbidity is usually the result of a delay in diagnosis. Fetal loss occurs in 3%–5% of pregnant patients without perforation but can be as high as 36% with perforation.³⁵ This high risk of fetal loss with perforation along with the difficulty of diagnosing appendicitis in the pregnant patient explains the high rate (50% in many series) of normal appendices found at operation.³⁹ Traditionally, this high rate of negative operation had not been found to increase maternal or fetal morbidity; however, recent data suggest that negative appendectomy may be associated with an increase in fetal loss.^{40,41} Therefore, it is important to confirm the diagnosis before heading to the operating room. Ultrasound, CT, MRI or diagnostic laparoscopy can confirm the diagnosis. Ultrasound should be the first-line study for abdominal pain in the pregnant female; however, the sensitivity ranges from only 20% to 36%. If ultrasound is indeterminate, the next study that should be ordered if available is an MRI. A review of imaging strategies for right lower quadrant pain in pregnant females performed a meta-analysis of six studies examining the role of MRI in diagnosing appendicitis in pregnant females. They found a pooled sensitivity of 0.91 and a specificity of 0.98.⁴² If MRI is unavailable, a CT may be ordered. While the diagnostic accuracy of CT for appendicitis in the non-obstetric population has been well demonstrated,⁴³ there is a paucity of data for pregnant females. Two small studies looking specifically at pregnant patients demonstrated successful diagnoses of appendicitis in 5/7 patients and 12/13 patients.^{44,45} Protocols involving abdominal ultrasound followed by CT scan, if inconclusive, have been associated with a reduction of negative appendectomy rates.³⁹ Our diagnostic algorithm for appendicitis is shown in [figure 1](#). Appendectomy can be performed open or laparoscopically²⁰ depending on the surgeon’s comfort level with the patient’s body habitus and degree of pregnancy. The laparoscopic approach has advanced to become the standard of care at many centers; this is the authors’ preference as well.

Gallbladder disease

Biliary tract disease is the second most common non-obstetric surgical problem.¹ Weight gain and hormonal changes

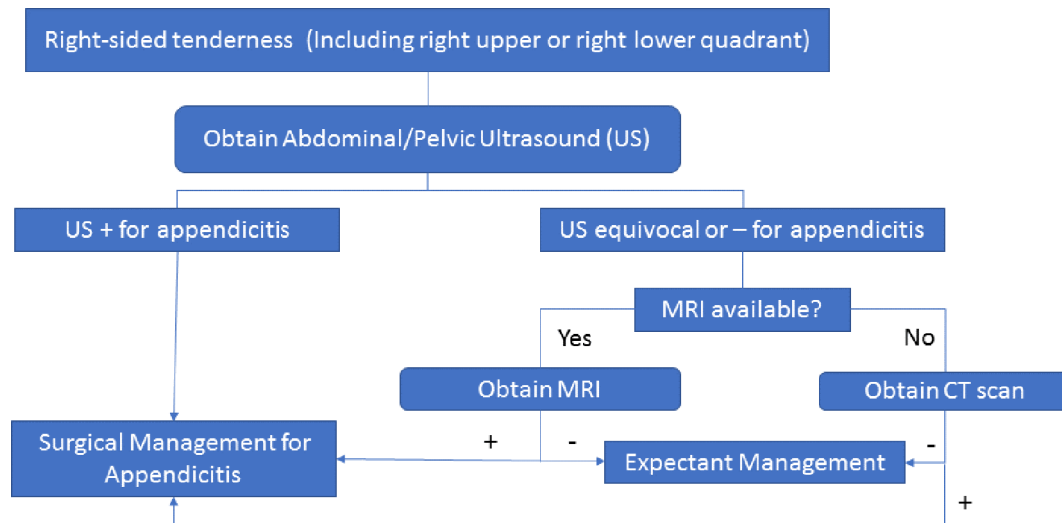


Figure 1 This algorithm is our suggested diagnostic workup for a pregnant patient with a suspected diagnosis of appendicitis.

predispose pregnant women to biliary sludge and gallstone formation. Weakened contractions and decreased emptying lead to increased gallbladder volume during fasting and postprandially. Biliary stasis contributes to cholesterol crystal sequestration, theoretically leading to formation of sludge and stones. Estrogen increases bile lithogenicity, whereas progesterone impairs gallbladder emptying.⁴⁶ Lower gallbladder ejection fractions and increasing parity appear to increase the risk of sludge formation.⁴⁷ The reported incidence of biliary sludge formation is as high as 31%, while gallstone formation ranges from 3% to 12%.^{48 49} A total of 1 in 1000 pregnancies will develop symptoms related to biliary colic.^{50 51} About one-third of patients with biliary colic will experience no additional bouts during the following 2 years. Unfortunately, approximately 80% of pregnant women presenting with symptoms will have recurrence of symptoms with 20%–40% recurring prior to delivery.^{52 53} This recurrence is often more severe than the initial presentation. Surgical intervention is indicated for obstructive jaundice, acute cholecystitis and gallstone pancreatitis. Where once the non-operative management with delayed cholecystectomy of symptomatic cholelithiasis was encouraged,^{54–58} there are data now suggesting that pregnant patients with symptomatic cholelithiasis should undergo cholecystectomy early due to the increase in the rate of recurrent hospitalizations, preterm deliveries, spontaneous abortions and fetal morbidity associated with non-operative management.^{21 59} In addition, non-operative management of symptomatic cholelithiasis increases the risk of gallstone pancreatitis up to 15%.⁵³ Whereas once it was thought that the second trimester was the optimal time for cholecystectomy due to decreased spontaneous abortions and preterm labor, there is a growing body of evidence that suggests laparoscopy can be performed in all trimesters with equal safety.^{20 21}

Cholangitis

Cholelithiasis in pregnancy is infrequent and is estimated to be around 1 in 1200 deliveries⁶⁰; however, therapeutic intervention is almost always required.⁶¹ The diagnosis of choledocholithiasis is similar in both pregnant and non-pregnant patients; fever, leukocytosis, abdominal pain, hyperbilirubinemia and elevated alkaline phosphatase, with or without shock suggests the diagnosis of cholangitis.⁶² While Charcot's original triad has been shown to be 95% specific for cholangitis, it is only 26% sensitive for the disease. The Tokyo guidelines for diagnosing

cholangitis first published in 2007 and revised in 2012 have much higher sensitivities (83% and 92%, respectively).^{63 64} Intravenous resuscitation and broad-spectrum antibiotics should be started immediately on suspicion of the diagnosis. Ultrasonography can detect common bile duct stones but only at a 30% sensitivity.^{65 66} If there is uncertainty in the diagnosis, MRCP seems to be an excellent diagnostic modality in pregnancy.⁶⁷ It is not associated with any known adverse fetal effects and can be used in all stages of pregnancy.⁶⁸

Endoscopic treatment of choledocholithiasis is presently the treatment of choice in pregnant patients, especially in the presence of cholangitis. Therapeutic ERCP in pregnancy was first reported in 1990 by Baillie *et al.*⁶⁹ Since then, there have been multiple studies that have demonstrated the safety and success of ERCP followed by sphincterotomy during pregnancy with minimal risk of radiation to the fetus.^{14 15 60 70–72} In cases where endoscopic retrieval of the choledocholithiasis is not possible, biliary stents may be placed; however, they do carry the risk of stent occlusion with subsequent cholangitis and also necessitate an additional procedure for stent removal.^{73–75}

ERCP has been described using both conscious sedation and general anesthesia with equal safety.^{76–79} Maternal fetal monitoring should be used during the procedure under the supervision of the obstetrician. In the rare situation when ERCP is unavailable or unsuccessful, percutaneous transhepatic cholangiography with drainage can be used.^{80 81} Another alternative is surgical intervention. Laparoscopic common bile duct exploration has been described in the second trimester and early third trimester in case reports, but no large studies have been published to date.^{82–86} Open cholecystectomy with choledochotomy and T-tube placement has also been described in older series, although with associated higher rates of fetal loss.^{55 59} Whatever the method used to clear the duct, cholecystectomy is offered during the same hospitalization due to the high rate of recurrent symptoms associated with outpatient management.⁸⁷

Acute pancreatitis

Acute pancreatitis complicates approximately 1 in 1000–5000 pregnancies, usually occurring late in the third trimester or in the early postpartum period.^{87–91} Cholelithiasis is the most common cause and accounts for 67%–100% of cases, followed by ethanol use and hyperlipidemia.^{91 92} The medical management is the same as in pancreatitis in non-pregnant women and

consists of bowel rest, fluid and electrolyte resuscitation and the use of analgesics.⁹³ These patients are best managed in an intensive care unit. As mentioned previously for choledocholithiasis, because of the high recurrence of gallstone-related symptoms, a prompt cholecystectomy should be performed when the patient improves during the same hospitalization if the determined etiology was biliary.⁸⁷

Intestinal obstruction

Acute intestinal obstruction is the third most common non-obstetric abdominal emergency with an incidence of 1 in 1500 pregnancies.⁹⁴ Adhesions cause 60%–70% of cases. Other causes include volvulus, intussusception, hernia, neoplasm and appendicitis. Of note, volvulus can be the cause of obstruction in up to 25% of cases of gestational obstruction, while in non-pregnant patients, it is only 5%.¹ Gestational bowel obstruction should never be confused with hyperemesis gravidarum, which can lead to a delay in diagnosis, the former of which will have abdominal examination findings.⁶ The approach to intestinal obstruction is the same in pregnancy as in the general population. Medical management involving hydration, bowel rest and nasogastric decompression will lead to resolution in the majority of cases.¹ Both laparoscopic as well as open approaches for surgery are acceptable.^{95,96} Mortality for gestational intestinal obstruction is higher than for non-pregnant patients and increases as gestational age increases.^{1,96} Excessive manipulation of the uterus should be avoided. Fetal monitoring should be used in all viable cases of 24 weeks and older.^{27,28}

CONCLUSION

Pregnant patients are a specific population, where worry about the risk of harm to the fetus often overshadows clinical decision making when presented with a possible surgical diagnosis. While it is important to limit duration of exposure to radiation and unnecessary surgery in this population, delays in diagnosis and treatment can also harm both fetus and mother. Obtaining the correct diagnosis in the pregnant patient can be challenging because of the normal physiologic and anatomic changes that occur with pregnancy. While reduced radiation imaging such as MRI or radiation-free ERCP may allow limiting of radiation exposure to the fetus, availability and time involved may hinder use depending on one's practice setting. Minimally invasive surgery may be performed safely depending on the surgeon's comfort level with the duration of pregnancy. In cases of general surgical emergencies during pregnancy, a diagnosis should be rapidly sought and treatment offered, lest we should ever penalize a patient for being pregnant.

Acknowledgements The authors would like to acknowledge Katherine Armstrong for her assistance with reviewing the manuscript.

Contributors JJS and AS wrote and reviewed the manuscript.

Competing interests None declared.

Provenance and peer review Commissioned; externally peer reviewed.

Open Access This is an Open Access article distributed in accordance with the Creative Commons Attribution Non Commercial (CC BY-NC 4.0) license, which permits others to distribute, remix, adapt, build upon this work non-commercially, and license their derivative works on different terms, provided the original work is properly cited and the use is non-commercial. See: <http://creativecommons.org/licenses/by-nc/4.0/>

© Article author(s) (or their employer(s) unless otherwise stated in the text of the article) 2017. All rights reserved. No commercial use is permitted unless otherwise expressly granted.

REFERENCES

- 1 Augustin G, Majerovic M. Non-obstetrical acute abdomen during pregnancy. *Eur J Obstet Gynecol Reprod Biol* 2007;131:4–12.

- 2 Taylor DJ, Lind T. Red cell mass during and after normal pregnancy. *Br J Obstet Gynaecol* 1979;86:364–70.
- 3 Yeomans ER, Gilstrap LC. Physiologic changes in pregnancy and their impact on critical care. *Crit Care Med* 2005;33:S256–S258.
- 4 Kinsella SM, Lohmann G. Supine hypotensive syndrome. *Obstet Gynecol* 1994;83:774–88.
- 5 Cheung KL, Lafayette RA. Renal physiology of pregnancy. *Adv Chronic Kidney Dis* 2013;20:209–14.
- 6 Kilpatrick CC, Monga M. Approach to the acute abdomen in pregnancy. *Obstet Gynecol Clin North Am* 2007;34:389–402.
- 7 Williams PM, Fletcher S. Health effects of prenatal radiation exposure. *Am Fam Physician* 2010;82:488–93.
- 8 Delongchamp RR, Mabuchi K, Yoshimoto Y, Preston DL. Cancer mortality among atomic bomb survivors exposed in utero or as young children, October 1950–May 1992. *Radiat Res* 1997;147:385–95.
- 9 Cullings HM, Fujita S, Funamoto S, Grant EJ, Kerr GD, Preston DL. Dose estimation for atomic bomb survivor studies: its evolution and present status. *Radiat Res* 2006;166:219–54.
- 10 Coppel J, El-Sayed HP, Whart KR. Guidelines for diagnostic imaging during pregnancy and lactation. *Committee opinion* 2016;656:1–10.
- 11 De Santis M, Cesari E, Nobili E, Straface G, Cavaliere AF, Caruso A. Radiation effects on development. *Birth Defects Res C Embryo Today* 2007;81:177–82.
- 12 Duke E, Kalb B, Arif-Tiwari H, Daye ZJ, Gilbertson-Dahdal D, Keim SM, Martin DR. A systematic review and meta-analysis of diagnostic performance of MRI for evaluation of acute appendicitis. *AJR Am J Roentgenol* 2016;206:508–17.
- 13 Baheti AD, Nicola R, Bennett GL, Bordia R, Moshiri M, Katz DS, Bhargava P. Magnetic resonance imaging of abdominal and pelvic pain in the pregnant patient. *Magn Reson Imaging Clin N Am* 2016;24:403–17.
- 14 Tham TC, Vandervoort J, Wong RC, Montes H, Roston AD, Slivka A, Ferrari AP, Lichtenstein DR, Van Dam J, Nawfel RD, et al. Safety of ERCP during pregnancy. *Am J Gastroenterol* 2003;98:308–11.
- 15 Kahaleh M, Hartwell GD, Arseneau KO, Pajewski TN, Mullick T, Isin G, Agarwal S, Yeaton P. Safety and efficacy of ERCP in pregnancy. *Gastrointest Endosc* 2004;60:287–92.
- 16 Dumonceau JM, Garcia-Fernandez FJ, Verdun FR, Carinou E, Donadille L, Damlakis J, Mouzas I, Paraskeva K, Ruiz-Lopez N, Struelens L, et al. Radiation protection in digestive endoscopy: European Society of Digestive Endoscopy (ESGE) guideline. *Endoscopy* 2012;44:408–24.
- 17 Shelton J, Linder JD, Rivera-Alsina ME, Tarnasky PR. Commitment, confirmation, and clearance: new techniques for nonradiation ERCP during pregnancy (with videos). *Gastrointest Endosc* 2008;67:364–8.
- 18 Wu W, Faigel DO, Sun G, Yang Y. Non-radiation endoscopic retrograde cholangiopancreatography in the management of choledocholithiasis during pregnancy. *Dig Endosc* 2014;26:691–700.
- 19 Al-Fozan H, Tulandi T. Safety and risks of laparoscopy in pregnancy. *Curr Opin Obstet Gynecol* 2002;14:375–9.
- 20 Affleck DG, Handrahan DL, Egger MJ, Price RR. The laparoscopic management of appendicitis and cholelithiasis during pregnancy. *Am J Surg* 1999;178:523–8.
- 21 Dhupar R, Smaldone GM, Hamad GG. Is there a benefit to delaying cholecystectomy for symptomatic gallbladder disease during pregnancy? *Surg Endosc* 2010;24:108–12.
- 22 Wilasrusmee C, Sukrat B, McEvoy M, Attia J, Thakkinian A. Systematic review and meta-analysis of safety of laparoscopic versus open appendectomy for suspected appendicitis in pregnancy. *Br J Surg* 2012;99:1470–8.
- 23 Sachs A, Guglielminotti J, Miller R, Landau R, Smiley R, Li G. Risk factors and risk stratification for adverse obstetrical outcomes after appendectomy or cholecystectomy during pregnancy. *JAMA Surg* 2017:E1–6.
- 24 Fatum M, Rojansky N. Laparoscopic surgery during pregnancy. *Obstet Gynecol Surv* 2001;56:50–9.
- 25 Thepsuwan J, Huang K-G, Wilamarta M, Adlan A-S, Manvelyan V, Lee C-L, et al. Principles of safe abdominal entry in laparoscopic gynecologic surgery. *Gynecology and Minimally Invasive Therapy* 2013;2:105–9.
- 26 Palmer R. Safety in laparoscopy. *J Reprod Med* 1974;13:1–5.
- 27 Barone JE, Bears S, Chen S, Tsai J, Russell JC. Outcome study of cholecystectomy during pregnancy. *Am J Surg* 1999;177:232–6.
- 28 Steinbrook RA, Brooks DC, Datta S. Laparoscopic cholecystectomy during pregnancy. Review of anesthetic management, surgical considerations. *Surg Endosc* 1996;10:511–5.
- 29 Kort B, Katz VL, Watson WJ. The effect of nonobstetric operation during pregnancy. *Surg Gynecol Obstet* 1993;177:371–6.
- 30 Parangi S, Levine D, Henry A, Isakovich N, Pories S. Surgical gastrointestinal disorders during pregnancy. *Am J Surg* 2007;193:223–32.
- 31 Lacasse A, Rey E, Ferreira E, Morin C, Bérard A. Epidemiology of nausea and vomiting of pregnancy: prevalence, severity, determinants, and the importance of race/ethnicity. *BMC Pregnancy Childbirth* 2009;9:1–9.
- 32 Hancock H. Disease of the appendix Caeci cured by operation. *Lancet* 1848;2:381.
- 33 Mazze RI, Källén B. Appendectomy during pregnancy: a Swedish registry study of 778 cases. *Obstet Gynecol* 1991;77:835–40.

- 34 Gomez A, Wood M. Acute appendicitis during pregnancy. *Am J Surg* 1979;137:180–3.
- 35 Babaknia A, Parsa H, Woodruff JD. Appendicitis during pregnancy. *Obstet Gynecol* 1977;50:40–4.
- 36 Baer JL. Appendicitis in pregnancy. *J Am Med Assoc* 1932;98:1359–64.
- 37 Mourad J, Elliott JP, Erickson L, Lisboa L. Appendicitis in pregnancy: new information that contradicts long-held clinical beliefs. *Am J Obstet Gynecol* 2000;182:1027–9.
- 38 Aggenbach L, Zeeman GG, Cantineau AE, Gordijn SJ, Hofker HS. Impact of appendicitis during pregnancy: no delay in accurate. *Int J Surg* 2015;15:84–9.
- 39 Wallace CA, Petrov MS, Soybel DI, Ferzoco SJ, Ashley SW, Tavakkolizadeh A. Influence of imaging on the negative appendectomy rate in pregnancy. *J Gastrointest Surg* 2008;12:46–50.
- 40 McGory ML, Zingmond DS, Tillou A, Jonathan HR, Clifford KY, Henry CM. Negative appendectomy in pregnant women is. *J Am Coll Surg* 2007;205:534–40.
- 41 Ito K, Ito H, Whang EE, Tavakkolizadeh A. Appendectomy in pregnancy: evaluation of the risks of a negative appendectomy. *Am J Surg* 2012;203:145–50.
- 42 Long SS, Long C, Lai H, Macura KJ. Imaging strategies for right lower quadrant pain in pregnancy. *AJR Am J Roentgenol* 2011;196:4–12.
- 43 Hlibczuk V, Dattaro JA, Jin Z, Falzon L, Brown MD. Diagnostic accuracy of noncontrast computed tomography for appendicitis in adults: a systematic review. *Ann Emerg Med* 2010;55:51–9.
- 44 Ames Castro M, Shipp TD, Castro EE, Ouzounian J, Rao P. The use of helical computed tomography in pregnancy for the diagnosis of acute appendicitis. *Am J Obstet Gynecol* 2001;184:954–7.
- 45 Lazarus E, Mayo-Smith WW, Mainiero MB, Spencer PK. CT in the evaluation of nontraumatic abdominal pain in pregnant women. *Radiology* 2007;244:784–90.
- 46 Behar J. Clinical aspects of gallbladder motor function and dysfunction. *Curr Gastroenterol Rep* 1999;1:91–4.
- 47 Bolukbas FF, Bolukbas C, Horoz M, Ince AT, Uzunkoy A, Ozturk A, Aka N, Demirci F, Inci E, Ovunc O. Risk factors associated with gallstone and biliary sludge formation during pregnancy. *J Gastroenterol Hepatol* 2006;21:1150–3.
- 48 Gilat T, Konikoff F. Pregnancy and the biliary tract. *Can J Gastroenterol* 2000;14(Suppl D):55D–9.
- 49 Maringhini A, Marcenò MP, Lanzarone F, Caltagirone M, Fusco G, Di Cuonzo G, Cittadini E, Pagliaro L. Sludge and stones in gallbladder after pregnancy. Prevalence and risk factors. *J Hepatol* 1987;5:218–23.
- 50 Swisher SG, Schmit PJ, Hunt KK, Hiyama DT, Bennion RS, Swisher EM, Thompson JE. Biliary disease during pregnancy. *Am J Surg* 1994;168:576–81.
- 51 Davis A, Katz VL, Cox R. Gallbladder disease in pregnancy. *J Reprod Med* 1995;40:759–62.
- 52 Jorge AM, Keswani RN, Veerappan A, Soper NJ, Gawron AJ. Non-operative management of symptomatic cholelithiasis in pregnancy is associated with frequent hospitalizations. *J Gastrointest Surg* 2015;19:598–603.
- 53 Lu EJ, Curet MJ, El-Sayed YY, Kirkwood KS. Medical versus surgical management of biliary tract disease in pregnancy. *Am J Surg* 2004;188:755–9.
- 54 Greene J, Rogers A, Rubin L. Fetal loss after cholecystectomy during pregnancy. *Can Med Assoc J* 1963;88:576–7.
- 55 Hiatt JR, Hiatt JC, Williams RA, Klein SR. Biliary disease in pregnancy: strategy for surgical management. *Am J Surg* 1986;151:263–5.
- 56 Hill LM, Johnson CE, Lee RA. Cholecystectomy in pregnancy. *Obstet Gynecol* 1975;46:291–3.
- 57 Hamlin E, Bartlett MK, Smith JA. Acute surgical emergencies of the abdomen in pregnancy. *N Engl J Med Overseas Ed* 1951;244:128–31.
- 58 Printen KJ, Ott RA. Cholecystectomy during pregnancy. *Am Surg* 1978;44:432–4.
- 59 Dixon NP, Faddis DM, Silberman H. Aggressive management of cholecystitis during pregnancy. *Am J Surg* 1987;154:292–4.
- 60 Daas AY, Agha A, Pinkas H, et al. ERCP in pregnancy: is it safe? *Gastroenterol Hepatol* 2009;5:851–5.
- 61 Othman MO, Stone E, Hashimi M, Parasher G. Conservative management of cholelithiasis and its complications in pregnancy is associated with recurrent symptoms and more emergency department visits. *Gastrointest Endosc* 2012;76:564–9.
- 62 Koncoro H, Lesmana CR, Philipi B. Cholelithiasis during pregnancy: multimodal approach treatment. *The Indonesian Journal of Gastroenterology, Hepatology, and Digestive Endoscopy* 2016;17:58–63.
- 63 Wada K, Takada T, Kawarada Y, Nimura Y, Miura F, Yoshida M, Mayumi T, Strasberg S, Pitt HA, Gadacz TR, et al. New diagnostic criteria and severity assessment of acute cholangitis: Tokyo Guidelines. *J Hepatobiliary Pancreat Surg* 2007;14:52–8.
- 64 Kiriyaama S, Takada T, Strasberg SM, Solomkin JS, Mayumi T, Pitt HA, Gouma DJ, Garden OJ, Büchler MW, Yokoe M, et al. New diagnostic criteria and severity assessment of acute cholangitis in revised Tokyo guidelines. *J Hepatobiliary Pancreat Sci* 2012;19:548–56.
- 65 Einstein DM, Lapin SA, Ralls PW, Halls JM. The insensitivity of sonography in the detection of choledocholithiasis. *AJR Am J Roentgenol* 1984;142:725–8.
- 66 Stott MA, Farrands PA, Guyer PB, Dewbury KC, Browning JJ, Sutton R. Ultrasound of the common bile duct in patients undergoing cholecystectomy. *J Clin Ultrasound* 1991;19:73–6.
- 67 Oto A, Ernst R, Ghulmiyyah L, Hughes D, Saade G, Chaljub G. The role of MR cholangiopancreatography in the evaluation of pregnant patients with acute pancreatobiliary disease. *Br J Radiol* 2009;82:279–85.
- 68 Ray JG, Vermeulen MJ, Bharatha A, Montanera WJ, Park AL. Association between MRI exposure during pregnancy and fetal and childhood outcomes. *JAMA* 2016;316:952–61.
- 69 Baillie J, Cairns SR, Putman WS, Cotton PB. Endoscopic management of choledocholithiasis during pregnancy. *Surg Gynecol Obstet* 1990;171:1–4.
- 70 Jamidar PA, Beck GJ, Hoffman BJ, Lehman GA, Hawes RH, Agrawal RM, Ashok PS, Ravi TJ, Cunningham JT, Troiano F. Endoscopic retrograde cholangiopancreatography in pregnancy. *Am J Gastroenterol* 1995;90:1263–7.
- 71 Tang SJ, Mayo MJ, Rodriguez-Frias E, Armstrong L, Tang L, Sreenarasimhaiah J, Lara LF, Rockey DC. Safety and utility of ERCP during pregnancy. *Gastrointest Endosc* 2009;69:453–61.
- 72 Smith I, Gaidhane M, Goode A, Kahaleh M. Safety of endoscopic retrograde cholangiopancreatography in pregnancy: Fluoroscopy time and fetal exposure, does it matter? *World J Gastrointest Endosc* 2013;5:148–53.
- 73 Slattery E, Kale V, Anwar W, Courtney G, Aftab AR. Role of long-term biliary stenting in choledocholithiasis. *Dig Endosc* 2013;25:440–3.
- 74 Donelli G, Guaglianone E, Di Rosa R, Fiocca F, Basoli A. Plastic biliary stent occlusion: factors involved and possible preventive approaches. *Clin Med Res* 2007;5:53–60.
- 75 Attaallah W, Cingi A, Karpuz S, Karakus M, Gunal O. Do not rush for surgery; stent placement may be an effective step for definitive treatment of initially unextractable common bile duct stones with ERCP. *Surg Endosc* 2016;30:1473–9.
- 76 Rex DK, Deenadayalu VP, Eid E, Imperiale TF, Walker JA, Sandhu K, Clarke AC, Hillman LC, Horiuchi A, Cohen LB, et al. Endoscopist-directed administration of propofol: a worldwide safety experience. *Gastroenterology* 2009;137:1229–37.
- 77 Coté GA, Hovis RM, Ansstas MA, Waldbaum L, Azar RR, Early DS, Edmundowicz SA, Mullady DK, Jonnalagadda SS. Incidence of sedation-related complications with propofol use during advanced endoscopic procedures. *Clin Gastroenterol Hepatol* 2010;8:137–42.
- 78 Garewal D, Vele L, Waikar P. Anaesthetic considerations for endoscopic retrograde cholangio-pancreatography procedures. *Curr Opin Anaesthesiol* 2013;26:475–80.
- 79 Thosani N, Banerjee S. Deep sedation or general anesthesia for ERCP? *Dig Dis Sci* 2013;58:3061–3.
- 80 Ozcan N, Kahrman G, Mavili E. Percutaneous transhepatic removal of bile duct stones: results of 261 patients. *Cardiovasc Intervent Radiol* 2012;35:890–7.
- 81 Lan Cheong Wah D, Christophi C, Muralidharan V. Acute cholangitis: current concepts. *ANZ J Surg* 2017;87:554–9.
- 82 Tuech JJ, Binelli C, Aube C, Pessaux P, Fauvet R, Descamps P, Arnaud JP. Management of choledocholithiasis during pregnancy by magnetic resonance cholangiography and laparoscopic common bile duct stone extraction. *Surg Laparosc Endosc Percutan Tech* 2000;10:323–5.
- 83 Liberman MA, Phillips EH, Carroll B, Fallas M, Rosenthal R. Management of choledocholithiasis during pregnancy: a new protocol in the laparoscopic era. *J Laparosc Surg* 1995;5:399–403.
- 84 Kim YW, Zagorski SM, Chung MH. Laparoscopic common bile duct exploration in pregnancy with acute gallstone pancreatitis. *JLS* 2006;10:78–82.
- 85 Lacin J, Rancane I, Plaudis H, Saukane E, Pupelis G, et al. Laparoscopic common bile duct exploration for choledocholithiasis during a pregnancy: a case report. *Acta Chirurgica Litviensis* 2016;16:41–3.
- 86 Lopez J, Rodriguez K, Targarona E, Corral I, Padilla F, Gameros R, Reyes A. Laparoscopic clearance of giant common bile duct stones in late pregnancy. *CRSLS* 2014:1–2.
- 87 Mador BD, Nathens AB, Xiong W, Panton ONM, Hameed SM. Timing of cholecystectomy following endoscopic sphincterotomy: a population-based study. *Surg Endosc* 2017;31:2977–85.
- 88 Hernandez A, Petrov MS, Brooks DC, Banks PA, Ashley SW, Tavakkolizadeh A. Acute pancreatitis and pregnancy: a 10-year single center experience. *J Gastrointest Surg* 2007;11:1623–7.
- 89 McKay AJ, O'Neill J, Imrie CW. Pancreatitis, pregnancy and gallstones. *Br J Obstet Gynaecol* 1980;87:47–50.
- 90 Ramin KD, Ramin SM, Richey SD, Cunningham FG. Acute pancreatitis in pregnancy. *Am J Obstet Gynecol* 1995;173:187–91.
- 91 Eddy JJ, Gideonsen MD, Song JY, Grobman WA, O'Halloran P. Pancreatitis in pregnancy: a 10 year retrospective of 15 Midwest. *Obstet Gynecol* 2008;112:1075–81.
- 92 Mali P. Pancreatitis in pregnancy: etiology, diagnosis, treatment, and outcomes. *Hepatobiliary Pancreat Dis Int* 2016;15:434–8.
- 93 Pitchumoni CS, Yegneswaran B. Acute pancreatitis in pregnancy. *World J Gastroenterol* 2009;15:5641–6.
- 94 Dietrich CS, Hill CC, Hueman M. Surgical diseases presenting in pregnancy. *Surg Clin North Am* 2008;88:403–19.
- 95 Unal A, Sayharman SE, Ozel L, Unal E, Aka N, Tizit I, Kose G. Acute abdomen in pregnancy requiring surgical management: a 20-case series. *Eur J Obstet Gynecol Reprod Biol* 2011;159:87–90.
- 96 Perdue PW, Johnson HW, Stafford PW. Intestinal obstruction complicating pregnancy. *Am J Surg* 1992;164:384–8.