





# Evaluation of Microsatellite Instability in Colorectal Adenomas and Carcinomas by Immunohistochemistry and a Comparison of Histopathological Features

Rukiye Yılmaz<sup>1</sup> , Recep Bedir<sup>1</sup> , Remzi Adnan Akdoğan<sup>2</sup> , Ahmet Pergel<sup>3</sup> 

<sup>1</sup>Department of Pathology, Recep Tayyip Erdogan University, School of Medicine, Rize, Turkey

<sup>2</sup>Department of Gastroenterology, Recep Tayyip Erdogan University, School of Medicine, Rize, Turkey

<sup>3</sup>Department of General Surgery, Recep Tayyip Erdogan University, School of Medicine, Rize, Turkey

## ABSTRACT

**Objective:** Approximately 15% of sporadic colorectal carcinomas (CRCs) develop along the microsatellite instability (MSI) pathway. In this study, we compared the MLH1, MSH2, Ki-67, and p53 immunostaining properties with histopathological features of colorectal adenomas and CRCs.

**Methods:** A total of 102 cases were selected, including 50 adenomatous polyps, 25 adenocarcinomas, 10 adenocarcinomas with mucinous component, 14 mucinous adenocarcinomas, and three signet-ring cell carcinomas. The tissues were stained for MLH1, MSH2, p53, and Ki-67 primary antibodies.

**Results:** Negative staining was observed for MLH1 in 25% and MSH2 in 3.8% of all CRC cases. Compared with adenocarcinoma not otherwise specified (NOS), mucinous adenocarcinomas showed weaker staining for MLH1, which was statistically significant. There was also a statistically significant difference between adenocarcinoma NOS and signet-ring cell carcinomas in terms of negative staining for MLH1. A total of 69.2% of the MLH1-negative cases were high-grade. There was a statistically significant relationship between the histological grade and MLH1 negativity. A positive correlation was found between the grade of dysplasia and p53 staining intensity and Ki-67 proliferation index. No negative staining was observed for MLH1 and MSH2 in any of the adenomatous polyps.

**Conclusion:** For the histopathological examination of CRCs, in the presence of mucinous and poorly differentiated morphology, tumor-infiltrating lymphocytes and Crohn-like inflammatory response, immunohistochemical staining for MLH1, and MSH2 antibodies may be useful in the detection of tumors showing MSI.

**Keywords:** Adenomatous polyps, colorectal carcinomas, immunohistochemistry, microsatellite instability

## INTRODUCTION

Colorectal carcinoma (CRC) is one of the leading causes of morbidity and mortality worldwide. CRC, representing approximately 9.7% of newly diagnosed carcinomas worldwide (1), is the fourth most common type of carcinoma in males after lung, prostate, and stomach carcinomas. Furthermore, in females, it is the third most common type of carcinoma after breast and cervical carcinomas in the world (1). Colorectal adenomas are relatively common lesions. The incidence increases after 50 years age. Colorectal adenomas are recognized as precursors in the majority of CRC cases (1-4).

Molecular events involving both genetic and epigenetic abnormalities occur during the development of CRCs. At least two genetic pathways have been identified. These are the chromosomal instability pathway and the microsatellite instability (MSI) pathway (1). Approximately 15% of sporadic CRCs and almost all

of the CRCs in patients with hereditary nonpolyposis colorectal carcinoma develop with the MSI pathway. Indirect immunohistochemical MSI diagnosis can be given as a result of developing specific antibodies against mismatch repair proteins, which are gene products of the mismatch repair system (1). A high level of agreement was found between the immunohistochemically detected MLH1 and MSH2 expressions and the MSI status determined by molecular methods (5-8).

In this study, the MLH1, MSH2, Ki-67, and p53 staining properties of colorectal adenomas and CRCs were evaluated and compared with the histopathological features.

## METHODS

Endoscopic polypectomy materials and colorectal resections (right hemicolectomy, left hemicolectomy, transverse colectomy, sigmoidectomy, and low-anterior resection) that were sent

ORCID ID of the author: R.B. 0000-0001-8247-3781; R.Y. 0000-002-9389-9397; R.A.A. 0000-0002-4151-3238; A.P. 0000-0002-0163-887X

Corresponding Author: Recep Bedir E-mail: bedirrecep@gmail.com

Received: 14.03.2018 • Accepted: 13.04.2018

to the Department of Pathology, Recep Tayyip Erdogan School of Medicine between 2011 and 2016 were obtained from our pathology reports. The study conformed to the ethical guidelines of the 1975 Declaration of Helsinki, as reflected in the Ethics Committee approval. Patients who were diagnosed with CRCs and adenomatous polyps were enrolled in the study after obtaining their written informed consent. Among these cases, a total of 102 cases were selected, including 20 tubular adenomas, 20 tubulovillous adenomas, 10 villous adenomas, 25 adenocarcinomas not otherwise specified (NOS), 10 adenocarcinoma with mucinous component, 14 mucinous adenocarcinomas, and three signet-ring cell carcinomas selected from our laboratory archive. Patients receiving neoadjuvant therapy and those who had a familial cancer history were not included in this study. The H&E stained slides of the cases were reviewed again, and the most suitable paraffin blocks were identified. Sections taken at a 4-micrometer thickness from selected paraffin blocks were placed onto poly-L-lysine coated slides. Primary antibodies to MLH1 (mouse monoclonal, clone G168-15, isotype IgG1/kappa, ready for use, Biocare Medical, USA), MSH2 (mouse monoclonal, clone FE11, isotype IgG1/kappa, Biocare Medical, USA), Ki-67 (Rabbit monoclonal, clone SP6, isotope rabbit IgG, Thermo Scientific, Fremont, CA, USA), and p53 (mouse monoclonal, clone BP53-12, IgG2a/kappa, ScyTek Laboratories, Logan, USA) were used for immunohistochemical staining with automated an IHC/ISH staining instrument (Roche, Ventana, Benchmark, TX, USA). Normal human tonsil tissue (for MLH1, MSH2, and Ki-67) and colon adenocarcinoma (for p53) were used as external positive controls. The results were evaluated independently by two pathologists with an Olympus BX51 light microscope.

#### Statistical Analysis

The Statistical Package for Social Sciences version 13.0 (SPSS Inc.; Chicago, IL, USA) statistical software was used to analyze the data. The one-way analysis of variance, Student's t test, and Mann-Whitney U test were used to compare the descriptive statistical measures (mean, standard deviation), as well as the quantitative data. The normal distribution of the data was assessed by the one-sample Kolmogorov-Smirnov test. A chi-squared test and Fisher's exact test were used for comparison of the qualitative data. Correlation coefficients and statistical significance were calculated by the Kendall Correlation test for the inter-variable interrelationships. P-values <0.05 were considered as significant.

#### Morphological Evaluation

Current World Health Organization criteria were used for adenoma and carcinoma diagnosing and typing, and for tumor differentiation and tumor grading (1). According to these criteria, the tumors were grouped as well differentiated, moderately differentiated, poorly differentiated, and undifferentiated. The following criteria for grading based on the gland formation alone were used: low-grade, greater than or equal to 50% gland formation; high-grade, less than 50% gland formation. These grading systems were not used for signet-ring cell carcinoma and mucinous carcinomas, as these tumors were accepted as high-grade (1). The TNM staging system by the American Joint Committee on Cancer and the International Union Against Cancer were used for pathologic tumor staging. The intratumoral lymphocytic

response (tumor-infiltrating lymphocytes) was assessed as 1 (none), 0-2 (mild to moderate 0-2 per high-power [X400] field), 3 (marked three or more per high-power field). Peritumoral lymphocytic response (Crohn-like response) was rated as 1 (none), 2 (mild to moderate), and 3 (marked). A stromal reaction in the tumor was classified as mild desmoplasia [1], moderate desmoplasia [2], and severe desmoplasia [3]. Histopathologic parameters such as tumor necrosis, perineural invasion, lymphovascular invasion, and tumor nodule presence were classified as present or absent.

The caecum, ascending colon, hepatic flexure, and transverse colon were determined as the right colon; the splenic flexure, descending colon, sigmoid colon, and rectum were determined as the left colon.

#### Immunohistochemical Analysis

The nuclear staining for Ki-67, p53, MLH1, and MSH2 was considered positive. The nuclear staining for MLH1 and MSH2 was considered positive, whereas the absence of staining was considered as negative staining. Tumors showing the loss of nuclear MLH1 or MSH2 expressions were classified as MLH1- or MSH2-negative. Nuclear staining in normal epithelial cells, lymphocytes, and stromal cells was used as a positive internal control for MLH1 and MSH2. In addition, the tonsillar tissue and normal bowel tissue were used as an external positive control on the slide. A single scoring system was used for both Ki-67 and p53. According to this scoring, a 0%-10% staining was accepted as G0, 11%-50% staining as G1, 51%-75% staining as G2, and 75% staining as G3.

## RESULTS

Of the 50 polypectomy cases, 21 were female (42%), and 29 (58%) were male. The mean age was 61.94 years. The age of the oldest patient was 84 and the youngest 33 years. 86% of the patients were over 50 years. Twenty polyps were tubular adenomas (40%), 20 tubulovillous adenomas (40%), and 10 villous adenomas (20%). Twenty-eight of the polyps (56%) had low-grade dysplasia, and 22 (44%) had high-grade dysplasia. The age and gender distribution, dysplasia grade, diameters, MSH2, MLH1, Ki-67, and p53 staining characteristics of polyps are summarized in Table 1. A positive correlation was found between dysplasia and p53 staining ( $p < 0.001$ ,  $r = 0.516$ ). A positive correlation was found between dysplasia and the Ki-67 proliferation index ( $p < 0.001$ ,  $r = 0.458$ ). It was determined that 100% of the tubular adenomas contained low-grade dysplasia, 70% of tubulovillous adenomas had high-grade dysplasia, and 80% of villous adenomas had high-grade dysplasia. There was a statistically significant relationship between the histologic type of adenomas and dysplasia grade ( $p < 0.001$ ). All adenomas were positively stained with MLH1 and MSH2 (Figures 1-4). The mean age in CRC cases was 62.4 years, with the maximum age being 86 years and the youngest age being 36 years. Twelve of the patients were under 50 years old. 42.3% of CRC cases were female, and 57.7% were male. The age distribution and localization of CRC cases and p53, Ki-67, MLH1, and MSH2 staining results are summarized in Table 2. The comparison of the MLH1 and MSH2 staining of CRCs with histopathological findings (differentiation, tumor grade, necrosis, lymphatic invasion, perineural invasion, stromal reac-

**Table 1.** Relationship between age, gender, and histopathological findings in adenomatous polyps n (%)

	Tubuler adenoma	Tubulovillous adenoma	Villous adenoma	p
Number/Percentage	20 (40%)	20 (40%)	10 (20%)	
Gender				0.691
Female	9 (45%)	9 (45%)	3 (30%)	
Male	11 (55%)	11(55%)	7 (70%)	
Age				
≥50 years	19 (95%)	15 (75%)	9 (90%)	
<50 years	1 (5%)	5 (5%)	1 (10%)	
Configuration				<0.001
Sessile	20 (100%)	9 (45%)	8 (80%)	
Pedunculated	11 (55%)	2 (20%)		
Mean size	0.47 cm	1.53 cm	1.78	0.001
Displasia				<0.001
Low grade	20 (100%)	6 (30%)	2 (20%)	
High grade		14 (70%)	8 (80%)	
p53				
G1	13 (65%)	-	-	
G2	7 (35%)	16 (80%)	9 (90%)	
G3	-	4 (20%)	1 (10%)	
Ki-67				
G1	11 (55%)	1 (5%)	-	
G2	9 (45%)	14 (70%)	8 (80%)	
G3	-	5 (25%)	1 (20%)	
MLH1 staining	Positive staining	Positive staining	Positive staining	
MSH2 staining	Positive staining	Positive staining	Positive staining	

MLH1: mutL homolog 1; MSH2: mutS homolog 2

tion, intratumoral lymphocytic response, Crohn-like response, and pathologic stage) is summarized in Table 3. No statistically significant difference was observed between adenocarcinoma, NOS (negative staining in 4%), and adenocarcinoma with mucinous component (negative staining in 30%) in terms of negative staining with MLH1 (p=0.061). There was no statistically significant difference between adenocarcinoma NOS (no negative staining) and adenocarcinoma with mucinous component (negative staining in 20%) in terms of negative staining with MSH2 (p=0.076) (Figures 5-9). There was a statistically significant difference between adenocarcinoma NOS (negative staining in

Figure 1. MLH1 positively stained tubular adenoma (x400)

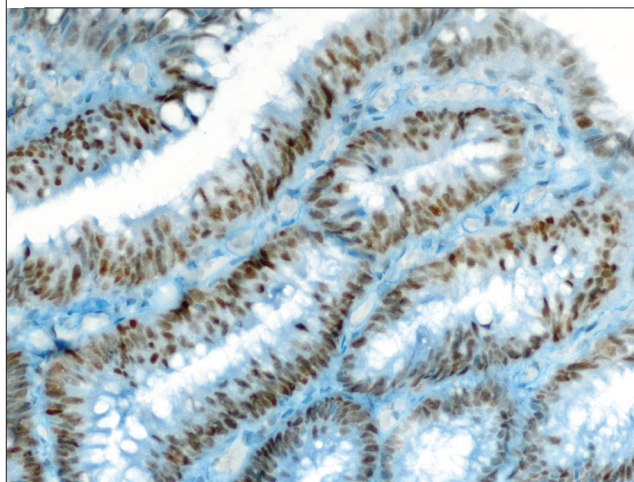


Figure 2. MSH2 positively stained tubular adenoma (x400)

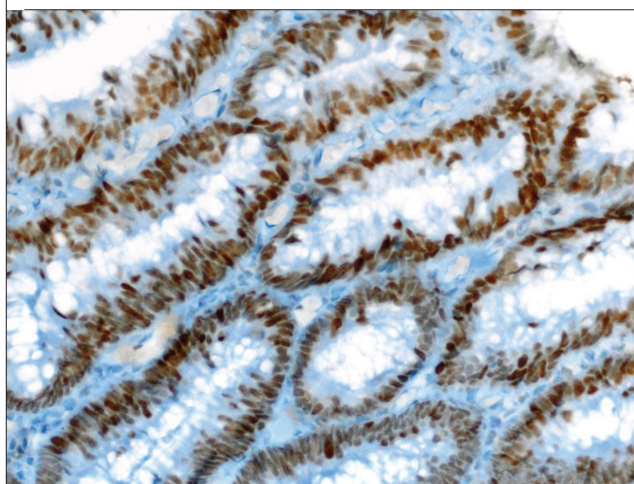
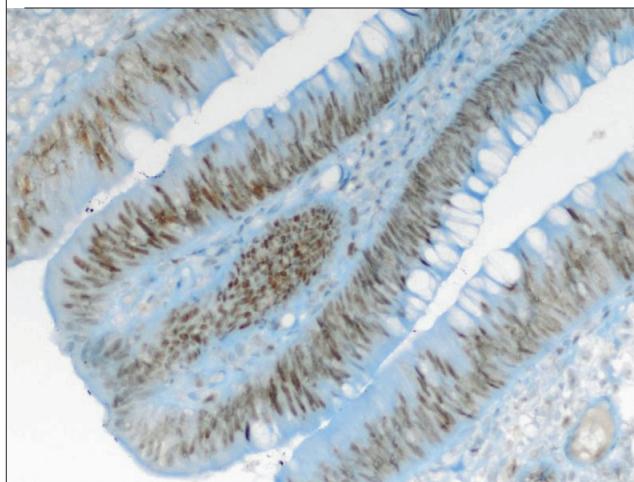


Figure 3. MLH1 positively stained villous adenoma (x400)



4%) and mucinous adenocarcinomas (negative staining in 50%) in terms of negative staining with MLH1 (p=0.001) (Figure 10). Positive staining with MSH2 was detected in all adenocarcino-

**Table 2. Relationship between cancer types and other histopathological findings n (%)**

	Adenocarcinoma, NOS	Adenocarcinoma with mucinous component	Mucinous adenocarcinoma	Signet-ring cell carcinoma
<b>Age</b>				
≥50 years	16 (64%)	9 (90%)	12 (85.7%)	3 (100%)
<50 years	9 (36%)	1 (10%)	2 (14.3%)	–
<b>Localization</b>				
Cecum	2 (8%)	3 (30%)	5 (35.7%)	1 (33.3%)
Ascending colon	4 (16%)	2 (20%)	1 (7.1%)	–
Hepatic flexure	2 (8%)	–	–	1 (33.3%)
Transverse colon	1 (4%)	–	2 (14.3%)	–
Splenic flexure	3 (12%)	–	1 (7.1%)	–
Descending colon	1 (4%)	1 (10%)	3 (21.4%)	–
Sigmoid colon	10 (40%)	2 (20%)	2 (14.3%)	–
Rectum	2 (8%)	–	2 (20%)	1 (33.3%)
<b>MLH1</b>				
Positive staining	24 (96%)	7 (70%)	7 (50%)	1 (33.3%)
Negative staining	1 (4%)	3 (30%)	7 (50%)	2 (66.7%)
<b>MSH2</b>				
Positive staining	25 (100%)	8 (80%)	14 (100%)	3 (100%)
Negative staining	–	2 (20%)	–	–
<b>p53</b>				
G0	5 (20%)	–	2 (14.3%)	–
G1	4 (16%)	2 (20%)	6 (42.9%)	–
G2	2 (8%)	2 (20%)	1 (7.1%)	1 (33.3%)
G3	14 (56%)	6 (60%)	5 (35.7%)	2 (66.7%)
<b>Ki-67</b>				
G1	–	–	2 (14.3%)	–
G2	8 (32%)	3 (30%)	7 (50%)	1 (33.3%)
G3	17 (68%)	7 (70%)	5 (35.7%)	2 (66.7%)

Adenocarcinoma NOS: adenocarcinoma not otherwise specified; MLH1: mutL homolog 1; MSH2: mutS homolog 2

mas NOS, mucinous adenocarcinomas, and signet-ring cell carcinomas. There was a statistically significant difference between adenocarcinoma NOS (negative staining in 4%) and signet-ring cell carcinomas (66.7% negative staining) in terms of negative staining with MLH1 ( $p=0.023$ ). There was no statistically significant difference between adenocarcinomas with mucinous component (30% negative staining) and mucinous adenocarcinomas (50% negative staining) in terms of the MLH1-negative staining ( $p=0.421$ ). Adenocarcinomas with mucinous component (negative staining in 20%) and mucinous adenocarcinomas (negative

staining were not observed) showed no statistically significant difference between each other in terms of the MSH2-negative staining ( $p=0.163$ ) (Figure 11). There was no statistically significant difference in terms of the MLH1-negative staining between mucinous adenocarcinomas (negative staining in 50%) and signet-ring cell carcinomas (negative staining in 66.7%) ( $p>0.05$ ) (Figure 12). There was no statistically significant difference between adenocarcinomas with a mucinous component (30% negative staining) and signet-ring cell carcinoma (66.7% negative staining) in terms of the MLH1-negative staining ( $p=0.510$ ). There

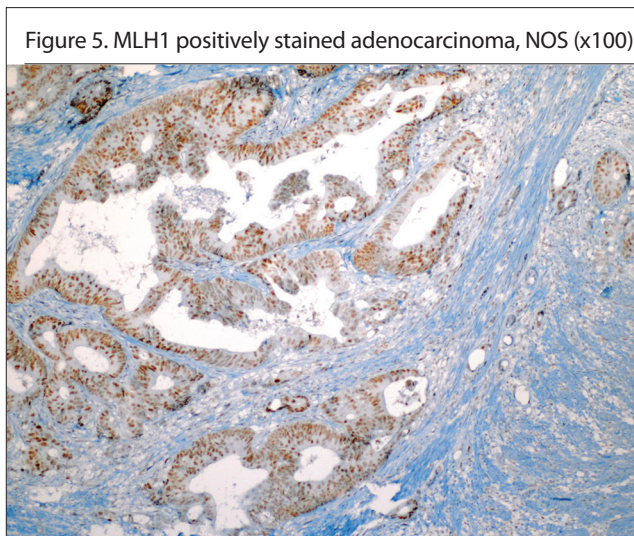
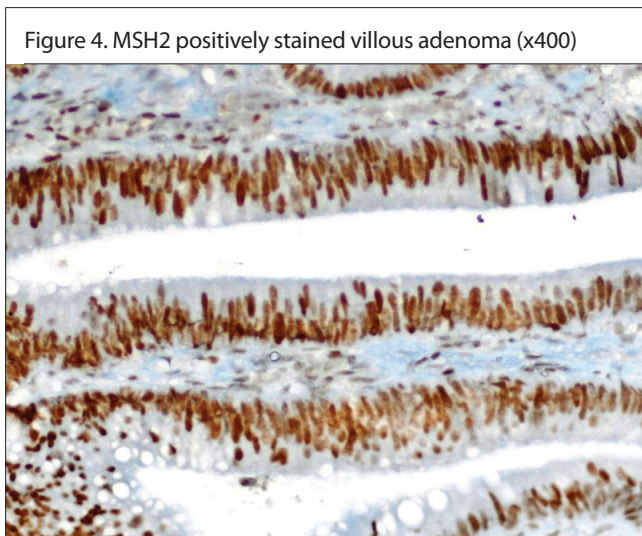
**Table 3.** Comparison of the MLH1 and MSH2 staining with other histopathological findings in CRCs n (%)

	MLH1+	MLH1-	P	MSH2+	MSH2-	P
<b>Gender</b>						
Female	15 (38.5%)	7 (53.8%)	0.331	22 (44%)	-	0.502
Male	24 (61.5%)	6 (46.2%)		28 (56%)	2 (100%)	
<b>Differentiation</b>						
Well differentiated	3 (7.7%)	-		3 (6%)	-	
Moderately differentiated	25 (64.1%)	4 (30.8%)		27 (54%)	2 (100%)	
Poorly differentiated	3 (7.7%)	-		3 (6%)	-	
Not applied	8 (20.5%)	9 (69.2%)		17 (34%)	-	
<b>Histological grade</b>						
Low	28 (71.8%)	4 (30.8%)	0.021	30 (60%)	2 (100%)	0.517
High	11 (28.2%)	9 (69.2%)		20 (40%)	-	
<b>pT</b>						
pTis	1 (2.6%)	-		1 (2%)	-	
pT1	-	-		-	-	
pT2	6 (15.4%)	2 (15.4%)		8 (16%)	-	
pT3	28 (71.8%)	8 (61.5%)		34 (68%)	2 (100%)	
pT4a	4 (10.3%)	2 (15.4%)		6 (12%)	-	
pT4b	-	1 (7.7%)		1 (2%)	-	
<b>Necrosis</b>						
Present	26 (66.7%)	8 (61.5%)	0.747	33 (66%)	1 (50%)	1.000
Absent	13 (33.7%)	5 (38.5%)		17 (34%)	1 (50%)	
<b>Perineural invasion</b>						
Present	10 (25.6%)	4 (30.8%)	0.729	14 (28%)	-	1.000
Absent	29 (74.4%)	9 (69.2%)		36 (72%)	2 (100%)	
<b>Lymphatic invasion</b>						
Present	16 (41%)	6 (46.2%)	1.000	21 (42%)	1 (50%)	1.000
Absent	23 (59%)	7 (53.8%)		29 (58%)	1 (50%)	
<b>Macroscopy</b>						
Ulcerovegetative	32 (82.1%)	9 (69.2%)		40 (80%)	1 (50%)	
Ulcerative	3 (7.7%)	2 (15.4%)		4 (8%)	1 (50%)	
Annular	2 (5.1%)	1 (7.7%)		3 (6%)	-	
Vegetative	1 (2.6%)	1 (7.7%)		2 (4%)	-	
Polypoid	1 (2.6%)	-		1 (2%)	-	
<b>Lymph node invasion</b>						
Present	6 (41%)	6 (46.2%)	1.000	21 (42%)	1 (50%)	1.000
Absent	23 (59%)	7 (53.8%)		29 (58%)	1 (50%)	

**Table 3.** Comparison of the MLH1 and MSH2 staining with other histopathological findings in CRCs n (%) (Continue)

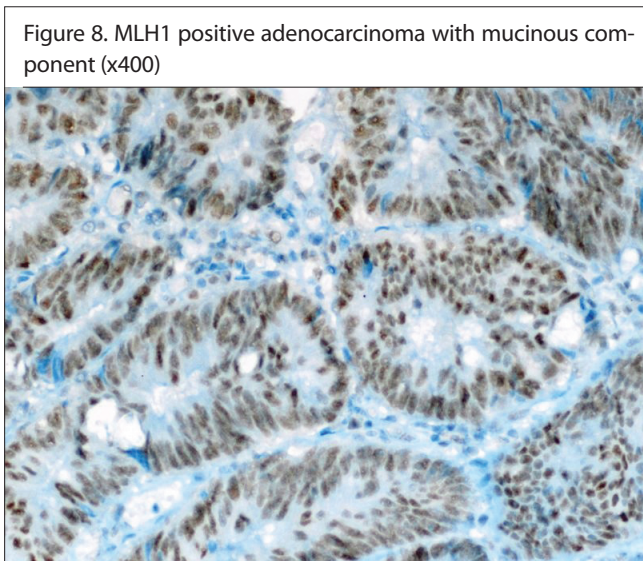
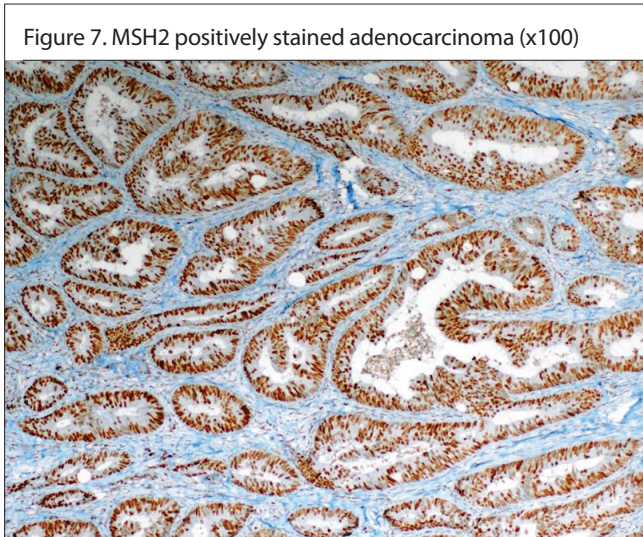
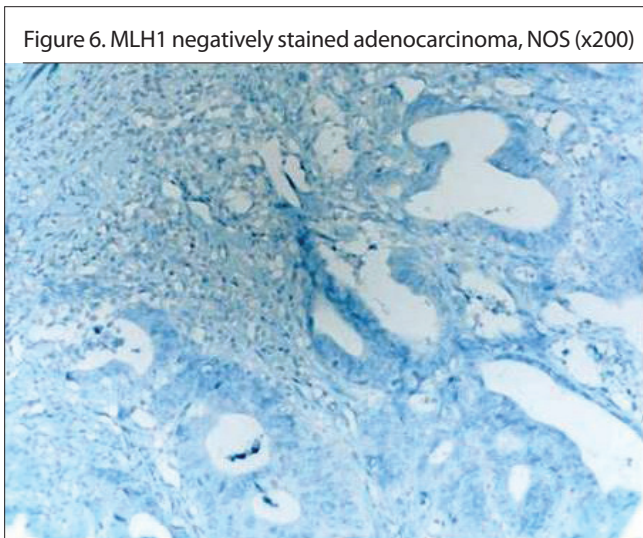
	MLH1+	MLH1-	P	MSH2+	MSH2-	P
<b>N</b>						
N0	23 (59%)	7 (53.8%)		29 (58%)	1 (50%)	
N1a	4 (10.3%)	-		4 (8%)	-	
N1b	5 (12.8%)	4 (30.8%)		8 (16%)	1 (50%)	
N2a	4 (10.3%)	1 (7.7%)		5 (10%)	-	
N2b	3 (7.7%)	1 (7.7%)		4 (8%)	-	
<b>Tumor nodule</b>						
Present	3 (7.7%)	2 (15.4%)	0.589	5 (10%)	-	1.000
Absent	36 (92.3%)	11 (84.6%)		45 (90%)	2 (100%)	
<b>Stromal reaction</b>						
Mild	10 (25.6%)	3 (23.1%)		13 (26%)	-	
Moderate	25 (64.1%)	10 (76.9%)		33 (66%)	2 (100%)	
Severe	4 (10.3%)	-		4 (8%)	-	
<b>Intratumoral lymphocytic response</b>						
None	7 (17.9%)	2 (15.4%)		9 (18%)	-	
Mild to moderate	28 (71.8%)	5 (38.5%)		32 (64%)	1 (50%)	
Marked	4 (10.3%)	6 (46.2%)		9 (18%)	1 (50%)	
<b>Crohn-like response</b>						
None	27 (69.2%)	5 (38.5%)	0.048	31 (62%)	1 (50%)	1.000
Mild to moderate	10 (25.6%)	5 (38.5%)		15 (30%)	-	
Marked	2 (5.1%)	3 (23.1%)		4 (8%)	1 (50%)	

CRCs: colorectal adenocarcinomas; MLH1: mutL homolog 1; MSH2: mutS homolog 2



was no statistically significant difference between adenocarcinomas with mucinous component (negative staining in 20%) and

signet-ring cell carcinomas (negative staining was not observed in terms of the MSH2-negative staining ( $p > 0.05$ ) (Figure 13).

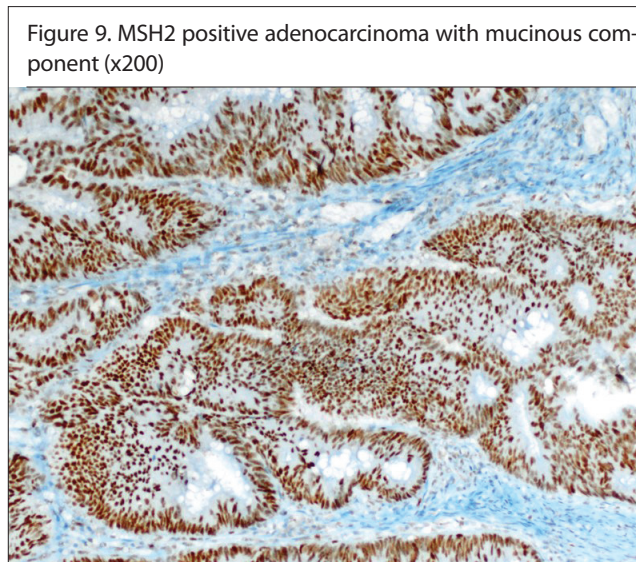


The intratumoral lymphocytic response was not observed in 15.4% (2 cases) of the MLH1-negative cases. The intratumoral lymphocytic response was mild to moderate in 38.5% (5 cas-

**Table 4. Comparison of the MLH1 and MSH2 staining in CRCs between previous studies and our study n (%)**

	Negative staining with MLH1	Negative staining with MSH2
Anderson et al.	177 (21%) (When negative staining is considered negative in one of the 4 mismatch repair proteins)	
Kenney et al.	13 (9.3%)	6 (4.3%)
Kumarasinghe et al.	12 (11%)	1 (1%)
Erdamar et al.	29 (39.2%)	5 (6.8%)
Lanza et al.	96 (13.4%)	18 (2.5%)
Jover et al.	11 (6.4%)	2 (1.16%)
Lindor et al.	228 (27.8%)	98 (11.9%)
Our study	13 (25%)	2 (3.8%)

CRCs: colorectal adenocarcinomas; MLH1: mutL homolog 1; MSH2: mutS homolog 2



es) and was significant in 46.2% (6 cases) of the MLH1-negative cases. Half of the MSH2-negative cases had mild-moderate intratumoral lymphocytic response, and half of them had marked intratumoral lymphocytic response. Crohn-like response was not seen in 38.5% (5 cases) of the MLH1-negative cases. Crohn-like response was observed in 38.5% (5 cases) of mild to moderate and was marked in 23.1% (3 cases) of the MLH1-negative cases. A significant statistical relationship was found between the presence of Crohn-like response and the MLH1-negative staining ( $p=0.048$ ). A positive correlation was found between the MLH1-negative staining and intratumoral lymphocytic response ( $p=0.048$ ,  $r=0.267$ ) and Crohn-like response ( $p=0.031$ ,  $r=0.292$ ). A positive correlation was found between the MLH1-negative staining and intratumoral lymphocytic response ( $p=0.048$ ,  $r=0.267$ ) and Crohn-like response ( $p=0.031$ ,

Figure 10. MLH1 positive mucinous adenocarcinoma (x400)

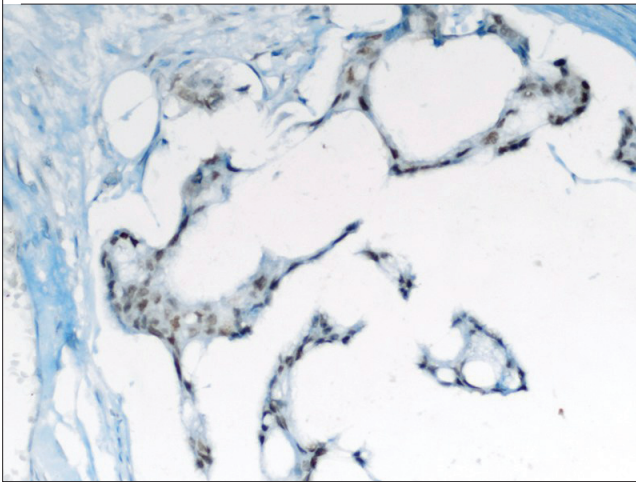


Figure 13. MSH2 positive signet-ring cell carcinoma (x400)

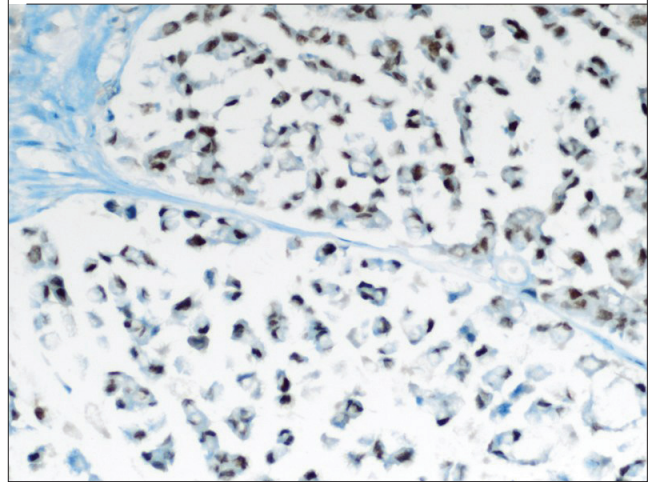


Figure 11. MSH2 positive mucinous adenocarcinoma (x200)

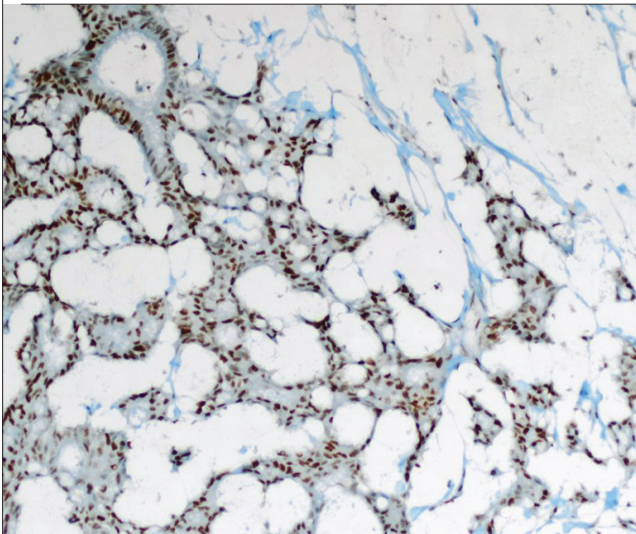


Figure 14. Positive correlation was found between the MLH1-negative staining and the intratumoral lymphocytic response

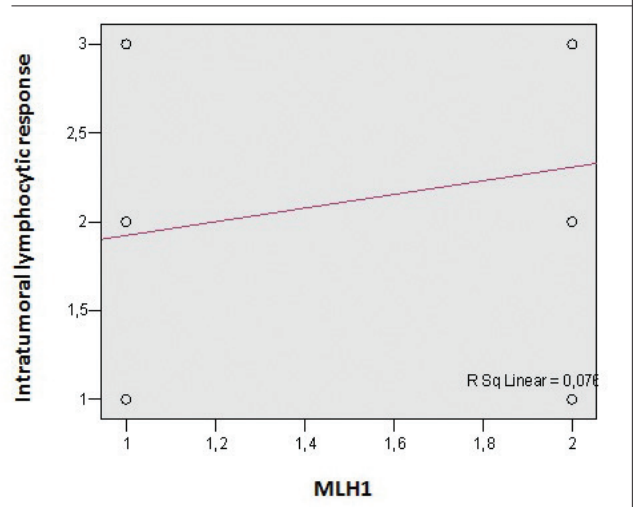


Figure 12. MLH1 positive signet-ring cell carcinoma (x400)

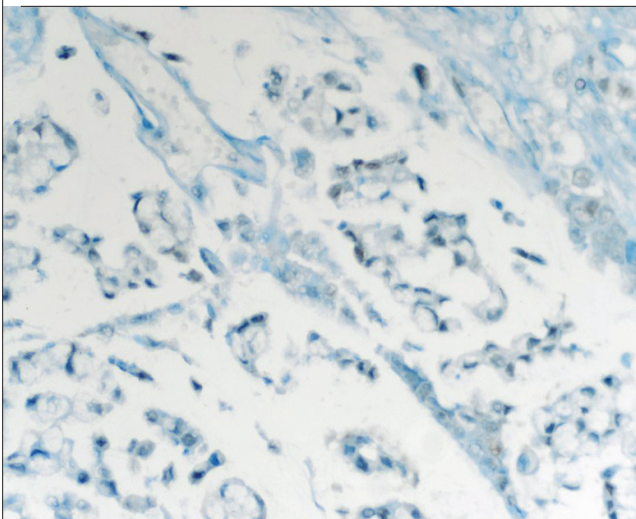


Figure 15. Positive correlation was found between the MLH1-negative staining and a Crohn-like response

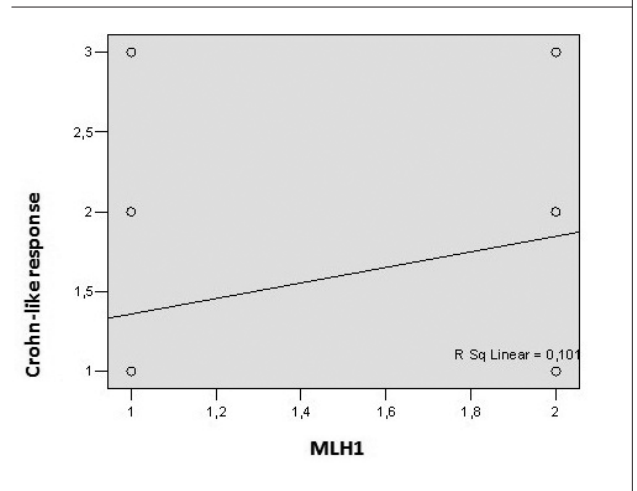




Figure 16. p53 staining in adenocarcinoma (G3) (x100)

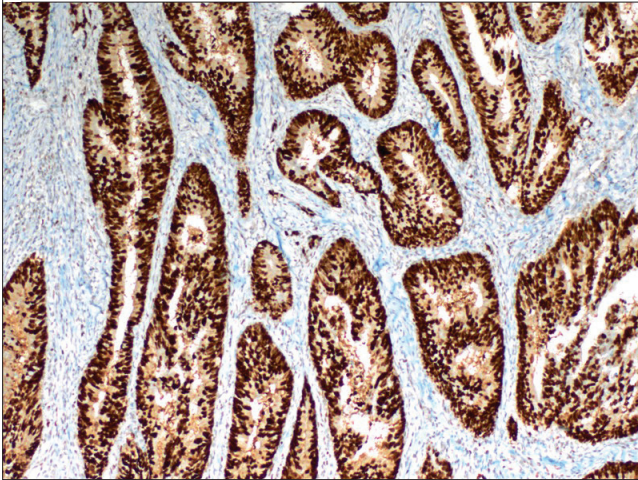
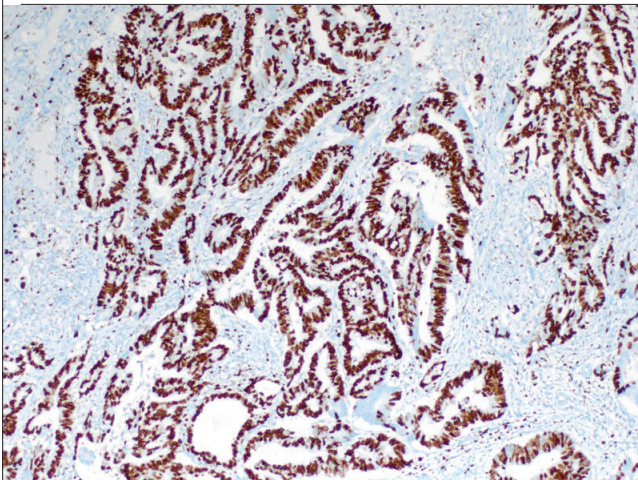


Figure 17. Ki-67 staining in adenocarcinoma (G3) (x100)



$r=0.292$ ) (Figures 14, 15). There was no statistically significant correlation between the intratumoral lymphocytic response/presence of the Crohn-like response and the MSH2-negative staining ( $p>0.05$ ). No significant statistical relationship was found between the MLH1 and MSH2 and the p53 and Ki-67 staining ( $p>0.05$ ) (Figures 16, 17).

## DISCUSSION

Colorectal adenomas are common lesions, and their incidence increases especially over the age of 50 (1, 2). In our study, the mean age was 61 years. Of all the patients, only seven cases were under the age of 50 (14%). It is known that many factors such as gender, race, ethnicity, body mass index, lifestyle, nutrition, and drug use affect the incidence of adenomas (2). In our study, 42% of the cases were female, 58% were male, and the frequency of polyps was higher in males. In the literature, adenomas have a high incidence of distal colon localization under 60 years of age, while there was an increasing incidence of proximal colon localization over 60 years (2). In our study, when the cases were grouped as over and under 50 years old, no significant statistical relation was found between the groups and tumor localization ( $p>0.05$ ).

The polyp diameter is the most important factor in determining the risk of carcinoma in an adenoma (2). When we compared the dysplasia grades in different sizes of polyps in our study, it was statistically determined that polyps with high-grade dysplasia (mean diameter 1.65 cm) had larger dimensions than polyps with low-grade dysplasia (mean diameter 0.76 cm) ( $p=0.005$ ). In a study of 13,992 polypectomy cases, it was found that advanced histological features and cancer risk increased in polyps that were 1 cm in diameter or larger (8, 9). In our study, villous adenomas were found to be larger than tubulovillous and tubular adenomas, and tubulovillous adenomas were found to be larger than tubular adenomas. We found a statistically significant relationship between the histological type and size. There was no statistically significant relationship between gender and histological type in our study.

In our study, positive staining with MLH1 and MSH2 was detected in all of the adenomatous polyps. Basterra et al. (10) found negative staining with MLH1 and PMS2 in 6 cases, PMS2 in 2 cases, MSH6 in 1 case, and MSH2 in a study of 187 adenomatous polyps with high-grade dysplasia. The study by Kang et al. (11) included advanced adenomas in patients aged 40 years, and less and advanced adenomas in patients aged 50 years and over, as a control group. In this study, cases with the MLH1-negative staining were found in tubular morphology and in the young patient group. Balbinotti et al. (3) did not detect the loss of MLH1 and MSH2 in hyperplastic polyps in a study of 138 cases. They detected negative staining in 20% adenomas with MLH1 and 15.5% with MSH2. In this study, the MLH1 and MSH2 staining were not correlated with age, gender, the adenoma size, localization, histologic type of adenoma, and grade of dysplasia. Hawkins et al. (4) studied the polyps that were detected in CRC resection materials. In this study, hyperplastic polyps localized in the right colon were found to be associated with MSI colorectal carcinomas, and negative staining with MLH1 was detected in these polyps. So, it was suggested that serrated polyps could be the precursor lesions of MSI CRCs.

Sporadic colorectal carcinoma is more common in men than in women, and the incidence is increasing with age. CRC is rarely seen under 40 years of age without genetic predisposing factors or other predisposing factors such as inflammatory bowel disease. Macroscopically, most CRCs are described as ulcerovegetative (1). In our study, tumors were macroscopically 78% ulcerovegetative, 9.6% ulcerative, 5.8% annular, 3.8% vegetative, and 1.9% polypoid. In the literature, carcinomas of the proximal splenic flexure have been described as showing a more exophytic growth pattern, while carcinomas of the descending colon and rectum have been described as showing a more endophytic and annular growth pattern (1). In our study, ulcerovegetative appearance was the most common type, whereas we found annular tumors more frequently in the right colon and ulcerative tumors more frequently in the left colon.

The microsatellite instability status in sporadic colorectal carcinomas is accepted as a prognostic and predictive factor (1). High-frequency microsatellite instability (MSI-H) tumors have a better prognosis than low-frequency MSI/microsatellite stable

(MSI-L/MSS) ones. MSI-H tumors show a poor response to 5-fluorouracil and oxaliplatin, and MSI-H CRCs are sensitive to irinotecan treatment. MSI-H CRCs provide a better survival after adjuvant irinotecan treatment (8). Lanza et al. (12) found a better clinical outcome in the MLH1/MSH2-negative tumors in Stage 2 and 3 colorectal cancers in a colorectal carcinoma study involving 718 patients.

An indirect immunohistochemical MSI diagnosis can be given as a result of developing specific antibodies against the mismatch repair proteins, which are gene products of the mismatch repair system (1). A high level of agreement was found between the immunohistochemically detected MLH1 and MSH2 expressions and the MSI status determined by molecular methods (5–8). Lindor et al. (5) demonstrated 27.8% of negative staining with MLH1 and 11.9% negative staining with MSH2 in a study involving 1144 cases. In this study, the immunohistochemical detection of MSI with MLH1 and MSH2 was found to be 92.3% sensitive and 100% specific. Lanza et al. (12) reported 13.4% negative staining with MLH1 and 2.5% negative staining with MSH2 in a study including 718 cases, and the immunohistochemical staining of MLH1 and MSH2 was found to be consistent with the MSI status detected by molecular techniques. Jover et al. (7) showed negative staining with MLH1 in 6.4% of the cases and negative staining with MSH2 in 1.16% of the cases in their study. Erdamar et al. (13) detected 39.2% negative staining with MLH1 and 6.8% negative staining with MSH2 in a study including 77 cases. Kumarasinghe et al. (14) reported 11% negative staining with MLH1 and 1% negative staining with MSH2 in a total of 112 cases. Kenney et al. (15) reported 9.3% negative staining with MLH1 and 4.3% negative staining with MSH2 in a total of 141 cases. Andersen et al. (16) reported 21% negative staining (when negative staining was considered negative in at least one of the four mismatch repair proteins) in a study including 833 cases. In our study, we observed negative staining with MLH1 in 25% of all cases and with MSH2 in 3.8% of the cases. Similar to literature, the percentages of the MLH1-negative stained cases were higher than the MSH2-negative stained cases. The percentage of the MLH1-negative staining that we observed in our study was similar to the results by Lindor et al. (5). The percentage of the MSH2-negative staining that we detected in our study was similar to the results reported by Lanza et al. (12) and Kenney et al. (15) (Table 4).

Lanza et al. (12) found that the MLH1- and MSH2-negative cases were seen more frequently in women in their study. Erdamar et al. (13) reported that all of the MSH2-negative cases were found in women in their study. Similar to these studies, Andersen et al. (16) observed that MSI tumors were more frequent in women. We did not find a significant statistical relationship between gender and the MLH1 and MSH2 negativity in our study. Similar to our findings, Jover et al. (7) found no statistically significant relationship between the MLH1- and MSH2-negative staining and age and gender. Lanza et al. (12) found that the MLH1- and MSH2-negative cases were more common in subjects over 70 years of age when compared to positive cases. Erdamar et al. (13) found that the MSH2-negative cases were more common in subjects over 50 years of age. In the study by Andersen et al. (16), there was no significant relationship between the MSI status and

age for CRC. We found no statistically significant relationship between the age groups and MLH1 and MSH2.

Andersen et al. (16) found that MSI tumors show the right colon localization more frequently. Lanza et al. (12) found that the MLH1- and MSH2-negative cases were located in the proximal colon. Erdamar et al. (13) reported that the majority of MSH2-negative tumors were located in the right colon. In our study, we found that the rate of MLH1-negative stained tumors was higher in the right colon than in the left colon.

Microsatellite instability tumors frequently exhibit an expansile growth pattern, with mucinous, medullary, or low differentiated morphology and marked host response (1, 16, 17). Most of the MSI tumors were detected in the histologic type of mucinous carcinoma (18). However, MSI was not detected in the majority of mucinous carcinomas (18). Mucinous carcinomas have been shown to be associated with good prognosis when showing MSI (1, 18).

In a study involving 323 sporadic CRC cases, Alexander et al. (19) reported that 15% of MSI-H tumors and 5% of MSS tumors were mucinous carcinomas. When the MSI-H and MSS tumor groups were compared in this study, tumors with mucinous component were found more frequently in the MSI-H group. Andersen et al. (16) reported MSI tumors were mostly mucinous, poorly differentiated, and of medullary carcinoma morphology. Erdamar et al. (13) observed no significant relationship between the MLH1/MSH2 expression and histologic type. Lanza et al. (12) found that the MLH1- and MSH2-negative cases showed a poorly differentiated morphology, mucinous and medullary histology, and marked Crohn-like response. Jover et al. (7) found a significant association between the tumor grade and the MLH1- and MSH2-negative staining; however, they did not find any statistically significant relationship between age, gender, tumor size, the pathological stage, mucin production, and MLH1/MSH2 staining. In our study, there was no statistically significant difference between adenocarcinoma, NOS, and adenocarcinoma with mucinous component in terms of negative staining with MLH1 and MSH2. However, similar to the literature, we found a statistically significant difference in our study between adenocarcinoma, NOS, and mucinous adenocarcinoma in terms of the MLH1-negative staining when compared with each other.

Lanza et al. (12) found that the MLH1- and MSH2-negative cases were poorly differentiated morphologically. Jover et al. (7) found a significant relationship between a high tumor grade and the MLH1- and MSH2-negative staining. Similarly, in our study, we found a statistically significant relationship between the histological grade and the MLH1 negativity. Signet-ring cell carcinomas with MSI show a better prognosis (1). Alexander et al. (19) found that 13% of the MSI-H tumors contained signet-ring cells. In the study by Andersen et al. (16), 33.3% of signet-ring cell carcinomas were detected as MSI. In our study, adenocarcinoma, NOS, and signet-ring cell carcinomas showed a statistically significant difference in terms of the MLH1-negative staining when compared with each other.

Tumor-infiltrating lymphocytes were found to be associated with MSI and good prognosis (18). Frequent MSI-H related morpholog-

ical findings, such as peritumoral lymphocytic response and tumor-infiltrating lymphocytes, are positive prognostic findings (1, 19). Alexander et al. (19) detected significant intraepithelial lymphocytosis in 21% of MSI-H tumors, while it was detected in only 3% of MSS tumors. In our study, we found a positive correlation between the MLH1-negative staining and intratumoral lymphocytic response in the CRCs. In half of the MSH2-negative cases, moderately marked intratumoral lymphocytic response were observed.

Crohn-like inflammation was found to be associated with good prognosis (18, 20, 21). Alexander et al. (19) observed no statistically significant difference in the presence of Crohn-like inflammatory responses in MSI-H and MSS tumors. Lanza et al. (12) found that the MLH1- and MSH2-negative cases showed a marked Crohn-like response. We found a statistically significant relationship between the Crohn-like response and MLH1-negative staining.

Andersen et al. (16) found less lymph node involvement in MSI tumors. We did not find any significant statistical relationship between the presence of lymphatic invasion/lymph node involvement and the MLH1/MSH2 staining.

## CONCLUSION

We conclude that routine immunohistochemical staining for MLH1 and MSH2 may be useful in the detection of MSI in tumors in the presence of mucinous and poorly differentiated morphology, tumor-infiltrating lymphocytes, and Crohn-like inflammatory response in the histopathological examination of colorectal tumors.

**Ethics Committee Approval:** Ethics committee approval was received for this study from the ethics committee of Recep Tayyip Erdoğan University School of Medicine (Approval date: 24 April 2016; number: 2016/18).

**Informed Consent:** Written informed consent was obtained from patients who participated in this study.

**Peer-review:** Externally peer-reviewed.

**Author Contributions:** Concept - R.Y., R.B.; Design - R.Y., R.B.; Supervision - R.Y., R.B.; Resources - R.Y., R.B., R.A.A., A.P.; Materials - R.Y., R.B., R.A.A., A.P.; Data Collection and/or Processing - R.B., R.Y.; Analysis and/or Interpretation - R.Y., R.B.; Literature Search - R.Y., R.B.; Writing Manuscript - R.Y., R.B.; Critical Review - R.Y., R.B.

**Conflict of Interests:** The authors have no conflicts of interest to declare.

**Financial Disclosure:** This study has received financial support from Recep Tayyip Erdoğan University Scientific Research Support Fund.

## REFERENCES

1. Fred T, Bosman FC, Ralph H, Hruban Neil D. Theise, ed. *Tumours of the colon and rectum*. 4 ed. WHO Classification of Tumours of the Digestive System. 2010, International Agency for Research on Cancer: Lyon. 131-81.
2. Strum WB. Colorectal Adenomas. *N Engl J Med* 2016; 374: 1065-75.
3. Balbinotti RA1, Ribeiro U Jr, Sakai P, Safatle-Ribeiro AV, Balbinotti SS, Scapulatempo C, et al. hMLH1, hMSH2 and cyclooxygenase-2 (cox-2) in sporadic colorectal polyps. *Anticancer Res* 2007; 27: 4465-71.
4. Hawkins NJ, Ward RL. Sporadic colorectal cancers with microsatellite instability and their possible origin in hyperplastic polyps and serrated adenomas. *J Natl Cancer Inst* 2001; 93: 1307-13.
5. Lindor NM, Burgart LJ, Leontovich O, Goldberg RM, Cunningham JM, Sargent DJ, et al. Immunohistochemistry versus microsatellite instability testing in phenotyping colorectal tumors. *J Clin Oncol* 2002; 20: 1043-8.
6. Overbeek LI, Ligtenberg MJ, Willems RW, Hermens RP, Blokx WA, Dubois SV, et al. Interpretation of immunohistochemistry for mismatch repair proteins is only reliable in a specialized setting. *Am J Surg Pathol* 2008; 32: 1246-51.
7. Jover R, Payá A, Alenda C, Poveda MJ, Peiró G, Aranda FI, et al. Defective mismatch-repair colorectal cancer: clinicopathologic characteristics and usefulness of immunohistochemical analysis for diagnosis. *Am J Clin Pathol* 2004; 12: 389-94.
8. Cawkwell L, Gray S, Murgatroyd H, Sutherland F, Haine L, Longfellow M, et al. Choice of management strategy for colorectal cancer based on a diagnostic immunohistochemical test for defective mismatch repair. *Gut* 1999; 45: 409-15.
9. Lieberman D, Moravec M, Holub J, Michaels L, Eisen G. Polyp size and advanced histology in patients undergoing colonoscopy screening: implications for CT colonography. *Gastroenterology* 2008; 135: 1100-5.
10. Basterra M, Gomez M, Mercado Mdel R, Irisarri R, Amorena E, Arropide A, et al. Prevalence of altered mismatch repair protein nuclear expression detected by immunohistochemistry on adenomas with high-grade dysplasia and features associated with this risk in a population-based study. *Gastroenterol Hepatol* 2016; 39: 500-7.
11. Kang KJ, Min BH, Ryu K, Kim KM, Kim ER, Kim JY, et al. Clinical usefulness of microsatellite instability test in Korean young patients with high-risk features associated with adenoma. *Clin Res Hepatol Gastroenterol* 2012; 36: 378-83.
12. Lanza G, Gafà R, Santini A, Maestri I, Guerzoni L, Cavazzini L. Immunohistochemical test for MLH1 and MSH2 expression predicts clinical outcome in stage II and III colorectal cancer patients. *J Clin Oncol* 2006; 24: 2359-67.
13. Erdamar S, Ucaryılmaz E, Demir G, Karahasanoglu T, Dogusoy G, Dirican A, et al. Importance of MutL homologue MLH1 and MutS homologue MSH2 expression in Turkish patients with sporadic colorectal cancer. *World J Gastroenterol* 2007; 13: 4437-44.
14. Kumarasinghe AP, de Boer B, Bateman AC, Kumarasinghe MP. DNA mismatch repair enzyme immunohistochemistry in colorectal cancer: a comparison of biopsy and resection material. *Pathology* 2010; 42: 414-20.
15. Kenney B, Deng Y, Mitchell K. Expression of p27, COX-2, MLH1, and MSH2 in young patients with colon carcinoma and correlation with morphologic findings. *Hum Pathol* 2013; 44: 591-7.
16. Andersen HS, Bertelsen CA, Henriksen R, Campos AH, Kristensen B, Ingeholm P, et al. The pathological phenotype of colon cancer with microsatellite instability. *Dan Med J* 2016; 63: pii: A5198.
17. Greenston JK, Bonner JD, Ben-Yzhak O. Phenotype of microsatellite unstable colorectal carcinomas: Well-differentiated and focally mucinous tumors and the absence of dirty necrosis correlate with microsatellite instability. *Am J Surg Pathol* 2003; 27: 563-70.
18. Compton CC. Colorectal carcinoma: diagnostic, prognostic, and molecular features. *Mod Pathol* 2003; 16: 376-88.
19. Alexander J, Watanabe T, Wu TT, Rashid A, Li S, Hamilton SR. Histopathological identification of colon cancer with microsatellite instability. *Am J Pathol* 2001; 158: 527-35.
20. Graham DM, Appelman HD. Crohn's-like lymphoid reaction and colorectal carcinoma: a potential histologic prognosticator. *Mod Pathol* 1990; 3: 332-5.
21. Harrison JC, Dean PJ, el-Zeky F, Vander Zwaag R. From Dukes through Jass: pathological prognostic indicators in rectal cancer. *Hum Pathol* 1994; 25: 498-505.

### How to cite:

Yılmaz R, Bedir R, Akdoğan RA, Pergel A. Evaluation of Microsatellite Instability in Colorectal Adenomas and Carcinomas by Immunohistochemistry and a Comparison of Histopathological Features. *Eur J Ther* 2019; 25(1): 28–38.