

Images in cardio-thoracic surgery

Intrathoracic pneumatosis cystoides intestinalis associated with Bochdalek hernia and lung hypoplasia

Sadi Kaya^a, Gokturk Findik^{a,*}, Hasan Türüt^b, Funda Demirag^c

^a Department of Thoracic Surgery, Surgery Education and Research Hospital, Ankara, Turkey

^b Department of Thoracic Surgery, Rize University, School of Medicine, Rize, Turkey

^c Department of Pathology Ataturk Chest Diseases and Chest, Surgery Education and Research Hospital, Ankara, Turkey

Received 7 November 2008; received in revised form 21 January 2009; accepted 22 January 2009; Available online 10 March 2009

Keywords: Intrathoracic pneumatosis cystoides intestinalis; Bochdalek hernia; Lung hypoplasia

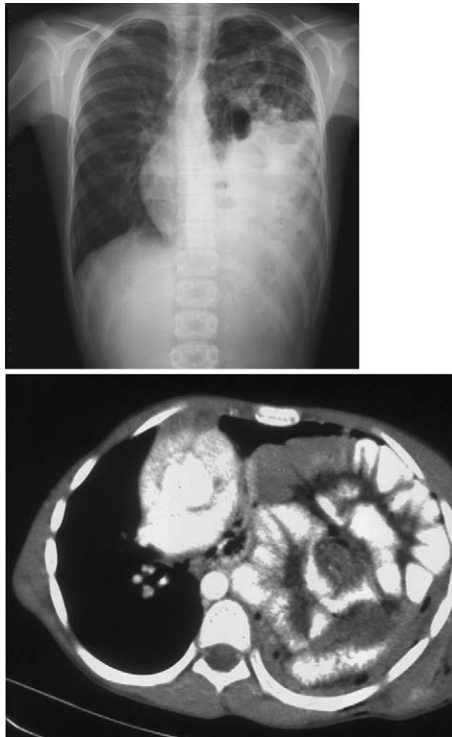


Fig. 1. Preoperative chest X-ray showing a mass-like opacity suggesting bowel loops in the left hemithorax and mediastinal displacement to the right. Thorax computed tomography scan revealing mediastinal shift, total lung atelectasis and location of intra-abdominal organs in the left hemithorax.

A 15-year-old-boy presented with cough and chest pain. Chest X-ray showed ill-defined opacity suggesting bowel loops in the left hemithorax. Thorax CT revealed total lung atelectasis and intrathoracic abdominal viscera (Fig. 1). Lung was found to be hypoplastic and thorax was filled by bowels associated with cystic formations (Fig. 2).

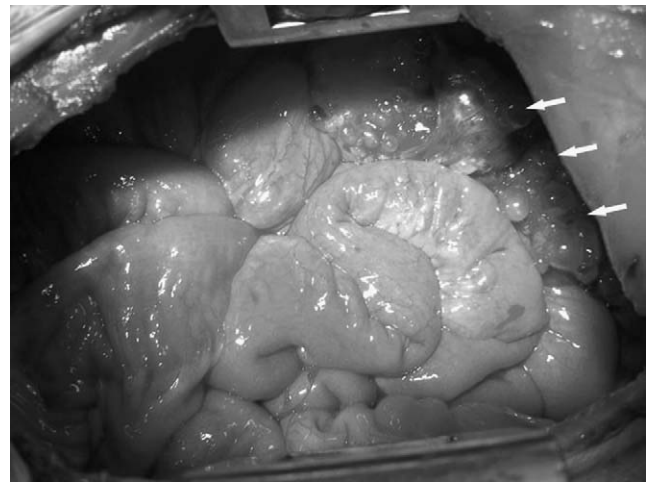


Fig. 2. Intra-operative photo depicting that the thorax was completely filled by bowels and cystic formations filled with gas (white arrows) noticed in one segment of the intestines. Also lung was hypoplastic and there was a defect in the posterior part of diaphragm (Bochdalek hernia).

* Corresponding author. Address: Department of Thoracic Surgery, Ataturk Chest Diseases and Chest Surgery Education and Research Hospital, 06096 Ankara, Turkey. Tel.: +90 3123552110; fax: +90 3123552135.
E-mail address: gokturkfindik@hotmail.com (G. Findik).