

Synergistic application of high-speed rotational atherectomy and intravascular lithotripsy for a severely calcified undilatable proximal left anterior descending coronary artery bifurcation lesion: Case of rotolithoplasty-facilitated DK-CRUSH

Tomasz Pawłowski¹, Jacek Legutko², Paweł Modzelewski¹, Robert J. Gil¹

¹Department of Invasive Cardiology, Center of Postgraduate Medical Education, Warsaw, Poland

²Jagiellonian University Medical College, Institute of Cardiology,

Department of Interventional Cardiology, John Paul II Hospital, Krakow, Poland

Coronary calcified plaques may affect both procedural and long-term outcomes of coronary stenting, resulting in impaired device deliverability, disruption of stent coatings, and poor stent expansion and apposition. A novel intravascular lithotripsy (IVL) method was introduced and recently tested in catheterization laboratories (ShockWave). A 62-year-old male presented with severely calcified proximal left anterior descending artery/diagonal true bifurcation stenosis (Medina 1,1,1) (Fig. 1A, B). The operator's strategy was to perform IVL after small balloon pre-dilation (NC Emerge 2.0 × 12 mm, Boston Scientific Co.), but advancement of the ShockWave (ShockWave Medical Co.) balloon was unsuccessful due to the unfavorable location of the calcium. After several pre-dilations with non-compliant balloons (2.0 mm, 2.5 mm, and 3.0 mm; NC Emerge, Boston Scientific Co.) inflated to

20 atm, the artery was not fully opened and IVL advancement failed. At this stage, the operators decided to perform high-speed rotational atherectomy with 1.5 burr. Subsequently, due to residual large calcific plaque burden after rotablation, the IVL balloon (3.5 × 12 mm) was placed within the lesion and 80 seconds of wave was applied to modify the plaque (Fig. 1C, D). Finally, the diagonal branch was protected with the wire and regular angioplasty was performed. The well-known classic double-kissing crush technique was implemented for the patient. Operators deployed Orsiro 2.5 × 22 mm (15 atm) (Biotronik) in the diagonal branch followed by another Orsiro stent 3.5 × 22 mm (14 atm) (Biotronik) in the left anterior descending artery. The final proximal optimization technique with 3.5 × 8 mm (16 atm) (NC Emerge; Boston Scientific Co.) was used and achieved an excellent angiographic result (Fig. 1E, F).

Conflict of interest: None declared

Address for correspondence: Tomasz Pawłowski, MD, PhD, Department of Invasive Cardiology, Center of Postgraduate Medical Education, ul. Wołoska 137, 02–507 Warszawa, Poland, tel: +48 22 5081119, e-mail: pawtom@gmail.com

Received: 16.02.2020

Accepted: 9.12.2020

This article is available in open access under Creative Commons Attribution-Non-Commercial-No Derivatives 4.0 International (CC BY-NC-ND 4.0) license, allowing to download articles and share them with others as long as they credit the authors and the publisher, but without permission to change them in any way or use them commercially.

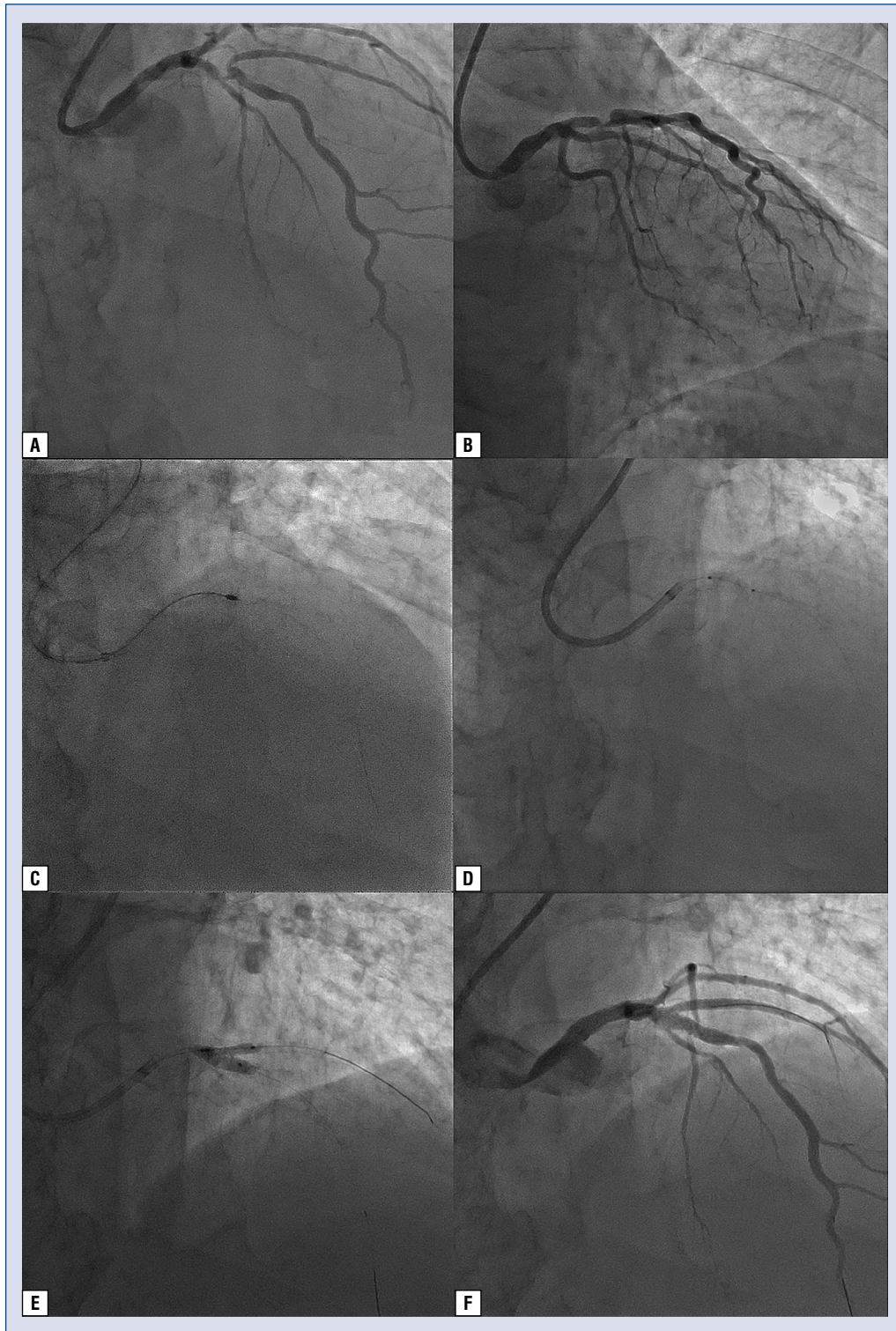


Figure 1. Coronary angioplasty of the left anterior descending artery using RotaShock strategy; **A, B.** Initial visualization of the lesion in the two orthogonal views; **C.** Rotablation with a 1.5-mm burr; **D.** A 3.5 × 12-mm ShockWave balloon; **E, F.** The kissing technique and the final angiographic result. Final kissing inflation was achieved with both non-compliant balloons (NC Emerge, Boston Scientific Co., Marlborough, USA) of 2.5 × 12 mm (14 atm) for the diagonal branch and 3.5 × 12 mm (14 atm) for the main vessel.