

Dentinogenesis imperfecta type II: a case report

• **Bruno Carvalho Albeny Morais** Dental Medicine School, Centro Universitário Católica do Leste de Minas Gerais (Unileste), Ipatinga, MG, Brazil • **Daniel Alves Leite** Dental Medicine School, Centro Universitário Católica do Leste de Minas Gerais (Unileste), Ipatinga, MG, Brazil • **Frederico Marques da Silva** Dental Medicine School, Centro Universitário Católica do Leste de Minas Gerais (Unileste), Ipatinga, MG, Brazil • **Gabriela Caldeira Andrade Americano** Dental Medicine School, Centro Universitário Católica do Leste de Minas Gerais (Unileste), Ipatinga, MG, Brazil • **Erika Storck Cezário** Dental Medicine School, Centro Universitário Católica do Leste de Minas Gerais (Unileste), Ipatinga, MG, Brazil

ABSTRACT | *Objective:* Dentinogenesis imperfecta (DI) type II is a rare dentin development disorder with an autosomal dominant inheritance that affects both functional and aesthetic aspects of deciduous and permanent dentitions. This study reports the clinical case of a patient diagnosed late with this anomaly. *Material and methods:* Male patient, 33 years old, sought dental care complaining of dental aesthetic dissatisfaction. During clinical examination, it was observed that the teeth had a brownish color, with wear and tear of the dental enamel and dentin exposure. Radiographically, the teeth presented the pulp chambers and root canals obliterated, in addition to bulbous crowns. The patient reported that several members of his family had the same condition. The established clinical diagnosis was DI type II. *Conclusion:* In this case, type II dentinogenesis imperfecta was diagnosed late and without adequate therapeutic intervention, causing aesthetic and functional damage to the patient.

DESCRIPTORS | Dentinogenesis Imperfecta; Diagnosis; Case Report.

RESUMO | **Dentinogênese imperfeita tipo II: relato de caso** • *Objetivo:* Dentinogênese imperfeita (DI) tipo II é um distúrbio raro do desenvolvimento da dentina com herança autossômica dominante, afetando aspectos funcionais e estéticos das dentições decídua e permanente. Este estudo relata o caso clínico de um paciente com diagnóstico tardio dessa anomalia. *Materiais e métodos:* Paciente do sexo masculino, 33 anos, procurou atendimento odontológico queixando-se de insatisfação estética dentária. Durante o exame clínico, observou-se que os dentes apresentavam coloração amarronzada, desgaste do esmalte e exposição da dentina. Radiograficamente, os dentes apresentavam as câmaras pulpare e canais radiculares obliterados, além de coroas bulbosas. O paciente relatou que diversos membros de sua família apresentavam o mesmo quadro. O diagnóstico clínico estabelecido foi DI tipo II. *Conclusão:* Neste caso, a dentinogênese imperfeita tipo II foi diagnosticada tardiamente e sem intervenção terapêutica adequada, causando prejuízo estético e funcional ao paciente.

DESCRITORES | Dentinogênese Imperfeita; Diagnóstico; Relato de Caso.

CORRESPONDING AUTHOR | • **Erika Storck Cezário** Dental Medicine School, Center University of Minas Gerais' East • **Bárbara Hellodora Street, 725, Block B, Ipatinga, MG, Brazil**
• **35160-215** E-mail: erika.storck@p.unileste.edu.br

• **Received** July 25, 2020 • **Accepted** Nov. 20, 2020.

• **DOI:** <http://dx.doi.org/10.11606/issn.2357-8041.clrd.2021.172836>

INTRODUCTION

Dentinogenesis imperfecta (DI) is a rare dentin development disorder without the involvement of any systemic disorder. This condition constitutes a genetic autosomal dominant inheritance anomaly, which results in dentin hypomineralization.¹ Clinically, the teeth have a brownish or bluish-gray color, with an opaque aspect.^{2,3} The enamel is often displaced from the dentin due to the alteration in the enamel-dentin junction, leading to the exposure of the dentin, which is quickly worn away due to attrition and may cause the destruction of the dental crown.⁴

The most used classification for DI was proposed by Shields et al.⁵ where this anomaly is categorized into three types: type I DI is associated with imperfect osteogenesis, a hereditary skeletal disorder. Type II DI is the most common and both dentitions are affected, but deciduous teeth are more severely affected than permanent teeth.¹ Radiographically, the teeth have bulbous crowns, cervical constriction, thin roots and early obliteration of the root canals and pulp chambers.^{1,6} The main difference found in type III is the radiographic aspect of the pulp, with the teeth being called ‘cupped teeth’ due to the pulp enlargement associated with very thin dentin thickness. This rare abnormality is found in primary dentition more often and pulp exposures are frequently present. Its occurrence is reported in the city of Brandywine, in the United States.

Although well-accepted, Shields’ classification⁵ is not entirely satisfactory because it is based only on clinical and radiographic aspects, not including aspects of molecular genetics.^{1,3} Dental changes similar to DI can be seen in osteogenesis imperfecta, which is associated with a mutation in the collagen gene COL1A1 or COL1A2. Type I DI is thus a syndromic form and types II and III would be non-syndromic forms of this alteration. Moreover, types II and III, according to Shields’ classification,⁵ are related to the mutation of the dentin sialophosphoprotein gene (DSPP), suggesting that they represent different forms of DI severity.¹

The aesthetic and functional damages caused by this anomaly are reported in the literature by several researchers.^{4,7} Given this context, this study reports the clinical and radiographic findings of a case of type II DI in a young adult patient.

CASE REPORT

Male patient, 33 years old, non-smoker and without systemic impairment, sought dental care at the Dentistry Clinic of the Eastern Minas Gerais University Center (UNILESTE) complaining of dental aesthetic dissatisfaction. The patient reported that since childhood he had aesthetic and functional problems in his teeth, but had never received a diagnosis or treatment. He also reported that several individuals in his family had the same anomaly as shown in Figure 1.

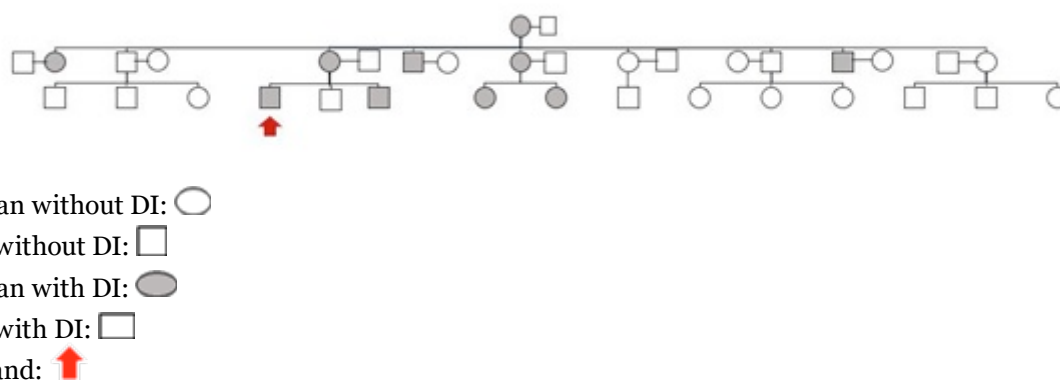


FIGURE 1 | Heredogram of the patient covering 3 generations

Clinical and radiographic aspects

Clinical examination found that the teeth had a brownish color, with advanced wear of the dental enamel and exposure of the dentin to several teeth (Figures 2A to 2C and 3).

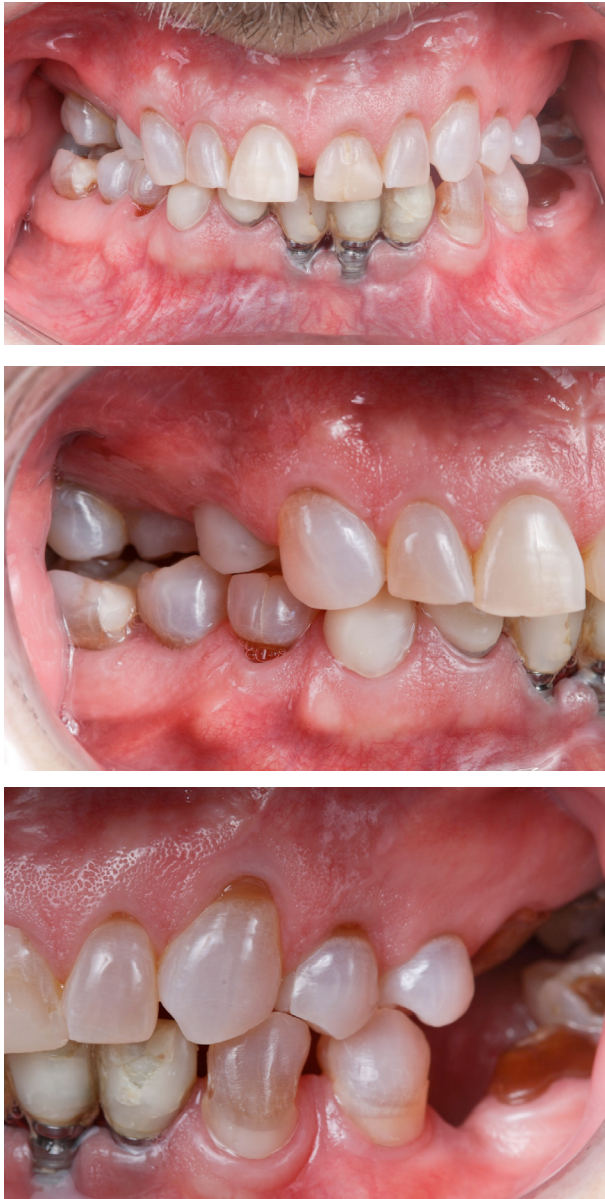

FIGURE 2 | Figure 2A: Buccal view; Figure 2B: Lateral view (right); Figure 2C: Lateral view (left)

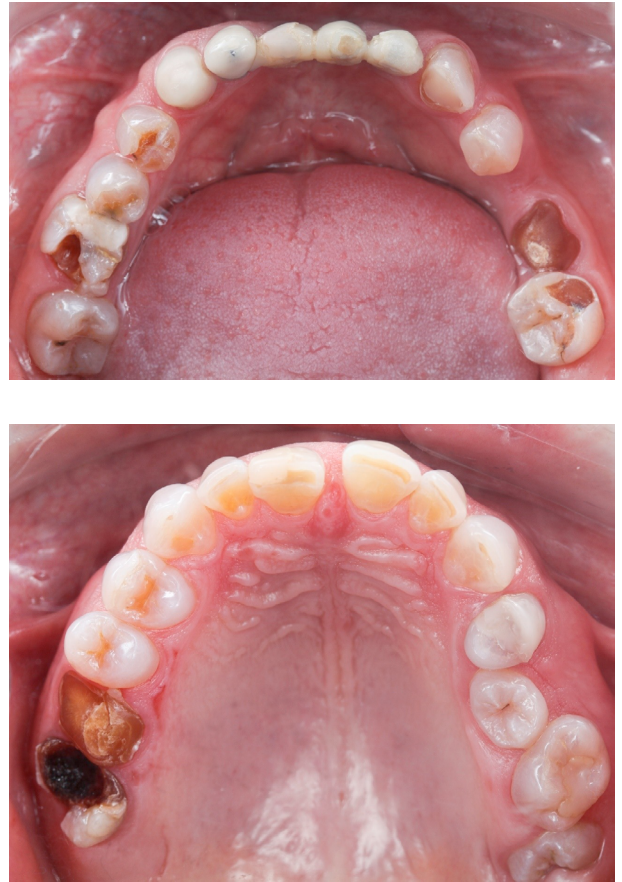

FIGURE 3 | Occlusal view of patient's teeth

Periodontal probing did not reveal a significant probing depth and clinical attachment loss. Teeth 32, 31, and 41 were absent and implants were installed in these regions. Root rest was found on tooth 36, as well as unsatisfactory restorations on teeth 17, 14, 21, 27, 46, and a maladaptive crown on tooth 42. The patient suffered from low self-esteem and shame when speaking and smiling.

Radiographically, all teeth showed obliteration of the pulp chambers and root canals, as well as thin and short roots. The posterior teeth had bulbous crowns and cervical constriction. Teeth 28, 38, and 48 were impacted (Figure 4).

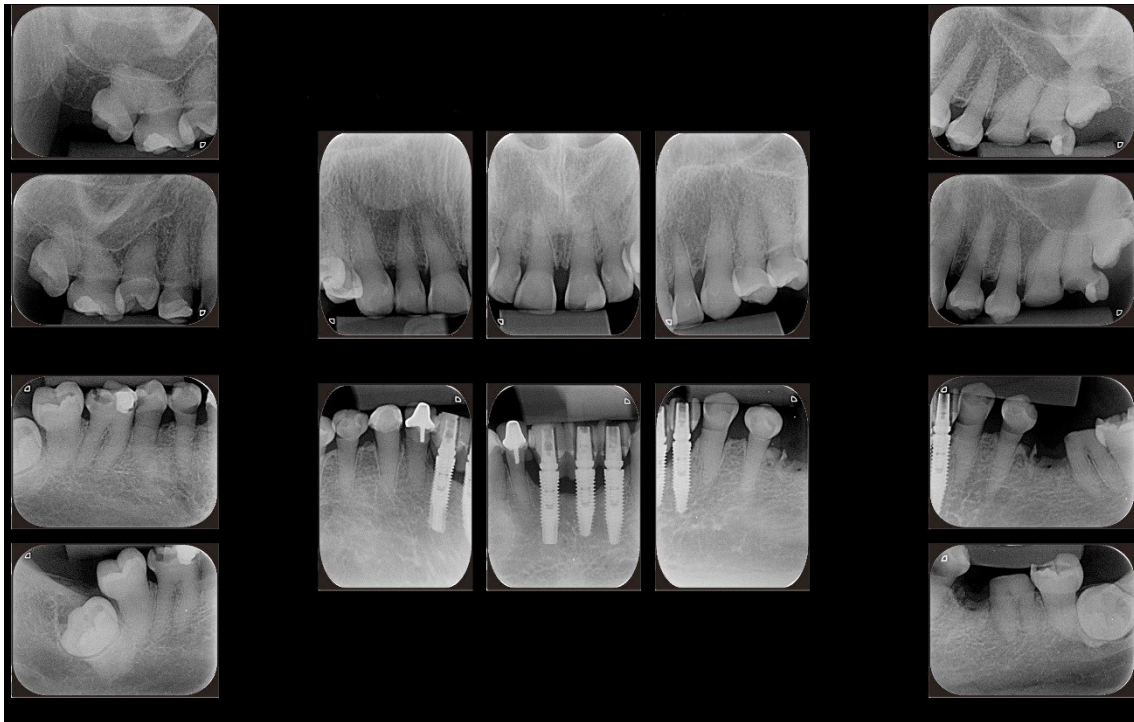


FIGURE 4 | Periapical radiographic examination of the patient's entire mouth

Considering the clinical and radiographic findings, the diagnosis established for the case was type II DI, according to the Shields et al.⁵ classification. The patient signed an informed consent form covering all study procedures.

Proposed treatment plan

Given the complexity of the case, the treatment will be divided into phases. The initial treatment phase for this case will include the extraction of the r 36 (root rest) and 28, 38, and 48 (impacted teeth) and provision of oral hygiene and plaque control instructions for the patient. Since the patient has a reduced vertical occlusal dimension (VOD) and major aesthetic and functional changes digital aesthetic planning will be carried out through Digital Smile Design (DSD), as well as and digital diagnostic waxing. Therefore, the molding of both arches with addition silicone will be done and, from the molds, study models cast in stone plaster

will be obtained. The centric bite will also be recorded in the previously determined VOD and facial arc registration for mounting the models on a semi-adjustable articulator. Digital diagnostic waxing will be performed digitally on the ideal VOD. From the printed waxing, an intra-oral mock-up will be made to define oral rehabilitation to be performed.

DISCUSSION

This case report describes the clinical case of a 33-year-old patient, diagnosed late with type II DI, according to the Shields et al.⁵ classification. Teeth wear caused a loss of dental structure and loss of the vertical dimension of the occlusion, resulting in aesthetic and functional damage to the patient. The literature indicates that many cases of type II DI require complex oral rehabilitation since they depend on the severity of fractures, existing dental attrition, pulp involvement, and the vertical dimension of lost occlusion.^{7,8} Soliman et al.⁷ reported a case of

rehabilitation of an ID patient through restorations in indirect resins of all teeth, restoring aesthetics and function. Other authors described the case of a patient with ID who was rehabilitated by the installation of implants on the posterior teeth and making adhesive restorations on the others. In the case of the current report, planning for the rehabilitation of the patient would involve the extraction of the root rest, installation of implants in the posterior areas, replacement of dentures and restoration of other teeth, contributing to the return of the shape, aesthetics and function of the patient's dentition. It is important to highlight that patients with ID have a lower risk of developing caries when compared with individuals without this anomaly; however, the acute teeth wear with DI can lead to tooth loss, a fact observed in the present case.

Regarding radiographic findings, total obliteration of the pulp chambers and root canals was found, as well as the presence of thin roots and constriction in the cervical area, which are characteristic of this anomaly. These conditions make endodontic treatment, when necessary, challenging.⁴

It was observed that, in 3 generations of the examined patient, 6 women and 4 men from the same family presented ID. This fact corroborates data from the literature, which reports that DI has almost complete penetrance and high expressiveness.⁹ Genetic analyses have shown that type II DI is related to chromosome 4q21, making siblings the primary candidates for this type of anomaly.¹⁰ Although the present case report did not carry out a genetic analysis of the individuals who presented type II DI, it was noted that one of the patient's brothers and some other relatives of his had the same anomaly.

We can thus conclude that type II DI has great impact on the functional and aesthetic aspects of individuals' oral health and that its late diagnosis contributes to the development of low self-esteem in the patient's daily activities.

DECLARATIONS

Conflicts of Interest: The authors declare they do not have conflicts of interest related to study.
Funding Statement: This research project did not receive specific funding. It was performed as part of the employment of the authors.

REFERENCES

1. de La Dure-Molla M, Fournier BP, Berdal A. Isolated dentinogenesis imperfecta and dentin dysplasia: revision of the classification. *Eur J Hum Genet.* 2015; 23(4):445-51. doi: 10.1038/ejhg.2014.159.
2. Li F, Liu Y, Liu H, Yang J, Zhang F, Feng H. Phenotype and genotype analyses in seven families with dentinogenesis imperfect or dentin dysplasia. *Oral Dis.* 2016;23(3):360-6. doi: 10.1111/odi.12621.
3. Andersson K, Malmgren B, Aström E, Dahllöf G. Dentinogenesis imperfecta type II in Swedish children and adolescents. *Orphanet J Rare Dis.* 2018;13(1):145. doi: 10.1186/s13023-018-0887-2.
4. Gama FJR, Corrêa IS, Valério CS, Ferreira EF, Manzi FR. Dentinogenesis imperfecta type II: a case report with 17 years of follow-up. *Imaging Sci Dent.* 2017;47(2):129-33. doi: 10.5624/isd.2017.47.2.129.
5. Shields ED, Bixler D, El-Kafrawy AM. A proposed classification for heritable human dentin defects with a description of a new entity. *Arch Oral Biol.* 1973;18(4):543-53. doi: 10.1016/0003-9969(73)90075-7.
6. Acevedo AC, Santos LJS, Paula LM, Dong J, MacDougall M. Phenotype characterization and DSPP mutational analysis of the three Brazilian dentinogenesis imperfect type II families. *Cells Tissues Organs.* 2009;189:230-6. doi: 10.1159/000152917.
7. Soliman S, Meyer-Marcotty P, Hahn B, Halbleib K, Krastl G. Treatment of an adolescent patient with dentinogenesis imperfecta using indirect composite restorations: a case report and literature review. *J Adhes Dent.* 2018;20(4):345-54. doi:10.3290/j.jad.a40991.
8. Goodman DB. Dentinogenesis imperfecta. *Int J Orthod.* 1973;11(1):11-6.
9. Kim JW, Simmer JR. Hereditary dentin defects. *J Dent Res.* 2007;86(5):392-99. doi: 10.1177/154405910708600502.
10. Dean JA, Hartsfield JK, Wright JT, Hart TC. Dentin dysplasia type II linkage to chromosome 4q. *J Craniofac Genet Dev Biol.* 1997;17(4):172-7.