



ISSN 0975-6299

Vol 3/Issue 2/April – June 2012

**International Journal of Pharma and Bio Sciences**

RESEARCH ARTICLE

PHARMACOLOGY

**WOUND HEALING ACTIVITY OF TOPICAL APPLICATION OF ALOE VERA GEL  
IN EXPERIMENTAL ANIMAL MODELS****K.C.HARITHA YADAV\*<sup>1</sup>, J. RAVI KUMAR<sup>2</sup>, S.ILIAS BASHA<sup>2</sup>, G.R.DESHMUKH<sup>3</sup>, RAVI GUJJULA<sup>4</sup>  
AND B.SANTHAMMA<sup>1</sup>**<sup>1</sup> Department of Pharmacology, Kamineni Institute of Medical Sciences, Nalgonda, India.<sup>2</sup> Department of Pharmacology, SVS Medical College, Mahabubnagar, India.<sup>3</sup> Department of Pathology, Aptus Biosciences, Mahabubnagar, India.<sup>4</sup> Department of Chemical Engineering, Indian Institute of Technology, Hyderabad, India.**K.C.HARITHA YADAV**Department of Pharmacology, Kamineni Institute of Medical Sciences, Nalgonda,  
India.**ABSTRACT**

*Aloe vera* gel of 50% and 96.4% were tested for its wound healing activity by topical application in experimental rats. The effect of *Aloe vera* gel on wound healing was evaluated by wound excision model and histopathology was used to study the effect on wound healing. The effect produced by *Aloe vera* gel with reference to wound contraction, wound closure, decrease in surface area of wound, tissue regeneration at the wound site and histopathological characteristics were significant in treated rats. The effect of *Aloe vera* gel on biochemical studies revealed significant increase in collagen and decreased hexosamine content and malondialdehyde levels when compared with control. The present study thus provided scientific rationale for the traditional use of *Aloe vera* gel for management of wounds.

## KEYWORDS

*Aloe vera* gel, wound healing activity, wound excision model, collagen.

## INTRODUCTION

Due to poor hygienic conditions both in developed and developing countries, wound infection has become common disease in recent years<sup>1</sup>. Wounds are physical injuries, which lead to open or broken skin and thus appropriate method for wound healing is essential for the restoration of disrupted anatomical continuity and functional state of the skin.<sup>2</sup> Wound is a break in epithelial integrity of the skin and may be accompanied by an alteration of the structure and function of underlying normal tissue and can also be caused by contusion, haematoma, lacerations or abrasions.<sup>3</sup>

Wound healing begins from the time of injury and can continue for varying periods of time, depending on the degree of wounding. Wound healing process can be diversified in to three stages namely inflammatory, proliferative and lastly the remodeling phase which determines the potency and appearance of the healed tissue.<sup>4</sup> Wound healing is a complex mechanism which holds numerous steps involving coagulation, inflammation, granulation tissue formation, matrix formation, connective tissue remodeling, collagenization and wound strength acquisition.<sup>5</sup> Many traditional practitioners worldwide, especially in countries like India and China have valuable information on many lesser known hitherto unknown wild plants for treating wounds and burns. Traditional forms of medicine practiced for centuries in Africa and Asia have been scientifically studied for their potential in the treatment of disorders associated with wounds.<sup>6</sup> Biswas and Mukherjee in their study noticed that 70% of the wound healing ayurvedic drugs are of plant origin, 20% of mineral origin and the remaining 10% consisting of animal products and these drugs have been shown to be effective in different circumstances. Among various plant herbs, *Aloe vera* is very popular in

both Ayurvedic and traditional Chinese medicine for its vast medicinal properties.<sup>7</sup>

In the Ayurvedic traditional Indian medicine *Aloe vera* is used internally as laxative, haemorrhoid remedy, antihelminthic and menstrual regulator. It is also used topically in combination with licorice root for treating psoriasis and eczema. *Aloe vera* has been used for centuries for its wound healing properties and therapeutic potential. Though more than 75 active ingredients were identified, therapeutic effects have not been well correlated with each components.<sup>8</sup> In India *Aloe vera* gel has been evaluated for its wound healing properties.<sup>9,10</sup> Against this backdrop the present study is aimed to determine the wound healing activity of *Aloe vera* gel in experimental animal models.

## MATERIALS AND METHODS

### i. *Experimental Animals*

Female Sprague Dawley rats weighing 150-250 gm were obtained from the central animal house of SVS Medical College, Mahabubnagar, Andhra Pradesh and housed under standard conditions of temperature, 12 hour light/dark cycle and fed with standard pellet diet and water *ad libitum*. These experimental rats were kept in polypropylene cages provided with paddy husk bedding and were acclimatized for a week under the aforesaid housing, feeding and other ménage mental conditions. The experimental protocols were approved by the Institutional Animal Ethical Committee (45/2008/IAEC/SVSMC/MBNR).

### ii. *Drugs*

96.4% *Aloe vera* gel and 50% *Aloe vera* gel (diluted with demineralised water) used in this

study were gifted by Bhaskara biotech (Hyderabad, India).

### iii. **Creation of wound**

The animals were anaesthetized using ether anesthesia. The anesthetized animals were secured to the operation table in the natural position. The fur of the dorsum of each animal was shaved and wound area was created. Ethanol (70%) was applied as an antiseptic for the shaved region before the wound creation. An impression was made on the dorsal interscapular region 5 mm away from the ears using a circular colored rubber stamp of 21 mm diameters as described by Morton and Malone<sup>11</sup>. Full thickness skin from the demarcated area was excised including *panniculus carnosus* to get a wound area of approximately 350 mm<sup>2</sup>. The wound was blotted with a cotton swab soaked in normal saline. The treatment included topical application 50% and 96.4% *Aloe vera* gel compared with untreated group. Treatments were continued until complete closure of the wound had occurred.

### iv. **Experimental Protocol**

After wound creation experimental animals were randomly divided into three groups: group I (n=15) untreated control rats; group II (n=15) rats treated topically with 50% *Aloe vera* gel and group III (n=15) rats treated with 96.4% *Aloe vera* gel. Six animals in each group were used for studying progressive changes in morphology of wound. Nine animals in each group were used for histopathological and biochemical analysis.

### v. **Assessment of wound healing**

The physical attributes of wound healing namely, wound closure, epithelialisation time and scar features are studied by tracing the raw wound area on tracing paper on the days 0, 4, 8, 12 and 16. Wound area was calculated by the number of squares of the retraced wound area on a 1mm<sup>2</sup> graph paper from the tracing paper. The degree of wound healing was calculated as percentage closure of the wound area from the original wound area using the Walker and Mason formula<sup>12</sup>:

$$\text{Percentage closure} = 1 - \frac{Ad}{Ao} \times 100$$

Where Ao is the wound area on the day zero and Ad is the wound area on corresponding days.

### vi. **Biochemical analysis**

After seventh, ninth and fourteenth day of wounding, animals were sacrificed by over dosage of ether anesthesia. The wound biopsies were collected and stored at -80°C until analysis. Difficulty was encountered in collecting the fourth day wounds thus fourth day sampling was not done. The granulation tissue was subjected for estimation of biochemical parameters. As an indication of total collagen content, hydroxyproline concentration was determined as described by Woessner.<sup>13</sup> To estimate hexosamine the tissue samples were defatted in chloroform:methanol (2:1) and dried in acetone, before use. Hexosamine was estimated by the method of Elson and Morgon respectively<sup>14</sup>. Lipid peroxide levels in granulation tissues were determined by the thiobarbituric acid reaction<sup>15</sup>.

### vii. **Histopathological studies**

The cross sectional full thickness skin biopsy specimen from each group was collected on days 7, 9 and 14 and the histological evaluation was carried out during the study. The tissues were fixed in 10% buffered formalin and passed through different grades of alcohol and were embedded in paraffin wax. Samples were sectioned (3-5µm) and stained with hematoxylin and eosin. For collagen deposition studies, traces of staining reaction, hyalinization and irregular arrangement of collagen bundles were considered as positive, where as the most intense reaction and compactly arranged collagen bundles were considered as ++++. Two areas in each section were counted for neovascularisation and fibroblast proliferation.

### viii. **Statistical analysis**

For the in vivo study of wound areas on rats, the results were expressed as a mean ± SD. The results were analyzed by one-way analysis of variance (ANOVA) by using SPSS 18.0

statistical software package. Tukey post hoc test was used on group comparison. Differences

were considered significant at  $P < 0.05$ .

## RESULTS

### i. Wound closure

**Table 1**  
**Wound healing activity of the Aloe vera gel on wound contraction.**

Post wounding days	Control (n=6)	50% Aloe vera gel (n=6)	96.4% Aloe vera gel (n=6)
0	350.83 ± 1.6	349 ± 3.8	350 ± 2.5
4	317.67 ± 4.4 (9.45)	245.83 ± 8.8 (29.56)**	235.17 ± 8.7 (32.82)**
8	224.17 ± 3.9 (36.10)	147.83 ± 7.8 (57.64)**	84.33 ± 6.2 (75.91)***
12	116.00 ± 6.3 (66.94)	48.83 ± 10.2 (86.00)**	30.33 ± 4.1 (91.33)***
16	48.83 ± 6.8 (86.07)	4.67 ± 4.7 (98.66)**	2.83 ± 1.7 (99.19)***
Epithelialisation Period	20.67 ± 1.8	18.33 ± 1.5	16.17 ± 0.7*

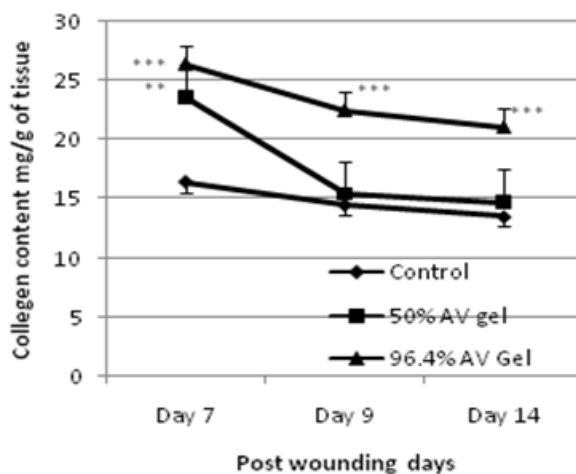
Values are expressed as Mean ± SD. \* $p = 0.05$ ; \*\* $p = 0.01$ ; \*\*\* $p = 0.001$ . Compared to control. Values in parenthesis are percentage of wound closure

A better healing pattern with complete wound closure was observed in rats treated within 16 days for 50% and 96.4% Aloe vera gel. The epithelialisation period recorded was very short for 96.4% and 50% Aloe vera gel. There was a significant reduction in wound area from day 4 onwards in treated rats and also on later days the closure rate was much faster when compared with control (Table 1). With reference to the percentage of wound closure, the results indicated that Aloe vera gel (96.4%) showed nearly 100% wound closure followed by Aloe vera gel (50%) which recorded 98.66%. The results clearly indicated that the Aloe vera gel influences the wound closure at a greater extent (Table 1).

### ii. Biochemical parameters

Collagen synthesis is an important process that takes place during the wound healing mechanism. The collagen content was measured in control and Aloe vera gel treated rats. The results indicated a common pattern of change in collagen content in all the three groups. Maximum collagen levels were found on day 7 of post wounding. In 50% Aloe vera gel group, the collagen level was drastically decreased by 9<sup>th</sup> day, where as in control and 96.4% the decrease in collagen levels was at lower rate. The levels continued to decrease later at slower rate in all the three groups (Graph1).

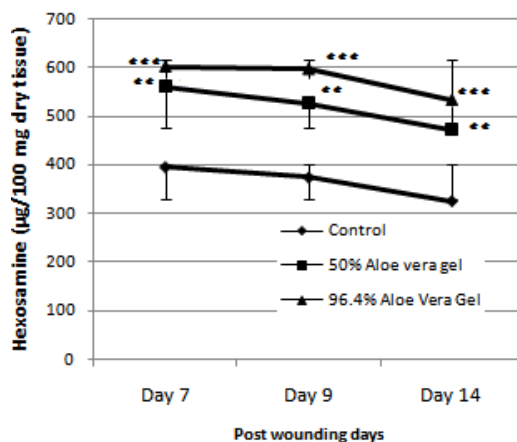
**Graph1**  
**Collagen (mg/g tissue) content of groups in excision wound model**



In the present study the hexosamine level was found to be decreased in 50% and 96.4% *Aloe vera* gel groups on 9<sup>th</sup> day of the experiment.

There was a gradual decrease in the hexosamine content in all the three groups on 14<sup>th</sup> day of the experiment (Graph 2).

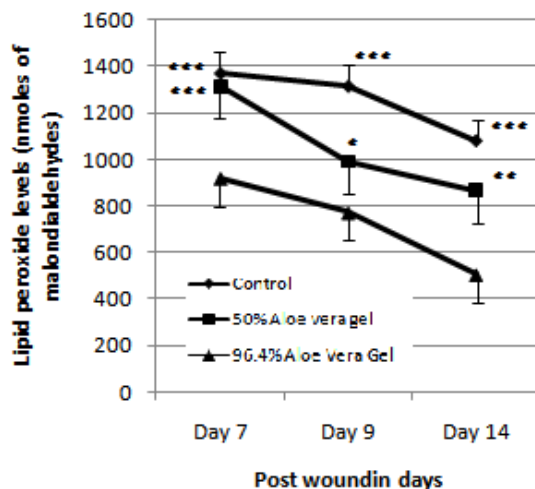
**Graph 2**  
**Hexosamine levels ( $\mu\text{g}/100 \text{ mg}$ ) in groups of excision wound model.**



The malondialdehyde (MDA) levels were measured on 7, 9 and 14 days of the experiment in all groups. The malondialdehyde (MDA) level which indicates lipid peroxidation in granulation

tissue was significantly decreased in the case of 50% and 96.4% *Aloe vera* gel groups compared with control on 9<sup>th</sup> day of the experiment (Graph 3).

**Graph 3**  
**Lipid peroxide levels (nmoles of malondialdehydes) in groups of excision wound model.**

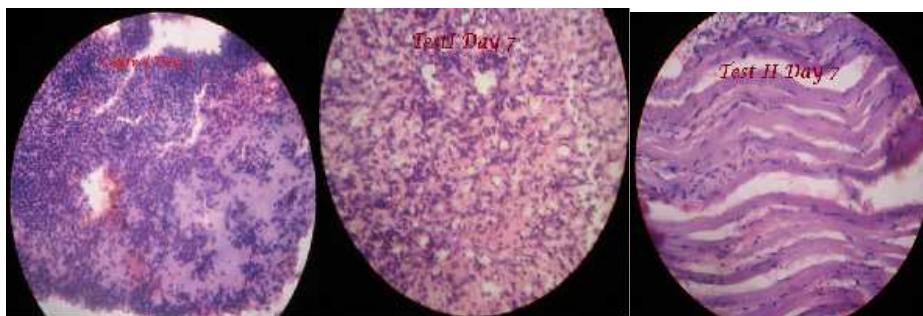


**iii. Histopathology results**

**Table 3**  
**The Collagen synthesis, neovascularisation and fibroblast proliferation in post wounded sections obtained on days 7, 9 and 14.**

Treatment/ PW days	Collagen fibers			Neovascularisation			Fibroblast proliferation		
	7th day	9th day	14th day	7th day	9th day	14th day	7th day	9th day	14th day
Control	-----	+	++	+	++	+	+++	+++	++
50% AV	+	++	+++	++	++	++	+++	++	+
96.4% AV	+	++	+++	+++	++	+	++	++	+++

**Figure 4**  
**Histological evaluation of the treated and untreated samples on day 7 of wound creation.**

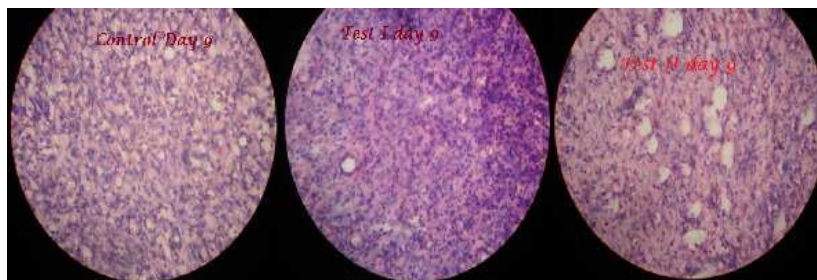


The histopathological evaluation on the 7<sup>th</sup> day in control tissues showed that there was intense inflammatory reaction with deposition of extra cellular matrix. There was formation of some new blood vessels which may be due to neovascularization. In the test I group there were

more intense inflammatory reaction with moderate neovascularization and loosely arranged collagen fibers. In the test II group there were more intense inflammatory reaction with moderate neovascularization and loosely arranged collagen fibers (Figure 4).

**Figure 5**

***Histological evaluation of the treated and untreated samples on day 9 of wound creation.***

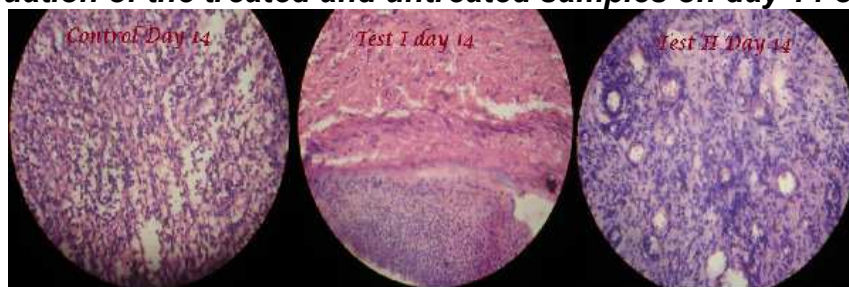


The histopathological evaluation on the 9<sup>th</sup> day in control tissues showed that there was intense inflammatory reaction with increased neovascularization and appearance of loose collagen fibers and few fibroblasts. In the test I group there was inflammatory reaction which is

less intense with neovascularization and increased collagen fibers and fibroblasts. In the test II group there was less Intense inflammatory reaction with few new blood vessels and increased deposition of collagen fibers (Figure 9).

**Figure 6**

***Histological evaluation of the treated and untreated samples on day 14 of wound creation.***



The histopathological evaluation on the 14<sup>th</sup> day in control tissues showed that there were dense collagen fibers and fibroblasts with more inflammatory cells showing incomplete healing. With reference to test I group there were dense collagen fibers and fibroblasts with neovascularization. Appearance of skin appendages can also be visualized. In the test II group more dense collagen fibers and fibroblasts with few neovascularization and appearance of Skin appendages can be visualized on 14<sup>th</sup> day of the experiment (Figure 14).

infection in compromised skin. These preparations allow high local antimicrobial efficacy while avoiding systemic toxicity and are most effective in the earlier stages of healing prior to the formation of a solid granulation bed. Results of the present investigation clearly indicated the wound healing properties of *Aloe vera*. Aloe was used by Hippocrates and Arab physicians, and was carried to the Western Hemisphere by Spanish explorers. Atherton has reported that the Alexander the great captured the island of Socotra in the Indian Ocean to secure its aloe supplies to treat his wounded soldiers<sup>16</sup>. Al-Henhena et al<sup>17</sup> reported in his article that wound healing is a complex and dynamic process of restoring cellular structures and tissue layers in damaged tissue as closely

## **DISCUSSION**

The rationale for application of topical medications is prophylaxis and treatment of

as possible to its normal state. According to Midwood et al<sup>18</sup> in his study reported that wound contracture is a process that occurs throughout the healing process, commencing in the fibroblastic stage whereby the area of the wound undergoes shrinkage. He also noticed that in the maturational phase, the final phase of wound healing the wound undergoes contraction resulting in a smaller amount of apparent scar tissue.

In the present study two dose levels of *Aloe vera* gel was studied for their wound healing properties. The topical application of *Aloe vera* gel significantly accelerated the rate of wound healing, histopathological studies of healed wound revealed comparatively less inflammation, more collagen and angiogenesis as evident from the findings of the present investigation. There are numerous reports about the wound healing effects.

Muhammad and Muhammad in their study noticed that the wound healing effects may be due to regulation of collagen expression and increase in tensile strength of the wounds. They also reported that enhanced healing activity has been attributed to increased collagen formation and angiogenesis<sup>19</sup>. Al-Henhena et al<sup>17</sup> in his study reported that collagen play a central role in the healing of wounds and it is a principal component of connective tissue and provides a structural framework for the regenerating tissue. A wound healing mechanism termed as angiogenesis improves the circulation to the wound site facilitating the oxygen and nutrients required for the wound healing process which involves reepithelisation. Angiogenesis and epithelial cell proliferation are the prominent wound healing process as suggested from the research reports.<sup>20</sup>

In the present study it was noticed that the epithelialisation period for both the doses of *Aloe vera* gel is short compared to the control groups. The findings indicate that *Aloe vera* had a prominent effect on the rate of wound contraction. The report coincides with the findings of Tsuchiya et al<sup>21</sup> who reported that *Aloe vera* leaf gel promote the wound healing mechanism and mainly due to their antimicrobial

properties, which appear to be responsible for wound contraction and increased rate of epithelialisation. The percentage of wound closure was high in both the doses of *Aloe vera* gel. This may be due to the presence of active compounds present in *Aloe vera* and also substances like enzymes, glycoproteins, growth factors, vitamins and minerals.<sup>10</sup> As reported by the Davis et al<sup>22</sup> among the two major constituents of *Aloe* glucose-6-phosphate and mannose-6-phosphate, mannose-6-phosphate is the important structural constituent that promotes wound healing and has anti-inflammatory activity.

Soon after an injury a rapid protein synthesis occur in the wound area. Collagen is the principal extracellular protein in the granulation tissue of the healing wound. Collagen plays a vital role in the haemostasis in addition providing an integrity and strength of the tissue matrix. The present study examined the influence of *Aloe vera* gel on the collagen content in granulation tissues of healing full-thickness wounds in experimental rats. The results indicated that 96.4% *Aloe vera* gel was found effective with reference to collagen synthesis and degradation. The present study corroborates with previous reports of Chitra et al.<sup>9</sup> where she reported that *Aloe* gel not only increased collagen content of the wound but also changed collagen composition and increased the degree of collagen cross linking. The fibroblasts synthesize proteoglycans and glycosaminoglycans in the wound area which forms a provisional matrix on which collagen fibers are embedded. Dunphy and Udupa<sup>23</sup> reported that due to the accumulation of collagen there is a decrease in hexosamine levels. The hexosamine content was evaluated in the present study to find out the effect of *Aloe vera* gel on wound healing. The results revealed that the treatment with *Aloe vera* gel (50 and 96.4%) decreased hexosamine content.

Malondialdehyde is a naturally occurring product of lipid peroxidation. In the present study the malondialdehyde level was significantly decreased in the case of 50 and 96.4% *Aloe*



*vera* gel treated experimental group of rats compared with the control. Present study is positively correlated with the findings of Anshoo et al<sup>24</sup>. Who indicated that *Aloe vera* gel application significantly reduced oxidative stress against sulphur mustard induced systemic toxicity and skin lesions.

The histopathological studies revealed that animals treated with 50 and 96.4% *Aloe vera* gel exhibited marked dryness of wound margins with tissue regeneration after 7 days of the experimental period. The histological evaluation showed that increased cellular infiltration from haematoxylin and eosin staining in treated cases may be due to chemo tactic effect enhanced by the crude extract which might have attracted inflammatory cells towards the wound site<sup>25</sup>. Increased cellular proliferation may be due to the mitogenic activity of the plant extract, which might have significantly contributed to healing process. Early dermal and epidermal regeneration in treated rats also confirmed that the extract had a positive effect towards cellular proliferation, granular tissue formation and

epithelialisation supported by Karodi et al<sup>26</sup>. in his study.

## CONCLUSION

The findings indicated the wound healing nature of *Aloe vera* gel on experimental rats. The topical application of *Aloe vera* gel significantly accelerated the wound contraction and marked wound closure. It may be concluded that *Aloe vera* gel is very effective on open wounds and a promising herbal drug. It also had a marked influence on the collagen level which is the precursor protein for wound healing mechanism. *Aloe vera* gel accelerated epithelialisation, neo-vascularization and increased wound contraction in the later stage of the wound healing process as evidenced by the histological studies. Hence it may be concluded that *Aloe vera* gel may be used as a cheap, effective topical gel and formulated as fairly economical therapeutic agent for wound management as a prohealer.

## REFERENCES

1. Kumar B, Vijayakumar M, Govindarajan R, Pushpangadan P. Ethnopharmacological approaches to wound healing--exploring medicinal plants of India. J Ethnopharmacol. 2007 Nov 1;114(2):103-13.
2. Meenakshi S, Raghavan G, Nath V, Ajay Kumar SR, Shanta, M. Antimicrobial, wound healing and antioxidant activity of *Plagiochasma appendiculatum*. J Ethnopharmacol. 2006 Aug 11;107(1):67-72.
3. Enoch S, John Leaper D. Basic Science of Wound Healing. Surgery (Oxford). 2008 Feb; 26(2):31-37.
4. Sumitra M, Manikandana P, Suguna L. Efficacy of *Butea monosperma* on dermal wound healing in rats. Int J Biochem Cell Biol. 2005 Mar;37(3):566-73.
5. Reddy JS, Rao PR, Reddy MS. Wound healing effects of *Heliotropium indicum*, *Plumbago zeylanicum* and *Acalypha indica* in rats. J Ethnopharmacol. 2002 Feb;79(2):249-51.
6. Krishnan P. The scientific study of herbal wound healing therapies: Current state of play. Curr Anaes Crit Care. 2006;17(1):21-27.
7. Biswas TK, Mukherjee B. Plant medicines of Indian origin for wound healing activity: a review. Int J Low Extrem Wounds. 2003 Mar;2(1):25-39.
8. Habeeb F, Shakir E, Bradbury F, Cameron P, Taravati MR, Drummond AJ, Gray AI, Ferro VA. Screening methods used to determine the anti-microbial properties of *Aloe vera* inner gel. Methods. 2007 Aug;42(4):315-20.

9. Chithra P, Sajithlal GB, Chandrakasan G. Influence of aloe vera on the healing of dermal wounds in diabetic rats. *Journal of ethnopharmacology*. 1998 Jan;59(3):195-201.
10. Subramanian S, Sathish Kumar D, Arul Selvan P. Wound healing potential of Aloe vera leaf gel studied in experimental rabbits. *Asian J. Biochem*. 2006;1(2):178-185.
11. Morton JJ, Malone MH. Evaluation of vulnerary activity by an open wound procedure in rats. *Arch Int Pharmacodyn Ther*. 1972 Mar;196(1):117-26.
12. Walker HL, Mason AD Jr. A standard animal burn. *J Trauma*. 1968 Nov;8(6):1049-51.
13. Woessner JF Jr. The determination of hydroxyproline in tissue and protein samples containing small proportions of this imino acid. *Arch Biochem Biophys*. 1961 May; 93:440-7.
14. Elson LA, Morgon WTJ. A colorimetric method for the determination of glucosamine and chondrosamine. *J*. 1933; 27(6): 1824–8.
15. Santos MT, Valles J, Aznar J, Vilches J. Determination of plasma malondialdehyde-like material and its clinical application in stroke patients. *J Clin Pathol*. 1980 Oct;33(10):973-6.
16. Atherton P. Aloe vera: magic or medicine? *Nurs Stand*. 1998; 12(49):52-54.
17. Al-Henhena N, Mahmood AA, Al-magrami A, Nor Syuhada AB, Zahra AA, Summaya MD, Suzi MS, Salmah I. Histological study of wound healing potential by ethanol leaf extract of *Strobilanthes crispus* in rats. *Journal of Medicinal Plants Research*. 2011, Aug.18; 5(16):3660–6.
18. Midwood KS, Williams LV, Schwarzbauer JE. Tissue repair and the dynamics of the extracellular matrix. *Int. J. Biochem. Cell Biol*. 2004 Jun;36(6):1031-7.
19. Muhammad HS, Muhammad S. The use of *Lawsonia inermis* Linn.(henna) in the management of burn wound infections. *African Journal of Biotechnology*. 2005; 4:934-937.
20. Szabo S, Kusstatscher S, Sakoulas G, Sandor Z, Vincze A, Jadus M. Growth factors: new 'endogenous drugs' for ulcer healing. *Scand J Gastroenterol Suppl*. 1995;210:15-8.
21. Tsuchiya H, Sato M, Miyazaki T, Fujiwara S, Tanigaki S, Ohyama M, Tanaka T, Iinuma M. Comparative study on the antibacterial activity of phytochemical flavanones against methicillin-resistant *Staphylococcus aureus*. *J Ethnopharmacol*. 1996 Jan;50(1):27-34.
22. Davis RH, Didonato JJ, Hartman GM, Haas RC. Anti-inflammatory and wound healing activity of a growth substance in aloe vera. *J. Amer. Podiatric Med. Assoc*. 1994Feb;84(2):77-81.
23. Dunphy JE, Edwards LC, Udupa KN. Wound healing; a new perspective with particular reference to ascorbic acid deficiency. *Annals of surgery [Internet]*. 1956 Sep;144(3):304-17.
24. Anshoo G, Singh S, Kulkarni AS, Pant SC, Vijayaraghavan R. Protective effect of Aloe vera L. gel against sulphur mustard-induced systemic toxicity and skin lesions. *Ind. J. Pharmacol*. 2005;37(2):103-110.
25. Hernández V, del Carmen Recio M, Máñez S, Prieto JM, Giner RM, Ríos JL. A mechanistic approach to the in vivo anti-inflammatory activity of sesquiterpenoid compounds isolated from *Inula viscosa*. *Planta Med*. 2001 Nov;67(8):726-31. 11731914
26. Karodi R, Jadhav M, Rub R, Bafna A. Evaluation of the wound healing activity of a crude extract of *Rubia cordifolia* L. (Indian madder) in mice. *International Journal of Applied Research in Natural Products*. 2009, Jun, 2;2(2):12-18.