

**SYMPATHETIC INVOLVEMENT IN PERIPHERAL NERVE INJURY**

Submitted for the degree of Doctor of Philosophy  
in the Faculty of Medicine

By

**JENNIFER R. SMALL**

INSTITUTE OF NEUROLOGY  
UNIVERSITY OF LONDON

1990

ProQuest Number: U051198

All rights reserved

INFORMATION TO ALL USERS

The quality of this reproduction is dependent upon the quality of the copy submitted.

In the unlikely event that the author did not send a complete manuscript and there are missing pages, these will be noted. Also, if material had to be removed, a note will indicate the deletion.



ProQuest U051198

Published by ProQuest LLC (2017). Copyright of the Dissertation is held by the Author.

All rights reserved.

This work is protected against unauthorized copying under Title 17, United States Code  
Microform Edition © ProQuest LLC.

ProQuest LLC.  
789 East Eisenhower Parkway  
P.O. Box 1346  
Ann Arbor, MI 48106 – 1346

## Abstract

The aim of this study was to investigate the response of noradrenergic sympathetic efferent fibres to injury in a peripheral nerve, and to attempt to elucidate the cytochemical basis for the abnormal interaction between sympathetic efferent and sensory afferent fibres which develops in experimental neuromas. The painful nerve injury model used throughout was the experimental neuroma. The numbers, distribution and morphological relationships of sympathetic efferent fibres in normal and injured rat sciatic nerve were studied. Noradrenaline (NA) was localized in fluorescence studies by a glyoxylic acid technique. Ultrastructural localization involved treatment of animals with a monoamine oxidase inhibitor, nialamide, followed by a 'false' transmitter, 5 - hydroxy dopamine (5-OH DA); or alternatively, cytochemical reaction according to a modified chromaffin technique, followed by x-ray microanalysis. Two pharmacological manipulations were employed. The first involved treatment with guanethidine, a sympathetic blocking agent, and secondly, neonatally administered capsaicin, which selectively destroys afferent C fibres. The development of alpha adrenoreceptors and opiate receptors in the spinal cord, normal and transected sciatic nerves was studied, using autoradiography with tritiated para amino clonidine, an alpha-2 adrenoreceptor ligand and tritiated diprenorphine, an opiate receptor ligand.

The fluorescence studies showed an accumulation of fluorescent material, NA, at the distal end of the proximal stump of the sectioned nerves, which was maximal 3 days after section. The number of sympathetic axons fell to below normal 14 days after section and returned towards normal by 8 weeks. NA could also be seen ultrastructurally, following pretreatment with nialamide and 5-OH DA, localized to electron-dense cored vesicles within sympathetic axons. Optimal localization of NA followed subsequent fixation in chromate containing fixative and electron probe x-ray microanalysis. Guanethidine treatment caused NA depletion, which was more marked in neuromas than normal nerves, especially at the distal tip of the proximal stumps, and varied between animals. Capsaicin treatment resulted in a loss of unmyelinated afferent axons, the effect being more obvious in the normal nerves. Autoradiographic studies showed a depletion of opiate receptors on the lesioned side of the spinal cord, but a slight increase in the number of alpha adrenergic receptors on this side. The neuromas appeared to have increased numbers of both types of receptors when compared to the normal sciatic nerves, which were not labelled.

## CONTENTS

	PAGE
<b>ABSTRACT</b>	2
<b>TABLE OF CONTENTS</b>	3
<b>LIST OF TABLES AND FIGURES</b>	6
<b>ACKNOWLEDGEMENTS</b>	11
<b>STATEMENT OF PROBLEM</b>	12
<b><u>CHAPTER I: INTRODUCTION</u></b>	
<b><u>A. PAIN WITH PERIPHERAL NERVE LESIONS</u></b>	
1. Trauma	
a) Causalgia	13
b) Reflex Sympathetic Dystrophy	15
Sympathectomy and Sympathetic blockade as a treatment for post-traumatic neuralgias	17
c) Phantom Limb and Amputation stump pain, treatment	19
d) Early hypotheses to explain pain with peripheral nerve injury	21
2. Painful mononeuropathies	
a) Post Herpetic Neuralgia	23
b) Entrapment neuropathies	24
c) Ischaemic neuropathies	24
d) Diabetic mononeuropathies	25
3. Polyneuropathies	25
<b><u>B. EXPERIMENTAL ANIMAL PHYSIOLOGICAL STUDIES OF DAMAGED PERIPHERAL NERVES</u></b>	
1. Acute effects	28
2. Chronic effects	
a) Ongoing activity	28
b) Adrenaline sensitivity	30
c) Mechanosensitivity	31
d) Sympathetic efferent/Sensory afferent interaction	31
3. Dorsal root ganglion cell changes following peripheral nerve injury	35
4. CNS changes following peripheral nerve injury	37
5. The possible importance of the sympathetic nervous system in pains unrelated to nerve injury	39
6. Animal 'models' of chronic peripheral nerve injury	40
<b><u>C. ANATOMICAL STUDIES</u></b>	
1. Degeneration and regeneration mechanisms in injured peripheral nerves	43
a) Proximal stump degeneration	
Myelinated fibres	43
Unmyelinated fibres	44
b) Proximal stump regeneration	
Myelinated fibres	46
Sympathetic unmyelinated fibres	49
c) Formation of the chronic neuroma	51

**D. NEUROCHEMICAL STUDIES**

- |   |    |
|---|----|
| 1. Axonal transport in injured peripheral nerves                      | 53 |
| Noradrenaline Transport   |    |
| 2. Identification of noradrenaline storage sites in peripheral nerves | 56 |

**E. CONCLUDING STATEMENT** 58**CHAPTER II: MATERIALS AND METHODS and RESULTS****MATERIALS AND METHODS INTRODUCTION** 59**1. NEUROMA FORMATION** 61**2. FLUORESCENCE MICROSCOPY : INTRODUCTION** 62

- |                         |                                |    |
|-------------------------|--------------------------------|----|
| MATERIALS AND METHODS : | A. FAGLU Fixation              | 66 |
|                         | B. Glyoxylic acid fluorescence | 67 |
|                         | C. Immunofluorescence          | 68 |
|                         | D. Reserpine Treatment         | 71 |

- |              |                        |     |
|--------------|------------------------|-----|
| 2. RESULTS : | A. FAGLU Studies       | 72  |
|              | B. Glyoxylic acid      | 72  |
|              | C. Immunofluorescence  | 99  |
|              | D. Reserpine Treatment | 99  |
|              | TABLE 1                | 102 |
|              | TABLE 2                | 103 |

**3. ULTRASTRUCTURAL STUDIES : MATERIALS AND METHODS**

- |                          |     |
|--------------------------|-----|
| A. FAGLU Studies         | 104 |
| B. Conventional Fixation | 104 |

- |              |                          |     |
|--------------|--------------------------|-----|
| 3. RESULTS : | A. Normal Sciatic Nerves | 106 |
|              | B. Neuromas              | 112 |
|              | TABLE 3                  | 203 |

**4/5. CHROMAFFIN AND X-RAY MICROANALYSIS STUDIES**

- |  |     |
|--|-----|
| 4. INTRODUCTION : X - Ray electron probe microanalysis | 204 |
| 5. INTRODUCTION : The Chromaffin Reaction              | 206 |

**MATERIALS AND METHODS : Chromaffin and X-Ray microanalysis** 206

- |                |  |     |
|----------------|--|-----|
| 4/5. RESULTS : | A. Chromium labelling in normal nerves | 210 |
|                | B. Chromium labelling in neuromas      | 212 |
|                | C. X - Ray Microanalysis               | 217 |

**6. GUANETHIDINE STUDIES**

- |                       |     |
|-----------------------|-----|
| INTRODUCTION          | 231 |
| MATERIALS AND METHODS | 231 |

- |              |                  |     |
|--------------|------------------|-----|
| 6. RESULTS : | A. Normal nerves | 233 |
|              | B. Neuromas      | 237 |
|              | TABLE 4          | 257 |
|              | TABLE 5          | 258 |
|              | TABLE 6          | 259 |

<b>7. CAPSAICIN STUDIES</b>	
INTRODUCTION	260
MATERIALS AND METHODS	264
<b>7. RESULTS :</b>	
A. Normal nerves	265
B. Neuromas	269
TABLE 7	280
<b>8. AUTORADIOGRAPHY STUDIES</b>	
INTRODUCTION	281
MATERIALS AND METHODS	282
<b>8. RESULTS :</b>	
A. Diprenorphine	285
B. Para Amino Clonidine	290
TABLE 8	294
TABLE 8A	295
TABLE 9	296
TABLE 10	298
TABLE 10A	299
TABLE 11	300
<b><u>CHAPTER III TECHNICAL CONSIDERATIONS - DISCUSSION</u></b>	
A. Fluorescence	301
B. Ultrastructure	303
C. Autoradiography	304
<b><u>CHAPTER IV - DISCUSSION</u></b>	
Fluorescence studies	306
Ultrastructural studies	311
Noradrenaline transport	313
Chromaffin technique and X-Ray microanalysis	320
Relationship between variations in NA levels and pathophysiology	321
Guanethidine studies	323
Capsaicin studies	327
Autoradiography studies	329
<b><u>CHAPTER V : GENERAL DISCUSSION AND CONCLUSIONS</u></b>	
<b><u>CHAPTER VI: APPENDICES</u></b>	
APPENDIX 1 Processing Schedule for conventional transmission electron microscopy	337
2 Quantitative image analysis of autoradiographs	339
3 Statistical methods	341
APPENDIX TABLE 1 : Fluorescence studies raw data, normals	349
TABLE 2 : Fluorescence studies raw data, neuromas	351
TABLE 3 : Guanethidine studies raw data, 'normals'	353
TABLE 4 : Guanethidine studies raw data, neuromas	355
<b><u>CHAPTER VII: REFERENCES</u></b>	
	356

## LIST OF TABLES AND FIGURES

TABLES

TABLE 1	Number of fluorescent axons in normal nerves and neuromas.	102
2	Table of statistics from fluorescence study results.	103
3	Counts of 5-OH DA labelled Schwann cell subunits.	203
4	Number of fluorescent axons in guanethidine treated normal nerves and neuromas.	257
5	Total numbers of fluorescent axons in guanethidine treated normal nerves and neuromas.	258
6	Table of statistics from guanethidine study results.	259
7	Counts of 5-OH DA labelled Schwann cell subunits in capsaicin treated animals.	280
8	Diprenorphine binding in spinal cord - Film counts.	294
8A	Diprenorphine binding in spinal cord - Slide counts.	295
9	Diprenorphine binding in peripheral nerve - Slide counts.	296
10	Clonidine binding in spinal cord - Film counts.	298
10A	Clonidine binding in spinal cord - Slide counts.	299
11	Clonidine binding in peripheral nerve - Slide counts.	300
APPENDIX TABLE 1	Raw data from fluorescence study - Normal nerves	349
2	Raw data from fluorescence study - Neuromas	351
3	Raw data from guanethidine study - Normal nerves	353
4	Raw data from guanethidine study - Neuromas	355

FIGURES

FIG. 1	L.M. FLU. Normal sciatic nerve, method of counting fibres.	69
2	L.M. FLU. T.S. Normal sciatic nerve.	75
3	L.M. FLU. L.S. Normal sciatic nerve.	75
4	L.M. FLU. 3 day neuroma, accumulation of NA.	78
5	L.M. FLU. 3 day neuroma, accumulation of NA.	78
6	Plot of No. of fluorescent axons vs. distance, 3,7,14 day neuromas.	79
7	L.M. FLU. 3 day neuroma, sympathetic sprouts 1mm from tip.	82
8	L.M. FLU. 7 day neuroma, network of sympathetic sprouts at tip.	82
9	L.M. FLU. 7 day neuroma, distal tip.	84
10	L.M. FLU. 7 day neuroma, fluorescent ovoid.	84

11	L.M. FLU. 14 day neuroma, lack of NA at distal tip.	87
12	L.M. FLU. 14 day neuroma, sympathetic sprouts.	87
13	L.M. FLU. 14 day neuroma, unusual swollen sympathetic axons.	89
14	Plot of No. of fluorescent axons vs. distance, 21 and 28 day neuromas.	90
15	L.M. FLU. 28 day neuroma, blood vessel innervation.	92
16	L.M. FLU. 21 day neuroma, fine sympathetic sprouts.	92
17	Plot of No. of fluorescent axons vs. distance, 42 and 56 day neuromas.	94
18	L.M. FLU. 42 day neuroma, point of section.	96
19	L.M. FLU. 42 day neuroma, sympathetic sprouts.	96
20	L.M. FLU. 42 day neuroma, punctate varicosities in sympathetic axon.	98
21	L.M. FLU. 6 month neuroma, sympathetic axons distal to point of section.	98
22	L.M. FLU. 3 day neuroma, distal tip, immunofluorescence with anti-DBH and FITC.	101
23	L.M. FLU. 3 day neuroma, treated with reserpine, distal tip.	101
24	L.M. Tol. Blue T.S. Normal sciatic nerve.	108
25	E.M. Normal sciatic nerve, 5 - OH DA only.	108
26	E.M. Normal sciatic nerve, nialamide and 5 - OH DA.	110
27	L.M. Tol. Blue 3 day neuroma, most distal 0.5mm.	110
28	E.M. 3 day neuroma, chromate fix. Macrophage within myelinated fibre.	115
29	E.M. 3 day neuroma, myelination.	116
30	E.M. 3 day neuroma, sympathetic sprouts within basal lamina of degenerate myelinated fibre.	118
31	E.M. 3 day neuroma, sprouts in myelinated fibre.	120
32	E.M. 3 day neuroma, accumulation of organelles.	120
33	E.M. 3 day neuroma, numerous dcv in sympathetic axons.	123
34	E.M. 3 day neuroma, clusters of dcv and clear vesicles.	125
35	E.M. 3 day neuroma, non 5 - OH DA labelled dcv.	128
36	E.M. 3 day neuroma, eccentrically cored dcv.	129
37	E.M. 3 day neuroma, illustration of Schwann cell subunit counts.	132
38	E.M. 3 day neuroma, axonal sprout containing principally glycogen.	133
39	E.M. 3 day neuroma, vacuole within sympathetic axon.	135
40	E.M. 3 day neuroma, vacuole within myelinated fibre.	136
41	E.M. 3 day neuroma, sympathetic sprouts within basal	138



	lamina of myelinated fibre.	
42	E.M. 3 day neuroma, sympathetic sprouts within basal lamina of myelinated fibre.	140
43	E.M. 3 day neuroma, sympathetic sprouts within basal lamina of myelinated fibre.	142
44	E.M. 3 day neuroma, single sympathetic sprout beneath basal lamina of myelinated fibre.	142
45	E.M. 3 day neuroma, group of sprouts with myelinated axon.	144
46	E.M. 3 day neuroma, sympathetic axons with blood vessel.	147
47	E.M. 3 day neuroma, sympathetic axon in the perineurium.	147
48	L.M. Tol. Blue 7 day neuroma, distal tip.	150
49	L.M. Tol. Blue 7 day neuroma, lmm from distal tip.	150
50	E.M. 7 day neuroma, Schwann cell proliferation.	152
51	E.M. 7 day neuroma, sympathetic axons.	154
52	E.M. 7 day neuroma, sympathetic sprout in perineurium.	155
53	E.M. 7 day neuroma, clusters of clear and dcx.	157
54	E.M. 7 day neuroma, Schwann cell subunit.	160
55	E.M. 7 day neuroma, shrunken basal lamina.	162
56	L.M. Tol. Blue 14 day neuroma, distal tip.	162
57	E.M. 14 day neuroma, distal outgrowth.	165
58	E.M. 14 day neuroma, axon about to become myelinated.	168
59	E.M. 14 day neuroma, accumulation of organelles.	170
60	E.M. 14 day neuroma, regeneration.	173
61	L.M. 28 day neuroma, fascicle formation.	174
62	E.M. 21 day neuroma, fascicle formation.	176
63	E.M. 21 day neuroma, perineurium with eosinophilic leucocyte	179
64	E.M. 21 day neuroma, large non-myelinated axons.	181
65	E.M. 21 day neuroma, concentric neurofilaments.	184
66	E.M. 21 day neuroma, sympathetic axons.	186
67	E.M. 21 day neuroma, sympathetic axon with degenerate material.	188
68	E.M. 21 day neuroma, sympathetic axon.	188
69	E.M. 6 week neuroma, small fascicles and different types of collagen.	191
70	E.M. 6 week neuroma, larger fascicles in more proximal tissue.	193
71	E.M. 6 week neuroma, small fascicle at distal tip.	195
72	E.M. 6 week neuroma, difficulties in differentiating axons and Schwann cell cytoplasm.	197
73	E.M. 6 week neuroma, fascicle without layers of perineurial cell processes.	197

74	L.M. 8 week neuroma, new tissue distal to the point of section.	200
75	E.M. 8 week neuroma, axon becoming myelinated.	200
76	E.M. 8 week neuroma, degenerate myelinated axon.	202
77	E.M. normal sciatic nerve, chromaffin reaction.	202
78	E.M. normal sciatic nerve, chromaffin reaction.	211
79	E.M. 3 day neuroma, chromaffin reaction.	214
80	E.M. 21 day neuroma, chromaffin reaction.	216
81	X-Ray spectrum from sympathetic axon in normal sciatic nerve.	219
82	" " " " " " " "	219
83	" " " " " " " "	221
84	X-Ray spectrum from nucleolus.	221
85	X-Ray spectrum from dcx in sympathetic axon in 3 day neuroma.	223
86	" " " " " " " "	224
87	" " " " " " " "	225
88	X-Ray spectrum from axoplasm of a sympathetic axon.	227
89	X-Ray spectrum from axoplasm of an unlabelled axon.	227
90	X-Ray spectrum from sympathetic axon in blood vessel.	229
91	X-Ray spectrum from sympathetic axon in blood vessel.	229
92	X-Ray spectrum from dense granule in platelet.	230
93	Plot of No. of fluorescent axons vs. distance in guanethidine treated normal nerves (3 day neuromas).	234
94	E.M. guanethidine treated normal sciatic nerve contralateral to 3 day neuroma.	236
95	Plot of No. of fluorescent axons vs. distance in guanethidine treated normal nerves (7 day neuromas).	238
96	Plot of No. of fluorescent axons vs. distance in guanethidine treated normal nerves (21 day neuromas).	239
97	L.M. FLU. Distal tip guanethidine treated 3 day neuroma.	241
98	L.M. FLU. Distal tip guanethidine treated 3 day neuroma.	241
99	Plot of No. of fluorescent axons vs. distance in guanethidine treated 3 day neuromas.	243
100	E.M. guanethidine treated 3 day neuroma, distal tip.	245
101	E.M. guanethidine treated 3 day neuroma.	247
102	E.M. guanethidine treated 3 day neuroma.	249
103	Plot of No. of fluorescent axons vs. distance in guanethidine treated 7 day neuromas.	250
104	L.M. FLU. Distal tip guanethidine treated 7 day neuroma.	252
105	Plot of No. of fluorescent axons vs. distance in guanethidine treated 21 day neuromas.	253

106 E.M. guanethidine treated 3 week neuroma.	256
107 L.M. FLU. Normal sciatic nerve treated with capsaicin.	266
108 E.M. Normal sciatic nerve treated with capsaicin.	268
109 L.M. Tol. Blue 7 day neuroma treated with capsaicin.	270
110 E.M. 3 day neuroma treated with capsaicin.	272
111 E.M. 3 day neuroma treated with capsaicin.	274
112 E.M. 14 day neuroma treated with capsaicin.	276
113 E.M. 14 day neuroma treated with capsaicin.	278
114 L.M. Tol. Blue 28 day neuroma treated with capsaicin.	279
115 L.M. Autoradiograph diprenorphine treated spinal cord.	287
116 L.M. Autoradiograph control diprenorphine treated spinal cord.	287
117 L.M. Autoradiograph diprenorphine treated 21 day neuroma.	289
118 L.M. Autoradiograph diprenorphine treated normal sciatic nerve.	289
119 L.M. Autoradiograph clonidine treated spinal cord.	292
120 L.M. Autoradiograph clonidine treated 21 day neuroma.	292
121 L.M. Autoradiograph clonidine treated 21 day neuroma.	293
122 Plot of No. of fluorescent axons vs. Time in neuromas.	332
123 Plot of Standard Deviation vs. Mean, untransformed data.	343
124 Normal Order Statistics plot, untransformed data.	343
125 Normal Order Statistics plot, transformed data.	345
126 Plot of Standard Deviation vs. Mean, transformed data.	345
127 Illustration of calculation of b and M15.	346

**ACKNOWLEDGMENTS**

It is with great pleasure that I express my thanks to my two supervisors, Dr.J.W.Scadding and Dr. D.N.Landon for initially providing me with the opportunity to undertake this thesis and subsequently for their expert guidance and constant encouragement throughout.

I would like to thank Professor C.D. Marsden for allowing me to use the facilities in his department, and for generously providing travelling expenses to enable me to attend the Peripheral Nerve Study Group meeting in Italy and the Congress on Neuromuscular Diseases in Munich, in order to present some of this work.

I am indebted to Drs. John Priestley and Steve MacMahon at St. Thomas's Medical School for the use of their facilities and expert help with the autoradiography studies.

It is also a pleasure to thank Mrs. Kerrie Riley for excellent assistance with the animal handling, and Mrs. Marje Gilbert for patient instruction in cryostat and photographic techniques. My grateful thanks also go to Mr. Brian Young for providing excellent electron microscopy facilities, and to Mrs. Jean Humphreys for typing the manuscript.

The studies in this thesis could not have been undertaken without the financial support of the Medical Research council, which is gratefully acknowledged.

Finally, I wish to thank my husband, Graham, for all his help with the proof-reading, and his encouragement and support throughout.

## STATEMENT OF PROBLEM

Physical injuries to peripheral nerves and a variety of other mononeuropathies and polyneuropathies may be associated with pain. In many instances pain may be the major and most disabling symptom, and in such cases it is often chronic and intractable. Treatment of the pains associated with peripheral nerve disease remains largely empirical and the consequences unpredictable, reflecting our poor understanding of the underlying pathophysiology.

There is substantial clinical evidence that sympathetic efferent activity is important in contributing to, and maintaining, pains associated with peripheral nerve damage in many patients. In regions of nerve damage an abnormal catecholamine sensitivity develops in sensory fibres and it has been shown in physiological experiments that an interaction develops between noradrenergic efferent and sensory fibres.

One of the most puzzling features of painful peripheral nerve injury is the variability of involvement of the sympathetic nervous system in similar types of nerve lesion, as judged by differences in pain relief, following sympathetic blockade. While this is likely to be due in part to central factors, independent of the sympathetic nervous system, the variable response of pain with peripheral nerve injury to regional sympathetic blockade indicates that peripheral factors may also be important in explaining this variability of therapeutic response.

The objective of the work described in this thesis was to examine the cytochemical basis of the abnormal interaction between noradrenergic sympathetic efferent fibres and sensory fibres using light microscopic and electron microscopic techniques, in one type of nerve injury, nerve section with neuroma formation. It was considered possible that the clinically observed differences in the importance of sympathetically maintained pain following nerve injury might, in part, be explained by cytochemical variation of this abnormal interaction within the region of nerve damage.

## INTRODUCTION

Pain is often an important symptom following peripheral nerve lesions. A wide range of conditions which affect the primary sensory neurone may lead to pain. These include traumatic injuries, other mononeuropathies and some polyneuropathies. These are reviewed here, with particular attention to the clinical observations which indicate sympathetic involvement.

### A. Pain with Peripheral Nerve Lesions

#### 1. TRAUMA

Traumatic injuries of peripheral nerves, ranging from compression to complete nerve section, may result in chronic pain, often associated with other persistent sensory disturbances. These may include hyperaesthesia, an increased sensitivity to stimulation, hyperalgesia, an increased response to a normally painful stimulus, allodynia, a painful response to a non-noxious stimulus, and hyperpathia, characterized by an increased pain threshold and then an increased reaction to a stimulus, especially of a repetitive type and an after sensation when the stimulus has stopped. In addition to these abnormal evoked sensations, there may also be continuous pain, taking the form of a deep ache, superficial burning, stinging or pricking, sometimes accompanied by paroxysms of lancinating pain which may spread widely throughout the affected limb (Scadding, 1989). The burning component of the pain associated with peripheral nerve damage is termed causalgia, and is of importance to this thesis, since it was one of the first painful conditions in which sympathetic activity was recognised as a contributing factor.

#### a) Causalgia

The International Association for the Study of Pain (IASP) definition of causalgia is 'a burning pain, with allodynia and hyperpathia, usually in the hand or foot, after partial injury of a nerve or one of its major branches'. Restriction of the use of the term

causalgia to refer only to burning pain with peripheral nerve injury is not agreed by all clinicians, and in this thesis the word will be used merely to refer to pain with a burning quality, without any implication about underlying cause. Although causalgia, i.e. burning pain, and the associated features of sympathetic dysfunction were originally described by Weir Mitchell (1864) in relation to peripheral nerve injury, exactly the same type of pain and associated features may develop in situations where there is no evidence of nerve injury (see Reflex Sympathetic Dystrophy, below).

The clinical features of causalgia were first described in 1864 by Weir Mitchell, Morehouse and Keen, in a monograph 'Gunshot wounds and other injuries of nerves'. They then introduced the term 'causalgia' in 1867 to describe the condition in which the pain was "burning, like fire, like a red hot wire." It was seen to vary in intensity from "the most trivial pain to a state of torture". The monograph of 1864 contained several case histories, including detailed descriptions of patients, all of whom suffered varying degrees of severe intractable burning pain. Although Mitchell et al were the first surgeons to describe causalgia, the case of a soldier in the Peninsular War with burning pain in the median nerve, whose arm was amputated to relieve the pain, had previously been reported (Denmark, 1813).

Although the clinical features of what later came to be called causalgia were first described in 1864 and the condition given a name in 1867 in an article in the United States Sanitary Commission Memoirs by Weir Mitchell, it was not until 1872 that symptoms and signs of sympathetic dysfunction were described with causalgia. Mitchell observed that the skin of the affected limbs of patients with a nerve injury producing causalgia was frequently red and glossy, and often warmer than that of the contralateral normal limb. There was also often profuse sweating of the limb. The pain is usually located in the cutaneous distribution of the affected nerve (Kirklin et al, 1947), but may spread diffusely beyond that distribution (Nathan, 1980). Another important characteristic of causalgia is that it can be evoked by many external stimuli, including light touch, heat, dryness, noise, excitement and emotion.

Causalgia due to peripheral nerve injury is most frequently, but not exclusively, a painful sequel of partial lesions of peripheral nerves (Nathan, 1947). Complete transections of peripheral nerves

cause causalgia less often than partial lesions - of 22 patients with causalgia studied by Nathan (1947) only 4 had complete lesions of the nerve. Shumacker et al (1948) reported that 11 out of 90 patients with causalgia had complete nerve lesions, as determined by the complete paralysis of muscles distal to the nerve lesion, but on surgical exposure it was found that there were not gaps between the ends of the nerves, and neuromas in continuity existed. Causalgia most often occurs as a complication of injuries involving the median nerve (35%) or the sciatic nerve (40%), or their brachial and lumbar plexus components (Nathan, 1947; Sunderland, 1976). The suggestion has been made that this may be because these two nerves carry the majority of the sensory and postganglionic sympathetic fibres which supply the hand (median nerve) and foot (sciatic nerve), Sunderland (1976). Causalgia is not uncommonly seen with ulnar nerve lesions too, and may occur with injury to small peripheral nerves, e.g. digital nerves (Scadding, personal communication). Wynn Parry (1988) reports that the operation of mobilizing and transposing the ulnar nerve runs the risk of causing causalgia. Causalgia is, however, an unusual consequence of nerve injury, though the reported incidence of causalgia following peripheral nerve lesions varies widely. Nathan (1947) studied 160 nerve lesions, of which 96 involved the sciatic, ulnar or median nerve, and reports an incidence of causalgia of 14%. Richards (1967) reviewed nine studies conducted in the 1940's and calculated an overall incidence of 3.9%, and Warfield (1984) and Hodges and McGuire (1988) report an incidence of between 2 and 5%. Wynn Parry (1988), in a review of peripheral nerve injuries, reports a slightly higher incidence; 5 - 10% of patients with a repair of a peripheral nerve with a large sensory component develop causalgia.

The onset of pain is often immediate, and causalgia starts in most patients who are to develop this type of pain within one week of the injury. Tasker and Dostrovsky (1989) report that in 43% of patients onset was immediate, in 16% during the first day after injury, 21% between days 2 - 7, 15% between days 7 - 30, and after one month in 5%.

#### b) Reflex Sympathetic Dystrophy

Another important pain syndrome in which the sympathetic nervous system is involved is Reflex Sympathetic Dystrophy (RSD), but this is not necessarily a consequence of peripheral nerve injury. The IASP define RSD as a condition with 'continuous pain in a portion of an



extremity after trauma which may include fracture but does not involve a major nerve, associated with sympathetic hyperactivity'. This definition is, like that of causalgia, not universally accepted, and many clinicians consider causalgia resulting from peripheral nerve injury to be one type of RSD.

There are three main types of symptoms and signs in RSD. Firstly, pain, which may be of a burning type (causalgia), often associated with allodynia and hyperalgesia. Secondly, there is a dystrophic component, present as soft tissue swelling initially, then as glossy, mottled skin, and atrophied soft tissue and bone (Sudeck's atrophy). Lastly, there is sympathetic hyperactivity, manifested as increased local sweating and decreased skin temperature, due to vasoconstriction. The onset of pain in this condition is gradual and variable. It may begin hours, days or weeks after the initial injury (Mitchell, 1864; Homans, 1940; Steinbrocker and Argyros, 1958).

Three main stages are commonly seen in this syndrome, but these are by no means uniform in occurrence amongst patients, do not appear always in this order and are not inevitable. For convenience they are divided as follows (Janig, 1985):

1. Acute Changes - Weeks after onset. Severe pain, disproportionate to the severity of the injury may occur, in the form of causalgia, hyperpathia, hyperaesthesia, and allodynia. This pain is generally restricted to the territory of the nerve. The overlying skin is dry, red and warm initially, but later turns pale, cold and cyanotic, with increased sweating. There is local oedema and increased hair/nail growth.

2. Dystrophic Changes - 3-6 months after injury. Pain may gradually subside, but increase on movement. Nails are cracked and brittle, and there is hair loss. Osteoporosis may begin.

3. Atrophic changes - more than 6 months after injury. Spontaneous pain is usually rare, but there are now irreversible changes. Bony demineralization begins and ankylosis sets in. The skin is smooth.

There are many causes of RSD. The most common cause of RSD is soft tissue injuries, such as sprains and cuts, which do not involve any nerve damage. Approximately 30% of RSD follows from this type of injury

(Pak et al, 1970; Patman et al, 1973). Fractures account for at least another 30% of RSD. Myocardial infarction may, extremely rarely, produce RSD known as the shoulder-hand syndrome, which may account for about 10% of cases of RSD. Peripheral nerve damage accounts for a minority of cases with RSD. Pak et al (1970) analysed the incidence of peripheral nerve injury in RSD in the reports of 140 patients referred to the Mayo clinic with RSD, and found that of the 40 cases with soft tissue trauma, 8 had peripheral nerve lesions, an incidence of 6%. Patman et al (1973) conducted a similar study, and found 25 patients with causalgia with a confirmed major nerve injury out of 113 cases of post-traumatic pain syndrome, an incidence of 22%. Although the incidence of RSD with peripheral nerve injury may be low, the pain may be very severe.

Sympathectomy and sympathetic blockade as a treatment for  
post-traumatic neuralgias.

a) Causalgia

The effects of sympathetic dysfunction in causalgia were recognised by Weir Mitchell in 1872, but it was not until the twentieth century that surgeons began to recognize the value of sympathectomy in the treatment of causalgia. Rene Leriche, a French surgeon, introduced regional sympathetic block during the First World War (1916), by means of infiltration with local anaesthetic, and periarterial sympathectomy as a treatment for causalgia. This method did not give consistently good results, and it was not until the Second World War, when many patients again presented with causalgia following nerve injuries from high velocity missiles, that progress was made. Just before this time, Spurling (1930) described a patient with causalgia following a gunshot wound of the brachial plexus, in which the pain was relieved by cervicothoracic sympathetic ganglionectomy after other local surgical procedures had failed. Ross (1932) and Kwan (1935) reported similar results. Three further studies following the Second World War (Shumacker, 1948; Slessor, 1948 and Barnes, 1953), emphasised the value of sympathectomy in the relief of causalgia, 49% of patients with upper limb and 28% of patients with lower limb causalgia being provided with excellent pain relief. Thereafter sympathectomy became established as the treatment of choice in causalgia (Richards, 1967, and Bonica, 1979). Doupe et al (1944) suggested that the relief of pain following

sympathectomy, either by surgical intervention, or by anaesthetic infiltration of the local sympathetic ganglion, is the cardinal diagnostic feature of causalgia, i.e. definition on the basis of therapeutic response, but this is by no means generally agreed, and does not feature in the IASP definition of causalgia. Transient or lasting relief of causalgia was reported in 96% of patients following a sympathetic block (Richards, 1967, Bonica, 1979). If causalgia is relieved, then permanent surgical or chemical sympathectomy may be considered (Bonica, 1979). However, sympathectomy often has only a transient effect, or no effect at all on causalgia. This may, in part, be due to the technical difficulties of achieving a complete sympathectomy. In particular, the burning pain may be relieved, but other pains and paraesthesiae may persist (Nathan, 1947). White and Silverstone (1956) in a follow-up study of 66 patients with injuries from the Second World War who had undergone a sympathectomy to treat causalgia, found that the burning pain was relieved in 30 for between 2 and 3 years, but in 16 relief was afforded for less than 2 years. The reports of the effectiveness of surgical preganglionic sympathectomy are very variable, the success rate ranging from 12 - 97% (Nathan, 1947; Bonica, 1979; Tahmoush, 1981; Rowlingson, 1983; Shumacker, 1985 and Payne, 1986).

#### b) Reflex Sympathetic Dystrophy (RSD)

Because of the evidence of the involvement of the sympathetic nervous system in RSD, the approach to treatment has been very similar to that for causalgia. It has been claimed that if treatment is begun early, sympathetic blocks may be the most effective treatment for this disorder (Bonica, 1979; Hannington-Kiff, 1979, 1982; Wang et al, 1985), but these were not adequately controlled studies. Betcher et al (1953) made the first systematic study of sympathetic blockade using local anaesthetic block of the sympathetic chain, in painful peripheral states which included peripheral vascular disease such as thrombosis, arterial embolism, frostbite and conditions such as post-traumatic neuralgia, postherpetic neuralgia, phantom limb pain and fractures which had resulted in RSD. A later report by Loh and Nathan (1978) is a study of pain relief by stellate ganglion block and regional guanethidine block, in patients with hyperpathia. The guanethidine block (Hannington-Kiff, 1974) uses the Bier block method and involves application of an inflated cuff proximal to the pain site, occluding the arterial circulation of the affected limb, followed by intravenous

injection of guanethidine. The cuff is subsequently deflated after 20 minutes. In their study, Loh & Nathan (1978) found that sympathectomy relieved or partially relieved the pain and hyperpathia in 5 out of 7 patients with RSD.

A controlled study by Bonelli et al (1983) of 19 patients with severe RSD following peripheral nerve lesions, suggests that eight daily stellate blocks with local anaesthetic are equivalent to four guanethidine blocks every four days. The therapeutic efficacy of the blocks was assessed by changes in pain scores and clinical signs of hyperpathia, allodynia, vasomotor disturbances and trophic changes. Guanethidine induces a greater degree of sympathetic block, as determined by the pharmacological effects on skin temperatures and amplitude of plethysmographic waves. A surprising finding is that the duration of the analgesia may outlast the duration of action of the drug. This finding applies to local anaesthetic blocks as well as to guanethidine or reserpine regional blocks. Fields (1987) reports that the local anaesthetic effect of xylocaine lasts 2 - 3 hours, but it is not unusual for relief of the pain of RSD in the upper limb of patients treated by stellate ganglion block to last more than 12 hours. Repeated blocks may provide pain relief which lasts days or weeks or even permanently (Fields, 1987). Permanent surgical sympathectomy is often not successful, and may only be used if severe causalgia is present, or if the temporary blocks are good but only provide transient relief (Loh and Nathan, 1978; Loh et al, 1981; Driessen et al 1983; Schutzer and Gossling, 1984; Wang et al, 1985). Increasingly, clinicians are recommending persistence with repeated sympathetic blocks rather than methods to produce permanent sympathectomy (Scadding, personal communication).

### c) Phantom limb and amputation stump pain

Phantom limb pain is a very common experience in amputees. Most amputees have phantom sensations, the incidence ranging from 80 % (Jolly, 1960) to 100% (Carlen et al, 1978). An early study by Browder and Gallagher (1948) reported that of amputees with phantom limb sensations, 30% experienced pain. Jensen et al (1983, 1985) reported that 72 per cent of amputees suffered from phantom limb pain 8 days after amputation, and in 65 % it was still present 6 months later. Another study (Krebs et al, 1984) found that 7 years after amputation some 60% of patients still suffered pain. Phantom limb pain is

sometimes causalgic in nature. Of the patients with painful limbs in the study by Carlen et al (1978), 10% of lower limb and 4% of upper limb amputees described burning pains. The pain may also be described as cramping, shooting or crushing (Melzack and Wall, 1982). The pain may be felt in localised parts of the missing limb together with the experience of abnormal or changing posture in the phantom. For example, a phantom hand may be felt as if it were attached directly to the shoulder and the pain felt as the fist being clenched and the thumb nail digging into the palm (Livingston, 1943). The occurrence or persistence of the pain is often unpredictable, it may be latent for months or years (Melzack and Wall, 1982). Sunderland (1978) reports that the pain may be transient in some patients and persistent for years in others.

Stump pain in amputees is more variable, reported incidences ranging from 17.5% (Finch et al, 1980) to 71% (Krainick and Thoden, 1976). Pain often persists indefinitely if not treated, despite good wound healing (Parkes, 1973). Browder and Gallagher (1948) studied 137 patients with surgical amputations and some of these patients described a burning sensation in the stump triggered by light touch, and there was also evidence of sympathetic changes; the stump was atrophic, cold, cyanotic and sweating. Stump pain is often immediate in onset, occurring in 57% of patients according to Jensen and Rasmussen (1989).

Phantom and stump pains are often seen together, but may occur independently. However, phantom pain is significantly more frequent in amputees with long-term stump pain (Jensen et al, 1985; Sherman and Sherman, 1985).

### Treatment

Sympathectomy may be an effective treatment for phantom limb pain (Leriche, 1937; Livingston, 1938; Doupe et al, 1944; Nathan, 1947) and amputation pain (White, 1930; Stammers, 1932), but unfortunately this is not invariably the case. Loh and Nathan (1978) report a series of sympathetic blocks in 7 patients with limb amputation pain, in which pain relief was only afforded to 3. In some cases, phantom limb pains may be exacerbated by sympathetic block. Walker (1942) reports a case of a man whose phantom hand was made more painful by a Novocain block of the cervical sympathetic chain. However, overall, sympathectomy, either chemically or surgically produced has helped a large number of

patients with phantom limb and amputation stump pain. Kallio (1950) observed a transient relief following sympathectomy in 43% of patients with phantom pain, and a more recent study (Engqvist et al, 1985) suggests that guanethidine blocks may be more useful in treating phantom limb and stump pain.

d) Early hypotheses to explain pain with peripheral nerve injury and reflex sympathetic dystrophy

There have been many attempts since Weir Mitchell first described causalgia to explain the pain of neuralgias. In one of the earliest hypotheses Letievant (1873) suggested that there were three anatomical sites fundamental to the generation of causalgic pain; 1) The peripheral nerve and its point of irritation, 2) The spinal cord and 3) The sensorium. He believed that the impulses from the peripheral nerve were transmitted to the spinal cord, where more abnormal impulses were produced, which spread to adjacent areas, and thence to the sensorium. The abnormal pain was produced here, and caused the peripheral changes that had been described by Mitchell (1872).

Later, two opposing hypotheses were proposed by Leriche and Sir Thomas Lewis, both concentrating on abnormal blood flow at the peripheral site. Leriche (1939) proposed that local vasomotor nerve fibres were irritated by the neuromatous scar tissue, and caused vasoconstriction at the injury site. This led to ischaemic tissue damage, causing pain, more scar tissue therefore being available to cause the vasomotor reflex, vasoconstriction, and a reflex arc of pain-vasoconstriction-pain being formed. Interruption of this arc by sympathectomy thus abolished the pain of causalgia. Livingston (1943) proposed a similar 'vicious circle' hypothesis, covering not only causalgia, but also reflex sympathetic dystrophy and certain phantom limb pains. He also proposed the peripheral nerve injury to be an irritating lesion, but suggested that it caused central effects, the noxious impulses from the lesion serving to set up closed, self-exciting neuron loops in the dorsal horn. The impulses in the spinal cord spread out and affect the lateral and ventral parts of the cord, activating pre- and post- ganglionic sympathetic neurones. The post-ganglionic neurone may then sensitize and activate the primary nociceptor, thus a vicious circle is created. Livingston therefore emphasised central changes.

In relation to peripheral nerve injury, Doupe et al (1944) and Nathan (1947) reject this hypothesis and argue that if sympathectomy only works because it causes dilatation of vessels, why do other vasodilators not cure causalgic pain? Additionally, the initial trigger to the generation of pain is provided from the irritation of axons by scar tissue in the neuroma, and sympathectomy will have no effect on this tissue.

A hypothesis resting the blame for the pain at the injury site on local vasodilatation was proposed by Lewis (1936, 1937). He suggested that antidromic impulses arising in a focus of the injured nerve caused the hyperalgesia and burning pain, and liberated pain producing vasodilator substances. These vasodilator substances reduced the threshold of normal sensory nerves and excited a special set of "nocifensor nerves", which were not active in normal nerves. Lewis later discarded this hypothesis involving a special set of nerves, on the evidence of the effects of sympathectomy.

Nathan (1947) considered that since causalgia does not arise in the denervated or partially denervated region distal to the injury, the peripheral blood supply cannot be of major importance. Since 1940, several further hypotheses to explain the pathophysiology of the neuralgias have been proposed. One such theory is the fibre dissociation theory. Noordenbos (1959) suggested that certain traumatic injuries, such as those which result in causalgia, selectively damaged the large diameter myelinated fibres, thus altering the balance of the different fibre groups comprising the nerve. Selective electrical stimulation of large diameter myelinated fibres may often relieve the burning pain of peripheral nerve injury (Meyer and Fields, 1972; Nathan and Wall, 1974; Wall and Sweet, 1967). This relief may be even more effective if applied proximally to the lesion (Meyer and Fields, 1972), and the relief of pain may outlast the period of stimulation by several hours (Melzack and Wall, 1982).

In addition to post-traumatic neuralgias a number of other non-traumatic mononeuropathies and some polyneuropathies are characteristically painful and may be associated with the same sensory disturbances of hyperaesthesia, hyperalgesia, allodynia, hyperpathia and sometimes sympathetic dysfunction.

## 2. PAINFUL MONONEUROPATHIES

### a) Post Herpetic Neuralgia (PHN)

This condition is one of the most important painful mononeuropathies, because of the large numbers of patients involved. This is a sequel to an infection by the herpes zoster virus, and results in inflammation and variable destruction of the DRG, peripheral nerve and roots. The pain subsides in the majority of patients over a few months, but in a substantial number, particularly elderly patients, goes on to become a chronic pain syndrome, which is frequently described as a burning or raw gnawing pain. It is commonly associated with cutaneous hyperpathia and hyperaesthesia. Lhermitte and Lhermitte (1924) found that the DRG, posterior roots and peripheral nerve were all affected in a case of acute zoster myelitis, and that the pathology was an acute inflammation with axonal degeneration and demyelination.

Prevention of PHN by treatment during the acute stage of the herpes infection with a topical application of a solution of 40% idoxuridine in dimethyl sulphoxide has been claimed to reduce the incidence of PHN (Juel-Jensen and MacCallum, 1972). The specific herpes virus drug, acyclovir, does not lower the incidence of PHN or significantly affect the rate of pain subsidence (Bean et al, 1983). Once established, PHN is usually resistant to treatment. An initial conservative approach with transcutaneous electrical nerve stimulation (TENS), cold packs and other counter-irritative measures may be effective. A combination of anti-convulsant therapy, such as carbamazepine, with anti-depressants is also sometimes effective, especially if 'lancinating' or shooting pain is present (Fields, 1987). Sympathectomy or sympathetic block has been tried, but overall the results are disappointing.

Hyndman (1939) reported the case of a man suffering from post herpetic neuralgia on the left side of the head, neck, chest and upper limb, whose pain was cured (for 5 months at the time of the report) by the surgical removal of the left splanchnic nerves, the 1st and 2nd dorsal lumbar ganglia, the stellate and upper three thoracic ganglia. Leger and Audoly (1942) reported two cases of herpes zoster in which pain relief was afforded following infiltration of the homolateral stellate ganglion. Not all reports are so favourable, and in a similar way to the preceding types of pain syndrome in which there is evidence



suggesting a sympathetic component, sympathectomy does not always cure pain. Loh and Nathan (1978) report 6 cases of post-herpetic neuralgia, in which sympathetic block was transiently successful as a pain relief treatment in only 3. They also report a series of 31 out of 46 patients whose pain syndromes included hyperpathia. Sympathetic block relieved the pain and hyperpathia in 21 of these patients, but in the 15 other cases without hyperpathia, sympathetic block was only an effective treatment in 2.

#### b) Entrapment neuropathies

It was originally thought likely that the nerve damage which resulted in nerve entrapment was due to ischaemia, but Thomas and Fullerton (1963) showed that beneath a region of chronic compression segmental demyelination occurs, and proximal and distal to the lesion the fibres are normal. There is characteristic myelin slippage of the inner lamellae, and paranodal myelin tapering (Ochoa, 1972), and unmyelinated fibres are relatively spared (Ochoa, 1978). Thus there is a selective damage to large fibres as compared to small fibres, a situation which will be discussed later in relation to the development of chronic pain. Regenerating fibres in chronic entrapment syndromes become mechanically sensitive, so that the Tinel sign may be elicited on gentle tapping of the skin overlying the nerve lesion. Morton's neuralgia, due to plantar digital nerve entrapment, is often associated with severe destructive change in the nerve (Ochoa, 1976; Scadding and Klenerman, 1987).

Pain with entrapment neuropathies is usually not severe, and responds to relief of the compression. Occasionally, pain is persistent, and may be associated with evidence of sympathetic dysfunction. This is particularly true of painful ulnar nerve entrapment at the elbow, treated by transposition of the nerve, which may exacerbate the pain, possibly due to additional ischaemic damage to the nerve produced by the immobilisation of a length of the nerve to allow transposition.

#### c) Ischaemic neuropathies

Dyck et al (1972) found degenerative changes in the central portions of nerve fascicles in the upper arm and leg, and proposed that these changes followed ischaemia of these regions. Experiments by Parry

and Brown (1982), in which they produced similar changes in rats following injection of arachidonic acid, showed that there was selective loss of small myelinated and unmyelinated fibres. A far more widespread ischaemia affecting the whole limb, in patients undergoing amputation for major vessel atheromatous disease, was shown by Eames and Lange (1967) to cause segmental demyelination and Wallerian degeneration in the peripheral nerves. Signs of sensory neuropathy were found in 87.5% of these patients. Ischaemia may exacerbate painful symptoms in nerves which are already damaged. Gilliatt and Wilson (1954) demonstrated a more rapid onset of paraesthesiae following application of a pneumatic cuff in patients with carpal tunnel syndrome. There are no data concerning the response of the pain associated with ischaemic neuropathy to sympathetic blockade.

#### d) Diabetic mononeuropathies

Mononeuropathies are common in diabetics, affecting the cranial or peripheral nerves including the ulnar, median, peroneal, femoral and lateral cutaneous nerves of the thigh (Scadding, 1984). The nature of the pain is variable. In a study of 40 cases of diabetic neuropathy, Brown et al (1978) reported the incidence of a wide range of severity of pain, from painless distal sensory loss with loss of tendon reflexes and joint position sense, to cases of severe burning pain, cutaneous hyperaesthesia and autonomic disturbances.

Dreyfus et al (1957) found maximal degenerative changes in the centre of the third cranial nerve in a case of palsy of that nerve. Asbury et al (1970) reported similar changes in a similar case. Raff et al (1968) described punctate lesions in the nerves of a diabetic patient who had developed mononeuritis multiplex in the legs six weeks before death. In experimental streptozotocin induced diabetes, hypoxia reproduces some of the electrophysiological abnormalities associated with diabetes (Low et al, 1986), whilst hyperbaric oxygen will reverse some of these changes (Low et al, 1988). The addition of ischaemia to experimental diabetes in rats leads to more extensive fibre degeneration than is seen in diabetic controls (Nukada, 1986).

### 3. POLYNEUROPATHIES

The majority of polyneuropathies are painless, but certain types are characteristically painful, although the incidence of pain may be

very variable. Some polyneuropathies may be classified according to the fibre size loss. Several strands of evidence suggested that in situations in which small fibres predominated in peripheral nerves, there may be pain. Histological studies of hyperpathic scars had revealed a reduced population of axons, mainly comprising small fibres (Lourie and King, 1966). Noordenbos had reported a preferential loss of large fibres in biopsies of intercostal nerves from patients with PHN (Noordenbos, 1959), and Wortis et al (1942) had demonstrated that sensations evoked after A fibre block with a pneumatic cuff mimicked the unpleasant hyperaesthetic burning pain reported by patients with alcoholic peripheral neuropathy. These observations later led to a large number of morphometric investigations of painful and painless polyneuropathies (reviewed by Scadding, 1989), particularly following the first statement of the gate control theory of pain (Melzack and Wall, 1965). The original gate control theory of Melzack and Wall (1965), which is concerned with the interactions in the dorsal horn of the spinal cord, proposed that large diameter myelinated afferents exert an inhibitory effect on small unmyelinated nociceptive primary afferents via inhibitory interneurons and transmission cells. Loss of the input of some large myelinated fibres may therefore result in a loss of inhibition of nociceptive afferents, and an exaggerated response of spinal pain transmission cells to activity in unmyelinated nociceptors, producing a painful condition. The gate control theory of pain emphasized that the perception of pain resulted from a balance between the inputs of myelinated and unmyelinated fibres.

Painful polyneuropathies with small fibre loss include diabetic polyneuropathy. Morphometric studies of 2 sural nerve biopsies by Brown et al (1978) suggested that a loss of unmyelinated C fibres was primarily involved, with some loss of small myelinated fibres. But Behse et al (1977) in a study of sural nerve biopsies of patients with diabetic neuropathies, found a loss of large and small myelinated and unmyelinated fibres. Ward et al (1989) also found a loss of all types of fibre (motor, sensory and sympathetic) in their morphometric studies of diabetic neuropathy. There is probably a vascular and microvascular involvement also (Newrick et al, 1986). Other painful neuropathies with small fibre loss include amyloid neuropathy, Fabry's disease and dominantly inherited sensory neuropathy. Painful neuropathies with non-selective fibre loss include alcoholic neuropathies. Nutritional deficiency neuropathies also occur, such as Beri-beri, Strachan syndrome and Burning feet syndrome. Detailed morphometric studies have

not been reported in these conditions. Severe pain, often with a burning quality, is a feature of these last types of neuropathy.

Large fibre loss neuropathies are not usually associated with pain, but this is not invariable. Isoniazid or Pellagra neuropathies are painful with large fibre loss, whereas Friedreich's Ataxia and chronic renal failure result in a painless large fibre loss. The nervi nervorum, the innervation of the connective tissue of the nerve itself, are derived from the fibres of the nerve (Hromada, 1963; Thomas and Olsson, 1975), and are thought to play a role in the pain of some neuropathies (Thomas, 1974; Asbury and Fields, 1984). In some neuropathies, the disturbance may be metabolic rather than grossly structural. This last possibility is likely in untreated acute diabetes, in which the neuropathy may resolve rapidly on treatment of the underlying diabetes, in a manner which would be too rapid for remyelination or regeneration to have taken place (Thomas, 1982).

A study by Dyck et al (1976) of many types of painful neuropathy, including diabetic and alcoholic neuropathies and amyloidosis, found that patients with acute myelin breakdown tended to have more pain, but failed to find a correlation between fibre size loss and incidence of neuropathic pain. In summary, fibre dissociation, with preferential loss of large or small fibres or regeneration of small fibres cannot of themselves provide a satisfactory explanation of pain associated with peripheral neuropathy, since there are too many exceptions to the rule that fibre size loss is related to the incidence of neuropathic pain.

## B. Experimental Animal Physiological Studies of Damaged Peripheral Nerves

### 1. ACUTE EFFECTS

Adrian (1930) first demonstrated an impulse barrage arising from small sensory fibres when a peripheral nerve is sectioned, and described this barrage as prolonged. Gasser (1935) and Skoglund (1942) reported briefly on this discharge and in a later investigation, Granit et al (1944) found evidence of an immediate interaction between motor and sensory fibres when a peripheral nerve is injured either by compression, ligation or section. They also noted that the transmission of impulses from motor to sensory fibres was accomplished more easily than the reverse situation, and that the discharge was always long-lived but variably present and fragile. Wall et al (1974) were unable to produce more than a transient injury discharge on sectioning a peripheral nerve, and concluded that the prolonged discharge recorded by Adrian was an artefact, which may have resulted from drying of the nerve during recording, or calcium deficiency in the bathing Ringer solution or residual intact sensory endings on a side branch of the nerve. Wall et al (1974) and Wall and Gutnick (1974) were unable to reproduce the cross-talk seen by Granit et al (1944) and Granit and Skoglund (1945), although Devor and Bernstein (1982) reported evidence of an acute short-lived ephaptic cross-talk.

It is now accepted that the acute injury discharge ceases within minutes and the afferent fibres become silent (Wall and Gutnick, 1974; Wall et al 1974), although Devor and Bernstein (1982) did find occasional fibres with prolonged discharges.

### 2. CHRONIC EFFECTS

#### a) Ongoing activity.

Following the initial barrage, a chronic ongoing sensory afferent barrage develops (Wall and Gutnick, 1974), as early as 3 hours following section in some cases (Kirk, 1974). Govrin-Lippmann and Devor (1978), recording from rat sciatic nerve proximal to developing neuromas, found a steep rise in the ongoing activity barrage, which peaked 13 days after section, when 29% of the fibres examined were active. The bulk of the active fibres measured were sensory. Activity then declined to a steady state, with 4% of fibres examined being active. This level was maintained

for at least 190 days. Scadding (1981) studied mice, and found a slightly different picture, a combination of mechanosensitivity, adrenergic sensitivity and ongoing activity beginning 24 hours after nerve section and showing an early peak of activity at 3 days following section. Activity could also be evoked in previously silent fibres following light pressure, 68% of fibres being mechanosensitive. Of these previously silent but mechanosensitive fibres, 5.6% became continuously active following adrenaline administration. Evoked activity was also recorded from a further 15% of fibres, which only became mechanosensitive following application of adrenaline. Activity increased, and showed a second larger peak after 14 - 21 days, a large component of which was due to mechanosensitivity, following which time activity declined, but continued at a low level for at least 7 weeks. Ongoing activity was recorded in 16% of the fibres examined, although only 44% of these fibres were regularly firing, the others fired irregularly or intermittently. The firing pattern began after 24 hours of injury, and proceeded as previously described. The first part of the ongoing activity discharge in chronically sectioned rat sciatic nerves (up to 3 weeks after nerve section) is due principally to the activity of A fibres. Between 3 and 16 days after nerve section 17% of A fibres fire spontaneously, but the later longer-lasting low level discharge occurs primarily in C fibres, which begin to discharge as the A fibre barrage declines (Devor and Govrin-Lippmann, 1985). Blumberg and Janig (1984) report no A fibre peak in cats, and Lisney and Diamond (personal communication in Devor, 1989) report little or no ectopic impulse discharge in rabbits. Local administration of colchicine or vinblastine, by soaked pads of Gelfoam, to a sectioned and ligated nerve blocks ectopic impulse generation in rat sciatic nerve neuromas, probably by an effect on the axonal transport of ion channels (Devor and Govrin-Lippmann, 1983).

Reports of spontaneous activity made by recording just proximal to the neuroma (Govrin-Lippmann and Devor, 1978; Blumberg and Janig, 1981; Scadding, 1981) show that most of the activity arises in the neuroma itself. Calvin (1979) considers that the ectopic pacemaker capability of the proximal ends of severed axons and sprouts is the most significant feature of damaged nerves with regard to the abnormal sensations that may accompany injury. The mid-nerve, non-terminal part of mammalian axons which is adapted to conduction of impulses is not normally capable of impulse generation, even when depolarized for a sustained period (Wall and Gutnick, 1974; Ruiz et al, 1981; Devor and Bernstein, 1982). However, following damage, ectopic pacemakers develop on the ends of severed axons

and sprouts. Howe et al (1976) and Wall and Devor (1983) have detected low level ongoing activity arising in DRG cells, which is enhanced following stimulation of normal and injured peripheral nerves. The discharge is greatly exaggerated following peripheral nerve injury, and contributes ectopic impulses in addition to those of the neuroma (Kirk, 1974; De Santis and Duckworth, 1982; Wall and Devor, 1983; Burchiel, 1984).

Damaged afferent fibres in neuromas also develop other novel properties, including adrenaline sensitivity and mechanosensitivity.

#### b) Adrenaline sensitivity

The afferent barrage of ongoing activity may be increased by the administration of adrenaline, either by i/v or close arterial injection (Wall and Gutnick, 1974; Devor and Janig, 1981; Korenmann and Devor, 1981; Scadding, 1981). It was shown that the existing ongoing activity could be potentiated following administration of noradrenaline, and that some ongoing activity could be elicited from previously silent afferent fibres. However, not all fibres are sensitive to noradrenaline (Devor and Janig, 1981; Korenmann and Devor, 1981; Scadding, 1981). Similar potentiation of myelinated afferents can be obtained by stimulation of the lumbar sympathetic trunk (LST) (Devor and Janig, 1981; Blumberg and Janig, 1984). It has recently been shown that low frequency electrical stimulation or reflex activation of the LST can excite unmyelinated afferent C-fibres in neuromas-in-continuity in cat peripheral nerves (Habler et al, 1987).

This catecholamine sensitivity is an alpha-adrenergic effect. It has been proposed that alpha receptors may develop on regenerating primary afferent fibres, although there has been no direct evidence for this (Korenmann and Devor, 1981; Scadding, 1982). The alpha receptor agonist phenylephrine has been shown to increase the afferent barrage, but isoprenaline, a beta receptor agonist has no effect, even at high doses (Wall and Gutnick, 1974; Devor and Janig, 1981; Korenmann and Devor, 1981; Scadding, 1981). Antagonists to alpha receptors, such as phentolamine, have been shown to block excitation by adrenaline i/v injection, or LST stimulation, whereas propranolol, a beta receptor blocker has no effect (Korenmann and Devor, 1981). Neither phentolamine nor propranolol had any effect on the ongoing activity arising from neuromas in Korenmann and Devor's experiments (Korenmann and Devor, 1981).

It was originally thought possible that the effects on the afferent

barrage which were observed when adrenaline was injected were secondary to changes in the blood supply, i.e. vasoconstriction. It has since been shown that this is not so. Clamping of the main artery to a neuroma has been shown to cause an initial increase in firing, followed by a cessation of the discharge. These changes exhibit a long latency, in contrast to that seen following injection of adrenaline. Additionally, firing will increase if adrenaline is injected below the level of the arterial clamp (Devor and Janig, 1981; Korenmann and Devor, 1981).

Diamond (1959) had earlier shown an abnormal chemosensitivity of regenerating sprouts, but to acetylcholine, not noradrenaline or adrenaline, but this result has not been reproduced in later studies (Korenmann and Devor, 1981).

### c) Mechanosensitivity

A third property which develops in afferent fibres of damaged peripheral nerves is an abnormal response to light mechanical stimulation. Outgrowing regenerating axons may develop highly localized spots where minimal force from a very small probe may produce or increase ongoing activity in sensory fibres (Wall and Gutnick, 1974; Scadding, 1981; Devor and Bernstein, 1982; Blumberg and Janig, 1984; Burchiel, 1984). The duration of this discharge may be variable, ranging from immediate onset following the stimulus, of a duration equal to that of the stimulus, or it may outlast the stimulus by some time ('mechanical afterdischarge'). Devor (1984) proposed that the evoked neuroma impulses result from stretch-activated channel-induced generator potential in the proximal ends of severed nerves or sprouts. Clinically, mechanosensitivity is exhibited as Tinel's sign or as a neuroma which is 'tender' to touch, although some of this sensitivity is due to nerve trunk pain.

This abnormal sensitivity may be important in the exacerbation of pain seen when a limb containing damaged peripheral nerves is touched or moved (Bonica, 1979).

### d) Sympathetic efferent / Sensory afferent fibre interactions

Foerster et al (1929), in early experiments, manipulated the cervical sympathetic trunk and caused pain. They then cut the trunk and stimulated the central end, again with the production of pain. Touching the stellate ganglion was shown to produce pain in the upper limb, and touching the



lumbar chain produced pain in the lower limb. Shaw (1933) carried out a cervicothoracic ganglionectomy, then crushed the ganglion with forceps to produce excruciating burning pain with a latency of a few seconds. Removal of the ganglion by traction on the thoracic chain produced similar pain which lasted for 24 hours. Experiments in intact nerves have been performed which demonstrate the ability of sympathetic efferent fibres to influence sensory afferents. An interaction between the sympathetic supply and the somatic afferent nerve fibres in the pulp of the tooth of a cat was demonstrated, following stimulation of the sympathetic trunk (Edwall and Scott, 1971; Matthews, 1976). Motsnyi and Bagramova (1972) and Bagramova et al (1976) showed that the stimulation of the sympathetic nervous system and secretion of noradrenaline influences dorsal root potentials and the dorsal root reflex in the cat. They concluded that sympathetic activity and circulating noradrenaline were factors affecting the membrane potential of primary afferent fibres.

The first proposal that some kind of abnormal synapse formed between the sympathetic efferent and sensory afferent fibres in damaged nerves was made by Doupe et al (1944). They proposed that the normal insulation between fibres was disrupted by nerve damage, so that impulses passing in sympathetic efferent fibres could excite neighbouring sensory afferent fibres; this cross-stimulation was proposed to be the cause of causalgic pain. The hypothesis was given credence by work of Granit et al, (1944), and Granit and Skoglund (1945), who found that stimulating ventral roots following nerve section in a cat produced detectable impulses in the sensory roots.

Recent demonstrations of an interaction between sympathetic efferent and sensory afferent fibres by Devor and Janig (1981) and Habler et al (1987) have already been cited (p 30 ).

Doupe et al (1944) and Granit et al (1944) proposed that ephaptic transmission between axons was responsible for the response of sensory afferent fibres to sympathetic efferent fibre stimulation, and that some kind of abnormal synapse develops. Seltzer and Devor (1979) proposed that ephapses, i.e. tight electrical couplings, develop in neuromas, whereby stimulation of one fibre will excite another with very short latency, and with a high safety-factor of transmission. In 1978, Rasminsky demonstrated ephaptic cross-excitation in damaged roots of dystrophic mice, and Seltzer and Devor (1979) reported a small number (7%) of fibres in a neuroma one month after section or ligation and section, had developed a tight

electrical coupling, with a high safety factor of impulse transmission. Blumberg and Janig (1982) investigated superficial peroneal nerve following section, recording 6-8 cm proximal to the neuroma. Unmyelinated and thinly myelinated fibres were activated via the neuromas following stimulation of unmyelinated and myelinated fibres, but no involvement of sympathetic efferent fibres was found. Lisney and Pover (1983) recording from cat sensory nerve neuromas also found evidence of ephaptic cross-talk. Meyer et al (1985) studied neuromas which formed following crush and section of the superficial radial nerve in baboons, and found that single nerve fibre recordings from fibres in the neuromas demonstrated spontaneous activity and electrical coupling - crosstalk - between fibres. Devor and Bernstein (1982) report a looser form of coupling, which ~~is~~<sup>follows</sup> nerve damage. An impulse volley entering the neuroma generated a prolonged (up to tens of seconds) discharge in the strands of the nerve being recorded. This response had a long and variable latency, and was measured from the ventral roots following stimulation of the dorsal roots.

However, the interaction of sympathetic efferent and sensory afferent fibres shows long and variable latencies (Devor and Janig, 1981). Anatomical substrates for ephapses have not been found in ultrastructural investigations of experimental neuromas by Spencer (1971), Morris et al (1972) or Scadding (1982). However, Rasminsky (1980), in dystrophic mouse roots, Bernstein and Pagnanelli (1982) and Devor and Bernstein (1982), in rat sciatic nerve neuromas, have reported closely apposed axon membranes in unmyelinated fibres, which they felt might subserve ephaptic transmission. As anatomical substrates for ephapses or abnormal synapses developing in damaged peripheral nerves have not been unequivocally identified, and would not explain the early development of pain after nerve injury, it seems unlikely that they could provide the major mechanism of interaction between sensory and sympathetic fibres. The available evidence favours a looser form of interaction (Devor and Janig, 1981; Korenmann and Devor, 1981; Scadding, 1981): Noradrenaline released at the site of injury from sympathetic efferents may stimulate abnormally sensitive sensory afferents, due to the development of alpha receptors on the axolemma, with diffusion of transmitter across short distances between sprouts, in the absence of specialized contacts (Scadding, 1982). A loose electrical coupling may also develop between sensory afferent and sympathetic efferent fibres (Devor and Bernstein, 1982).

Thus, the sensitivity of the damaged sprouting sensory fibres to

noradrenaline, ongoing activity and the abnormal mechanical sensitivity are all likely to be contributing factors to pain production in damaged nerves. Torebjork and Hallin (1979) have reported the case of a patient with incomplete nerve transection and with successfully treated causalgia who exhibited abnormal peripheral sensitivity to noradrenaline. This patient had hyperalgesia in the left hand distal to the site of the nerve lesion, and a narrow range of temperatures which could be tolerated without pain (25 - 33°C). An intracutaneous injection of 1 µg noradrenaline into the hand provoked a severe pain attack in the entire left arm, which lasted for several hours, and was unresponsive to large doses of intramuscular morphine. Scadding (1982) suggests that abnormal impulses may arise from sensitized peripheral regenerated fibres as well as from those at the site of the nerve lesion, as a possible explanation of why the pain from incomplete lesions tends to be more severe than that of complete transections. Wynn Parry (personal communication in Scadding, 1982) comments that some patients report worsening of their dysaesthesias following nerve grafts or repair.

### 3. DORSAL ROOT GANGLION CELL CHANGES FOLLOWING PERIPHERAL NERVE INJURY

The changes which occur in the cell body of a peripheral axon following its interruption affect the regeneration of that axon since the cell body is responsible for the growth and maintenance of that axon. Nissl, in 1892, first described morphological changes in the cell body following severance of its axon. These included swelling of the cell, movement of the nucleus to an eccentric position and the disappearance of basophilic (Nissl) substance from the cell cytoplasm. This process is generally termed 'chromatolysis', but Grafstein (1975) suggests 'cell body response' is a more suitable term. Immediately following mechanical trauma, there is a depolarization of the membrane at the site of the injury which lasts for several hours (Evans and Saunders, 1974), and is responsible for a lowering of membrane potential over the whole cell. This change in membrane potential in the cell body may be responsible for the initial swelling of the cell, following abnormal water movement, and during later stages of the reaction the cell is swollen with a reservoir of materials for axon formation (Grafstein, 1975). Changes in the neuronal membrane potential may be followed by a loosening of the perineuronal-glial cell attachment, and in some cases the glial cell may become interposed between the injured neurone and the presynaptic fibres ending on it (Blinzinger and Kreutzberg, 1968; Kerns and Hinsman, 1974).

There is an increase in RNA synthesis (Lieberman, 1971; Murray, 1973) in readiness for increased protein synthesis (Lieberman, 1971). Although there is an increase in protein synthesis of structural proteins, there is a decrease in the content of many proteins required for synaptic transmission. In sympathetic neurones, for example, there is a decrease in dopamine beta hydroxylase (Kopin and Silberstein, 1972), tyrosine hydroxylase (Cheah and Geffen, 1973), and monoamine oxidase (Harkonen, 1964). Generally, there is a decrease in the production of transmitter components in favour of structural components, in a similar pattern to that seen in immature neurones (Griffin and Lavelle, 1971; Grafstein, 1975).

Lipid synthesis also increases very soon after axotomy (Harkonen and Kauffman, 1974) presumably for use in the synthesis of membrane components of the neurone. Following synthesis of components within the neurone, materials for the growth of the axon are transported to

their required site by axonal transport. This is not immediately affected by axotomy - materials continue to move along the intact portion of the axon in the same volume and at the same rate as that before injury leading to an initial accumulation of material proximal to the point of section (Grafstein and Murray, 1969; Grafstein, 1971). The variation in axonal transport begins about 2 days after injury, initially with a decrease (Boyle and Gillespie, 1970; Karlstrom and Dahlstrom, 1973; Reis and Ross, 1973) and much later following onset of axonal outgrowth with an increase in both amount and transport rate of protein materials (Grafstein and Murray, 1969; Grafstein, 1971). This modification of transport begins following increased RNA and protein synthesis (Grafstein, 1975), and ribosomes may be seen in axons (Lieberman, in Grafstein, 1975) suggesting that protein synthesis above and beyond the normal rate occurs during regeneration. Intact side branches of the axon and dendrites also participate in the above changes, so that the whole field of distribution of the neurone may be affected (Reis and Ross, 1973; Sumner and Watson, 1971).

However, not all neurones survive, and depending on the location of the axonal damage a large number may die. Purves (1975) reports half the neurones in the superior cervical ganglion of adult guinea pigs died following crush of the major efferent axons. There have not been many studies of cell death following loss of efferent axons. Lieberman (1971) reports that neuronal loss is greater in young animals than adults, and Romanes (1946), for example, reported a 40-50% loss of spinal motor neurones within 7 days of axotomy in neonatal rats. Early studies demonstrated that the site of the lesion is important in relation to the amount of cell death which ensues. Romanes (1941) could not detect chromatolysis following distal nerve section in a limb, whereas section of a nerve close to the ganglion resulted in a 50 per cent loss of ganglion cells within two months (Ranson, 1906).

Histochemical changes also occur. Fluoride resistant acid phosphatase (FRAP) is synthesized in some small cells of the DRG, and is depleted following peripheral nerve section within 4 days, showing that the cells of the DRG have reacted to injury (Schoenen et al, 1968; Kniyhar and Csillick, 1976). There is also a decrease in substance P, the main transmitter of primary sensory neurones, and also of cholecystinin (Jessell et al, 1979). Substance P decreases by about 48% 4 - 28 days following sciatic nerve section.

Physiological changes important to the pain of peripheral nerve injury also occur. Normal DRG cells have an ectopic pacemaker ability, and may discharge spontaneously (Howe et al, 1976; Wall and Devor, 1983). This discharge may increase following chronic nerve section, and contribute to the afferent impulse barrage originating from the neuroma. DRG cells are also highly sensitive to mechanical distortion (Howe et al, 1977). In addition to the changes which may follow traumatic nerve injury, Mayer et al (1986) and Schon et al (1987) showed that DRG cells may become electrically coupled, forming a syncytium, following Herpes simplex infection. This formation might serve to amplify any ectopically generated impulses and impulse activity from the periphery, and neurons beyond those in which the activity was originally evoked may become excited. This development may have a possible role in the pain of PHN.

In addition to evoking activity in the DRG cells, a cut sciatic nerve is capable of evoking dorsal root potentials on roots which are distant and contain no cut fibres. Within 4 days of peripheral nerve section there is a loss of the dorsal root potential generating mechanism around the central ends of the cut fibres (Wall and Devor, 1981). Nerve root damage may also cause chronic pain. Root compression is often painful and associated with paraesthesiae. Howe et al (1977) found that compressed roots may generate ectopic impulses and are sensitive to mechanical distortion.

#### 4. CNS CHANGES FOLLOWING PERIPHERAL NERVE INJURY

Light microscope changes in afferent terminals in the spinal cord are not seen in the first two weeks following peripheral nerve section (Wall and Devor, 1982), in contrast to central degeneration in the trigeminal cell bodies following nerve section or tooth extraction (Grant and Arvidsson, 1975; Westrum et al, 1976). Ultrastructurally, however, the picture is quite different. Six days following sciatic nerve section, changes were seen in the upper layers of the dorsal horn, which were more marked by two weeks following section (Csillick and Knyihar, 1978). They observed accumulations of whorl-like bodies, cytolysosomes, and osmiophilic dark particles in axon boutons. Small axons were seen to contain glycogen particles and clustered synaptic vesicles. Other changes included disintegrated mitochondria and changes in ground substance. These changes were called synaptic atrophy. Moradian and Rustioni (1977) observed degenerate large and

small primary afferent terminals in the dorsal horn, following section of upper limb nerves in the rat.

Histochemical changes include a disappearance of fluoride resistant acid phosphatase (FRAP), which is a marker for primary afferent terminals in the substantia gelatinosa, from this site following sciatic nerve section in rats (Knyihar and Csillick, 1976). Devor and Claman (1980) narrowed down this location to segments L4 and L5 following sciatic nerve section, showing that this must be the locus of the terminations of unmyelinated primary afferent axons from the sciatic nerve. Substance P, the transmitter in primary sensory neuromas, is depleted by 75-80% in the dorsal horn 7 days following sciatic nerve section (Jessell et al, 1979), but the ventral horn was unaffected. These histochemical changes serve to illustrate the large scale changes which occur centrally in afferent terminals following nerve section.

Cell death in the DRG, or root section, will lead to deafferentation of dorsal horn cells in the spinal cord. Some of these cells may take on new receptive fields in the periphery following a section or ligation injury (Devor and Wall, 1978), but not following a crush injury (Devor and Wall, 1981). Deafferented cells may become spontaneously active and may contribute to the pain of peripheral nerve lesions (Loeser and Ward, 1967). Partial deafferentation may lead to increased sensitivity developing in the remaining cells. A beta fibres probably exert an inhibitory effect on A delta and C fibres in the spinal cord dorsal horn (Woolf and Wall, 1982). It has been shown that the loss of the large myelinated fibre input from A beta fibres which follows chronic peripheral nerve section results in disruption of this inhibition, and may contribute to the generation of chronic pain by increasing the excitability of dorsal horn A delta and C neurones (Woolf and Wall, 1982). Whether this inhibition is mediated pre- or post synaptically, or both, has yet to be determined, but Woolf and Wall propose that presynaptic inhibition is likely to be the major mechanism.

The previous evidence outlines the changes which occur following peripheral nerve injury, and serves to illustrate that pain cannot be explained solely on the basis of peripheral changes. Secondary central nervous system changes, for example in the dorsal horn, may be of equal importance.

## 5. THE POSSIBLE IMPORTANCE OF THE SYMPATHETIC NERVOUS SYSTEM IN PAINS UNRELATED TO NERVE INJURY

The sympathetic nervous system may also become important in relation to the production and maintenance of pain in certain situations when there is no nerve injury. This role in RSD resulting from non-neural injury has already been discussed. In addition, there is new evidence of involvement of sympathetic efferent fibres in experimentally induced arthritis and in rheumatoid arthritis (Levine et al, 1986; 1988).

Arthritis can be experimentally induced by the intradermal injection into rats of a suspension of *Mycobacterium butyricum* in mineral oil (Pearson and Wood, 1959), and the severity of the resulting disease assessed by the use of X-rays and a grading scale (Ackerman et al, 1979). Levine et al (1985) found that sympathectomy by guanethidine or reserpine administration reduces reflex neurogenic inflammation which may be generated away from the injury site, and also (Levine et al, 1986) that sympathectomy reduces inflammation and injury at the affected joint site. It was also demonstrated that regional sympathetic block with guanethidine reduces pain and increases pinch strength in patients with rheumatoid arthritis (Levine et al, 1986). Levine et al (1988) investigated the effects of treating the experimental arthritis with sympatholytic agents before and after the onset of clinical symptoms. Sympathectomy retarded the onset of disease (Levine et al, 1986), and reduction of sympathetic activity produced highly significant lessening of joint injury when treatment was begun after the onset of clinical symptoms. Levine et al (1988) also investigated the effect of receptor selective adrenergic blocking therapies, and discovered that the most successful therapy was beta receptor antagonists, specifically beta<sub>2</sub> blockade. There is also evidence of the involvement of sensory afferent fibres. Depletion of unmyelinated peripheral afferent axons with capsaicin depletes substance P and lessens the inflammation which results from the injection of noxious substances (Gamse et al, 1980). Colpaert et al (1983) and Levine et al (1986) showed that neonatal administration of capsaicin attenuated joint injury following induced arthritis. Thus it has been shown that activity in both sympathetic efferents and large and small diameter primary afferents influences the severity of joint injury in arthritic rats (Levine et al, 1986).



On the basis of these observations, Levine et al (1986) proposed that there was an interaction between sympathetic efferent and primary afferent nociceptors which may increase inflammation and pain in arthritis and that beta<sub>2</sub> receptor antagonists may have significant clinical value in the treatment of pain and inflammation of arthritis (Levine et al, 1988).

Sympathetic efferent activity is not normally thought to influence primary sensory afferent fibre function, in the absence of peripheral nerve injury or peripheral injury. However, sympathetic efferent fibre endings are found in close association with primary afferent terminals, for example, the Pacinian corpuscle, (Pease and Quilliam, 1957; Santini, 1968, 1969; Santini et al, 1971). Sympathetic efferent fibres have also been shown to be closely apposed to DRG cells (Owman and Santini, 1966) and Gasserian ganglion cells (Santini, 1966, 1972). Santini (1976) reported that preganglionic stimulation of sympathetic fibres in a cat mesentery preparation gave mixed results in the Pacinian corpuscles, some afferent fibres were excited (29%) whilst others were inhibited (34%). Stimulation of the sympathetic supply of the DRG cells produced an initial excitation of the Pacinian corpuscle, followed within 100secs by inhibition (Santini, 1976). Another example of the interaction of sympathetic efferent and sensory afferent fibres in the tooth pulp of cats has been previously described (page 32, Edwall and Scott, 1971; Matthews, 1976).

Reserpine and monoamine oxidase inhibitors have been demonstrated to decrease amino acid levels in the Gasserian (trigeminal) ganglion (Santini and Berl, 1972) and Santini (1976) suggests that the sympathetic efferent supply to these ganglia could have a role in regulating amino acid production. He proposed that the sympathetic and sensory neurones are coupled, and the primary sensory neurones are a feedback target for the sympathetic efferent neurones. The possible role of sympathetic efferent fibre activity on the responses of primary afferent fibres is a relatively under-investigated area of sensory neurophysiology, which merits further study.

## 6. ANIMAL 'MODELS' OF CHRONIC PERIPHERAL NERVE INJURY

Much of the detailed knowledge about the physiology of pain which may follow peripheral nerve damage has come from animal experiments. Wall and Gutnick (1974) first noted self-mutilation of the anaesthetic

area, autotomy, following peripheral nerve section in rats. Wall et al (1979a) proposed that the self-mutilation activity was a reaction to a chronic painful condition which they termed 'anaesthesia dolorosa'. They also proposed that the magnitude of the behavioural response was related to the extent of dysaesthetic or painful symptoms. It was proposed that autotomy may be caused by spontaneous abnormal activity generated in the regenerating axonal sprouts of the neuroma (Wall et al, 1979a,b; Weisenfeld and Lindblom, 1980; Scadding, 1981; Devor and Raber, 1983). Scadding (1981) found a reasonable correlation between maximum afferent activity (ongoing activity, mechano-and adrenaline sensitivity) and maximum autotomy in mice. In rat and mouse neuromas, sympathetic activity seems to be important in the development of autotomy, since guanethidine in high doses inhibits autotomy (Wall et al, 1979a; Scadding, 1982). Autotomy following sciatic nerve section is increased following treatment with a MAO inhibitor, pargyline, which increases noradrenaline levels but has no effect on denervation (Yasumo et al, 1984).

The usefulness of autotomy as a measure of pain or dysaesthesia, has been questioned. Sweet (1981) and Rodin and Kruger (1984) consider that autotomy is simply an attack by the animal on a denervated insensate limb, which is recognized as possibly foreign. However, there is no evidence for a simple correlation between the amount of denervation and autotomy (Coderre et al, 1986). Wall et al (1979b) reported that the degree of autotomy following saphenous nerve section is less than that which follows sciatic nerve section. If both nerves are sectioned, autotomy is maximized. However, a more extensive nerve section would also be likely to increase spontaneously generated abnormal impulses (Coderre et al, 1986). Autotomy is reduced if the nerve is crushed rather than sectioned (Wall et al, 1979b). The incidence of autotomy is reduced following intrathecal administration of morphine and increased following naltrexone, an opioid antagonist (Weisenfeld-Hallin, 1984).

There is also behavioural evidence that points to autotomy being a response to painful sensations. Autotomy following distal rhizotomy is associated with distress in the animal being handled and hyper-reactivity to touch (Heybach et al, 1979). Lombard et al (1984) found highly disturbed slow wave sleep in animals exhibiting autotomy in response to dorsal rhizotomy. Sleep disturbances are common in patients with pain and dysaesthesiae (Sternbach, 1984; Sweet, 1981).

Weisenfeld and Hallin (1980) found that rats with sectioned sciatic nerves reacted in a stressful way when housed in a cold environment; and Chudler and Dong (1983) found severe autotomy after sciatic nerve section more often in rats housed in isolation.

Although autotomy may be indicator of the response to chronic pain, autotomy scores alone may not be a reliable index of pain level. Chudler and Dong (1983) report abnormalities in motor behaviour, and decreases in body weight following sciatic nerve section, which are indicators that the animal may be in pain, but these changes did not correlate with autotomy. Also, autotomy is known to cease about six weeks following nerve section (Wall et al, 1979a, b; Scadding 1981, 1982) whereas clinically, chronic pain may persist for months or years. Autotomy patterns change following increased deafferentation of the dorsal horn neurones by capsaicin and thus the main role in the automutilating behaviour is assigned by some studies to activity in dorsal horn neurones (Nagy et al, 1986; Russell and Burchiel, 1986).

The majority of the experiments described above used nerve section or section with ligation to mimic painful peripheral nerve injuries which are seen clinically. There are obvious limitations in using these types of animal nerve injury as suitable 'models' for the human situation, in which a wide variety of nerve lesions may lead to pain. Bennett and Xie (1988) have investigated an injury in which a series of loose ligatures are tied around a peripheral nerve, barely constricting the nerve. This situation seems to produce allodynia and hyperalgesia, as inferred from the animal's response to being placed on a chilled floor, or to innocuous mechanical stimulation. Gross changes were also seen as overgrown claws of the affected foot. Additionally, the onset of apparently painful symptoms is more acute and severe, if autotomy is used as an indicator of pain. It is suggested that this is a better model of a chronic partial nerve lesion and that the type of pain syndrome produced may better mimic causalgia than that which follows nerve section. Use of this type of injury in experimental animals may pave the way for further useful research into the painful sensory disorders which accompany peripheral nerve injuries.

## C. Anatomical Studies

### DEGENERATION AND REGENERATION MECHANISMS IN INJURED PERIPHERAL NERVES

#### 1. Proximal stump degeneration

Following nerve section, the most traumatic form of peripheral nerve injury, retrograde changes occur in the proximal stump. Immediately following nerve section the stumps of the nerves retract, due to the fact that the nerve is normally held under tension, creating a small gap between the proximal and distal stumps. The axons within the stumps also retract in an individual manner, and assume a spiral configuration.

##### a) Myelinated Fibres

Degenerative changes in the proximal stump begin very soon after nerve section, in as little as 4 - 6 hours, in the axons immediately proximal to the point of section (Cajal, 1928). Cajal demonstrated that axons swell in response to injury, on both sides of a transection or crush. These axonal swellings contain accumulations of abnormal organelles, as detailed later. The axon is later extruded from the myelin sheath, shrinks and degenerates and is then ingested and removed by the Schwann cell and invading macrophages. Cajal showed that most axons degenerate proximally to the first internode, although in some smaller fibres degeneration extends much further, and in larger fibres sometimes only extends to the nearest Schmidt-Lanterman incisure. The distance up to which fibres degenerate proximally is not certain. Ranson (1912) reports degeneration of fibres 3-4cm proximally, by light microscopy, whereas Morris et al (1972a), in a fine structure study, report extensive myelin degeneration 36 hours after section in the terminal 1.5mm of the proximal stump, which corresponds to the maximum internodal length in mammalian myelinated fibres (Williams and Wendell-Smith, 1971). The axons of myelinated fibres swell in response to transection, and this swelling and accumulation of organelles results in myelin slippage in the terminal portions of fibres in the proximal stump (Friede and Martinez, 1970). The myelin sheath then degenerates, usually as far proximally as the first node, but the degree of degeneration depends on the level of injury in relation to the Schwann cell nucleus (Lubinska, 1961). The myelin lamellae first split apart, and the sheath takes on a wrinkled appearance. It then

fragments into ellipsoids and the degenerate myelin is then further broken down by lysosomal activity in the Schwann cells and subsequently removed by macrophages.

b) Unmyelinated fibres

Unmyelinated fibres in the proximal stump of a sectioned nerve also swell in response to section, and accumulations of cellular organelles are seen within them. Lampert, (1967) suggests that these changes should be described as 'reactive' rather than degenerative. Although there is no well defined distinction between 'reactive' (degenerate or arrested profiles) as opposed to regenerative profiles (swollen growth cones), Lampert (1967) suggests that reactive axons have a higher organelle content. Unmyelinated axons begin to regenerate very quickly after damage, within 4-6 hours (Cajal, 1928), so it is difficult to distinguish degenerating fibres from regenerating sprouts.

The organelles which accumulate in unmyelinated axons proximal to a constriction or section of a peripheral nerve include normally occurring organelles, such as distended neurotubules, normal or swollen mitochondria (Blumcke et al, 1966; Zelena et al, 1968) and large accumulations of dense-cored and clear vesicles (Grillo and Palay, 1962; Kapeller and Mayor, 1969; Spencer, 1971; Morris et al, 1972). The class of dense-cored vesicles was further divided by Pellegrino de Iraldi et al (1964) into large and small granular vesicles. These vesicles are thought to be catecholamine storage sites (Grillo and Palay, 1962; Tranzer and Thoenen, 1967; Tranzer and Richards, 1976; Lascar, 1980), and this accumulation is discussed further under the heading of axoplasmic transport.

Several abnormal organelles may also be found, such as lamellar osmiophilic bodies (Zelena et al, 1968; Kapeller and Mayor, 1969; Morris et al, 1972c). These have been suggested to be degenerate mitochondria (Weiss and Pillai, 1965; Lampert, 1967). Dense bodies of various sizes, some of which may be lysosomal are also found (Holtzman and Novikoff, 1965; Morris et al, 1972). Alveolate vesicles, sometimes with densely staining oval structures, (Morris et al, 1972c) are seen, which Richards and Tranzer (1975) describe, if clear, as large elongated vesicles, and suggests that they may represent sections of smooth endoplasmic reticulum. Clear vesicles and multivesicular bodies (Wettstein and Sotelo, 1963; Blumcke et al, 1966; Roizin et al, 1967;

Zelena et al, 1968; Lascar, 1980) are also found.

The origin, nature and functions of organelles which accumulate in the axoplasm of constricted or sectioned peripheral nerve axons, particularly the dense-cored vesicles, has been the subject of much study (Webster, 1962; Wettstein and Sotelo, 1963; Holtzman and Novikoff, 1965; Blumcke et al, 1966; Zelena et al, 1968; Ballin and Thomas, 1969; Kapeller and Mayor, 1969; Martinez and Friede, 1970; Tranzer and Richards, 1976; and Lascar, 1980).

The mitochondrial accumulation may be the result of migration from other parts of the axon, or in situ synthesis. The latter theory is considered unlikely by Martinez and Friede (1970), in view of the more than 10-fold increase in organelles within 48 hours. Such a multiplication factor is inconsistent with the low levels of RNA measured from the axoplasm (Edstrom et al, 1962), which are required for synthesis. In addition to organelle accumulation, there is an accumulation of amorphous axoplasm (Martinez and Friede, 1970).

Dyck and Hopkins (1972), studying degeneration of unmyelinated fibres in the rat cervical sympathetic trunk, report that 34 hours after crush injury many of the swollen fibres had been replaced by watery empty spaces containing small clumps of axonal material, absence of tubules and filaments, and occasional clumps of electron dense material. Some swollen fibres 3 and 4 um in diameter were still persisting. Morris et al (1972c) describe 3 types of abnormally enlarged non-myelinated axons containing accumulations of organelles classified according to size:-

- a) 'Supergiant' axons, greater than 10um in diameter. These may be components of regenerating units, and were seen 8, 12 and 14 days following nerve section.
- b) 'Giant' axons, 3-10um in diameter, present as single fibres. These fibres did not always have an accumulation of organelles.
- c) Non-myelinated axons, 0.5-8um in diameter, grouped in clusters, but not identified as type II regenerating units, the clusters containing between 2 and 40 axons. By 69 hours after crush, no intact unmyelinated fibres were visible, but Schwann cell nuclei had proliferated, and clusters of finger-like processes of Schwann cell cytoplasm were forming within basal lamina tubes.

Observations on the persistence of degenerating unmyelinated nerves are always complicated by the presence of regenerating axonal sprouts, since regeneration of unmyelinated fibres begins early following nerve damage and is prolific.

## 2. Proximal stump regeneration

Regeneration of unmyelinated fibres is more rapid than myelinated fibres (Dyck & Hopkins, 1972); although the earliest studies of peripheral nerve regeneration were concerned with myelinated fibre regeneration, due to limitations of the available technology.

### a) Regeneration of Myelinated fibres

Sprouting of myelinated fibres from the proximal stump of a sectioned nerve is very prolific in the first few days after section. In Cajal's study of 1928, he noticed "buds" or "clubs of growth" on the preserved parts of terminal axons. "Clubs of growth" were also seen on collateral axons. Cajal (1937) later named these terminal clubs "Growth cones". Cajal also noted the retrograde growth of long ranging sprouts, and a later study by Aitken (1949) reported that up to 50% of the sprouts originating from myelinated fibres in neuromas grow in a retrograde direction. Sprouts with a spiralling form were described by Perroncito (1907), and the sprouts intermingled to form a complex network of fibres, Cajal (1928). Axons that had no necrotic portion on the distal stump sprouted directly from this terminal region. However, the majority of sprouts were collateral, preferentially, but not exclusively from the node of Ranvier (Cajal, 1928). Most sprouts arose from the terminal preserved node, although a minority have been reported to arise internodally (Friede and Bischausen, 1980). Such sprouts have not been conclusively demonstrated in micrographs however, and the proposal that fibres may sprout between nodes is not universally accepted. All sprouts remained within the basal lamina (Friede and Bischausen, 1980).

Growth cones consist of swellings on the terminal growing portion of an axon, and are distinguished not only by an accumulation of organelles, but also by filopodial outgrowths, which move to and fro, as seen under the microscope in tissue culture (Ochs, 1982). These outgrowths may be 10 - 20um long, with a diameter of 0.3um, consisting mainly of a fine filamentous matrix (Tennyson, 1970), composed of

microfilaments (Yamada et al, 1971). Many microtubules and neurofilaments are also seen in the filopodia. These organelles are synthesized in situ from materials such as tubulin and neurofilament triplet protein subunits, transported by slow axoplasmic transport to the sites where they are required (Friede and Bischausen, 1980; Ochs, 1982). Although these components are transported by slow axonal transport, Hoffman and Lasek (1980) and Hoffman et al (1981), found a much increased rate of transport of tubulin in regenerating nerves, but neurofilament triplet protein transport was decreased by 50%. Tubular vesicles of smooth endoplasmic reticulum are seen in close association with microfilaments in the filopodia (Bray, 1973). Dense cored vesicles and cisternae are also seen at the base of the filopodia, near to the body of the growth cone, and are thought to be a packaging depot for transport of materials back to the perikaryon (Bunge, 1973). Bunge et al (1982) consider the dense vesicles to be a preparation artefact, the morphology in the living state being somewhat different. Growth cones retract and extend during regeneration, the movement probably due to the actomyosin content of the filopodia (Bray, 1979).

Not all axonal sprouts which arise in peripheral nerves remain viable, Young (1942) reports that progressively fewer axonal bulbs and spiral formations are seen in older neuromas, sprouts which do not reach their peripheral target being sometimes absorbed. Fibres which do not make peripheral connections may contribute to lasting pain after peripheral nerve injury (Scadding, 1982).

The advent of electron microscopy provided the impetus for many studies on the early regenerative changes in myelinated fibres, including those of Blumcke and Niedorf (1965), Morris et al (1972 b-d) and Friede and Bischausen (1980). Morris et al studied the sprouting of myelinated fibres at various distances proximally from the point of section, over a period of time. In this paper (1972b), axon sprouts were seen 36 hours after section in the terminal 1.5mm of the proximal stump, but further proximally (3-4.5mm from the tip) no sprouts were seen in association with myelinated axons until 7 days following section; therefore the most prolific sprouting does occur in the most distal portion of the proximal stump one week following section.

Morris also describes two types of "regenerating units". Type I: single myelinated axons associated with one or more non-myelinated axons. These myelinated axons had a normal ratio of myelin thickness



to axon diameter, and therefore had not regenerated. Early formations of type I units were surrounded by an intact basal lamina. Type II: comprising non-myelinated axons only. Several criteria are proposed to differentiate type II regenerating units from groups of normal unmyelinated axons:

1. Groups were approximately circular in transverse section.
2. Not all of the profiles in the Schwann cell unit were individually enveloped by the Schwann cell, some sprouts were clustered together especially in groups containing more than 10 axons. Groups in developing peripheral nerves also exhibited this feature.
3. Some large axons, diameter up to 6.0um were present.
4. A number of the groups possessed a loose basal lamina, with a serpentine configuration.

At either end of the spectrum, some type II regenerating units consisted of only one large axon, whilst others contained up to 80 sprouts. Some unmyelinated axons were seen in type II units 7 days after section, and by 10 days after section nearly all groups contained at least one unmyelinated fibre. By 10 days following section, Schwann cell cytoplasm had penetrated between the axons, producing endoneurial spaces and giving a 'looser' appearance to the groups. The original enclosing basal lamina also became fragmented. The clear subdivision of axons into either type I or type II regenerating units became blurred after 10-14 days due to the separation of axons by collagen and perineurial-type cell processes.

The number of regenerating units seen in the nerve varied both with time after section, and distance from the point of section. There were more regenerating units at the distal tip of the nerve, although the number seen more proximally rose with time following section, so that 14 days following section, 12% of the total neural elements consisted of regenerating units 3-4.5mm proximal to the point of section. The proportion of type I regenerating units decreased with time, indicating that many of the non-myelinated profiles seen shortly after nerve section arose from myelinated fibres; and also that the non-myelinated profiles further proximally in the nerve were the result of demyelination. This last observation illustrates the difficulty in identifying profiles as being unmyelinated rather than not-yet-myelinated axons in neuromas, although size is often a helpful guiding factor.

## b) Sympathetic unmyelinated axon regeneration

Many studies of unmyelinated axon regeneration have been performed on autonomic nerves, to avoid the 'contaminating' effect of non-myelinated sprouts from myelinated fibres. (Dyck and Hopkins, 1972; Bray et al, 1972). The population of unmyelinated C fibres in mixed peripheral nerves consists of sympathetic efferent and sensory afferent fibres, and the changes following injury in both types of unmyelinated fibre are similar. Cajal (1928) reported orthograde but not retrograde growth of unmyelinated fibres close to the wound site within a few hours of injury. Rapid degeneration and regeneration occurs in postganglionic sympathetic nerves, such as the rabbit anterior mesenteric nerve (Bray et al, 1972; Aguayo et al, 1973b) and rat carotid nerve (Matthews, 1973). In the preganglionic rat cervical sympathetic trunk, following crush, degeneration had begun by 3 days, and regeneration by 5 days (Dyck and Hopkins, 1972). Electron microscope studies have demonstrated small axonal sprouts 1-2mm proximal to the point of injury one day following section, although these could not confidently be identified as unmyelinated axonal sprouts (Morris et al, 1972c). Studies in the postganglionic rabbit anterior mesenteric nerve found sprouting within 2 days (Aguayo et al, 1973b). Ohshiro et al (1978) also found sprouting at 2 days, and reported a regeneration rate of 4mm/day. The most striking feature after crush/transection injuries is the presence of increased numbers of small axons in each Schwann cell (Dyck and Hopkins, 1972; Bray et al, 1972; Aguayo et al, 1973a,b). This is due to sprouting. Aguayo et al, (1973b) report as many as 200 sprouts per Schwann cell, the largest being 0.4um in diameter. These changes were originally interpreted as degenerative (Taxi, 1959). McQuarrie et al (1978) in a NA fluorescence study, found an increase of 75% in the numbers of adrenergic axons 0.35mm from the distal tip of a sectioned nerve as compared to the numbers 1.4mm from the tip, showing that sprouting must have taken place. They also reported the effect of transecting the tibial nerve 2 weeks before a crush injury of the sciatic nerve. The transection or 'conditioning' lesion caused an impairment of regeneration of adrenergic axons, so that 1.4mm distal to the testing crush, the numbers of axons in animals with a conditioning lesion were 24% less than those in animals with a crush lesion only. These clusters of sprouts appeared to be enclosed in distended Schwann cell cytoplasm, and the close apposition of sprouts meant that many profiles were isolated from Schwann cell cytoplasm (Aguayo et al, 1973a). Two weeks

following section, Schwann cell processes separated the axons into smaller bundles in a similar manner to that seen in myelinated fibre sprouts. By 13 weeks following lesion, all axons were separated one from another by Schwann cell processes (Aguayo et al, 1973b), although individual sub units remained large, and it was concluded that transection simulates fetal patterns of neurogenesis. If longitudinal growth of fibres was prevented by the enclosure of the severed nerve in a silicon rubber tube, lateral growth was reduced and axons failed to fill the proximal portion of the tube. Aguayo et al (1973b) also reported that many small sprouts failed to mature. By 13 weeks, small axonal profiles persisted, by which time a normal size distribution had been attained in nerves which were able to make a peripheral connection. Aguayo et al (1973b) and Bray and Aguayo (1974) concluded that peripheral connections and the disappearance of sprouts which have failed to make correct connections are necessary factors in the full maturation of unmyelinated axons. Myelinated fibres are also thought to influence the orientation of growth of unmyelinated fibres (Evans and Murray, 1954). King and Thomas (1971) showed that following a crush injury to the rabbit cervical vagus nerve, unmyelinated axons become diverted to the laryngeal nerve and are orientated circumferentially around regenerating myelinated axons. This influence presumably results from the proliferation of Schwann cells to form longitudinally orientated columns, which direct the regeneration of unmyelinated fibres.

One of the major problems in a study of regeneration of unmyelinated fibres is the difficulty in differentiating between axonal sprouts and Schwann cell cytoplasm profiles. Dyck and Hopkins (1972) addressed this problem by serial sectioning without success. Generally axonal sprouts have a pale axoplasm, and a regular arrangement of microtubules and neurofilaments. Schwann cell cytoplasm usually contains elements of rough endoplasmic reticulum and occasional scattered microtubules and small bundles of intermediate filaments.

Growth of unmyelinated axons, of both sympathetic and sensory fibres, is dependent on Nerve Growth Factor for maturation and survival (Levi-Montalcini, 1976; Mobley et al, 1977). NGF is essential for neonatal development, but is also necessary for the maintenance of sympathetic and sensory neurones in the adult, thus it is a neurotrophic factor (Angeletti et al, 1971). In adrenergic neurones, NGF induces an increase in the synthetic enzymes tyrosine hydroxylase

and dopamine beta hydroxylase (Paravicini et al, 1975). It also promotes polymerization of actin and myosin ATPase activity and increases the density of microtubules and neurofilaments (Calissano et al, 1978). NGF is possibly contained in growth cones (Ochs, 1982), and thus may have a direct enhancing action on microtubules and neurofilaments. It has a neurotropic action, being released from target organs, taken up by growth cones and directing growth towards target cells (Levi-Montalcini, 1976).

### 3. Formation of the chronic neuroma

If regenerating axons fail to grow into the distal nerve stump, they will grow in various directions, some retrogradely, (Cajal, 1928) and a tangle of axons and connective tissue, a neuroma, will be formed (Young, 1942; Sunderland, 1953; Spencer, 1974). If the cut end of a nerve is ligated, this swelling is more severe (Battista and Cravioto, 1981). Neuroma formation has been extensively studied by both light microscopy, (Nageotte, 1932; Holmes and Young, 1942; Rexed, 1942; Denny-Brown, 1946) and electron microscopy (Spencer, 1971; Morris et al, 1972(d); Lassmann and Amerrer, 1974; and Jurecka et al, 1975).

Axonal regenerating units become separated by proliferating connective tissue elements, a process which begins about two weeks following nerve section (Thomas and Jones, 1967). Morris et al (1972d) called this process 'compartmentation'. This process is more pronounced towards the periphery of the nerve trunk and begins in the most distal 1.5mm, spreading proximally with time. Endoneurial fibroblasts are considered to be responsible for this process, although some early reports implicate Schwann cells as well, for example, Nageotte (1932). Morris et al (1972a) consider both endoneurial fibroblasts and Schwann cells to be responsible. These cells and their processes envelop regenerating axons, and these fascicles become multi laminate over a period of several weeks. The enveloping cells also develop basal laminae and form closed rings indicating a change from fibroblasts to perineurial type cells, this change occurs within 3 weeks of nerve section (Thomas and Jones, 1967). Pinocytotic vesicles and caveolae intracellulares are also present.

Morris et al (1972d) conclude that compartmentation occurs as a result of perineurial disruption, and represents the efforts of the neural elements to re-establish physical continuity of its barrier with

the environment external to the nerve. The effect of the external environment results in the process of compartmentation beginning at the periphery of the nerve where axons are most exposed. The presence of viable axons was thought to be a stimulus for the process of compartmentation (Morris et al, 1972d), although it is now known to occur in the absence of regenerating axons. Battista and Cravioto (1981) suggest that the regeneration of the perineurium is an attempt to reconstruct the proximal nerve, but results in fasciculation. If the perineurium is kept intact by fascicle ligation, less compartmentation occurs and the resulting neuroma is less swollen; and it is suggested that this type of surgery might be an effective method of preventing the formation of neuromas in the clinical situation (Battista and Cravioto, 1981).

The origins of axons become increasingly difficult to elucidate with the development of the chronic neuroma, in particular whether sprouts within a group have arisen from the parent fibre in that group, or whether they are sister sprouts from other nearby fibres which have penetrated into that Schwann cell subunit. The relationship between sprouts from different classes of fibre is particularly important in relation to the pain which may develop from chronic neuromas. Tight junctions or synapses have not been seen between closely related sprouts by electron microscopy, in contrast to early light microscope reports that they probably exist (Perroncito, 1907; Young, 1942). Candidates for the sites of ephaptic transmission have been proposed, most noticeably apposed unidentified unmyelinated sprouts lacking intervening Schwann cell cytoplasm (Bray et al, 1977; Bernstein and Pagnanelli, 1982; Devor and Bernstein, 1982). A fine structural site for the pathophysiological relationship which develops in chronic neuromas between sensory afferent and sympathetic efferents has not yet been demonstrated.

## D. Neurochemical Studies

### AXONAL TRANSPORT IN INJURED PERIPHERAL NERVES

Organelles such as mitochondria, clear and dense-cored vesicles and multivesicular bodies are seen to accumulate proximal to a constriction or section in axons of peripheral nerves (Grillo and Palay, 1962; Webster, 1962; Holtzman and Novikoff, 1965; Blumcke et al, 1966; Pellegrino de Iraldi and De Robertis, 1968; Zelena et al, 1968; Ballin and Thomas, 1969; Kapeller and Mayor, 1969). This accumulation is due to damming of axonal flow, first shown to exist by Weiss and Hiscoe (1948), and although suggestions have been made that some organelles such as mitochondria and multi vesicular bodies are synthesized in situ in the swollen terminal portion of the damaged axon, this was considered unlikely by Martinez and Friede (1970) for reasons given earlier. Since I am concerned in this thesis with changes in sympathetic nerves following injury, it is pertinent here to consider the axonal transport of noradrenaline with respect to the accumulations of dcv, the storage sites of noradrenaline, in sectioned axons.

#### Noradrenaline transport

Weiss and Hiscoe (1948) were the first to demonstrate axoplasmic flow in myelinated nerves. This flow has also been shown to occur in unmyelinated nerves, by the accumulation of noradrenergic fluorescence proximal to a ligation (Dahlstrom and Fuxe, 1964; Dahlstrom, 1965; Dahlstrom and Haggendal, 1966; Eranko and Harkonen, 1965; Kapeller and Mayor, 1965, 1967; Boyle and Gillespie, 1968; Geffen and Rush, 1968; Laduron and Belpaire, 1968). The amount of fluorescence seen and the noradrenaline content of ligated nerves were measured by Boyle and Gillespie, (1968), and corresponding rises and falls in these two components were found. All of these studies utilized the Falck and Hillarp method of fluorescence production (Falck et al, 1962) relying on the reaction of humidified formaldehyde vapour with noradrenaline to produce a fluorophore. The onset of this accumulation of fluorescent material proximal to a constriction of a peripheral nerve was almost immediate, first seen 5 to 10 minutes after ligation (Dahlstrom, 1970). This accumulation then increases in a linear fashion with time, up to about 48 hours (Dahlstrom and Haggendal, 1966). Boyle and Gillespie

(1968) found the maximum accumulation in a ligated post-ganglionic splenic nerve occurred 4 days after ligation. Following this period levels of noradrenergic fluorescence fell to normal 17-23 days following surgery (Karlstrom and Dahlstrom, 1973). The initial accumulation of noradrenaline proximal to a constriction is a result of the damming of axoplasmic flow rather than a local synthetic effect (Dahlstrom, 1967a). Only one enzyme related to noradrenaline synthesis, dopamine  $\beta$  hydroxylase, has been found accumulating following constriction (Laduron and Belpaire, 1968). This enzyme is localized to the storage vesicles (Kaufmann and Friedmann, 1965). Other enzymes such as tyrosine hydroxylase and dopamine decarboxylase do not accumulate within the first 24 hours (Laduron and Belpaire, 1968), therefore it is unlikely that noradrenaline is synthesized locally proximal to the ligature, since not all of the necessary synthetic enzymes are present.

Pellegrino de Iraldi and De Robertis (1968) suggested that storage granules may be formed locally by "pinching off" parts of local tubular structures. Massive amounts would need to be synthesized. The biggest drawback to this theory is that it is known that neurotubules grow very slowly and move down the axon at the rate of 1-2mm per day (Droz, 1967; Sjostrand and Karlsson, 1970). Monoamines are synthesized in the perikarya of adrenergic neurones and transported distally as storage granules along the axons to nerve terminals (von Euler, 1959; 1961) at a rate of at least 5mm/hour (Dahlstrom and Haggendal, 1966). A more recent study (Dahlstrom et al, 1975) has revised this figure to 9mm/hour or 216mm/day, following the finding that not all the noradrenaline in the nerve is free to move. Haggendal et al (1974) reported that only about half the noradrenaline is rapidly transportable. Ultrastructurally, a concomitant accumulation of dcv, which correspond to amine storage granules, is seen proximal to a ligation in sympathetic axons (Mayor and Kapeller, 1967; Kapeller and Mayor, 1967; 1969; Geffen and Ostberg, 1969). Both the fluorescent material and the dcv are depleted following reserpine treatment (Dahlstrom, 1965, 1967b; Kapeller and Mayor, 1967).

No substantial accumulations of fluorescent material or dcv are seen distal to a constriction (Kapeller and Mayor, 1967; Banks et al, 1969; Geffen and Ostberg, 1969), although a small amount of fluorescent material was reported by Dahlstrom, (1970), who concluded that this represented a leakage through the ligature. Therefore, transport of

noradrenaline appears to occur in a somatofugal direction. Noradrenaline in storage vesicles is transported by the fast axonal transport at a rate of 200-400mm per day, (Dahlstrom and Haggendal, 1966; Lasek, 1968; Geffen and Livett, 1971; Banks and Mayor, 1972; Ochs, 1972). Schmitt (1968) proposed that fast axonal transport operates via axonal microtubules and administration of antimetabolic drugs such as vinblastine or colchicine blocked the accumulation of noradrenaline proximal to a crush in rat sciatic nerve, supporting the suggestion that intact microtubules are required for axonal transport of noradrenaline (Dahlstrom, 1968, 1970, 1971; Banks et al, 1971; Hokfelt and Dahlstrom, 1971). Local injection of colchicine under the epineurium of the sciatic nerve produces a tremendous increase in intensity of fluorescence and enlargement of axons in that locality, producing a picture similar to that seen after blocking of axonal transport by nerve ligation (Dahlstrom, 1970). Further experiments by Banks and Till (1975) using podophyllotoxin, colchicine and griseofulvin, demonstrate that the effect of inhibition of axonal transport can be ascribed to depolymerization of microtubules. Podophyllotoxin, colchicine and griseofulvin bind to tubulin, albeit at differing sites, and cause the microtubules to break down. Lumino colchicines are potent mitotic inhibitors, but do not depolymerize microtubules by binding to tubulin, and therefore have no effect on vesicle transport (Wilson et al, 1974).

Noradrenaline usually ceases to accumulate in nerves 48 hours after ligation, although Boyle and Gillespie (1970) report accumulation up to 4 days, and a plateau phase is then seen 48-96 hours after injury, followed by a decrease in noradrenaline content of the nerve (Dahlstrom and Haggendal, 1970; Karlstrom and Dahlstrom, 1973; Ohshiro et al, 1978). The cessation of noradrenaline accumulation after 48 hours is due to the reaction of the cell bodies to injury, resulting in a decrease in synthesis and transport of amine granules, rather than to a change in monoamine oxidase levels (Boyle and Gillespie, 1970), which continue to increase peripherally for up to 7 days following ligation of the sciatic nerve to approximately twice normal levels (Dahlstrom et al, 1969). This accumulation of monoamine oxidase is ascribed to the accumulation of mitochondria. NA is membrane-bound in granules and therefore not available for metabolism (Dahlstrom and Haggendal, 1970). Boyle and Gillespie (1970) have shown that a monoamine oxidase inhibitor, nialamide, administered to cats with ligated splenic nerves four days prior to killing did not halt the decline in NA levels after



48 hours. The cell body reaction is therefore the major mechanism responsible for the cessation of noradrenaline accumulation after 48 hours. The cell bodies of damaged neurones show a net decrease in their neuronal content of certain proteins, including the MAO and the synthetic enzymes dopamine beta hydroxylase and tyrosine hydroxylase, due to increased proteolysis (Lieberman, 1971; Grafstein, 1975). Sympathetic ganglia show parallel changes, deficits in NA, tyrosine hydroxylase and MAO being maximal one week following ligation of the peripheral nerve (Cheah and Geffen, 1973). There is also a change in the pattern of protein synthesis, away from transmitter synthetic proteins in favour of structural components, which may contribute to the fall in NA levels (Griffith and Lavelle, 1971; Cheah and Geffen, 1973). Eranko and Harkonen (1965) observed decreased NA fluorescence in the perikarya of sympathetic rat neurones a few days after cutting the postganglionic nerve, and Karlstrom and Dahlstrom (1973) reported decreases in both the synthesis and transport of amine granules following axotomy.

The time taken for noradrenaline levels to return to normal in the damaged nerve is dependent on the type of injury sustained (Karlstrom and Dahlstrom, 1973). A crush is a minor type of injury, leaves the connective tissue of the nerve intact and NA levels return to normal 17-23 days following this operation (Karlstrom and Dahlstrom, 1973). Ligating or sectioning the nerves produces a more profound long lasting depletion. Ohshiro et al (1978) report that accumulation of NA above a crush 12 weeks after section and ligation of the rat sciatic nerve, was one quarter of that seen above a ligation in normal nerves.

#### IDENTIFICATION OF NORADRENALINE STORAGE SITES IN PERIPHERAL NERVES

There has been much discussion concerning the actual site of noradrenaline storage in nerve terminals. The characteristic granular vesicles found ultrastructurally in sympathetic nerve terminals were first identified by Hager and Tafuri, (1959); Grillo and Palay, (1962); Richardson, (1962) and De Robertis, (1964). Two types of granular vesicle have been identified, differentiated on the basis of size into "small" and "intermediate" by Pellegrino de Iraldi et al (1964). These two types are now known as small dcv, 30 - 60 nm in diameter, and large dcv, 60 - 100nm in diameter. Non-granular or clear vesicles are also seen.

Early pharmacological and ultrastructural autoradiography experiments demonstrated that the dense-cored vesicles probably represented the storage site of noradrenaline (Wolf et al, 1962; Bloom and Barrnett, 1966). This has now been confirmed (Hokfelt, 1966; Kapeller and Mayor, 1966; Tranzer et al, 1969). However, the number and size of the dcv seen ultrastructurally depends on the fixation parameters employed. Grillo and Palay, (1962) and Van Orden et al, (1966) used osmium tetroxide as the sole fixative. Tranzer and Thoenen, (1967); Tranzer et al, (1969) and Sotelo (1971) used both aldehydes and osmium. Chromate-dichromate solutions plus osmium were used by Wood and Barrnett, (1964); Tranzer and Snipes, (1968); Woods, (1969) and Tranzer and Richards (1976).

The majority of small dcv are known to contain noradrenaline, but the content of the large cored vesicles was questioned until more recently, principally because reserpine did not completely deplete the electron dense core (Jaim-Etcheverry and Ziehar, 1969; Tranzer et al, 1969). Till and Banks (1976) investigated the noradrenaline content of vesicles accumulating proximal to a constriction of the cat hypogastric nerve following a variety of drug treatments and fixation parameters. They concluded that the large granular vesicles were indeed noradrenaline storage sites, but that they contained material additional to catecholamines in the axonal matrix. Small dcv do not contain this matrix (Jaim-Etcheverry and Ziehar, 1969; Hokfelt, 1966; Till and Banks, 1976), and it has been suggested that small dcv are formed in the nerve terminals from large dcv (Lagercrantz, 1976; Lascar, 1980; Smith and Winkler, 1972; Till and Banks, 1976). Small dcv are uncommon in the cell bodies of adrenergic neurones, the majority at this site being large dcv. Lascar (1980) has identified a third possible noradrenaline storage site, large elongated vesicles, 60 - 100nm in diameter. These vesicles also have a reserpine resistant dense-core, and are probably a variety of the large dcv rather than a new storage site.

### E. Concluding statement

The content of this thesis comprises a morphological study of the sympathetic nervous system in injured peripheral nerves. There is substantial clinical evidence that the sympathetic nervous system plays a major role in the development and maintenance of chronic pain which may result from peripheral nerve injuries, by means of the development of a pathophysiological interaction between primary afferent and sympathetic efferent fibres. A better understanding of the nature of this interaction may lead to a more rational approach to the therapy of chronic pain which may result from peripheral nerve injury.

## Materials and Methods Introduction

The nerve injury used throughout the study was the experimental neuroma, produced in rat sciatic nerves by section and avulsion of the distal stump to prevent peripheral regeneration and reinnervation of the distal stump of the nerve. There is clinical evidence that neuromas resulting from traumatised peripheral nerves are painful, and so study of experimental neuromas may produce insights into the role of the sympathetic nervous system in chronically painful peripheral nerve lesions.

In this thesis, the capacity of noradrenergic axons to regenerate and the way in which the population of sympathetic axons varies with time following peripheral nerve injury <sup>were</sup> ~~was~~ investigated. This anatomical study of sympathetic axons used both fluorescence and electron microscopy techniques. A possible relationship between variations in the sympathetic axon population and the known variations of the afferent impulse barrage which arises following peripheral nerve injury was also considered.

The relationship between sympathetic efferent fibres and other fibres in neuromas, particularly with reference to a morphological substrate for the interaction which develops between sympathetic efferent and sensory afferent fibres was also investigated by fine structural methods. Ultrastructural localization of noradrenaline was facilitated by the use of a monoamine oxidase inhibitor, nialamide, followed by a false transmitter, 5-hydroxy dopamine, which reacts with osmium tetroxide to produce a highly electron dense product. Ultrastructural localization by reaction of noradrenaline with chromium followed by X-Ray probe microanalysis was also carried out.

Pharmacological manipulations of the sympathetic efferent axon population were carried out by treating the rats with systemic guanethidine. This drug is widely used clinically to treat many painful conditions including traumatic nerve injuries, and the mechanism of action is assumed to be related to the ability of guanethidine to deplete noradrenaline stores. The sciatic nerves and neuromas of rats treated with guanethidine were examined by light and electron microscopy, in order to assess the anatomical effects of guanethidine on the sympathetic fibre population.

In order to further investigate a possible morphological site for the abnormal interaction which develops between sympathetic efferent and sensory afferent fibres in neuromas, a similar manipulation of the sensory afferent axon population was carried out by neonatal dosing with capsaicin. This drug depletes the afferent sensory fibre population, producing a relatively 'pure' population of sympathetic efferent C fibres, without the contaminating effect of afferent C fibres. The results were examined ultrastructurally.

Finally, the possibility that alpha-adrenergic receptors develop on sensory afferent fibres in neuromas was considered. The direct and specific enhancing action of injected noradrenaline on ectopic impulse generation in sensory fibres and the blocking of this action by the alpha receptor blocker phentolamine implies the development of alpha receptors on the axolemmae of nerve sprouts. Tissue from the spinal cord, spinal roots, dorsal root ganglia and normal and neuromatous sciatic nerves was reacted for autoradiography following the application of radioactive ligands. The populations of opiate receptors in these tissues were also investigated, in order to obtain additional information about the behaviour of the afferent fibre population.

## Materials and Methods 1

### Neuroma Formation

All experiments were conducted on adult female Wistar rats, weighing between 170 and 200g at the time of the initial surgery. Animals were anaesthetized with a mixture of Hypnorm, Hypnovel and water for injection in the ratio 1:1:2, at a dose of 2 ml anaesthetic per kg body weight by intraperitoneal injection. Hypnorm consists of Fentanyl citrate,  $0.315 \text{ mgml}^{-1}$ ; and Hypnovel is midazolam hydrochloride,  $5 \text{ mgml}^{-1}$ . With sterile precautions, the left sciatic nerve was exposed in the popliteal fossa and lower thigh, and dissected free from surrounding tissues. The nerve was then sectioned with a pair of fine scissors at the trifurcation point of the tibial, peroneal and sural nerves. The distal 1 cm of these nerves was then avulsed to prevent regeneration from the proximal stump to the periphery, permitting neuroma formation. The skin was closed with silk sutures, and the wound sealed with Nobecutane plastic spray.

## Materials and Methods Introduction 2

### Fluorescence Microscopy - Chemical basis

The fluorescence histochemical technique for localization of monoamines is based on the original observations of Eros (1932), Eranko (1952) and Barter and Pearse (1953, 1955) on formalin-induced fluorescence in enterochromaffin and chromaffin cells in formalin-fixed tissue. The first use of this principle in the specific localization of adrenergic neurons by light microscopy was made by Falck et al (1962), who modified the original Eranko method (1955) by using formaldehyde vapour. The Falck and Hillarp method of localizing catecholamines in nervous tissue is only relatively recently being superceded by more sensitive and convenient techniques utilizing glyoxylic acid as the fluorophore (Axelsson et al, 1973; Lindvall and Bjorklund, 1974).

The catecholamines dopamine, noradrenaline and adrenaline all belong to the beta-phenylethylamine class of monoamines, biosynthesized from the aromatic amino acids tyrosine and phenylalanine. All three catecholamines are fluorogenic in the formaldehyde reaction, and the reaction products are visibly indistinguishable.

The principle underlying the specific histofluorescence methods employed is the conversion of non-fluorescent catecholamines to strongly fluorescent compounds. The conversion requires a ring closure of the ethylamine side chain, induced by reactive carbonyl compounds, such as reactive aldehydes, to form isoquinoline derivatives. This cyclization is known as the Pictet-Spengler condensation (Pictet and Spengler, 1911), and can be carried out with a variety of carbonyl compounds, especially in the presence of strong mineral acids in solution. In practice, the mild reaction conditions which prevail in tissue section mean that only two carbonyl compounds will specifically induce fluorescence with monoamines. A useful histochemical reagent must induce fluorescence such that general tissue constituents (i.e. the section 'background') remain essentially non-fluorescent. Only two aldehydes fulfil these criteria, formaldehyde and glyoxylic acid.

The mechanism of the fluorophore formation in the formaldehyde method was discovered by Corrodi and Jonsson (1967). The

fluorophore-forming reaction between biogenic amines and formaldehyde takes place in two steps. The first, the Pictet-Spengler condensation, forms the weakly fluorescent tetrahydroisoquinoline derivative of the monoamine. The second reaction proceeds either by auto-oxidation, or by an acid-catalyzed reaction with formaldehyde to yield the strongly fluorescent dihydroisoquinoline derivative, by dehydrogenation.

The glyoxylic acid formation of fluorophores with monoamines also takes place in two similar steps, with the formation of very similar intermediates. The initial Pictet-Spengler condensation proceeds very efficiently in solution, forming the tetrahydroisoquinoline, however the second dehydrogenation step runs very slowly in solution (Jonsson, 1967). Corrodi and Hillarp (1963, 1964) have shown that this step is facilitated in a dry protein matrix, which is the rationale behind the removal of water, often combined with or followed by heating, to produce the full development of fluorescence in the tissue section.

The original Falck-Hillarp method (1962) for the demonstration of tissue monoamines required fresh tissue to be frozen in liquid propane cooled by liquid nitrogen then transferred to liquid nitrogen for storage. This step was accomplished quickly to prevent dislocation or loss of monoamines during freezing. Frozen tissues were then freeze dried and transferred immediately to a dessicator containing  $P_2O_5$ , and kept light-tight. Tissue specimens were then placed in a closed glass vessel over paraformaldehyde powder and heated to  $80^{\circ}C$  for 1-2 hours, the paraformaldehyde powder having previously been humidified to 50-90% relative humidity by incubating with sulphuric acid-water mixtures for 5-7 days. Specimens were then vacuum embedded in previously degassed paraffin wax, ready for sectioning.

This original protocol has been much modified, most notably by perfusion of tissue with ice cold formaldehyde solution containing high concentrations of aluminium or magnesium salts. These ions are efficient fluorescence promoting agents in the FA reaction, at least partly due to the Lewis' acid properties of these metal ions, acting as catalysts. This fixative needs to be kept ice-cold to prevent movement of the monoamines from their original sites during fixation. Subsequent modification of this method by Furness and Costa (1978), allows the fixative to be administered at room temperature; this is due to the fact that their fixative contains formaldehyde and glutaraldehyde, which penetrates and fixes the tissue much more rapidly



than formaldehyde alone.

The SPG technique (de la Torre and Surgeon, 1976)

One of the most useful adaptations of the original observations on aldehyde induced fluorescence is employed in the glyoxylic acid method of de la Torre and Surgeon (1976). Fresh tissue is frozen, sectioned in a cryostat, and the fluorophore reaction takes place by immersion of the sections on slides in a glyoxylic acid-sucrose-phosphate solution. This is followed by air drying under a cool air stream, then heating to 80°C for 5 minutes to fully develop the fluorogenic product.

The SPG method has a number of distinct advantages for the demonstration of tissue monoamines:

i) It is a highly sensitive technique. Preterminal and axonal varicosities of varying sizes down to 'ultrafine' can be visualized using this technique (de la Torre and Surgeon, 1976). 'Ultrafine' varicosities were seen in the rat cerebellum, hippocampus, thalamus and most cortical regions.

ii) The technique produces less morphological alteration of tissue, since tissue is not required to be dried before sectioning.

iii) The fluorescence produced is more easily reproducible than that of the Falck-Hillarp technique, since the reaction product is not consequent upon factors such as relative humidity during the critical drying step of the reaction.

iv) The fluorescence product is stable under ultra-violet light, allowing more extensive analysis of the anatomical detail of the tissue section. The Falck-Hillarp reaction product is only stable for about 5 minutes in the microscope beam. The monoamine fluorescence is also stable on prolonged storage (for at least 6 weeks), if slides are kept in a closed container in a fridge.

This method is therefore extremely useful, providing a few caveats are observed - i) the pH of the reactant solution is critical. A pH of 7.4 is required. A change in this pH of more than one unit can cause microscopic diffusion of fluorescence in very fine terminal endings (de la Torre and Surgeon, 1976).

ii) Prolonged exposure to the glyoxylic acid solution or a decrease in the strength of the solution will cause a weakening of the fluorescence.

iii) Oven heating for less than 5 minutes results in weaker fluorescence, but overheating will result in artefactual 'pooling' of fluorescence.

### Specificity tests

To prevent misinterpretation of results, the specificity of any monoamine fluorescence must be confirmed. There are certain biological molecules which fluoresce naturally, a phenomenon termed autofluorescence, when exposed to light in the blue/ultraviolet wavelength band. The most notable of these is elastin, which displays a greenish autofluorescence, and lipofuscin pigment (e.g. in macrophages) which has a yellow/orange autofluorescence similar to that of serotonin. Several specificity tests can be applied:-

i) Omission of the fluorogenic agent, formaldehyde or glyoxylic acid, from the processing will result in no fluorescence production.

ii) Catecholamine fluorescence which results from reaction with formaldehyde will fade quickly on exposure to ultraviolet light, whereas autofluorescent structures are resistant to photodecomposition.

iii) Catecholamine fluorescence is quenched when sections are mounted in water, but autofluorescence is unaffected by the presence of water.

iv) Sodium borohydride ( $\text{Na BH}_4$ ) in alcoholic solution is a powerful reducing agent, the fluorescent dihydroquinoline molecule being reduced to the tetrahydroderivative which is non-fluorescent (Corrodi et al, 1964). Fluorescence can be subsequently produced on addition of more FA or GA.

In addition to these histochemical tests, pharmacological manipulations can also be applied before processing of tissue. The administration of catecholamine depleting agents, such as reserpine, will result in the non-appearance of fluorescence in subsequently processed sections, confirming that the fluorescent structures did specifically contain catecholamines.

## Materials and Methods 2 FLUORESCENCE STUDIES

### A. Formaldehyde and Glutaraldehyde Fixation (FAGLU)

The left sciatic nerve was sectioned in 15 adult Wistar rats as previously described. Neuromas were allowed to develop for 3 days. At the end of this time, animals were reanaesthetized with Sagatal (sodium pentobarbitone,  $60\text{mgkg}^{-1}$ ). In 5 animals the left and right sciatic nerves were exposed as before, and the cavity in the popliteal fossa filled with FAGLU fixative; 4% formaldehyde and 1% glutaraldehyde in 0.1M phosphate buffer, at  $4^{\circ}\text{C}$ . The nerves were then removed and immerse fixed for a further 1 hour. The adrenal medullae and small pieces of mesentery were also removed and immerse fixed. Longitudinal sections, 30um thick, of the nerves and adrenal medullae from two animals were sectioned on a vibratome. The tissues from the other 3 animals were mounted on cork chucks embedded in gum tragacanth, and frozen by plunging into isopentane cooled by liquid nitrogen. Sections 12um thick were then cut on a cryostat and mounted in FAGLU on glass slides. The pieces of mesentery were mounted as stretch preparations in FAGLU.

The other 10 animals were killed by cardiac perfusion with FAGLU at  $4^{\circ}\text{C}$ . The pressure of the perfusate was 120mm Hg, and the flow rate  $30\text{mlmin}^{-1}$ . Each animal received 300 mls of fixative. The tissues were then removed and placed in FAGLU at room temperature, ready for sectioning or freezing, as before. Slides were examined in a Nikon Labophot fluorescence microscope equipped with epi-fluorescence, with B-2A excitation (450 - 490 nm) and Blue (520 nm) barrier filters.

## B. Glyoxylic acid induced fluorescence

The left sciatic nerves of 44 adult Wistar rats were sectioned as previously described, at least 4 per time course. At 3 days, 1,2,3,4,6,8 weeks and 6 months following nerve section, animals were reanaesthetized with Sagatal (sodium pentobarbitone 60 mgml<sup>-1</sup>) at a dose of 1.5 mlkg<sup>-1</sup>. The left sciatic nerve was exposed as before, and the neuroma which had formed on the proximal stump was excised together with 1 cm of the proximal nerve. In each animal the normal right sciatic nerve was removed at the same level as a control. Both nerves were then embedded in fresh liver for mechanical support, orientated longitudinally, and mounted onto separate cork chucks using gum tragacanth. Tissue was frozen rapidly by plunging into isopentane cooled by liquid nitrogen, with agitation, for 10 seconds. The whole process of removing and freezing tissue took less than 30 minutes. After the removal of the two sciatic nerves, animals were killed with an overdose of anaesthetic.

Eight further control nerves were removed from four normal unoperated rats, and treated in a similar fashion.

10um frozen sections of the nerve were cut in a cryostat set at -20°C and every fourth section was thaw-mounted onto a cleaned glass slide. Sections were then treated with glyoxylic acid, according to the histochemical fluorescence method of de la Torre and Surgeon (1976), for the demonstration of tissue monoamines:

1. Sections were collected singly onto glass slides,
2. Air dried for a few seconds, then
3. Dipped into a freshly made solution of 1% glyoxylic acid in 0.2M sucrose and 0.236M potassium phosphate buffer at pH 7.4 (SPG solution) for 3 seconds.
4. The excess fluid was then wiped from around the sections and the slides placed in a cool airstream for 10-15 minutes to dry completely.
5. The fluorescence reaction was developed by heating the slides in an oven at 80°C for 5 minutes.
6. Sections were coverslipped using liquid paraffin, and heated on a hotplate for 90 seconds to eliminate any air bubbles trapped under the coverslip.

00

Slides were then examined in a Nikon Labophot fluorescence microscope equipped with an epifluorescence system, BV-2A excitation (400 - 440nm) and Blue-Violet (470nm) barrier filters.

M15 and b calculations. p. 68

The mean slopes, b, of the plots of number of fluorescent axons vs. distance and the mean midpoints of these slopes, M15 measures, were used as summary statistics for the statistical analyses (see Appendix 3 for details of their derivations).

were counted from each nerve, encompassing virtually the whole nerve. Details of statistical analysis and raw data are given in Appendix 3.

## Materials and Methods 2

### C. Immunofluorescence

One of the other fluorescence techniques tried initially was immunofluorescence, using <sup>anti</sup> dopamine beta hydroxylase as the primary antibody and fluorescein isothiocyanate (FITC) as the fluorescent marker complex (Potter, 1967).

The left sciatic nerves from two adult female Wistar rats, weight 170-200g, were sectioned as previously described, and neuromas allowed to develop on the proximal stumps over a period of 3 days. Animals were then reanaesthetized with Sagatal by i/p injection, and perfused through the heart with a fixative solution of 4% paraformaldehyde in phosphate buffered saline (P.B.S.) at 4°C. The fixative was administered at a pressure of 120mm Hg and allowed to run for 10 minutes, allowing a delivery of 300ml of solution (30 ml/minute flow rate). Following perfusion fixation, the left and right sciatic nerves were excised, and further fixed by immersion in fixative solution at 4°C for 2 hours.

Tissues were then washed by 6 x 30 minute changes of P.B.S. with 7% sucrose and 1% sodium azide as a preservative. Tissues were then left in this solution at 4°C overnight. Following impregnation with this cryoprotectant solution, tissues were mounted onto cork blocks and frozen in isopentane as previously described. 10um frozen sections were then cut in a cryostat, and mounted on poly-L-lysine coated slides.

Slides were then examined in a Nikon Labophot fluorescence microscope equipped with an epifluorescence system, BV-2A excitation (400 - 440nm) and Blue-Violet (470nm) barrier filters.

The numbers of blue-green fluorescing noradrenergic axons in each section were counted at 5 different sites along the length of nerve, these being 0.5, 1.0, 1.5, 2.0 and 2.5 mm proximal to the point of nerve section. Distances on the slides were measured using the Vernier scale on the microscope stage, and only axons which crossed the eyepiece graticule cursor were scored positively (Fig. 1). 20 sections were counted from each nerve, encompassing virtually the whole nerve. Details of statistical analysis and raw data are given in Appendix 3.

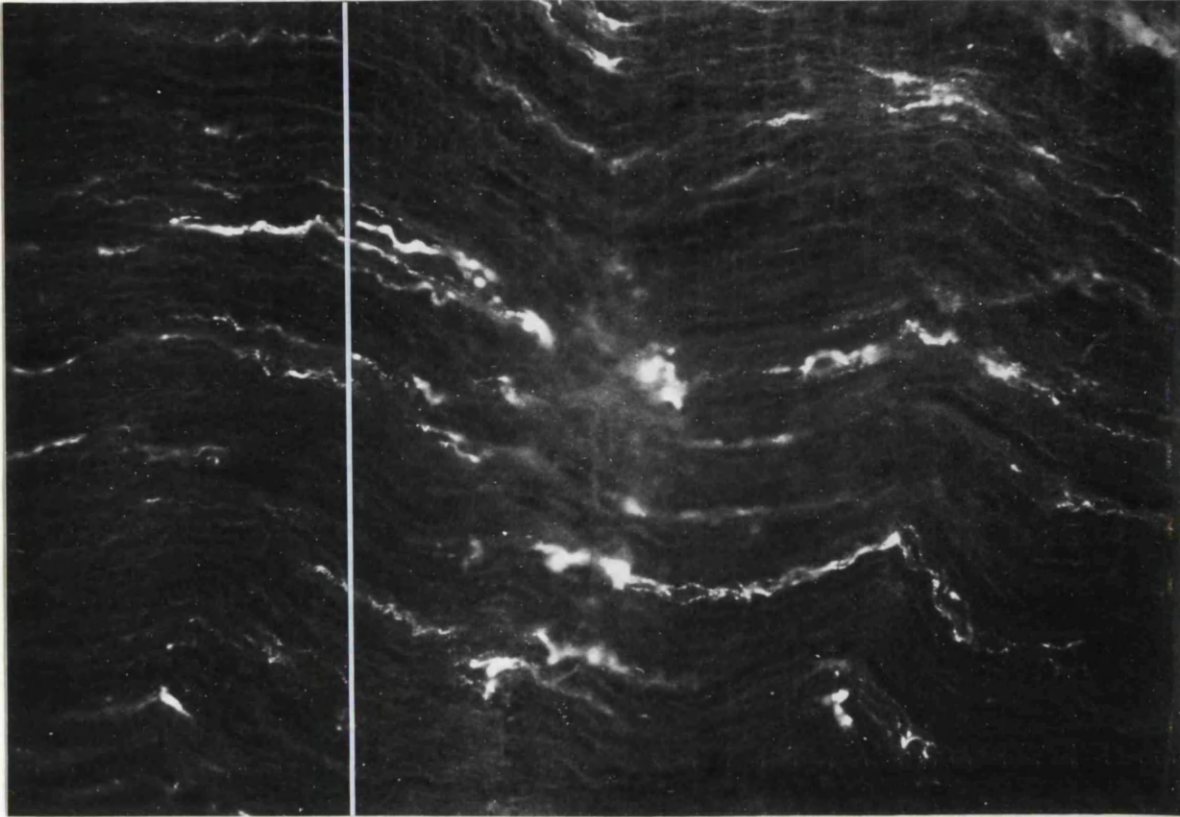
## Materials and Methods 2

### C. Immunofluorescence

One of the other fluorescence techniques tried initially was immunofluorescence, using <sup>anti</sup> dopamine beta hydroxylase as the primary antibody and fluorescein isothiocyanate (FITC) as the fluorescent marker complex (Potter, 1967).

The left sciatic nerves from two adult female Wistar rats, weight 170-200g, were sectioned as previously described, and neuromas allowed to develop on the proximal stumps over a period of 3 days. Animals were then reanaesthetized with Sagatal by i/p injection, and perfused through the heart with a fixative solution of 4% paraformaldehyde in phosphate buffered saline (P.B.S.) at 4°C. The fixative was administered at a pressure of 120mm Hg and allowed to run for 10 minutes, allowing a delivery of 300ml of solution (30 ml/minute flow rate). Following perfusion fixation, the left and right sciatic nerves were excised, and further fixed by immersion in fixative solution at 4°C for 2 hours.

Tissues were then washed by 6 x 30 minute changes of P.B.S. with 7% sucrose and 1% sodium azide as a preservative. Tissues were then left in this solution at 4°C overnight. Following impregnation with this cryoprotectant solution, tissues were mounted onto cork blocks and frozen in isopentane as previously described. 10um frozen sections were then cut in a cryostat, and mounted on poly-L-lysine coated slides.



**FIGURE 1.** Longitudinal section of normal sciatic nerve processed for glyoxylic acid fluorescence according to the SPG method of De La Torre and Surgeon (1976), showing the normal distribution of sympathetic axons in a mixed peripheral nerve. The method used for counting fluorescent axons is illustrated by the positioning of the cursor. Each fluorescent axon which crossed the cursor was scored positively. Thus the count at this point was = 7 sympathetic axons.

x 100

These were left to air dry at room temperature for at least 1 hour, to ensure section-slide adherence.

Slides were then rinsed in a 0.1% solution of Triton X in P.B.S. by 3 x 10 minute changes of solution, the detergent facilitating antibody penetration into the sections. Slides were then dried around the sections to remove excess fluid, and therefore dilution of the antibody solution, and placed on a horizontal surface in a humidified incubation chamber. The first layer of the immunofluorescent stain, a 1:800 dilution of rabbit anti-dopamine beta hydroxylase (anti DBH - Eugene Tech. Inc., New Jersey, U.S.A.) in antibody diluting fluid was applied to the sections, which were then left overnight in the sealed chamber at room temperature. Control sections were treated in an identical manner, but incubated with antibody diluting fluid only, the primary antibody being omitted.

Following this incubation, slides were rinsed by 3 x 10 minute changes of P.B.S. solution, to remove excess primary antibody solution, the presence of which would give background non-specific staining. The second layer, a 1:100 dilution of goat anti-rabbit FITC (Nordic Immunology Labs., Maidenhead, Berkshire), was then freshly made up by diluting the stock FITC solution (2ml lyophilized powder dissolved in 2mls P.B.S.) with P.B.S. This was then applied to the sections on the slide and slides were incubated in this solution for 1 hour at room temperature. Excess non-bound FITC fluorescent stain was then washed off by 3 x 10 minute rinses of P.B.S. Sections were then mounted in Citifluor, a glycerol/P.B.S. solution which prevents fading of the fluorescence and examined in the fluorescence microscope as before, but with B-2A excitation (450 - 490 nm) and Blue (520nm) barrier filters.



### Reserpine Treatment

Reserpine treatment depletes catecholamines from storage vesicles by being preferentially taken up, displacing the endogenous noradrenaline, and impairing reuptake mechanisms (Bowman and Rand, 1982). Depletion of fluorescence following reserpine treatment is another specificity test for the fluorescence product (Corrodi and Jonsson, 1967).

Following left sciatic nerve section, two rats were treated with reserpine (Sigma Chemical Co., Poole, Dorset),  $10\text{mgkg}^{-1}$  dissolved in 0.1M acetic acid, given intraperitoneally 24 hours before biopsy. The right and left sciatic nerves were removed 3 days after nerve section, and processed for glyoxylic acid fluorescence microscopy as previously described.

## Results 2 FLUORESCENCE STUDIES

### A. FAGLU STUDIES

This technique was unsuccessful as a method of localising sympathetic axons in mixed peripheral nerve, probably due to the low concentrations of noradrenaline in such nerves. Virtually no fluorescent fibres were seen either in the normal sciatic nerves or in the acute neuromas. A few yellow autofluorescent mast cells were seen, and bright green autofluorescent elastin was visible in the endothelium of blood vessels. The background fluorescence was bright, due to the glutaraldehyde component of the fixative. Some fluorescent axons were seen in the mesentery stretch preparations and catecholamine fluorescence could be seen in the sections of adrenal medullae.

### B. GLYOXYLIC ACID (SPG) STUDIES

#### NORMAL SCIATIC NERVES

Cryostat sections of normal sciatic nerves had a wavy appearance in longitudinal sections due to the contraction of the fibres induced during the freezing process. Sympathetic axons were the only class of fibres which were fluorescent following glyoxylic acid treatment, the reaction between noradrenaline and glyoxylic acid producing a bright green-blue fluorescence when viewed by violet light of wavelength 436nm. The outline of other structures in the nerve such as myelinated fibres were visible in the background of the section, but did not fluoresce. The nodes of Ranvier in these fibres could be clearly seen. Blood vessels could be distinguished by the lumen, and also sometimes by the presence of yellow/orange autofluorescent erythrocytes. The fluorescent adrenergic axons innervating these vessels were also visible, being much brighter and coarser than sympathetic axons within the nerve proper. Additionally, axons innervating blood vessels did not run parallel with the axis of the nerve, but were more randomly orientated. The elastin fibres surrounding the endoneurium of blood vessels appeared as pale green autofluorescent structures, forming a fine network around the vessel. Highly distinctive mast cells containing brightly autofluorescent large yellow granules were seen both in the perineurium and in the endoneurium. The central nuclear area was dark and non-fluorescent, surrounded by a ring of large fluorescent granules.

Fluorescent axons were present throughout the normal nerves, evenly distributed across the width (Fig. 2) and along the length of each nerve. Each axon appeared bright and uniform in diameter along its length, although individual axons varied in calibre (Fig. 3). The contraction of the nerve on freezing resulted in fairly short lengths of fluorescent sympathetic axons being visible in each section (Fig. 3). Each axon consisted of a chain of small varicosities (Fig. 1). At higher magnifications ( $\times 100$ ), these varicosities could be resolved as distinct entities, but at lower magnifications the sympathetic axon appeared to be continuously fluorescent, punctuated by bright spots. Axons were irregularly distributed across the nerve, and often appeared to be intertwined, 4 or 5 running together as a group (Fig. 1).

Counts of fluorescent axons in control sciatic nerves from unoperated animals showed no significant variation along the length of the nerve examined, the mean values of these counts in a distal to proximal direction being 190, 202, 194, 199 and 186 (Table 1). Counts of fluorescent sympathetic axons in the contralateral normal right sciatic nerves from animals with neuromas were similar, although there was a larger variation in counts between animals. The mean values of counts of fluorescent axons in a distal to proximal direction in these contralateral nerves were 182, 211, 210, 200 and 192 (Table 1). Following the logarithmic transformation of data (see Appendix 3) and the plotting of  $\log(\text{no. of axons})$  vs. distance for the normal uncut nerves (contralateral to neuromas) and normal nerves (from unoperated animals), it was seen that the slopes of all these plots were approximately zero, i.e. there was no significant variation in the numbers of fluorescent axons along the nerves (Table 2). Any small variations seen were probably the result of branching of the unmyelinated axons (Aguayo et al, 1976) or uneven contraction of the tissue on freezing. The M15 values were not significantly different between these two groups of animals; for uncut nerves, 5.2496, and normal nerves, 5.2445 (Table 2).

Within the groups of normal nerves contralateral to neuromas at various times following nerve section, there was no difference between groups, the F ratio being 1.10 for the slopes and 1.04 for the M15 values (Appendix 3). This means that sectioning the left sciatic nerve had no effect on the sympathetic axon population of the intact right nerve. The F ratio for the slopes of the pairs of normal nerves from unoperated animals was 1.75, but the ratio for the M15 values was

**FIGURE 2.** Transverse section of normal sciatic nerve, showing the normal distribution of sympathetic axons. Sympathetic axons innervating the blood vessels within the perineurium can also be seen. Glyoxylic acid.

x 40

**FIGURE 3.** Section of normal sciatic nerve, showing the longitudinal arrangement of varicose sympathetic axons. Non fluorescent, slightly fragmented liver tissue, which was used for mechanical support during the sectioning process can be seen to either side of the nerve. Glyoxylic acid.

x 40



40.52, which showed that the pairs of nerves were correlated. These normal nerves were not included in the pooled slope or pooled M15 calculation, which was restricted to nerves contralateral to neuromas.

Total numbers of fluorescent axons in 20 sections at a particular locus in non-operated control animals ranged from 132 to 268 and in normal right sciatic nerves contralateral to neuromas, the range was 120 to 348 (Appendix 3, Table 1). Thus there was no significant difference between the completely normal nerves and those 'normal' nerves contralateral to neuromas.

## NEUROMAS

### 1. 3 Days post section

When examined macroscopically at 3 days after nerve section, the proximal stump appeared to be slightly swollen, with prominent blood vessels visible on the surface of the neuroma. Viewed microscopically, very large accumulations of granular fluorescent material were seen at the distal tip of the neuroma, making identification of individual axons in the 0.5mm zone proximal to the neuroma tip difficult and axon counts impossible (Figs. 4 and 5). However, estimates based on counts from 1 week neuromas suggest that the number of fluorescent axons may rise to approximately 5 times normal at the distal tip (Table 1 and Fig.6). Further proximally along the nerve, individual axons were very much thicker than normal and very much more numerous. Counts taken 1.0mm from the tip of the proximal stump showed that fluorescent axon numbers were increased to over 3 times the normal value (Table 1). The accumulation of fluorescence persisted throughout the length of nerve examined, so that at a distance of 2.5mm from the tip, counts were still some 2.5 x normal (Table 1). The numbers of sympathetic axons in the sectioned nerve decreased rapidly in a distal to proximal direction, reflecting the accumulation of noradrenaline at the distal tip of the neuroma (Table 1, Fig. 6). The mean slope,  $b$ , of the plot of the transformed data was negative, which reflected the fact that there were more fluorescent axons at the distal tip of the neuroma than further proximally (Table 2). The mean slope and M15 value, which was related to the number of sympathetic axons in the neuromas, were both significantly different from normal at 3 days after section (at  $p < 0.01$  level, Table 2).

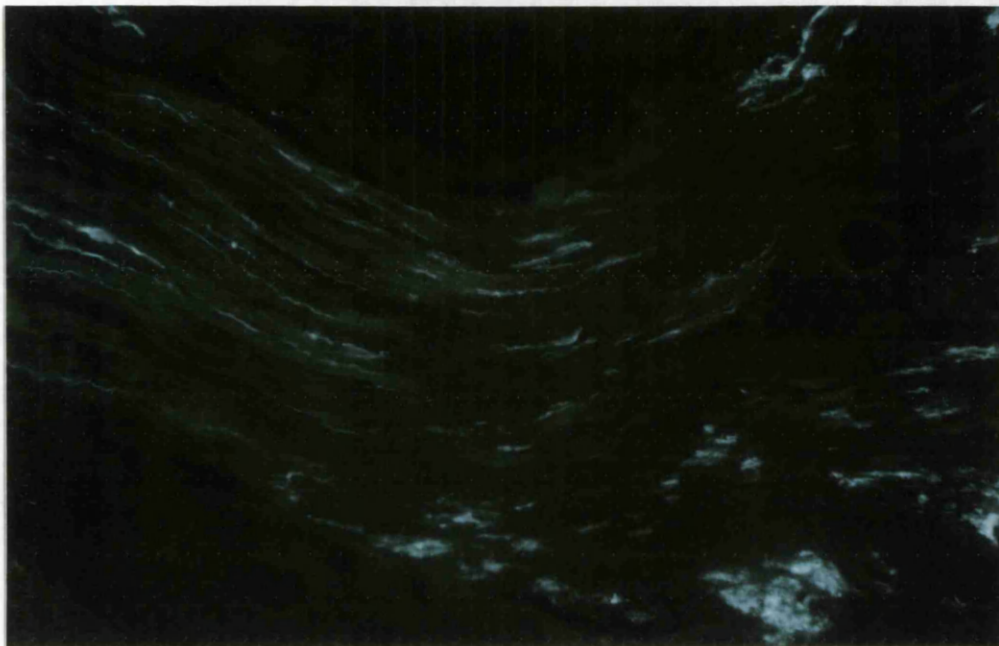
Sprouting of sympathetic axons was already present 3 days after

**FIGURE 4.** Neuroma three days after nerve section, the distal tip to the right of this micrograph. An accumulation of NA fluorescence in swollen axons can be seen throughout the nerve, especially towards the distal tip. Glyoxylic acid.

x 40

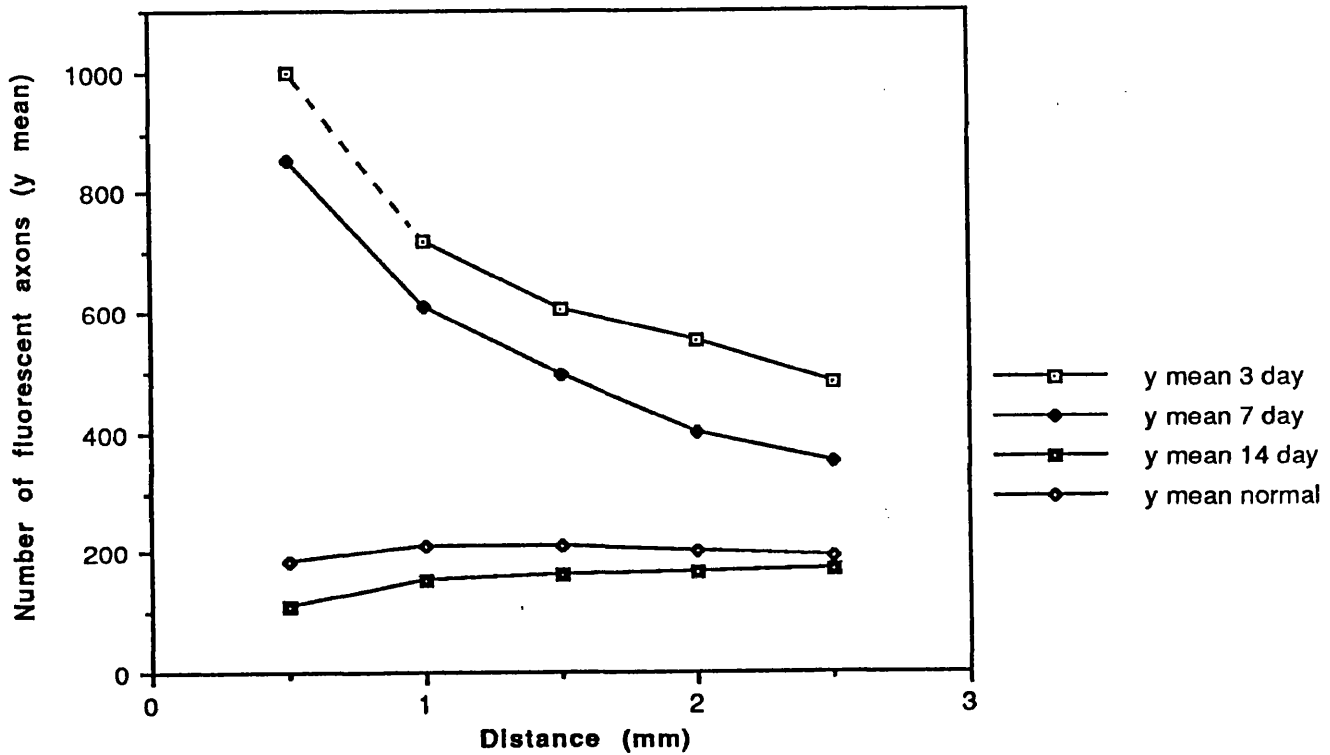
**FIGURE 5.** Neuroma 3 days following section, 0.5mm from the distal tip. The fluorescent material in many sympathetic axons has 'pooled' so that individual axons cannot be resolved. A few sympathetic sprouts are visible. Glyoxylic acid.

x 80





**Neuromas 3,7 and 14 days plus normal  
Number of axons vs. Distance**



**FIGURE 6** Number of fluorescent axons vs. distance in neuromas 3,7 and 14 days following nerve section, compared with the number of fluorescent axons in normal nerves. The 0.5mm distance point for the 3 day neuromas is an extrapolation, based on the curves for the 3 and 7 day neuromas.

nerve section. Numerous very fine fluorescent axons could be seen around the distal tip of the neuroma, especially towards the perimeter of the nerve. Many of these sprouts were orientated at right angles to the main body of the nerve, and were growing parallel to each other in groups (Fig. 7). These areas of perpendicular sprouts largely failed to be included in the counts of sympathetic axons since they were running parallel to the plane of the cursor across which axons were being counted, rather than perpendicular to it, as in the case of all the other axons counted.

Some degeneration of myelin could be observed in the non-fluorescent profiles in the background of the section, and many yellow autofluorescent erythrocytes were seen around the distal tip of the neuroma. Mast cells with yellow autofluorescent granules were seen in the perineurium. Some of the less granular yellow / orange autofluorescent cells seen in and around the neuromas may have been macrophages, since the lipofuchsin pigment in these cells is also autofluorescent under violet light.

## 2. 7 Days post section

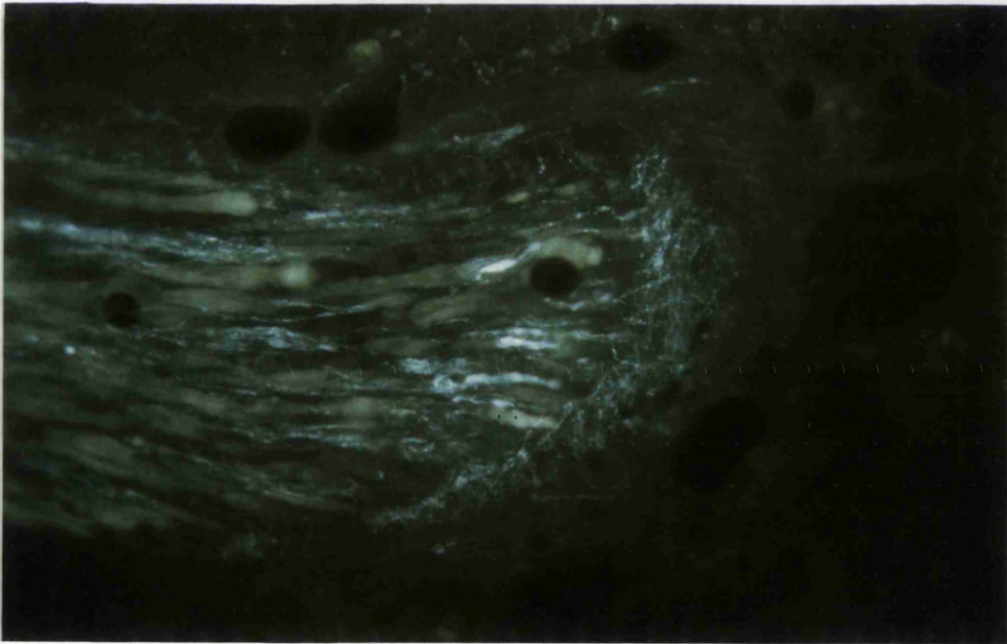
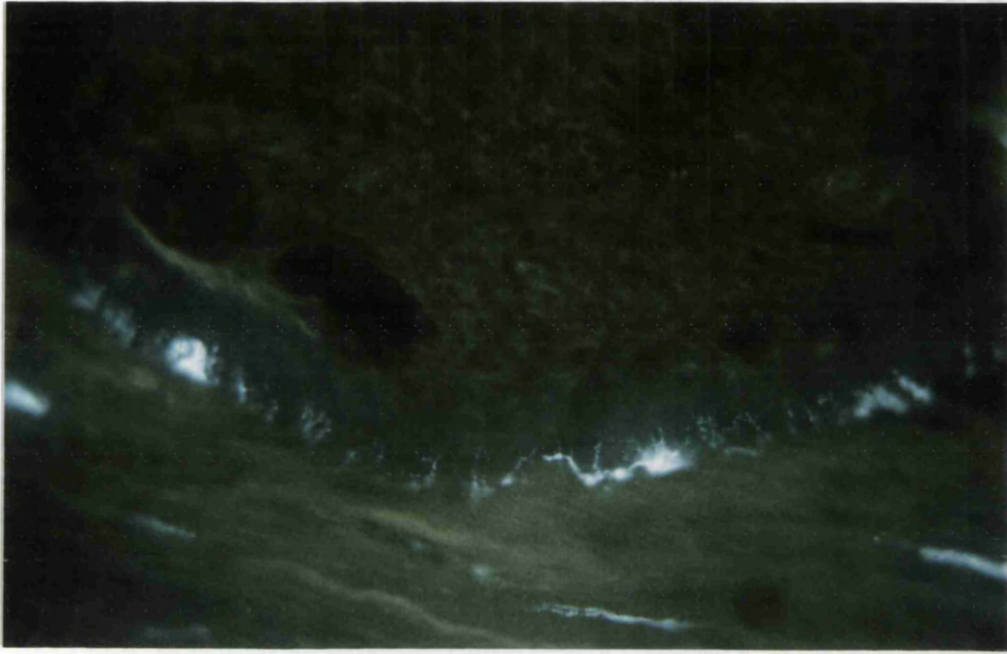
At one week after nerve section the numbers of fluorescent axons were still greatly increased, by 4.5 times at 0.5mm from the distal tip (Table 1), the mean slope was therefore negative (Table 2). There were still large numbers of swollen fibres at the distal tip and an accumulation of NA was still in evidence, such that the number of fluorescent axons at the distal tip was more than twice that counted 2.5mm proximally (Table 1). Most of the 'pooling' of noradrenaline fluorescence seemed to have subsided, and resolution of individual axons for counting purposes was therefore more reliable. Sympathetic axon numbers were still increased well above normal throughout the nerve. Both the mean slope and M15 values were significantly different from normal ( $p < 0.001$ , Table 2). A large network of very fine intermingling fluorescent sprouts were seen all around the distal tip, many sprouts again being observed running at right angles to the main body of the nerve (Figs. 8 and 9). A few axons were seen to have large ovoid swellings of uniformly dense fluorescent material, with varicose axons of normal thickness connected to each side. These large fluorescent bodies (approx. 25um in diameter) were never seen at the distal tip of the neuroma, but most usually about 1-1.5mm proximal to the point of section. Only one ovoid profile per section was ever seen,

**FIGURE 7.** Neuroma 3 days after section, 1.0mm from the distal tip. A large number of sympathetic sprouts growing at right angles to the main body of the nerve are visible. Glyoxylic acid.

x 80

**FIGURE 8.** Distal tip of a neuroma 7 days after section. A network of fine intermingling fluorescent sprouts has grown out from the cut end of the nerve (right). Large numbers of fluorescent axons, many of which are swollen, are still visible, but the large pools of fluorescent material have disappeared, and resolution of individual axons is now possible. Glyoxylic acid.

x 80


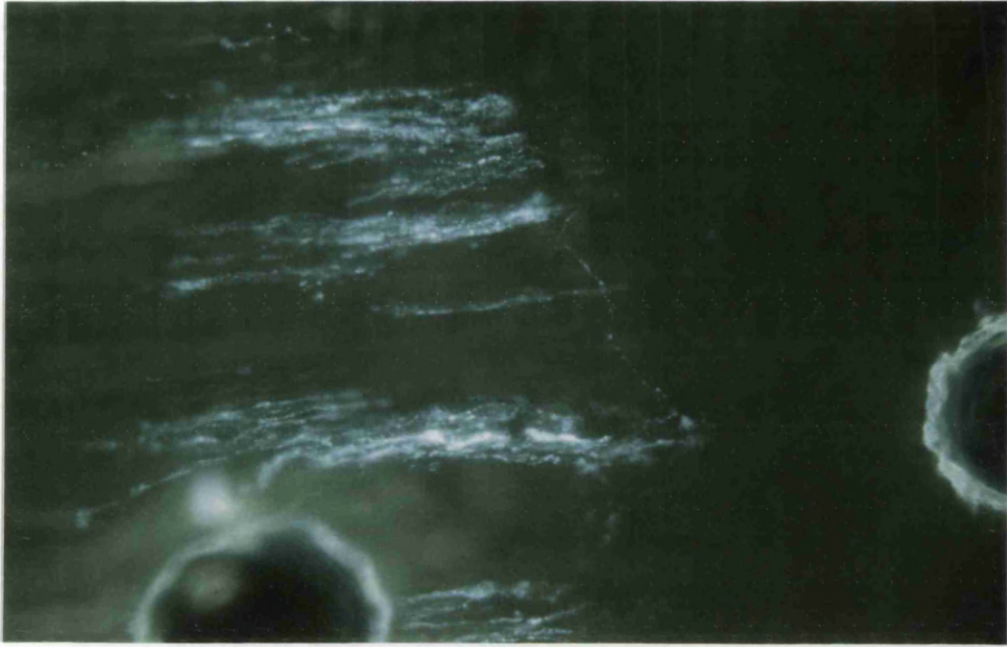


**FIGURE 9.** Distal tip of a neuroma 7 days after section, containing many fluorescent axons running in groups, and one thin sympathetic sprout running across the distal tip of the nerve (right). Glyoxylic acid.

x 160

**FIGURE 10.** Neuroma 7 days after nerve section, 1.5mm from the distal tip. An unusual ovoid of fluorescent material can be seen as a swelling in this axon. Glyoxylic acid.

x 80



and they were only present in a very few sections (Fig. 10). These fluorescent bodies may possibly have corresponded with the 'supergiant' axons which contain dcv, occasionally seen in the electron microscope, and are probably therefore sympathetic.

### 3. 2 Week neuromas

Neuromatous tissue was now visible distal to the original point of section of the nerve. The point of section was easily distinguished since the orientation of axonal sprouts distal to this point was more random, and many non-fluorescent rings of myelin which were very thin, representing transversely-sectioned fibres, could be seen in the background of the section (Fig. 11). 'Blobs' of degenerate myelin could be seen at the point of section extending proximally for about 1mm, and further proximally, swollen fibres could be seen. Many yellow brightly autofluorescent mast cells were seen in the perineurium around the point of section, and a few were also seen within the nerve itself.

There were very few fluorescent sympathetic axons in the sectioned nerve at the distal tip, the numbers having decreased to 60% of normal 0.5mm proximally from the point of section (Table 1, Fig. 6). The mean slope for these neuromas was positive, due to this decrease in numbers of fluorescent axons at the distal tip and was significantly different from normal at the  $p < 0.01$  level (Table 2). The M15 value was also significantly different from normal, but at  $p < 0.001$  (Table 2). No large collections of fluorescence were seen, and axons at the tip of the original nerve were thinner than normal. A few very fine fluorescent axonal sprouts were visible in the new neuromatous tissue which was growing distal to the point of section, and growing down the sides of the original nerve. The terminal varicosities in these sympathetic axons were very pronounced. Sprouts running perpendicular to the long axis of the nerve were again visible around the original nerve at the point of section, although not all of these sprouts were fluorescent, myelinated fibres being visible in the background.

Fluorescent axons were more numerous further proximally, and of greater calibre. At 2.5mm proximal to the point of section, total fluorescent counts were still reduced, to 90% of normal numbers (Table 1, Fig. 6).

In one animal, there were many more fluorescent axons at the

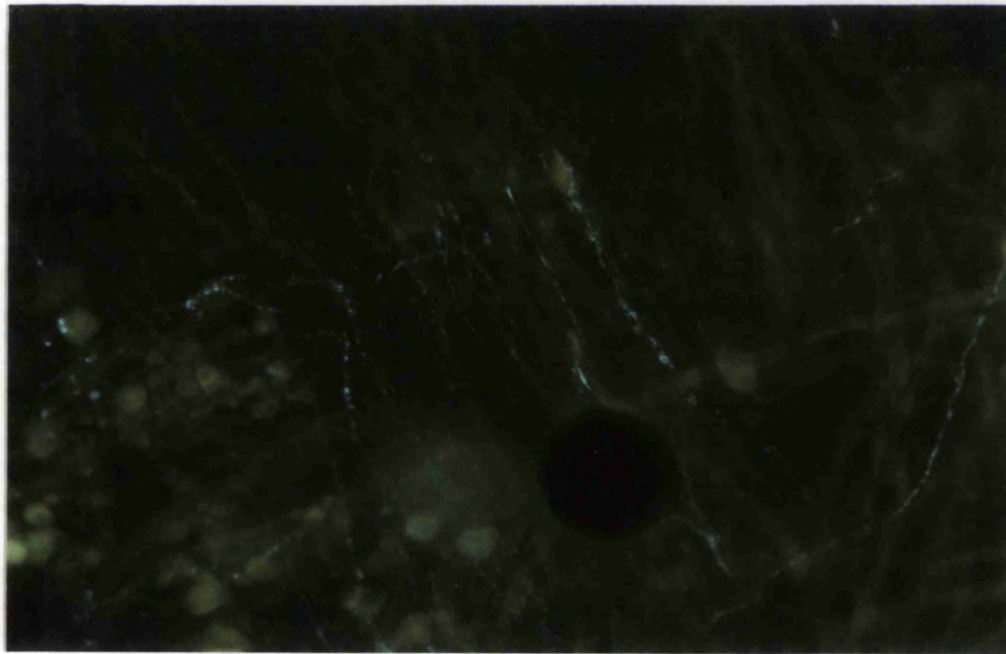
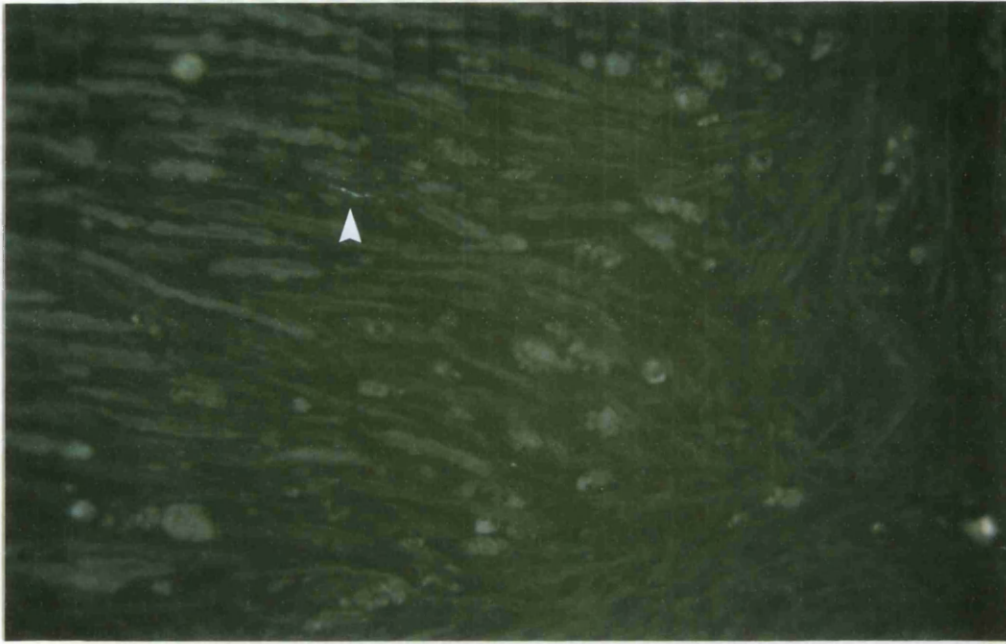
**FIGURE 11.** Distal tip of a neuroma 14 days after nerve section. Very few fluorescent axons are usually seen 2 weeks after nerve section. Only one sympathetic axon can be seen at the distal tip of this neuroma (arrow). Glyoxylic acid.

x 80

**FIGURE 12.** Neuroma 14 days after nerve section, 1mm from the distal tip. An unusually large number of thin fluorescent sprouts running mainly along the longitudinal axis of the nerve are visible, but intermingled with these sprouts are others of differing orientations. Glyoxylic acid.

x 160





distal tip than in the other animals. Several groups of very fine sympathetic sprouts were seen proximal to the point of section (Fig. 12). Others were seen to contain large fluorescent axonal swellings, similar to the ovoids of fluorescence seen one week after nerve section. These swellings were varied in both size and shape, two being rather ellipsoid and the others more triangular in shape (Fig. 13). These large varicosities were highly unusual, being seen in only one section of neuroma.

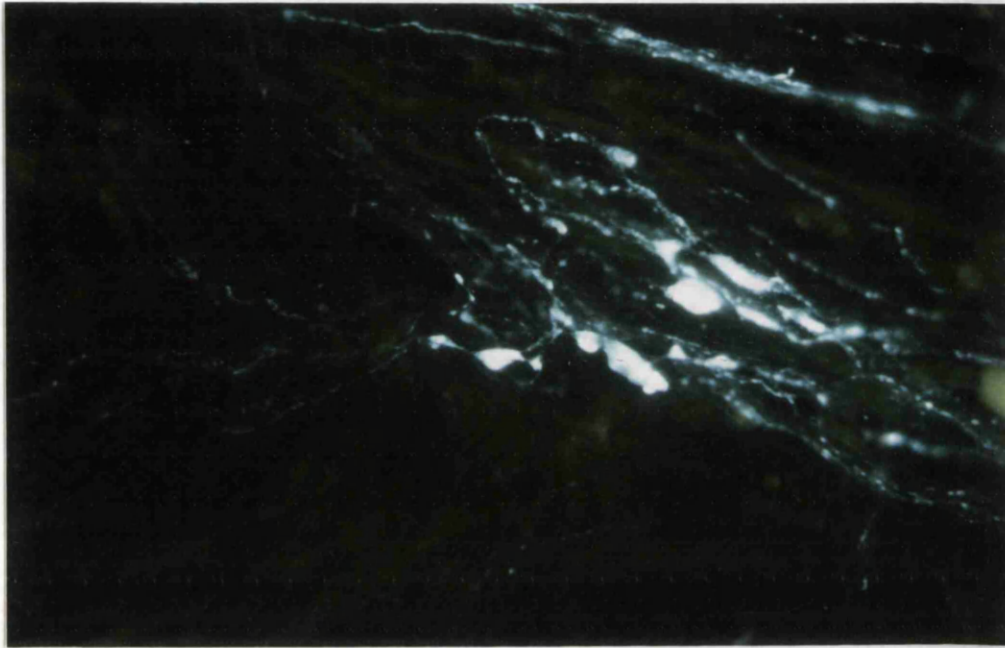
#### 4. 3-4 Week neuromas

An increase in sprouting of sympathetic axons was obvious around the distal tip of the neuroma, when 3 - 4 week old neuromas were compared with those taken from animals killed 2 weeks post section. Intermingling fluorescent sprouts with random orientations could be seen up to 2mm distal to the point of section. At a distance of 0.5mm proximal to the original point of nerve section, counts of sympathetic axons were increased to about twice normal values by 4 weeks after nerve section (Table 1, Fig. 14) and the mean slopes of these 3 and 4 week old neuromas were negative and significantly different from normal at  $p < 0.001$  (Table 2). The M15 values were not significantly different from normal. New growth was visible around both sides of the nerve, running up to 1.5mm proximally. Many sympathetic sprouts were again seen running perpendicularly to the main axis of the nerve, but now around the sides of the nerve extending proximally, not just at the neuroma tip. Blood vessels were very prominent in the neuromatous outgrowth, with a very distinct adrenergic innervation. This vascular innervation was distinguishable from the sympathetic axons of the nerve proper on the basis that the fluorescence was somewhat coarser than that of axons running in the nerve trunk itself (Fig. 15), similar to that seen in normal nerves.

Further proximally in the nerve, clusters of fine sympathetic axons were observed (Fig. 16). At four weeks after nerve section, counts of fluorescent axons were slightly below normal at 2.5mm proximal to the estimated point of nerve section (Table 1, Fig. 14).

#### 5. 6 - 8 Week Neuromas

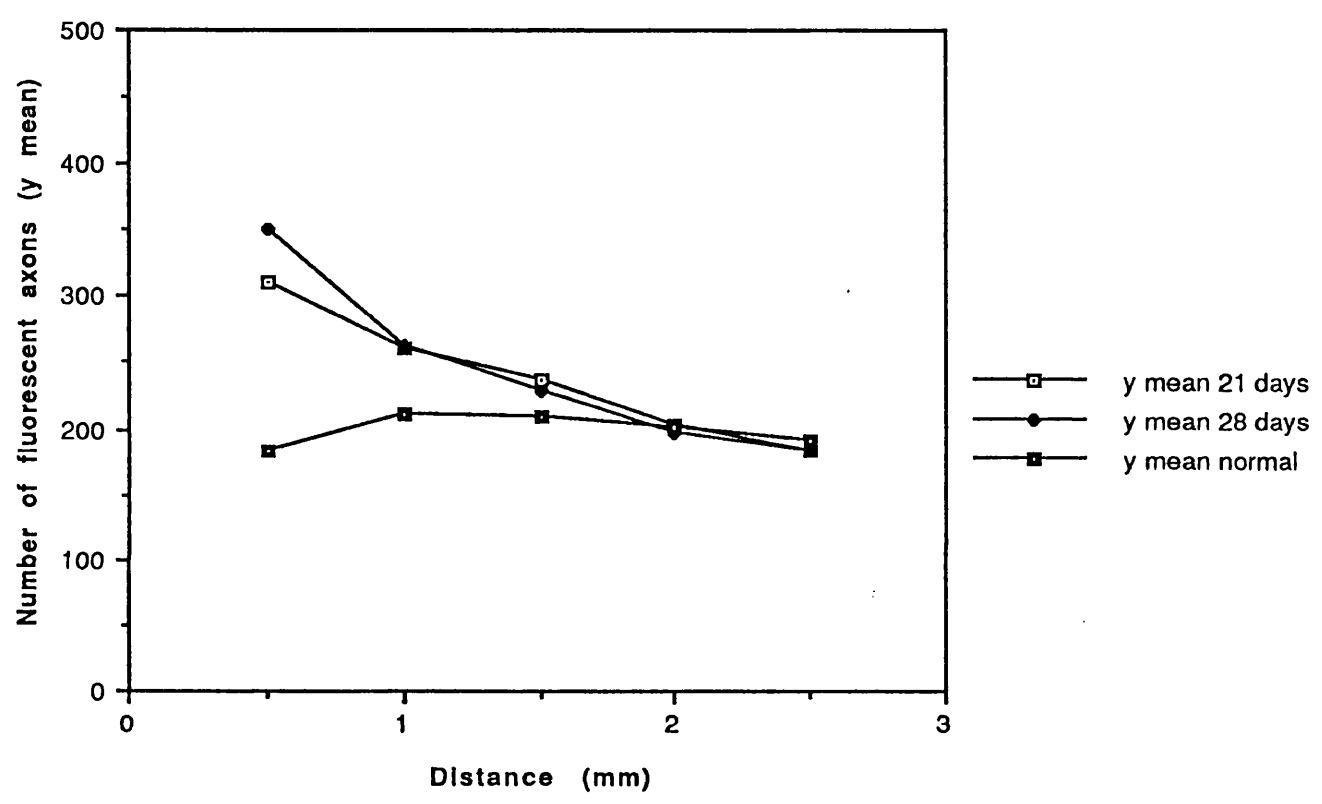
Neuromas from sciatic nerves sectioned 6 and 8 weeks previously were similar in appearance to those from nerves sectioned 4 weeks



**FIGURE 13.** Neuroma 14 days following section, 1.5mm from the distal tip. A highly unusual group of swollen sympathetic axons contain fluorescent material midway along their axons. Glyoxylic acid.

x 80

### Neuromas 21 and 28 days, plus normal Number of axons vs. Distance



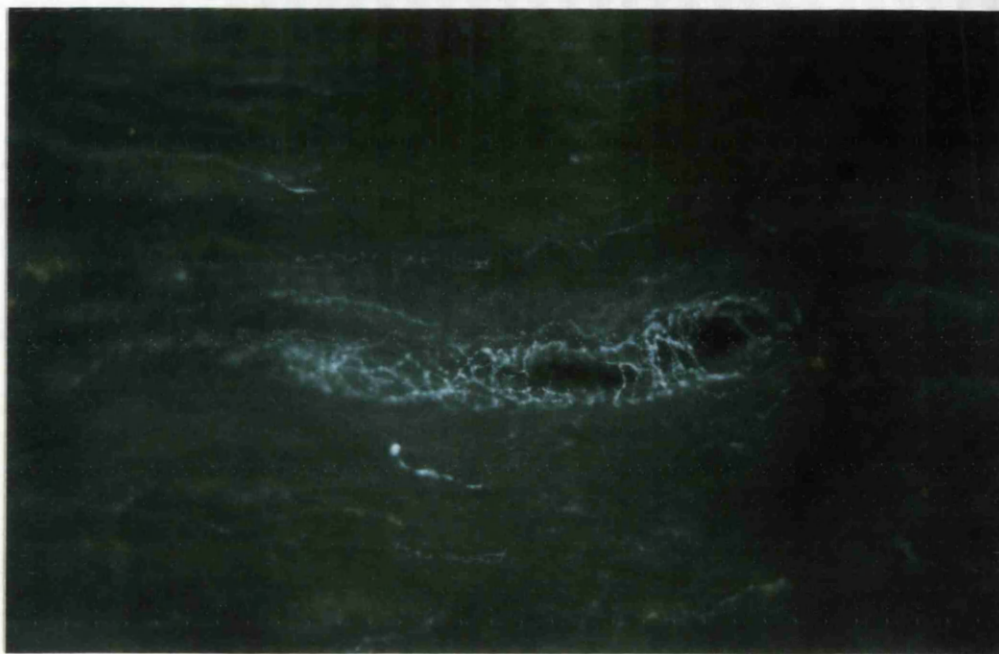**FIGURE 14** Number of fluorescent axons vs. distance in neuromas 21 and 28 days following nerve section, compared with the number of fluorescent axons in normal nerves.

**FIGURE 15.** Neuroma 28 days after section. The sympathetic innervation of the blood vessel in the centre can be distinguished from sympathetic axons in the nerve proper, since the individual axons are thicker and less uniformly orientated in the blood vessel. Glyoxylic acid.

x 80

**FIGURE 16.** Neuroma 21 days after section. A collection of fine sympathetic sprouts are running together 1.5mm from the distal tip of the neuroma. Glyoxylic acid.

x 80



before the animals were killed, except that more fluorescent axons were visible in the neuroma outgrowth. At 6 and 8 weeks after nerve section, counts 0.5mm from the distal tip were lower than at 4 weeks after nerve section (Table 1). Along each nerve, in a distal to proximal direction from the point of section, counts decreased, but there was a smaller gradation 8 weeks after section as compared to 6 weeks (Table 1, Fig.17). Both mean slopes were negative at 6 and 8 weeks. The mean slope of the 6 week old neuromas was significantly different from normal at  $p < 0.001$ , and the mean slope of the 8 week old neuromas significant at  $p < 0.02$  (Table 2). The M15 values were not significantly different from normal at either time.

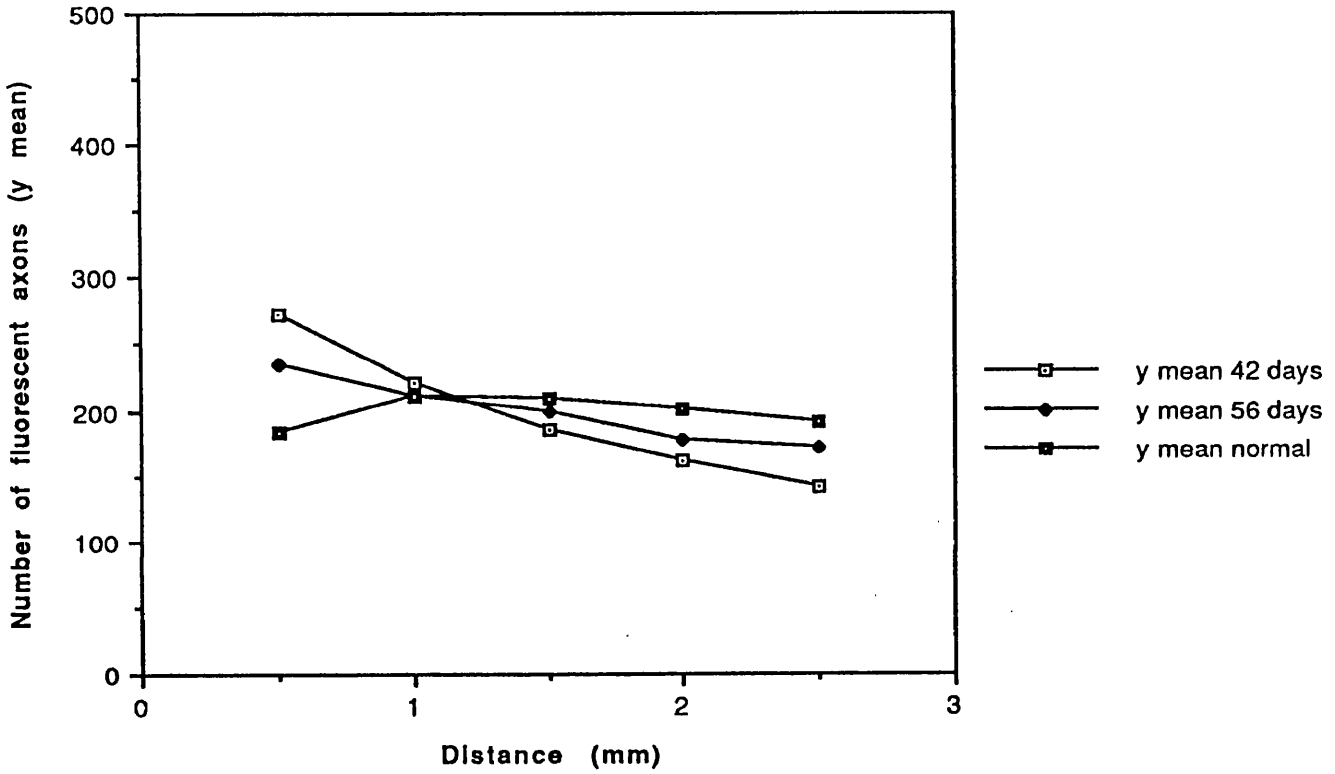
Vascularity in the neuromatous tissue distal to the point of section was very much increased, with an extensive network of fluorescent axons innervating the vessels. There were many fine fluorescent axons throughout the neuromatous tissue, still in a random orientation (Fig. 18). Sympathetic axons in the neuroma, although numerous, tended to exist singly, rather than in the groups usually seen in normal nerves. They did not have a completely normal morphology and were often thin with pronounced varicosities (Fig. 19). One sympathetic axon consisted of very large, bright, widely separated varicosities with very little inter-varicose fluorescence (Fig. 20). Another sympathetic axon in the nerve itself was much thicker at the distal end with a bulb of fluorescence at the tip. A few fluorescent perpendicular axonal sprouts were seen at one edge of one neuroma. Further proximally in the original nerve, fluorescent axons were much thicker, and ran in groups with the morphology of sympathetic axons in normal nerve.

At one point of section, which was demarcated by a change in myelinated fibre thickness and orientation, collections of yellow autofluorescent mast cells were obvious. Some pale yellow globules of myelin were also seen but these were only visible as background autofluorescence (Fig. 18). Some of the granular yellow / orange autofluorescent cells seen may again have been macrophages, the lipofuscin pigment of which is autofluorescent (Fig. 18).

#### 6. 6 Month Neuromas

The tissue in these neuromas was very similar to that seen 8 weeks following section, and there were many small thin fluorescent axons

### Neuromas 42 and 56 days, plus normal Number of axons vs. Distance



**FIGURE 17** Number of fluorescent axons vs. distance in neuromas 42 and 56 days following nerve section, compared with the number of fluorescent axons in normal nerves.

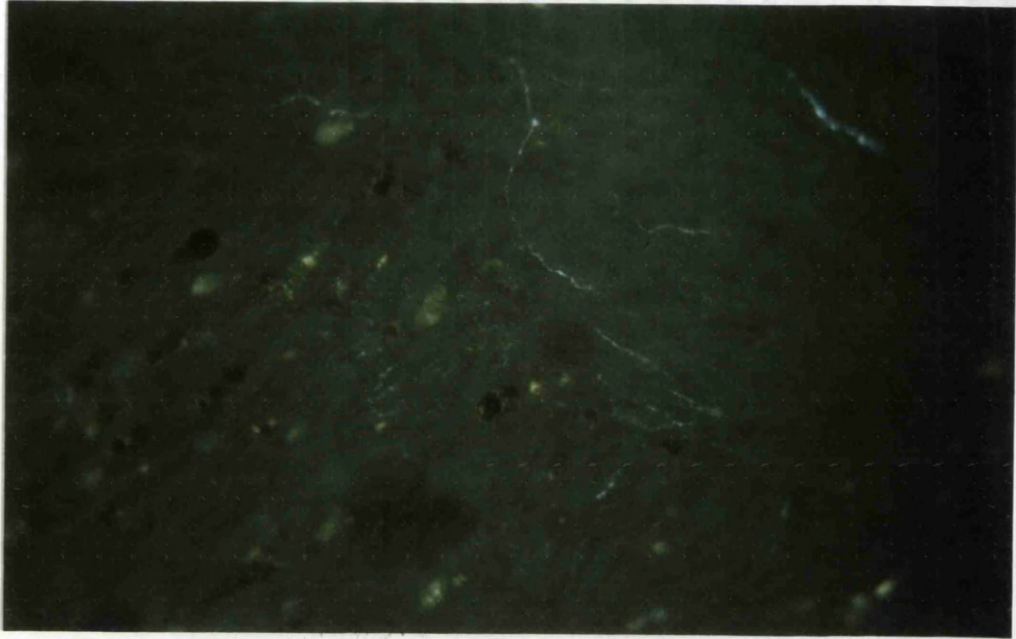


**FIGURE 18.** Neuroma 42 days after nerve section. The original tissue can be distinguished to the left of the micrograph because it contains yellow autofluorescent mast cells and vacuoles from degenerate material. The new neuromatous tissue towards the upper right is more homogenous and contains fine fluorescent sprouts. Glyoxylic acid.

x 80

**FIGURE 19.** Neuroma 42 days after section, 1mm from the distal tip. Many thin sympathetic axon sprouts orientated along the longitudinal axis of the nerve can be seen in the centre of the micrograph, but there is also an extensive collection of sympathetic sprouts running at right angles. Glyoxylic acid.

x 160



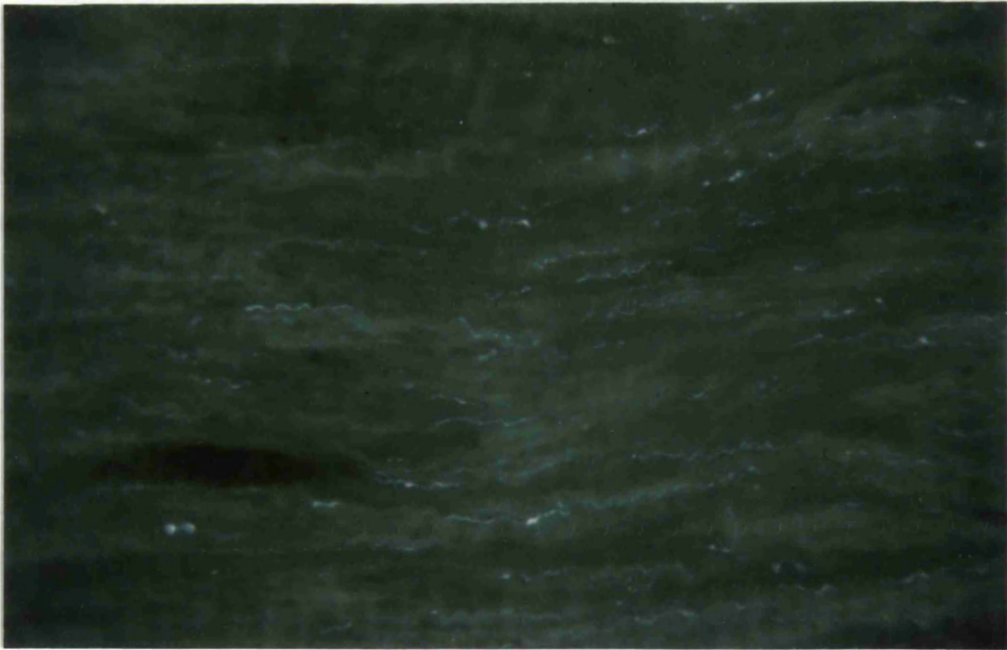
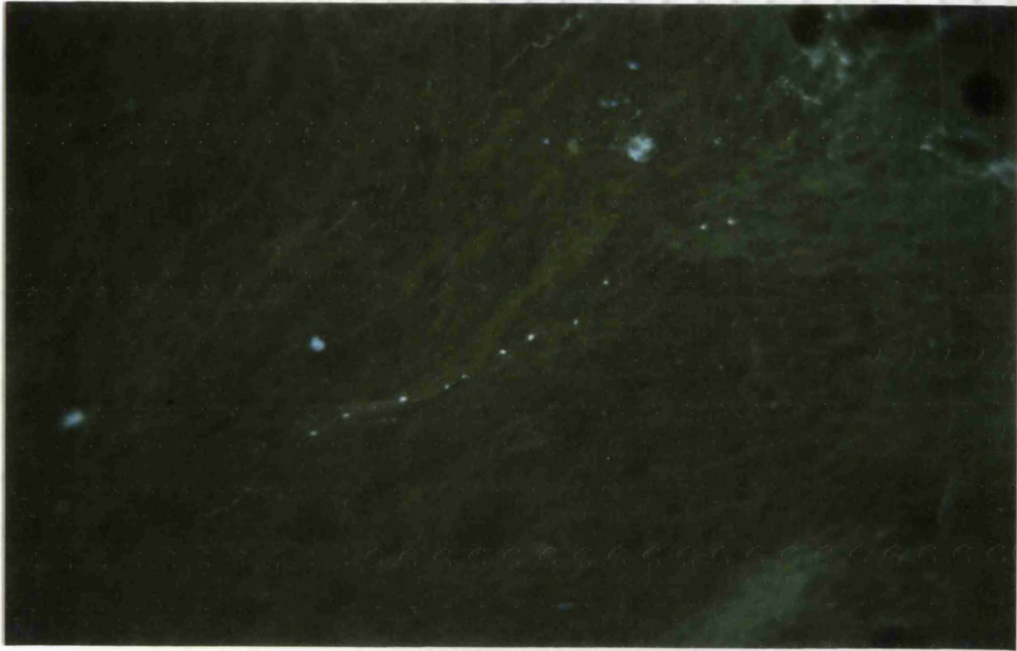
57

**FIGURE 20.** Neuroma 42 days after nerve section, 1.5mm from the distal tip. This unusual axon has large punctate fluorescent varicosities, but very little fluorescent material in the remainder of the axon. Glyoxylic acid.

x 80

**FIGURE 21.** Neuromatous tissue 6 months after section. Many fine sympathetic axon sprouts, some of which contain large varicosities, are visible in the neuromatous outgrowth distal to the original point of section. Glyoxylic acid.

x 80



visible in the neuromatous outgrowth distal to the point of nerve section (Fig. 21). The sympathetic innervation of the blood vessels was again very pronounced. No counts of sympathetic axons were made in this tissue, but in the main body of the old nerve, the distribution of fluorescent axons appeared to be normal.

### C. IMMUNOFLUORESCENCE STUDIES

The patterns of fluorescence seen in normal nerves and 3 day old neuromas processed by an immunofluorescence method were similar to those seen in nerves and neuromas treated with glyoxylic acid (Fig.22). The main difference was in the intensity of the fluorescence, which was very much lower in the immunofluorescent preparation. This was because the fluorescent marker was FITC, and the wavelength of the incident illumination was longer and therefore less energetic. The immunofluorescence was also less stable in the microscope light beam, and faded more rapidly on storage.

For these reasons, the immunofluorescence method was abandoned, in favour of the SPG glyoxylic acid technique.

### D. RESERPINE TREATED ANIMALS

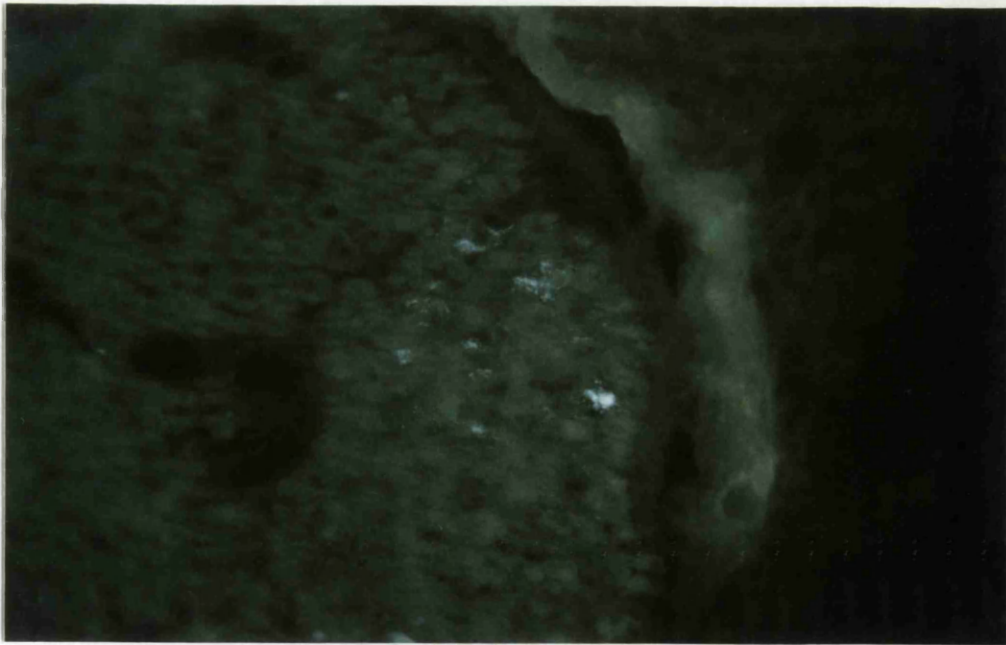
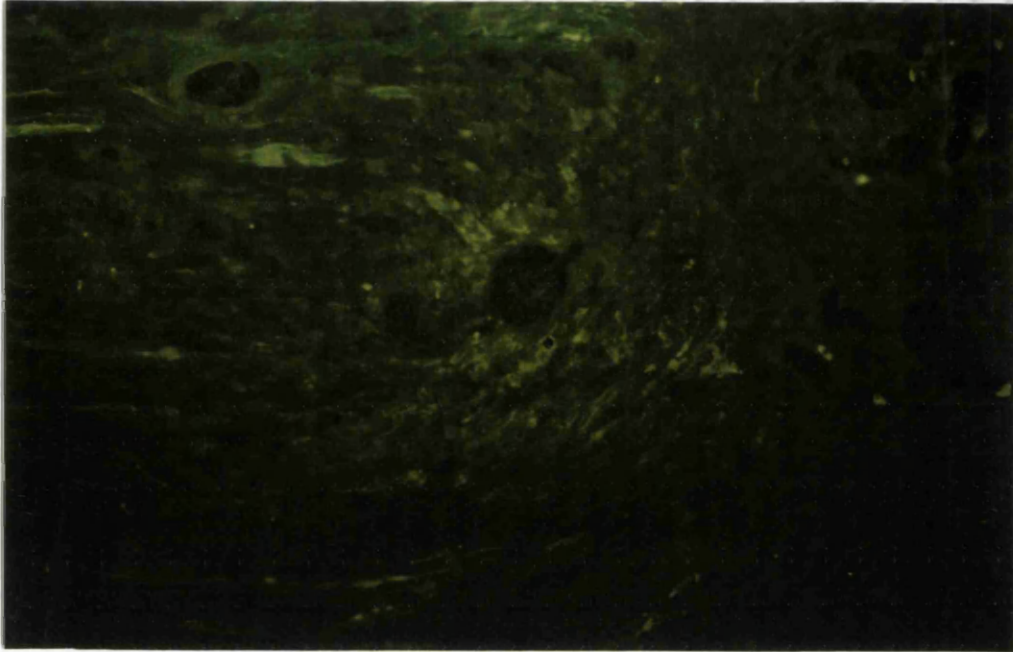
At 3 days after nerve section there was a marked reduction in the numbers of fluorescing axons, when compared with nerves in rats not treated with reserpine. Very small patches of diffuse fluorescence were seen at the distal tip of neuromas, but there were virtually no axons fluorescing in the remainder of the nerve (Fig. 23), confirming that the fluorescent product seen following glyoxylic acid treatment is an effective marker for sympathetic axons in the peripheral nerves.

**FIGURE 22.** Distal tip of a neuroma 3 days following nerve section, reacted for immunofluorescence using anti-dopamine beta hydroxylase as the primary antibody and FITC as the fluorescent marker. The pattern of fluorescence is similar to that seen in Figure 4 following glyoxylic acid treatment.

x 40

**FIGURE 23.** Distal tip of a neuroma 3 days following section, from an animal pretreated with reserpine 24 hours before killing. The sympathetic axons at the distal tip of the neuroma (right) contain very little noradrenaline (cf Figure 5). Glyoxylic acid.

x 40



Quantitative fluorescence study

TABLE 1

NORMAL NERVES AND NEUROMAS

Days post section	n	Number of fluorescent axons at distance from distal tip (y mean)				
		0.5mm	1.0mm	1.5mm	2.0mm	2.5mm
Normal uncut	22	182	211	210	200	192
Normal control	6	190	202	194	199	186
Neuroma 3	2	(1000)*	717	604	554	484
Neuroma 7	3	855	609	496	397	349
Neuroma 14	5	111	154	161	165	171
Neuroma 21	4	285	261	237	203	184
Neuroma 28	3	351	264	260	197	183
Neuroma 42	3	273	220	186	162	141
Neuroma 56	3	235	210	198	177	171

\* Extrapolated Value



TABLE 2 NORMAL NERVES AND NEUROMAS

Days Post Section	n	Mean Slope b <sup>ⓐ</sup>	95% C.I.	Signif.	Mean M15	Diff. from normal mean	95% C.I.	Signif.
Normal uncut	22	+0.0263	-	-	5.2496	-	-	-
Normal control	6	-0.0133	-	-	5.2445	0.0051	-0.206 to +0.216	0
Neuroma 3	2	-0.2457	-0.414 to -0.077	***	6.4254	1.1758	+0.837 to +1.515	****
Neuroma 7	3	-0.4351	-0.566 to -0.305	****	6.2312	0.9816	+0.699 to +1.264	****
Neuroma 14	5	+0.175	+0.068 to +0.282	***	4.9885	0.2611	+0.034 to +0.488	*
Neuroma 21	4	-0.2624	-0.375 to -0.149	****	5.446	0.1964	-0.053 to +0.446	0
Neuroma 28	3	-0.3253	-0.456 to -0.195	****	5.466	0.2164	-0.066 to +0.499	0
Neuroma 42	3	-0.3215	-0.452 to -0.191	****	5.2471	0.0025	-0.280 to +0.285	0
Neuroma 56	3	-0.1621	-0.293 to -0.032	**	5.2811	0.0315	-0.251 to +0.314	0

ⓐ Mean slope of normal nerves taken as = 0.00

Therefore, mean slope b for neuromas = Difference between normal mean and neuroma mean.

Significance levels :  
 p<0.05 = \*  
 p<0.02 = \*\*  
 p<0.01 = \*\*\*  
 p<0.001 = \*\*\*\*

## Summary of Fluorescence Results

1. Fluorescent sympathetic axons could be identified in cryostat sections of normal sciatic nerves, following glyoxylic acid treatment, and consisted of a chain of small, bright varicosities. Counts of fluorescent axons in control sciatic nerves from unoperated animals showed no significant variation along the length of nerve examined, and counts in the normal right nerves contralateral to neuromas were similar.

2. Large accumulations of fluorescent material were seen at the distal tip of the proximal stump neuromas 3 and 7 days following nerve section, and the numbers of fluorescent sympathetic axons were well above normal throughout the whole length of the neuromas examined. Sympathetic axon sprouts were seen at the distal tips of 3 day old neuromas, many running at right angles to the main body of the nerve.

3. By two weeks following section, the number of fluorescent sympathetic axons had fallen to 60% of normal at the distal tip, but began to increase again 3 - 4 weeks following nerve section. In 8 week old neuromas, the number of sympathetic axons was normal, as judged by MI5 values.

4. In 6 month old neuromas, there were many small thin fluorescent axons visible in the neuromatous outgrowth distal to the original point of section, showing that sympathetic axons were still sprouting 6 months following nerve injury.

5. The pattern of fluorescence following immunocytochemical labelling with antidopamine beta hydroxylase/FITC was similar to that in the glyoxylic acid preparations. Reserpine depleted the glyoxylic acid induced fluorescence. From these two results, it was concluded that the fluorescence induced by the SPG technique was due to the presence of noradrenaline.

specimens were processed for transmission electron microscopy and embedded in epon resin in the conventional manner (see Appendix 1).

0.5 $\mu$ m sections were cut on a Reichert Ultracut ultramicrotome, and stained with 1% toluidine blue in 1% borax solution, for light microscope localization of suitable areas of tissue for ultrastructural analysis. Following this localization, 60-90nm thin sections were cut (silver interference colour on the Peachey scale), and mounted on 300 mesh thin bar copper grids.

Sections were then stained for 15 minutes with saturated 50% methanolic uranyl acetate, rinsed in 50% methanol, followed by 10 minutes staining in Reynold's lead citrate solution, and rinsed in filtered distilled water.

#### Counts of labelled Schwann cell subunits

Grids with sections of normal nerves and 3 day old neuromas were selected for quantitative analysis. The most central twelve grid squares were chosen from the grid, and all the Schwann cell subunits within those squares analysed.

All Schwann cell subunits within those areas were scored, either as positive, if one or more 5-OH DA labelled axons could be identified within the subunit, or as negative. The percentage of labelled subunits was then calculated.

### Results 3 ULTRASTRUCTURAL STUDIES

#### Light microscopy (resin sections) and Electron Microscopy

All figures are taken from transverse sections of tissue fixed with 3% glutaraldehyde, post-fixed with 1% aqueous osmium tetroxide and stained with uranyl acetate and lead citrate unless otherwise stated.

#### A. NORMAL SCIATIC NERVES

Normal sciatic nerves from rats or mice, contralateral to a neuroma of the left sciatic nerve, or from control animals, had the usual appearance of mixed peripheral nerves (Landon, 1976). The nerve was composed of 3 large fascicles (Fig. 24), and each consisted of many large and small myelinated fibres, and small groups of unmyelinated fibres, enclosed within Schwann cell subunits (Fig. 25). Surrounding the central nerve was the perineurium - a layer of closely packed connective tissue, composed of collagen and fibroblasts. Small blood vessels were visible in both the nerve itself and the outermost surrounding layer of connective tissue, the epineurium. This outer layer also contained large lipid droplets. Mast cells, which were easily distinguished in toluidine blue sections by their pinkish-blue colour and dense granules, were distributed throughout the endo-, peri- and epineurium.

Pre-treatment with nialamide and 5-hydroxy dopamine did not alter the structure of these nerves at the light microscope level, only the density of vesicles visible in the electron microscope. The morphology of nerves fixed by perfusion through the aorta or by immerse fixation of the sciatic nerves with 3% glutaraldehyde in 0.1M sodium cacodylate was very similar, the only difference being the presence of blood cells in the capillaries of immerse - fixed tissue. Tissue fixed with FAGLU solution was also well preserved, but the dcv were not sufficiently dense to allow positive identification of axons as sympathetic.

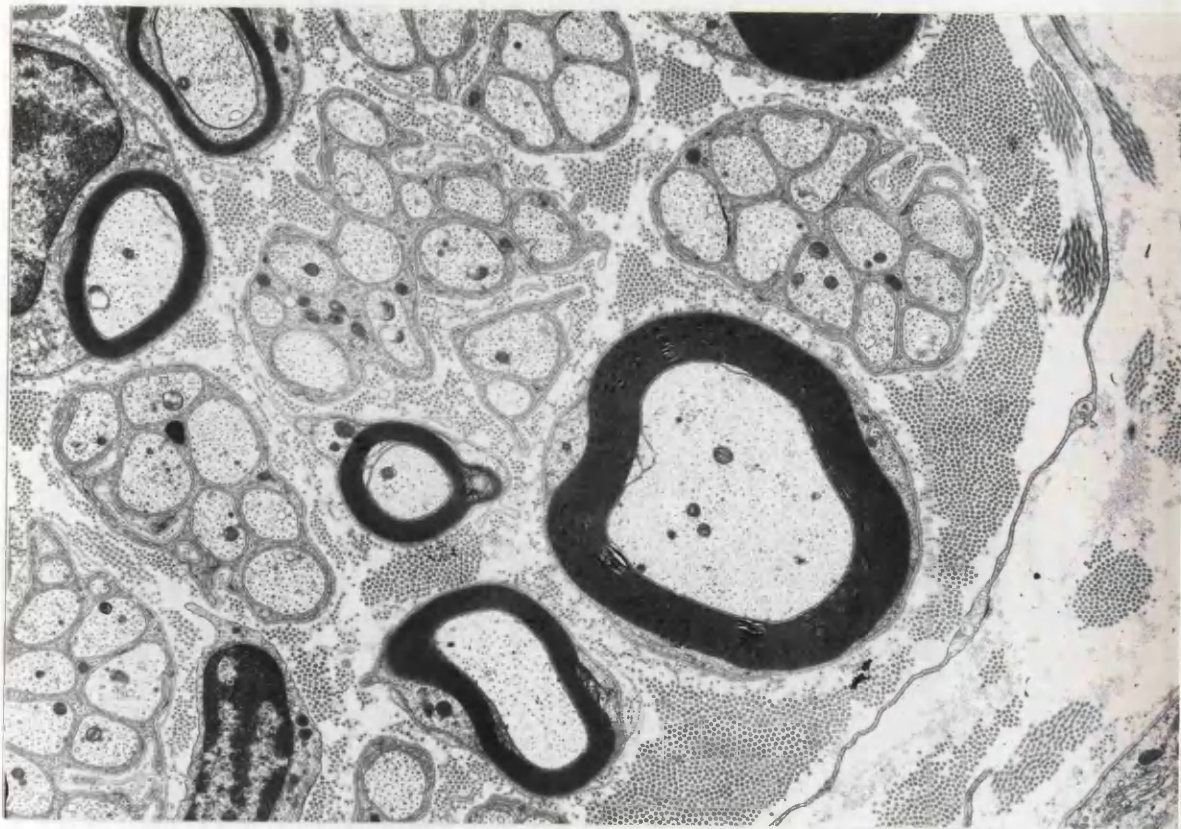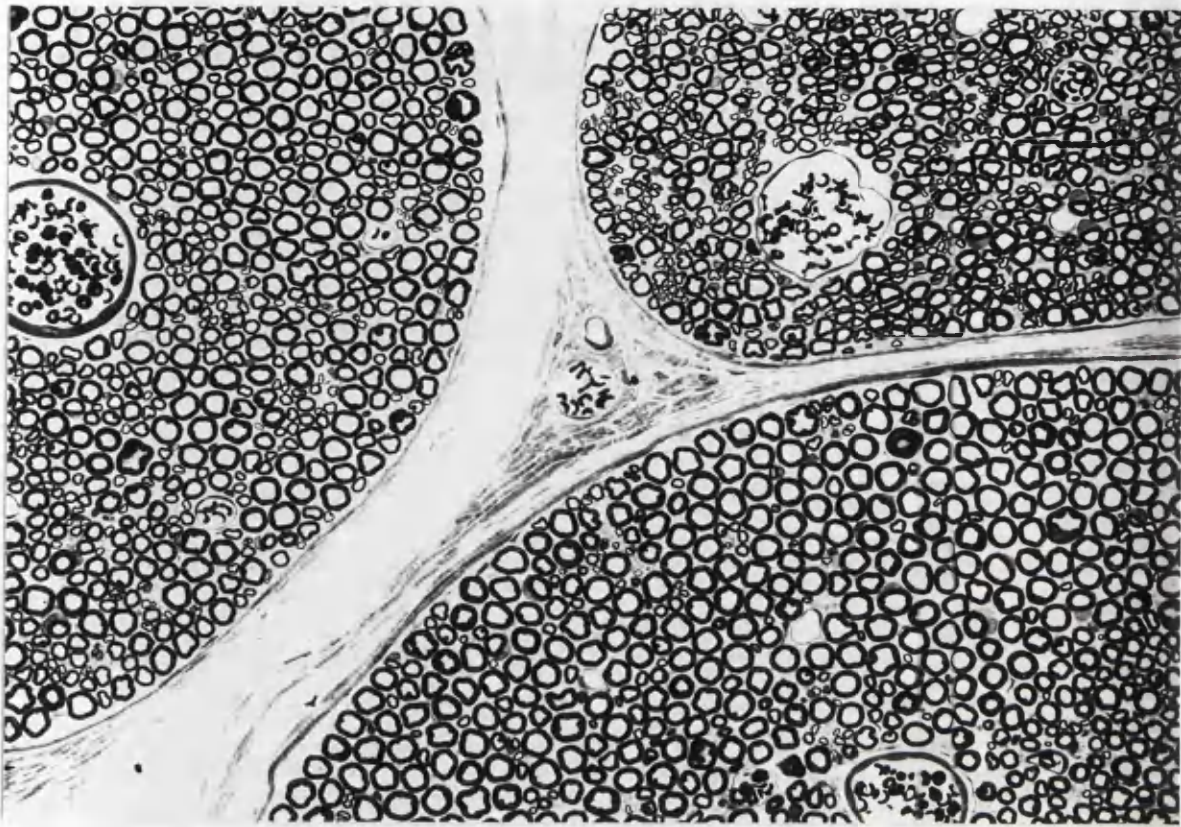
In animals which had been pre-treated with nialamide and 5-hydroxy dopamine, some unmyelinated axons could be identified as sympathetic due to the presence of highly electron-dense cored vesicles in their cytoplasm (Fig. 26). These vesicles were highly conspicuous, even at low magnifications (2,600x), the main criterion for their positive

**FIGURE 24.** Normal sciatic nerve, immersion fixed. Normal myelinated and unmyelinated axons are contained within fascicles surrounded by perineurium. The blood vessels are not empty because the tissue has been immersion fixed. Glutaraldehyde / Resin / Toluidine Blue.

x 135

**FIGURE 25** Normal rat sciatic nerve, pretreated with 5-OH DA only, no 5 - OH DA labelled dcx are visible in any unmyelinated axons.

x 12 900

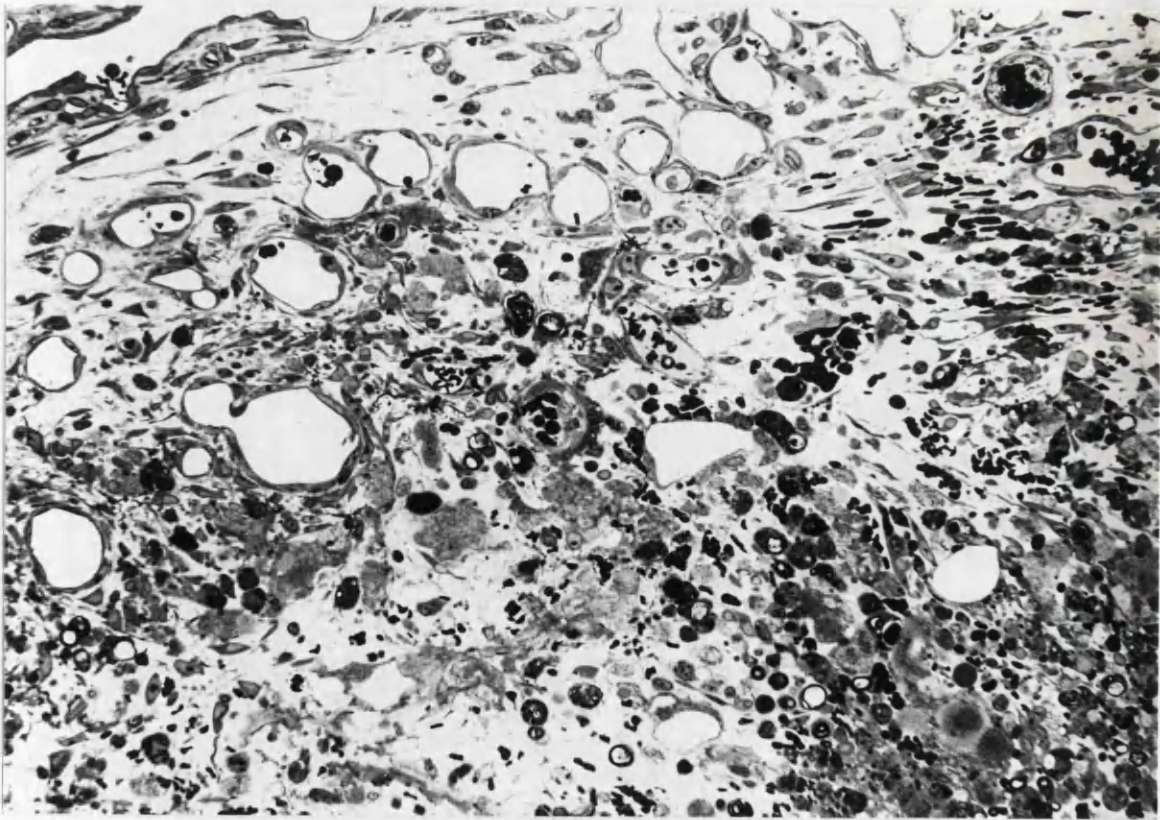
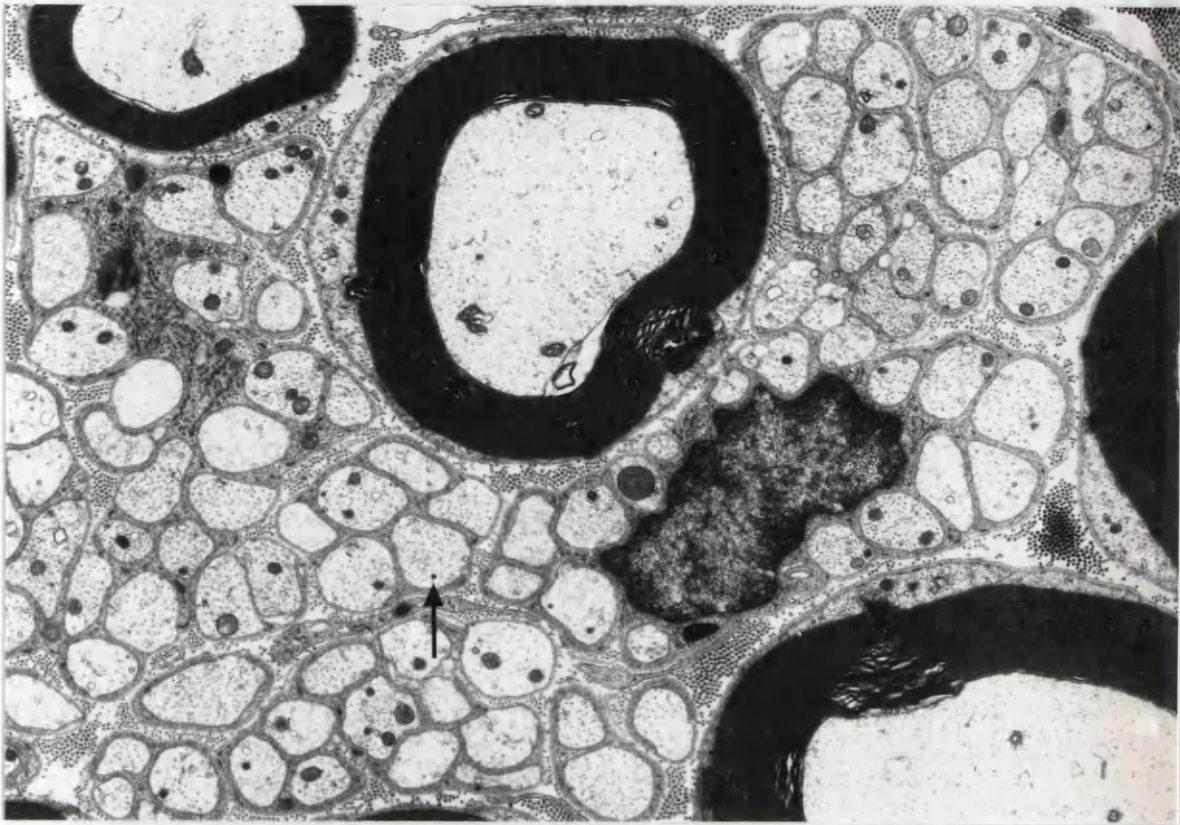


**FIGURE 26** Normal rat sciatic nerve. Pretreated with nialamide and 5-OH DA, showing very electron dense 5-OH DA labelled dcv (arrow) in unmyelinated axons, which are therefore identified as sympathetic.

x 10 000

**FIGURE 27.** Distal tip of a neuroma 3 days following section, showing the inflammatory reaction and new blood vessels present. Groups of sprouting axons are not present in the most distal tissue. Glutaraldehyde / Resin / Toluidine blue.

x 120





identification as noradrenergic dcv being their extreme electron density. Additionally, the size of these vesicles always fell between 30 and 100nm.

There were, however, still difficulties in positively identifying some cases of putatively labelled axons, since the electron density of these 5-OH DA labelled vesicles was by no means uniform. In sciatic nerves from untreated animals it was very difficult to identify sympathetic axons with any certainty. At higher magnifications, (15-20 000x) vesicles with an electron-dense core could be identified in unmyelinated axon cytoplasm, but these vesicles were not immediately obvious, and were fewer in number than in those animals treated with nialamide and 5-hydroxy dopamine.

Quantitative studies showed that approximately 11% of Schwann cell sub-units (Remak bundles) contained at least one sympathetic axon (Table 3). Each 5-OH DA labelled Schwann cell subunit normally contained up to 3 labelled axons. Other unlabelled unmyelinated axons in the Schwann cell subunits may have been sympathetic, but noradrenaline in post-ganglionic sympathetic axons is stored in terminal varicosities, and one of these varicosities containing dcv may not have been seen in the plane of section examined. Sympathetic axons usually contained one or sometimes two dense-cored vesicles per axon. Sympathetic axons were seen evenly distributed throughout the whole section of the nerve, and were not especially clustered, for example toward the perineurium.

Very rarely, dcv which were very dense and appeared to be labelled were seen in the Schwann cell cytoplasm, although it was highly unlikely that these were noradrenergic. Occasionally, vesicles with a dense core were seen in the axoplasm of myelinated fibres, but the core of these vesicles was never dense enough to allow them to be identified as 5-OH DA labelled vesicles.

Occasionally, collagen pockets enveloped by Schwann cell cytoplasm were seen. These profiles appeared to be very similar to unmyelinated axons at low magnifications, and positive identification, by the differentiation of collagen fibrils from microtubules, required study of the sections at a magnification of between 8-10,000x.

## B. NEUROMAS (SECTIONED LEFT SCIATIC NERVE)

The most marked morphological changes occurred in the most distal tip of the sectioned nerve. The majority of the tissue examined came from the terminal 0.5 - 1.0mm of the nerve. In the chronic neuromas, more proximal tissue was examined, up to 2mm proximal to the point of nerve section. Additionally, also in the more chronic neuromas, the neuroma outgrowth was examined. This tissue extended up to 2mm distal to the original point of section.

### 1. 3 DAYS POST-SECTION

Macroscopically, even at this short interval after section, a swelling was seen on the terminal 1-2mm of the proximal stump. Fine blood vessels representing a vascular outgrowth were seen on the surface of the nerve, giving the tissue a pinker appearance than the corresponding contralateral normal sciatic nerve. The tissue of the neuromatous swelling at the distal end of the proximal stump appeared slightly more translucent than the more normal proximal portion of the nerve. This translucent appearance is probably due to myelin degeneration, resulting in less compact myelin at the distal tip.

#### 1.1 Non-axonal structures

'Free' erythrocytes - i.e. not enclosed in blood vessels - were seen throughout the perineurium and epineurium, especially at the most distal tip of the sectioned nerve. Some were also seen in the endoneurial space, but these may have migrated from the cut end of the nerve. Even in well perfused tissue, there were a few capillaries which still contained erythrocytes. The increased vascularity of the tissue could be seen in toluidine blue stained resin sections (Fig. 27).

There were many macrophages present in the sectioned nerve, either free in the endoneurium or in the process of phagocytic activity, when cellular debris was seen in their cytoplasm. There was often more than one macrophage per Schwann cell subunit, at low magnifications giving the appearance of a multi-nucleated cell. Also present were many mast cells, which could be easily differentiated from macrophages on the basis of differences in their respective cytoplasmic granules, and general shape. The mast cells were very much more rounded in

appearance, although both types of cell showed pseudopodial processes. Mast cells had a more central nucleus surrounded by extremely dense large granules. The lysosome-like granules in macrophages were much less electron dense, although of similar size, and took up a smaller part of the cytoplasmic area. Macrophages also had the classical appearance of mono-nuclear cells; an indented nucleus with dense chromatin around the periphery of the nucleus (Fig. 28). The cytoplasm of macrophages also contained more endoplasmic reticulum and mitochondria than that of the mast cells. Mast cells were only ever seen free in the endoneurial space, or within the perineurium.

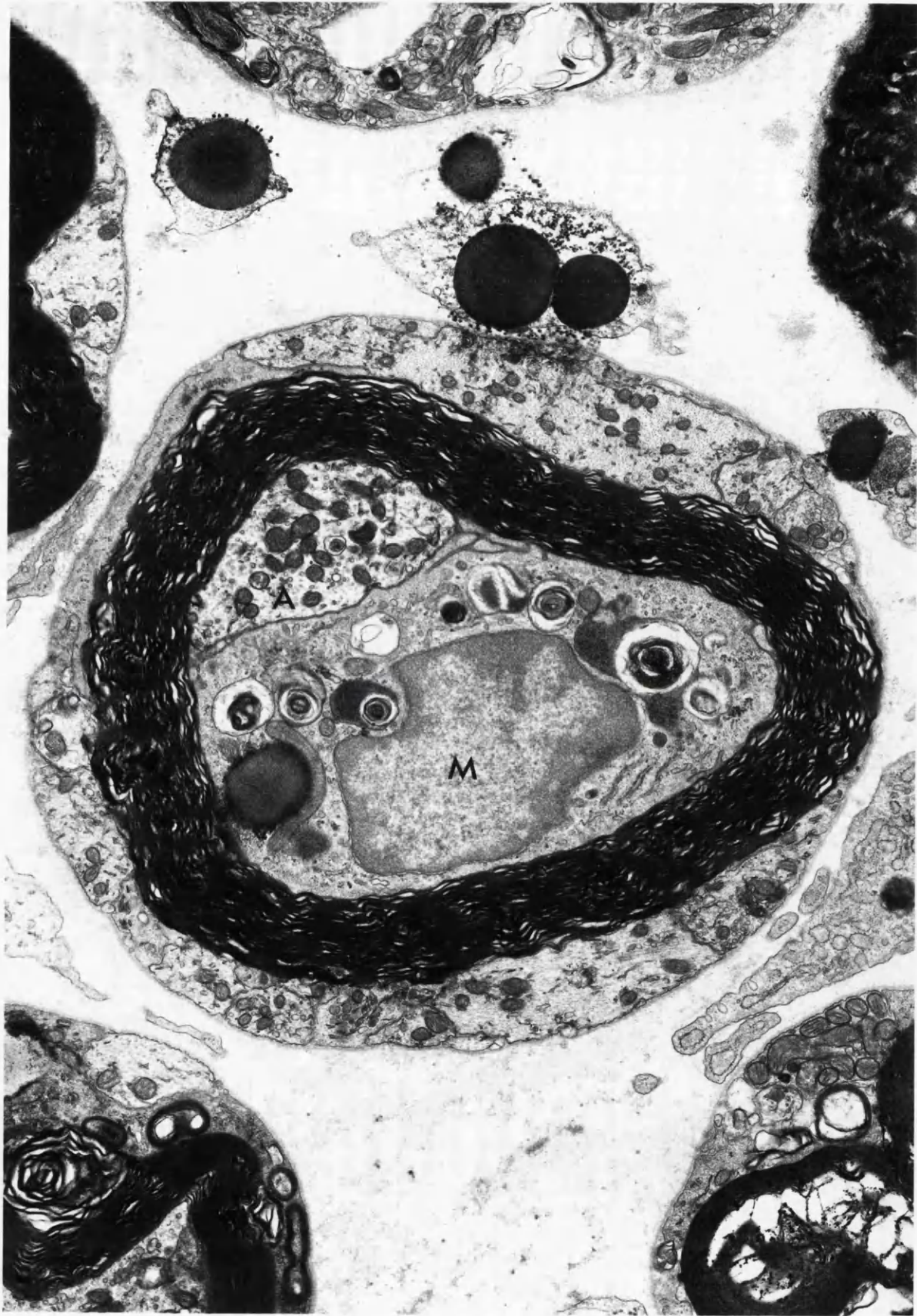### 1.2 Myelinated Fibres

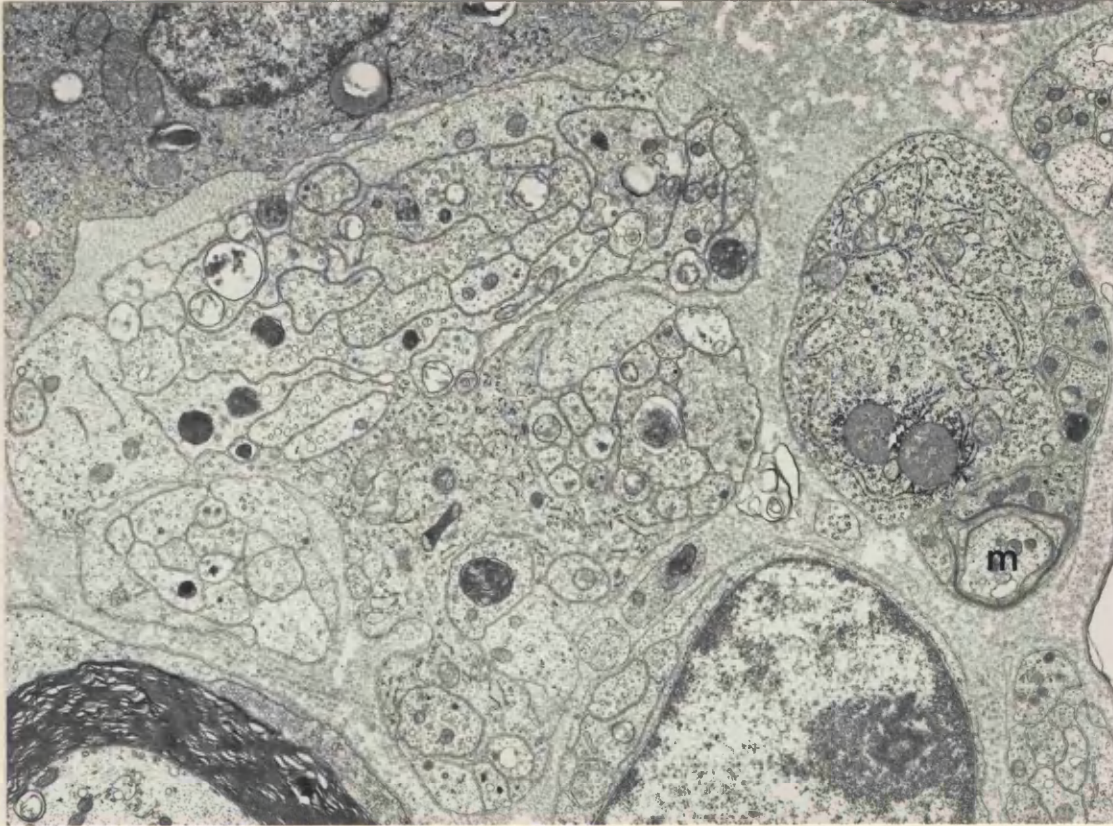
The most prominent feature of the myelinated fibres 3 days after nerve section was degeneration, although some limited regeneration had begun (Fig. 29). These changes were most noticeable in the terminal 0.5 - 1.0mm of the proximal stump. Fibres examined 2 - 3 mm further proximally appeared essentially normal. The largest myelinated fibres showed the most degenerative changes; more of the large myelinated fibres appeared to have begun degenerating, and the changes in these fibres were more extensive than those seen in the smaller fibres. Often, the axon had been extruded from the myelin sheath. The sheath in these cases showed gross degenerative changes; large whorls of degenerate myelin were visible within the Schwann cell cytoplasm with opaque droplets of phospholipid breakdown products (Fig. 30). Frequently, macrophages had entered the Schwann cell tube, and were in the process of ingesting the myelin. The macrophage cytoplasm was usually distinguishable from that of the Schwann cell on the grounds that it was denser, had a large complement of rough endoplasmic reticulum and free ribosomes. Whorls of myelin debris and breakdown products were common to both Schwann cells and macrophages, indicating that both may sometimes have a phagocytic role, although it is generally thought that Schwann cells are principally involved in the phagocytic process.

Some myelinated fibres showed less severe degenerative changes. Many showed loosening of myelin lamellae, sometimes with a honeycomb-like structure appearing within the lamellae. Myelin sheaths often had a wavy, crenated appearance, with axon retraction from the inner lamellae. Sometimes, axonal sprouts were seen growing inside the myelin sheath of a myelinated fibre (Fig. 31). The axon itself often

**FIGURE 28** 3 day neuroma, distal 1mm. Chromate fixative. This myelinated fibre contains a macrophage (M) within the central tube. The axon (A) has been displaced to one side. Numerous sprouts are visible within the outer basal lamina.

x 13 900



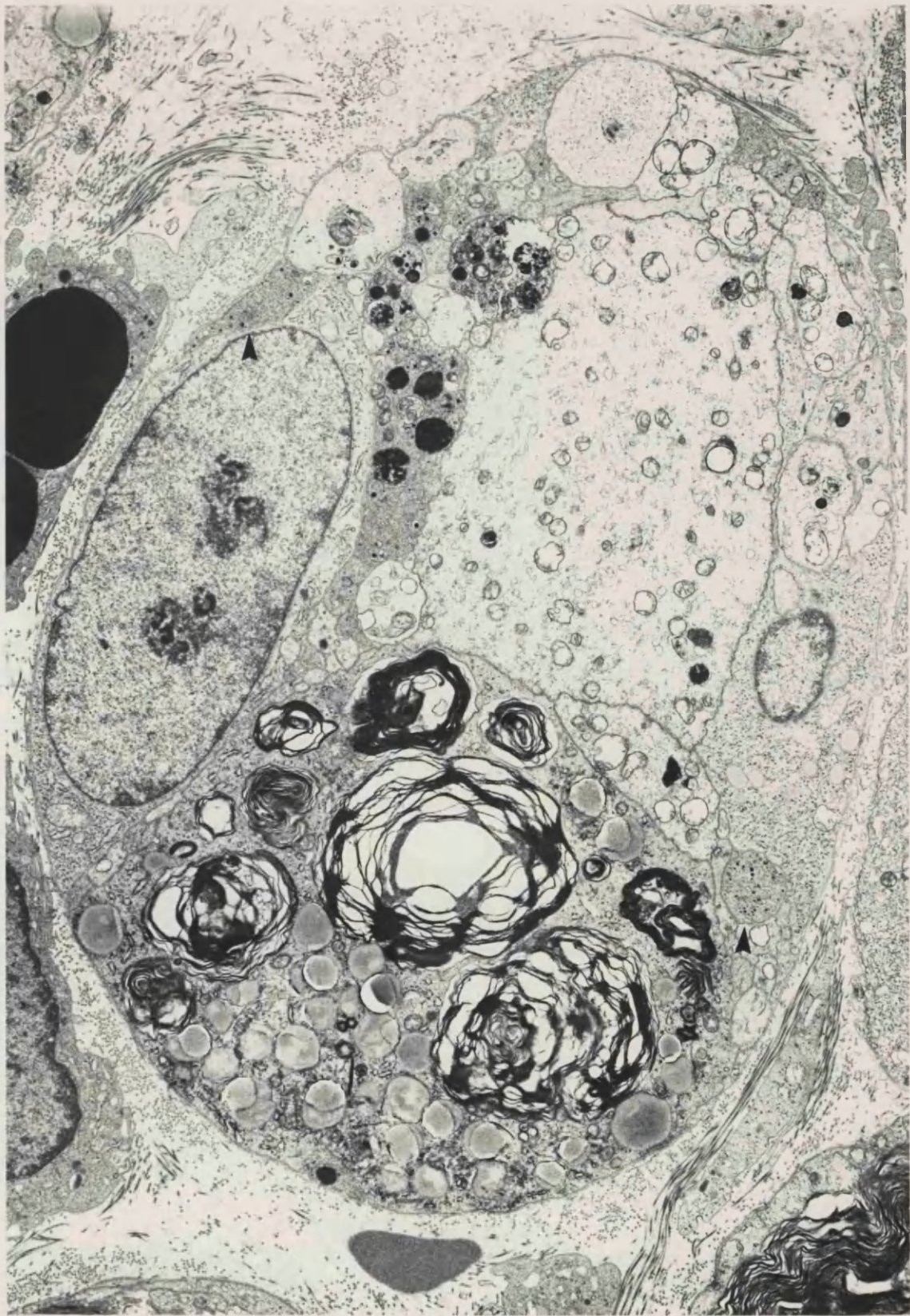


**FIGURE 29** 3 day neuroma, distal 1mm. One of the small axons which is beginning to myelinate (M), contains 4 axonal sprouts within the Schwann cell cytoplasm. Myelination is not commonly seen at such an acute time following nerve section.

x 11 100

**FIGURE 30** 3 day neuroma, distal 1mm. This formerly myelinated fibre contains sympathetic axons within the basal lamina (arrows). The degenerate myelin remains to one side of the Schwann cell cytoplasm and the large central axon is probably the original axon of this fibre.

x 6 300



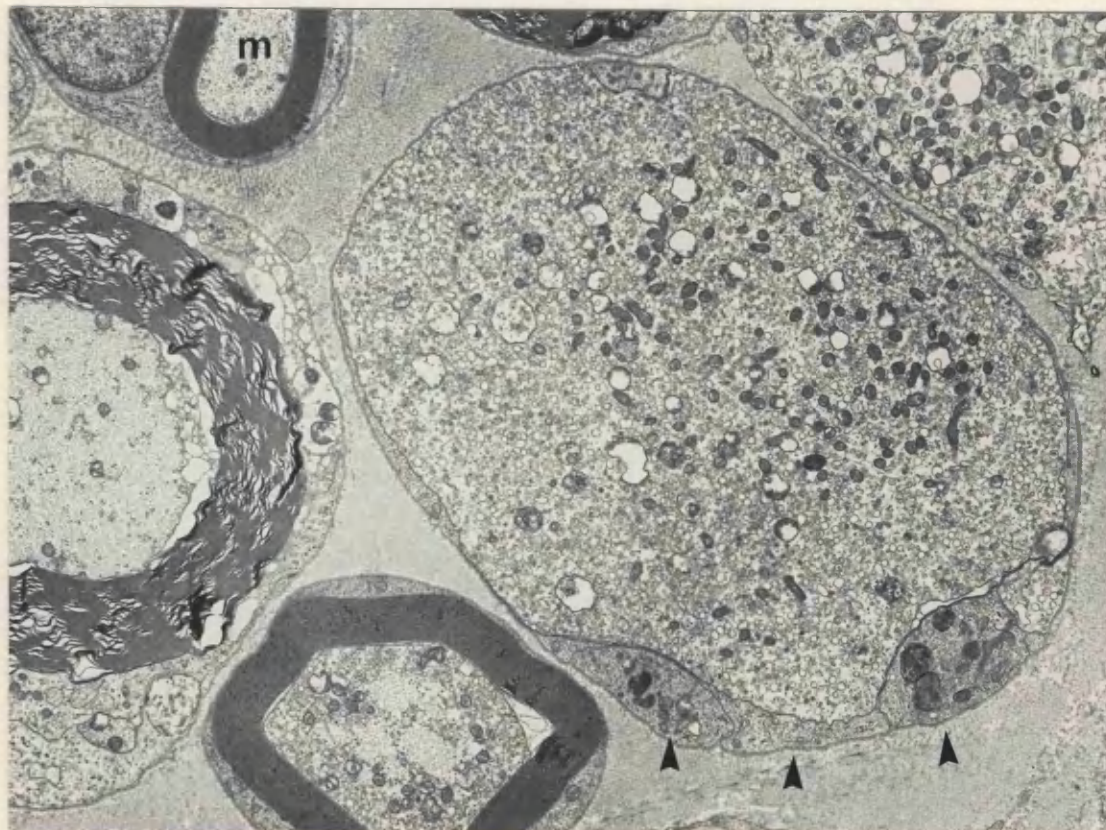
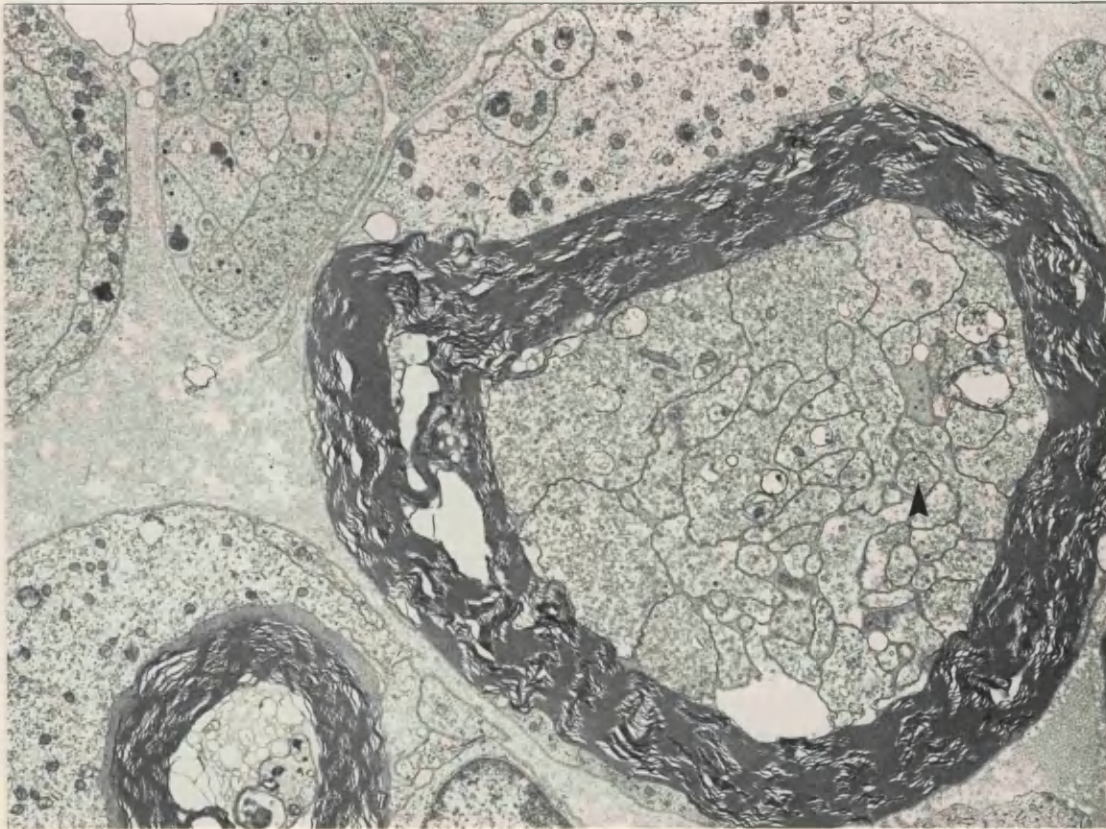


**FIGURE 31** 3 day neuroma, distal lmm. Numerous sprouts can be seen within the myelin sheath of this fibre, one of which may be sympathetic (arrow). Sprouts can also be seen within the outer basal lamina.

x 7 200

**FIGURE 32** 3 day neuroma, distal lmm. This large very swollen axon contains an accumulation of organelles, mainly mitochondria, granulated and clear vesicles, and multivesicular bodies. No 5-OH DA labelled dcv are visible. The three large profiles within the same subunit are probably Schwann cell cytoplasm (arrows). An intact myelinated fibre is also present (M).

x 14 800



showed degenerative changes - the least severe of these being mitochondria with swollen matrix material, and a loss of axonal microtubules. More marked changes included grossly swollen axons, filled with an accumulation of large granular and clear vesicles, small and large mitochondria and multivesicular bodies, probably representing axonal debris from degenerate organelles. Some of the fibres which had grossly swollen axons also had rather thin myelin sheaths, probably due to myelin slippage, a process whereby the myelin lamellae are believed to slip over each other to make room for the expanded axon (Martinez and Friede, 1969). Many small myelinated fibres were completely normal in appearance, even at the distal tip of the nerve, with apparently no degeneration (Fig. 32).

Numerous axonal sprouts were often seen within the Schwann cell basement membrane of myelinated axons. The Schwann cell cytoplasm had an irregular outline, with thin processes of cytoplasm between axonal sprouts or protruding macrophage cytoplasm. The basement membrane was generally compact around the nerve fibres, but sometimes was becoming loosened, with folds of flocculent-looking membrane. Rarely, empty Schwann cell tubes were seen, the basement membranes being highly folded (Fig. 33).

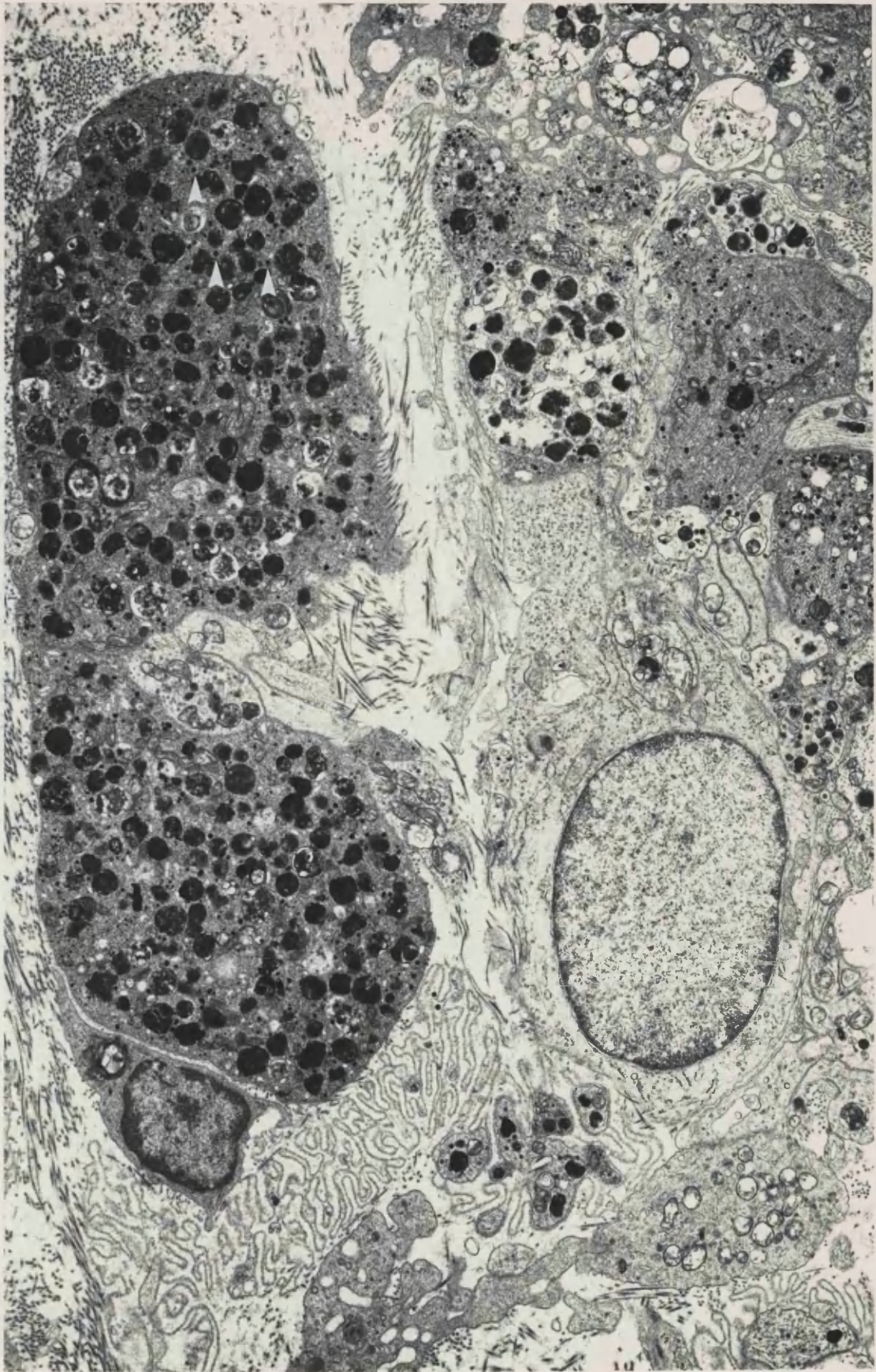
### 1.3 Unmyelinated Fibres

Unmyelinated fibres were often contained within large Schwann cell subunits, which contained many more profiles than in normal nerves, although some fibres were seen in isolation. Many of the axons in these groups were degenerating, appearing very swollen, and packed with abnormal organelles (Fig. 32). These organelles included large flocculent osmiophilic bodies, some of which had a lamellar appearance, probably representing axonal debris (Fig. 33). These dense lamellar bodies probably represent auto-phagosomes, containing debris from degenerate mitochondria and other organelles. Also seen were multi-vesicular bodies, clear vesicles of various sizes and very many dense-cored vesicles (Fig. 34). Irregularly oriented smooth walled tubules of smooth endoplasmic reticulum were abundant, and there was an abnormally large number of mitochondria, microtubules and neurofilaments. Some of the unmyelinated fibres had swollen to a giant size, the 'supergiant' axons of Morris et al (1972).

**FIGURE 33**

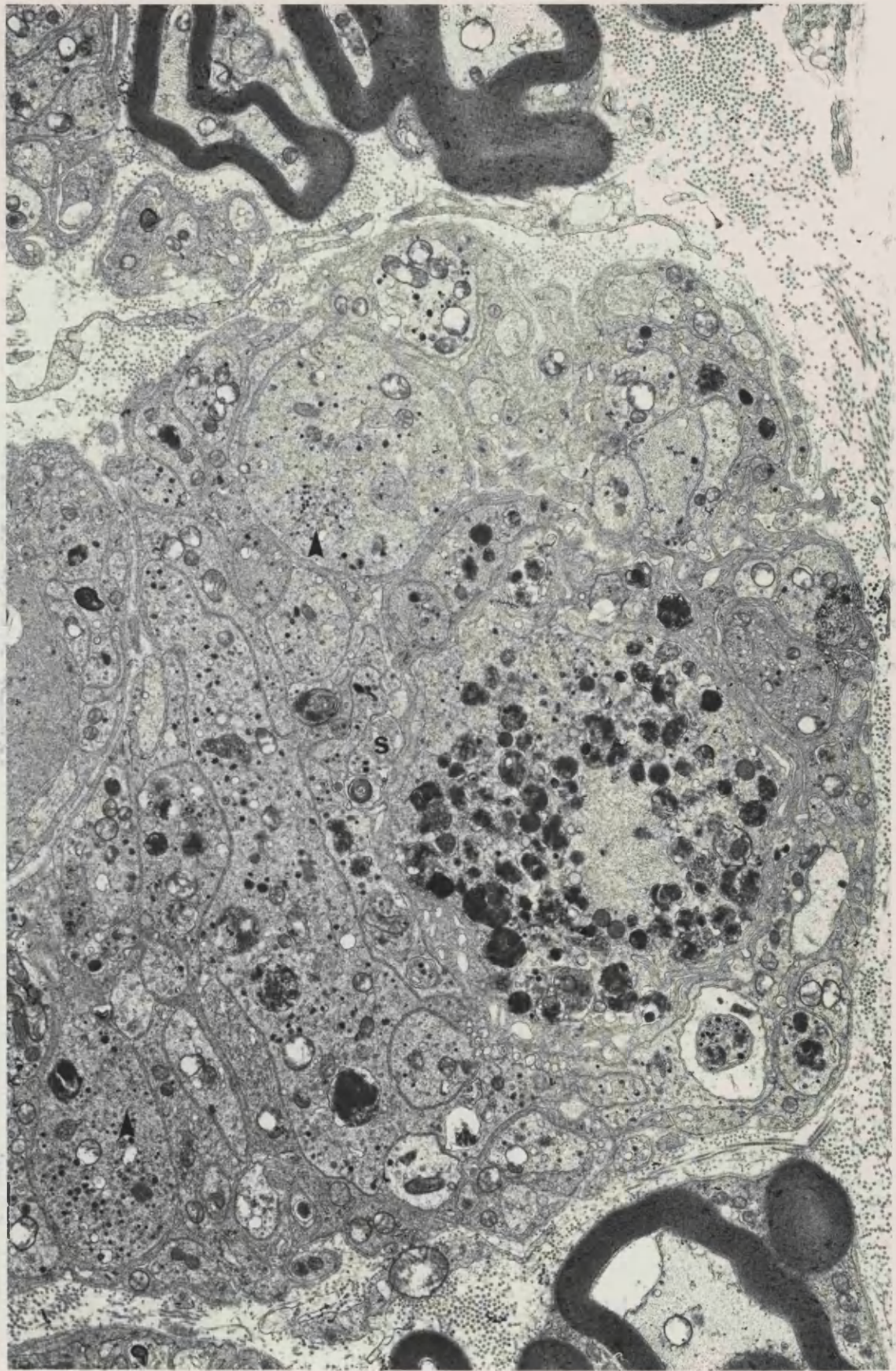
Neuroma 3 days following section, approximately 1.0mm from the distal tip. On the left are two swollen unmyelinated axons containing numerous large dense bodies of axonal debris and many 5-OH DA labelled dcv (arrows). Most of the axons in this area are sympathetic. An invaginated empty Schwann cell basal lamina can be seen in the bottom left-hand corner.

x 8 200



**FIGURE 34** 3 day neuroma, distal lmm. Most of the axons and sprouts (S) in this area contain labelled dcv and are therefore identifiable as sympathetic. Some axons also contain clusters of small clear vesicles (arrows).

x 10 100



Some of the unmyelinated axons of neuromas from animals treated with nialamide and 5-hydroxy dopamine contained very conspicuous highly electron-dense cored vesicles. There were two populations of dcv, distinguishable by size: small dcv 30-60 nm in diameter, and large dcv, 60-100nm in diameter (Fig. 34). The unmyelinated axons of control animals which were not pre-treated with nialamide and 5-hydroxy dopamine also contained dcv, but the core was only slightly electron dense in comparison with the 5-OH DA labelled vesicles (Fig. 35).

Many Schwann cell subunits contained one or more labelled profiles, about 50% of sub units containing labelled axons in the plane of section examined. Many subunits were seen to contain several sympathetic axons, and in some cases virtually all of the axons in a subunit were labelled (Fig. 34). Each axonal profile could contain many labelled dcv, as many as 101 being counted in one swollen unmyelinated axon. Labelled dcv were also seen in structures believed to represent new axonal sprouts, although there were usually fewer dcv in these small profiles.

Usually, the dense core was surrounded by a narrow halo, giving the appearance of a 'filled' vesicle. Occasionally the dense core did not fill the whole membrane, but was displaced to one side, giving an eccentrically cored dcv (Fig. 36). Sometimes the dcv were clustered together, but they were generally spread evenly throughout the cytoplasm.

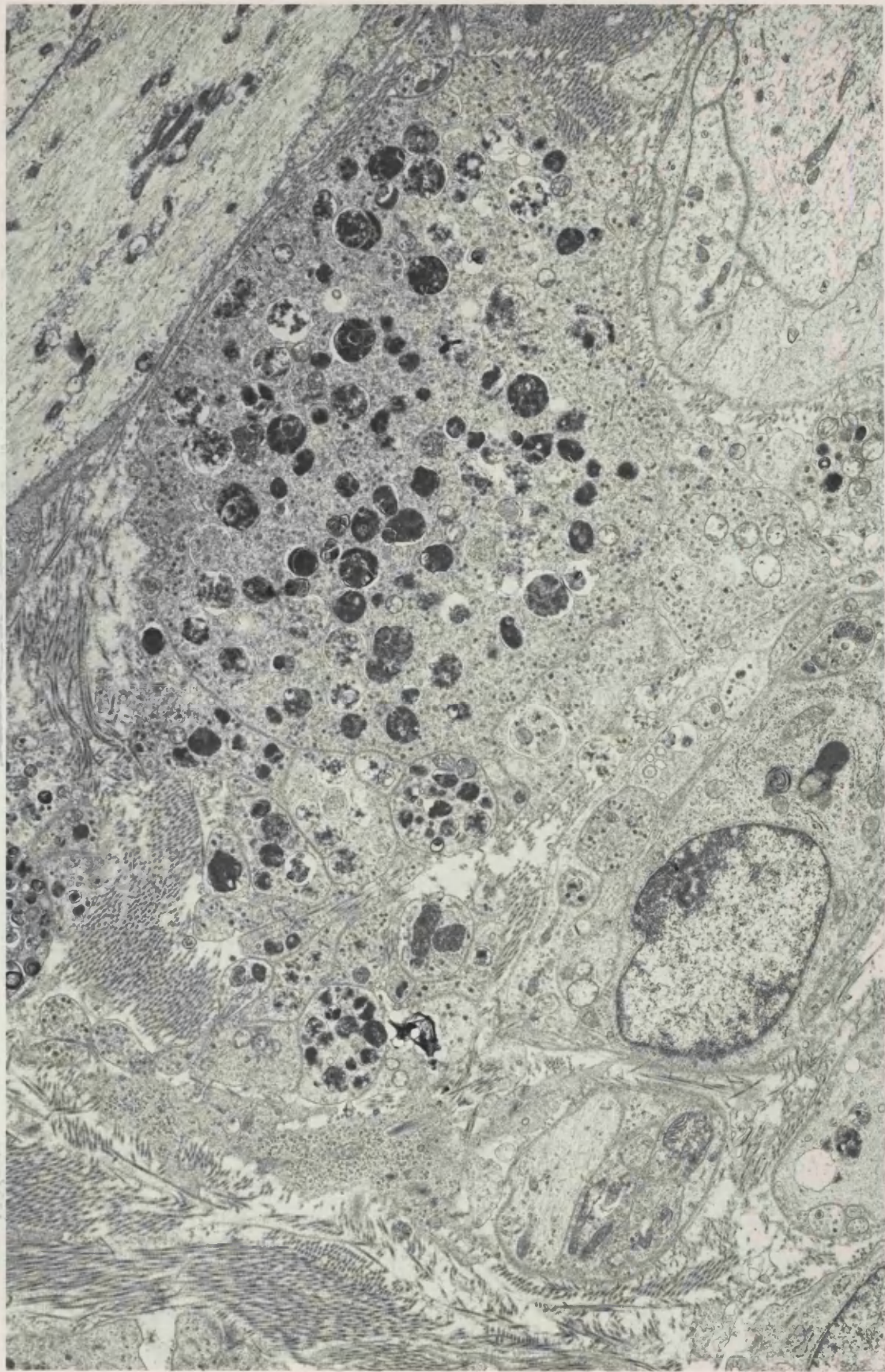
The vesicle population of sympathetic axons also included clear vesicles - i.e. without an electron dense core. These were usually of similar size to the dcv, but sometimes much larger. Occasionally these small clear vesicles were also seen in clusters (Fig. 34). Some of these vesicles had pale flocculent material in the centre, although this was not a truly dense core. Not all of the vesicles were spherical, there was also a population of clear elongated vesicles, which were probably small tubules of smooth endoplasmic reticulum. In normal nerve, smooth endoplasmic reticulum is oriented parallel to the axis of the nerve, but this orientation varies in sectioned nerve.

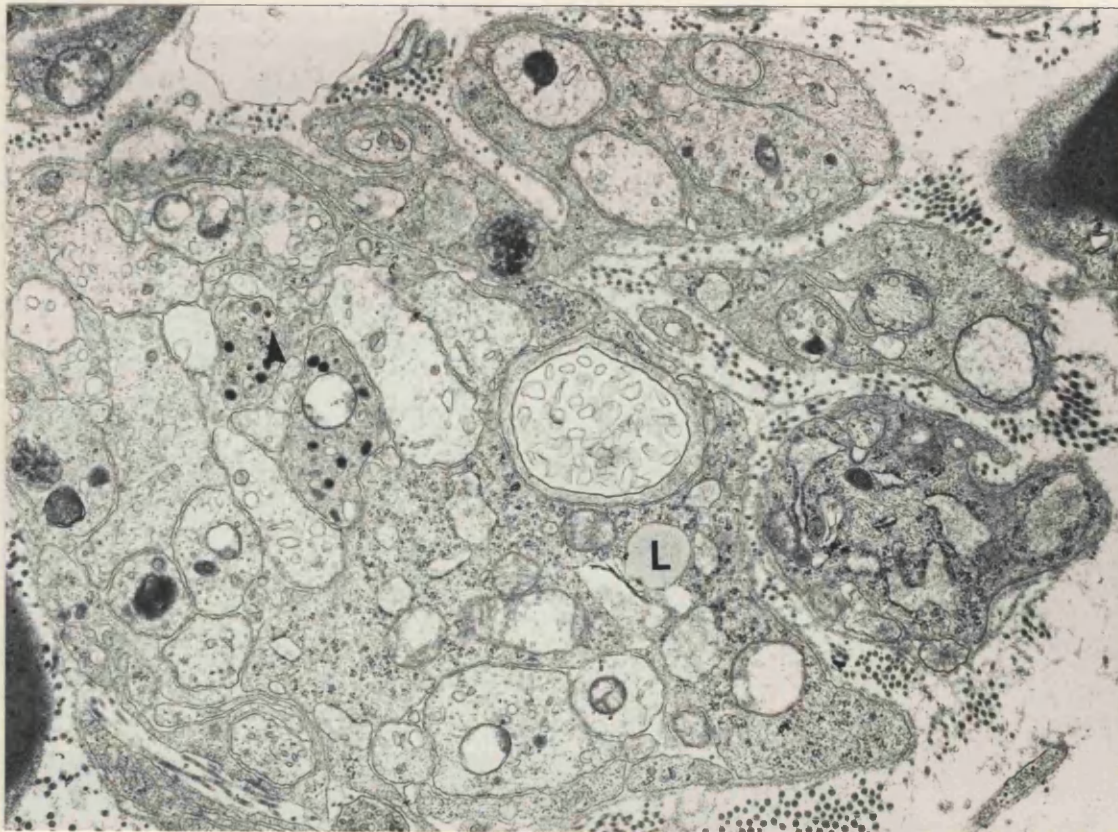
The axonal profiles within the Schwann cell subunits were widely ranging in size. A number of small round profiles could be identified



**FIGURE 35** 3 day neuromas, distal lmm. No 5-OH DA. The cores of the dev in unmyelinated axons are very much paler than those labelled with 5-OH DA.

x 9 200





**FIGURE 36** 3 day neuroma, distal 1mm. One of the numerous axonal sprouts, which is sympathetic, contains an eccentrically cored dcv (arrow). An opaque lipid droplet can be seen within Schwann cell cytoplasm (L).

x 16 000

with some confidence as axonal sprouts, but identification of larger profiles was more difficult (Fig. 37). Schwann cell proliferation was evident in neuromas at 3 days post section, and many profiles seen within the subunits were pockets of Schwann cell cytoplasm. These could be distinguished in some cases because Schwann cell cytoplasm was often darker in appearance than axoplasm, and the presence of rough endoplasmic reticulum was a distinguishing feature of these profiles. There was usually a more regular array of microtubules in axons, but there were still a number of profiles which could not be identified positively as axons.

Glycogen was more abundant in these neuromas than in normal nerves, often visible as large compact nodular granules. These granules were seen in the endoneurial cells of blood vessels and also in axonal cytoplasm. In one instance, glycogen was the main constituent of the axoplasm (Fig. 38).

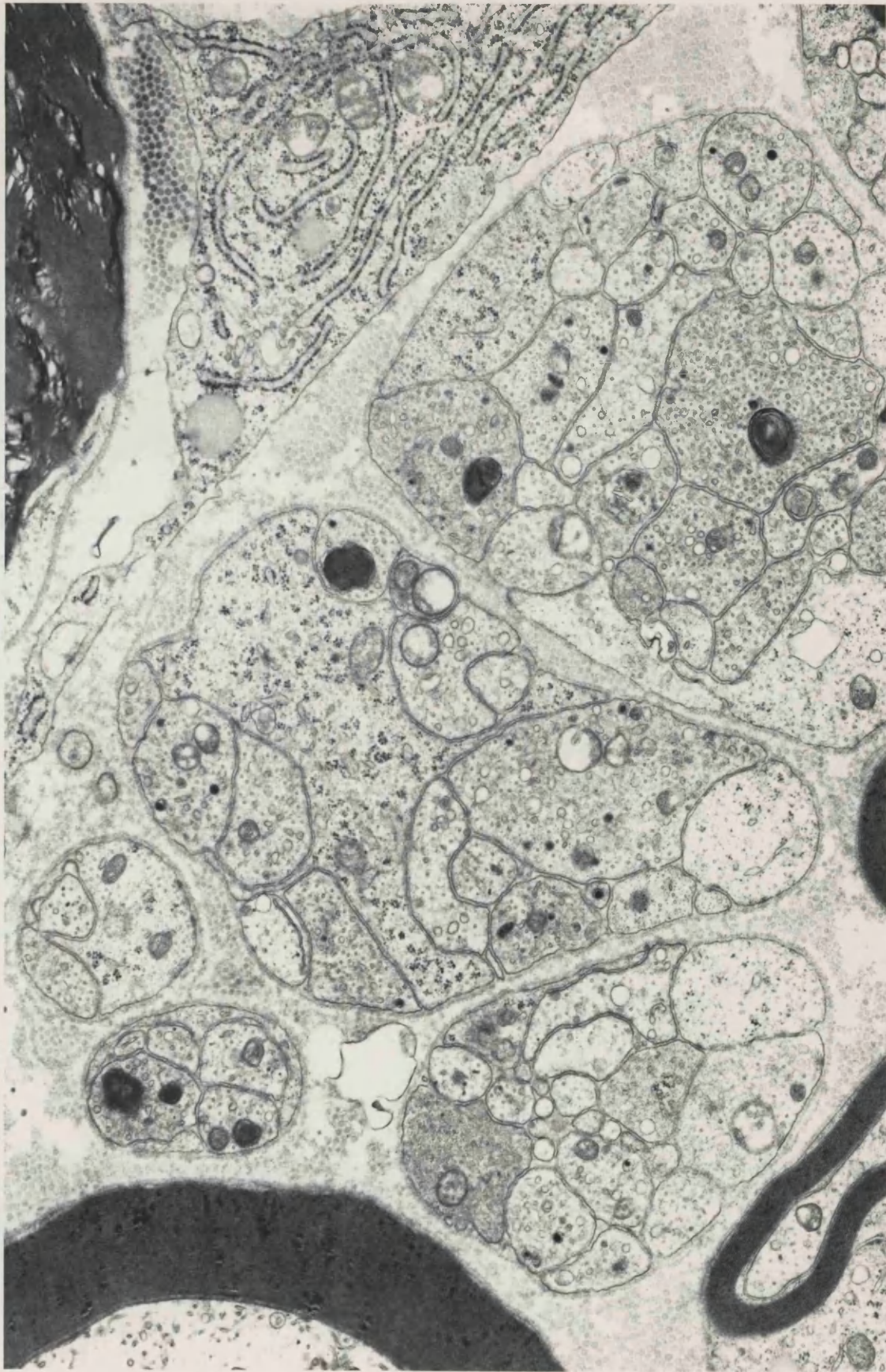
Usually, unmyelinated axons and sprouts existed in compact groups, but occasionally contained a large membrane-bound vacuole. These vacuoles were not completely empty but contained a sparse distribution of residual flocculent proteinaceous material. At very low magnifications these vacuoles with surrounding axons and sprouts appeared to be blood vessels, but at higher magnifications they were distinguishable as vacuoles, on the basis of a lack of endothelial cells (Fig. 39). Similar structures were often seen within the axon of degenerating myelinated fibres, or between the axon and myelin lamellae (Fig. 40).

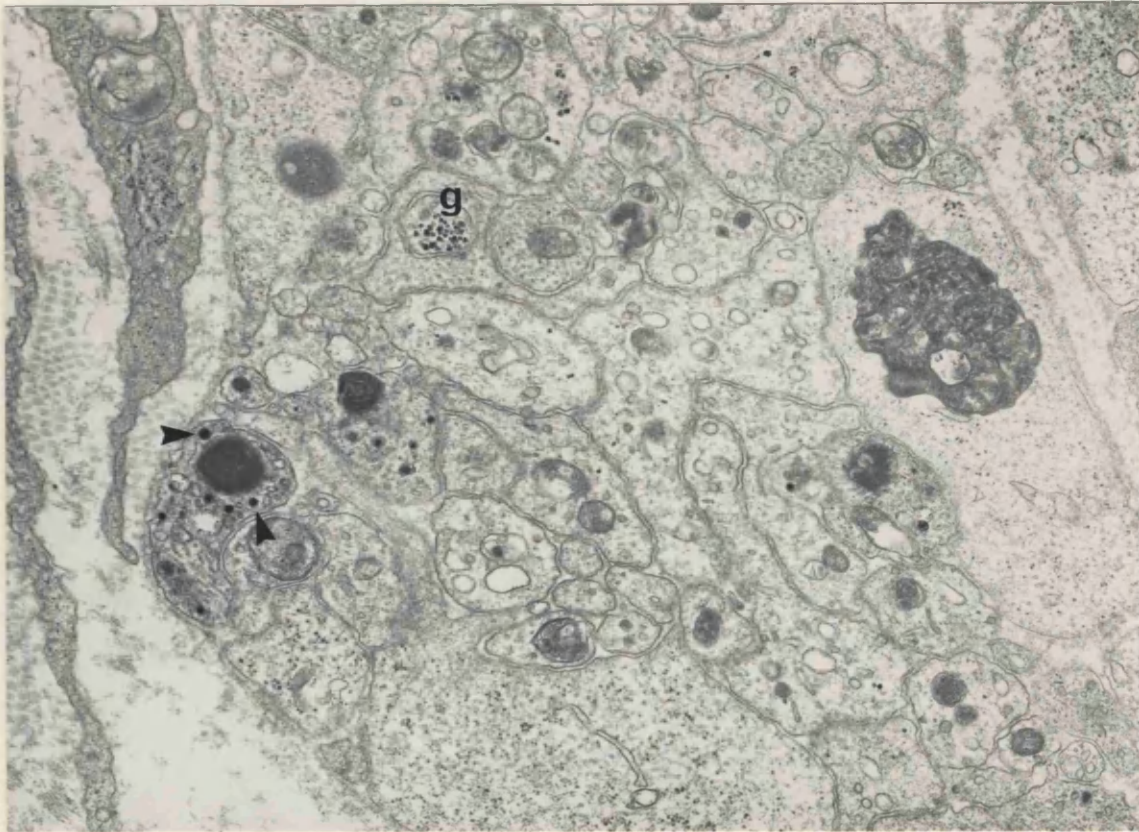
Occasionally, labelled sympathetic axon sprouts were seen within the Schwann cell basal lamina of myelinated fibres (Fig. 41). The myelinated fibres involved varied in size and degree of degeneration, some being intact (Figs. 42,43), whilst others were more degenerate (Figs. 44,45,30). The basal laminae of some large non-myelinated axons also contained sympathetic sprouts and these large axons may have represented demyelinated axons or myelinated axon sprouts, but it was difficult to identify these axons with certainty. Sometimes sympathetic sprouts were just within the outer edge of the basal lamina, and sometimes further into the group.

Quantitative counts indicated that the number of Schwann cell subunits which were labelled had increased to about 54% (Table 3). The

**FIGURE 37** 3 day neuroma, distal 1mm. An illustration of how Schwann cell subunit counts were made: 4 complete Schwann cell subunits can be seen, 2 of which contain labelled sympathetic axons, and were thus scored positively. The Schwann cell cytoplasm and axonal profiles in some of these subunits are very similar in appearance and it is difficult to differentiate between them.

x 20 500





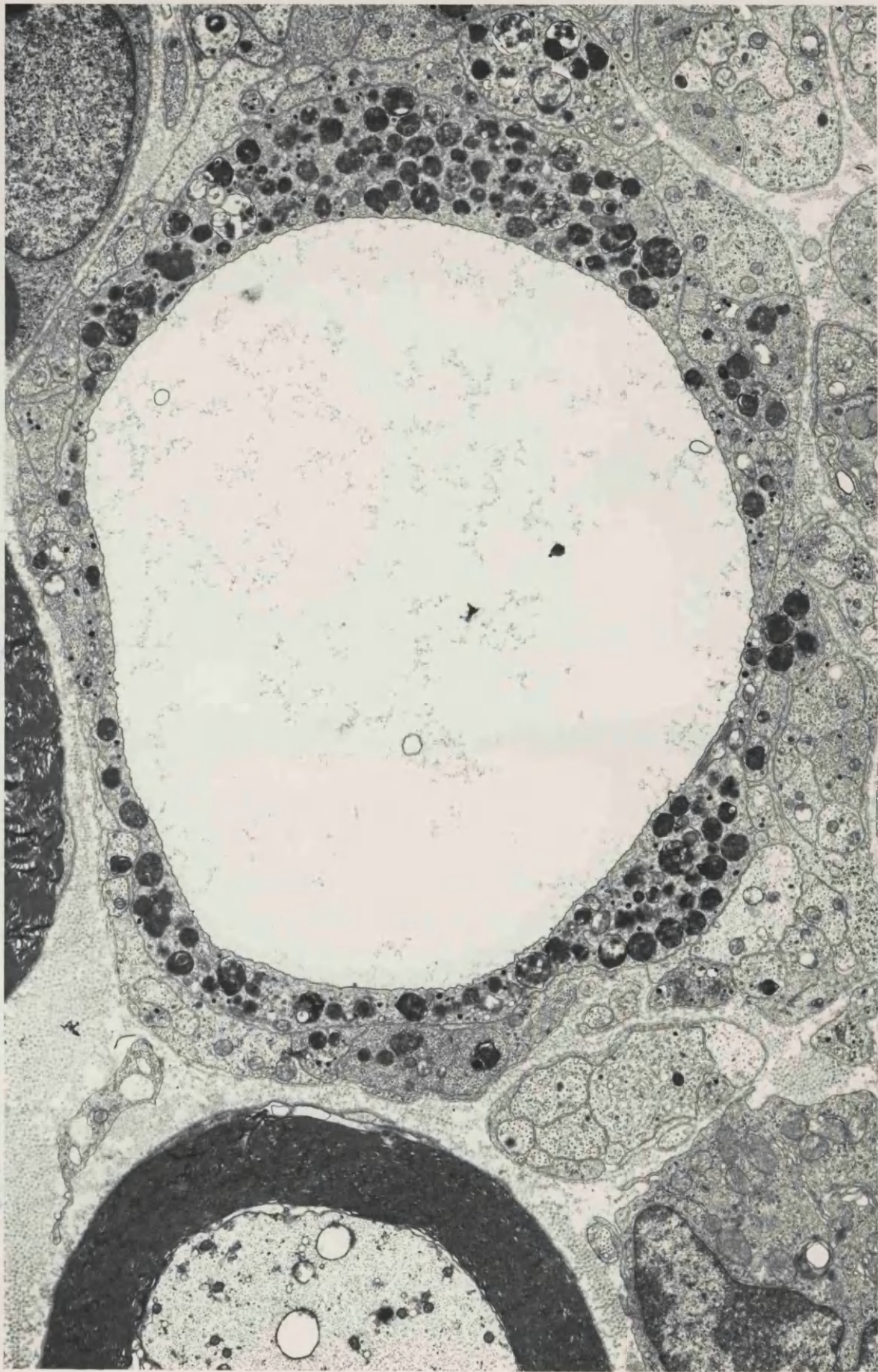
**FIGURE 38** 3 day neuroma, distal 1mm. Many small profiles are contained in this neuroma, most of which are axonal sprouts. Three sympathetic axons can be identified, the largest of these containing both small and large dcv (arrows). Another sprout contains principally glycogen (g).

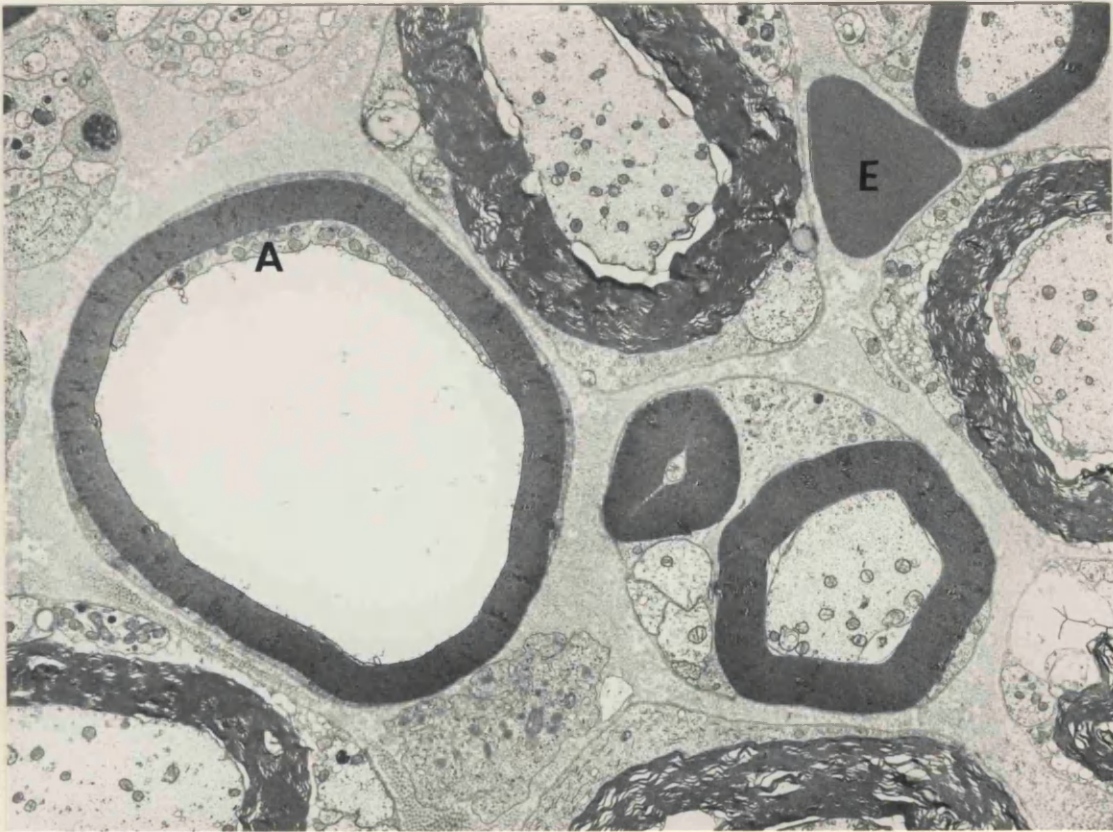
x 19 300

**FIGURE 39** 3 day neuroma, distal lmm. A large vacuole containing traces of flocculent protein material is enclosed within a single sympathetic axon which contains many dense bodies and dcv.

x 9 400





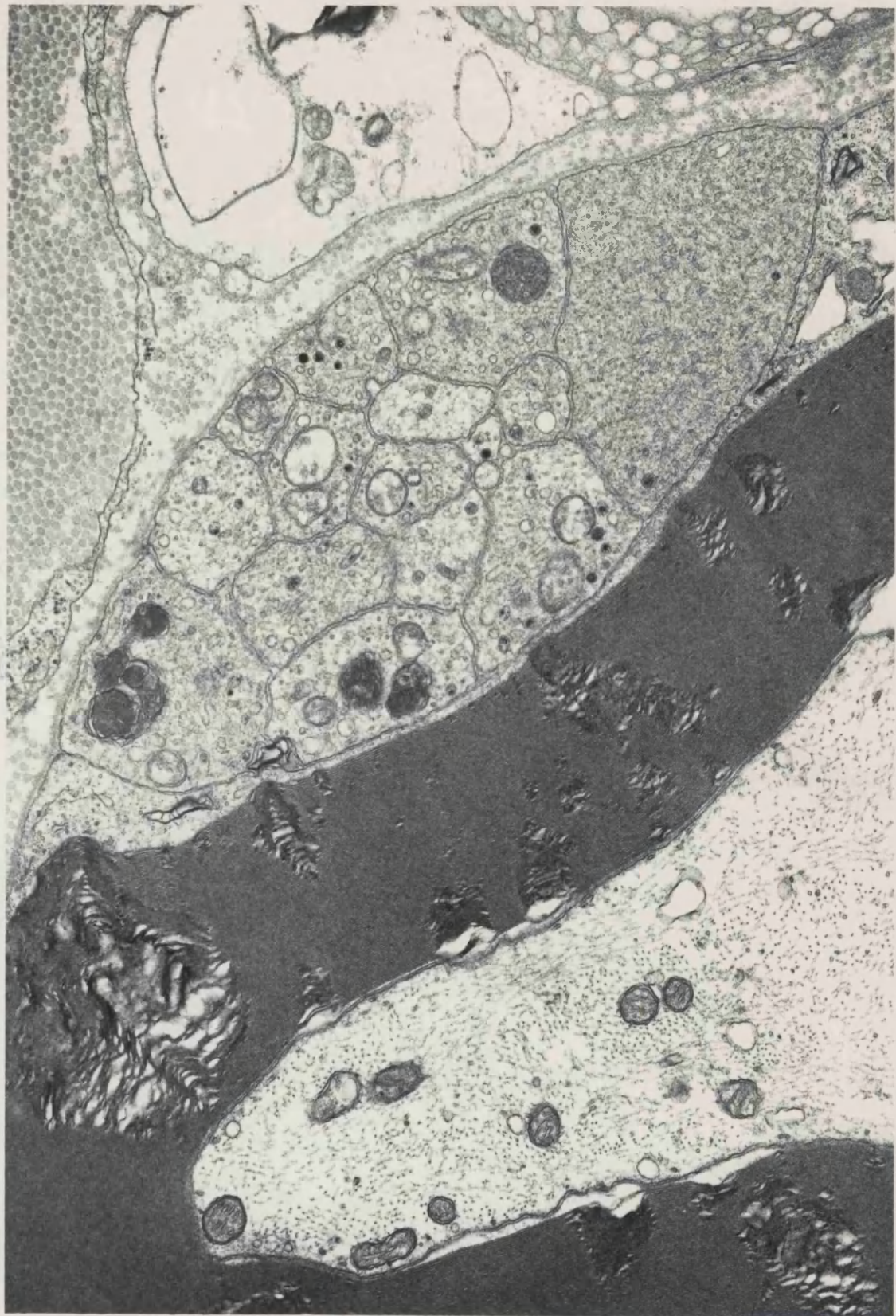


**FIGURE 40** 3 day neuroma, distal 1mm. The axon (A) of this fibre is seen as a thin strip to one side of the large vacuole which is between the myelin sheath and inner mesaxon. An erythrocyte (E) with a triangular profile is free within the endoneurium.

x 6 400

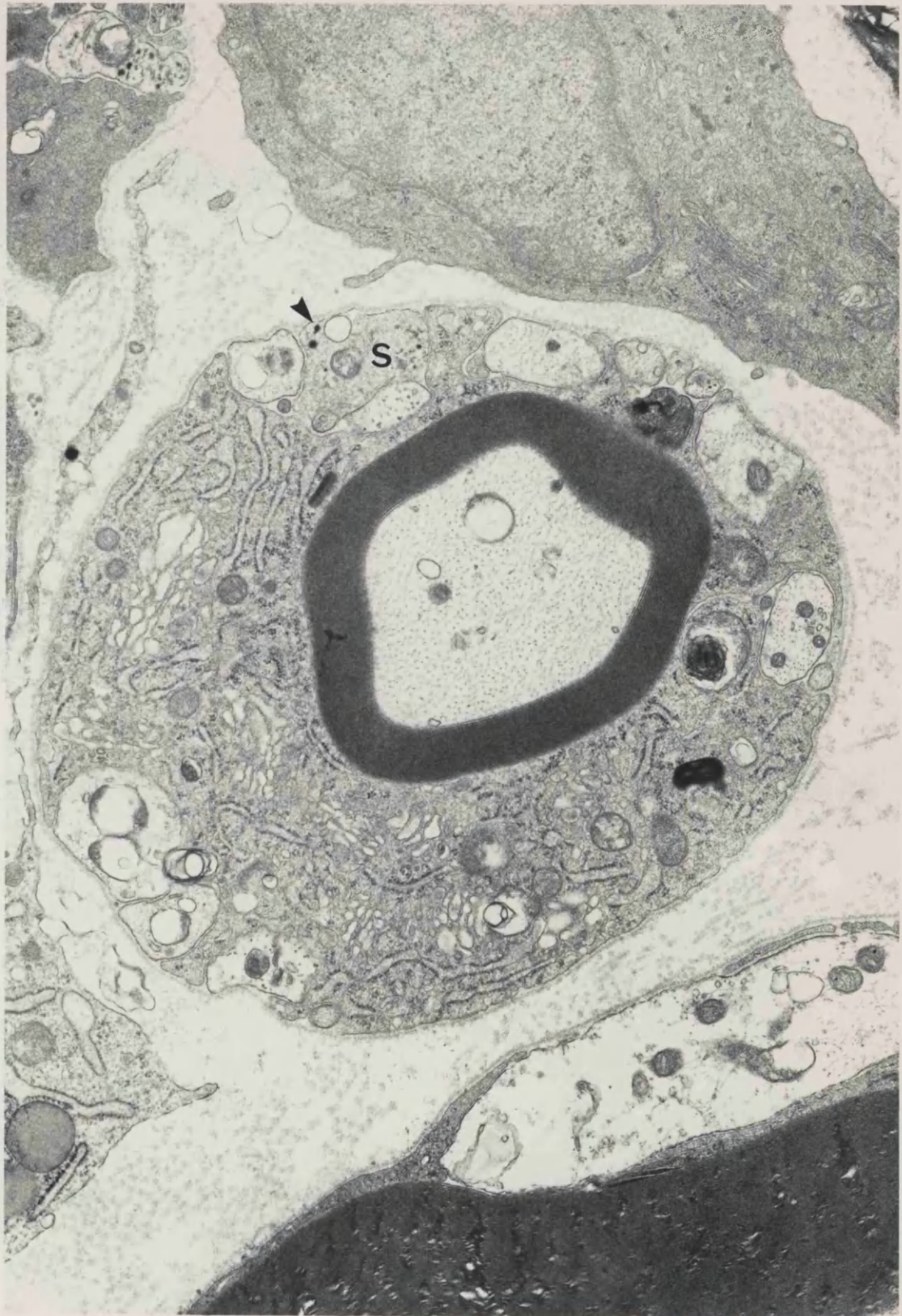
**FIGURE 41** 3 day neuroma, distal 1mm. 5 sympathetic axons are contained within the basal lamina of this intact myelinated fibre.

x 27 000



**FIGURE 42** 3 day neuroma, distal 1mm. Chromate fixed. Numerous sprouts, one of which is sympathetic (S), have penetrated beneath the basal lamina of this intact myelinated fibre. One of the dcv in the sympathetic axon has a slightly elongated appearance (arrow).

x 19 400

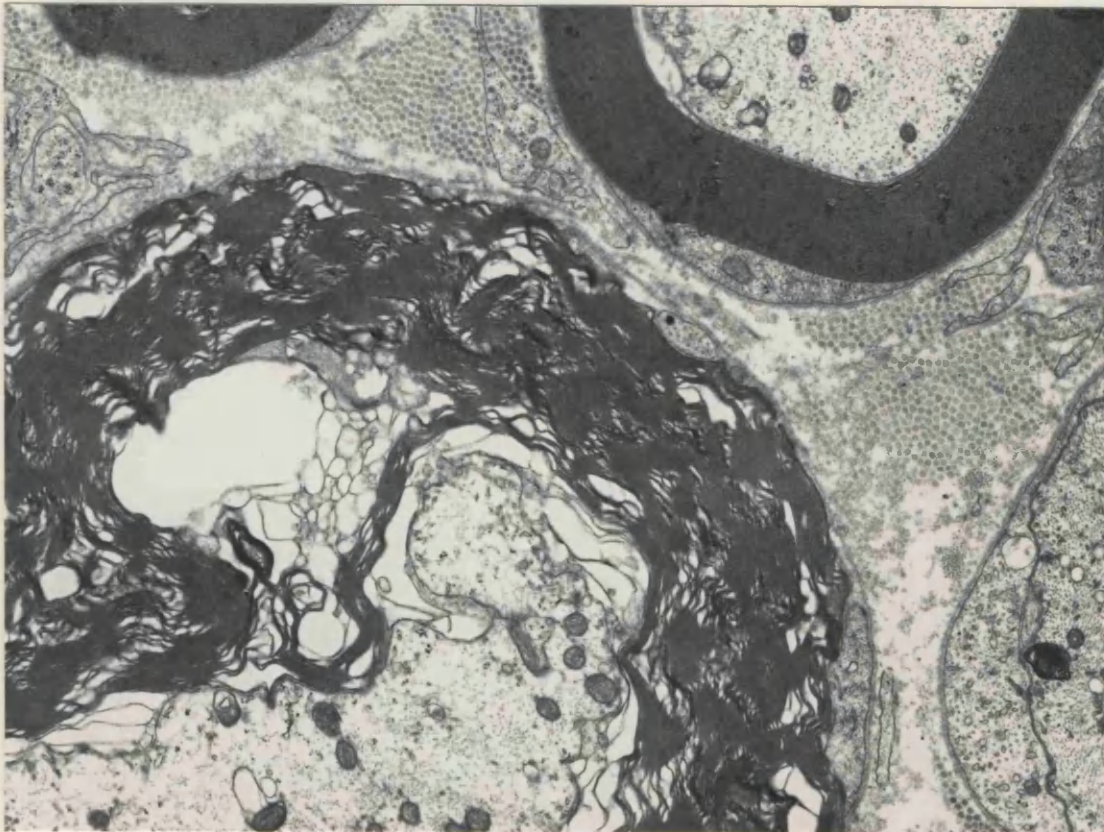
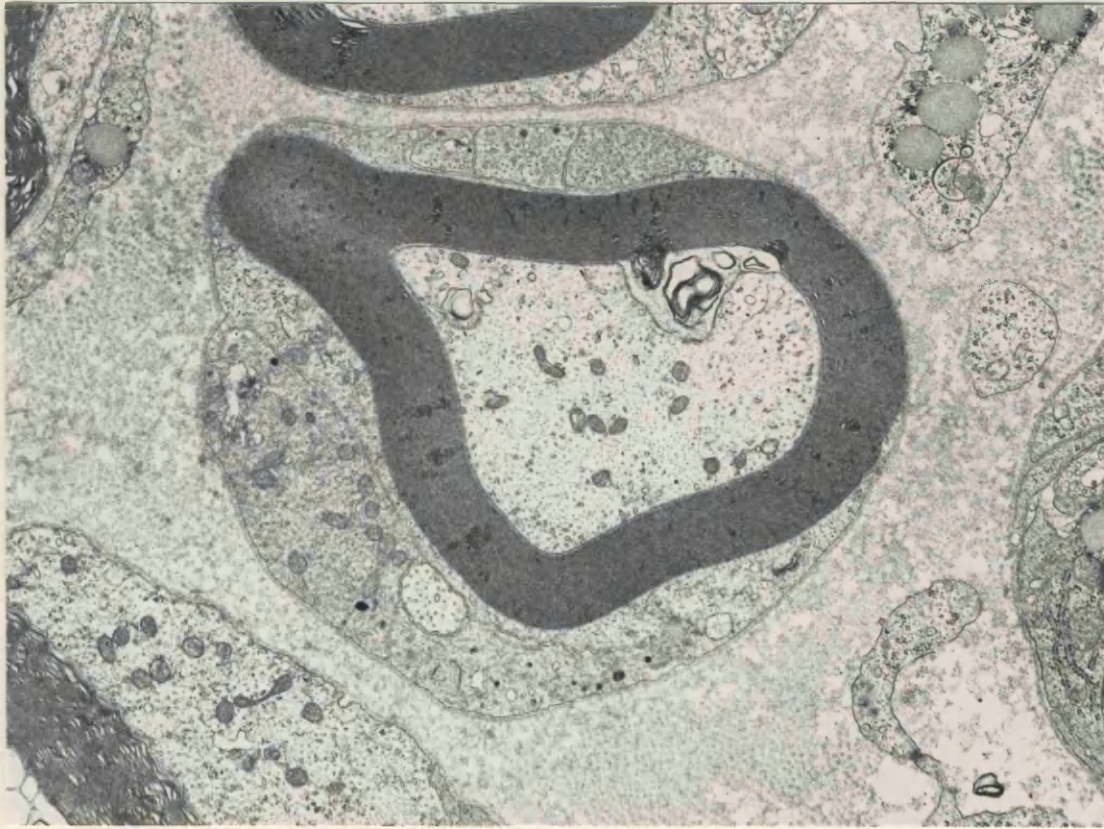

**FIGURE 43** 3 day neuroma, distal 1mm. 3 sympathetic axon sprouts have penetrated beneath the basal lamina of this intact myelinated fibre.

x 12 000

**FIGURE 44** 3 day neuroma, distal 1mm. A sympathetic sprout containing a single dcv is visible beneath the basal lamina of this degenerate myelinated fibre.

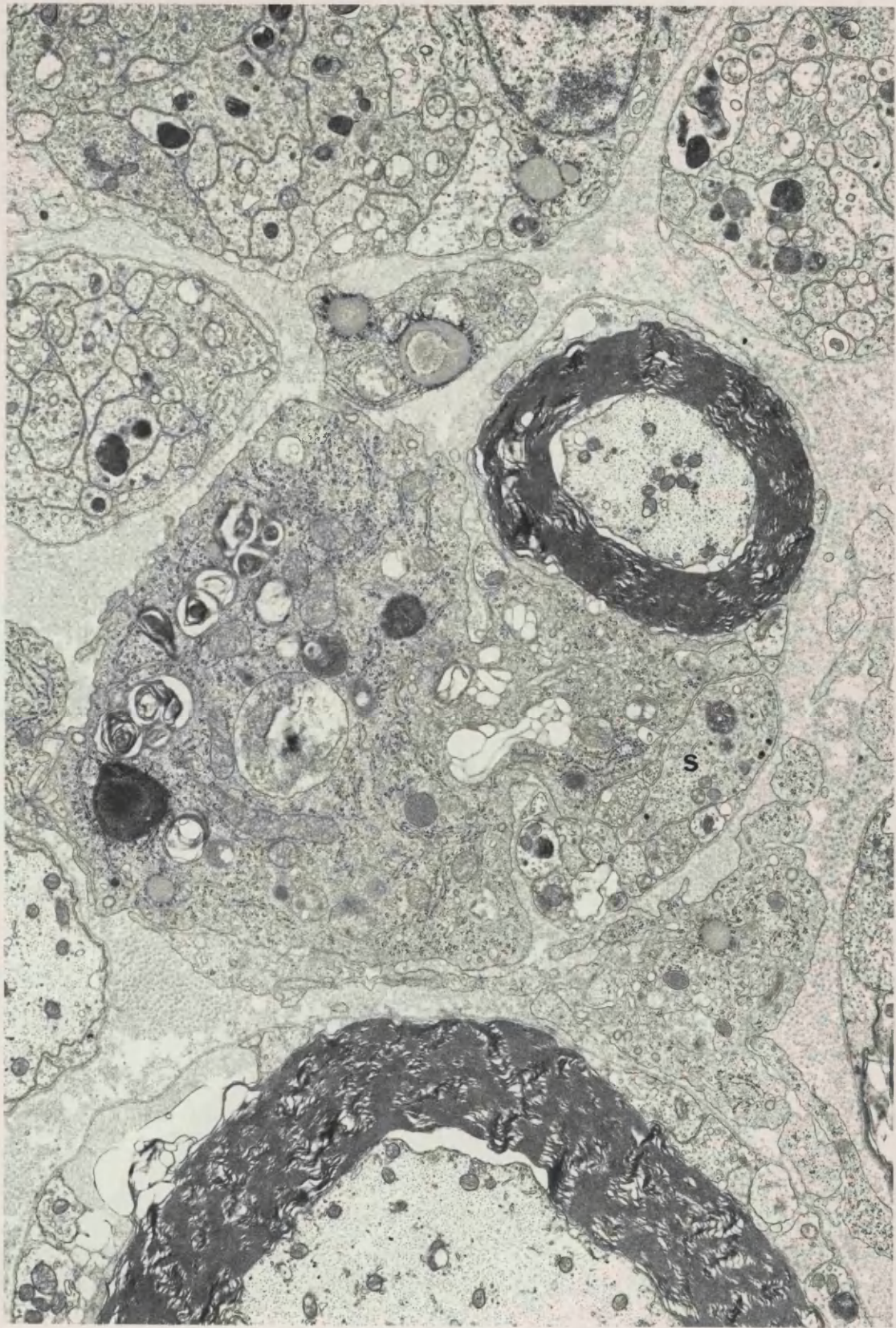
x 15 000





**FIGURE 45** 3 day neuroma, distal 1mm. The basal lamina of this myelinated fibre is surrounding a group of unmyelinated axons and sprouts, one of which is sympathetic (S).

x 11 000



number of subunits counted within 12 grid squares had decreased by about one third, probably due to the increased size of each subunit and possibly also to degeneration of some axons.

5-OH DA labelled axons could be seen in association with many blood vessels, correlating with the fluorescent axons seen around blood vessels in the light microscope (Fig. 46). Labelled axons were also seen in the perineurium (Fig. 47).

## 2. 7 DAYS POST - SECTION

### 2.1 Non-axonal structures

Neuromatous tissue at the distal tip of the proximal stump of the sectioned nerve had a similar appearance to that of neuromas 3 days after nerve section, with some notable differences. The perineurium appeared to be thicker, and more laminated by 7 days after section. There was also a number of small blood vessels within the perineurium, many still containing blood cells, in addition to free erythrocytes within the perineurial collagen. Large lipid droplets were also seen within the epineurium. The layers in the perineurium were made up of collagen, mostly running parallel to the axis of the nerve, but some fibrils had a transverse orientation. Dispersed throughout the collagen were numerous fibroblasts, the processes of which were packed with rough endoplasmic reticulum, indicating that they were actively engaged in the synthesis of collagen. The processes of these fibroblasts were distinguishable from those of Schwann cells since they were lacking a basement membrane. Many of the outer membranes of these fibroblasts were packed with pinocytotic vesicles. Mast cells were also very numerous in the perineurium, and smaller numbers were seen within the nerve bundle itself. Many macrophages were present in the perineurium, sometimes containing cellular debris from degenerate axons. The collagen which comprised the endoneurium was not as densely packed as that of the perineurium, and the fibrils were much smaller in diameter. There was often flocculent proteinaceous material between the fibrils themselves, and within the gaps between the collagen clumps.

### 2.2 Myelinated Fibres

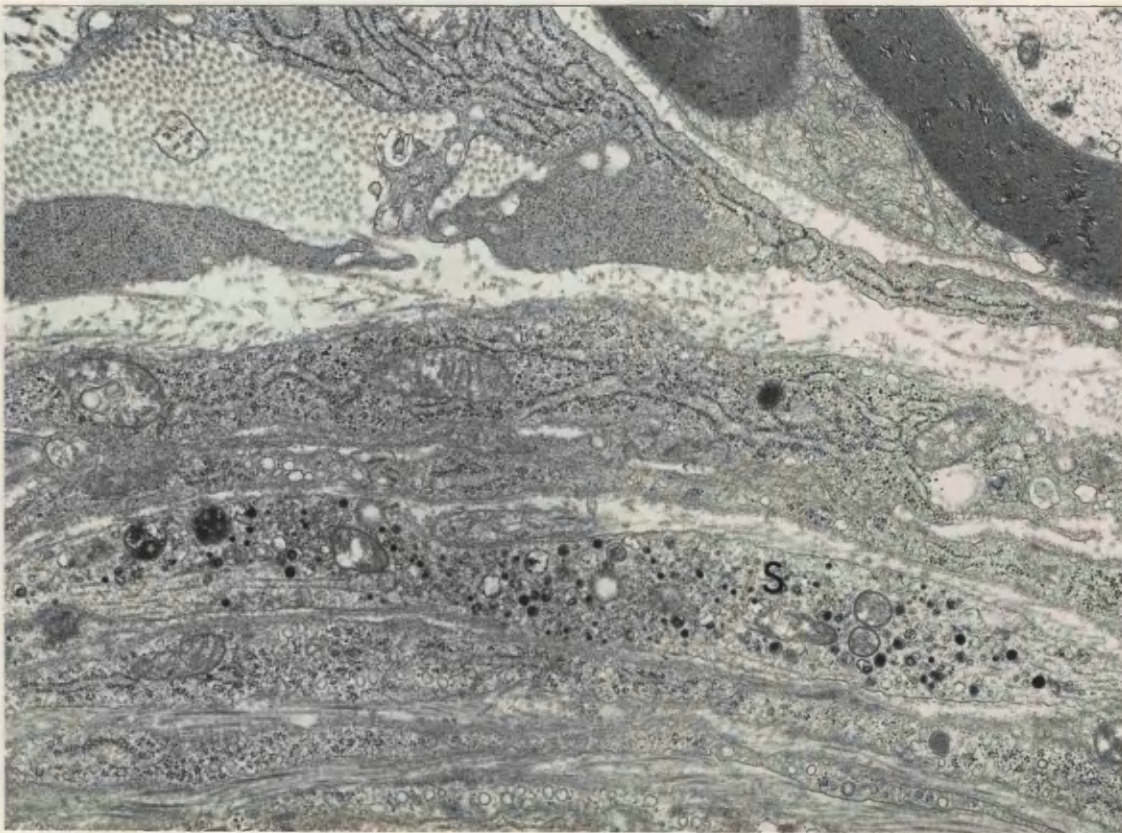
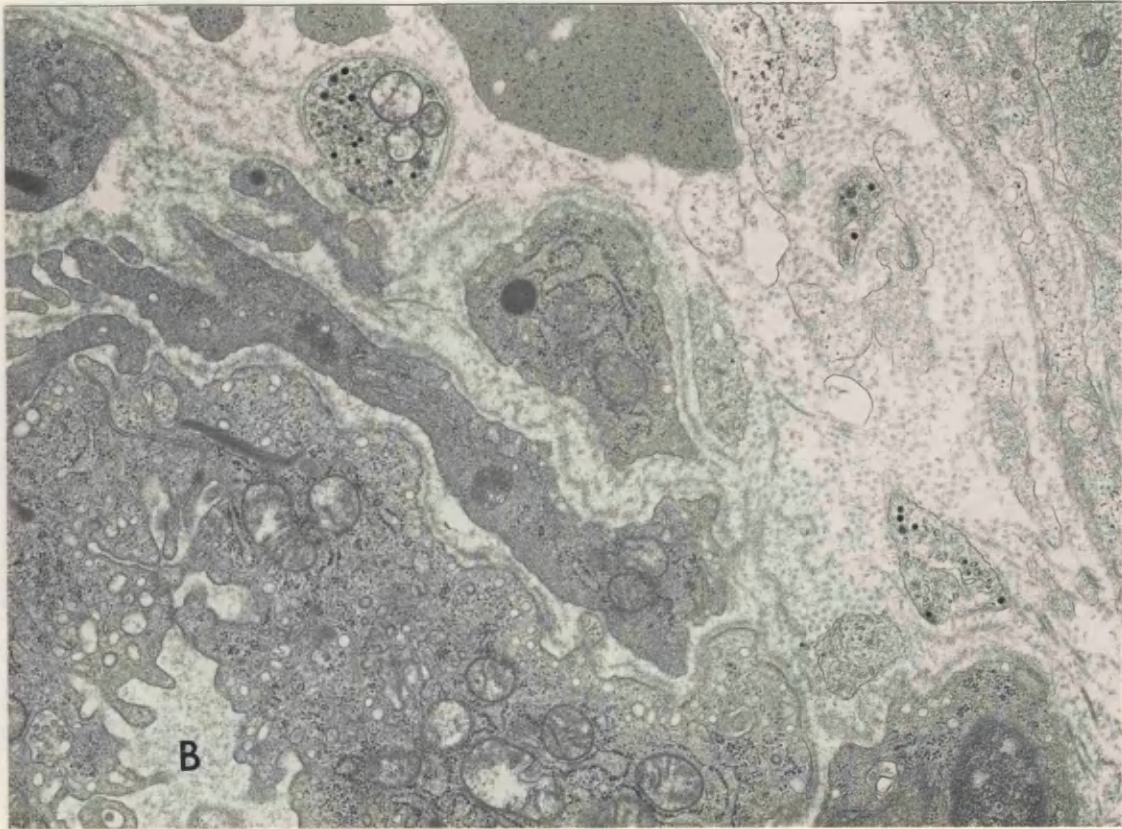
Generally the orientation of nerve fibres was maintained, so that most fibres appeared in transverse section. The most distal part of the

**FIGURE 46** 3 day neuroma, distal 1mm. 3 Sympathetic axons are close to the endothelium of a small blood vessel (B). One is packed with both dense-cored and clear vesicles.

x 16 500

**FIGURE 47** 3 day neuroma, distal 1mm. A sympathetic axon (S), in longitudinal section, is sited between fibroblasts and perineurial cells in the perineurium.

x 16 000



perpendicular to the plane of section, but generally about oriented

neuromatous outgrowth consisted primarily of a few very thinly myelinated regenerating axons in a background of inflammatory cells (Fig. 48). In the terminal 1 mm of the proximal stump, almost all of the myelinated fibres were in a stage of degeneration, although this varied a great deal between fibres (Fig. 49). Some myelinated fibres still showed very little degeneration, the only noticeable change being vacuolation of the myelin lamellae, but many were in an advanced state, the axon having degenerated completely, with just whorls of myelin debris and droplets of phospholipid breakdown products left within the dark macrophage or Schwann cell cytoplasm. The axon of some fibres was left intact, but they had become completely demyelinated. The residual axon was often intact, showing no signs of degeneration, and probably awaiting remyelination by the Schwann cell (Fig. 50). Such axons were often in a group with other axonal sprouts and profiles of Schwann cell cytoplasm, and the group often contained numerous Schwann cell nuclei. The majority of myelinated fibres had axonal sprouts growing beneath the basement membrane, even if the myelinated fibre itself was completely intact.

The basal lamina of many fibres was loosened and folded. Many empty, tightly folded, flattened Schwann cell tubes were seen in the endoneurium (Fig. 51), and many macrophages containing cellular debris were still present.

By 7 days after nerve section, there was evidence of remyelination. A few non-myelinated axons were seen wrapped with one or two lamellae, and a few other axons had up to 10 myelin lamellae.

### 2.3 Unmyelinated Fibres

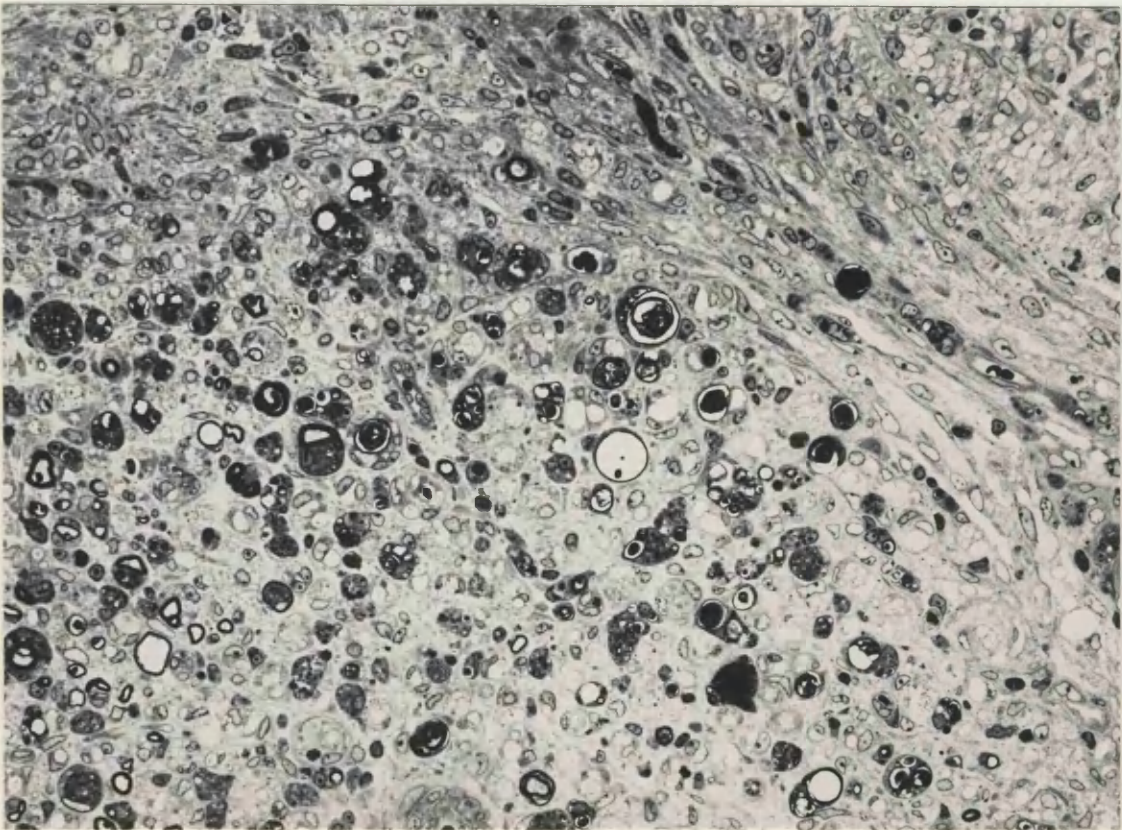
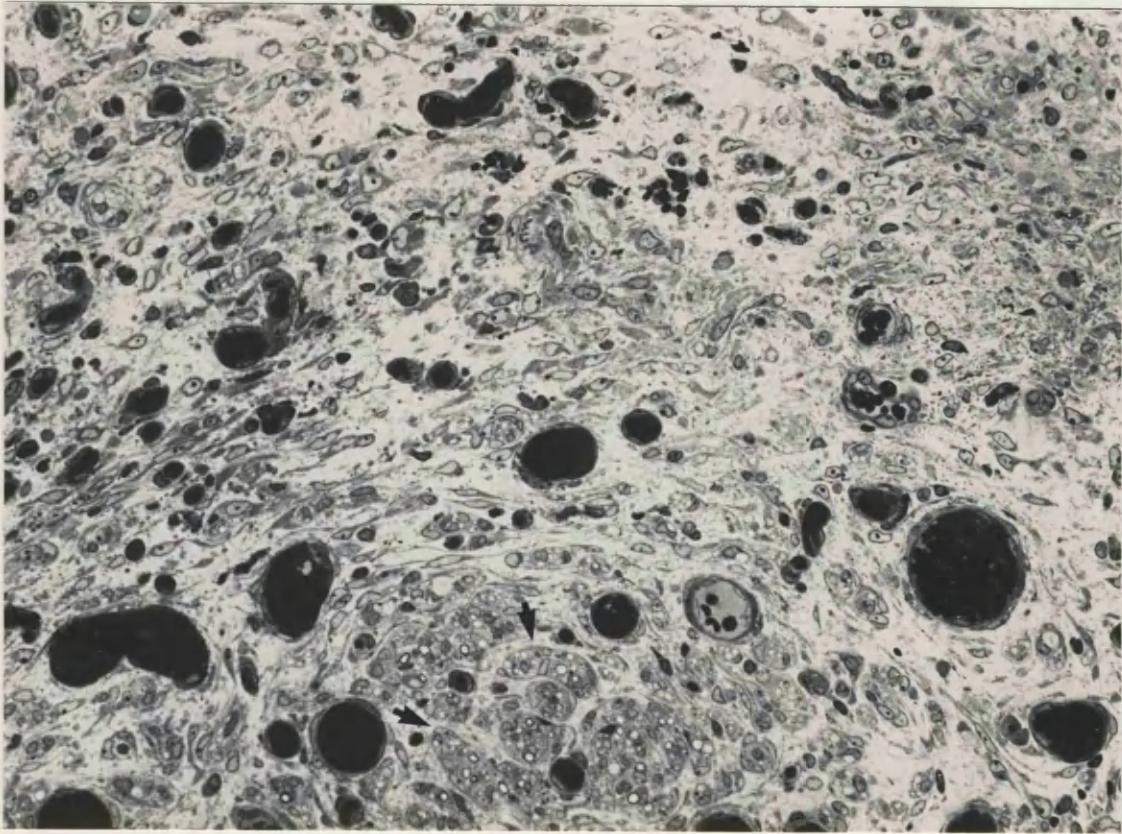
Small groups of axonal sprouts could be seen within the layers of perineurium, some of which could be identified as sympathetic (Fig. 52). Similar numbers of sprouts were seen to those in neuromas 3 days post-section (Fig. 53). Many Schwann cell sub-units were seen to contain large numbers of sprouts, as many as 100 in some cases, although not all of these profiles could be identified as sprouts with certainty, and many may have been Schwann cell cytoplasmic processes. Some larger axons were probably derived from myelinated axons, possibly being either demyelinated axons awaiting remyelination, or the sprouts of myelinated fibres. A few sympathetic sprouts were seen growing perpendicular to the plane of section, but generally sprouts appeared

**FIGURE 48.** The distal tip of a neuroma one week after nerve section. Numerous small blood vessels packed with blood cells can be seen, many tiny regenerating fascicles of axonal sprouts (arrows) and inflammatory cells are also visible. Glutaraldehyde / Resin / Toluidine blue.

x 170

**FIGURE 49.** The distal tip of a neuroma one week after nerve section, 0.5mm further proximal than Fig. 48. Inflammatory cells, blood vessels, degenerating myelinated axons and swollen unmyelinated axons are present at the distal tip. Glutaraldehyde / Resin / Toluidine blue.

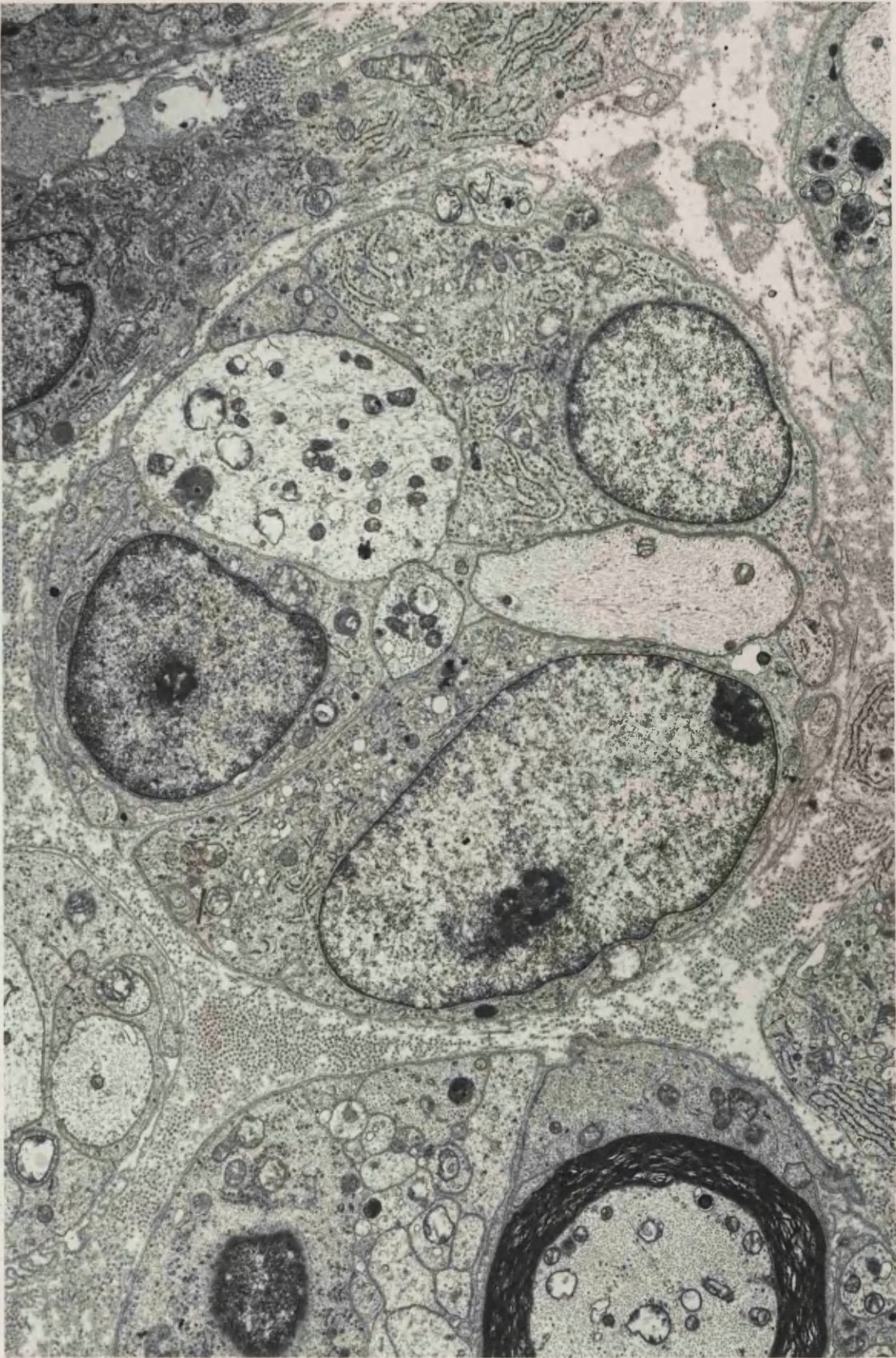
x 135





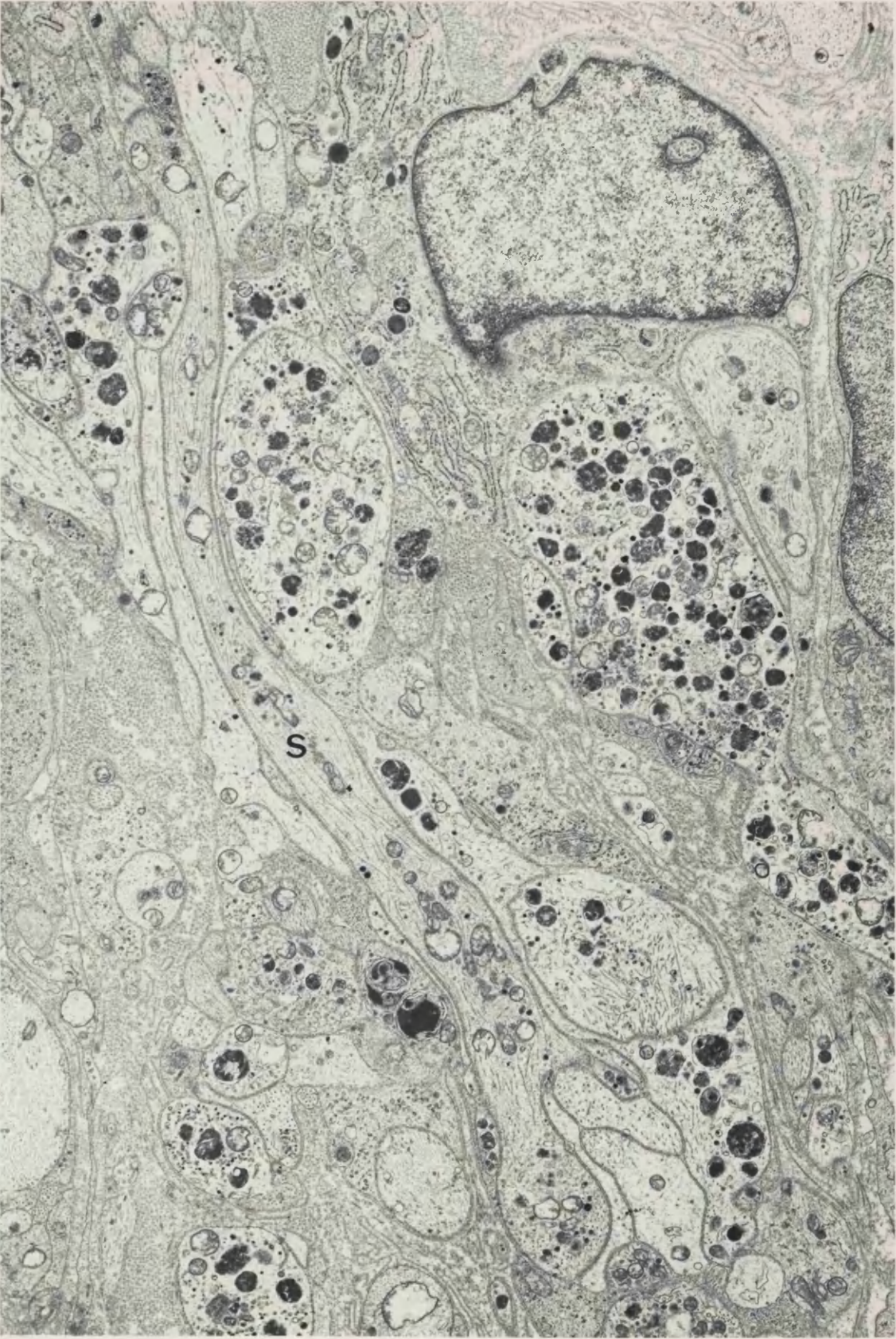
**FIGURE 50** 7 day section, distal 1mm. Several Schwann cells have proliferated within this subunit and three nuclei are visible. 1 small and 2 large axons are also present, and one of the large axons may become myelinated.

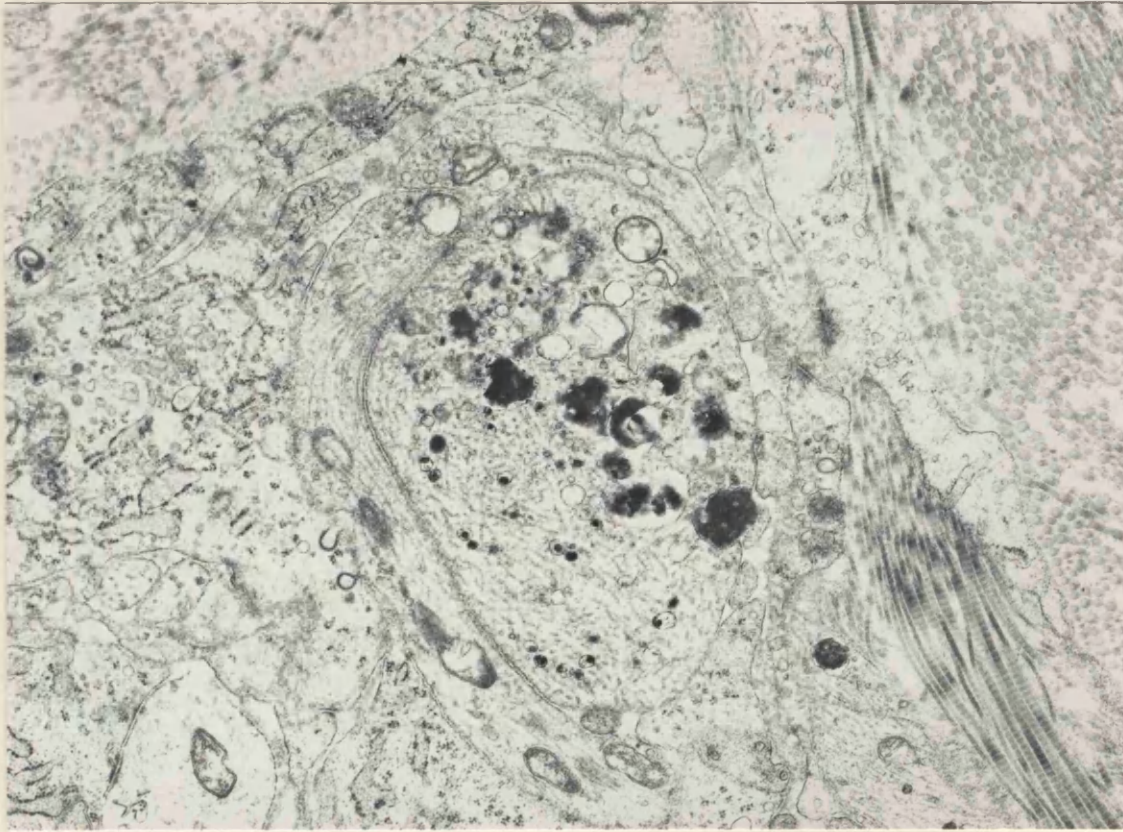
x 9 500



**FIGURE 51** 7 day neuroma, distal 1mm. This transversely sectioned area contains several obliquely sectioned axons, most notably one sympathetic axon (S). This type of orientation may correspond to the perpendicular fluorescent axons which are commonly seen by light microscopy in neuromas 7 days after nerve section. Empty, flattened Schwann cell tubes are present, the remains of degenerated axons.

x 8 500



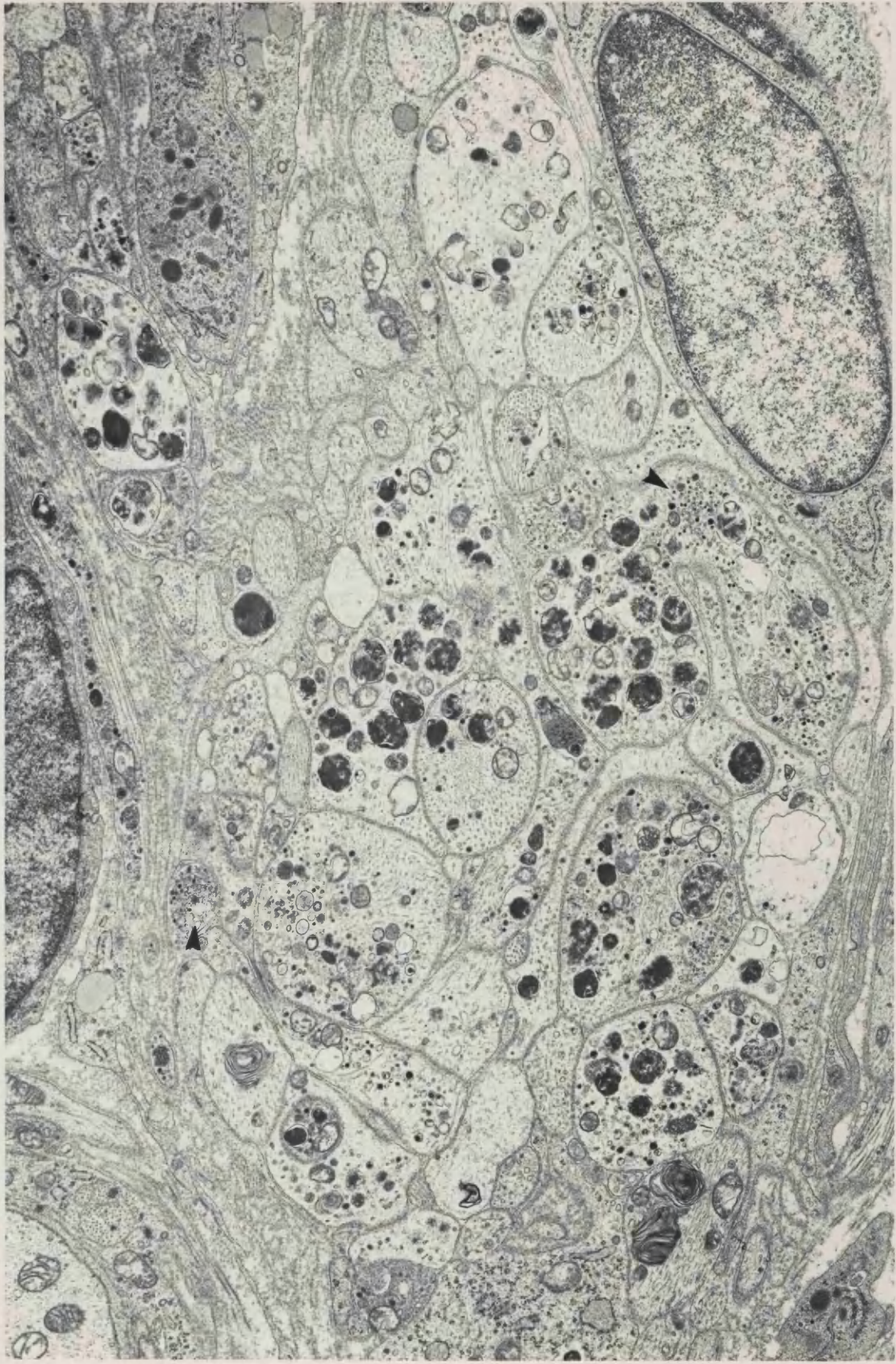


**FIGURE 52** 7 day section, distal 1mm. This sympathetic axon in the perineurium, contains severally eccentrically cored dcv. Closely apposed is another axon sprout.

x 15 000

**FIGURE 53** 7 day neuroma, distal 1mm. The appearance of this tissue is very similar to that of a 3 day neuroma. Many of the axons are identifiable as sympathetic. Several clusters of clear and dcv are visible (arrows).

x 10 900



to be growing in parallel with the axis of the nerve trunk. These sprouts which appeared in longitudinal section may correlate with the 'perpendicular' fluorescent sprouts seen in the light microscope 3 and 7 days after nerve section (Fig. 51).

No 'giant' swollen axons, packed with organelles, were seen by 7 days after section, but there were still some large swollen axons, containing large dense osmiophilic bodies. The majority of unmyelinated axons and sprouts had a more normal distribution of cellular organelles, although these were often more numerous than in normal tissue. Lipid droplets were a common constituent of Schwann cell cytoplasm.

Many labelled dcv were seen within axons, although slightly fewer sympathetic axons could be identified than in neuromas at 3 days post-section. A large number of unmyelinated axons were seen to contain accumulations of dcv, especially toward the distal tip of the neuroma. However, even the largest accumulations generally contained fewer dcv than the accumulations seen 3 days after nerve section (Figs. 51 and 53). There were no Schwann cell subunits in which all profiles appeared to be sympathetic i.e. contain labelled dcv. Generally the largest numbers of dcv were seen within axons which also contained large dense osmiophilic lamellar bodies. Labelled dcv were often seen accumulating with clear vesicles of similar size. Many dcv with eccentrically placed dense cores were seen. Numerous clear vesicles, both round and elongated were also seen. Some of these vesicles were probably tubules of smooth endoplasmic reticulum, as seen in neuromas 3 days after section. Large numbers of multi-vesicular bodies, consisting of circular membranes enclosing very small clear vesicles were still present. Many of the small axonal sprouts contained large membrane bound vacuoles, some of which could have been degenerate mitochondria.

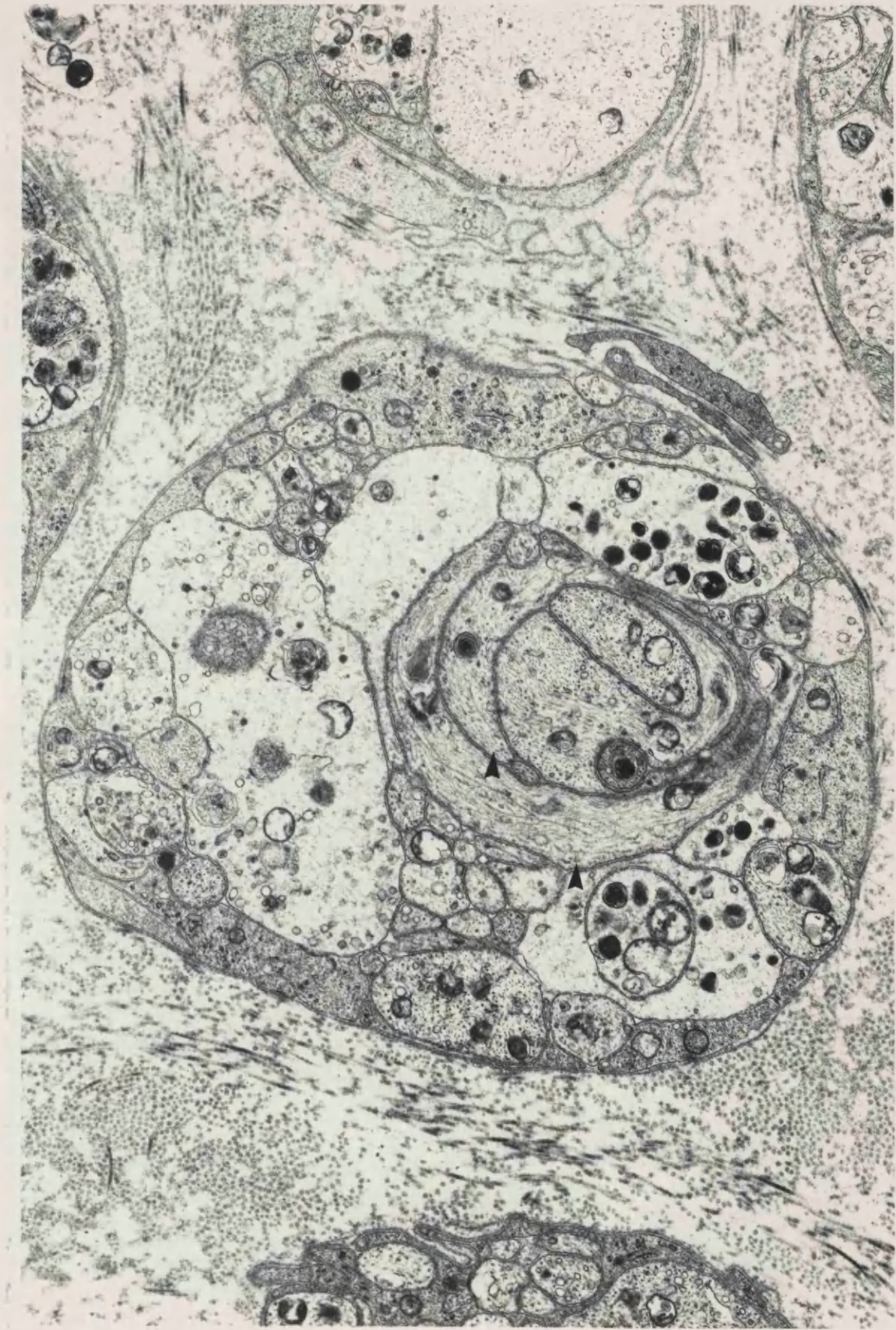
Often Schwann cell bands of flattened, twisted processes were seen, typical of the degeneration of unmyelinated axons (Fig. 54) and some Schwann cell subunits were surrounded by loosened basal laminae (Fig. 55). Such conformations were not seen 3 days after nerve section.

Sympathetic axon sprouts were not seen within the basement membranes of myelinated fibres 7 days after nerve section, but labelled dcv were fewer in number by this time, so less sympathetic axons were identifiable.



**FIGURE 54** 7 day section, distal 1mm. This Schwann cell subunit contains many axons and sprouts, and towards the centre, several flattened twisted profiles of Schwann cell cytoplasm (arrows).

x 12 900

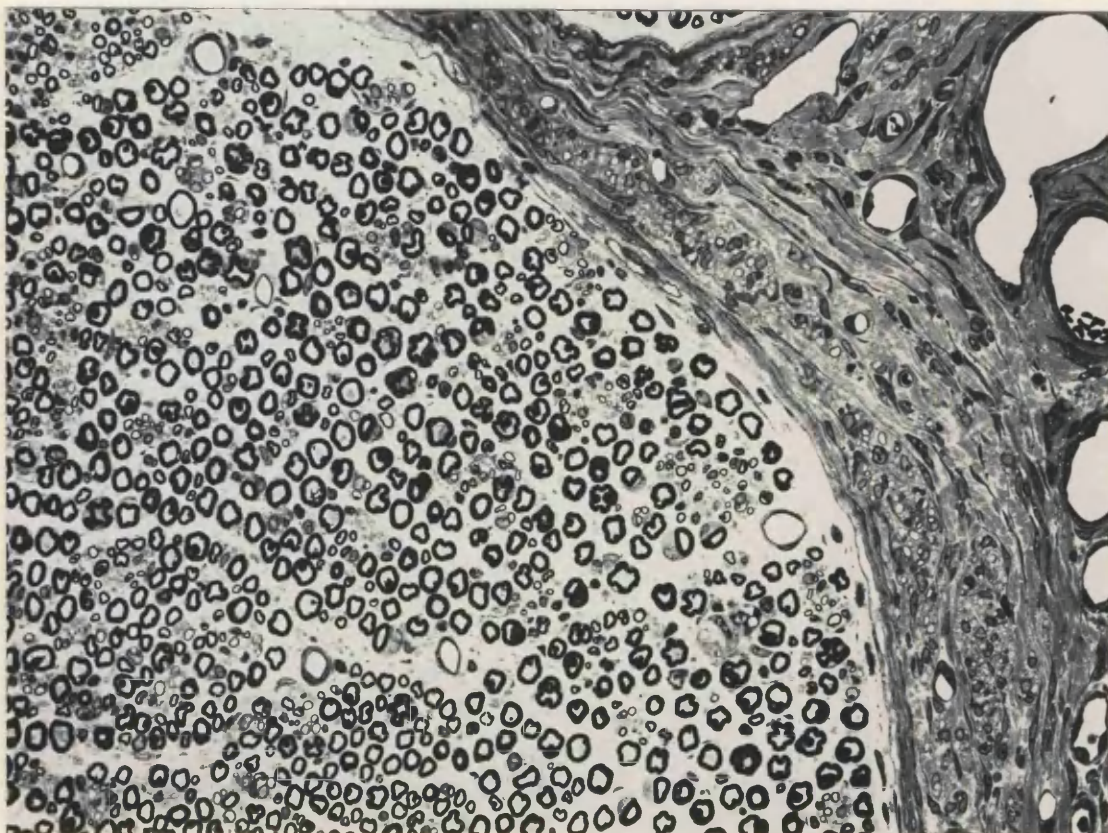
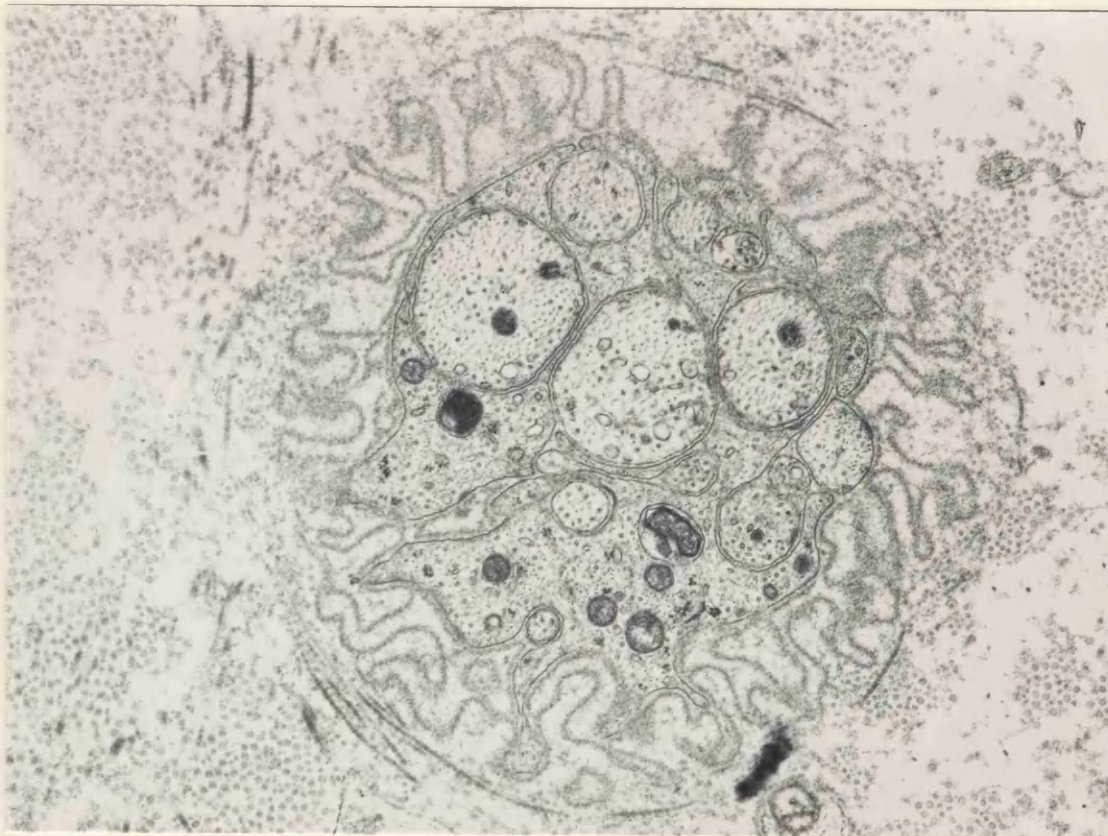


**FIGURE 55** 7 day section, distal 1mm. Several sprouts are present within this subunit which once contained one or more much larger cells, as suggested by the shrunken nature of the outer folded basal lamina. Collagen fibrils are closely encircling this group.

x 19 900

**FIGURE 56.** Distal part of a neuroma 2 weeks after nerve section, 0.5 to 1.0mm proximal to the distal tip. New tissue containing many large blood vessels, layers of fibroblasts and small fascicles of axonal sprouts surround the original nerve. Glutaraldehyde / Resin / Toluidine blue.

x 142



57) Many groups of spores were growing around lipid droplets in the

### 3. 14 DAYS POST - SECTION

#### 3.1 Neuroma Outgrowth

A thin outgrowth of tissue could be seen at the very distal tip of the tissue, distal to the main swelling of the neuroma. In one animal this outgrowth had penetrated between underlying muscle layers. Nerve fibres had a random orientation in plastic sections, running both transversely and longitudinally. Collagen fibres which were interspersed between axons also ran in random orientations. A very fine plexus of blood vessels was again seen on the surface of the neuroma, and the tissue of the neuroma outgrowth was highly vascular, containing many large blood vessels, which were often highly branched. Some small vessels still contained erythrocytes and lymphocytes, even though many smaller vessels had been adequately perfused. There were many macrophages with characteristic phagocytic appearance and lysosome granules in this part of the nerve, but no mast cells were seen either here or in the perineurium. The majority of the nerve area consisted of tiny, packed axonal sprouts, many of which were thinly myelinated. The perineurium surrounding the outgrowth contained many small blood vessels, layers of collagen fibrils and flattened Schwann cells, and was thicker than in normal nerve. There was no epineurium present at the distal tip of the outgrowth.

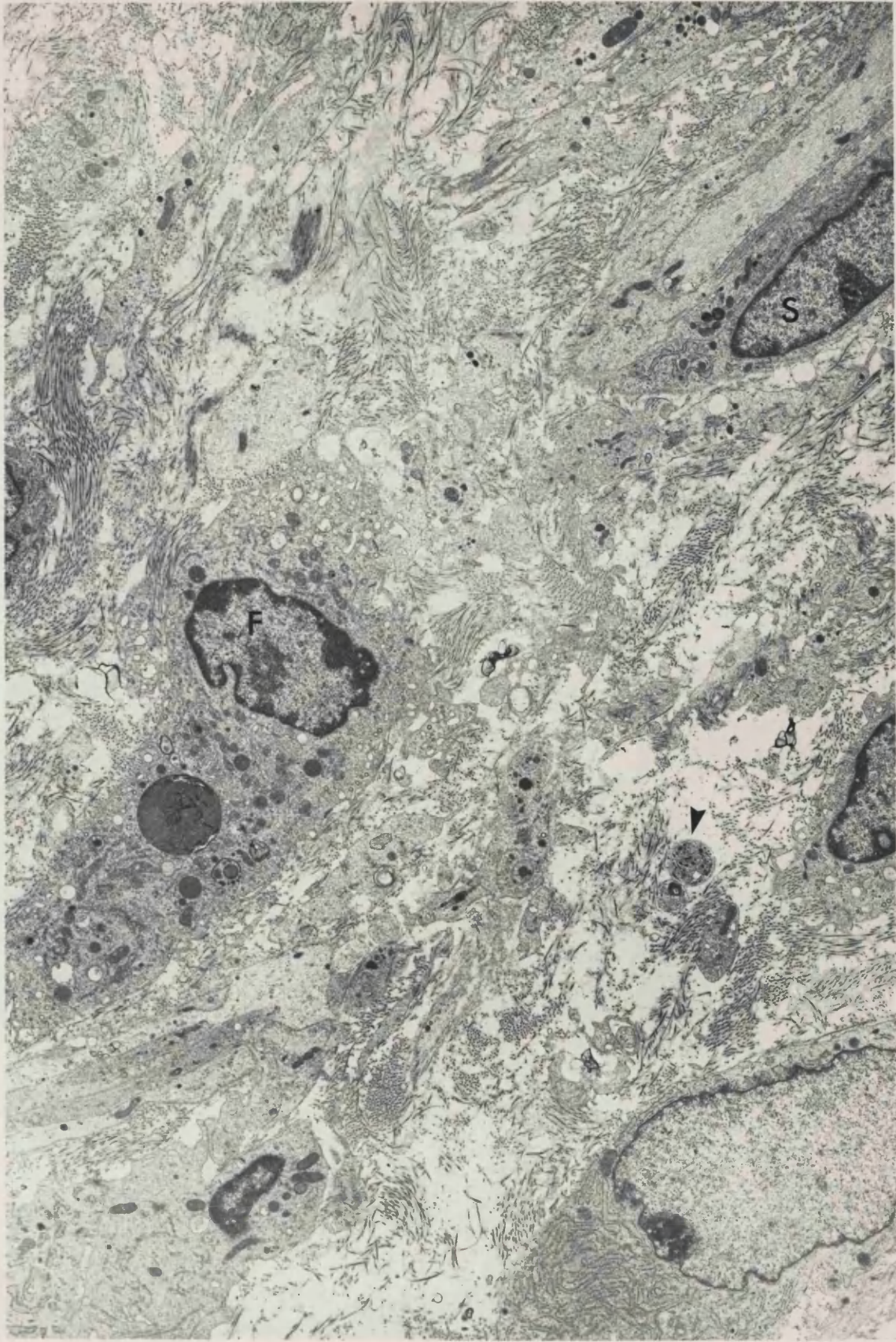
#### 3.2 Main body of neuroma swelling.

The overall shape of the neuroma was elongated, rather flatter than the shape of normal nerves. Around the main body of the original nerve was a ring of axonal sprouts which were 'compartmented', organized into small fascicles, each containing several Schwann cell sub-units (Fig. 56). This new tissue was highly vascular and contained many thinly myelinated axons. Between each sub-unit were densely packed collagen fibrils, with fibroblast processes forming individual perineuria around each sub-unit.

Many blood vessels, some of which were very large, were dispersed throughout the perineurium of the original nerve. The collagen of the perineurium was much more heavily stained than that of the endoneurium, and individual fibrils were larger. In the endoneurium, fibrils were often sparse and surrounded by a flocculent background material (Fig. 57). Many groups of sprouts were growing around lipid droplets in the

**FIGURE 57** 14 day section, distal 0.5mm. Part of the distal outgrowth of the neuroma, containing fibroblasts (F), Schwann cells (S) and numerous axonal sprouts (arrows). The fibrils of collagen are sparsely distributed and surrounded by a flocculent background matrix.

x 4 700



perineurium. Within the perineurium, many fibroblasts contained typical pinocytotic vesicles, showing the characteristic 'omega' configurations of the outer membrane. They also appeared to be highly active, with large amounts of rough endoplasmic reticulum in their cytoplasm, much of it closely packed in parallel layers around the outside of the cell. Mast cells were numerous, both in the perineurium and within the nerve itself. This appearance correlated with the position of autofluorescent mast cells in the neuromas examined by fluorescence microscopy, these cells being seen at the point of section of the nerve and further proximally, not at the distal tip. Around the outside of the perineurium was a highly vascular epineurium, containing occasional free erythrocytes.

### 3.2.1. Myelinated axons

Many new small and thinly myelinated axons were interspersed between the older myelinated fibres. There were many fewer degenerating fibres than at 7 days, and those which were degenerating were in an advanced state. Many fibres had begun to remyelinate. The thickest myelin sheaths contained 15-20 lamellae although there were many axons with much thinner sheaths, containing only 2-3 lamellae. These thin sheaths were often seen to contain contact points between lamellae, appearing as small electron-dense areas (Fig. 58). Many lamellae, however, were very loosely wound, with tongues of Schwann cell cytoplasm visible between them. In Schwann cell groups where one axon was remyelinating, the other axonal sprouts had disappeared, probably following degeneration. There were still many large bare axonal sprouts awaiting remyelination by the numerous Schwann cells.

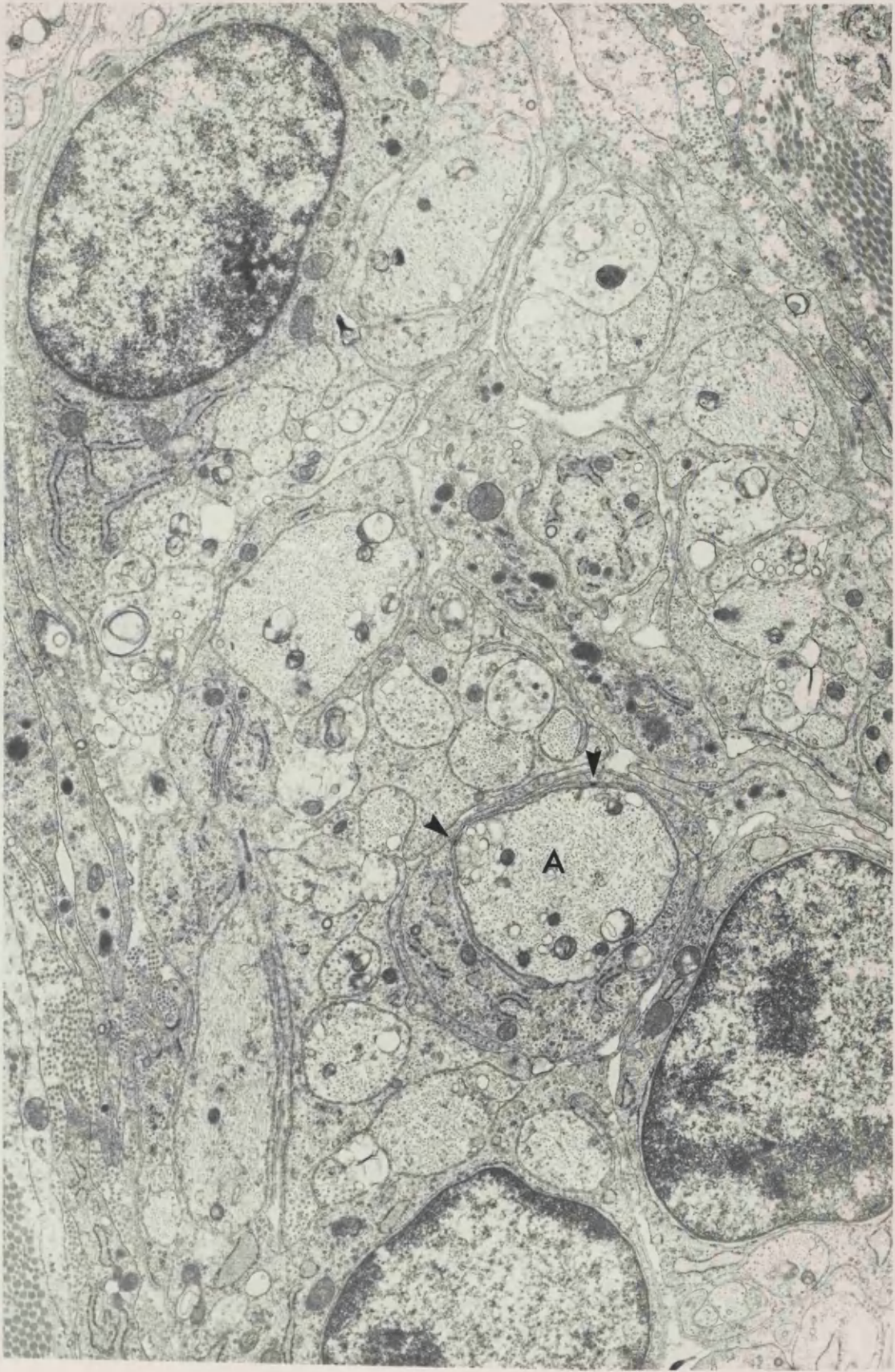
### 3.2.2 Unmyelinated axons

Very few axons with convincing labelled dcv were seen. Those sprouts which were possibly labelled generally were of a larger size, and these axons contained other organelles in addition to the dcv. On the basis of the appearance of neuromas 14 days after section as seen in the fluorescence microscope, very few sympathetic axons were present in the most distal part of the neuroma. Of the few axons seen with cored vesicles none of these were dense enough to allow positive identification of that axon as sympathetic (Fig. 59). There were many fewer small axonal sprouts by this time, so that most sprouts left were of a larger size, and there were fewer sprouts



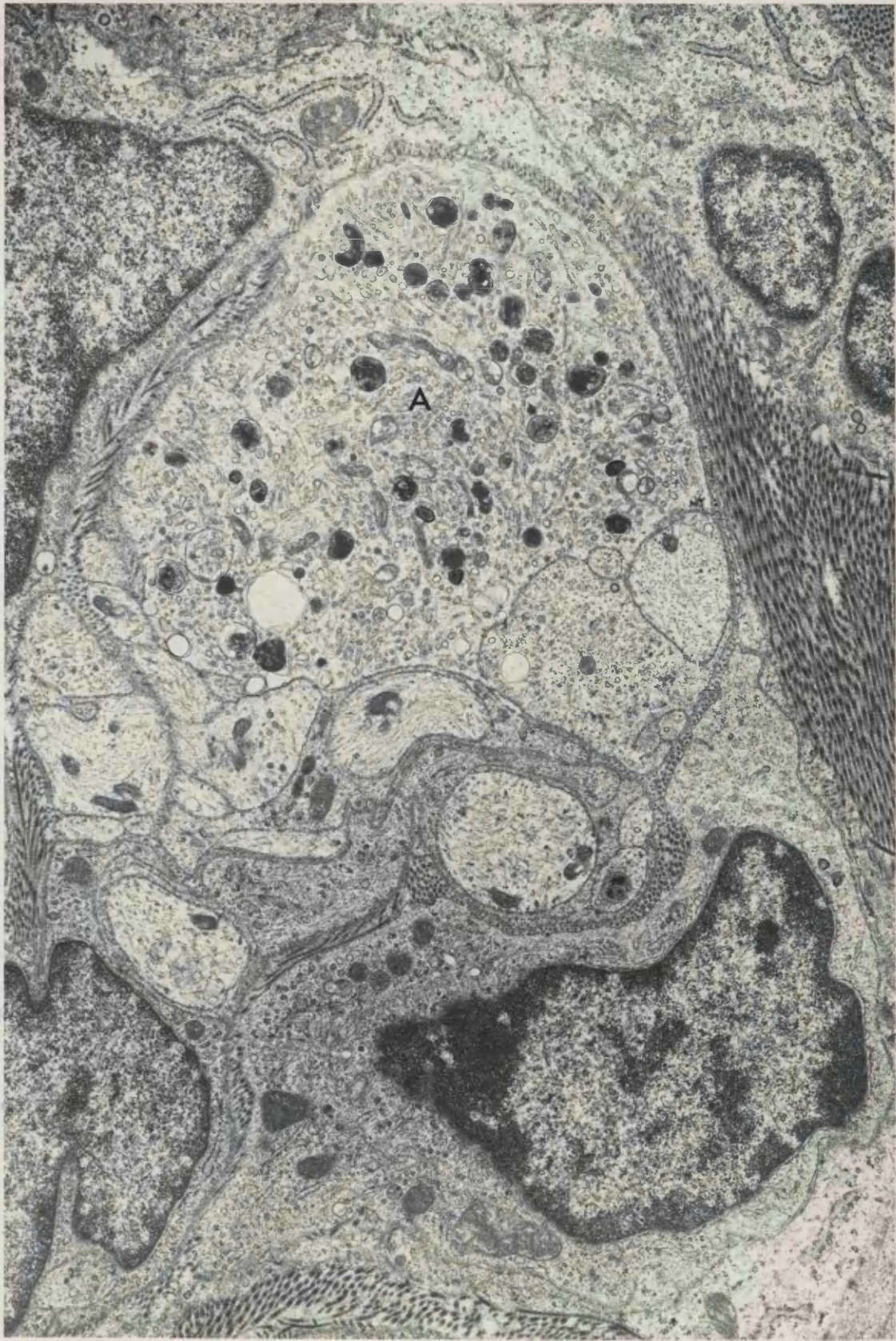
**FIGURE 58** 14 day neuroma, distal lmm. The central axon (A) has an active Schwann cell containing much rough endoplasmic reticulum, and is completely surrounded by a second membrane which shows contact points (arrows) with the mesaxon. These features suggest that this axon will probably become myelinated.

x 12 850



**FIGURE 59** 14 day neuroma, distal 1mm. Axon (A) containing an accumulation of organelles, but no 5-OH DA labelled dcv. Other axons and sprouts with the group show a similar lack of dcv.

x 12 100



per Schwann cell subunit (Fig. 60). Very few axons containing dense bodies were seen, and there were only one or two highly swollen axons packed with organelles. There were still a few axons with higher than normal numbers of clear vesicles, multivesicular bodies and small amount of smooth endoplasmic reticulum, but most axons and sprouts contained mainly mitochondria, microtubules and neurofilaments. Many axons with spiralling neurofilaments were seen.

#### 4. 21 - 28 DAYS POST - SECTION

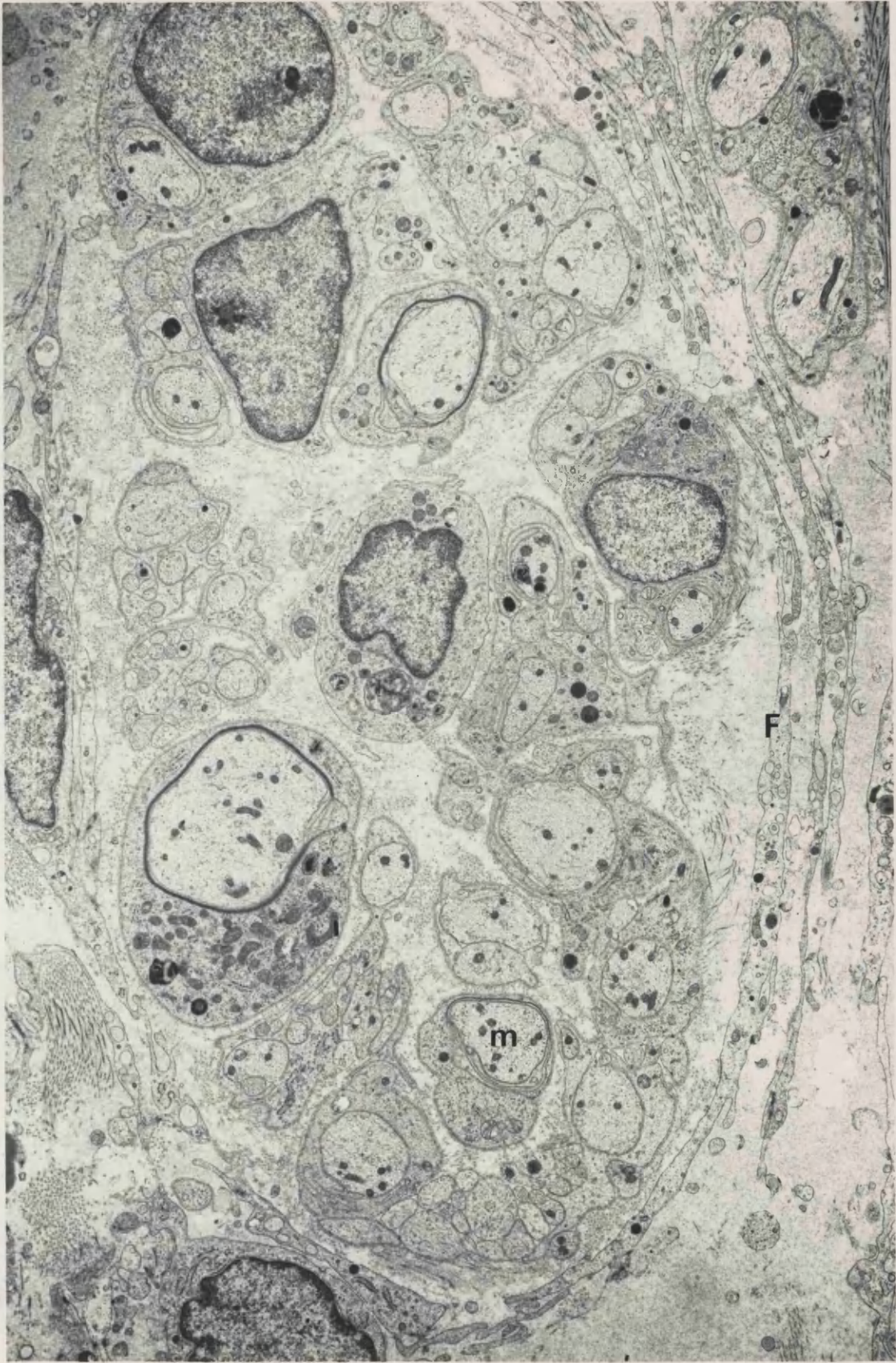
##### 4.1 Neuroma Outgrowth. 4.1.1 Non-Axonal Structures

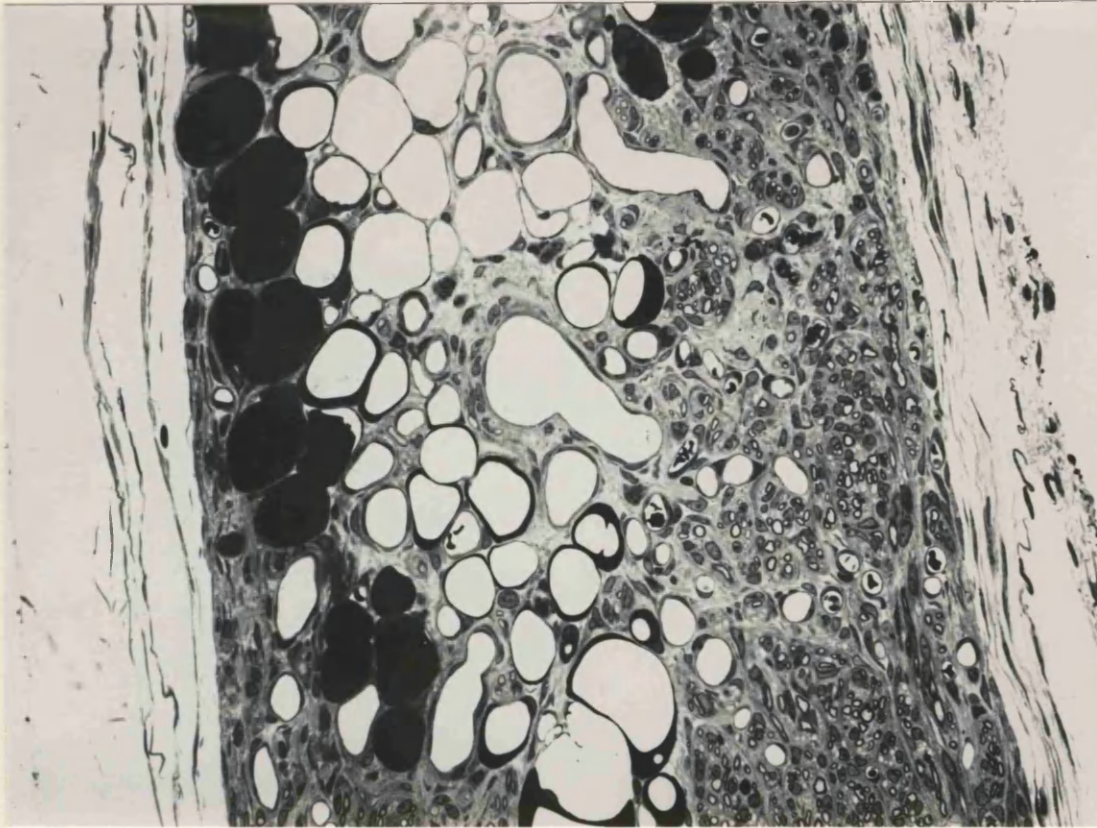
Most of the neuroma outgrowths were again long thin flattened processes, running very close to the underlying muscle, and growing between groups of muscle fibres in one instance. The central areas were thickened, with one long thin process running off to one side, consisting mainly of collagen, but which also contained a few axonal sprouts, in mini-fascicles, interspersed between the fibrils (Fig. 61). At the most distal tip, tissue was arranged into very loosely packed small fascicles, bounded by loosely packed perineurial collagen, fibroblasts and perineurial cells. Many fascicles were surrounded by 4 - 5 layers of processes containing flattened mitochondria and rough endoplasmic reticulum (Fig. 62). Fibroblasts could be distinguished from perineurial cells on the grounds that fibroblasts were devoid of a basal lamina. Perineurial cells had basal laminae, even if they were not complete, or only occurred on one side of the cell process. In neuromas less than the three weeks old, all the processes surrounding the newly forming microfascicles were derived from fibroblasts. As the neuroma aged, these cells were transformed into perineurial type cells. Between each layer was compact collagen, the fibrils of this endoneurial collagen were smaller than that of the perineurium, and of a more uniform diameter. There were many blood vessels in the neuroma outgrowth, many of which were larger than the fascicle units themselves. The endothelium of many of the smaller capillaries consisted of just one cell in the plane of section examined, and the diameter of the vessel was often only large enough to contain a few erythrocytes at a time.

There were also many large lipid droplets in the outgrowth, often with the fascicles of new growth between them. Only one mast cell was

**FIGURE 60** 14 day neuroma, distal 1mm. Two axons are beginning to become myelinated (m), and others are surrounded by more than one layer of membranes. Many tiny sprouts are still present 14 days after nerve section. Fibroblast processes (F) are beginning to surround these regenerating axon groups.

x 6 500





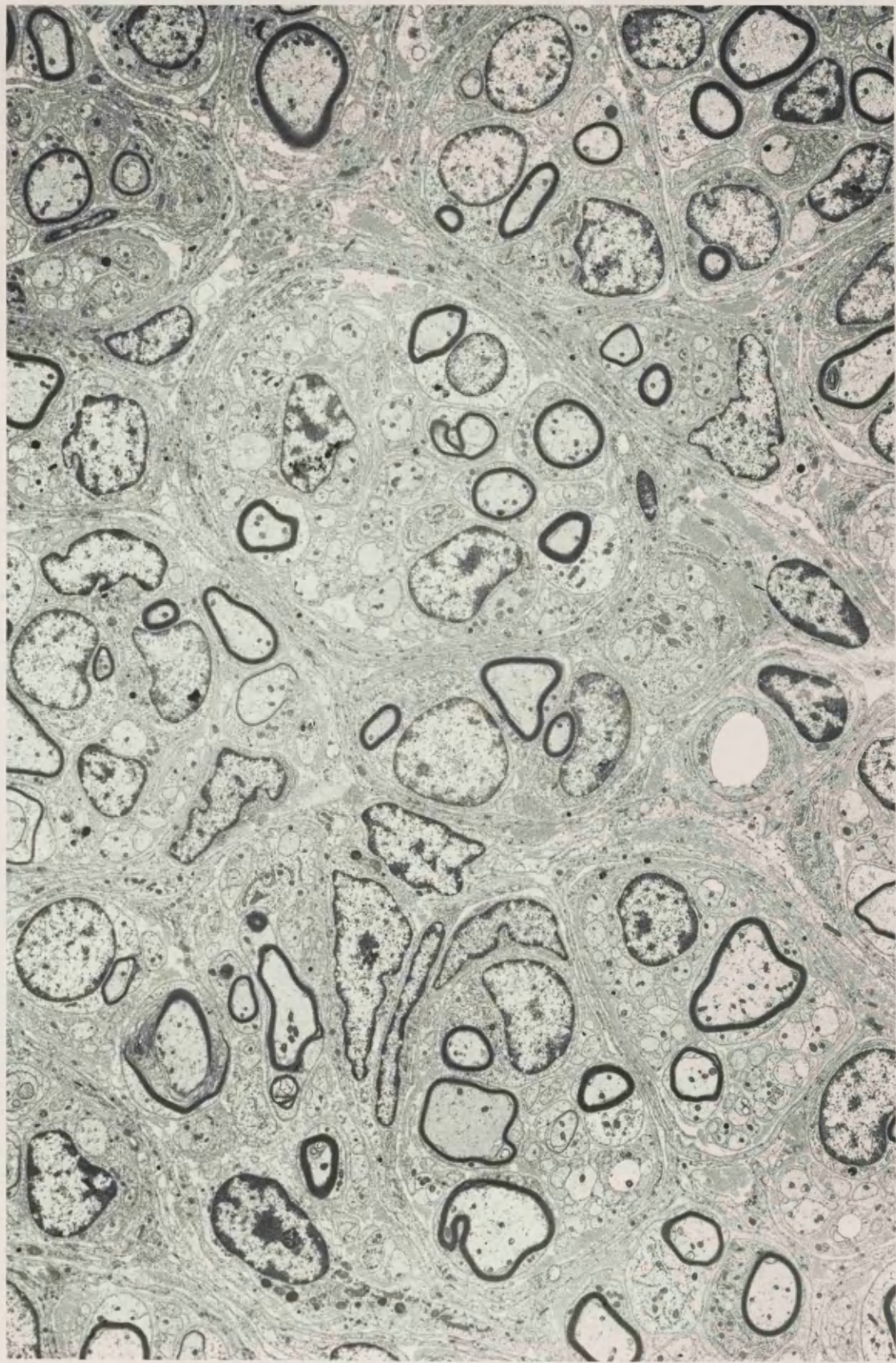
**FIGURE 61.** Neuroma 4 weeks post-section. Outgrowth, distal to the original point of section. The principal tissue elements are blood vessels, dense lipid droplets and closely packed fascicles of both myelinated and unmyelinated axonal sprouts. Glutaraldehyde / Resin / Toluidine blue.

x 155



**FIGURE 62** 21 day neuroma, distal 1mm. The neuromatous tissue has now become organized into small fascicles, surrounded by one or two layers of fibroblast processes. Many axons are in the process of becoming myelinated, and any other sprouts which may once have been contained in the Schwann cell cytoplasm of these axons have now disappeared.

x 3 500



seen at the most distal tip of the neuroma within the perineurium. Eosinophilic leucocytes were seen in the perineurium, containing characteristic ovoid inclusion bodies with electron dense stripes across the centre (Fig. 63). The perineurium here was thickened, made up of many layers of collagen, fibroblasts and perineurial cells.

#### 4.2 More proximal tissue

In the more proximal tissue, the original nerves were surrounded by a ring of mini fascicles of new growth. The myelin of the original myelinated fibres which was intact, was much thicker than that of the new fibres, and the original fibres were correspondingly larger. The nerves were rather flattened, having a more 'squashed' appearance, and appeared to be divided into several large groups, with strings of small blood vessels, and collagen between the groups. Schwann cell proliferation was also evident in the old nerve, and there were several abnormally large blood vessels. The new growth mini-fascicles were much more closely packed here than at the distal tip, and the collagen between them was also very densely packed. There were also many more mast cells further proximally into the neuroma, distributed throughout the new growth of the perineurium and the original nerve. 26 were counted in one section.

There were no groups of sprouts in the epineurium, but this tissue was also abnormally vascular.

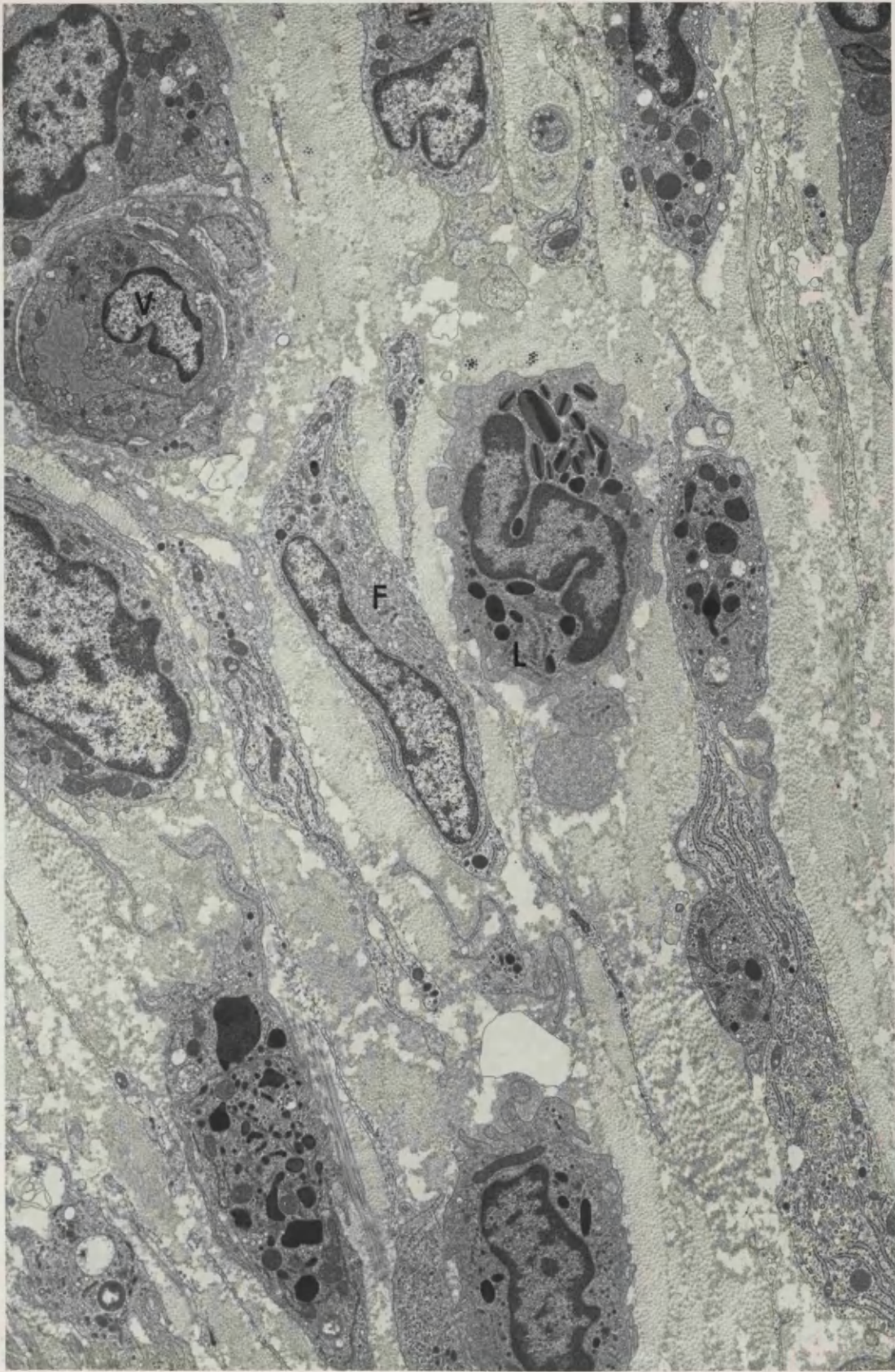
##### 4.2.1 Myelinated Fibres

Axonal sprouts were very rarely seen beneath the basement membrane of myelinated fibres, which had reverted to the normal configuration of 1 myelinated axon to each Schwann cell. The fibres with very thin myelin sheaths at the distal tip of the neuroma were not being remyelinated but newly myelinated, whereas large axons further proximally had probably originally been myelinated and were now becoming remyelinated. Remyelination was occurring in many different stages, with many large bare axons awaiting myelination. Some of the axons had only a whorled mesaxon around them, giving 1-2 lamellae, others had a few myelin lamellae, and many had almost complete sheaths. The myelin sheath was generally thicker in neuromas 4 weeks post-section. Loops of myelin could be seen within the Schwann cell cytoplasm of some axons, sometimes as a loop protruding from the myelin

170

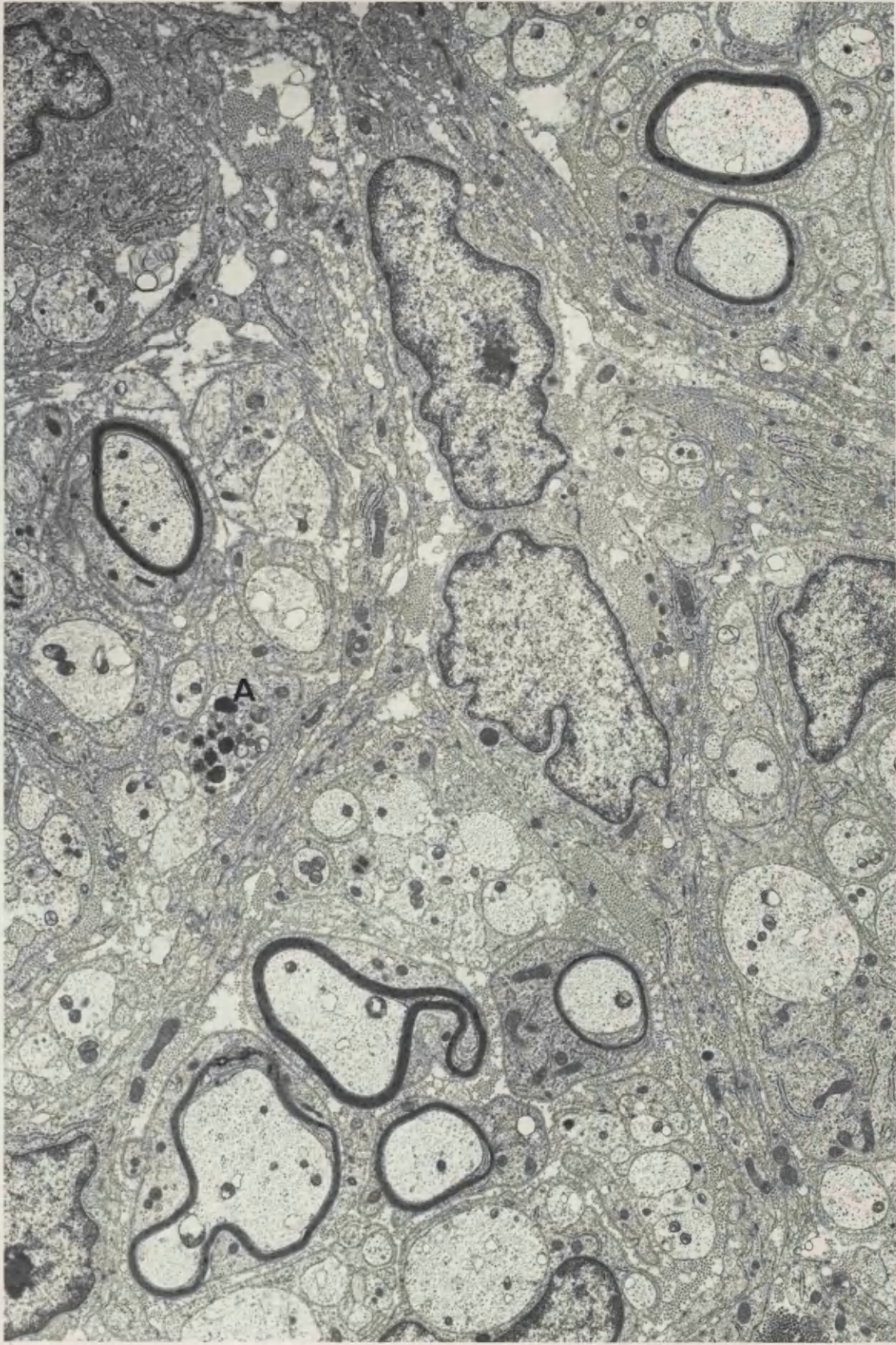
**FIGURE 63** 21 day neuroma, distal 1mm. The perineurium of this neuroma consists of layers of fibroblasts (F), collagen, blood vessels (V), and occasionally eosinophilic leucocytes with striped inclusion bodies (L).

x 6 400



**FIGURE 64** 21 day neuroma, distal 1mm. A number of large and, as yet, unmyelinated axons are seen within active Schwann cell cytoplasm, their size suggesting that they may become myelinated. One axon (A) contains degenerate material and in others loops of myelin can be seen protruding from the rest of the sheath.

x 8 800



sheath (Fig. 64) and sometimes as separate whorls in the cytoplasm. These whorls of myelin were probably continuous with the myelin sheath further along the fibre. Often, myelin lamellae were loosely arranged at one point in the sheath with Schwann cell cytoplasm filling the gaps. These configurations probably represented the beginnings of Schmidt-Lanterman incisures. There was no degeneration of myelin visible throughout the length of neuroma examined, and few macrophages were seen, these generally occurring in the perineurium. The Schwann cells often appeared to be very active with many stacks of Golgi membranes, mitochondria and rough endoplasmic reticulum visible in the cytoplasm. Very large homogeneously dense membrane-bound bodies and ciliary bodies were often also visible.

A few empty basement membranes of Schwann cells were still visible, flattened and highly folded, in the endoneurium.

#### 4.2.2 Unmyelinated Fibres

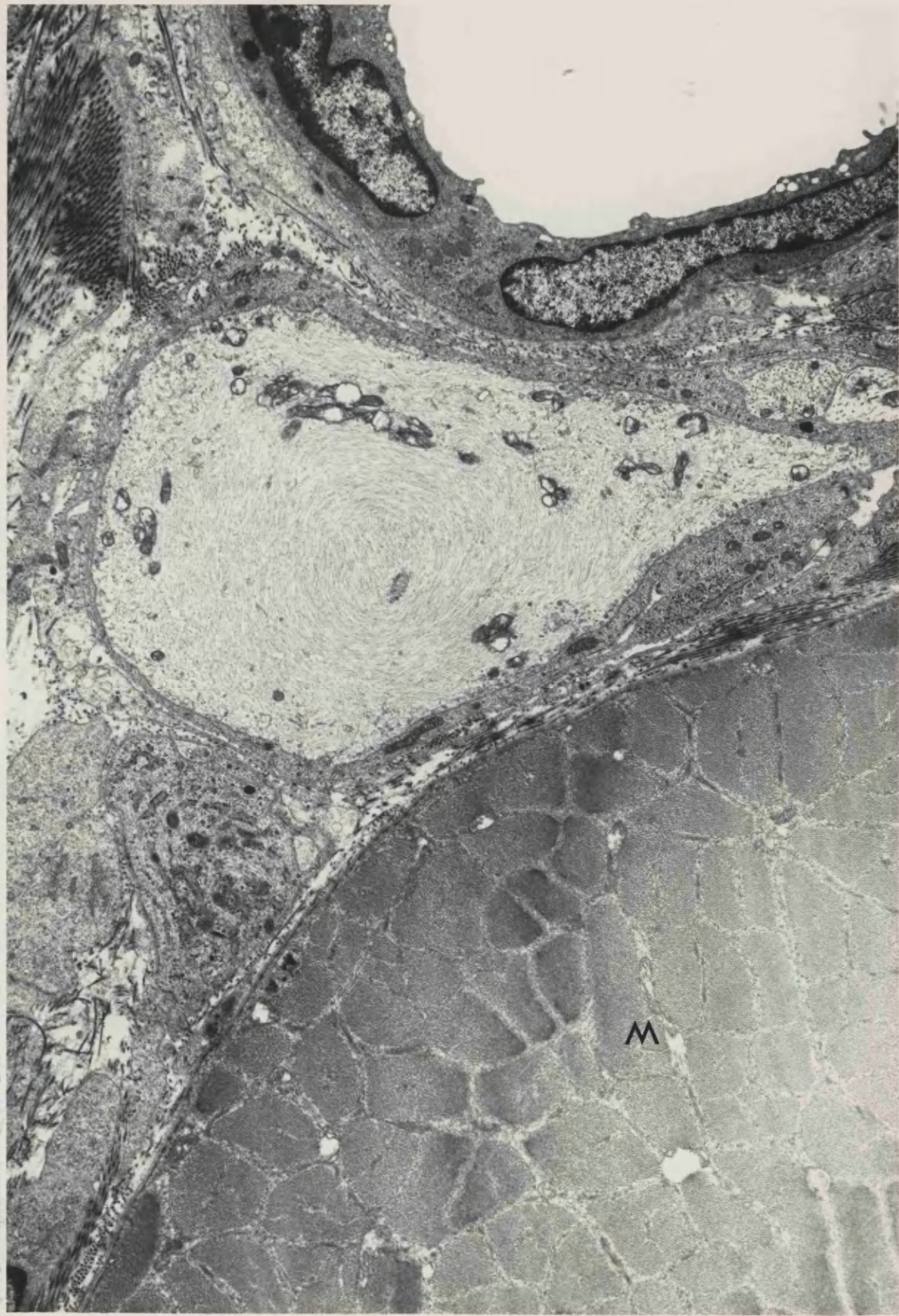
Three to four weeks after nerve section the Schwann cell sub-units were small. Smaller sprouts were visible further distally towards the tip of the neuroma. Most unmyelinated axons now had a normal density and complement of organelles. Neurofilaments within the axons were sometimes not aligned longitudinally in the fibre, but frequently ran obliquely in part of the axon. Sometimes filaments appeared to be arranged in whorls around the axon, in oblique section around the inner edge of the mesaxon and in transverse section in the axon centre (Fig. 65).

There were some axons with labelled dcx, which were identified as being sympathetic. These sympathetic axons usually had more vesicles than seen in normal tissue, both clear and dense-cored (Figs. 66 and 67) and a few larger axons were also packed with smooth endoplasmic reticulum and mitochondria. Sympathetic axons were usually seen within a group of other small non-myelinated axons, but sometimes one or more of the group would be large, and possibly these large axons may have been myelinated axon sprouts (Fig. 68). It was not possible to make conclusions about the number of sympathetic axons seen in neuromas 4 weeks after section without detailed quantitative analysis, but there seemed to be an increase in the numbers visible when compared to those seen in neuromas 2 weeks post-section.



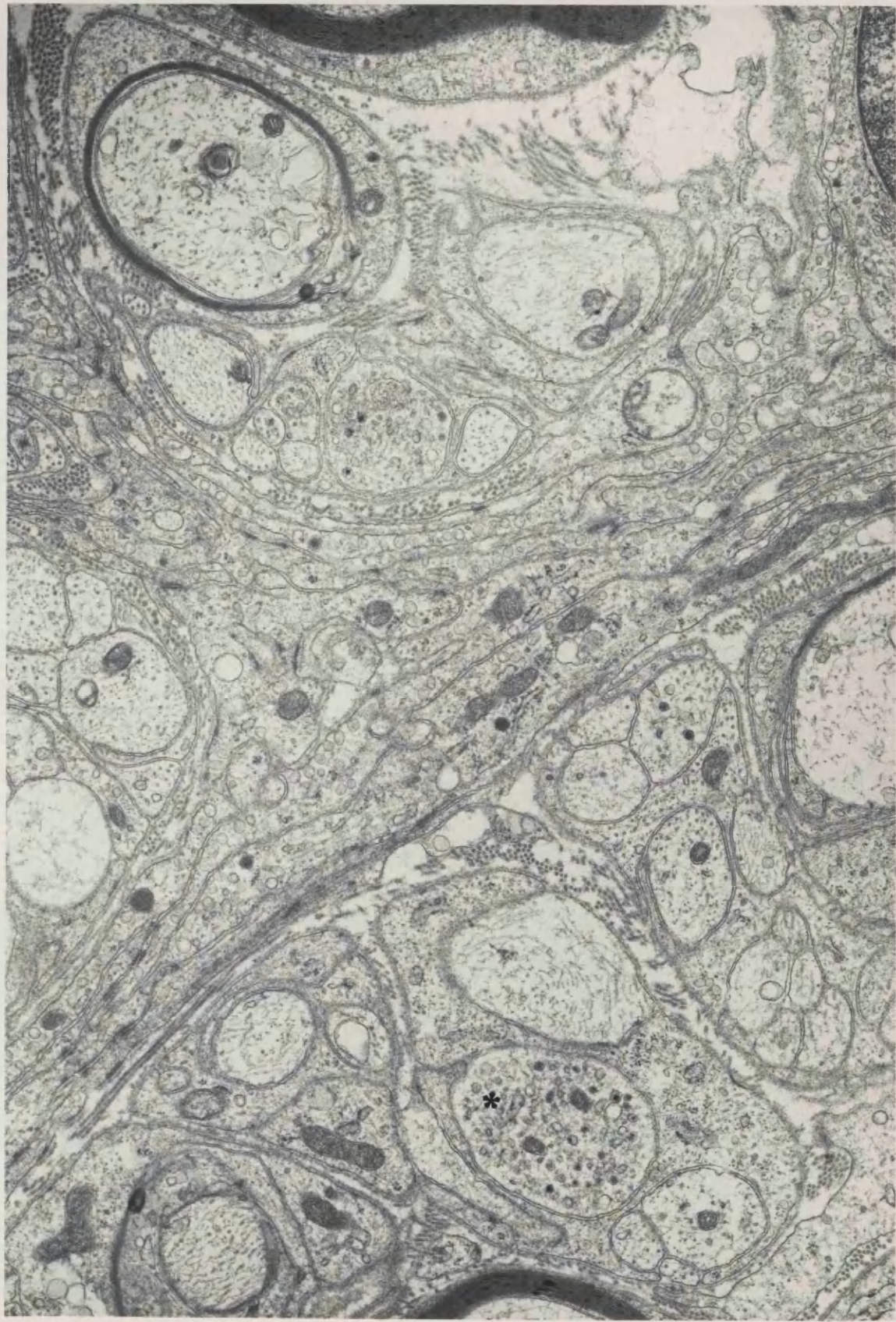
**FIGURE 65** 21 day neuroma, distal 1mm. Pretreated with nialamide and 5-OH DA. This axon, which is part of the outgrowth of the neuroma which closely overlies muscle (M), contains neurofilaments in a concentric configuration.

x 8 600



**FIGURE 66** 21 day neuroma, distal 1mm. 3 sympathetic axons contain several dcv. One large axon (star) contains many more dcv than are seen in normal tissue.

x 16 800

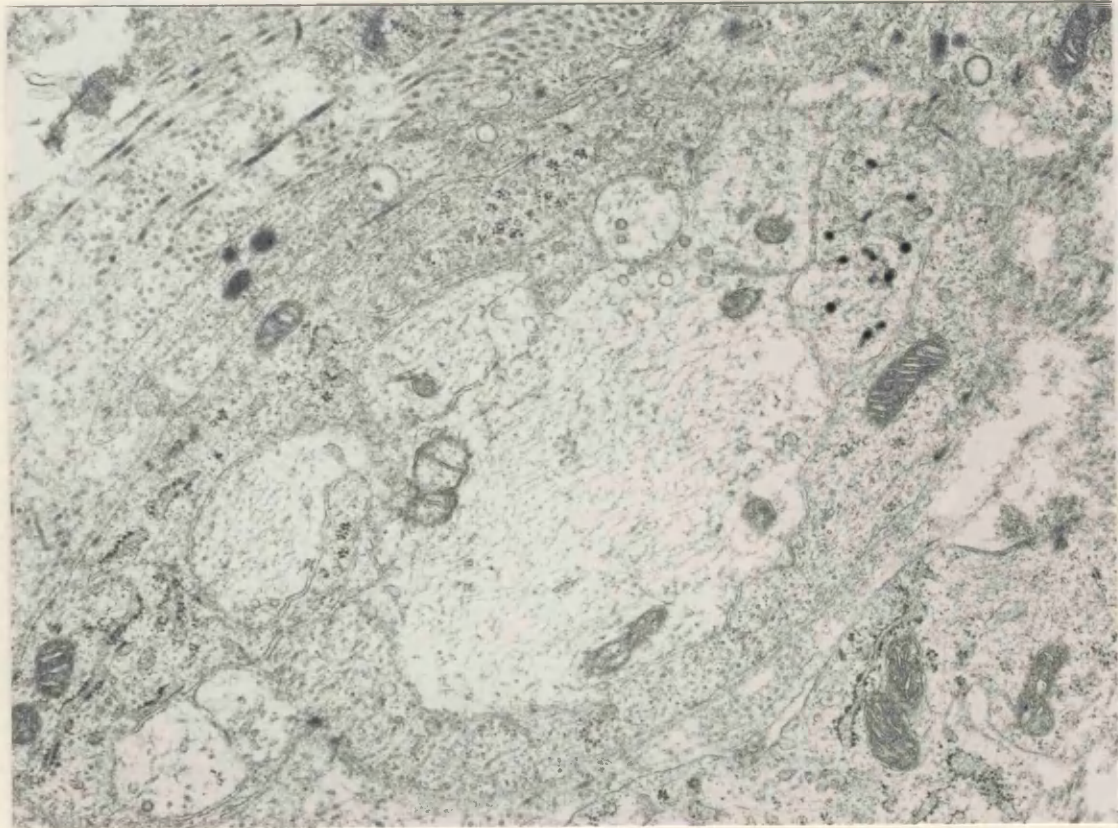
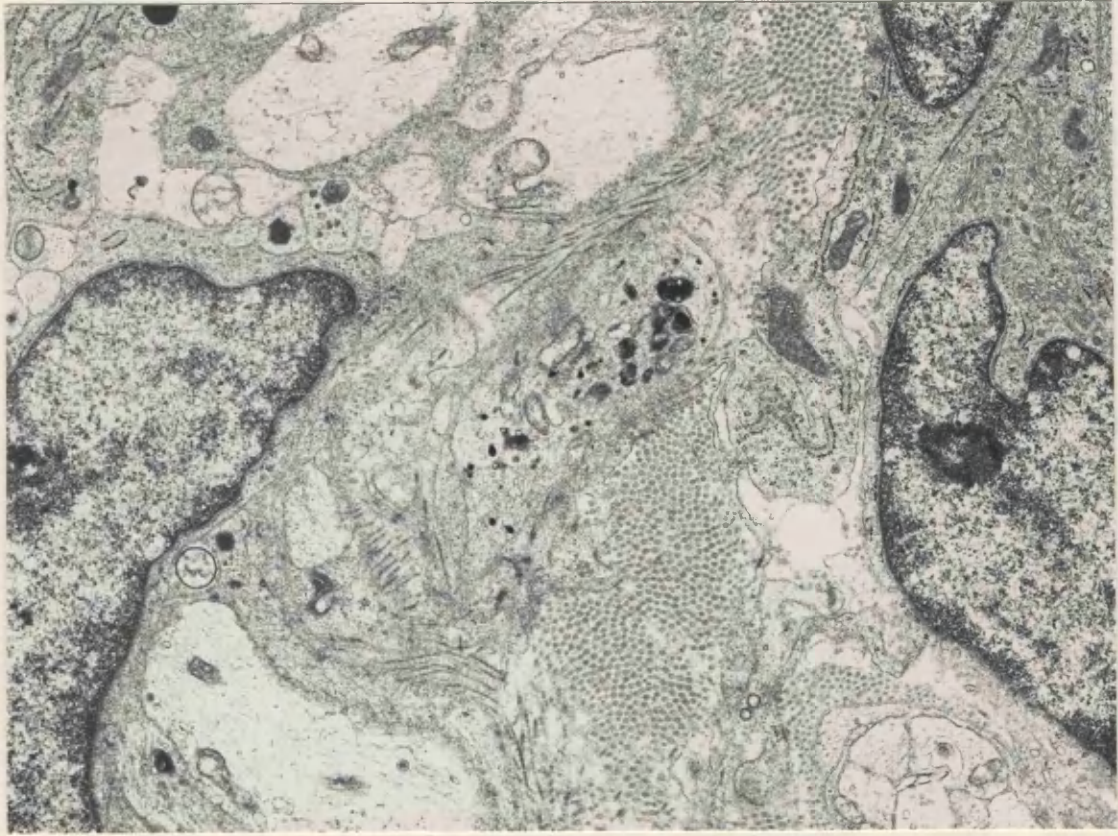


**FIGURE 67** 21 day neuroma, distal 1mm. Pretreated with nialamide and 5-OH DA. A sympathetic axon containing numerous dcv also contains several dense bodies of degenerate material.

x 12 100

**FIGURE 68** 21 day neuroma, distal 1mm. Pretreated with nialamide and 5-OH DA. A sympathetic axon is in close association with a much larger axon which is of a suitable size to become myelinated.

x 19 800



## 5. 42-56 Days Post Section

### 5.1 Distal Tip of Neuroma Outgrowth

At the very distal tip, the neuroma outgrowth was a very small circular growth consisting of 3 bundles of fibres in nerves at 42 days post-section, but more bundles were seen by 56 days following section. These fascicles were still very loosely distributed, interspersed with collagen. 2 distinct types of collagen were identifiable:

- 1) Varying sized fibrils in a dense matrix, perineurial collagen,
- 2) Very uniform small fibrils - endoneurial collagen.

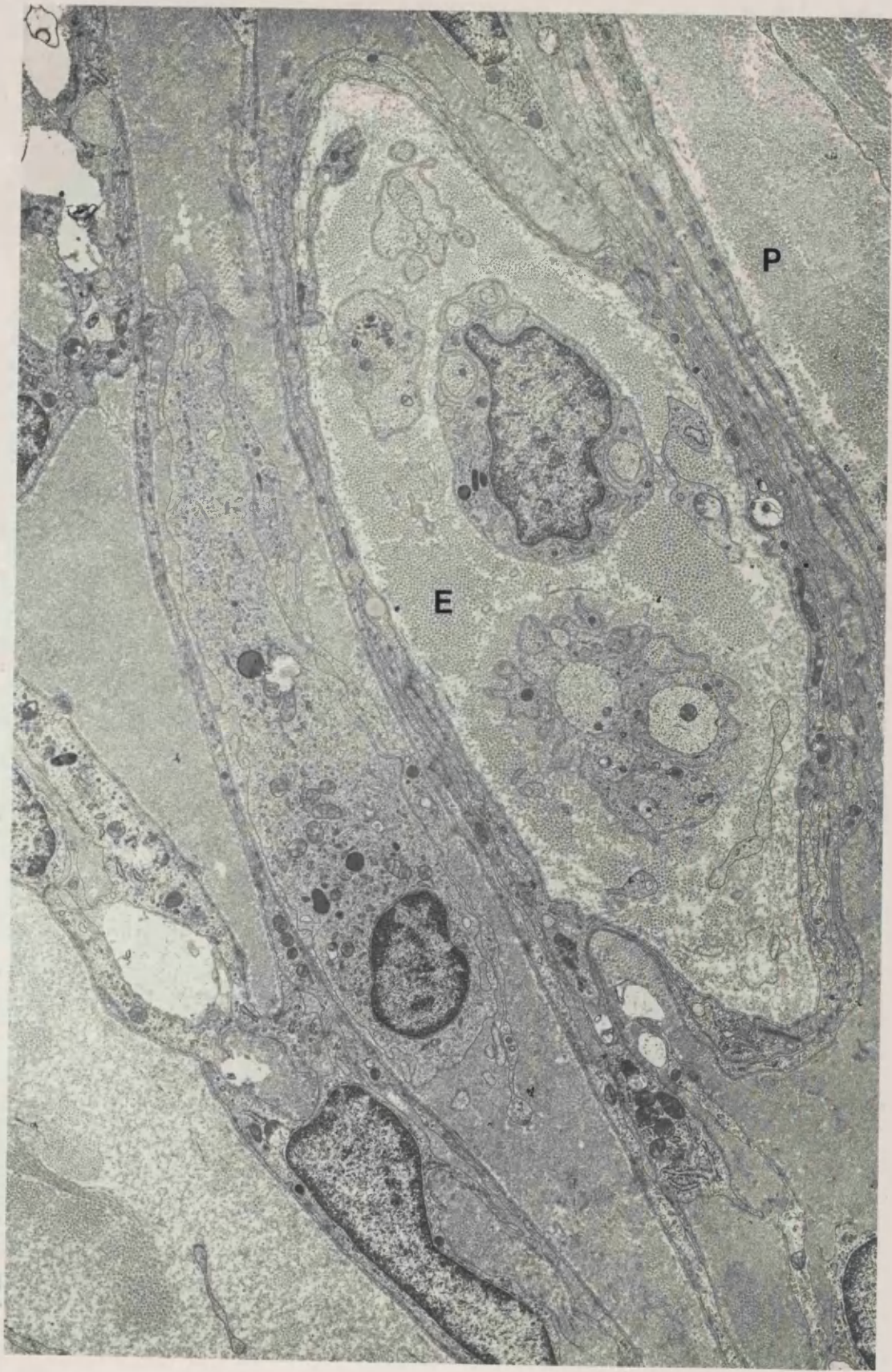
Often the groups of regenerating axons were surrounded by a thin layer of very densely packed tiny fibrils, layers of larger collagen fibrils around this (Fig. 69). There were many sprouts still present at the distal tip, contained in small fascicles of variable size (Fig. 70). The largest contained 20 myelinated and 10-15 sub-units of unmyelinated axons; the smallest contained 1-2 myelinated fibres and 3-4 unmyelinated sub-units. Within some sub-units were collagen pockets where endoneurial collagen had become surrounded by invaginations of the Schwann cell basement membrane. Often the Schwann cell subunits consisted of groups of only 2 or 3 axons, surrounded by a basal lamina which followed the irregular external contours of the group. There were also small groups consisting entirely of profiles of Schwann cell cytoplasm, sometimes as many as 7 or 8 to a group, with no clearly identifiable axons. Most of the myelinated fibres were very thinly myelinated, often with only 3 or 4 lamellae, and were sometimes seen in isolation, not as part of a group of regenerating axons. The small Schwann cell subunits were organized into varying configurations. Sometimes there was a central myelinated axon with a complete ring of non-myelinated axonal sprouts, surrounded by a collagen matrix, then surrounded by layers of perineurial cell processes, with a few remaining fibroblasts (Figs. 71, 72). But sometimes groups of axons were 'bare' with no surrounding layers of perineurial type cell processes (Fig. 73). By 42 - 56 days following section, the orientation of tissue at the tip of the neuroma was very much more random than at earlier times post-section.

### 5.2 Further Proximal

**FIGURE 69** 6 week neuroma, distal 1mm. Small fascicles containing axonal sprouts are surrounded by collagen composed of small uniform fibrils. Outside this layer, but within the layers of perineurial cells is collagen of a type which more closely resembles endoneurial collagen (E). A third type of collagen, where the fibrils are larger and not of uniform diameter, perineurial type collagen (P), is also present.

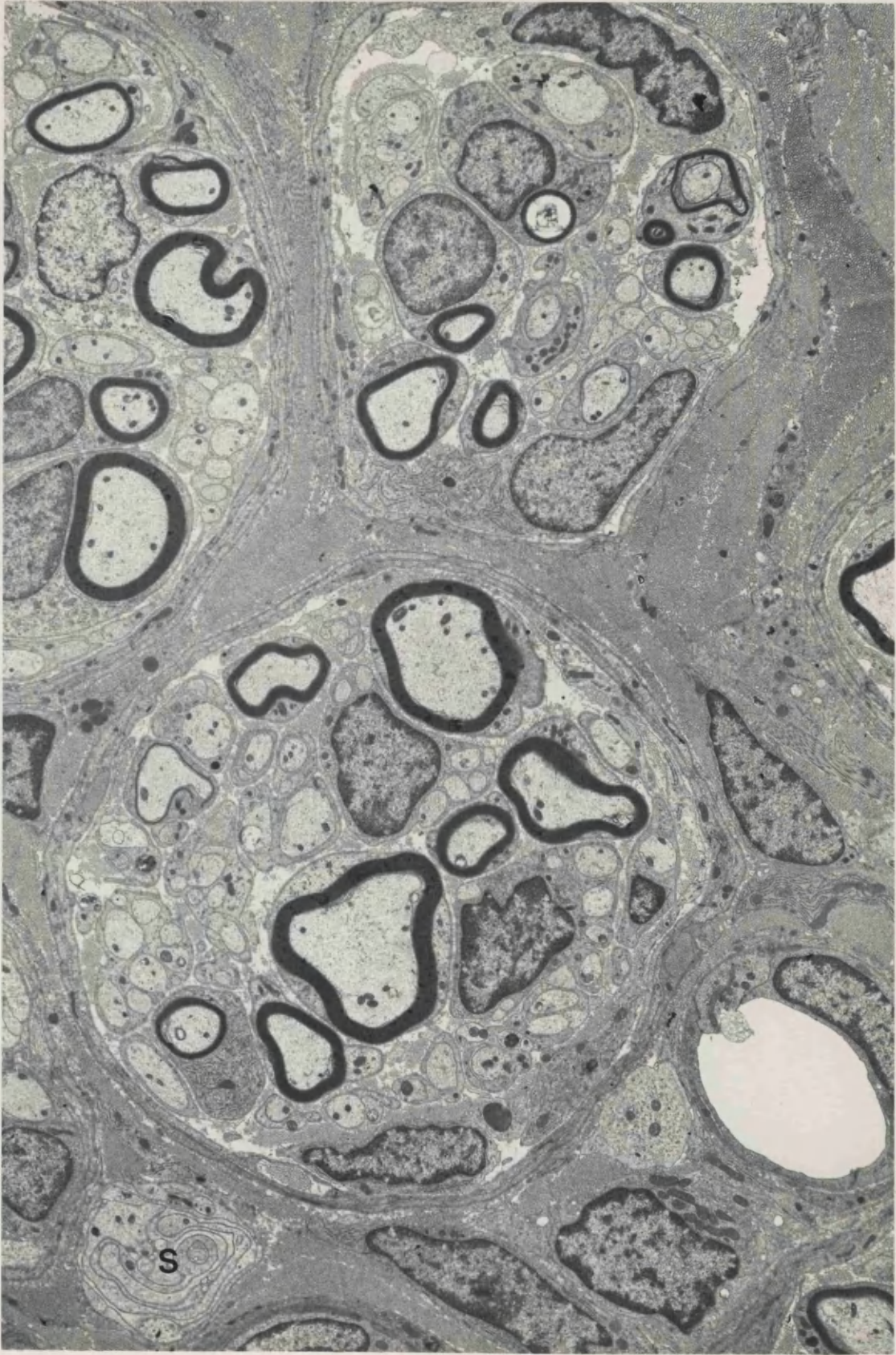
x 8 100





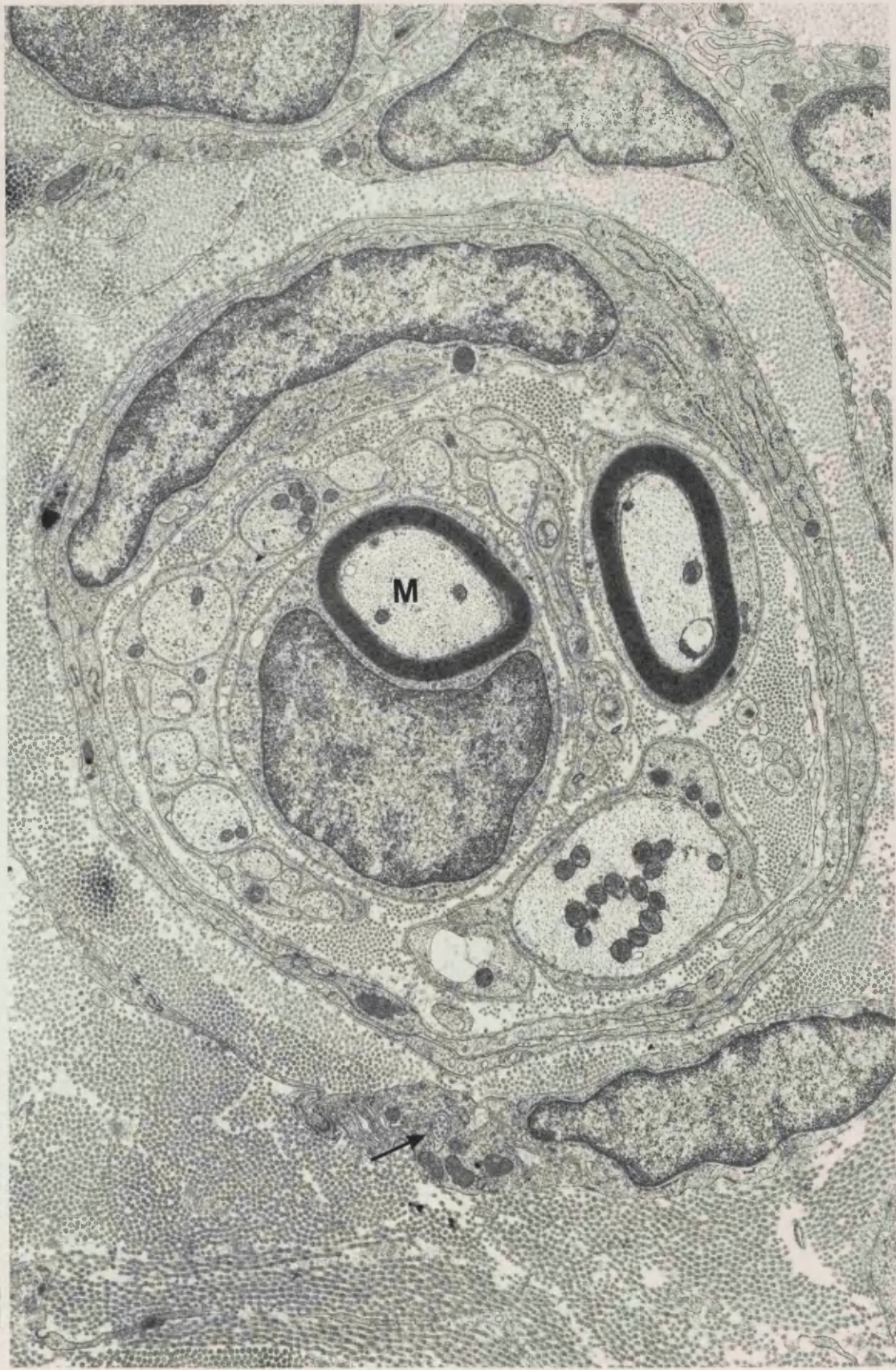**FIGURE 70** 6 week neuroma, distal 1mm. The fascicles of the neuroma tend to be larger and contain more Schwann cell subunits in the more proximal tissue (cf. Fig. 71), and are surrounded by compact collagen. One subunit contains principally bands of flattened, twisted Schwann cell cytoplasm (S).

x 4 800



**FIGURE 71** 6 week neuroma, distal 0.5mm. One of the myelinated axons (M) in this small fascicle is almost completely surrounded by a Schwann cell subunit containing unmyelinated axons and sprouts. The fascicle is surrounded by two layers of perineurial type cell processes. A cilium (arrow) can be seen within the cytoplasm of a fibroblast.

x 13 400

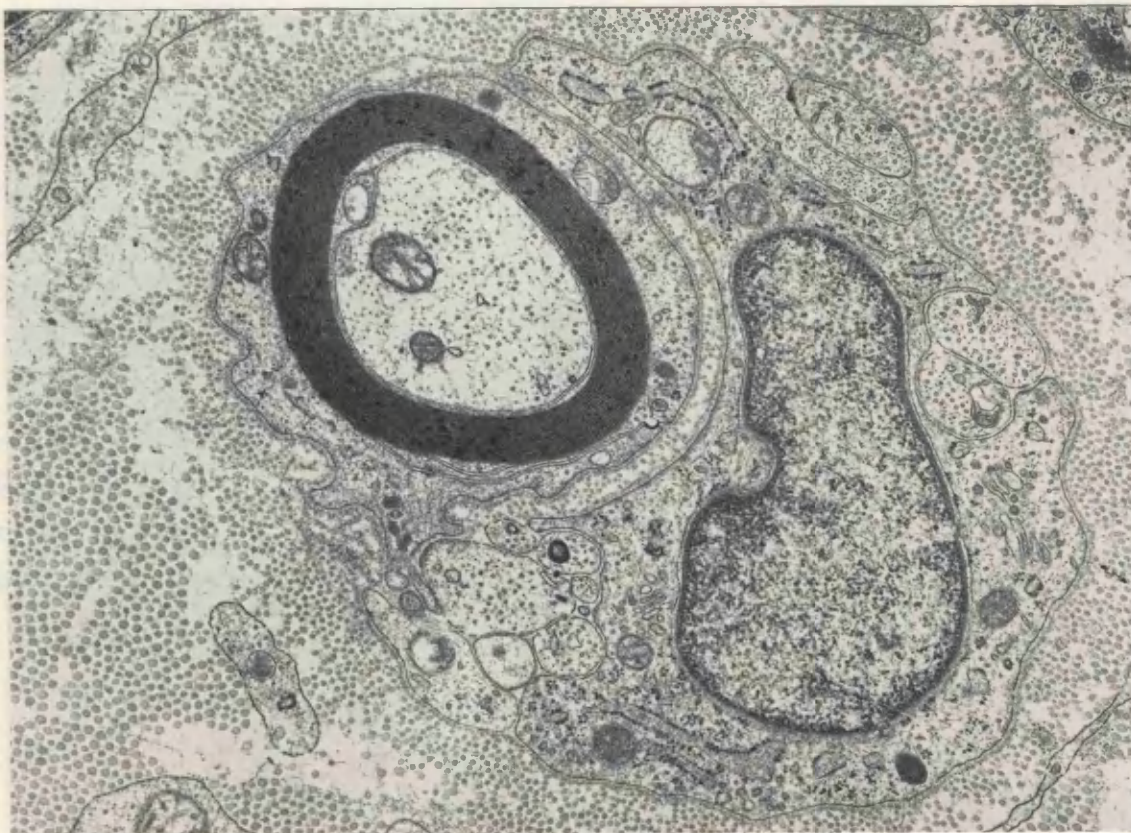
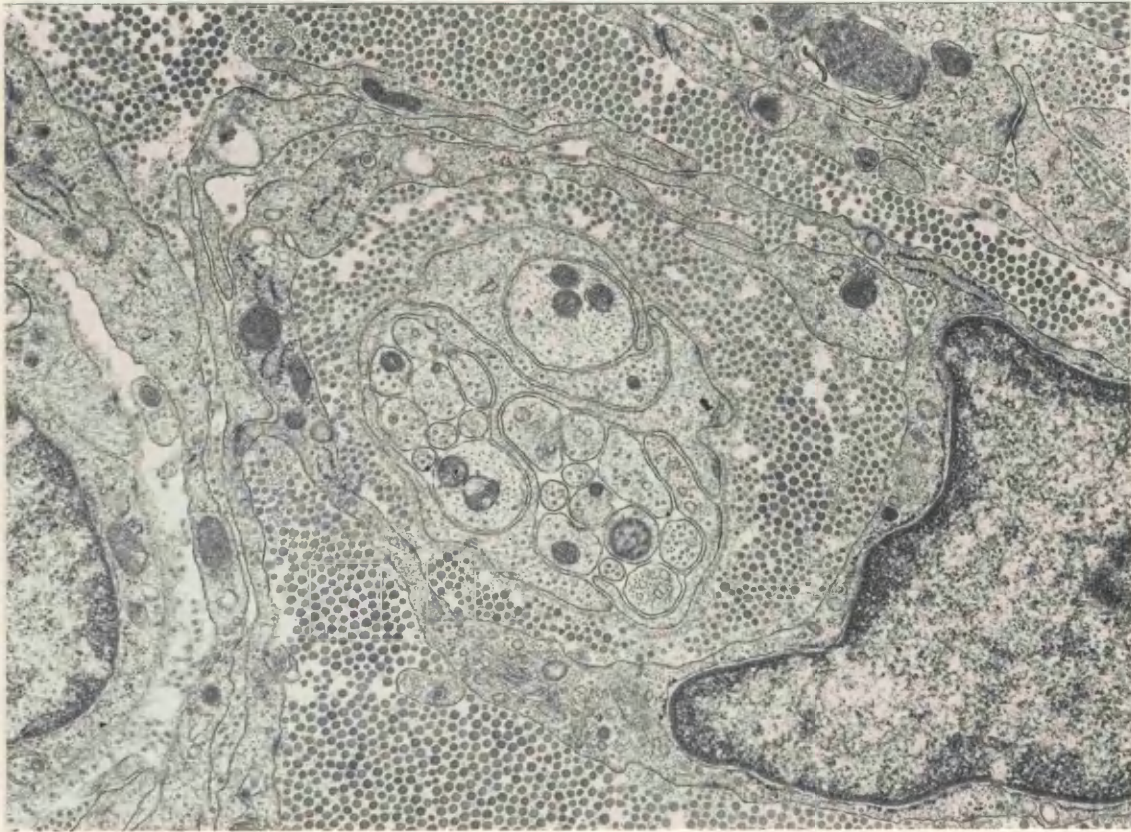


**FIGURE 72** 6 week neuroma, distal 1mm. Microfascicle containing axons, sprouts and Schwann cell cytoplasm. The organelle content is very similar in each profile, and it is difficult to differentiate between axoplasm and Schwann cell cytoplasm.

x 15 400

**FIGURE 73** 6 week neuroma, distal 1mm. Microfascicle containing small myelinated axon and another Schwann cell with several unmyelinated axons all within one basal lamina. This group is not surrounded by layers of perineurial type cells.

x 19 400



Individual units were often large.

The outgrowth more closely resembled that seen at 3-4 weeks following section, i.e. a central 'bulge' with unilateral outgrowth. 42 days following section there were two long outgrowths of mini-fascicles to one side, overlying each other. At one end of one of these outgrowths were closely packed small blood vessels. At 56 days following section, the neuroma was growing in between the muscle layers, so that some groups of muscle fibres were isolated in the plane of section examined from the adjoining muscle, and surrounded by rings of mini-fascicles of axonal sprouts. Many mini-fascicles around the edge of the outgrowth were more loosely packed, but those in the centre were very compact. The perineurium contained mast cells.

### 5.3 Proximal - point of section

The original nerve was now visible, with the perineurium consisting of several layers of small fascicles of new axonal growth. The fascicles here were very densely packed (Fig. 74). New growth could be seen within the original nerve and this new growth was especially evident all around the inner edges of the perineurium in the original nerve. New fibres here were organized into small fascicles like those seen in the perineurium, but without such obvious boundaries. Although a few fibres were still in the process of myelination (Fig. 75), generally the thickness of the myelin sheath in these fibres seemed to correspond well with the size of the axon, indicating that myelination was probably complete. Mast cells were present within the nerve trunk and the perineurium and epineurium.

#### 5.3.1 Unmyelinated axons

Few unmyelinated axons contained dcv, although some sympathetic

---

p.198.3.3.

"Plane of section artefact" refers to sympathetic axons being identified positively only if a labelled dcv was present in that particular plane of section.

myelinated fibres in the densely packed small fascicles. Some sympathetic axons still had larger than normal numbers of dcv, and one profile which was degenerating, containing ~~with~~ many large dense osmiophilic bodies was seen (Fig. 76). Many unmyelinated fibres were contained within Schwann cell subunits of normal size, although the individual axons were often large.



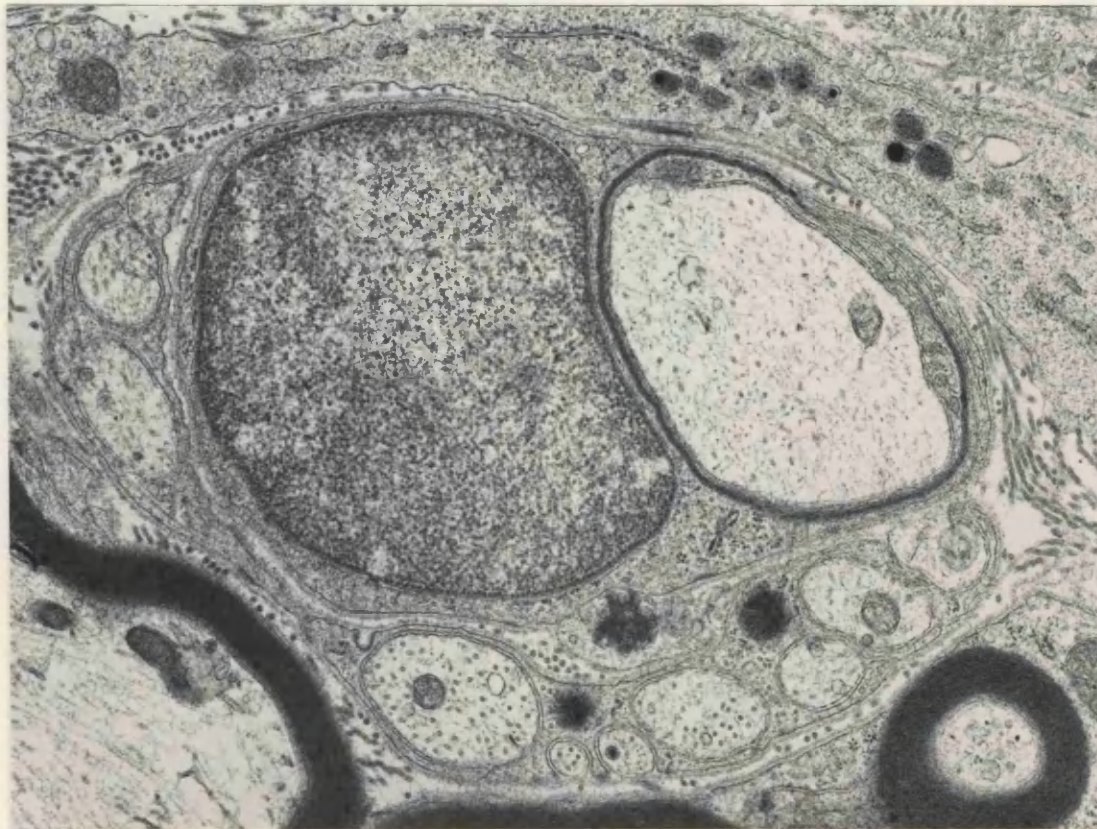
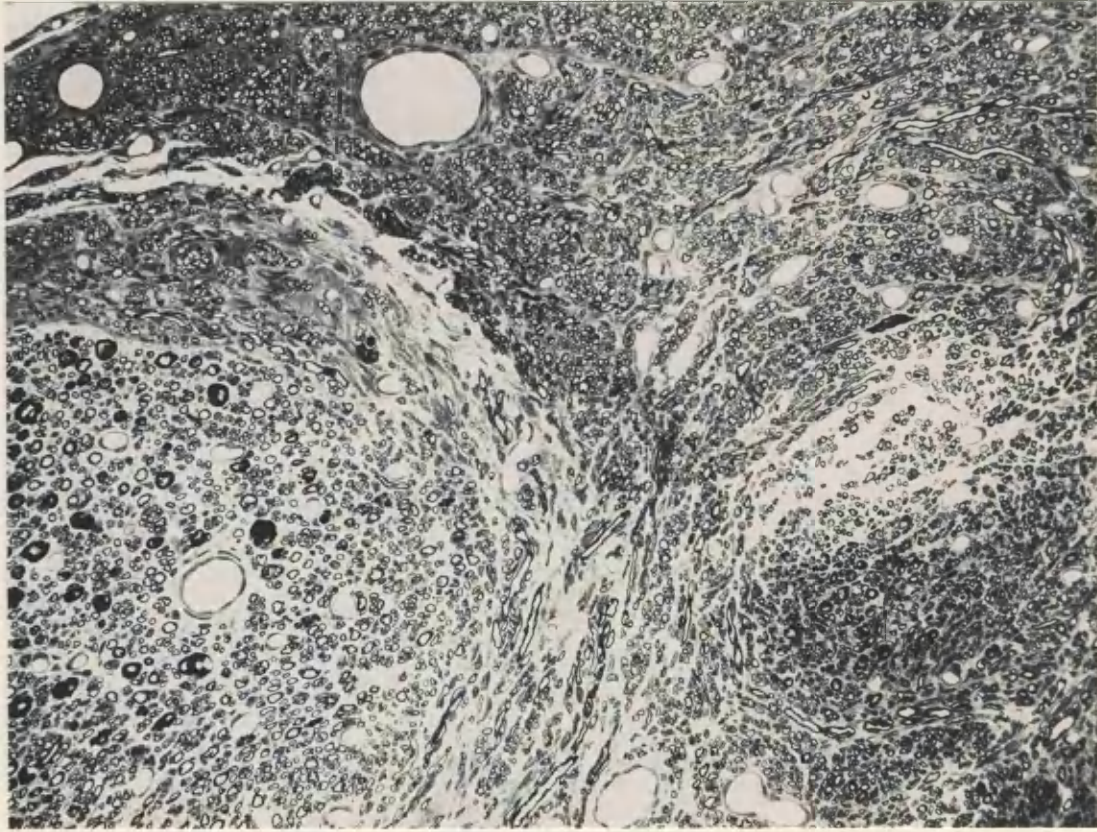
155

**FIGURE 74.** Neuroma 8 weeks following nerve section, 1mm from the distal tip. To the left, the original nerve still contains a few axons with thick myelin sheaths, but the majority of tissue in this micrograph is new regenerated tissue. This new tissue has a less uniform orientation than the older tissue, and the diameter of the myelinated axons is generally smaller. Glutaraldehyde / Resin / Toluidine blue.

x 155

**FIGURE 75** 8 week neuroma, distal 1mm. Small axon in the process of becoming myelinated, in close apposition with a group of unmyelinated axons, one of which is sympathetic.

x 22 000

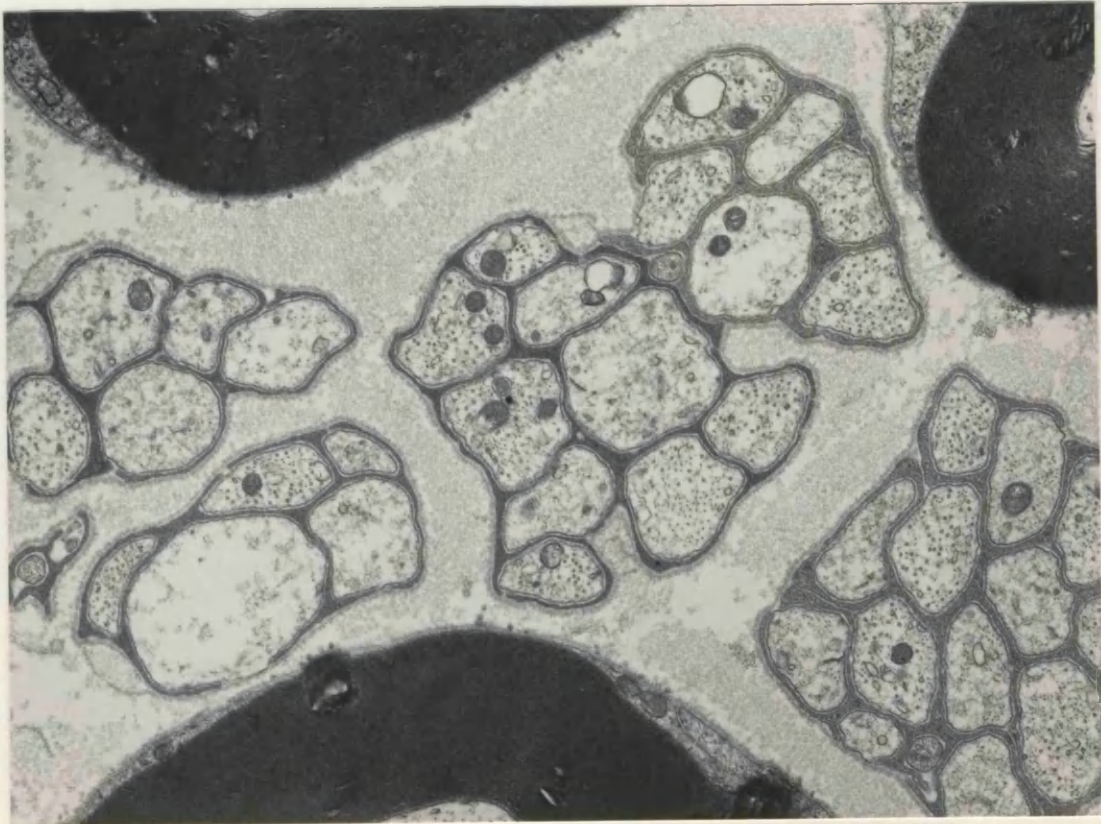
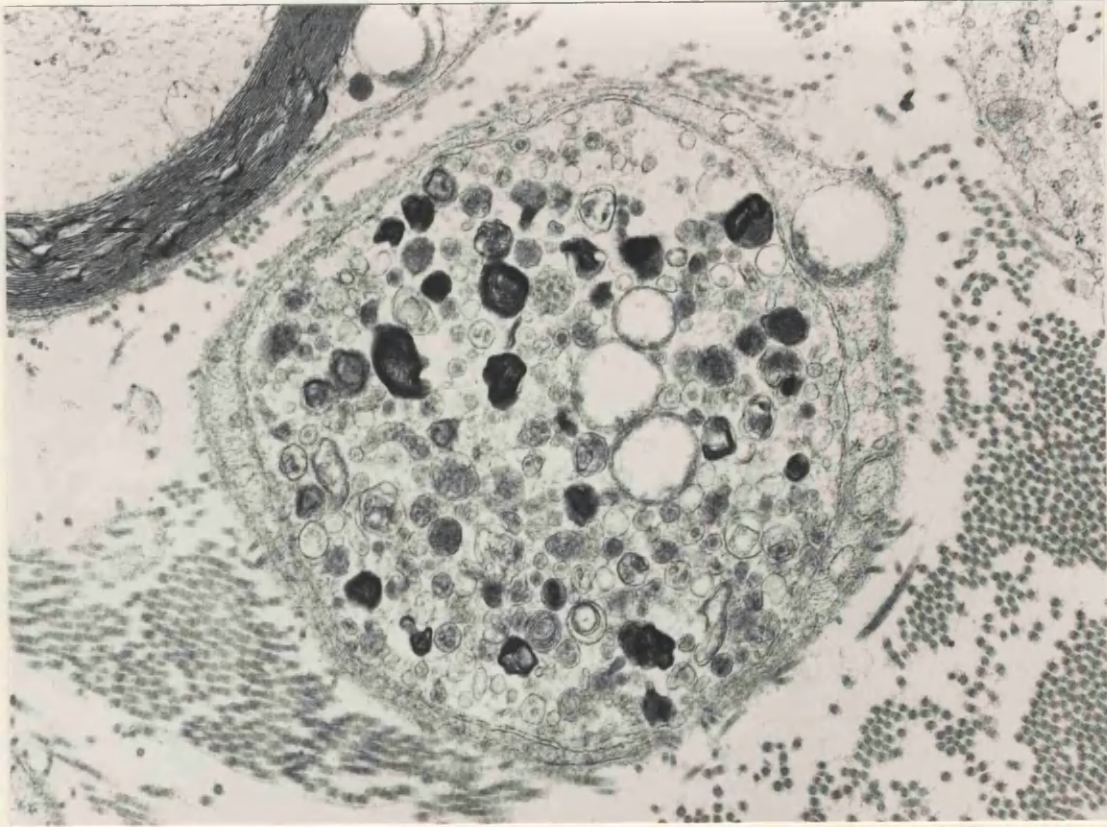


**FIGURE 76** 8 week neuroma, distal 1mm. An unusual unmyelinated fibre, containing large osmiophilic bodies of degenerate material and vesicles which have a slightly dense core.

x 21 500

**FIGURE 77** Normal rat sciatic nerve. Pretreated with nialamide and 5-OH DA, and fixed with chromate containing fixative. The density of the Schwann cell cytoplasm, which is due to the chromate content of the fixative, varies between subunits.

x 16 500



**TABLE 3**  
**COUNTS OF 5-OH DA LABELLED SCHWANN CELL SUBUNITS**  
**NORMAL NERVES**

Animal No.	Total Units	Labelled	Unlabelled	% Labelled
1	376	51	325	13.56
2	328	30	298	9.15
3	359	34	325	9.47
4	335	47	288	14.03
5	324	38	286	11.70
6	337	34	303	10.09

$$\bar{x} = 343.17 \pm 8.23$$

$$\bar{x} = 11.33 \pm 0.352$$

**3 DAY NEUROMAS**

1	253	135	118	53.36
2	233	98	135	42.10

## Summary of Ultrastructural Results.

1. Sympathetic axons, identified as unmyelinated fibres with characteristic dcv, could only be found in animals which had been pretreated with nialamide and 5-OH DA. Such axons were not common in normal sciatic nerves, indeed only 11% of Schwann cell subunits of unmyelinated axons contained positively identified sympathetic axons.
2. In acute neuromas, 3 and 7 days following nerve section, many axons containing large numbers of 5-OH DA labelled dcv could be identified. These sympathetic axons also contained accumulations of mitochondria, osmiophilic dense bodies, clear vesicles, microtubules and neurofilaments. Many axon sprouts, differentiated from axons on the basis of their small size, often containing dcv, were also seen in these neuromas.
3. Some of these sympathetic sprouts appeared to have penetrated beneath the basal lamina of myelinated fibres. Most of the myelinated fibres at the distal tip of the neuroma were degenerating by 7 days following nerve section.
4. In 14 day neuromas, 5-OH DA labelled sympathetic axons were rare. By 3 - 4 weeks after section, the sectioned nerves were taking on the appearance of chronic neuromas, the tissue being organized into small fascicles, with many axons in the process of myelination, divided by perineural type cells and densely packed collagen. Sympathetic axons could be identified in these chronic neuromas.
5. The ultrastructural changes in sympathetic axons mirrored those changes seen by fluorescence microscopy, although quantitative ultrastructural studies of the changes in numbers of sympathetic axons with time in neuromas were not undertaken.

### X-Ray Microanalysis

#### Generation of X-Rays

The shells of electrons in an atom of a particular element can be excited by an incident electron beam, and generate an X-Ray whose energy is characteristic of that element. The inner shell of electrons, the K shell, is the least energetic. Progressing outward from the nucleus, electrons in the shells have more energy, L, M, etc.

If an incident electron beam strikes the atom, it may 'knock out' one of the lowest energy electrons from the K shell, leaving an ionized atom. In order to stabilize the atom, an electron from one of the more energetic shells will take its place. There is a difference in potential energy levels between the two electron shells, and during the electron transition process an X-Ray photon representing the exact difference between the energy levels is emitted.

If the energy of electrons in the K shell is  $E_k$ ; the L shell  $E_l$ , the energy of an X-Ray emitted when an electron is knocked out from the K shell, and one from the L shell replaces it is  $E_l - E_k$ . This transition corresponds to the energy of the k alpha x-ray peak. A transition from the M to K shell produces the k beta peak, and so on. A series of lines which are characteristic for a particular element are thus produced. This is the X-Ray energy spectrum of an atom of that element which is unique to that element. The energy ( $E$ ) of the X-Ray is measured in Kilo-Electron Volts (KeV), and  $E = hf$ , where  $f$ =frequency of the X-Ray, and  $h$  = Planck's constant.

If the incident electron beam interacts with the nucleus rather than the outer orbital electrons of an atom in the specimen, it is decelerated by the nuclear charge. This energy loss from inelastic scattering is variable, ranging from the maximal energy of the incident electron beam  $E_0$  to zero. This variable loss of energy by many of the incident electrons, emitted directly as photons produces a background radiation spectrum or Bremsstrahlung, which is noncharacteristic. Characteristic X-Ray lines are superimposed upon this spectrum.

## Energy Dispersive X-Ray Microanalysis

The key component in the detection system for energy dispersive X-Ray spectroscopy is a lithium drifted silicon crystal, cooled to liquid nitrogen temperature. Impingement of an X-Ray upon this crystal causes ionization, i.e. the creation of an electron-hole pair. The number of such hole pairs created is proportional to the energy of the incident X-Ray, and so by a conversion factor, 3.8eV being required to generate each hole-pair, this characteristic energy can be calculated. To prevent contamination of the detector, and to reduce intrinsic thermal movements of electrons, the crystal is sited in its own vacuum system, cooled by liquid nitrogen, and X-Rays are admitted through a thin (8um) Beryllium window, although there are now thin window and windowless detectors available. Low energy X-Rays, below 1 KeV are absorbed by the Beryllium and thus in practice, elements lighter than sodium (Z=11) cannot be detected, which places many limitations on the detection of elements in biological samples.

Energy dispersive spectrometers can be placed close to the specimen, so that their collecting power is typically  $10^3$  to  $10^4$  times greater than that of the classical diffracting (or wavelength dispersive) spectrometer. The whole spectrum can also be analysed ~~s~~imultaneously, however because of the presence of the Bremsstrahlung background, the peak to background ratios are low. Overlap of adjacent peaks also occurs, which can be a particular problem in the separation of the peaks of lighter elements, however much computer software has been developed to overcome these latter problems.

### Specimen requirements

The requirements for microanalysis of biological specimens are that 1) the tissue must be in a form which will withstand high vacuum conditions and electron bombardment, 2) the tissue must be preserved in a state which bears a known relationship to the natural living state.

In practice, for examination in the TEM, these conditions may be satisfied if the tissue is either:-

a) Quench frozen in freon, isopentane, propane or nitrogen, all cooled to at least liquid nitrogen temperature; then sectioned and freeze-dried, or examined as frozen hydrated sections.



b) Conventionally fixed for electron microscopy, possibly following a histochemical precipitation step; dehydrated, embedded in resin and sectioned. It is with this type of preparation that I am concerned in this thesis.

The limit of spatial resolution of the analysis technique is in the order of 20-30nm, there being little spreading of the beam in thin sections. The resolution of the technique is approximately half the section thickness, however there is little to be gained in terms of improved resolution from much thinner specimens, since the amount of material available to generate X-Rays will also be much smaller, and therefore the signal will be generally poorer. The minimum detectable mass varies from  $10^{-16}$  to  $10^{-19}$ g, depending on operating conditions. Quantitative analysis may be undertaken if the thickness of the specimen is known, or if standards are used with which to compare the size of the elemental peak in question.

## **Materials and Methods Introduction 5**

### The Chromaffin Reaction

Noradrenaline cannot be detected by X-Ray microanalysis since all its constituent elements have atomic numbers below the detection limit of the system. However, it can be reacted with chromate/dichromate, which is then detectable at the sites in the tissue containing noradrenaline.

Henle (1865) first demonstrated the reaction of biogenic amines with chromate when he reported a brown colouration of adrenomedullary cells treated with chromate. The 'chromaffin' reaction was first attributed to the presence of adrenaline by Kohn (1902), but later also to other compounds such as aminophenols and polyamines, (Lison, 1936). The method was first used at the ultrastructural level by Wood and Barnett (1964), who later (Wood, 1966), proposed that the reaction does not differentiate between noradrenaline, adrenaline, dopamine and serotonin. The method has since been modified further, as ultrastructural preservation requirements become more exacting, notably by Tranzer and Richards (1976), who included low concentrations of glutaraldehyde in the primary fixative and buffered all steps in the procedure with chromium salts.

## Mechanism of reaction:-

Coupland and Hopwood (1966) showed that some biogenic amines will form stable Schiff monobases with glutaraldehyde. Wood (1974) and Nemes (1974) subsequently demonstrated that these monobase residues will bind hexavalent metals such as chromium. In the case of noradrenaline, it is the unsubstituted amino group of the molecule which reacts with the aldehyde groups of the glutaraldehyde fixative. The two other hydroxyl groups of the aromatic ring in the noradrenaline then react with dichromate ions, and thus an electron dense compound is formed.

Not all biogenic amines react in this way, and Coupland and Hopwood (1966); Santer et al (1978); and Lever et al (1977) demonstrated differential yellow cytoplasmic colouration in adrenomedullary cells containing noradrenaline but no colouration in adrenaline containing cells.

The fixation of chromium at sites in tissue which contain noradrenaline was first detected by electron probe X-Ray microanalysis by Wood et al, (1971); Wood (1974, 1975). Further studies by Lever et al (1977) and Santer et al (1978) have detected noradrenaline in granules of the Type II cells of rat sympathetic ganglia. Rose et al (1979) subsequently studied chromium binding of a variety of monoamines by both X-Ray microanalysis and Sephadex binding studies, and concluded that 1-dopa, dopamine, noradrenaline and 5-hydroxytryptamine will bind chromium, but that adrenaline and histamine will not. Thus exogenously administered amines such as 5-hydroxy dopamine will bind chromium, and can augment the visualization of noradrenaline sites. Tissues used in this study included rat adrenaline medulla, sympathetic ganglia, carotid body glomus cells and duodenal mucosa.

## Materials and Methods 4 and 5

### Modified chromaffin reaction preparation for X-Ray microanalysis

The original chromaffin method of Henle (1865) described the brown staining of adrenomedullary cells after treatment with potassium dichromate solution. This method has been modified by Woods (1969) for the localization of noradrenaline in the electron microscope, but better preservation of tissue and localization of noradrenaline is obtained by using the modified chromaffin reaction of Tranzer and Richards (1976). Localization of chromate as a marker for noradrenaline is then possible by this method.

Following surgical section of the left sciatic nerve in 10 Wistar rats and 4 CBA mice as previously described, neuromas were allowed to develop on the proximal stumps. At 3 days, 3 weeks, 4 months, or 8 months following nerve section, all the animals were dosed with nialamide and 5-OH DA as described above. 2 control rats with 3 day old neuromas were just anaesthetized and immerse fixed or perfused with chromium fixative. All the other animals were anaesthetized and either perfused or immerse fixed as detailed below following pretreatment.

Perfusion fixation was carried out as previously described, but with a primary fixative solution of 3% glutaraldehyde and 0.4% paraformaldehyde in 0.1M sodium chromate/potassium dichromate buffer, at pH 7.2 and 4°C.

During excision of the left and right sciatic nerves and the following dissection, tissues remained in the primary fixative for a period not exceeding 2 hours, to prevent deterioration of the monoamine-chromium reaction product by the presence of the aldehydes.

Tissues were then transferred to 0.2M chromate/dichromate buffer, pH 6, to which 7% sucrose had been added, and immersed in this buffer overnight at 4°C, with continuous agitation. Tissues were then washed in 0.1M chromate/dichromate buffer, pH 7.2, and post fixed in 2% osmium tetroxide solution in this buffer vehicle at room temperature. Following this post fixation, tissues were processed and embedded in epon resin for transmission electron microscopy in the conventional manner.

207

For non-perfused animals, the left and right sciatic nerves were exposed and immerse fixed in situ with 3 x 5 minute changes of the primary fixative solution at 4°C. Following excision of the nerves, fixation and processing was completed as above.

0.5um sections were cut on a Reichert Ultracut ultramicrotome, and stained with 1% toluidine blue in 1% borax solution, for light microscope localization of suitable areas of tissue for ultrastructural analysis. Following this, 100-120nm thick sections (gold interference colours on the Peachey scale) were cut and mounted on 300 mesh thin bar copper grids for X-Ray microanalysis. Sections were examined either unstained, or stained for 10 minutes in Reynold's lead citrate solution.

Analysis was carried out using a Link AN 10/85S electron probe microanalysis attachment on a Jeol 1200 CX transmission electron microscope. Counts of emitted X-Rays were made for 2 x 100 seconds. Between these counting periods, the location of the probe was checked to see whether it had drifted away from the area of interest. The sensitivity of the X-Ray collection was in the 0 - 20KeV range.

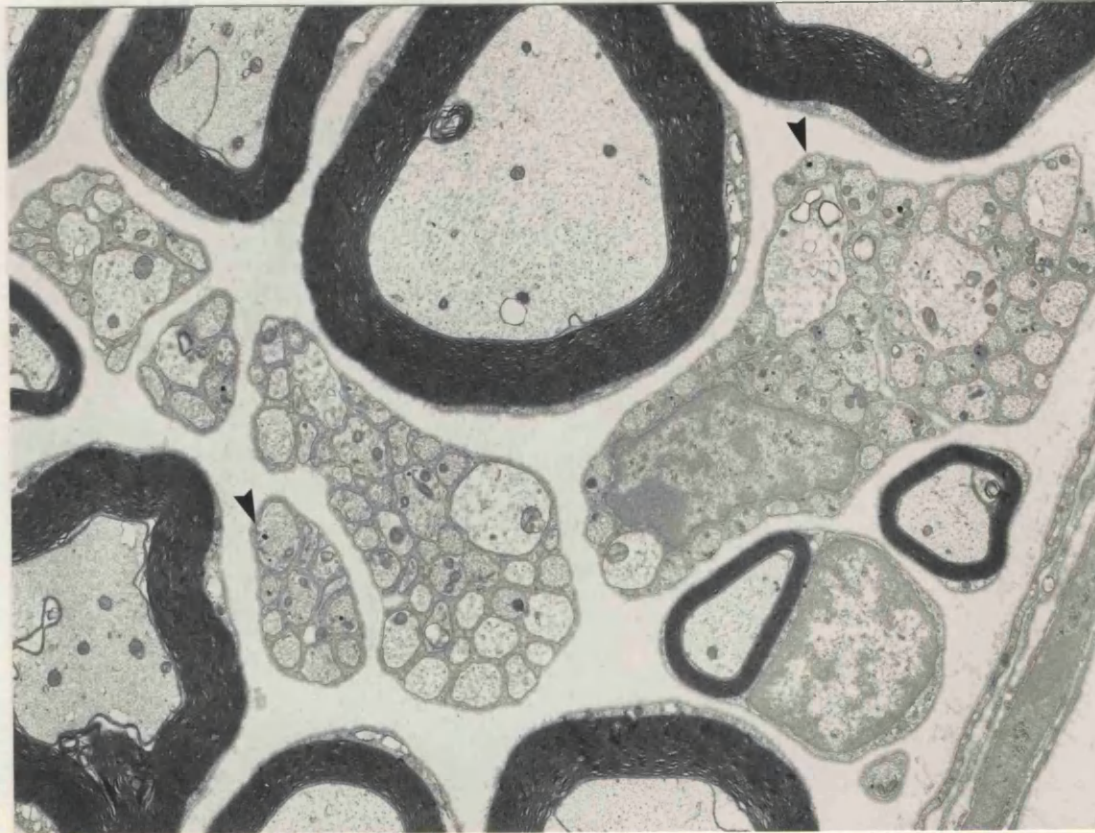
Chromaffin studies/X-Ray analysisA. Chromium labelling - Normal nerves

All sections of tissue from animals which had been fixed with chromium buffered fixative were stained with lead citrate only. Thus the collagen in all these sections was only very lightly stained, and appeared to be very indistinct. The rest of the tissue generally had more contrast, due to both the lead-only staining, and also the staining properties of the chromate fixative.

The most noticeable difference between tissue fixed routinely by glutaraldehyde and paraformaldehyde fixatives and that fixed by chromium buffered fixatives was an increase in the density of Schwann cell cytoplasm and in some cases, the nucleus. The cytoplasm surrounding some groups of unmyelinated axons was homogenously very electron dense, although this varied between groups. In some bundles, there appeared to be two groups of different origin, since there were two quite different densities of Schwann cell cytoplasm (Fig. 77). The density of the cytoplasm of some Remak bundles was no different to that from nerves fixed in glutaraldehyde/paraformaldehyde. The Schwann cell cytoplasm of myelinated fibres was rarely more densely stained than those of routinely fixed tissue.

Preservation of the tissue was generally good, whether perfused or immerse fixed. The myelin lamellae of myelinated fibres were only slightly disrupted. There was, however, some shrinkage and crenation of membranes, which was particularly noticeable in the unmyelinated fibres (Fig. 78). This may have been due, in part, to the immersion of the tissue overnight with a pH 6 buffer. The basal laminae around groups of unmyelinated fibres were generally slightly loosened, indicating tissue shrinkage. This effect was more pronounced around bundles in which the Schwann cell cytoplasm was densely stained.

Dcv in sympathetic axons in tissue fixed with chromate fixative were slightly denser than those in tissue fixed with glutaraldehyde / paraformaldehyde only. Dcv were more electron-dense following both chromate fixation and pharmacological treatment (Fig. 78) than with just nialamide and 5-OH DA treatment. What appeared to be labelled dcv



**FIGURE 78** Normal rat sciatic nerve. Pretreated with nialamide and 5-OH DA, and fixed with chromate containing fixative. Some unmyelinated axons contain highly electron dense dcv (arrows). The membranes of the unmyelinated axons and the myelin are slightly crenated, which is an artefact of the fixation procedure. The endoneurial collagen has very little contrast because the tissue has been stained with lead citrate only.

x 8 600

The cytoplasmic processes of some fibroblasts and perineurial cells around microvasculature were also very black in some cases, but

were again seen in Schwann cell cytoplasm. A few very dense small black 'blobs' which represent calcium accumulations were seen within mitochondria, but these were not purely a product of chromate fixation since they could be identified in tissue fixed conventionally.

## B. Neuromas

The most striking difference between chromate and conventionally fixed neuromas was again the extreme electron density of the Schwann cell cytoplasm of some subunits. In a similar pattern to that seen in normal tissue, not all the subunits contained electron-dense cytoplasm (Fig. 79). Lysosome-like granules were seen to have a dense 'halo' of particles, which was more pronounced in tissue in chromium fixative.

Dcv in sympathetic axons were extremely electron dense and numerous in acute neuromas 3 days after nerve section (Fig. 79). They were often completely filled with electron-dense material, thus a halo was not visible. The two populations were very clearly demarcated. A few of the large dcv often appeared to be swollen to a maximum size of 120-130nm, instead of 100nm which is the norm. The larger dcv were often elongated in shape, or appeared to have a 'tail'. A few dcv were paler than the others, not so heavily labelled with chromate.

The appearance of the tissue otherwise was very similar to that of conventionally fixed 3 day neuromas. Some sympathetic axons were seen within the basal laminae of myelinated fibres. Dcv which appeared to be labelled were also occasionally seen within fibroblasts. Platelets within the blood vessels of immerse fixed tissue contained two populations of granules, one type contained very electron dense precipitates in chromate fixed material.

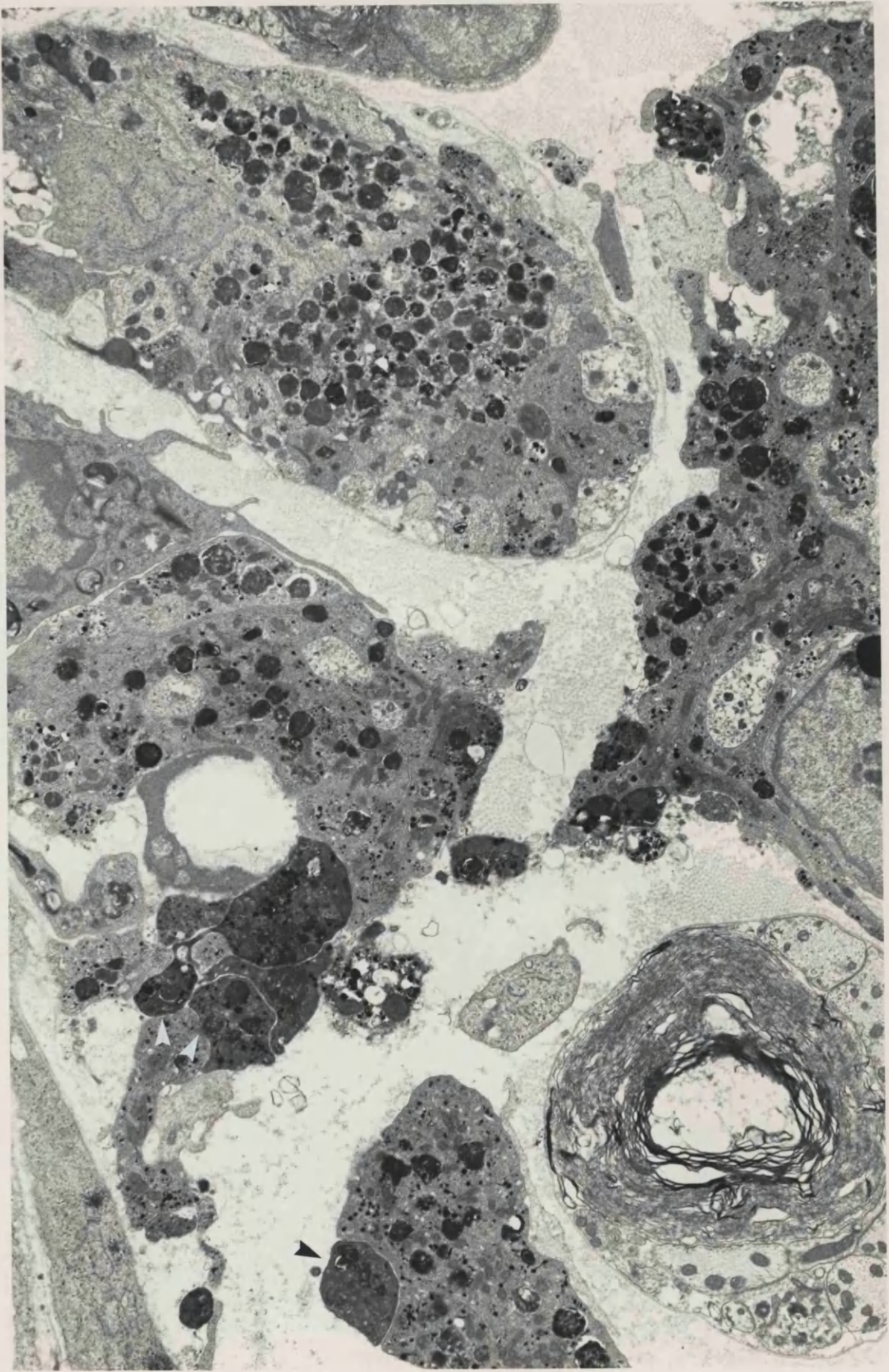
In the more chronic neuromas 3 weeks after nerve section, cytoplasm of some Schwann cells was extremely dense, almost black in some cases, obscuring cellular detail (Fig. 80). The axoplasm of axons within these bundles, however, was still very light, and this method may be a means of differentiating between axons and processes of Schwann cell cytoplasm in some instances. However, it could not be infallible, because not all Schwann cells stain in this way.

The cytoplasmic processes of some fibroblasts and perineurial cells around microfascicles were also very black in some cases, but

**FIGURE 79** 3 day neuroma, distal 1 mm. Pretreated with nialamide and 5-OH DA, fixed with chromate containing fixative. Most axons and sprouts contain very dense dcv, and in all cases the halo around the central core cannot be distinguished, giving the appearance of a 'filled' vesicle. Some vesicles also have an elongated appearance. Some axoplasm appears to be particularly dense (arrow).

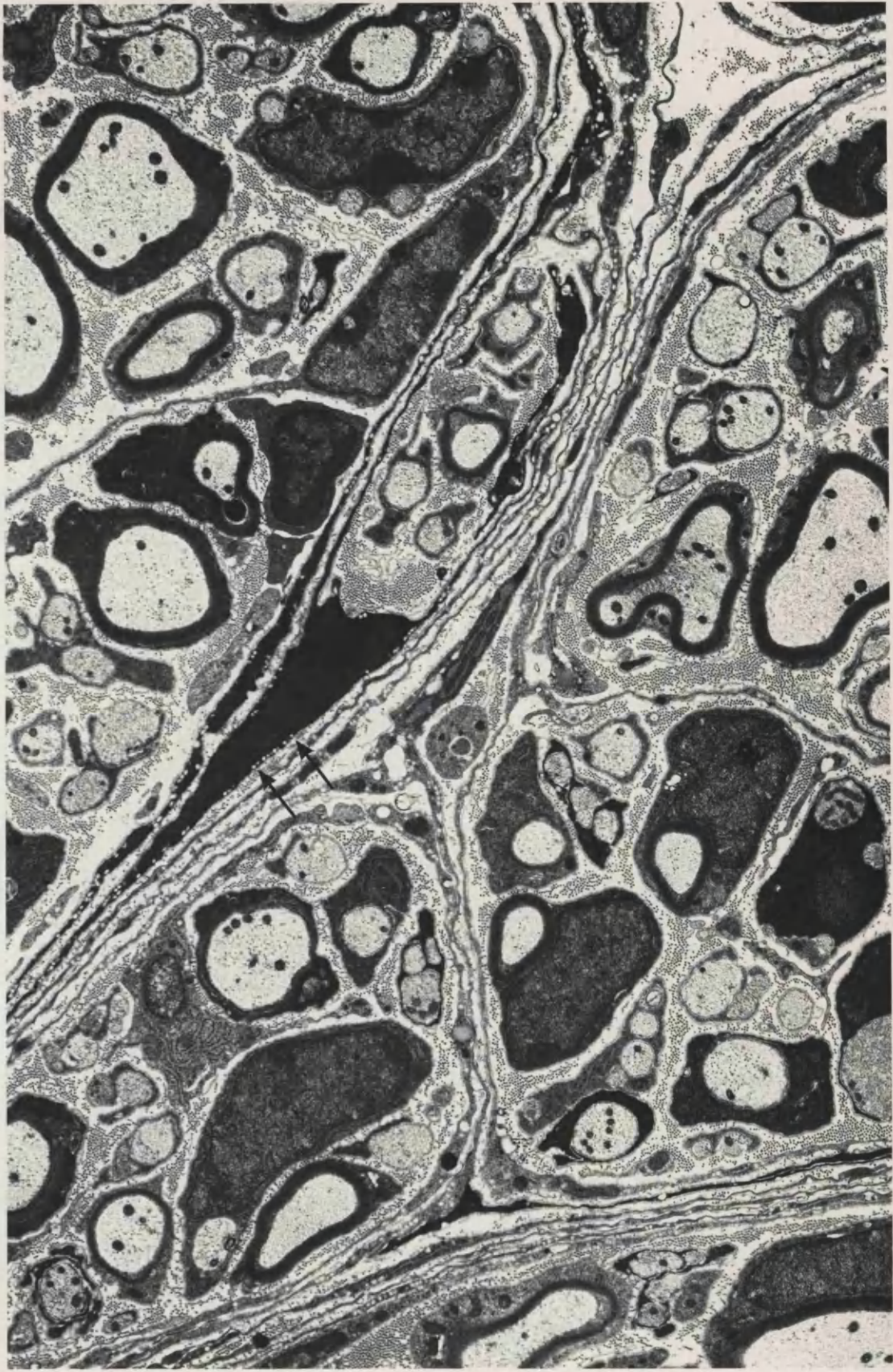
x 8 400





**FIGURE 80** 21 day neuroma, distal 1mm. Chromate fixative. The cytoplasm of the fibroblast processes surrounding the small fascicles are very densely stained by the chromate fixative, and the caveolae intracellulares are prominent (arrows). Schwann cell cytoplasm is also very densely stained.

x 7 200



again, not uniformly so. There seemed to be more of the densely staining Schwann cells and fibroblasts towards the distal tip of the neuroma, and fewer in the more proximal tissue. Densely labelled dcv could be identified within unmyelinated axons, and the neuromas were very similar in appearance to those conventionally fixed.

The most chronic neuromas (4 and 8 months after nerve section) showed similar changes to those outlined above. At the distal tip of these neuromas, most of the Schwann cell cytoplasm of unmyelinated fibres was densely stained. In some small fascicles, the cytoplasm of all the Schwann cells was highly electron dense. Most of the processes of the perineurial cells around the fascicles were densely stained too. The vacuoles, caveolae intracellulares, of these processes were very numerous, and were well contrasted against the dark background (Fig. 80). Cellular processes around the endothelium of blood vessels were also densely stained.

### C. X-Ray analysis

Characteristic X-Ray spectra obtained from tissue sections of these nerves always included large peaks from the following elements:

- 1) Copper - mainly contributed by the grid material,
- 2) Osmium - from the secondary fixative solution,
- 3) Lead - from the lead citrate counter stain.
- 4) Chlorine - from the epoxy resin

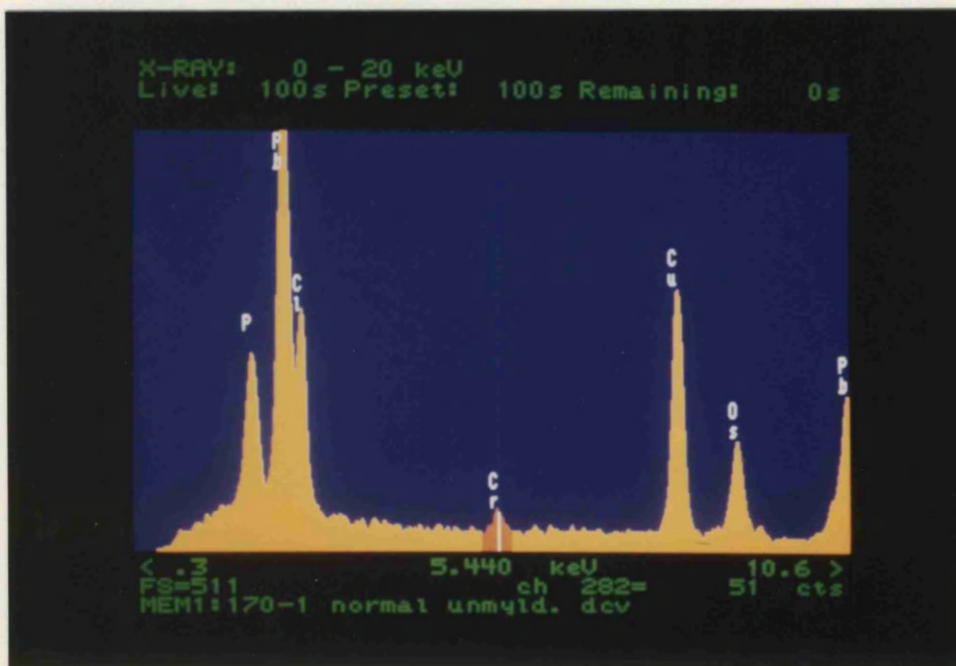
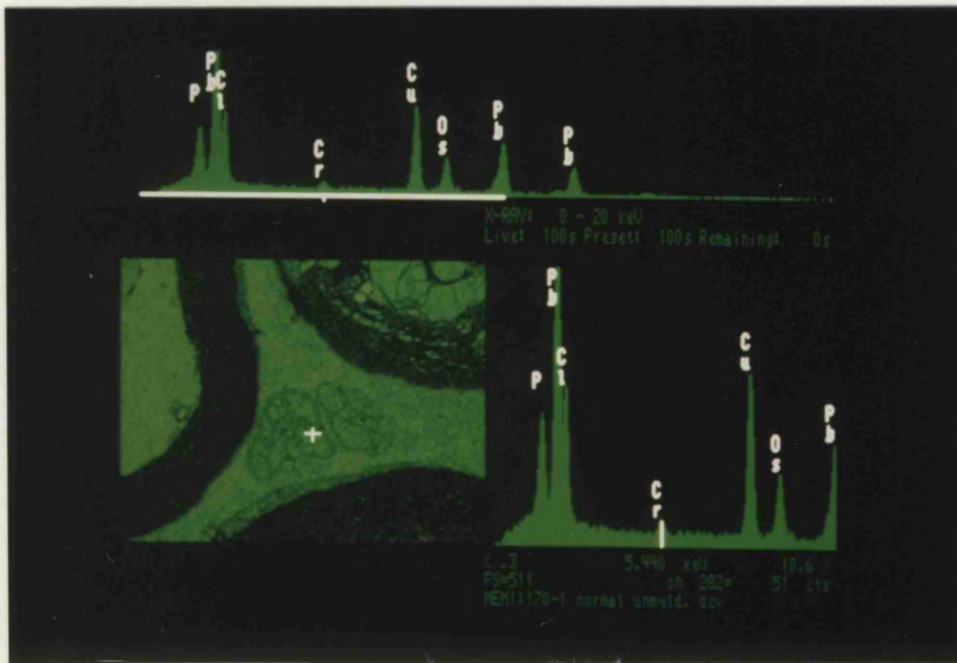
Other peaks from biological elements such as calcium and phosphorous were sometimes collected.

There was a flat background Bremsstrahlung in the area of interest, between 4.0 and 7.0Kev, the K-alpha peak for chromium is at 5.44Kev. K-alpha peaks corresponding to chromium were detected from single labelled dense-cored vesicles in sympathetic axons of normal sciatic nerve (Figs. 81 and 82). These peaks were much lower than those of the copper and osmium peaks (Fig. 83). Very small chromium peaks were detected from axoplasm and collagen. These small peaks, just above background radiation levels, were probably obtained from these non-labelled structures because chromium was bound to cross-linked proteins by the glutaraldehyde in the primary fixative. Slightly

All spectra and micrographs in Figs. 81 to 92 are taken from animals pretreated with nialamide and 5-OH DA, the tissue then fixed in 3% glutaraldehyde, buffered with solutions of chromate/dichromate salts and subsequently processed by the modified chromaffin method (Lascar, 1980).

**FIGURE 81** X-Ray spectrum of a 5-OH DA labelled dcx and electron micrograph showing the area sampled, in a normal sympathetic unmyelinated axon. The chromium peak collected from the dcx can be clearly distinguished. In addition, peaks collected from osmium and lead, elements which were used in the preparation of the tissue; copper from the supporting grid and chlorine from the embedding medium, are also present.

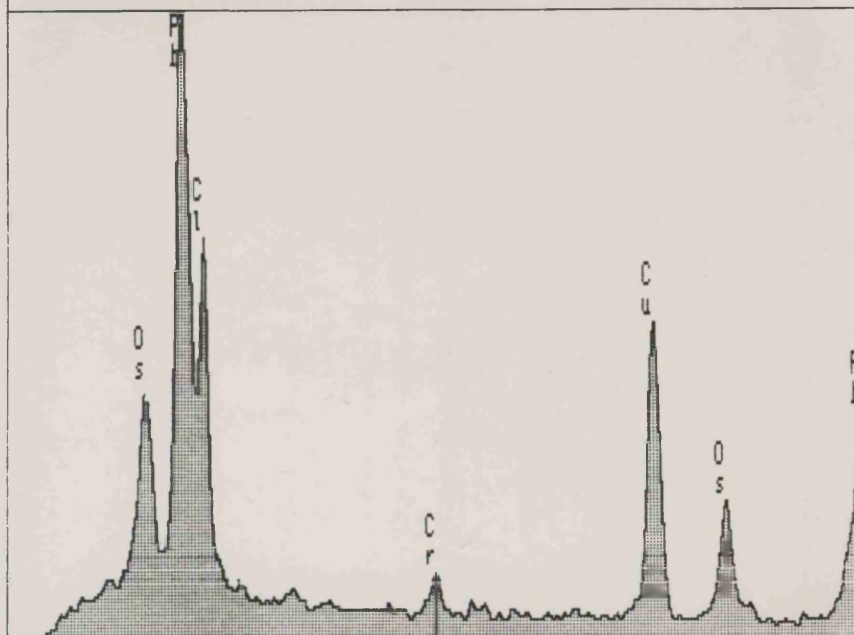
**FIGURE 82** Full screen image of spectrum in Figure 81.



**FIGURE 83** X-Ray spectrum print-out from a 5-OH DA labelled dcx in a normal sympathetic axon. Taken from a different animal to that in Figs. 81 & 82.

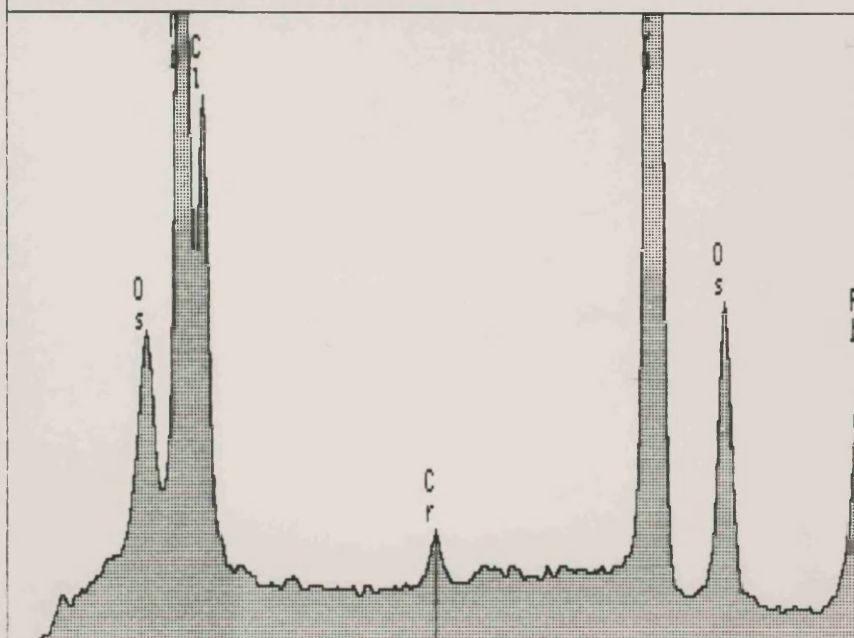
**FIGURE 84** X-Ray spectrum from a nucleolus in a nucleus of a Schwann cell. The tissue of the nucleolus contains a small amount of chromium, probably as a result of the chromatin being osmiophilic and having an affinity for stains, and therefore binding chromate ions.

X-RAY: 0 - 20 keV  
 Live: 100s Preset: 100s Remaining: 0s



< .3 5.440 keV 10.6 >  
 FS=511 ch 282= 54 cts  
 MEM1:170-1 dcw normal unmyld.

X-RAY: 0 - 20 keV  
 Live: 200s Preset: 100s Remaining: 0s



< .3 5.440 keV 10.6 >  
 FS= 2K ch 282= 377 cts  
 MEM1:M9-2/1 Chromate fix. nucleolus

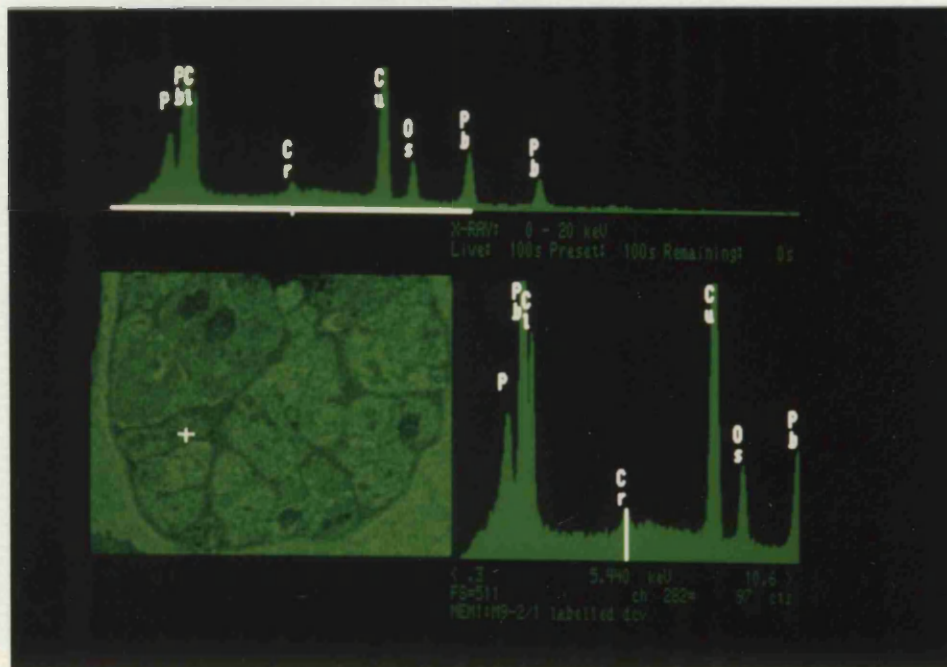


larger peaks for chromium were detected from the dense Schwann cell cytoplasm, indicating that the increased electron density of these cellular components was due to chromium staining. Nuclei in the sections examined also gave small chromium peaks (Fig. 84). The osmium peaks for these structures were also smaller, because they were not highly osmiophilic structures.

Large X-Ray peaks, characteristic of chromium, were detected from labelled large and small dcv in unmyelinated axons of neuromas, identified as sympathetic (Fig. 85). If the K-alpha peak was very large, a small K-beta peak was sometimes also detected, to the right (higher Kev) of the K-alpha peak (Figs. 86 and 87). The variability of the size of the peaks was probably partly a stereological effect, depending on the volume of the vesicle contained within the tissue section. Chromium peaks were again detected from small single labelled dcv in small axonal sprouts, proving this to be a sensitive technique. Peaks for chromium were also detected from single dcv in chronic (4 and 8 month old) neuromas.

Other dense bodies, such as dcv without any 5-OH DA label and lamellar bodies of axonal debris did not give significant peaks for chromium. Slightly higher peaks for chromium were detected from the axoplasm of axons containing labelled dcv than from unlabelled axons (Figs. 88 and 89). It is possible that this may have been an effect of the displacement of noradrenaline from the dcv into the axoplasm, by 5-OH DA, and its subsequent non-metabolism by the blocked monoamine oxidase enzymes, but this difference in peak heights may have been merely an artefact due to variations in the thickness of the section. Very few analyses of these areas were done, so it is not possible to be conclusive about these small differences in peak heights.


Labelled dcv in the unmyelinated axons surrounding blood vessels also gave large peaks for chromium (Figs. 90 and 91), as did the dense granules which probably contained 5-hydroxy tryptamine in platelets (Fig. 92).



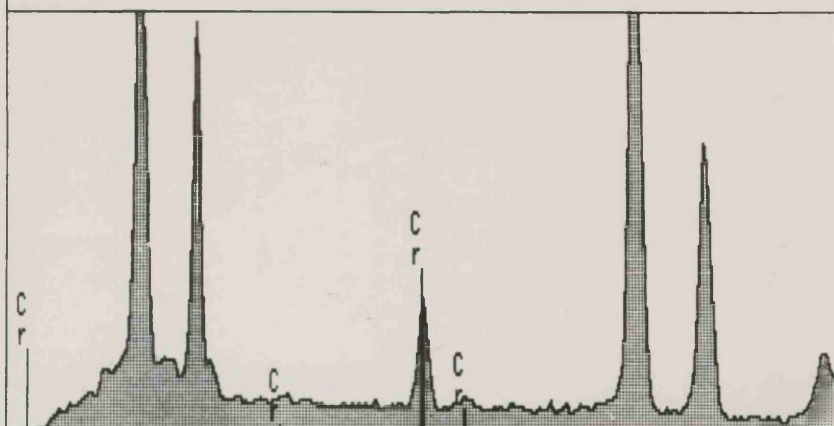
**FIGURE 85** X-Ray spectrum of a 5-OH DA labelled dcv and electron micrograph showing the area sampled, from a sympathetic axon in the distal tip of a three day old neuroma.

**FIGURE 86** X-Ray spectrum print-out from a 5-OH DA labelled dcv from a sympathetic axon in the distal tip of a three day old neuroma, from the same animal as Fig. 85. The K-beta peak for chromium can be seen in this spectrum, to the right of the K-alpha peak.

**FIGURE 87** X-Ray spectrum print-out from a 5-OH DA labelled dcv from a sympathetic axon in the distal tip of a three day old neuroma. Taken from a different animal to that in Fig. 85. Both the K-beta and K-alpha peaks are visible.

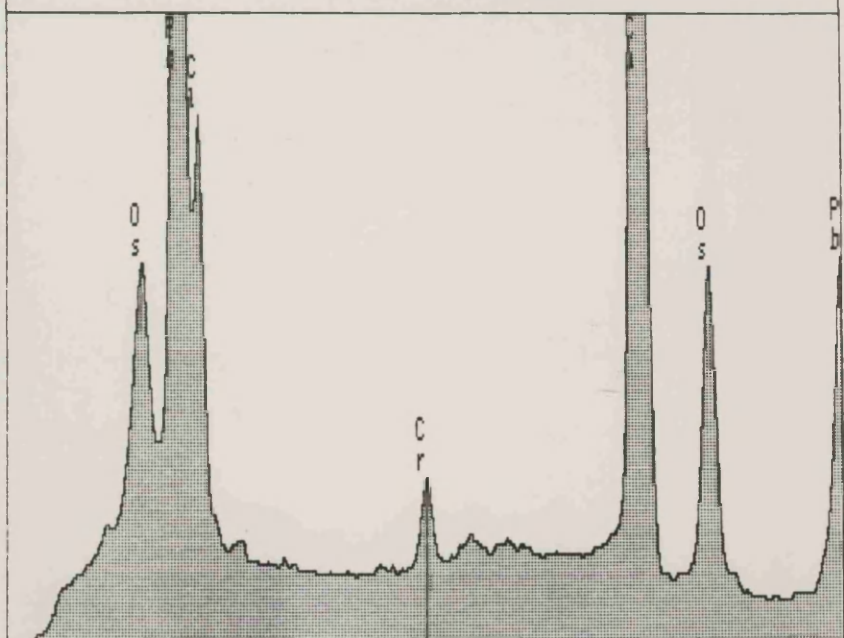


X-RAY: 0 - 20 keV  
 Live: 100s Preset: 100s Remaining: 0s



< .3 5.440 keV 10.6 >  
 FS=511 ch 282= 167 cts  
 MEM1:170-2/1 dcv

X-RAY: 0 - 20 keV  
 Live: 200s Preset: 100s Remaining: 0s



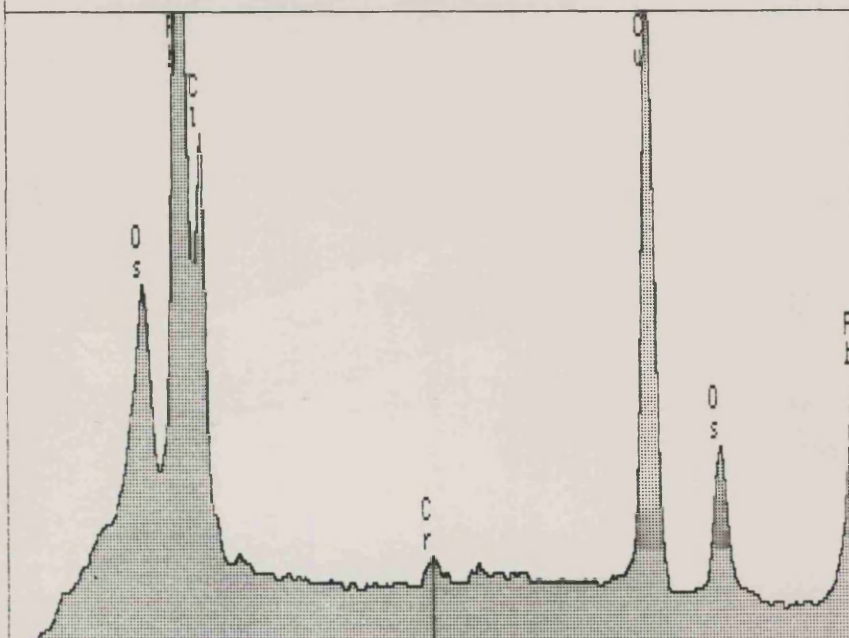
< .3 5.440 keV 10.6 >  
 FS= 2K ch 282= 543 cts  
 MEM1:M9-2/1 Chromate fix dcv

**FIGURE 88** X-Ray spectrum from the axoplasm of a sympathetic axon in a 3 day neuroma. A small chromium peak has been collected.

**FIGURE 89** X-Ray spectrum from the axoplasm of an unmyelinated axon, adjacent to that in Fig. 88, which did not contain any labelled dcv. This chromium peak is smaller than that in Fig. 88, but this is probably not significant.

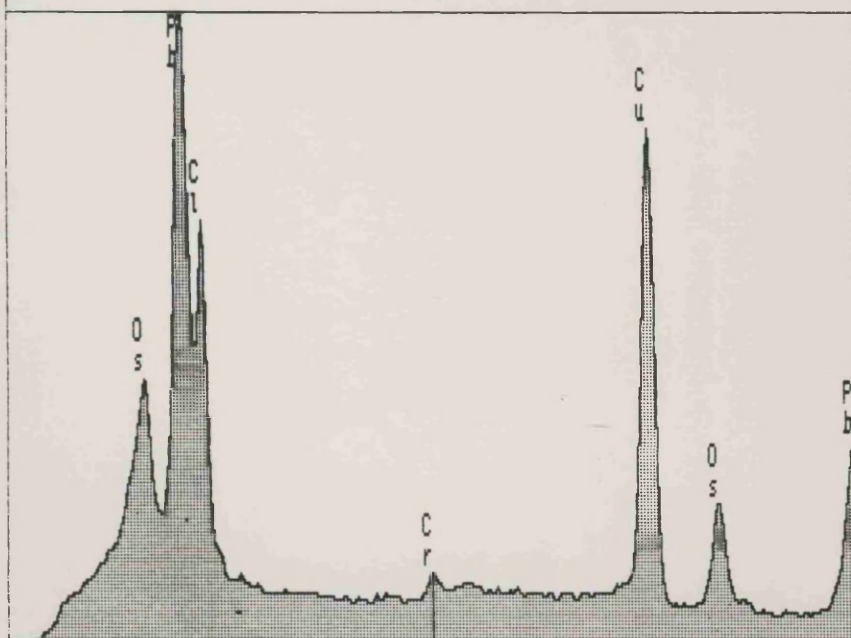
The chromium peaks in both Figs. 88 and 89 may represent a background level of chromium which results from the tissue being fixed with primary and secondary fixative solutions which both contained chromate ions.

X-RAY: 0 - 20 keV  
 Live: 200s Preset: 100s Remaining: 0s



< .3 5.440 keV 10.6 >  
 FS= 2K ch 282= 285 cts  
 MEM1:M9-2/1 Chromate fix axoplasm dev

X-RAY: 0 - 20 keV  
 Live: 200s Preset: 100s Remaining: 0s



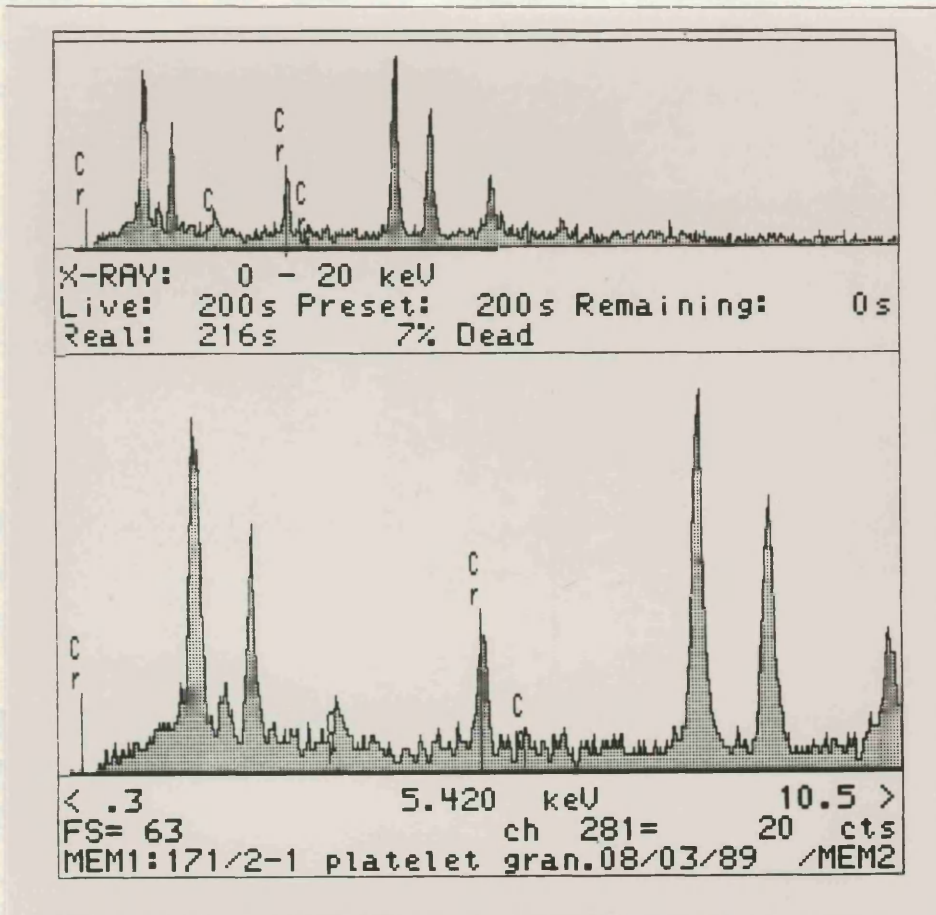
< .3 5.440 keV 10.6 >  
 FS= 2K ch 282= 227 cts  
 MEM1:M9-2/1 Chromate unlab. axoplasm

**FIGURE 90** X-Ray spectrum of a 5-OH DA labelled dcx and electron micrograph showing the area sampled, from a sympathetic axon innervating a blood vessel in the perineurium of a three day old neuroma.

**FIGURE 91** Print-out of the full screen image of the spectrum in Fig. 90.







**FIGURE 92** X-Ray spectrum from a dense granule in a platelet, probably containing 5-HT, which has reacted with chromate ions to form a dense precipitate. Taken from a blood vessel in a three day old neuroma.

## Summary of X-Ray Analysis Results

Normal nerves and neuromas were fixed with a chromate containing fixative and electron probe X-Ray microanalysis was performed on sections from these tissues.

1. The dcv in sympathetic axons in tissue fixed with chromate containing fixative were slightly denser than those in tissue fixed with glutaraldehyde/paraformaldehyde only. Dcv were more electron dense following both pharmacological treatment, with nialamide and 5 - OH DA, and chromium fixation than with pharmacological treatment only.

2. Following this combined schedule, dcv were easily identified in sympathetic axons in normal nerves. Schwann cell cytoplasm was also stained with the chromate fixative, and this density varied between subunits.

3. In neuromas, NA containing dcv were extremely electron dense, and very numerous. Schwann cell cytoplasm, fibroblast processes and perineurial cell processes all appeared to be stained by the chromate fixative.

4. X-Ray peaks, characteristic of chromium, were detected from single large and small labelled dcv in sympathetic axons in normal nerves, acute and chronic neuromas, proving this to be a very sensitive method. Chromium could not be detected in dcv which were not labelled with 5 - OH DA, or from other dense bodies. Chromium peaks could also be detected from stained Schwann cell cytoplasm.

5. Peaks from chromium could also be detected from dense granules in platelets, presumably due to the chromaffin reaction of 5 - hydroxy tryptamine.

6. All electron probe X-Ray microanalysis spectra from tissue sections also contained large peaks from copper, osmium, lead and chlorine, from the supporting grid and preparative methods.

## Materials and Methods Introduction 6

### Mode of action of Guanethidine

Guanethidine is taken up by storage vesicles in noradrenergic nerves, following administration, and displaces noradrenaline from the vesicle. The concentration of guanethidine then builds up at these sites, and prevents re-uptake of the released noradrenaline from the synaptic cleft (Bowman and Rand, 1982). Persistence of guanethidine at these sites also prevents further release of noradrenaline, and a profound sympathetic block is established (Hannington-Kiff, 1984). Guanethidine thus has a biphasic effect - i) an initial release phase due to displacement from the dcv, ii) followed by block of reuptake mechanisms and further release of noradrenaline.

Repeated administration of guanethidine leads to a prolonged block, because guanethidine accumulates in the nerves, and acts as a false transmitter, being released following nerve stimulation (Nickerson and Collier, 1975). Eventually, in sufficient concentration, guanethidine can cause permanent damage to the noradrenaline re-uptake 'pump'. In large doses, guanethidine will cause a permanent chemical sympathectomy. Large doses in experimental animals in the order of  $30\text{mgkg}^{-1}$  can cause axon retraction, whereby sympathetic nerve endings withdraw from their effector sites (Burnstock and Costa, 1975). Hannington-Kiff (1984) suggests that this effect may occur clinically in patients treated by a Bier type block for local neuralgic pain. Guanethidine is also thought to have a local anaesthetic action.

## Materials and Methods 6

### Guanethidine

The left sciatic nerves of 36 animals were sectioned, and neuromas allowed to develop for 3 and 7 days, 3 and 8 weeks, and 7 months, as previously described. Animals were then dosed with guanethidine, (Ismelin ampoules;  $10\text{mgkg}^{-1}$  guanethidine monosulphate, CIBA, Horsham, West Sussex)  $30\text{mgkg}^{-1}$ , by i/p injection, according to the following schedule:-

Dosage days (inclusive)

3 day neuromas	1 - 3
7 day neuromas	1 - 4
	4 - 7
3 week neuromas	4 - 9
	17 - 21
8 week and 7 month neuromas	consecutive 5 days before killing

Doses of guanethidine on day one of surgery were given on recovery from anaesthesia. Doses of guanethidine on the day of death were given 4 hours prior to killing.

The left and right sciatic nerves from these animals were either prepared for glyoxylic induced fluorescence microscopy by freezing, or for transmission electron microscopy by perfusion with 3% glutaraldehyde in 0.1M sodium cacodylate buffer following pretreatment with nialamide and 5-hydroxydopamine as previously described. Sciatic nerves prepared for freezing were mounted in normal liver from untreated animals, to serve as an in situ control for the fluorescence method. Any absence of fluorescence in the nerves could be compared to the presence of fluorescence in the innervation of the hepatic vessels, and thus the reliability of the method checked. The numbers of fluorescent noradrenergic axons was counted in some of the nerves processed for fluorescence microscopy, as detailed in section 1 of this chapter. The number of animals used for either fluorescence or electron microscopy were as follows:

	Fluorescence	Electron Microscopy
3 day neuromas	4	2
7 day neuromas	5	2
3 week neuromas	4	2
8 week neuromas	3	1
7 month neuromas	2	2

Details of statistical analysis and raw data are given in Appendix 3.

## Results 6 GUANETHIDINE

### A. 'Normal' nerves

#### 1. Contralateral to 3 day neuromas.

Rats which had been dosed with guanethidine appeared to be slightly sedated. The normal right sciatic nerve from animals in which the left sciatic nerve had been sectioned three days previously contained very numerous thick fluorescent axons when viewed by fluorescence microscopy.

The numbers of fluorescent axons in these nerves were slightly higher than those seen in normal nerves, although there was some overlap with the top end of the normal range. The number of axons counted at any particular locus ranged from 269 - 403 (120 - 319 in normal nerves), Appendix Table 3. The total counts were also high - ranging from 1474 to 1858 (normal range, 669 - 1564), Table 5. The mean slope of these nerves was very small, but the M15 value was significantly larger than that in normal untreated nerves,  $p < 0.001$  (Table 6, Figure 93).

~~When examined ultrastructurally, there was a large variation in~~

p.233.3.7.

Sympathetic activity following pharmacological treatment was identified in these animals as bulging eyes and pronounced piloerector activity.

~~no and any labelled sympathetic axons. Sympathetic activity was~~  
apparent in all animals following nialamide and 5-OH DA treatment.

#### 2. Contralateral to 7 day neuromas.

Numbers of fluorescing sympathetic axons counted in 'normal' nerves contralateral to one week old neuromas were lower than those counted in nerves contralateral to three day neuromas. Counts at particular loci across the nerve fell within the normal range (118 - 220, Appendix Table 3), as did the total counts in 20 sections (637 - 1029), Table 5. The appearance of the sympathetic axons was normal. Counts of sympathetic axons in nerves from animals dosed on days 1-4 tended to be lower than those from animals dosed on days 4-7 (Table 4

## Results 6 GUANETHIDINE

### A. 'Normal' nerves

#### 1. Contralateral to 3 day neuromas.

Rats which had been dosed with guanethidine appeared to be slightly sedated. The normal right sciatic nerve from animals in which the left sciatic nerve had been sectioned three days previously contained very numerous thick fluorescent axons when viewed by fluorescence microscopy.

The numbers of fluorescent axons in these nerves were slightly higher than those seen in normal nerves, although there was some overlap with the top end of the normal range. The number of axons counted at any particular locus ranged from 269 - 403 (120 - 319 in normal nerves), Appendix Table 3. The total counts were also high - ranging from 1474 to 1858 (normal range, 669 - 1564), Table 5. The mean slope of these nerves was very small, but the M15 value was significantly larger than that in normal untreated nerves,  $p < 0.001$  (Table 6, Figure 93).

When examined ultrastructurally, there was a large variation in the number of sympathetic axons in different animals. There was no evidence of degeneration of sympathetic axons; a regular array of microtubules and neurofilaments were seen, and the matrix of mitochondria appeared normal. 5-OH DA labelled dcx were very prominent and numerous in one animal (Fig. 94), but in another, it was difficult to find any labelled sympathetic axons. Sympathetic activity was apparent in all animals following nialamide and 5-OH DA treatment.

#### 2. Contralateral to 7 day neuromas.

Numbers of fluorescing sympathetic axons counted in 'normal' nerves contralateral to one week old neuromas were lower than those counted in nerves contralateral to three day neuromas. Counts at particular loci across the nerve fell within the normal range (118 - 220, Appendix Table 3), as did the total counts in 20 sections (637 - 1029), Table 5. The appearance of the sympathetic axons was normal. Counts of sympathetic axons in nerves from animals dosed on days 1-4 tended to be lower than those from animals dosed on days 4-7 (Table 4

Normal + Guanethidine treated normal  
contralateral to 3 day neuroma

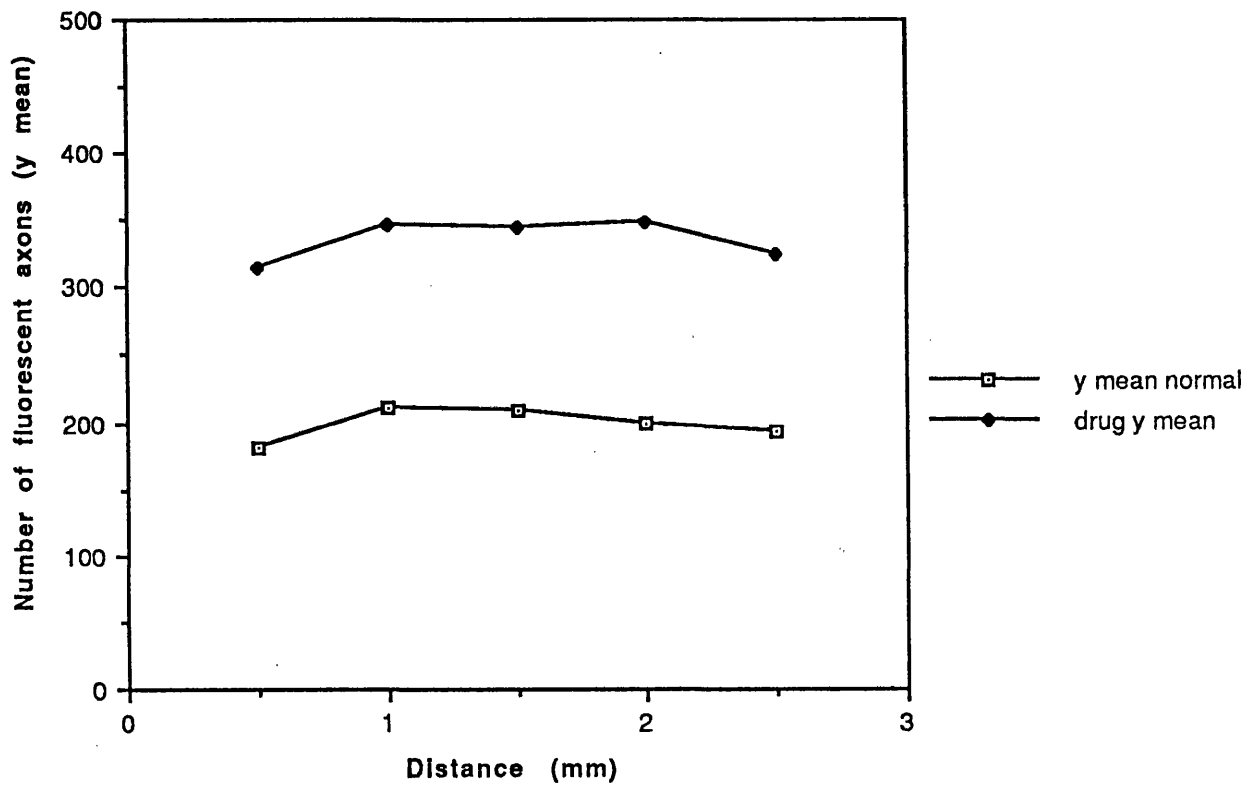
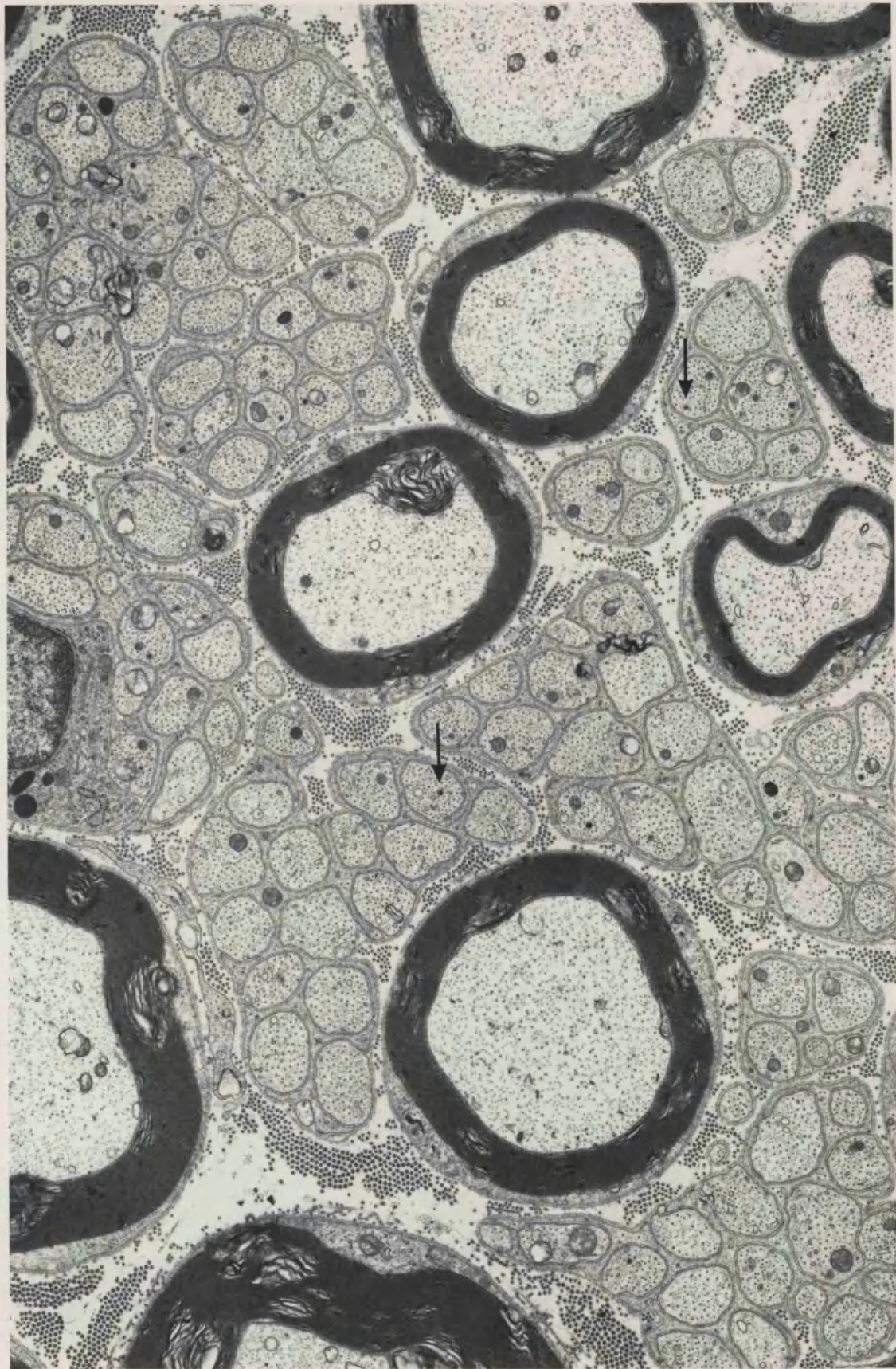


FIGURE 93 Number of fluorescent axons vs. Distance. Comparison of normal nerves with guanethidine treated normal nerves contralateral to three day old neuromas.

**FIGURE 94** Normal sciatic nerve, contralateral to a 3 day neuroma, from an animal dosed with guanethidine on days 1 - 3 after nerve section. Pretreated with nialamide and 5 -OH DA. Many sympathetic axons can be identified (arrows).

x 8 900





and Fig. 95). The M15 value for animals dosed on days 1-4 was significantly lower than normal ( $p < 0.001$ , Table 6), but M15 from animals dosed on days 4-7 was not significantly different from normal. However, there was more variation among the animals in this latter group; two of these animals had much lower numbers of fluorescent axons than normal, but the other animal appeared to be barely affected by the guanethidine (Appendix Table 3). Ultrastructurally, many axons containing labelled dcV could be seen in the nerve from animals dosed on days 1-4, but virtually none were seen in another animal dosed on days 4-7, which may be a representation of interanimal variability in response to guanethidine dosing.

### 3. Contralateral to 21 day neuromas.

There were many more sympathetic axons in nerves contralateral to 3 week neuromas in animals which had been dosed on days 4-9 than in nerves from animals dosed on days 17-21, which contained almost one third fewer fluorescent axons (Table 4, Fig. 96). The M15 value for this group was significantly less than normal,  $p < 0.01$ , but the M15 for the group dosed on days 4 - 9 was significantly larger than normal,  $p < 0.01$  (Table 6). There was a large variation between the two animals in this latter group. Total counts showed similar changes, Table 5.

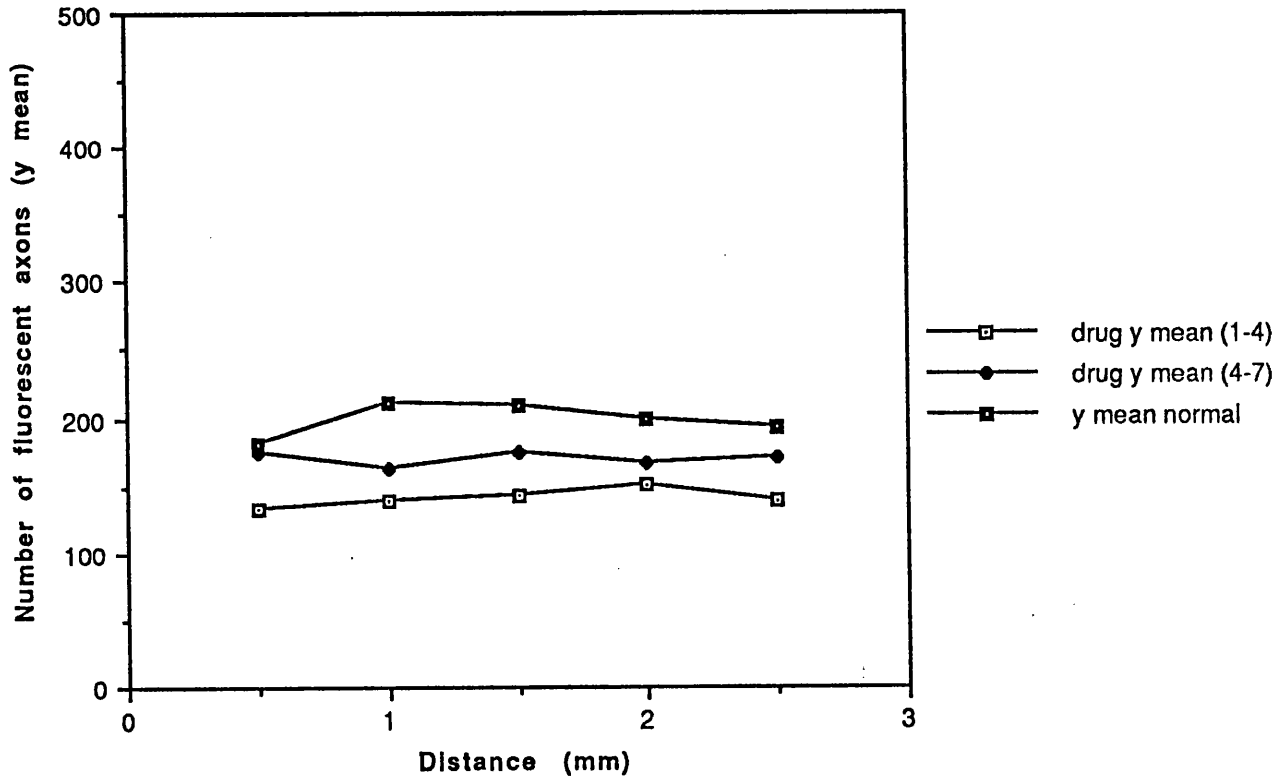
## B. Neuromas

Generally, the neuromatous tissue showed a larger depletion of noradrenaline from sympathetic axons than did the normal tissue from animals dosed with guanethidine. There was a much larger variation between the slopes,  $b$ , in the groups of guanethidine treated neuromas than between the slopes of untreated neuromas (Tables 6 and 2), the  $F$  ratios being 39.73 and 13.10 respectively (Appendix Table 3).

### 1. 3 day neuromas.

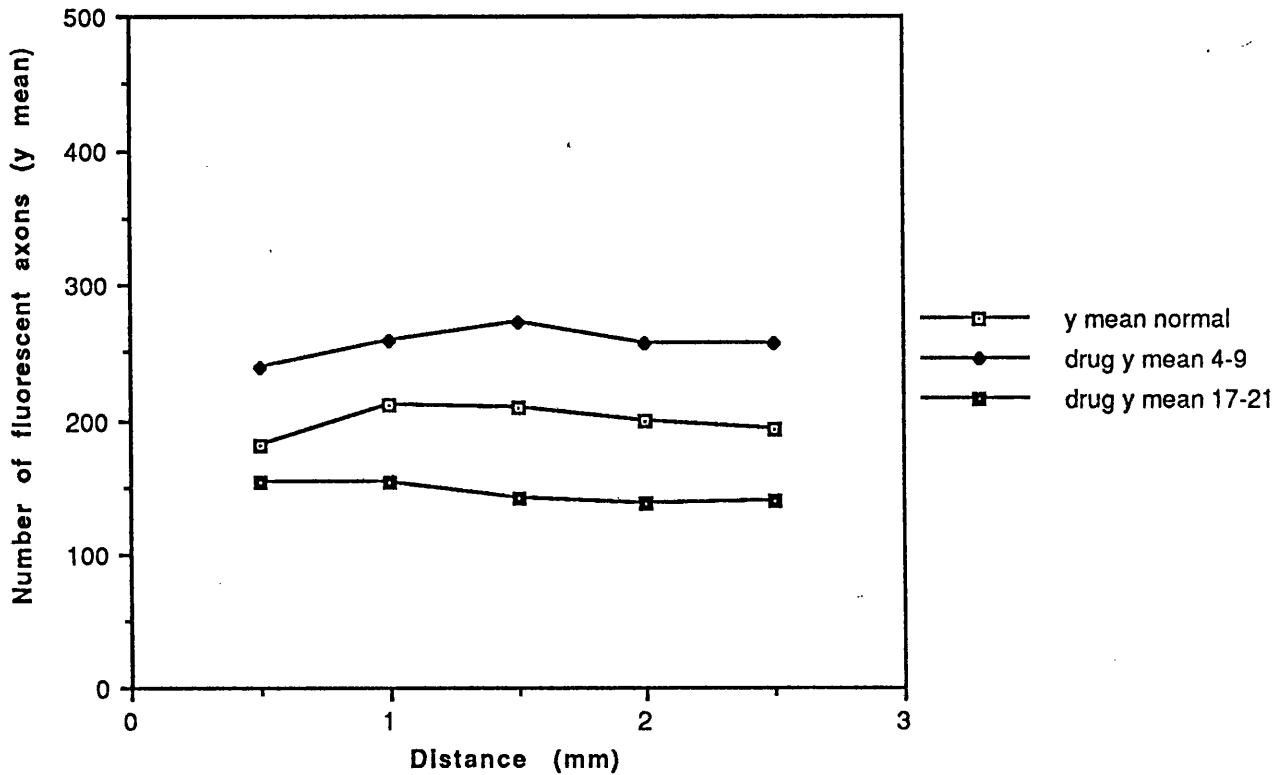
3 days following section, there were some small accumulations of noradrenaline fluorescence at the distal tip but these were very variable between animals (Figs. 97 and 98) and much smaller than those seen in untreated neuromas. Two or three sections had larger collections of fluorescent material, but this tended to be on side branches, not on the central nerve. There were also many thin sympathetic axons seen throughout the length of nerve examined. The

Normal and Guanethidine treated normal  
contralateral to 7 day neuroma.  
Dosed days 1 - 4 and 4 - 7



**FIGURE 95** Number of fluorescent axons vs. Distance. Comparison of normal nerves with guanethidine treated normal nerves contralateral to seven day old neuromas, from animals dosed on days 1 - 4 and 4 - 7 after nerve section.

Normal + Guanethidine treated normal  
contralateral to 21 day neuroma.  
Dosed days 4 - 9 and 17 - 21



**FIGURE 96** Number of fluorescent axons vs. Distance. Comparison of normal nerves with guanethidine treated normal nerves contralateral to twenty one day old neuromas, from animals dosed on days 4 - 9 and 17 - 21 after nerve section.

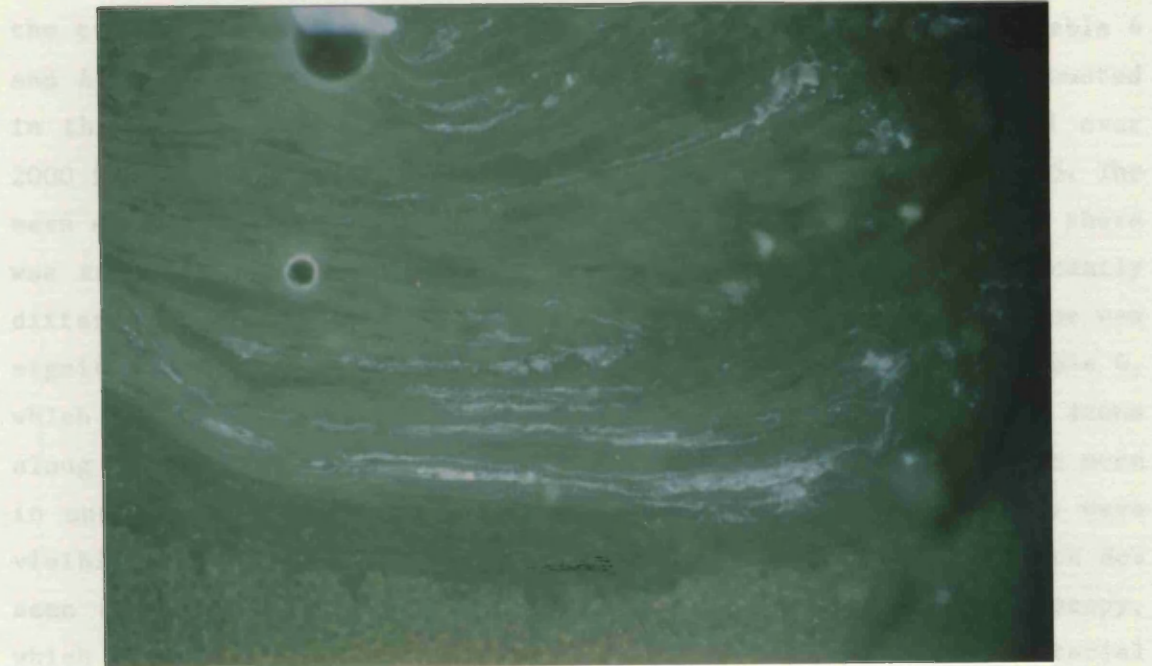
**FIGURE 97.** Distal tip of a neuroma 3 days after nerve section, from an animal treated with guanethidine on days 1 - 3 following nerve section. The amount of fluorescent material which has accumulated at the distal tip of this neuroma is less than would be expected in an untreated neuroma (cf. Fig. 5), but is very much more than is seen in other 3 day neuromas from animals treated with guanethidine (cf. Fig. 98). Glyoxylic acid.

x 40

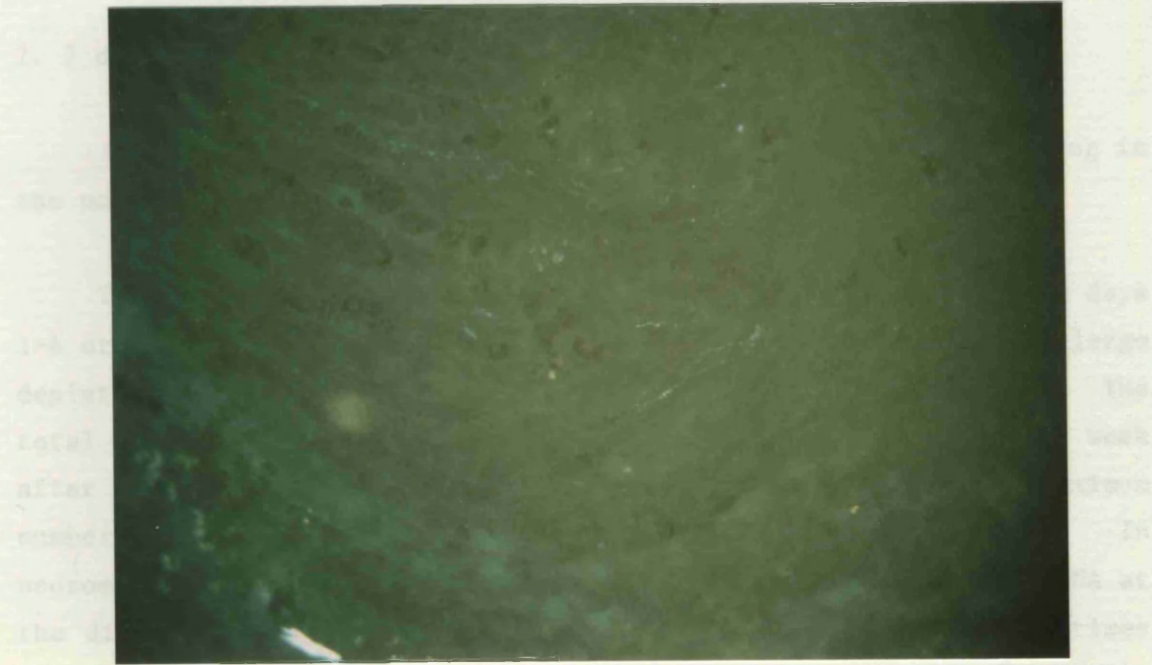
**FIGURE 98.** Distal tip of a neuroma 3 days after section from an animal treated with guanethidine on days 1 - 3 following section. The tissue contains a few faint fluorescent axons, but no accumulations of noradrenaline. Glyoxylic acid.

x 80

maximum number of fluorescent axons counted from the distal tip was 515 in postnatal treated animals, compared to more than 800 in untreated animals, and this number fell to about 100 1.5mm distal to the tip.



also by light microscopy (Figs. 100 and 101). However, some axons contained dye which had not been labelled with 5-DM DA, but which were contained within axons which were morphologically identical to sympathetic axons (Fig. 102).



those axons were proximally and the mean slope was negative (Table 5). The mean slope was not significantly different from that of untreated 7 day old animals, but the MII value was significantly reduced. In a similar pattern to that seen in the 3 day old animals (Table 6, Fig. 103). Axons at the distal tip of the neurone were thin, and generally sparsely scattered, not running in groups. A few sympathetic axons

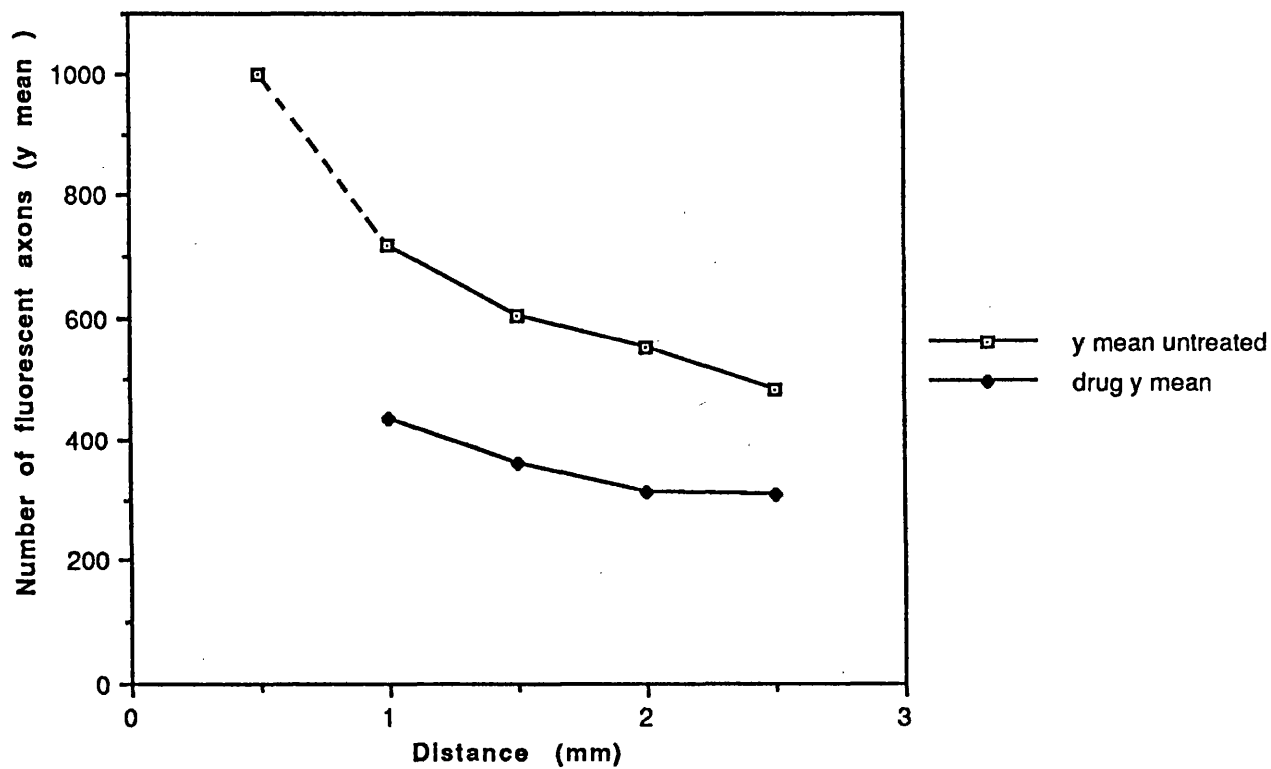
maximum number of fluorescent axons counted 1.0mm from the distal tip was 518 in guanethidine treated animals, compared to more than 800 in untreated animals, and this number fell to about 300 2.5mm distal to the tip, under 2/3 of the number (480) seen in normal animals (Table 4 and Appendix Table 4). The total numbers of sympathetic axons counted in these neuromas ranged from 1262 to 1713, as compared to well over 2000 in untreated animals, all excluding the distal 0.5mm, Table 5. The mean slope of the 3 day neuromas was still negative, showing that there was an accumulation of NA at the distal tip and was not significantly different from the untreated 3 day neuroma. However, the M15 value was significantly lower than that for untreated neuromas,  $p < 0.001$ , Table 6, which shows that the rate of change in the number of sympathetic axons along the guanethidine treated neuromas was very similar to those seen in untreated neuromas, but overall, many fewer sympathetic axons were visible (Fig. 99). There were still many swollen axons packed with dcv seen at the distal tip of neuromas examined by electron microscopy, which would correspond to the small 'pools' of fluorescent material seen by light microscopy (Figs. 100 and 101). However, some axons contained dcv which had not been labelled with 5-OH DA, but which were contained within axons which were morphologically identical to sympathetic axons (Fig. 102).

## 2. 7 day neuromas.

Depletion of noradrenaline fluorescence was much more striking in the neuromas one week following section.

The morphology of one week old neuromas from animals dosed on days 1-4 or 4-7 were quite different, although both groups showed very large depletions of noradrenaline, compared with untreated neuromas. The total numbers of sympathetic axons in the untreated neuromas 1 week after section ranged from 2300 to over 3000, compared with a maximum number in the guanethidine treated neuromas of 515 (Table 5). In neuromas treated on days 1-4, there was still an accumulation of NA at the distal tip, since counts of sympathetic axons here were 2-3 times those seen more proximally and the mean slope was negative (Table 6). The mean slope was not significantly different from that of untreated 7 day old neuromas, but the M15 value was significantly reduced, in a similar pattern to that seen in the 3 day old neuromas (Table 6, Fig. 103). Axons at the distal tip of the neuroma were thin, and generally sparsely scattered, not running in groups. A few sympathetic sprouts

### Neuroma 3 days untreated and Guanethidine treated

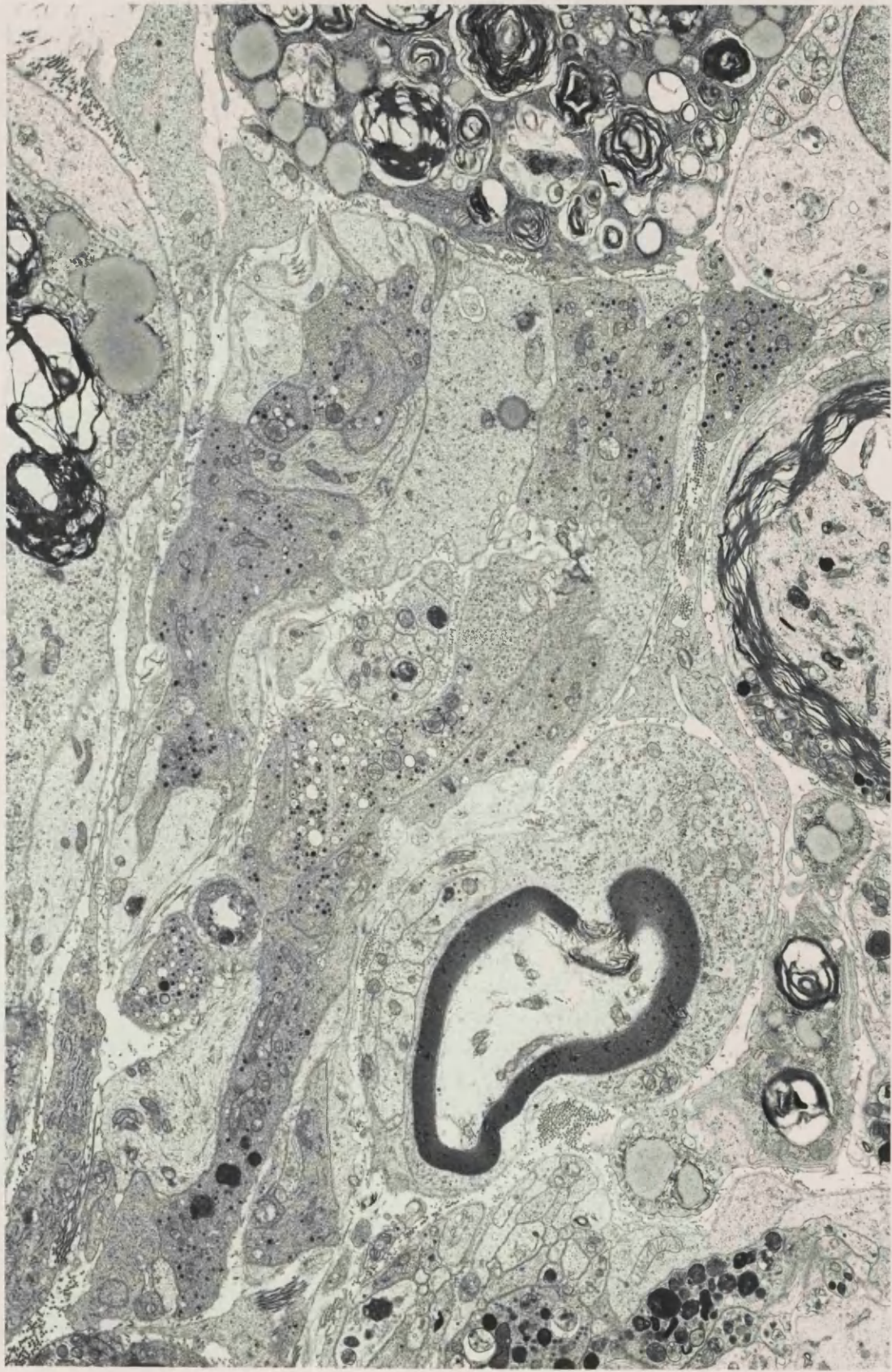


**FIGURE 99** Number of fluorescent axons vs. Distance. Comparison of 3 day neuromas with guanethidine treated 3 day neuromas.



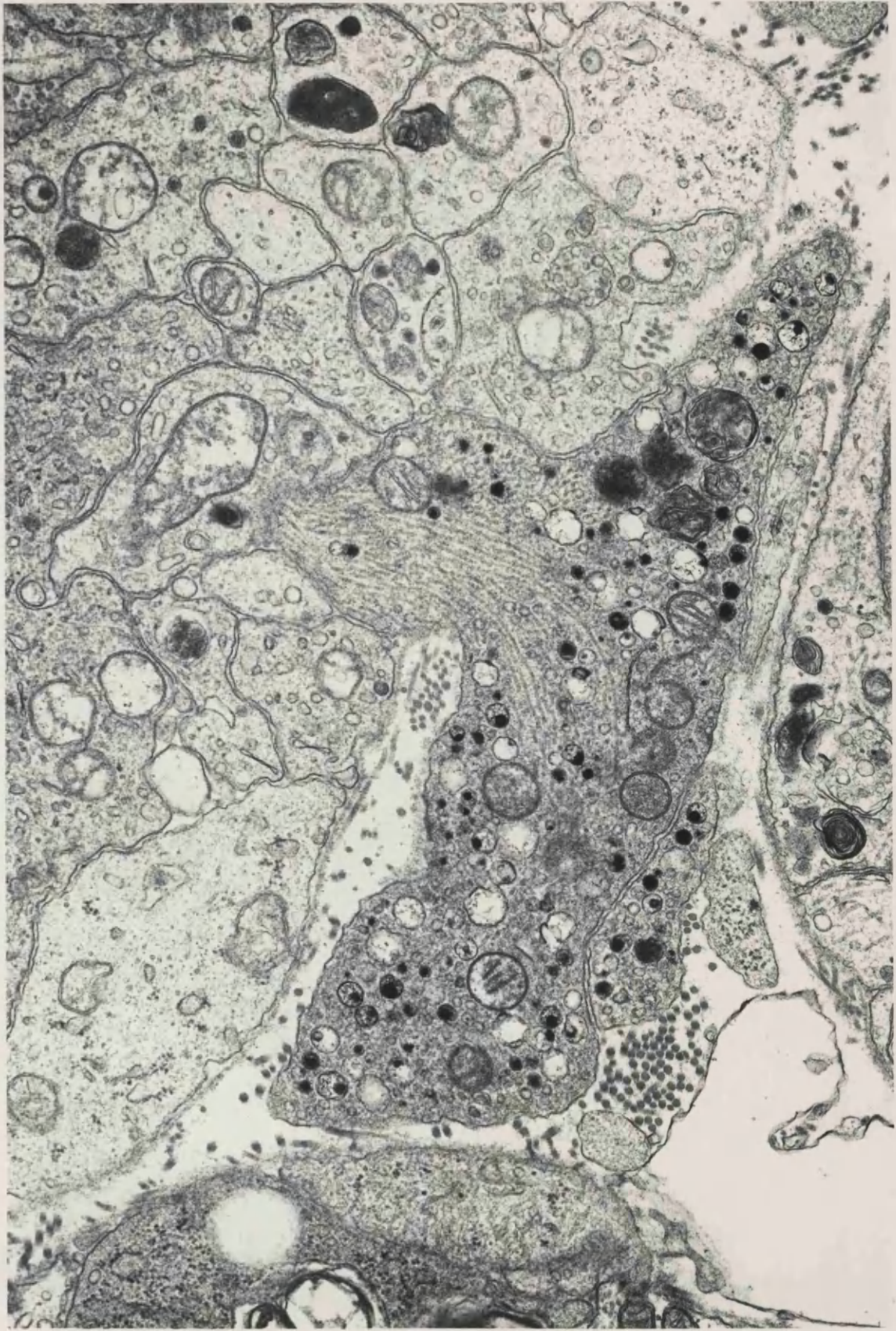
**FIGURE 100** 3 day neuroma, distal 1mm, from an animal treated with guanethidine on days 1 - 3 following nerve section. Pretreated with nialamide and 5 - OH DA. Sympathetic axons containing many labelled dcv are prominent.

x 7 200



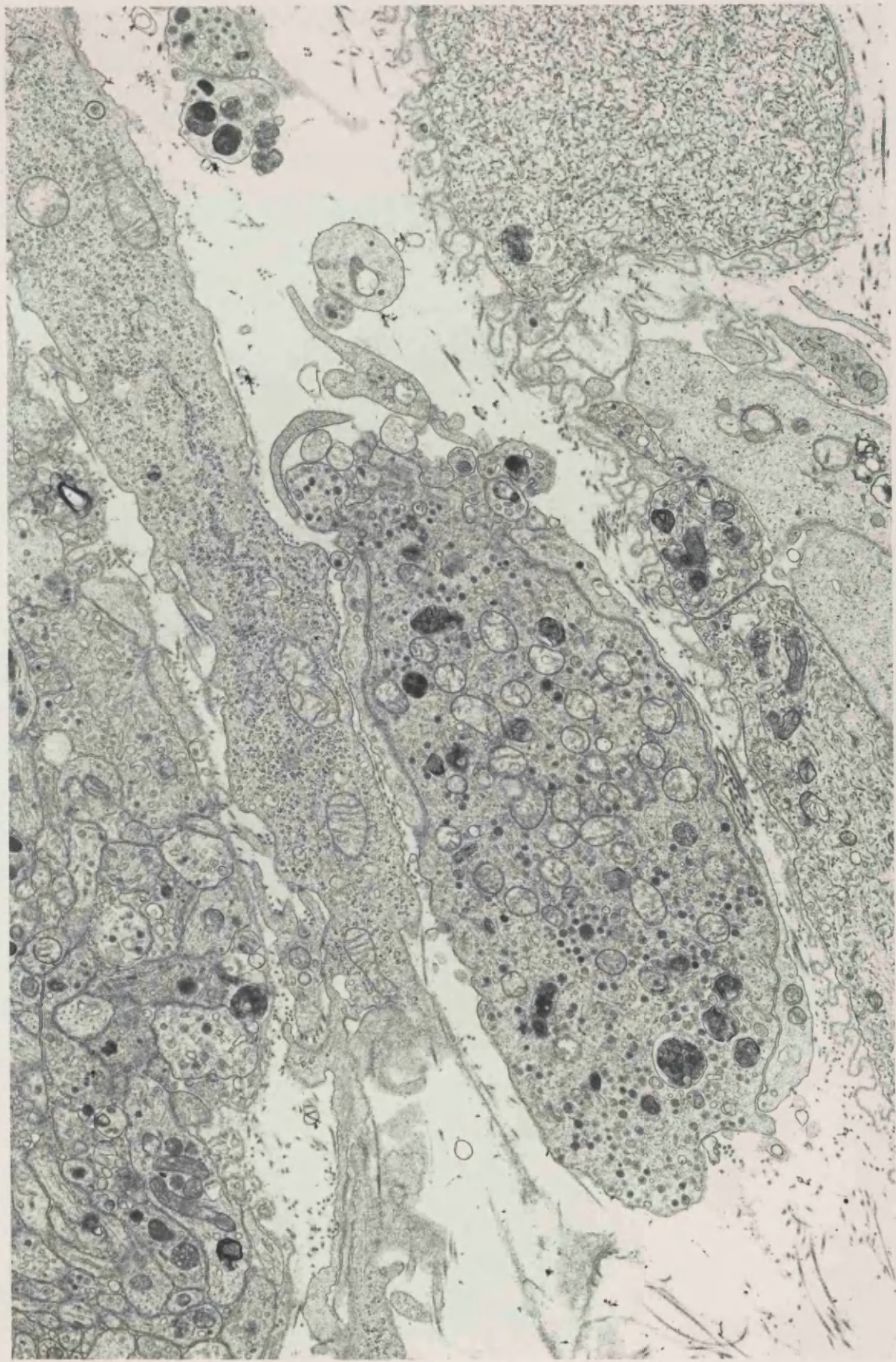
**FIGURE 101** 3 day neuroma, distal lmm, from the same animal as Figs. 100 and 102. The central sympathetic axon contains an accumulation of dcv, some with eccentric cores, mitochondria and neurofilaments. The dual population of small and large dcv is evident.

x 27 500

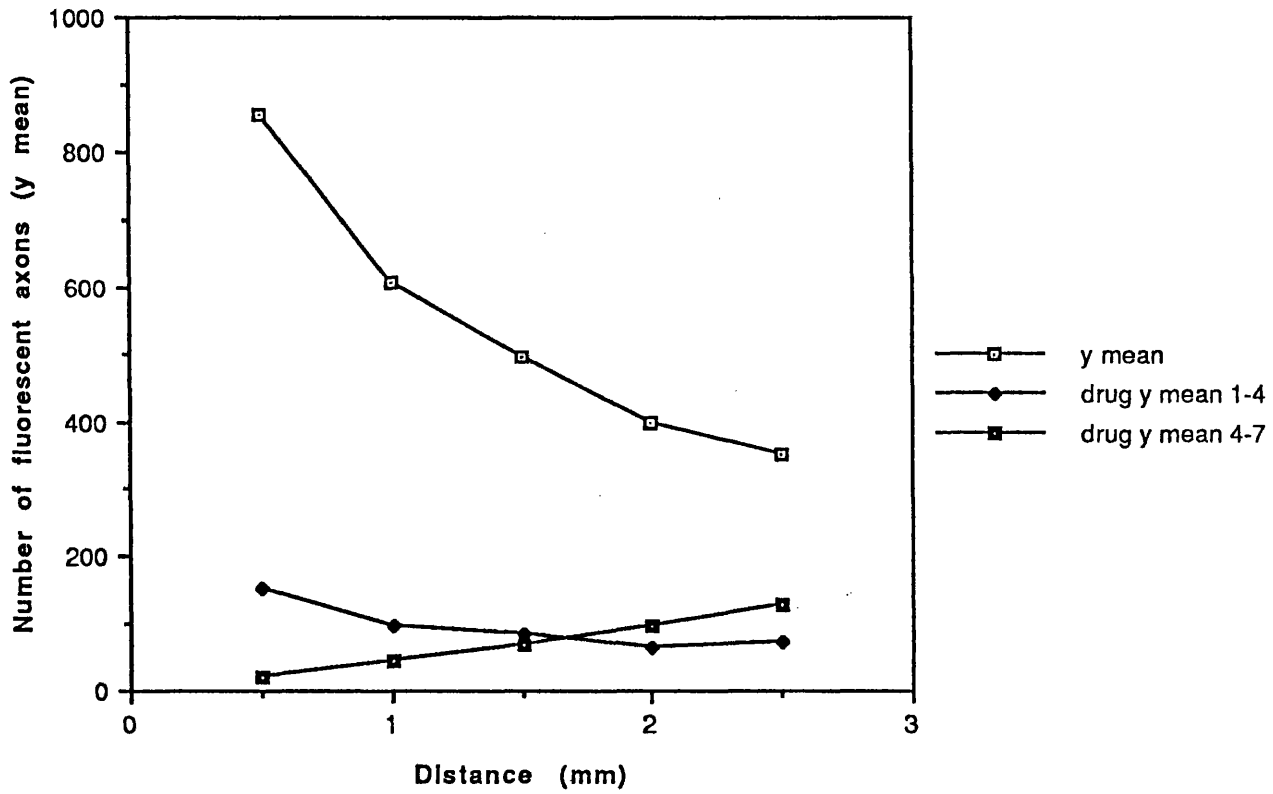


**FIGURE 102** 3 day neuroma, distal lmm, from the same animal as Fig. 100, but none of the dcv in these axons are labelled with 5 - OH DA.

x 10 600



### Neuroma 7 days Untreated and Guanethidine treated



**FIGURE 103** Number of fluorescent axons vs. Distance. Comparison of 7 day old neuromas with guanethidine treated 7 day old neuromas, from animals dosed on days 1 - 4 and 4 - 7.

could be seen growing into the new tissue at the distal tip of the neuroma.

However, in neuromas treated on days 4-7, there was very little fluorescence at the distal tip (Table 4 and Fig. 104) and in some sections there was a complete absence of fluorescence extending more than 2.0mm proximally from the tip. Both the mean slope and the M15 values in these animals were significantly different from untreated animals ( $p < 0.001$ , Table 6). The mean slope was positive, reflecting the fact that there were less sympathetic axons at the distal tip than further proximally (Fig. 103).

There was a large interanimal variation in response in neuromas dosed on days 4-7, the total number of sympathetic axons ranging from 208 to 492, Table 5.

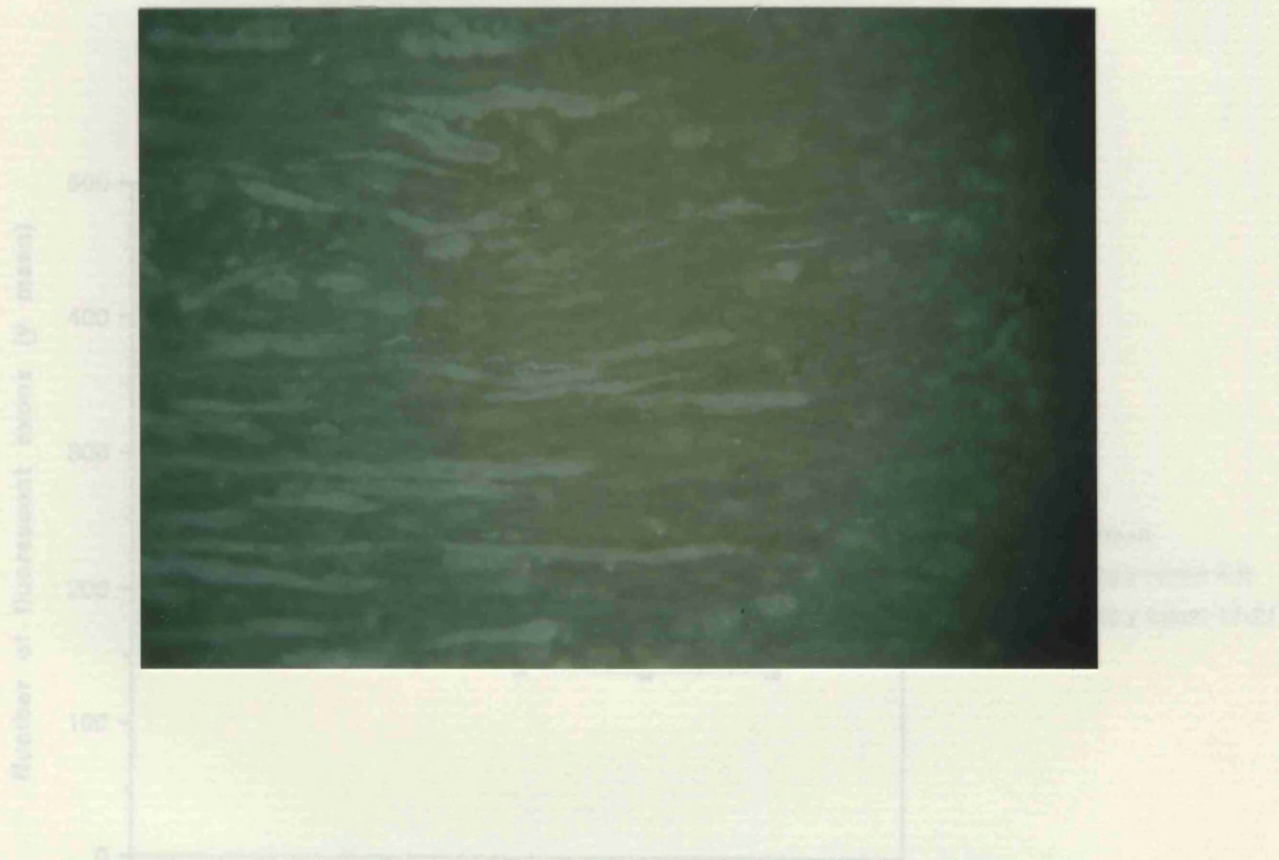
Ultrastructurally, a few swollen axons with collections of 5-OH DA labelled dcv were seen in the distal tip tissue of neuromas from animals dosed on days 1-4, but labelled dcv were virtually absent in those animals dosed on days 4-7, which correlates well with the appearance of tissue seen by fluorescence microscopy.

### 3. 21 day neuromas

The numbers of fluorescent axons counted in neuromas of animals treated with guanethidine on days 4 - 9 were roughly half those seen in untreated neuromas. In guanethidine treated neuromas the number of sympathetic axons at the distal tip was lower than that further proximally, the mean slope being slightly positive (Table 6, Fig. 105). In untreated neuromas the reverse was true. Both the slope and M15 values were significantly different from those in untreated neuromas ( $p < 0.001$ , Table 6).

Neuromas taken from animals treated on days 17 - 21 were virtually devoid of sympathetic axons (Table 4). Only 108 were counted in one animal, compared with totals of over 1000 in normal animals (Table 5). Usually there were no fluorescent axons within 1.5mm of the distal tip, and numbers further proximally were very depleted. There was a large positive slope in the one animal quantitatively examined, which was significantly different from the untreated 21 day old neuromas (Table 6, Fig. 105). The M15 value was also significantly lower than normal

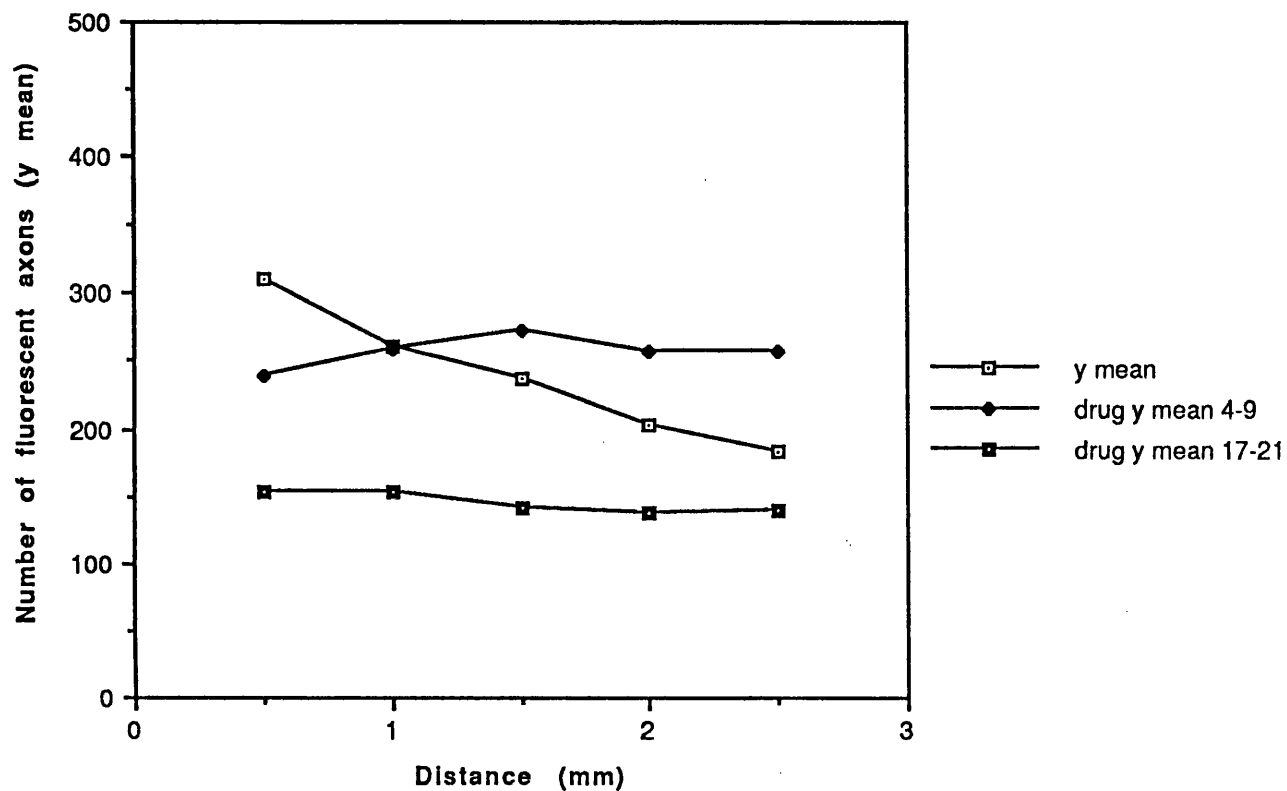




**FIGURE 104.** Distal tip of a neuroma 7 days after section, from an animal treated with guanethidine on day 4 - 7 following nerve section. Very few faintly fluorescent axons can be seen, and there is a large degree of depletion of NA compared with a neuroma from an untreated animal (cf. Fig. 8). Glyoxylic acid.

x 80

### Neuroma 21 days Untreated and Guanethidine treated



**FIGURE 105** Number of fluorescent axons vs. Distance. Comparison of 21 day old neuromas with guanethidine treated 21 day old neuromas, from animals dosed on days 4 - 9 and 17 - 21.

254  
( $p < 0.001$ , Table 6). Ultrastructurally, labelled dcV could be identified in both types of neuroma (Fig. 106), but it was not possible to say with certainty whether sympathetic axons were more common in neuromas from animals dosed on days 4 - 9.

**FIGURE 106** 3 week neuroma, distal 1mm, from an animal treated with  
on days 4 - 9 after nerve section. Pretreated with  
nialamide and 5 - OH DA. A sympathetic axon (S)  
containing similar numbers of dcv to those seen in  
untreated 3 week old neuromas is seen in the centre.

x 31 000

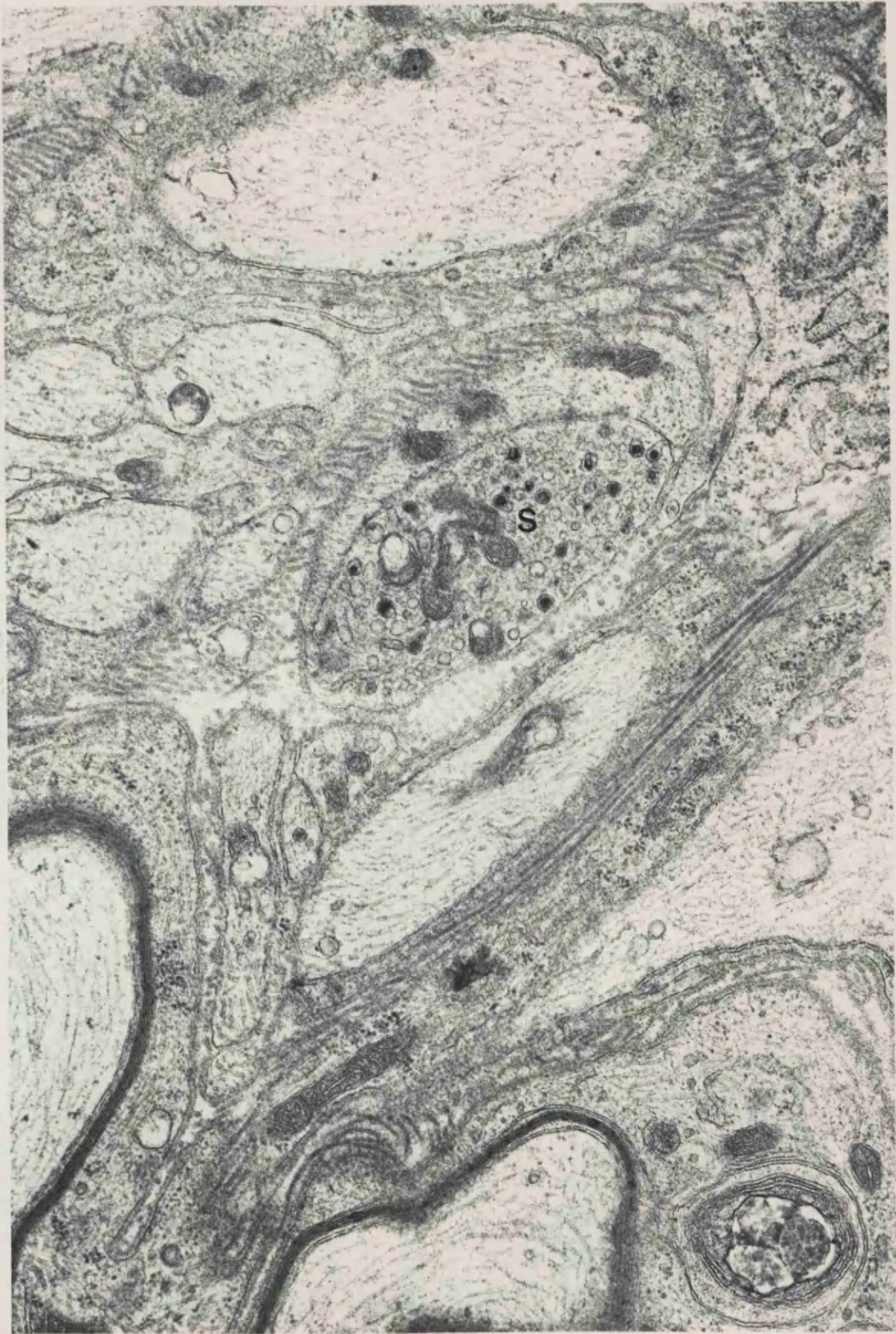


TABLE 4

## GUANETHIDINE TREATED NERVES AND NEUROMAS

Days post section	n	Number of fluorescent axons at distance from distal tip (y mean)				
		0.5mm	1.0mm	1.5mm	2.0mm	2.5mm
Normal (3 days)	4	315	346	345	349	323
Normal (7 dosed 1-4)	2	133	139	143	151	139
Normal (7 dosed 4-7)	3	175	164	176	167	171
Normal (21 dosed 4-9)	2	239	259	273	257	257
Normal (21 dosed 17-21)	2	153	154	142	138	139
Neuroma 3 days	3	-	435	360	313	309
Neuroma 7 dosed 1-4	2	150	97	82	63	72
Neuroma 7 dosed 4-7	3	21	44	66	95	127
Neuroma 21 dosed 4-9	2	141	144	165	178	187
Neuroma 21 dosed 17-21	1	3	11	17	36	41

**TABLE 5**  
**TOTAL NUMBERS OF SYMPATHETIC AXONS**  
**IN GUANETHIDINE TREATED ANIMALS**

**A. 'Normal' Nerves**

(Contralateral to 3 day neuroma)

Dosed days 1 - 3	1474	1684	1725	1858
------------------	------	------	------	------

(Contralateral to 7 day neuroma)

Dosed days 1 - 4	637	780		
Dosed days 4 - 7	758	773	1029	

(Contralateral to 21 day neuroma)

Dosed days 4 - 9	1158	1413		
Dosed days 17 - 21	713	763		

**B. Neuromas**

(3 day)	Dosed days 1 - 3	1262	1264	1488	1713
---------	------------------	------	------	------	------

(7 day)	Dosed days 1 - 4	411	515		
	Dosed days 4 - 7	208	364	492	

(21 day)	Dosed days 4 - 9	722	907		
	Dosed days 17 - 21	108			





## Summary of Guanethidine Results

1. Sympathetic axons in normal and traumatically injured nerves were depleted of their NA content by guanethidine, as shown by the depletion of NA fluorescence or labelled dcv. Normal nerves were much less susceptible to this effect.
2. In the proximal stump neuromas, the more damaged tissue at the distal tip was more sensitive to the effects of the guanethidine, being more heavily depleted of NA, than more normal proximal tissue.
3. This susceptibility also depended on the amount of regenerative activity going on, i.e. the time following nerve section. The NA content of 3 day old neuromas was depleted less, proportionally, than that of 7 or 21 day old neuromas.
4. The degree of depletion caused by the drug was also influenced by the dosage regime, in particular, the time elapsed between the last dose of guanethidine and killing the animal. NA levels were more depleted in animals which were dosed on the day of killing, and some recovery of NA levels was seen following the last dose of guanethidine.
5. There was also considerable inter-animal variability in the degree of NA depletion in response to the drug. If the clinical efficacy of guanethidine as an analgesic in peripheral nerve injury is linked to NA depletion in the region of nerve damage, the variability of the efficacy of guanethidine in depleting NA might be one factor responsible for the variations in the effectiveness of regional guanethidine block in man.

## Materials and Methods Introduction 7

### Mode of action of capsaicin

Capsaicin, 8-methyl-N-vanillyl-6-nonenamide, is the pungent irritant compound in the capsicum plant (chilli pepper, red pepper etc). Following an acute painful inflammatory reaction when capsaicin is injected into the skin, an insensitivity to further noxious chemical stimuli develops and persists for several days (Jancso and Jancso-Gabor, 1959; Jancso, 1960; Szolcsanyi et al, 1975). The immediate excitatory effects of acute low doses of capsaicin in adult animals are quite different to those which are seen following chronic large doses (Jancso, 1960; Jancso, 1968), when there is degeneration of neurones. Capsaicin given as a single dose to neonatal animals causes rapid degeneration of a specific population of neurones in the dorsal root ganglia, the small B-type, and abolishes the cutaneous response to chemical irritants (Jancso et al, 1977). In addition there is permanent depletion of afferent C-fibres. Thus there are three types of action which capsaicin can exert:-

- 1) The acute phase - produced by low doses of capsaicin in adult animals.
- 2) The chronic phase and desensitization, produced by larger chronic doses in adult animals.
- 3) Permanent neurotoxic actions, seen following administration to neonatal animals.

### Acute/Chronic studies in adult animals

Capsaicin has the ability to cause the release of substance P and somatostatin from the central and peripheral terminals of primary sensory neurones (Gamse et al, 1979; Gamse et al, 1981; Yaksh et al, 1979), however when administered to adult animals it does not cause degeneration of these neurones (Fitzgerald, 1983). Joo et al (1969) showed mitochondrial damage to small B-type dorsal root ganglion cells, which persisted more than 60 days after treatment, but no neuronal degeneration. Jessell et al (1978) report a decrease of 48% of the substance P content of the dorsal horns following 5 days' dosage of adult rats with increasing doses of capsaicin. Hayes and Tyers (1980) report an 81% deficit at the same location, but ventral horn levels

201

were unaltered, suggesting the effect is selective to primary afferent terminals. There was an accompanying reduction in skin substance P of 64%, showing that capsaicin affects both central and peripheral terminals in acute doses.

p.261. Capsaicin.

However, Pini et al (1990) have now reported that topical application of capsaicin to the saphenous nerve for 30 minutes in adult rats leads to a 36 % loss of C fibres, and a decrease in size of the remaining fibres, 3 - 12 months following treatment.

subcutaneously and locally applied capsaicin to the skin or eye. Gamse (1982) reports that increased thresholds to hot plate tests last 10 days, and tail immersion tests for 2 days. Most reports studying thermal thresholds in capsaicin dosed adult rats demonstrate no change in heat pain thresholds, although testing usually began 1-4 months after treatment (Holzer et al, 1979; Jancso and Jancso-Gabor, 1980). Buck et al, (1982) found an acute, transient change, and reported an increased hot plate latency on day 1 which had subsided by day 6. Szolcsanyi (1976) showed an increased hot plate latency of 61% on day 1 which had fallen to 39% by day 4.

Neurotoxic effects from neonatal dosing

Many neuroanatomical studies have shown that capsaicin, administered to neonatal rats, will cause a massive degeneration of primary afferent neurones, specifically small B type sensory ganglion cells (Jancso et al, 1977). Large A type neurons are unaffected. The onset of degeneration is rapid, fine structural changes can be seen only 30 minutes after administration (Fitzgerald, 1983). Nagy et al (1980) reported degenerating boutons and unmyelinated axons in the dorsal horn after only 2 hours. Complete engulfment by glia of degenerating unmyelinated axons within 15 hours occurs in the upper dorsal horn, Jancso et al, (1977). The destruction of these small neurones leads to extensive degeneration of afferent C-fibres in the periphery, however it is not known whether small myelinated A-delta fibres are also affected. Lawson and Nickels (1980) reports a 30% drop in A fibres and a 90-95% drop in C fibres, in a study of L4 and T13 dorsal root fibres. Scadding (1980) demonstrated a 64% reduction in the number of C fibres in rat saphenous nerve, but no change in myelinated fibres. Jancso et al (1980) report a similar loss of

C-fibres, but an additional 10% loss of small myelinated fibres, again in rat saphenous nerve. Although C and A-delta fibre loss is very variable following neonatal capsaicin, a residual 5% of the population always remains in the dorsal roots (Fitzgerald, 1983). Degeneration of C-fibres is only seen in rats treated up to 14 days of age, Jancso and Kiraly (1980).

Substance P levels are reported to be greatly depleted following neonatal capsaicin, 50mg/kg, the usual figure agreed on by most reports being 50-60%. Levels in other tissues also fall, for example in the DRG by 65%, the effects appearing to be specific for primary afferents. The degree of fibre depletion and the type of fibres affected appears to be a dose dependent response (Nagy et al, 1981).

The insensitivity of animals to noxious chemical stimuli following neonatal treatment is widely accepted, however, the nociceptive response to thermal and mechanical testing is more controversial. Hayes et al, (1980); Buck et al (1982) and Cervero and McRitchie (1981) report no change in thermal thresholds following neonatal capsaicin treatment, but Holzer et al (1979) found a 50% increase in latency to hot plate tests, and Nagy et al (1980) report a 44% increase in latency. Jancso and Jancso-Gabor (1980) also report an increase in the mean latency. Hayes et al, (1980) and Cervero & McRitchie, (1981) found that mechanical response latencies are increased following neonatal capsaicin treatment.

#### Mechanism of action

The action of capsaicin is confined peripherally to afferent fibres, which is probably the site of desensitization, and centrally the predominant action is on the sensory neuron. Yaksh et al (1979) emphasized the importance of this central effect when it was shown that intrathecal capsaicin in adult rats abolishes behavioural response to noxious stimuli. The peripheral reflex events of vasodilation that follow local application of capsaicin have been shown to occur in C fibres classed as polymodal nociceptors, (Burgess and Perl, 1973; Lynn, 1975, 1977; Iggo, 1977). The exact molecular mode of action of capsaicin has yet to be found, however, work by Szolcsanyi and Jancso-Gabor (1975, 1976) has identified the parts of the molecule essential for the mode of action, which suggest a specific molecular site on the primary afferent neurone. Nagy (1982) proposes that since

the action of capsaicin is so specific, it cannot act via a neuronal membrane-associated secretion coupling or action potential generator mechanism.

Capsaicin was used in the following experiments to deplete the afferent C fibre population neonatally, producing a relatively 'pure' population of efferent C fibres in the adult animal. These experiments were designed to further investigate the morphology of the pathophysiological interaction which develops in neuromas between these two classes of fibres by removing the contaminating effect of the afferent fibres.

## Materials and Methods 7

### Capsaicin

Capsaicin, 50 mgkg<sup>-1</sup>, (Sigma) in a solution of 10% Tween 80 / 10% alcohol / 80% saline, was administered to neonatal rats on day 2 of life by intraperitoneal injection. 7 litters were treated, with one litter receiving injection vehicle only, as a control. Because of the problems of indelibly marking neonatal rat pups it was not possible to use littermate controls which had received the injection vehicle alone. However, pups were all born within 4 days of each other, and it was decided that interlitter variation would be minimal.

Rats were then allowed to fully mature and 8 weeks later, when the animals weighed over 170g, neuromas were created by section of the left sciatic nerve as previously described. Neuromas were allowed to develop for the following periods - 3,7,14,21,28 and 56 days. 4 Animals were operated on at each interval. In addition to the absolute controls (vehicle injection only), litter mate controls which had been dosed neonatally with capsaicin at the same time as the other animals, but had not undergone neuroma surgery, were produced.

The right sciatic nerves and neuromas from 2 rats were excised 3 days after nerve section and processed for glyoxylic acid fluorescence.

All the tissue from the other animals was processed for electron microscopy, following pre-treatment with nialamide/pargyline and 5-OH DA then perfusion with 3% glutaraldehyde in 0.1M sodium cacodylate buffer as previously described.

## Results 7 CAPSAICIN

Rats treated with capsaicin were more aggressive than their control counterparts, objecting to being handled, and scratching and trying to bite excessively when being handled for injections. Several litter mates were separated by the animal house staff after fighting occurred. Many rats suffered deep scratches to the head and neck, and two animals were culled when these wounds became chronic and would not heal.

### A. 'Normal' sciatic nerves.

In semi-thin resin sections (0.5um) stained with toluidine blue, the myelinated fibres appeared normal. There were no very large areas of unmyelinated fibres, even towards the perineurium, where such areas are often found in normal nerves. There was a great deal of variability between animals. Some sections had quite large numbers of unmyelinated fibres, and others had very few altogether. There was no difference between the 'normal' right sciatic nerves contralateral to the neuromas and 'normal' nerves from unoperated animals, both dosed with capsaicin.

The appearance of nerves from animals dosed with the injection vehicle solution only was completely normal.

In frozen sections reacted with glyoxylic acid, there was no appreciable difference between the fluorescence of noradrenergic axons in normal sciatic nerves from capsaicin treated or control animals (Fig.107). The numbers and appearance of the fluorescent axons were very similar, although detailed counts were not made, and it therefore seems likely that the sympathetic efferent C-fibres were unaffected by capsaicin treatment.

Ultrastructurally, fewer unmyelinated fibres were seen in sciatic nerves from capsaicin treated animals, corresponding to the appearance at light microscope level (Fig. 108). Those which remained however, appeared to be normal, with the usual complement of organelles. It was not possible to say whether these axons had a normal size distribution, without quantitative analysis. The Schwann cell subunits appeared to be smaller than in normal nerves, many only containing one or two axons, although again this possibility would require quantitative verification. Occasionally, flattened empty Schwann cell tubes could be



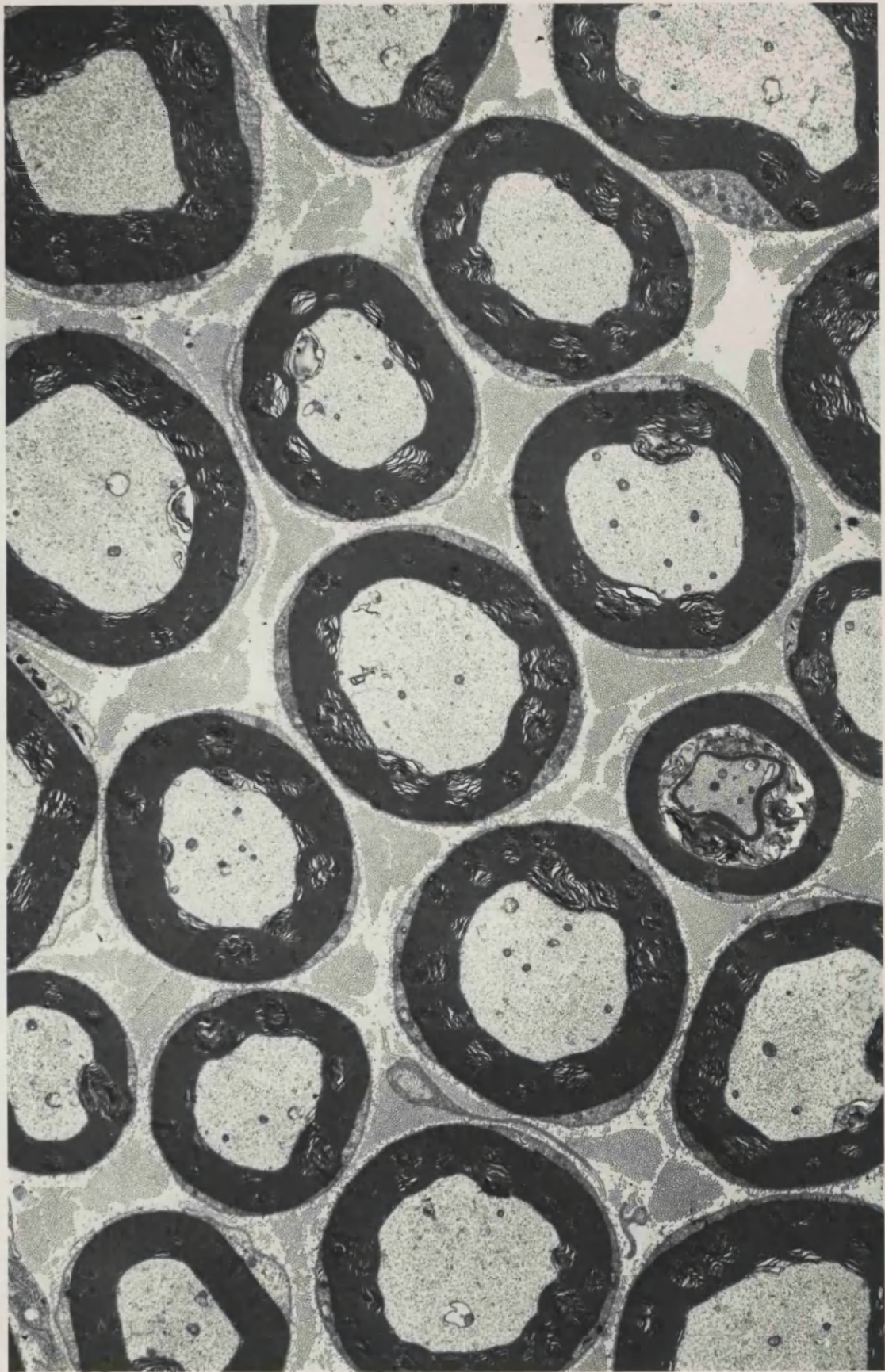
**FIGURE 107.** Normal sciatic nerve from an animal treated neonatally with capsaicin. The fluorescent sympathetic axon population has been unaffected by the capsaicin. Glyoxylic acid.

x 80



**FIGURE 108** Normal sciatic nerve from an animal dosed neonatally with capsaicin. Pretreated with nialamide and 5 - OH DA. Only one unmyelinated axon is visible.

x 16 400



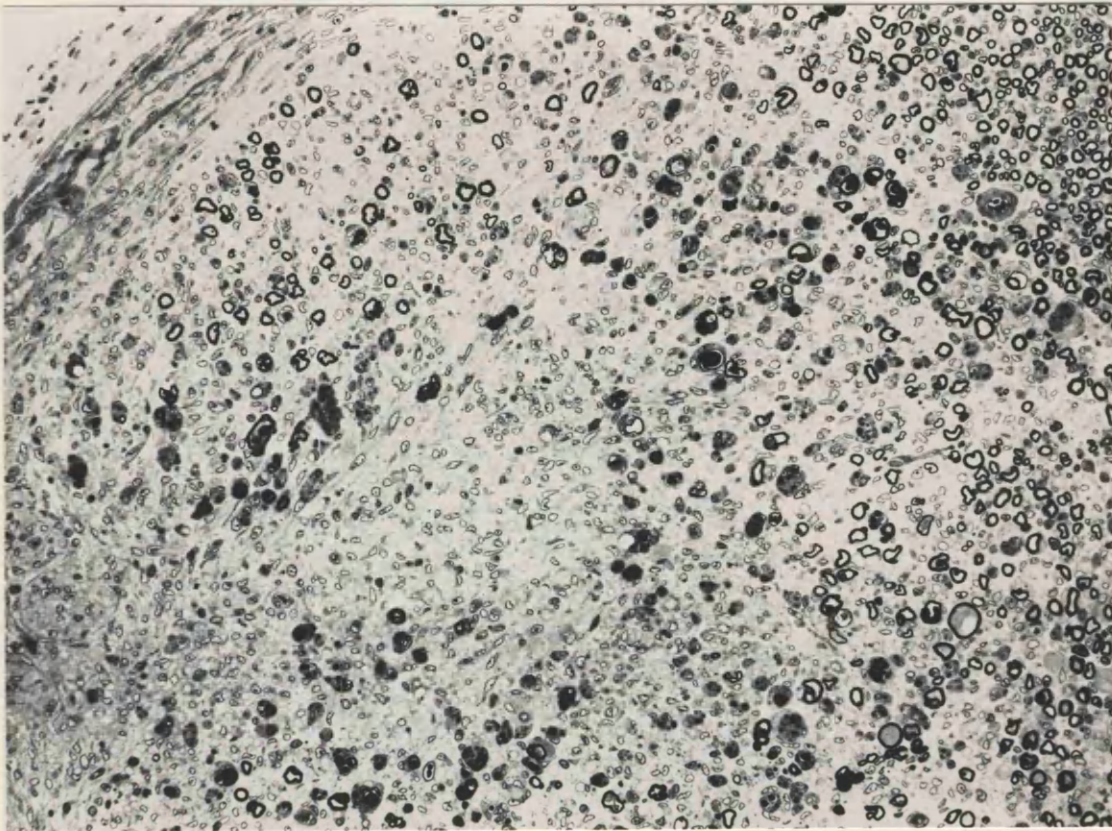
seen within sections, indicating a loss of axons, but large numbers of degenerate fibres were not seen in any of the sections examined.

Sympathetic axons with their characteristic dense cored vesicles could be identified in all sections. Counts of the numbers of Schwann cell subunits containing at least one 5-OH DA labelled sympathetic axon were made in normal right sciatic nerves and 3 day neuromas, as described previously in section 3. In 'normal' unsectioned nerves, the number of Schwann cell subunits was about 1/3 of the number in normal nerves from untreated animals (Tables 7 and 3). The percentage of subunits containing at least one labelled sympathetic axon was very slightly increased from normal, but this was not significant, - 11.75% compared to 11.33% (Tables 7 and 3).

#### B. Neuromas (sectioned left sciatic nerves).

The neuromas from animals treated with capsaicin were very similar in appearance to those of untreated animals (Fig.109). In the acute experiments, there were many non-myelinated sprouts at the distal tip of the neuroma, many of which were sympathetic, containing dcv labelled with 5-OH DA (Fig. 110). There were also many swollen unmyelinated axons, with collections of clear vesicles, mitochondria and dense lamellar bodies of axonal debris (Fig.111). The Schwann cell subunits of myelinated and non-myelinated profiles were similar in size between the capsaicin treated and non-treated neuromas (Fig. 110), both containing many axonal sprouts. The numbers of subunits, however, varied. 253 subunits were counted in 12 grid squares of an untreated 3 day neuroma and 144 in a capsaicin treated 3 day neuroma, a reduction of about 1/3 (Table 7). This depletion was similar to the change seen in the normal right sciatic nerves of capsaicin treated and untreated animals.

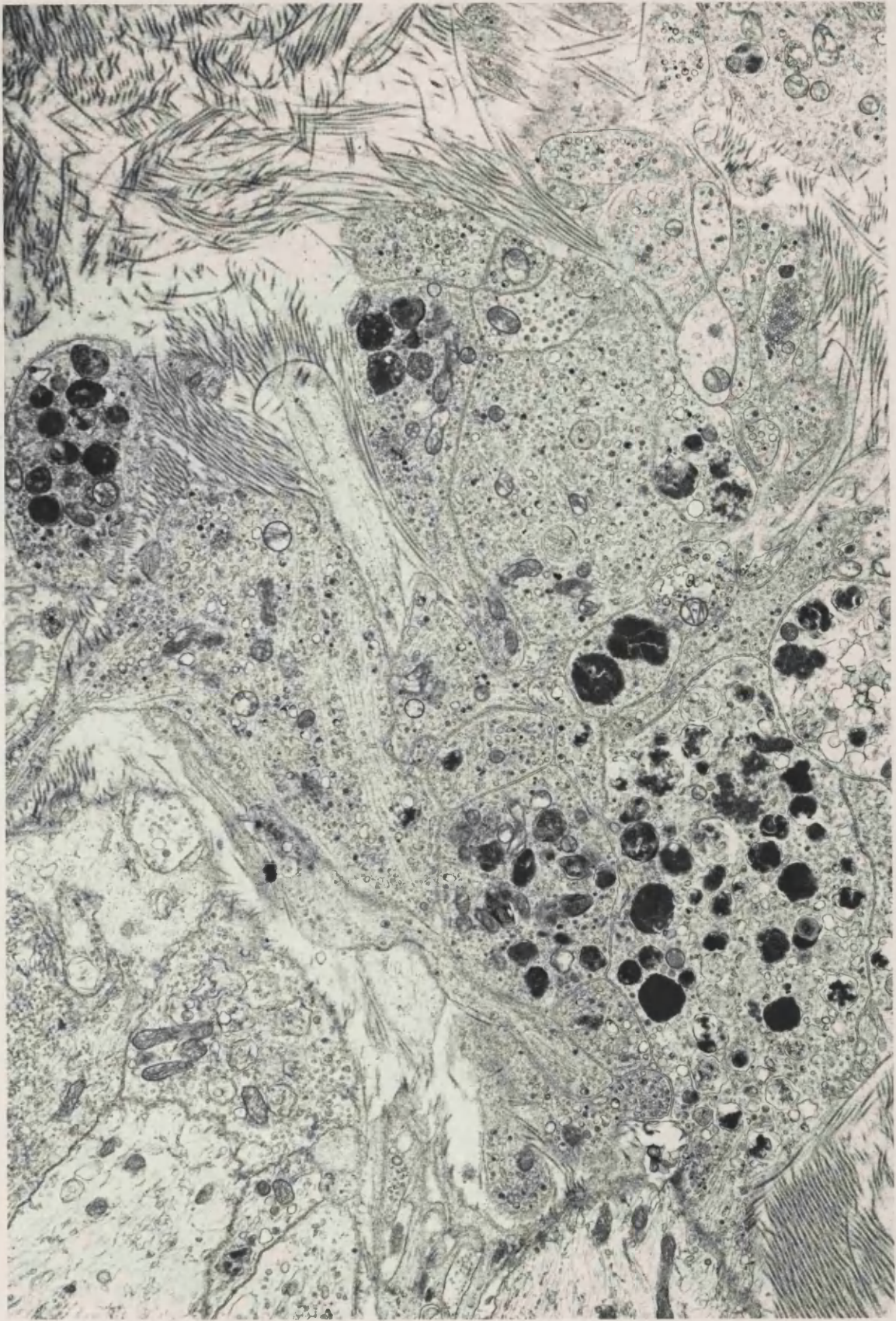
The tissue of more chronic neuromas (at least 2 weeks post-section) was organized into small fascicles of unmyelinated and newly myelinated axons at the distal tip (Figs. 112 and 113). Qualitatively, this tissue was very similar to that from untreated animals (Fig.114), and without quantitative analysis it was not possible to determine whether there were any differences between capsaicin treated and untreated neuromas (Fig.114).



**FIGURE 109.** Neuroma one week following section, 0.5mm from the distal tip. From an animal dosed neonatally with capsaicin. The tissue is very similar in appearance to a neuroma from an untreated animal. Glutaraldehyde / Resin / Toluidine blue.

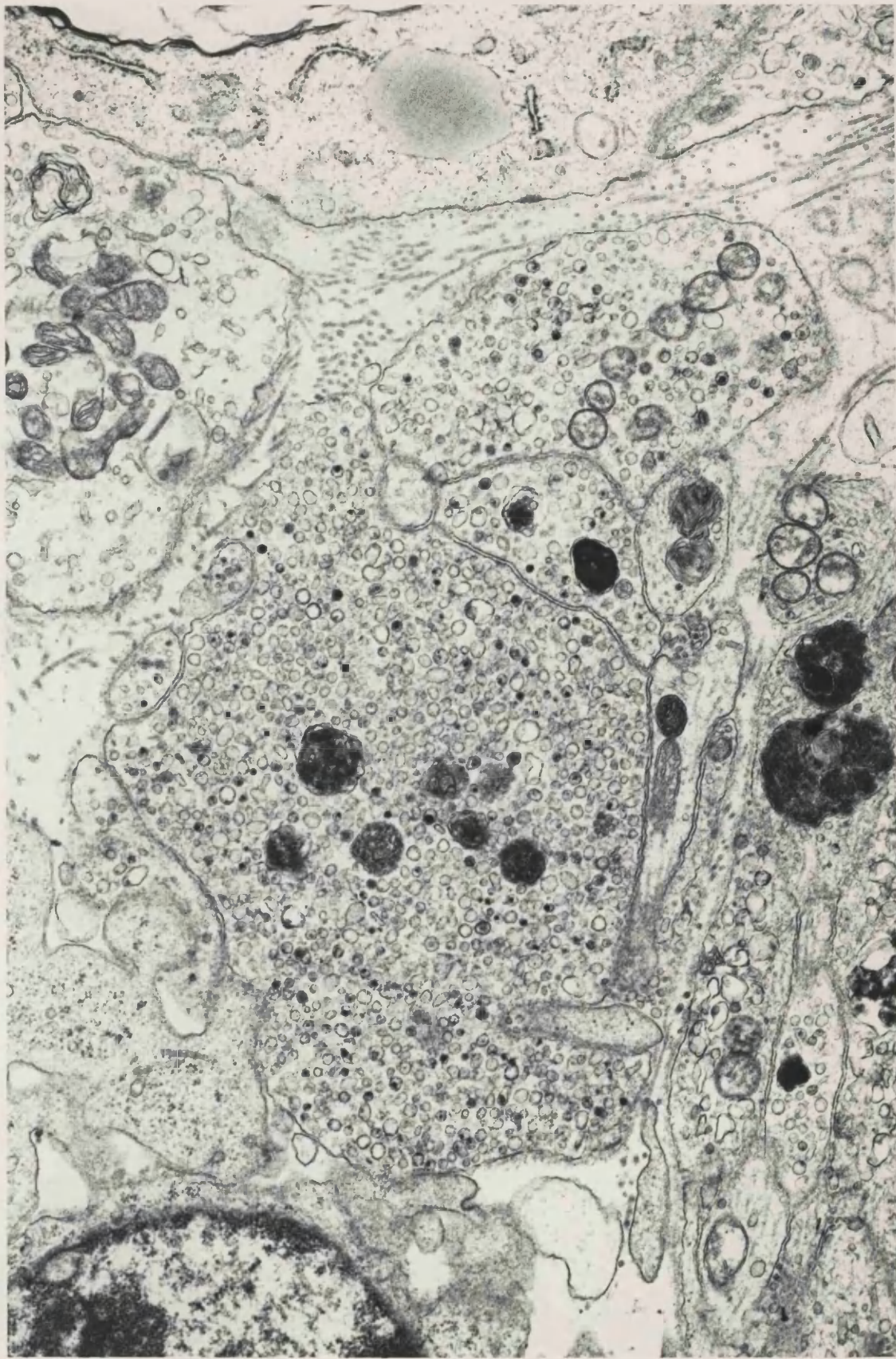
**FIGURE 110** 3 day old neuroma, distal 1mm, from the same animal as Fig. 108. The appearance of this tissue is very similar to that of tissue from an animal not treated with capsaicin.

x 10 800



**FIGURE 111** 3 day neuroma, distal 1mm, from the same animal as that in Figs. 108 and 110. These sympathetic axons contain very many vesicles, both clear and 5 - OH DA labelled dcv, and appear to be unaffected by the capsaicin.

x 18 100

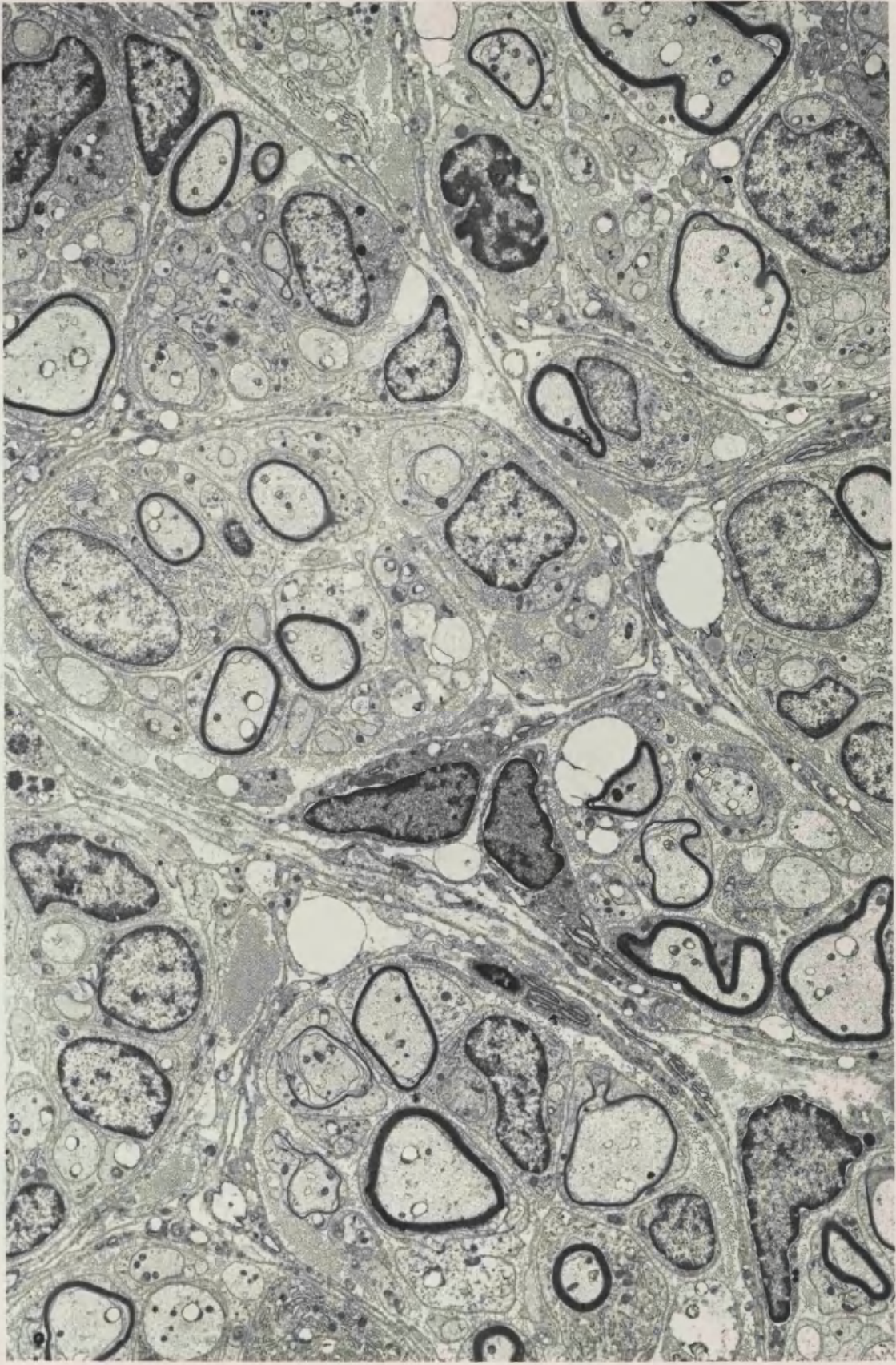




275

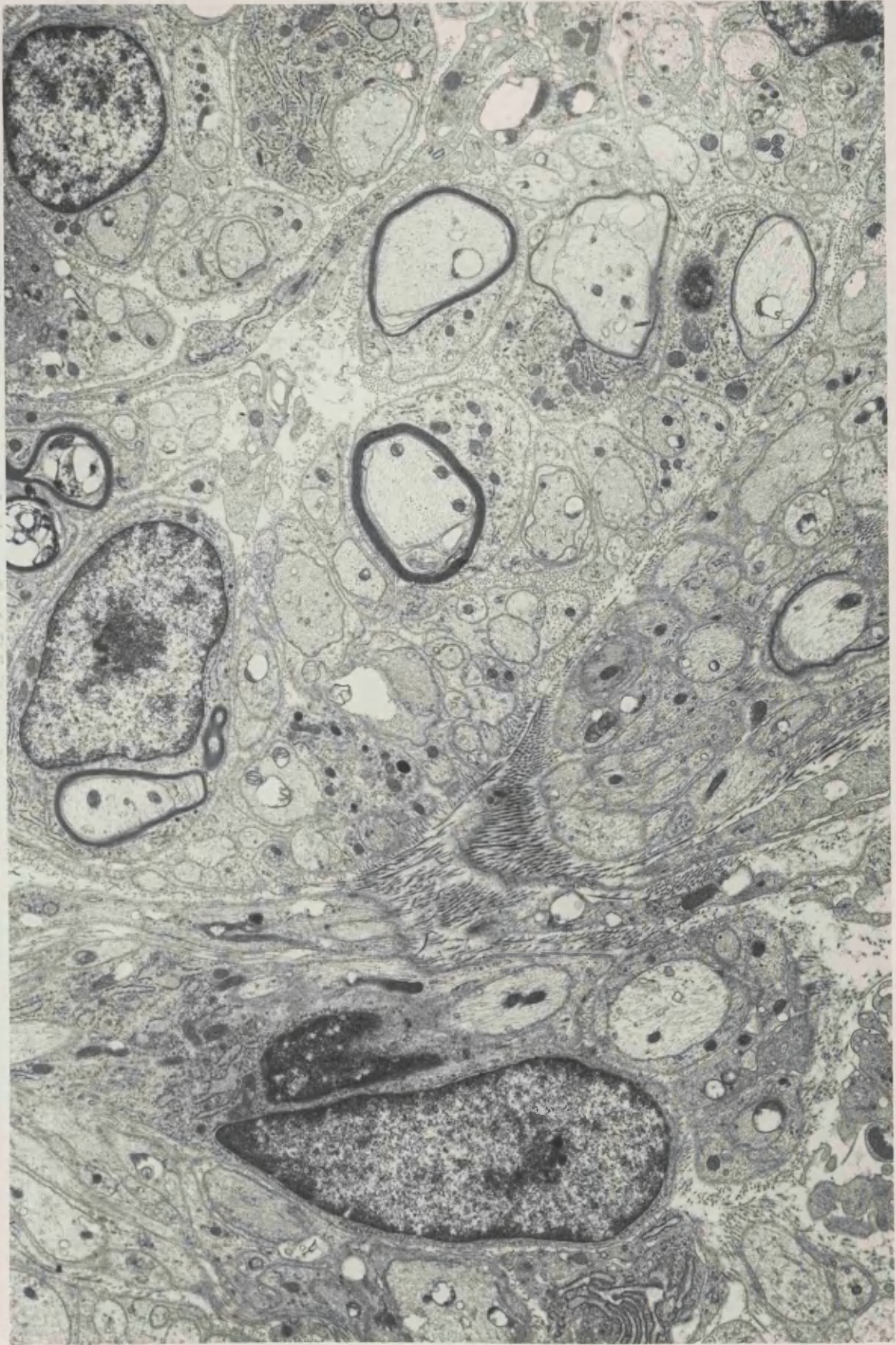
**FIGURE 112** 2 week neuroma, distal 1mm, from an animal dosed neonatally with capsaicin. New growth in the neuroma is again beginning to divide into fascicles in the same way as tissue from untreated neuromas.

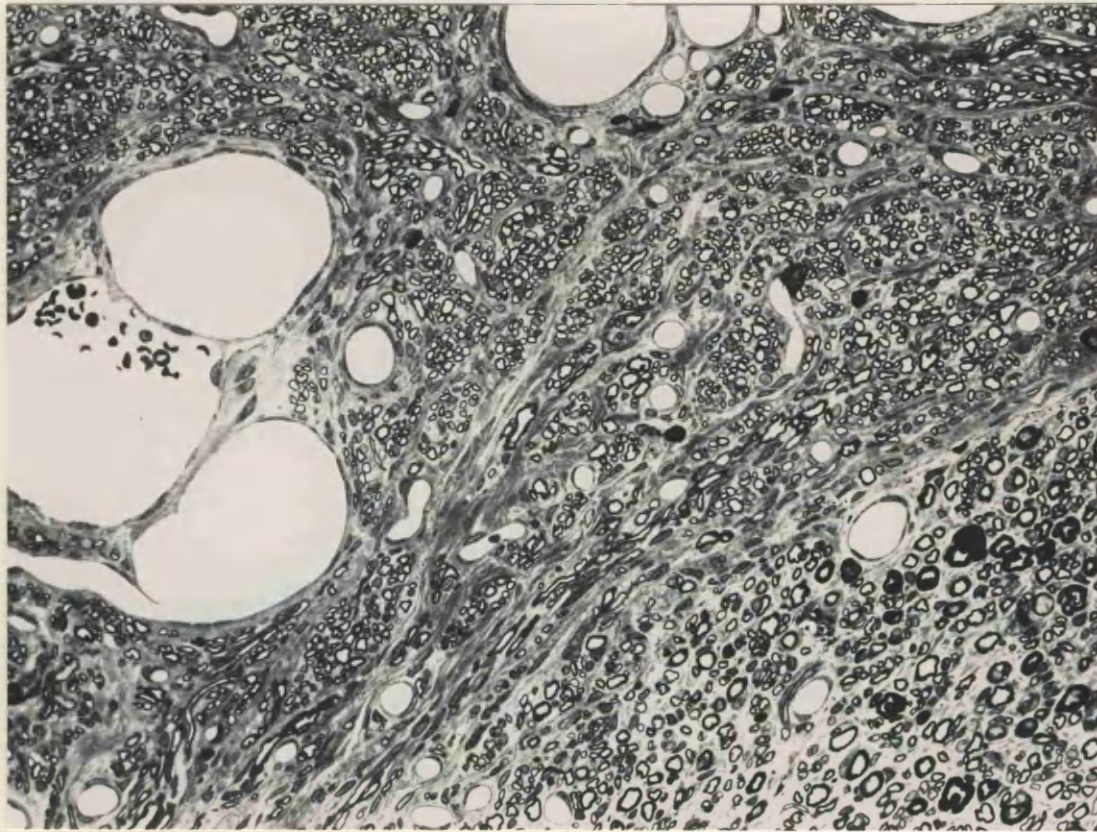
x 5 700



**FIGURE 113** 2 week neuroma, distal 1mm, from an animal dosed neonatally with capsaicin. Preatreated with nialamide and 5 - OH DA. The appearance of this tissue is very similar to that of untreated 2 week old neuromas.

x 8 300





**FIGURE 114.** Neuroma four weeks following section, 1mm from the distal tip, from an animal dosed neonatally with capsaicin. Similar to a chronic neuroma from an untreated animal. Glutaraldehyde / Resin / Toluidine blue.

x 50

**TABLE 7**  
**COUNTS OF 5-OH DA LABELLED SCHWANN CELL SUBUNITS**  
**CAPSAICIN TREATED - NORMAL NERVES**

Animal No.	Total Units	Labelled	Unlabelled	% Labelled
1	237	28	209	11.81
2	231	27	204	11.69
3	218	22	196	10.10
4	207	28	179	13.53
5	242	31	211	12.81
	$\bar{x} = 227 \pm 14.34$			$\bar{x} = 11.99 \pm 1.3$

**3 DAY NEUROMAS**

1	144	80	64	55.5
2	119	55	64	46.0

## Summary of Capsaicin Results

1. The number of Schwann cell subunits containing unmyelinated fibres were decreased by about one third in normal nerves from animals treated neonatally with capsaicin.
2. Those unmyelinated axons which remained appeared to be larger than in untreated nerves, although this change was not quantified. Small numbers of degenerate fibres were seen in the sections examined.
3. The sympathetic axon population was not affected by the capsaicin treatment, as judged by the appearance of glyoxylic induced NA fluorescence in a normal sciatic nerve.
4. In the neuromas, the number of Schwann cell subunits was again decreased by about one third.
5. There did not appear to be any change in the sympathetic axon population, and very many 5 - OH DA labelled axons and sprouts could be seen in the acute neuromas.
6. The appearance of the chronic neuromas was very similar to that of untreated animals, being compartmented into small fascicles of regenerating tissue, and it was difficult to draw any conclusions about the effects of capsaicin in these neuromas without more extensive quantitative studies.

## Materials and Methods Introduction 8

### Receptor binding studies

Noradrenaline produces pharmacological effects by reversibly binding to adrenergic receptors on the cell surface of target cells. Ahlquist (1948) proposed that there were two types of adrenergic receptor - alpha receptors, responsible for the mediation of the contraction of smooth muscle, and beta receptors, responsible for the relaxation of smooth muscle.

Alpha and beta receptors have now been subdivided further, on the basis of the relative potency of various antagonists / agonists. Lands et al (1967) divided beta receptors into two groups, and found that beta<sub>1</sub> receptors are more common in the heart and intestinal smooth muscle, and beta<sub>2</sub> receptors more common in the bronchial, uterine and vascular smooth muscle. The subdivision of alpha receptors occurred more recently, during the 1970's. Langer (1974) proposed that postsynaptic alpha receptors mediating smooth muscle contraction had a different pharmacology to presynaptic receptors, and he classified these alpha<sub>1</sub>, and alpha<sub>2</sub> respectively. It later became clear that alpha<sub>2</sub> receptors had a more widespread distribution than just presynaptic nerve terminal locations. Post-synaptic alpha<sub>2</sub> receptors were located, and the classification of alpha receptors on the basis of synaptic location was revised. The present classification is formed on the basis of the relative potencies of adrenergic antagonists. Methoxamine, phenylephrine and prazosin are efficient alpha<sub>1</sub> receptor agonists (Starke, 1981; Cambridge et al, 1977). Methyl-noradrenaline, yohimbine and clonidine are potent alpha<sub>2</sub> receptor agonists (Starke, 1981; Starke et al, 1975).

### Ligand-Receptor interaction

The direct binding assay, which was used in the experiments in this thesis involves the incubation of a suitable tissue receptor preparation with an isotopically labelled ligand. The non-bound ligand is then removed, and the bound radioactivity determined, in this case by autoradiography. The assumption is made that the ligand-receptor binding is a reversible bimolecular reaction, which at equilibrium obeys the Law of Mass Action. An initial assay will help to determine



the optimum concentration of labelled ligand to yield the highest ratio of specific: non-specific binding. The degree of non-specific binding increases with concentration of ligand. Specific binding sites are saturable, whereas non-specific sites are not. Specific ligand-receptor binding is also a reversible competitive type of binding, and addition of excess non-radioactive ligand will displace some of the bound radioactivity.

Determination of optimum binding conditions must always be performed by a saturation experiment before any other studies are commenced. Sets of pairs of test tubes are set up in which a fixed amount of tissue preparation is incubated with increasing concentrations of the radioactive ligand in the presence or absence of an excess of non-radioactive drug. In the presence of an excess of non-radioactive drug (displacer), the degree of non-specific binding can be determined. In the absence of displacer, the total binding can be determined. From these two figures, specific binding at various concentrations can be determined, and thus the optimum concentration of radioactive ligand determined, in order that the ratio specific:non-specific binding is maximised. The specific binding at each concentration of ligand can be calculated, as can the equilibrium dissociation constant ( $K_d$ ) and binding site density ( $B_{max}$ , Hrdina, 1986).

The concentrations of radioactive ligand used are very low (up to 20nM), in order to minimize non-specific binding. If a new receptor in tissue slices is being studied, fixation parameters have to be determined carefully. The receptor must be retained at its physiological site, but not over fixed so that its activity is lost.

## **Materials and Methods 8**

### Autoradiography

The left sciatic nerves of 14 adult Wistar rats weighing between 170-200g, were sectioned as previously described. Between 17 and 24 days after section, 10 animals were reanaesthetized and perfused briefly with a rinse of normal saline to clear the vessels of blood. 8 animals were then perfused with 0.1, 1 or 2% paraformaldehyde in Tris buffer for 10 minutes, but 2 animals were perfused with the saline rinse only. The right sciatic nerve, left sciatic nerve with the

neuroma attached, left and right dorsal root ganglia, and lumbar region of the spinal cord were then removed and frozen in liquid nitrogen.

24 hours before killing, the L4 and L5 spinal roots of 4 animals were ligated bilaterally, and the animals perfused 24 hours later with 1% paraformaldehyde, as previously described.

12 $\mu$ m frozen sections were then cut in a cryostat, mounted onto gelatin-subbed slides and left to dry at 4°C for 1 hour, to ensure complete section-slide adherence. Slides were then allowed to warm to room temperature in a closed container to prevent condensation forming on the sections, which may result in diffusion of the receptors. Sections which were to be incubated with adrenergic alpha receptor ligands were then preincubated in 0.05M Tris buffer + 10 mM MgCl<sub>2</sub> at room temperature for 30 minutes to dissociate endogenous ligand from the receptors.

---

p.283. Autoradiographic studies.

Diprenorphine was used as an internal control for the methods, because it is known to bind specifically and reproducibly in spinal cord tissue. Idazoxan was used as another test adrenergic ligand, in addition to prazosin and para amino clonidine.

coated coverslip. Coverslips were coated under safelight conditions, by dipping into Ilford K5 nuclear gel emulsion, diluted 1:1 with distilled water, and heated to 43°C. Slides were allowed to air dry for several hours in a humidified environment in order that the emulsion would gel before drying. Coverslips were held in place aligned with 2 corners of the slide, by superglue at one end, and the prepared autoradiograms were then placed in light tight black plastic slide boxes with gelatin capsules containing silica gel, and allowed to develop for between 3-4 months at 4°C. In addition, a series of slides were placed in X-Ray cassettes, and a piece of autoradiographic film placed over them. The cassette was then stored in the dark at 4°C for 3 - 4 months.

Following the allocated exposure to photographic emulsion, autoradiograms were developed. Under safelight conditions, coverslips

neuroma attached, left and right dorsal root ganglia, and lumbar region of the spinal cord were then removed and frozen in liquid nitrogen.

24 hours before killing, the L4 and L5 spinal roots of 4 animals were ligated bilaterally, and the animals perfused 24 hours later with 1% paraformaldehyde, as previously described.

12 $\mu$ m frozen sections were then cut in a cryostat, mounted onto gelatin-subbed slides and left to dry at 4 $^{\circ}$ C for 1 hour, to ensure complete section-slide adherence. Slides were then allowed to warm to room temperature in a closed container to prevent condensation forming on the sections, which may result in diffusion of the receptors. Sections which were to be incubated with adrenergic alpha receptor ligands were then preincubated in 0.05M Tris buffer + 10 mM MgCl<sub>2</sub> at room temperature for 30 minutes to dissociate endogenous ligand from the receptors.

All sections were then covered with 0.4ml of one of the 4 ligand solutions - either tritiated 3nM diprenorphine, idazoxan (Amersham International), prazosin or paraminoclonidine (Du Pont), for 60 minutes at room temperature. Control sections were covered with non-tritiated ligand. Slides were quickly washed in 2 x 1 minute changes of 0.05mM Tris buffer at 4 $^{\circ}$ C, followed by a very brief dip in distilled water at 4 $^{\circ}$ C to remove any buffer salts, and rapidly dried by chilled dessicated compressed air to prevent receptor-ligand diffusion. Slides were then left to dry overnight at 4 $^{\circ}$ C, and photographic emulsion applied on a coated coverslip. Coverslips were coated under safelight conditions, by dipping into Ilford K5 nuclear gel emulsion, diluted 1:1 with distilled water, and heated to 43 $^{\circ}$ C. Slides were allowed to air dry for several hours in a humidified environment in order that the emulsion would gel before drying. Coverslips were held in place aligned with 2 corners of the slide, by superglue at one end, and the prepared autoradiograms were then placed in light tight black plastic slide boxes with gelatin capsules containing silica gel, and allowed to develop for between 3-4 months at 4 $^{\circ}$ C. In addition, a series of slides were placed in X-Ray cassettes, and a piece of autoradiographic film placed over them. The cassette was then stored in the dark at 4 $^{\circ}$ C for 3 - 4 months.

Following the allocated exposure to photographic emulsion, autoradiograms were developed. Under safelight conditions, coverslips

were eased from the slides with fine forceps and a piece of orange stick inserted under the coverslip to allow access of the developer. They were then developed in Ilford D19 developer, diluted 1:1, at 20°C for 2 minutes. Slides were then washed in distilled water for 30 seconds as the stop bath, and fixed by 2 x 5 minute changes of 25% sodium thiosulphate solution. They were then washed with 2 x 5 minute changes of tap water, followed by 2 x 5 minute changes of distilled water.

The slides with the tissue sections were fixed for 30 minutes in 4% paraformaldehyde in 0.1M phosphate buffer, then washed with 3 x 10 minute changes of phosphate buffer. Sections were then stained with 1% toluidine blue, dehydrated, and mounted with DPX mountant.

Details of the image analysis protocols are given in Appendix 2.

p.285.

Unfortunately, no DRG sections were available for counting, because in all cases one of a matched pair had been lost during processing. The DRG would have been the best site in which to look for increased adrenergic receptors, since it contains the cell bodies i.e. the synthetic sites for sensory axons.

been reacted with [ $^3$ H] diprenorphine. Labelling was seen in the substantia gelatinosa, laminae I and II of the dorsal horn, on both the left and right sides (Fig. 115). This pattern of labelling was seen on both the autoradiographic film and also on the emulsion coated coverslips. The area of labelling corresponded to the termination zone of primary afferent sensory fibres. When the coverslips and the film were subjected to quantitative image analysis, the left substantia gelatinosa consistently displayed lower density silver grain labelling, measured as field detected area, than the contralateral right side (Tables 8 and 8A), although there were some exceptions. The left side of the dorsal horn received inputs from the damaged peripheral nerve, and so there was probably a decrease in the opiate receptor density over the s.g. which received input from the lesioned peripheral nerve. A very low density of silver grains was seen on the control slides to which unlabelled diprenorphine had been applied (Fig. 116).

#### ii) PERIPHERAL NERVE

Any changes seen in the peripheral nerves examined were more complex to interpret. In all nerves, there was a higher density of labelling over the sectioned left sciatic nerve than over the intact right nerve (Table 9, Figs. 117 and 118). This was true of the pharmacological control slides as well as the slides to which the radioactive ligand had been applied. The neuromas contained a large amount of connective tissue, especially towards the distal tip, and it was possible that this tissue had a high affinity for non-specific binding. The silver grains formed an artefactual outline of the tissue around the perineurium, where the connective tissue was heavily concentrated. The labelling over the distal tip of the neuroma was also often very heavy, but patchy, resembling the pattern of cellular labelling, however it was concluded that this pattern of labelling was probably artefactual in this situation, since it was unlikely that it

## Results 8. AUTORADIOGRAPHY

There was no appreciable labelling, identified as dense silver grains, seen in the sections reacted with idazoxan or prazosin, either in spinal cord or peripheral nerve.

### A. DIPRENORPHINE - i) SPINAL CORD

High density silver grain labelling was seen on sections which had been reacted with  $^3\text{[H]}$  diprenorphine. Labelling was seen in the substantia gelatinosa, laminae I and II of the dorsal horn, on both the left and right sides (Fig. 115). This pattern of labelling was seen on both the autoradiographic film and also on the emulsion coated coverslips. The area of labelling corresponded to the termination zone of primary afferent sensory fibres. When the coverslips and the film were subjected to quantitative image analysis, the left substantia gelatinosa consistently displayed lower density silver grain labelling, measured as field detected area, than the contralateral right side (Tables 8 and 8A), although there were some exceptions. The left side of the dorsal horn received inputs from the damaged peripheral nerve, and so there was probably a decrease in the opiate receptor density over the s.g. which received input from the lesioned peripheral nerve. A very low density of silver grains was seen on the control slides to which unlabelled diprenorphine had been applied (Fig. 116).

### ii) PERIPHERAL NERVE

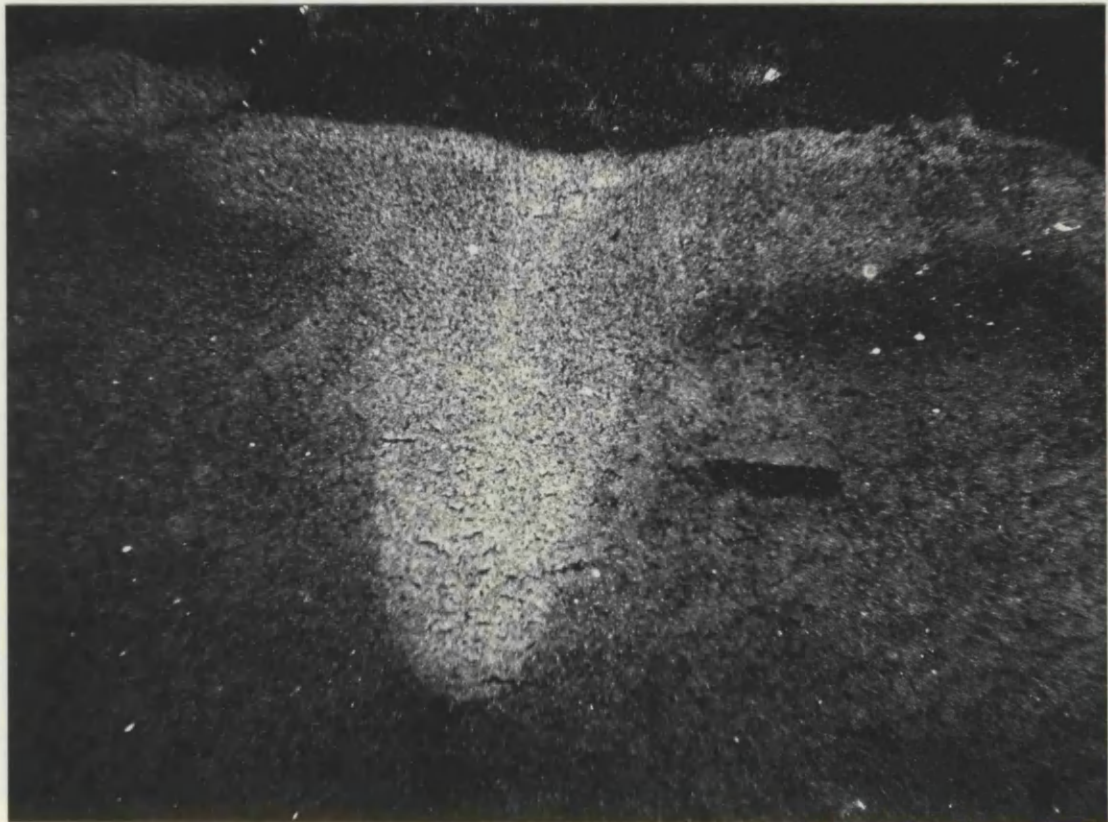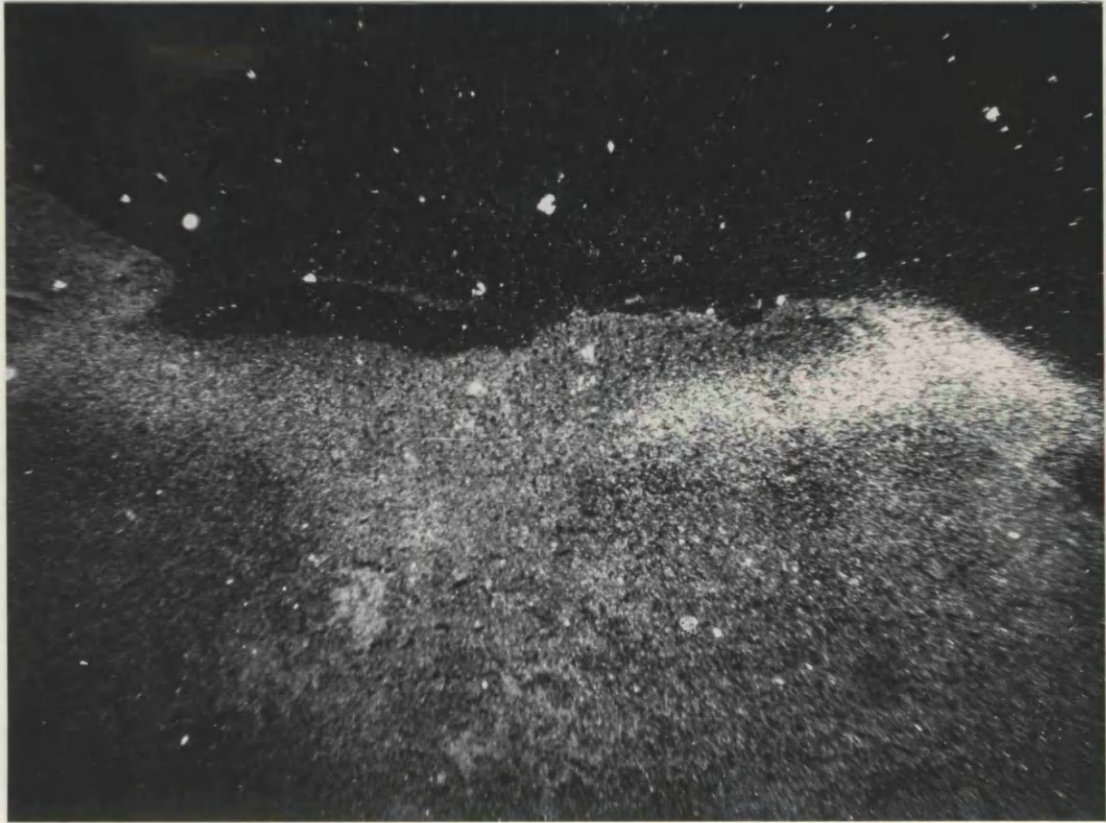Any changes seen in the peripheral nerves examined were more complex to interpret. In all nerves, there was a higher density of labelling over the sectioned left sciatic nerve than over the intact right nerve (Table 9, Figs. 117 and 118). This was true of the pharmacological control slides as well as the slides to which the radioactive ligand had been applied. The neuromas contained a large amount of connective tissue, especially towards the distal tip, and it was possible that this tissue had a high affinity for non-specific binding. The silver grains formed an artefactual outline of the tissue around the perineurium, where the connective tissue was heavily concentrated. The labelling over the distal tip of the neuroma was also often very heavy, but patchy, resembling the pattern of cellular labelling, however it was concluded that this pattern of labelling was probably artefactual in this situation, since it was unlikely that it

**FIGURE 115.** Binding sites of tritiated diprenorphine in spinal cord tissue from an animal with a neuroma from the left sciatic nerve, sectioned 21 days previously. Opiate receptors in the substantia gelatinosa are labelled bilaterally with silver grains. The density of labelling is clearly heavier on one side (right). Paraformaldehyde / Cryostat section / Dark field.

x 195

**FIGURE 116.** Control autoradiogram of spinal cord tissue exposed to diprenorphine+. From the same animal as Fig. 115. No labelling is present in the substantia gelatinosa. The central bright area is from the background tissue section. Paraformaldehyde / Cryostat section / Dark field.

x 195



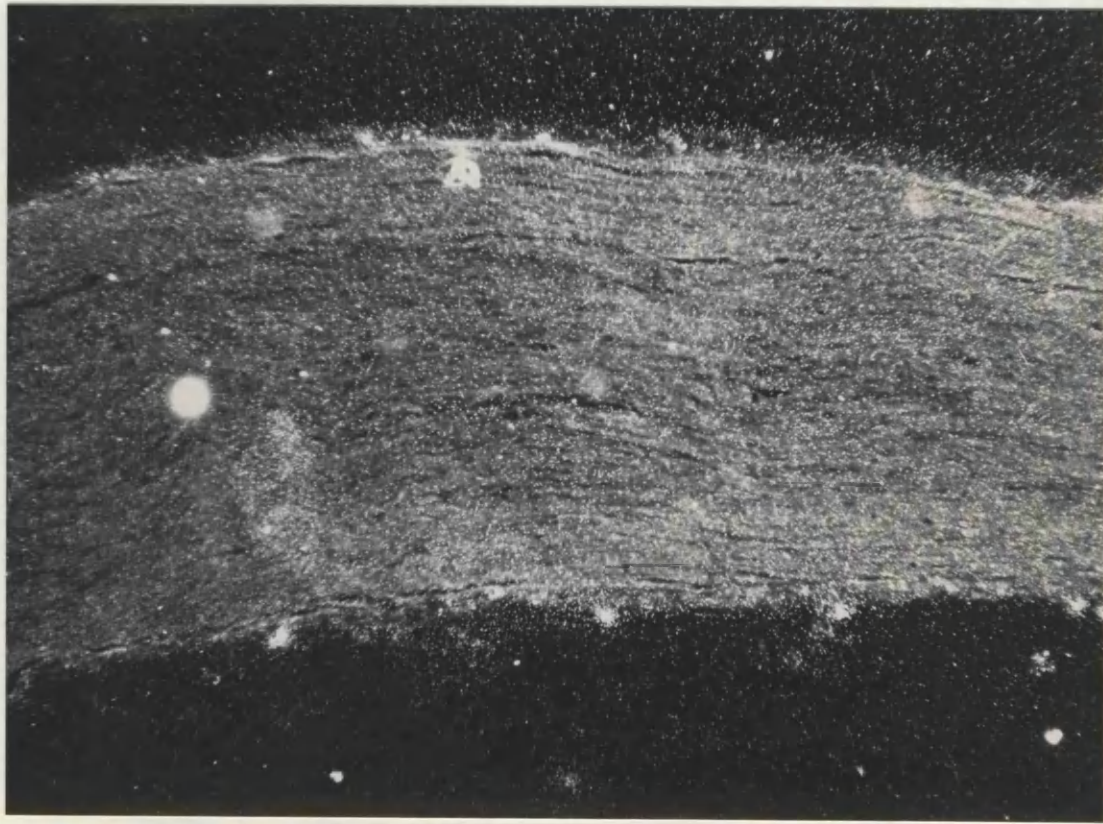


**FIGURE 117.** Binding sites of tritiated diprenorphine in the distal tip of a 21 day old neuroma. The axons in the central area of the micrograph appear to express opiate receptors and are labelled with silver grains. (The distal tip of the neuroma is towards the bottom of the page). Paraformaldehyde / Cryostat section / Dark field.

x 300

**FIGURE 118.** Binding sites of tritiated diprenorphine in normal sciatic nerve. Apart from some artefactual labelling along the epineurium of the nerve, there does not appear to be any labelling of opiate receptors. The density of silver grains across the nerve appears to be the same as that in the non-tissue background. Paraformaldehyde / Cryostat section / Dark field.

x 300



would have a morphological correlate in the tissue examined. Areas to be analyzed by quantitative analysis were selected in parts of the distal area of the neuroma where grain density was more homogenous. Although both the pharmacological controls and the experimental tissue which had been exposed to the radioactive ligand displayed higher grain densities over the neuromatous tissue, the differential between grain density in the neuroma and normal right sciatic nerve was much larger on the slides exposed to the radioactive ligand.

If the measurements of silver grain densities were pooled for each animal and the means calculated, the standard deviations were much larger for the sections of peripheral nerve than for spinal cord, in some cases of a similar size to the mean (Table 9). This made statistical analysis difficult and unreliable.

#### B. PARA AMINO CLONIDINE - i) SPINAL CORD

High density labelling of adrenergic receptors was seen in the dorsal horn substantia gelatinosa, in a similar pattern to that following exposure to tritiated diprenorphine (Fig. 119). However, when the density of silver grains was analysed, it was found that generally there was a higher density of labelling in the left substantia gelatinosa as compared to the right (Tables 10 and 10A), exactly the reverse of the situation which was seen with in the opiate receptor ligand experiments. This change was reproduced on both the coverslips and the film when analyzed. No labelling was seen in the pharmacological controls.

#### ii) PERIPHERAL NERVE

Again, the situation was more complex than that seen in the spinal cord experiments, higher silver grain densities being seen on all neuromas whether reacted with the radioactive ligand or not. However, the differential in labelling densities between the left and right sciatic nerves was much higher on the sections which had been exposed to the tritiated para amino clonidine (Table 11). These differentials were also much larger than those measured with the diprenorphine ligand. Therefore, it seems likely that there is a higher concentration of adrenergic receptors in neuromatous tissue than in normal peripheral nerve (Figs. 120 and 121). The appearance of the normal peripheral nerve with tritiated para amino clonidine was very similar to that with tritiated diprenorphine (Fig. 118)

**FIGURE 119.** Binding site map of tritiated para amino clonidine in spinal cord from the same animal as Fig. 115. High densities of  $\alpha_2$  adrenergic receptors can be seen in the substantia gelatinosa bilaterally. There also appear to be receptors in lamina X. Paraformaldehyde / Cryostat section / Dark field.

x 195

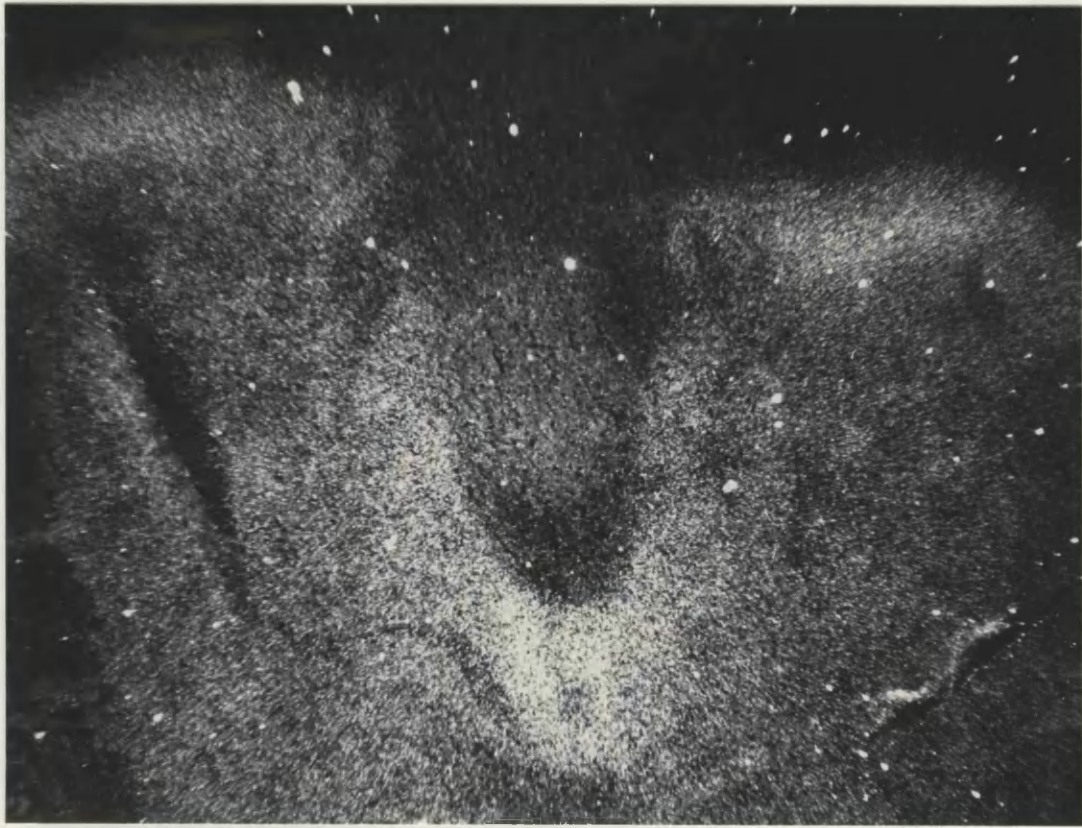**FIGURE 120.** Binding sites of tritiated para amino clonidine at the distal tip of a 21 day old neuroma. Some of this highly dense labelling is almost certainly artefactual and related to the amount of connective tissue in this area of the neuroma (Fig. 62). However, the more homogenous area to the left of the very tip of the neuroma seems to contain a high density of  $\alpha_2$  adrenergic receptors. Paraformaldehyde / Cryostat section / Dark field.

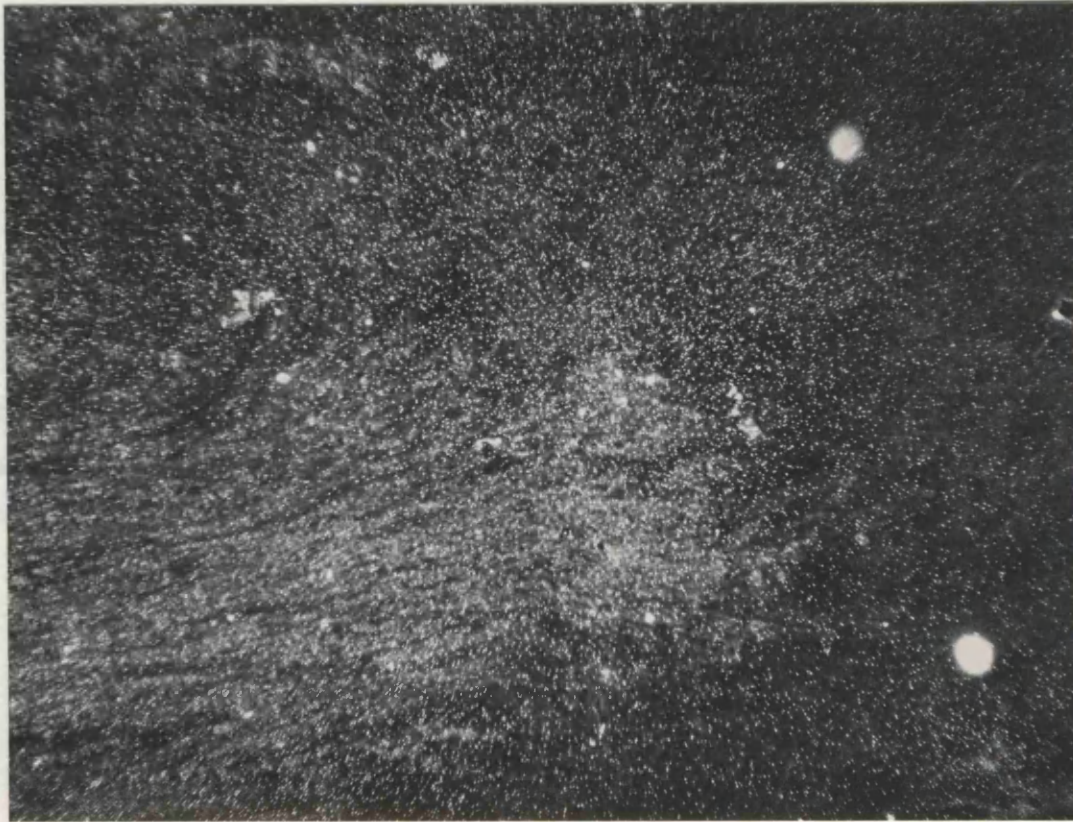x 195

---

p.292.

It is difficult to draw conclusions from labelling in this spinal cord section, since it comes from the level of L1/L2, and therefore would not be expected to receive afferent inputs from the lesioned sciatic nerve.





**FIGURE 121.** Binding sites of tritiated para amino clonidine at the distal tip of a 21 day old neuroma (different animal to that in Fig. 120). The distal tip of the neuroma is to the right. High densities of  $\alpha_2$  adrenergic receptors can be seen over the axons in the centre of the micrograph. Paraformaldehyde / Cryostat section / Dark field.

x 300

---

p.294.

"Counts" refers to silver grain densities, not counts of individual silver grains.



**AUTORADIOGRAPHY RESULTS**

Each number represents the mean of 3 repeated counts on 1 section

**TABLE 8: Film Counts - Spinal Cord**  
DIPRENORPHINE (OPIATE RECEPTOR BINDING)

Animal	Left S.G.*	Right S.G.	Control (non S.G)
1	259.5	258.75	15.00
	419.63	391.13	112.5
	$\bar{x}$ 339.56	324.94	63.75
2	251.63	288.75	20.63
	214.5	568.13	57.75
	559.5	693.38	149.63
	$\bar{x}$ 341.88	516.75	76.00
	$\pm$ 189.38	207.15	86.4
3	196.25	228.00	0.75
	290.25	371.75	38.25
	304.5	321.25	12.00
	$\bar{x}$ 263.58	307.00	17.00
	$\pm$ 58.73	72.93	19.24

\* S.G. = substantia gelatinosa

Each number represents the mean of 3 sampled areas on 1 section

**TABLE 8A: Slide Counts - Spinal Cord**

DIPRENORPHINE (OPIATE RECEPTOR BINDING)

Animal	Left S.G.	Right S.G.	Background (non-tissue)
1	1384.25	1413.00	
	1521.50	2318.5	
	1663.75	3926.5	
	$\bar{x}$ 1523.17	2552.67	50.25
	$\pm$ 139.76	1273.00	
2	1171.75	1778.25	
	693.00	1550.25	
	1254.75	2372.75	
	939.75	1649.5	
	531.25	1290.25	
	804.75	2347.5	
	$\bar{x}$ 899.21	1831.58	22.75
$\pm$ 278.99	440.07		
3	2097.5	2150.00	
	2020.75	3151.00	
	3289.75	7440.00	
	10104.50	8161.75	
	6542.00	5609.25	
	$\bar{x}$ 4807.3	5302.4	12.50
$\pm$ 3484.9	2617.51		
Control(Dip+)	$\bar{x}$ 160.25	101.00	18.75
	$\pm$ 66.41	52.63	
Control(Dip+)	$\bar{x}$ 112.75	37.75	7.25
	$\pm$ 85.78	23.53	

**TABLE 9: Slide Counts - Peripheral Nerve**

DIPRENORPHINE (OPIATE RECEPTOR BINDING)

Animal	Normal (Right) nerve	Neuroma (Left) nerve	Background
1	351.25	1568.0	
	456.0	1334.75	
	395.75	4458.75	
	383.75	1523.75	
	661.0	2295.5	
	416.25	998.5	
	$\bar{x}$ 444.0 + 111.86	2029.88 1263.84	50.25
2	145.25	1339.75	
	487.75	1176.0	
	120.75	945.5	
	400.25	1554.75	
	481.75	579.75	
	555.25	690.0	
	$\bar{x}$ 365.17 + 186.59	1047.63 378.48	22.75
3	152.75	530.75	
	253.0	563.0	
	588.25	428.25	
	$\bar{x}$ 331.33 + 228.07	507.33 70.36	12.5
Controls (Dip+)	159.75	1050.5	
	352.0	849.5	
	272.0	789.75	
	$\bar{x}$ 272 + 100.9	896.58 136.6	18.75

TABLE 9 (continued)

Animal	Normal (Right) nerve	Neuroma (Left) nerve	Background	
4	513.0	771.75		
	174.25	1459.25		
	377.75	1938.75		
	644.00	497.75		
		2032.00		
	$\bar{x}$	427.375	1339.9	12.5
	+	200.449	686.272	
5	141.5	1063.5		
	369.25	89.5		
	88.25	235.25		
	1115.50	799.5		
	291.25	745.5		
	347.25	1630.25		
	$\bar{x}$	392.167	760.5833	8.5
+	371.789	561.45		
Controls (Dip+)	182.25	82.0		
	218.50	71.58		
	56.00	511.75		
	$\bar{x}$	152.25	221.777	7.25
+	85.303	251.178		
2	157.5	55.5	7.25	
	16.0	33.5		
	106.25	32.25		
	$\bar{x}$	93.25	40.417	
+	71.64	13.077		

**TABLE 10: Film Counts - Spinal Cord**

CLONIDINE (ADRENERGIC RECEPTOR BINDING)

Animal	Left S.G.	Right S.G.	Control (non S.G.)
1	181.25	117.00	26.25
	211.50	123.38	0.38
	281.25	199.13	9.00
	$\bar{x}$ 224.63	146.5	11.88
	+ 51.36	45.69	13.18
2	212.25	103.88	0.0
	241.25	118.88	0.0
	181.5	33.0	0.0
	$\bar{x}$ 211.67	85.25	0.0
	+ 29.88	45.87	0.0
3	105.38	142.5	11.25
	85.5	162.75	163.13
	67.13	74.63	10.13
	$\bar{x}$ 86.0	126.63	61.5
	+ 19.13	46.16	88.01
4	793.8	627.38	652.5
	714.75	669.75	460.13
	$\bar{x}$ 754.31	648.56	556.31
5	620.75	422.25	183.5
	585.25	405.5	54.75
	$\bar{x}$ 603.00	413.88	119.13

**TABLE 10A: Slide Counts - Spinal Cord**  
**CLONIDINE (ADRENERGIC RECEPTOR BINDING)**

Animal	Left S.G.	Right S.G.	Background (non-tissue)
1	5338.31 4523.44	3667.13	
	$\bar{x}$ 4930.88 $\pm$ 576.2	3667.13 522.76	6.75
2	3107.06 6492.00 3880.31	2895.19 4114.69 3030.56	
	$\bar{x}$ 4493.13 $\pm$ 1773.73	3346.81 668.44	11.25
3	$\bar{x}$ 4228.69 $\pm$ 422.69	1622.25 230.16	29.50
Control(Clom+)	50.81 18.94		
	$\bar{x}$ 34.87 $\pm$ 22.54		18.25
Control(Clom+)		$\bar{x}$ 29.81 $\pm$ 29.84	4.00

TABLE 11: Slide Counts - Peripheral Nerves

CLONIDINE (ADRENERGIC RECEPTOR BINDING)

Animal	Normal (Right) nerve	Neuroma (Left) nerve	Background
1	877.0	5146.25	
	1039.5	3954.75	
	4910.0	8839.27	
	250.0	15532.17	
	739.75	17146.53	
	158.75	19598.8	
	$\bar{x}$ 1329.17 $\pm$ 1788.44	11702.96 6600.99	6.75
2	1938.0	4190.75	
	744.5	5191.5	
	2863.25	5378.75	
	3261.5	17006.77	
	2016.25	15726.53	
	4013.0	30220.53	
	$\bar{x}$ 2472.75 $\pm$ 1151.36	12952.47 10165.43	11.25
3	1163.25	3338.5	
	474.0	4358.5	
	1533.0	2968.75	
	$\bar{x}$ 1056.75 $\pm$ 537.47	3555.25 719.78	29.5
Control (Clon+)	1325.25	1640.75	
	1039.5	1813.25	
	4910.0	940.75	
	$\bar{x}$ 2424.92 $\pm$ 2156.68	1464.92 462.06	7.25

## Summary of Autoradiography Results

Opiate and adrenergic receptors were localised in spinal cord, normal peripheral nerves and neuromas following incubation with tritiated ligands and autoradiography.

1. High density silver grain labelling, corresponding to opiate receptor populations, was seen bilaterally in the substantia gelatinosa of the spinal cord in tissue sections incubated with tritiated diprenorphine. Quantitative studies on films and coverslips suggested that this labelling was depleted in the left s.g. in animals whose left sciatic nerves had been sectioned, probably due to degeneration of the afferent terminals in this region following axotomy of the peripheral nerve.

2. Changes in opiate receptor labelling in the peripheral nerves were more difficult to interpret, because the silver grain density counts were very variable. However, the labelling in the neuromas was much heavier than that in the normal nerves. There appeared to be some artefact at the very tip of the neuromas, but further proximally there was more homogeneous dense labelling.

3. The pattern of labelling seen in spinal cord sections exposed to tritiated para-amino clonidine was similar to that seen with diprenorphine, but there seemed to be an increase in adrenergic receptor labelling over the left side of the s.g. which received inputs from the lesioned peripheral nerve.

4. The changes in the peripheral nerves were again similar to those seen following diprenorphine labelling, but the difference in silver grain densities between the normal nerves and the neuromas were much more pronounced. Very dense silver grain labelling was seen over the distal tips of all sections of the neuromas, and it seems likely that there was a higher concentration of adrenergic receptors in the neuromas than in the contralateral normal nerves.



## Discussion 1 TECHNICAL CONSIDERATIONS

### A. FLUORESCENCE

Originally, the same technique was intended to be used for both fluorescent localization of sympathetic axons and then ultrastructural localization on serial sections. The first method tried was fluorophore production by reaction with FAGLU solution (Furness et al, 1978). This fixative was tried both by perfusion and immersion fixation. Section cutting on a vibratome was unsuccessful since peripheral nerve has a great deal of connective tissue, and although longitudinal sectioning of normal nerve was just possible, neuromas were impossible to section. Transverse sectioning was also impossible because of the nature of the tissue. It was feasible to use frozen sections cut in a cryostat if the nerve was embedded in liver or a similar homogenous tissue for mechanical support, but even with cryoprotectant infiltration, a large degree of freezing artefact was introduced, which was unacceptable for ultrastructural studies. Some fluorescent axons were seen in cryostat sections, but these were dim and very sparse, however autofluorescent structures such as mast cells and elastin were seen in blood vessels. The fluorescent product was not improved by pretreating animals with L-Dopa, even though the sympathomimetic effects of this drug were seen shortly after the animal was dosed. There was a high degree of background fluorescence too, due to glutaraldehyde component of mixture. Virtually no fluorescent axons were seen in acute neuromas, either following ligation or nerve section. The technique did produce fluorescence with catecholamines if present in relatively high concentrations, since in the mesentery and artery stretch preparations and the adrenal medullae, fluorescent axons and cells could be seen. However, this method was not suitable for the detection of NA sympathetic axons in mixed peripheral nerve, where the NA concentration is low.

Ultrastructurally, the FAGLU mixture gave generally good preservation of tissue, but the dcv in sympathetic axons were not distinctive. Dcv were denser in acute neuromas, but it was not possible to identify sympathetic axons in normal sciatic nerve. Therefore the FAGLU method was rejected, even though it was the only possibly suitable method for examination of tissue by both fluorescence and

subsequently electron microscopy.

It was decided not to try the Falck-Hillarp technique for catecholamine fluorescence production because this method is laborious. An immunofluorescence technique using anti-DBH as the primary antibody and FITC as the fluorescent label proved suitable for localization of sympathetic axons in both normal and neuromatous tissue, but again this would have been unsuitable for a large quantitative study: overnight incubations with the primary antibody were required, and the maximum numbers of sections processed at any one time was 10-20. Not all the processed sections were suitable for use, because drying out of a few sections overnight occurred. Sections processed for immunofluorescence were unsuitable for electron microscopy because cryostat sections had been cut. In addition, the tissue could not be fixed with glutaraldehyde because this would destroy the immunoreactivity of the DBH enzyme. The fluorescent product was not very stable in the microscope light beam and did not store well.

Glyoxylic acid was then tried as a fluorophore, either by perfusion with a 2% solution in phosphate buffer or incubation in the solution for 1.5 hours. The fluorophore was developed by drying the sections, but with little success. A modified version of the original glyoxylic acid method, the SPG method of De la Torre and Surgeon, 1976, (1% glyoxylic acid and potassium phosphate and sucrose) worked extremely well, and proved to be a highly specific and sensitive technique. Many very bright sympathetic axons were seen fluorescing in normal sciatic nerves, and large quantities of fluorescent material were seen in the neuromas. There were similar patterns of fluorescence to those seen following immunocytochemistry with FITC, but the glyoxylic acid fluorescence appeared to be more specific; the sympathetic axons were thinner, and the varicosities more pronounced. Individual axons were also brighter, and appeared to be more numerous, although this may have been the effect of the brighter fluorescence. Very thin sprouts were visible in the neuromatous tissue. The fluorophore was relatively stable in the ultraviolet beam, and, if stored in a closed box in a refrigerator, kept well for several months. The technique was also very quick to use, taking 20 minutes from section cutting to viewing the finished slide in the microscope.

However, there were drawbacks. The brightness of the background was variable, sometimes appearing too bright, and obscuring any catecholamine fluorescence which may have been produced. The reason for this was

unclear, and seemed to be a vagary of the drying process. Sections therefore had to be checked in the microscope after each batch had been cut and reacted, which was time consuming. The treatment of tissue in this technique also made it totally unsuitable for subsequent ultrastructural use. The tissue was unfixed, and then frozen prior to cryostat sectioning, and the subsequent immersion in glyoxylic acid solution seemed to destroy the background tissue detail. There was therefore no suitable technique which bridged the gap between fluorescence and electron microscopy, and so parallel experiments were carried out.

## B. ULTRASTRUCTURE

Fixation with conventional fixatives produced non-distinctive sympathetic axons. The dcv did not have particularly dense cores, even following osmication. Fixation with chromium buffered fixatives improved the density, but generally, because of the low concentrations of NA in mixed peripheral nerve, pharmacological manipulations were required in order to be able to identify sympathetic axons with any confidence. Treatment with 5-OH DA produced very dense-cored vesicles in acute neuromas, where the overall concentration of NA was high. Each vesicle may have had a higher than normal content of NA, and there were increased numbers of dcv, but labelling in chronic neuromas and normal nerves was equivocal. There was some labelling of dcv in normal nerves and chronic neuromas, but this did not seem reliable. If the animals were treated with nialamide before 5-OH DA, then it was possible to identify sympathetic axons in normal nerves and chronic neuromas.

If, following this treatment, fixation was accomplished with a chromium buffered fixative, then very strikingly dense dcv were seen in both normal nerves and acute and chronic neuromas. Labelled dcv were also identifiable at relatively low magnifications. The identity of any putatively labelled axon could be confirmed by X-Ray analysis. It was possible to localise chromium, and therefore NA, in a single dcv in an axon. There was, however, a low residual background signal because chromium was included in the primary fixative, and therefore probably became bound to some proteins during the glutaraldehyde fixation step. The chromium fixative was suitable for use after treatment of the animals with 5-OH DA because dopamine also precipitates chromium in the dcv. Chromium was also detectable from the dense granules in platelets because the 5-HT content reacts similarly to other catecholamines.

Even after the use of all three factors, nialamide, 5-OH DA and chromium fixation, not all of the sympathetic axons in the tissue can be identified. This is for the reasons given earlier in the results section, namely that the NA is contained in dcv in terminal varicosities in the axon, and one of these varicosities would not always appear in the plane of section examined. The concentration of NA in the axon between these varicosities is very low. If a constriction is made in the nerve, the dcv which flow via axonal transport in a proximo-distal direction are 'dammed up' and more axons can be identified. A ligature tied around the nerve for an hour before fixation may assist in the identification of sympathetic axons, without inducing gross degenerative changes.

### C. AUTORADIOGRAPHY

The radioactive ligands used in these experiments were of relatively low activity, especially the alpha adrenergic ligands, therefore long exposure times were required for the autoradiogram to develop. Because of this factor, the assessment of technical improvements was a lengthy process.

The photographic emulsion had to be superimposed over the tissue on coated coverslips because the slides could not be directly dipped into the emulsion. This was because the tissue was only lightly fixed, in order to retain receptor activity, and the receptors would quickly diffuse away from their original site in the emulsion solution. The coverslips were only attached to the slides at one end with superglue, so that they could be lifted slightly, but remain attached during photographic development. There was some movement of some coverslips during the development stage, so no conclusions could be reliably drawn about any cell body labelling, since the coverslip may have been out of register with the tissue section underneath.

There were considerable technical problems associated with the quantitative analysis of the autoradiograms. In many cases sections had become detached from the slide during processing, and so only one or two sections were available for analysis, which made assessment of the widely varying results unsatisfactory and means and standard deviations could not be calculated. Rarely, there were no sections remaining. The FDA numbers varied widely between animals, and even between sections from the same animal. In addition, slides were developed in batches following a suitable exposure time, and there was a degree of variability between the background

level of silver grain density. This made the reliability of counts dubious, and comparisons between animals difficult. Not all of the sections across a group showed the same changes, so that, for example, 5 out of 6 sections would show that opiate receptor binding was decreased in the left substantia gelatinosa, but the remaining section showed the opposite result.

Some of the variability between sizes of FDA counts could have been due to section thickness: because the normal nerves and neuromas had quite different cutting properties in the cryostat it was not possible to cut them together in one block. Slides were also developed at different times, as previously described, although as far as possible, the development schedules were identical.

All of these anomalies and artefacts considered together meant that caution had to be exercised in the statistical interpretation of the quantitative results, and confidence confined mainly to the qualitative analysis.

## Discussion

Evidence that the sympathetic nervous system is important in contributing to, and maintaining pain which may be associated with peripheral nerve damage in many patients has been discussed in depth in the introduction to this thesis. In regions of nerve damage sensory fibres develop an abnormal catecholamine sensitivity, and sympathetic block may provide relief of pain in many patients. The clinical response to sympathetic block is variable, however, and the cytochemical basis for the pathophysiology of the interaction of sensory afferent and sympathetic efferent fibres which has been demonstrated in animal experiments is uncertain.

The objective of the work described in this thesis was to examine the cytochemical nature of this abnormal interaction, specifically with regard to the morphology of sympathetic efferent fibres in developing neuromas following the section of a peripheral nerve.

The first problem addressed was whether numbers of sympathetic efferent (NA) axons vary with time after section, in particular whether there was a gradual reduction in numbers of fibres, as proposed by Janig and McLachlan (1984).

### Fluorescence studies

This problem was addressed by means of a fluorescence microscope study because much larger areas of the nerves and neuromas could be sampled by this method in comparison with an ultrastructural study. It was not practical to cut serial sections and count all the fluorescent axons in the nerves, so samples of every fourth section were taken. Because large areas could be sampled, any changes seen in the sympathetic fibre population as a result of nerve section were likely to be representative of the true picture. However, the resolution of a fluorescence microscope study was necessarily limited, and it was not possible to visualize unmyelinated fibres other than sympathetic axons directly, following the SPG reaction. Therefore, no conclusions could be drawn about the relationship of sympathetic efferent and other classes of fibre. The tissue from further similar experiments conducted in parallel was examined by electron microscopy in order to investigate this relationship, and these experiments will be discussed

following the fluorescence studies (page 311).

The SPG glyoxylic acid method was found to be a good technique for visualizing sympathetic axons in the fluorescence microscope, being very sensitive and enabling the study of the sympathetic axon population of normal peripheral nerves. Numerous brightly fluorescent axons were seen widely distributed across the nerve, in contrast to earlier studies which found that they were weakly fluorescent and sparsely distributed (Ohshiro et al, 1978). However, the study of Ohshiro et al employed the Falck-Hillarp method (1962), using formaldehyde gas to produce the fluorophore, which may be less sensitive than SPG as determined by the results of the present study. Earlier studies and McQuarrie et al (1978) used acute ligations in order to visualize NA in normal nerves. Normal nerves from control animals and the normal right nerves contralateral to neuromas of experimental animals had similar numbers of sympathetic axons, and it was shown that there was no difference between these populations. Therefore, sectioning the left sciatic nerve in a rat does not appear to affect the sympathetic axon population of the right sciatic nerve. McLachlan and Janig (1983) showed that in the superficial peroneal nerve of cats less than 1% of the sympathetic neurones lie in the contralateral sympathetic chain. Therefore it is unlikely that sectioning one sciatic nerve will affect the contralateral nerve.

Fluorescent material, demonstrated by the SPG method, was seen to accumulate in axons of developing sciatic nerve neuromas. Many previous studies have also shown this accumulation, using the Falck-Hillarp method (Dahlstrom and Fuxe, 1964; Dahlstrom, 1965; Dahlstrom and Haggendal, 1966; Eranko and Harkonen, 1965; Kapeller and Mayor, 1965, 1967; Boyle and Gillespie, 1968; Geffen and Rush, 1968; Laduron and Belpaire, 1968). The SPG method is specific for monoamines (de la Torre and Surgeon, 1976) and the virtually complete depletion of fluorescence by reserpine in the present study supports the conclusion that the fluorescence observed in the experimental material indeed resulted from the presence of noradrenaline. After interruption of axons by crush, ligation or section, tissue levels of noradrenaline rise due to a block in the proximo-distal axonal transport beyond the point of injury, and an initial rise in the rate of transport of amine granules to the proximal stump (Dahlstrom and Haggendal, 1970). In this study the maximum accumulation of fluorescence occurred at three days, although the timing of the absolute peak could not be determined

500

with precision as nerves were only sampled at three and seven days during the first week after nerve section. Dahlstrom and Haggendal (1970), Karlstrom and Dahlstrom (1973) and Ohshiro et al (1978) reported that the accumulation of noradrenaline proceeded linearly up to 48 hours, followed by a plateau phase lasting between 48 - 96 hours in ligation or crush experiments on rat sciatic nerves. It would be possible from the counts in the present study for the true peak value to lie between 3 and 7 days after injury ( Fig. 1), but this appears unlikely as the other studies referred to all report earlier peaks. It is therefore probable that by 3 days following section the accumulation rate has ceased to increase and is in the plateau phase reported by Karlstrom and Dahlstrom, (1973).

The cessation of noradrenaline accumulation after 48 hours is due to the reaction of the cell bodies to injury, resulting in a decrease in synthesis and transport of amine granules, rather than to a change in monoamine oxidase levels (Boyle and Gillespie, 1970) which continue to increase peripherally for up to 7 days following ligation of the sciatic nerve (Dahlstrom et al, 1969). The transmitter is membrane bound in granules and therefore is not available for metabolism (Dahlstrom and Haggendal, 1970) and the experiments of Boyle and Gillespie (1970) have shown that monoamine oxidase inhibitors administered to cats with ligated splenic nerves 4 days prior to sacrifice did not halt the decline in noradrenaline levels after 48 hours. The cell body reaction is therefore the major mechanism responsible for the cessation of noradrenaline accumulation after 48 hours. The cell bodies of damaged neurones show a net decrease in the content of certain proteins, including the monoamine oxidases and the synthetic enzymes dopamine beta hydroxylase and tyrosine hydroxylase, due to increased proteolysis (Lieberman, 1971; Grafstein, 1975). There is also a change in the pattern of protein synthesis following axotomy away from transmitter synthetic proteins in favour of structural components, which may contribute to a fall in noradrenaline synthesis (Griffith and Lavelle, 1971). Eranko and Harkonen (1965) Olson and Malmfors (1970) and Cheah and Geffen (1973) have observed such decreased noradrenaline fluorescence in the cell bodies of sympathetic adrenergic rat neurons a few days after cutting the postganglionic nerve and Karlstrom and Dahlstrom (1973) have also reported decreases in both the synthesis and transport of amine granules following axotomy.



The large numbers of fluorescent axons seen at three days following nerve section may result not only from accumulation of noradrenaline in axons which might otherwise not reach the level of visibility, but also from an increase in the actual numbers of axons present due to sprouting. In keeping with the observations in this study, McQuarrie et al (1978) reported a 75% increase in sympathetic axon counts in rat sciatic nerve at 2 weeks after tibial nerve transection and 3 days following subsequent sciatic nerve crush.

In the present study by 7 days following section, the number of fluorescing axons in the body of the nerve was much reduced. There was a 14% reduction in the number of fluorescent axons between 3 and 7 days at 0.5mm from the distal tip, and a 28% decrease for the same time period at 2.5mm from the distal tip, although these numbers are still well above normal levels. However, a fine network of regenerating adrenergic sprouts was seen distal to the original section point, but these did not feature in the counts. Counts of adrenergic axons fell rapidly to a minimum at 2 weeks, the lowest value being 59% of normal 0.5mm from the distal tip (Table 1). Between 1 - 2.5mm proximally, counts were approximately static at 80% of normal levels. Ohshiro et al (1978) found that the depletion which followed transection occurred much later than that which followed crush, with levels rising to normal 10 days after crush. The degree and length of depletion thus depends on the nature of the trauma caused to the nerve. Ligation or section of a nerve is a more severe injury, with disruption of the perineurial sheath, and in the case of section, a persistent separation of the proximal and distal parts of the nerve and a much greater effect on the cell body reaction (Gutmann and Sanders, 1943; Karlstrom and Dahlstrom, 1973).

By four weeks following injury, counts of fluorescing axons had risen significantly, particularly at the distal tip of the neuroma (Fig. 122). This increase in the distal portion may either be due to sprouting between two and four weeks, or to an increase in NA content of axons due to a rise in the rates of transport and/or synthesis. The fluorescence intensity of NA axons is related to their NA content, and regenerating sprouts are often more brightly fluorescent than their parent axons (McQuarrie et al, 1978) and therefore visible.

By eight weeks following nerve section the number of sympathetic axons in the normal nerves and neuromas did not differ significantly,

although at the distal end of the neuroma the number of sympathetic axons was slightly above normal, and at the proximal end (2.5mm from the estimated original point of section) slightly below normal. Purves (1975) studied the superior cervical ganglia of the guinea pig following crush of the cervical sympathetic trunk, and found that approximately half the neurones died 1-5 weeks after crushing the trunk. In addition, the mean number of synapses identified by electron microscopy in the ganglia decreased by 50%, 24-90 days after crush. Blumberg and Janig (1982) studied the cat superficial peroneal nerve and found that the proportion of sympathetic post ganglionic fibres which could be physiologically activated following stimulation of the lumbar sympathetic trunk decreased from 20-30% to around 7%, 100 days after nerve section and ligation. Carter and Lisney (1987) counted the number of unmyelinated axons 4-6mm proximal to the section point in rat saphenous nerves, and found that 26 weeks after nerve section, only 60% of the normal number of unmyelinated axons were present. Janig and McLachlan (1984) counted the number of cell bodies of sympathetic and sensory axons projecting via the superficial peroneal nerve about 5 months following nerve section and ligation. They found that the number of sympathetic neurones had decreased to about 31% of the values on the contralateral normal side and that the size of the cross sectional area of the cell bodies was only 76% of normal. The sensory neurone population had fallen by about half, and the cross sectional area of each cell was about 65% of the control. In contrast, Peyronnard et al (1986) counted the number of myelinated and unmyelinated axons in cut and ligated rat sural nerves 30mm proximal to the neuroma and found no change in the number of unmyelinated axons, although they could not differentiate between sympathetic efferent and afferent sensory axons. However, the species of animal and the nerves lesioned in these previous studies differed from those examined in this thesis. In addition, Janig and McLachlan (1984) report that there was no detectable catecholamine fluorescence following processing by the SPG method, in transverse sections of the 5 month old neuromas, although catecholamine fluorescence was visible in the endothelium of the surrounding blood vessels.

Neuromas examined in longitudinal section at 8 weeks following section in the present work showed a large network of fluorescent axons sprouts in the distal neuromatous tissue. It is possible that the numbers of sympathetic axons in neuromas 8 weeks following section in this study approach normal levels because of a large degree of

---

Discussion p.311

**NGF**

It is possible that the number of unmyelinated axons in the proximal stump in the tube was artificially elevated due to the stimulating effect of NGF in the environment of the closed tube. Schwann cells secrete NGF following axotomy (Korsching et al, 1986). Levels of NGF, NGF receptor expressed on Schwann cells and their respective mRNAs increase enormously when a nerve is cut (Heumann et al 1987), and this environment stimulates axonal growth. However, the oldest neuroma studied by this group was 20 days old, and levels of mRNA<sup>NGF</sup> were decreasing towards normal by this time, so the counts of Jenq and Coggeshall (1985) may not have been artificially elevated because of the enclosure of the proximal stump in a tube.

sprouting. Carter and Lisney (1987) counted axons 4-6mm from the section point, but in this work axons were counted no more than 2.5mm from the section point, so it is possible that increased sprouting at the distal tip of the neuromas accounted for the discrepancy in results. If the number of sympathetic neurones is reduced centrally, but the peripheral axons are sprouting prolifically, then it is possible that the number of fluorescent axons counted in the neuromas may be normal. A quantitative study by fluorescence microscopy cannot differentiate easily between many sprouts from one original sympathetic fibre and many original fibres, although sprouts tend to look slightly thinner. Although the counts of sympathetic axons in chronic neuromas in this work are at odds with some studies (Purves, 1975; Blumberg and Janig, 1982; Janig and McLachlan, 1984), there are other studies which agree with these results.

In an ultrastructural study of myelinated and unmyelinated axon numbers in sectioned and ligated rat sciatic nerves, Jenq and Coggeshall (1985) found that the number of unmyelinated axons in the proximal end of a sectioned nerve which was reapposed to the distal stump in a tube at the region of transection, 8 weeks following injury, was close to that in a normal nerve. The number in the distal stump was 60% of normal. Although unmyelinated afferent C fibres must also have been counted, this study closely parallels the findings of the current experiments which found that in the nerve proximal to a neuroma the numbers of sympathetic unmyelinated axons approach normal levels by 8 weeks after nerve section.

A study in preparation by Scadding, Brown and Cauthen, in which the noradrenaline content of neuromas was assayed, found that NA levels were returning towards normal by 8 weeks following section, consistent with the morphometric data.

The changes seen in the sympathetic axon population following section by fluorescence microscopy could also be detected ultrastructurally.

#### Ultrastructural studies

Sympathetic axons could be positively identified ultrastructurally following treatment of the animals with nialamide and 5-OH DA, when very dense-cored vesicles were prominent in the axoplasm of such axons.

Sympathetic axons could be identified in normal peripheral nerve but only following treatment with both nialamide and 5-OH DA. The combination of both nialamide with 5-OH DA produced better labelling than did 5-OH DA alone. Nialamide increased both the number of dcv within the axoplasm of sympathetic axons and the amount of NA available within each core, because released NA in the cytoplasm could not be metabolised by monoamine oxidases. Reuptake mechanisms are not impaired, so the number and content of the dcv increases (Bowman and Rand, 1982). Since 5-OH DA acts by displacing the transmitter from each core, an increased amount of the 5-OH DA is available within the core to produce the highly electron dense product formed following reaction with osmium tetroxide. Any 5-OH DA in the cytoplasm is also not metabolised by monoamine oxidase, and is repackaged as dcv by the same method as noradrenaline. The best identification of sympathetic axons followed fixation with chromate buffered fixative after the pharmacological treatments. 11% of Schwann cell subunits contained at least one sympathetic axon, but this was probably an underestimate since not all of the sympathetic axons in the plane of section viewed would have displayed dcv; the postganglionic axons of the sympathetic nervous system contain very low levels of NA, the majority being contained in terminal varicosities. The concentration of NA in the axon is 1/150 of that in the terminals (Geffen and Livett, 1971). Thin sections suitable for examination in the electron microscope are typically only 60nm thick, so it is highly unlikely that every sympathetic axon in the plane of section examined will contain a varicosity. A study of conduction velocities in unmyelinated fibres in the cat superficial peroneal nerve by Blumberg and Janig (1982) found that 20-30% of all unmyelinated fibres in intact skin nerves were sympathetic post-ganglionic fibres, which conducted impulses more slowly than sensory afferent fibres. McLachlan and Janig (1983) studied the cell bodies of axons projecting to the gastrocnemius, sural and superficial peroneal nerves in the cat hind limb, and estimated the relative proportions of sensory and sympathetic axons in these nerves following cell body labelling with HRP. They also found that 29% of the unmyelinated axons in the predominantly sensory superficial peroneal and sural nerves were sympathetic, and that 75% of the unmyelinated axons of the gastrocnemius nerve, which innervates skeletal muscle, were sympathetic.

In the studies undertaken in this thesis, no attempt was made to calculate the percentage of the total number of unmyelinated axons in

the sciatic nerve which were sympathetic. However if this was done on the axons identified in these studies, the figure would be much smaller than 11%. This figure was therefore a gross underestimate, and only a proportion of the sympathetic axons in the sections of normal nerve examined could be positively identified, using the criterion of 5-OH DA labelled dcv in the axoplasm. The sciatic nerve, via the tibial and common peroneal branches, innervates skeletal muscle such as the biceps femoris and adductor magnus muscles, and has a large cutaneous distribution over the leg and foot via many sensory nerves including the sural nerve. Therefore, the proportion of sympathetic fibres in this nerve would be expected to lie between 29% (cutaneous nerve) and 75% (skeletal nerve), according to the figures of McLachlan and Janig (1983). A ligation applied to the nerve 1 to 2 hours before the animal was killed would increase the number of axons which could be identified as sympathetic, due to the 'damming-up' effect on the axonal transport mechanism (Cheah and Geffen, 1973). The technique of labelling sympathetic dcv pharmacologically was very useful in the discrimination of sympathetic dcv and other dcv in tissue, such as those containing other transmitters. Further confirmation of the identification of axons as sympathetic was possible with X-Ray microanalysis, when chromium was located in NA containing dcv. The effects of chromate fixation and use of X-Ray analysis are discussed further on pages 320 & 321.

#### Noradrenaline Transport

The accumulation of NA which is seen in acute neuromas 3 to 7 days after section by fluorescence microscopy could also be seen at the ultrastructural level, as an accumulation of large and small 5-OH DA labelled dcv in unmyelinated axons. The very large numbers of dcv which accumulate in sympathetic axons as a result of nerve section are the result of a block in the proximo-distal transport of NA (Kapeller and Mayor, 1969), by the same mechanism which results in the accumulation of fluorescent material at the light microscope level. Noradrenaline in the form of dcv is known to be transported via fast axonal transport using microtubules. This has been demonstrated by experiments in which antimitotic drugs such as vincristine and vinblastine have been applied to a constricted nerve and prevented the build up of NA proximal to the constriction. These results show that disruption of the microtubules leads to a failure of axonal transport (Dahlstrom, 1968, 1970, 1971; Banks et al, 1971; Hokfelt and Dahlstrom, 1971). Mitotic inhibitors,

such as luminocolchicines, which do not depolymerize microtubules have no effect on axonal transport.

Several theories have been proposed to account for the involvement of microtubules in this type of axonal transport. Weiss (1970) proposed that materials were transported within microtubules via a convection mechanism. This theory has now been largely discounted, principally because of the amount of hydraulic pressure which would be required to move large amounts of materials down the inside of long narrow channels (Ochs, 1982). In addition this mechanism would not be available for the transport of dcv because their diameter is too large to fit inside the microtubules. Another model which has been proposed is the transport filament model (Ochs, 1971a,b). Materials are transported following binding to the transport filament. The transport filaments are then moved along the microtubules by means of the side-arms projecting from the microtubules in a manner analogous to the sliding filament theory of skeletal muscle. The movement is powered by ATP via a Ca-Mg ATPase associated with the side-arms. As yet, the transport filament has not been characterized, but a likely candidate is actin in the filamentous (F) form (Ochs, 1982). The final model is the 'rolling vesicle' model, proposed by Schmitt (1968). Materials, such as NA, are carried down the outside of the microtubules within vesicles which have specific projections on their surfaces. These projections temporarily bind to complementary sites on the microtubules, and the making/breaking of these temporary bonds causes the vesicle to roll down along the microtubules. One drawback of this model is that all materials, even large organelles such as adrenergic dcv are known to be transported at the same rate (Ochs, 1982) and it is possible that it would be expected that larger materials would be transported more slowly by this mechanism in this model.

In the present investigation large swollen axons containing very many dcv correlate with the 'pools' of fluorescent material seen in the light microscope. Many labelled axons are seen in close proximity by electron microscopy, but these cannot be resolved by light microscopy, so the fluorescent material appears to coalesce. Many fine axonal sprouts containing dcv can be seen, which also mirrors the findings at the light microscope level. The largest numbers of labelled dcv are seen in neuromas 3 days after section, and slightly smaller numbers are still present 7 days after section. Many large elongated vesicles are also seen which appear to have a dense core, although these are fewer

in number than the circular dcv.

There has been much discussion, since the advent of electron microscopy, concerning the nature of the storage site of noradrenaline in sympathetic nerves. The earliest experiments which demonstrated the presence of granular vesicles in sympathetic nerve terminals include those of Hager and Tafuri, 1959; De Robertis and Pellegrino de Iraldi, 1961; Grillo and Palay, 1962; Richardson, 1962; and Wolfe et al, 1962. As previously described (introduction p. 57) the number and size of the vesicles depends on the fixation conditions employed, but more recent studies have used an aldehyde and osmium tetroxide fixation, with or without added chromate/dichromate ions. A bimodal size distribution was identified by Pellegrino de Iraldi et al (1964), who described small granular vesicles 30-60nm in diameter and large granular vesicles, 60-100nm in diameter, the granular core representing NA storage. A third population of agranular, clear vesicles also exists in adrenergic nerve endings. These agranular vesicles are morphologically similar to those of cholinergic nerves, and were originally thought to contain acetyl choline, representing a morphological correlate of the cholinergic link in post-ganglionic sympathetic transmission, as postulated by Burn and Rand (1959). Tranzer et al (1969) and Geffen and Livett (1971) concluded that it was likely that these agranular vesicles are a form of granular vesicle, but have a very low NA content and so with most fixation conditions the granular core is not seen. However, more recent studies which utilise the optimal fixation and reaction conditions for NA visualization have concluded that these vesicles do not represent a NA storage site (Till and Banks, 1976; Richards and Da Prada, 1980; Lascar, 1980, and Ochs, 1982). The results of the present study echo this view, since the methods employed were very sensitive, but a population of agranular vesicles remained.

The small dcv are located mainly in the axons and terminal varicosities, and the large dcv in the cell body, although both sizes of vesicle are sometimes seen in both locations. It has been proposed (Lagercrantz, 1976) that the small dcv are synthesized from large dcv in the terminal parts of the axon, but this has not been definitely established. Lascar (1980) has identified a further type of dcv, which he names a 'large elongated vesicle' (LEV). Such vesicles were only seen proximal to the constriction in ligated sciatic nerves, and were in a minority compared with the large and small dcv. Lascar concludes,



from measurements of the vesicle areas and the fact that these vesicles are sometimes dumbbell shaped, that these LEV vesicles represent a variety of the large dcv. This study also supports the view that small dcv are synthesized at the nerve terminals from large dcv, in ligated sciatic nerves. Lascar also reports that dcv were never seen in myelinated axons, a statement which is in disagreement with early studies of Pellegrino di Iraldi and De Robertis (1968,1970) and also Richards and Tranzer (1975). This later study identified chromate labelled dcv in myelinated axons, but these were seen in myelinated axons in the superior cervical ganglion. No 5-OH DA labelled dcv were seen within the axons of myelinated fibres in peripheral nerves in the present study, although occasionally vesicles with a dense core were seen.

It has been proposed that the density of the dense core reflects the amount of NA stored in the vesicle (Banks et al, 1969; Mayor et al, 1971). However a more recent study (Till and Banks, 1976) disputes this view. Tetrabenazine depletes ligated peripheral nerves of their accumulated noradrenaline, but does not deplete the dense cores. Early experiments with reserpine by Jaim-Etcheverry and Ziehar (1969) showed a similar result. It was concluded that the large dcv contain material additional to NA in their vesicle matrix. About 30% of the dry weight of dcv is composed of acidic water soluble proteins called chromogranins (Bowman and Rand, 1982). The results described in this thesis tend to support the view that electron density of the dcv is related to NA content: identification of dcv as sympathetic, by means of electron density, could only be established in normal sciatic nerves if their NA content had been increased following nialamide treatment, i.e. an increased NA content was reflected in increased density following nialamide and 5-OH DA treatment. Normal nerves treated with 5-OH DA alone did not show cores which were dense enough for positive identification, i.e. did not contain enough of the false transmitter. The density of dcv in the acute neuromas also appeared to be increased, when they contained more NA than the normal nerves. Very electron-dense cores labelled with 5-OH DA were seen in both large and small dcv in the neuromas following treatment with nialamide and 5-OH DA. In addition, chromium peaks could be detected from both sizes of vesicles. The LEV of Lascar were only seen in acute neuromas, up to 7 days after section, and were best visualized following fixation of tissue by the modified chromaffin reaction. Richards (1980) reports that treatment of animals with nialamide does not result in an extraventricular chromaffin

reaction. In the results described in this thesis, there were no visually obvious signs of such a reaction, but slightly higher peaks for chromate were detected by X-Ray analysis from the axoplasm of sympathetic axons with adrenergic dcV in the axoplasm. However, no firm conclusions can be drawn from this result, since the peak heights in X-Ray analysis depend on many variables, including section thickness, and no corrections were made for these parameters.

The dcV are also known to contain ATP. Richards and Da Prada (1977) have used the uranaffin reaction to identify 5' - phosphonucleotides in large and small dcV in peripheral adrenergic neurons. This reaction is similar to the chromaffin reaction, but uranium ions are used as the stain, by means of en bloc staining of tissue with acidic 4% aqueous uranyl acetate. ATP is stored as a complex with NA in the dcV in the ratio of 1 molecule ATP : 4 molecules catecholamine (Bowman and Rand, 1982), and in addition is found in tubular endoplasmic reticulum and multi vesicular bodies (mvb), (Richards and Da Prada, 1980). These authors suggest that mvb are involved in the synthesis and breakdown of adrenergic dcV, and show that chromaffin-positive small dcV have been seen within mvb. Descarries and Droz (1968) in an autoradiographic study previously reported that mvb have the ability to accumulate [<sup>3</sup>H] NA. Although many multivesicular bodies were seen in neuromas examined in the present study, no 5-OH DA labelled dcV were seen within their limiting membranes, although such a situation was not searched for specifically.

It is concluded from the various fixation schedules and pharmacological treatments investigated in this thesis that optimal visualization of NA in dcV follows treatment with an exogenous amine (5-OH DA) and fixation by the modified chromaffin reaction. This finding agrees with those of Richards (1980).

In common with previous studies on neuromas, no tight junctions or synaptic contacts between axons of any type have been observed. However, a finding of possible relevance to the pathophysiological interaction between sympathetic efferent and sensory afferent fibres which develops in neuromas, was several examples of apparently labelled sprouts beneath the basement membrane of a myelinated fibre. The myelinated fibres showing such conformations were not uniform in size, or in a similar state of degeneration, with a tendency for some of the smaller fibres to remain intact. Often only one sympathetic sprout was

visible, but occasionally several could be identified. No direct conclusions about the relevance of such situations to the pathophysiology of neuromas can be made, but they do show that sympathetic fibre sprouts are capable of entering the basal laminae of Schwann cell tubes of other classes of fibre. Some sympathetic sprouts probably also invaded nearby Schwann cell subunits containing unlabelled axons which may have been sensory, although this must remain speculative until both sensory and sympathetic fibres can be positively identified in the same section. The percentage of Schwann cell subunits which contained 5-OH DA labelled sympathetic axons increased in acute neuromas as compared with normal nerves, from 11 to 50%. This is probably because all of the sympathetic axons in the plane of section examined contained dcv, and also because sprouting was very much in evidence at this time in common with earlier studies (Bray et al, 1972; Dyck & Hopkins, 1972 and Aguayo et al, 1973); sympathetic axon sprouts may therefore have entered Schwann cell tubes which previously contained only unlabelled axons, thereby increasing the number of labelled subunits. In addition, regenerating unmyelinated fibres have been shown to branch following injury (Aguayo et al, 1976), but this does not occur in normal nerves. Many studies (Bray et al, 1972; Dyck and Hopkins, 1972; Aguayo et al, 1973a,b) have shown that regeneration of unmyelinated fibres is well under way by 5 days following crush or nerve section. The observation that sympathetic sprouts may be seen within the basement membrane of myelinated fibres was most common in acute neuromas up to 7 days after section, possibly because sympathetic fibres are most easily identified at this time.

There are always difficulties in distinguishing between axons, axonal sprouts and processes of Schwann cell cytoplasm in transverse section. Aguayo et al (1973b) suggests that axons are best distinguished from sprouts on the basis of size. Sprouts are much smaller, and usually of more uniform size. Differentiating between axons sprouts and processes of Schwann cell cytoplasm is more problematical. Bray et al (1972) adopted the criteria of Dyck and Lambert (1969) in their study of reaction of unmyelinated fibres to injury, which were that axons usually exhibited a more pallid cytoplasm, their microtubules and neurofilaments were more prominent and a mesaxon was present. Schwann cell cytoplasm usually contains rough endoplasmic reticulum, occasional scattered microtubules and small bundles of intermediate filaments. An additional complicating factor to the identification of axonal profiles is that it is difficult

to differentiate between unmyelinated axons and the non-myelinated sprouts of myelinated fibres in acute neuromas, when myelination or remyelination is not prevalent. However, some clues are evident from the location of the sprouts or axons, and the sprouts of myelinated fibres are usually larger than unmyelinated axons.

Regeneration in the form of myelination was in evidence by 7 days after nerve section. Some of the thin myelin sheaths seen would have represented new myelination of axon sprouts, and others remyelination of demyelinated axons. The thin layers of myelin were more likely to represent myelination rather than slippage of the original myelin, because the axon had a normal organelle content, but its diameter was disproportionately large for the thickness of the myelin sheath (Ref. here to axon diameter:myelin sheath thickness ratios <sup>Williams & Wendell-Smith, 1971</sup>). If the thinness of the myelin sheath represented slippage, it would be expected that the axon would appear swollen and filled with organelles.

By two weeks following section, regeneration was very much in evidence but there were very few identifiable sympathetic axons, as in the fluorescence study. At two weeks following nerve section, many unmyelinated axons sprouts could still be seen in the neuroma. Dyck and Hopkins (1972) and Bray and Aguayo (1974) report that axonal sprouting is still very evident 2 weeks after section. The lack of sympathetic dcv seen in these neuromas in the results in this thesis therefore probably relate to the depression of NA content of individual axons, due to the reaction of the cell body to injury. The neuromatous tissue was beginning to become organized into fascicles, and this process was more advanced by 3 weeks following section. By 3 - 4 weeks regeneration of tissue around and within the original nerve fibre was advanced, and since it was likely that some sympathetic axon sprouts may have entered the basal lamina tubes of other classes of fibre, the axonal types within these fascicles were probably mixed. Many axon sprouts were closely apposed and did not have intervening Schwann cell cytoplasm in these fascicles, and it is possible that this may be a site for interactions between sympathetic and sensory fibres.

By six to eight weeks following section, the regenerating tissue was organized into the formation of the chronic neuroma, with compact collagen and perineurial cells and processes between fascicles of axons. This process has been well documented by many authors notably Spencer, 1971; Morris et al, 1972 and Lassmann and Amerrer, 1974. The

neuromatous tissue remained in this form, and in neuromas up to eight months old, there was no reorganization into normal peripheral nerve formation of this tissue. Schwann cell subunits were generally smaller than in normal nerves, this finding is in agreement with a study by Carter and Lisney (1987). In the eight week old neuromas sympathetic axons were more evident than at slightly earlier times after section, but it was not possible to say on the basis of ultrastructural evidence whether normal numbers of sympathetic axons were present. On the evidence of counts of fluorescent axons it is likely that normal numbers of sympathetic axons were present.

If the regenerating fibres eventually re-establish terminal connections, there is a loss of redundant axonal sprouts (Dyck and Hopkins, 1972; Bray and Aguayo, 1974). However, if connections are not re-established, then the number of abnormally small axons (sprouts) persists, and even 6 months after injury, the median axon diameter of the unmyelinated fibres remains low, it was also suggested that unmyelinated fibres take longer to mature than myelinated fibres (Bray and Aguayo, 1974). It is possible, therefore, that in chronic neuromas, unmyelinated axons may be sprouting for at least one year after nerve injury, and this may have implications for the pain and paraesthesiae which persist in some patients following nerve injury.

#### Chromaffin technique and X-Ray Analysis:

Identification of sympathetic axons by localization of dcv was possible following treatment with nialamide and 5-OH DA, but better localization of dcv was possible if the tissue was subsequently fixed with a chromate containing fixative, as previously described. All of these three manipulations are highly specific to monoamines.

5-OH DA will react specifically with monoamines, but will not differentiate between catecholamines and 5-HT. However, the chromaffin reaction will only identify noradrenaline, dopamine and 5-HT (Hopwood, 1971), and it is known that neither dopamine nor 5-HT are contained in the dcv of peripheral sympathetic nerves (Bowman and Rand, 1982). However, following treatment with nialamide and 5-OH DA, the principal constituent of the dcv is 5-OH DA, and this will react with chromate to form an electron-dense precipitate.

There was an added advantage to this method in that the dcv could

then be confirmed to be noradrenergic by localising the chromium by X-Ray analysis. This is the first time that localization of NA in peripheral nerve by X-Ray analysis, via chromate fixation, has been reported. Because there may be problems in positively identifying all dcv in tissue from an animal which has been treated with 5-OH DA, the use of X-Ray analysis may be a very useful tool in confirming identification. Further identification of NA in situations where NA dcv would not usually be seen, such as in sympathetic sprouts beneath the basal laminae of myelinated fibres, was especially helpful. Chromate can also be detected from both large and small dcv, showing that both sizes of vesicle act as storage sites for NA, in contrast to early studies (Intro. p 57). Dcv which do not appear to react with 5-OH DA, and from which chromate cannot be detected, are therefore probably not contained within sympathetic efferent axons but afferent fibres, and may contain a peptide neurotransmitter such as CGRP or substance P. Identification of these 'non-labelled' dcv which are in a small minority in acute neuromatous tissue would be strengthened by the application of an immunocytochemical staining procedure. This method was very sensitive and in addition to localization of NA in dcv in acute neuromas, chromium could be located in single dcv in chronic neuromas. There are possibilities for also applying this method to the detection of sympathetic axons in human neuromas obtained by biopsy, since the tissue could be dosed with 5-OH DA in vitro (Furness and Iwayama, 1972) and then immerse fixed with a chromate containing fixative. This may prove to be an important tool in the investigation of the nature of the sympathetic axon population in painful neuromas from injured peripheral nerves. Schwann cell cytoplasm also stains with chromate containing fixatives but the degree of staining varies from cell to cell. Unmyelinated axons in these different Schwann cells probably originated in different subunits further proximally in the nerve and therefore it may be possible to utilize this differential staining in a morphological investigation of the organization of unmyelinated fibres.

#### Relationship between variations in NA levels and pathophysiology

A quantitative study of ongoing activity, mechanosensitivity and adrenergic sensitivity in mouse sciatic nerve neuromas revealed an early peak of these activities 3 -4 days after section followed by a later larger peak at 14 - 21 days (Scadding, 1981). Measurement of ongoing activity alone in rat sciatic nerve neuromas showed a peak at

14 - 21 days (Govrin-Lippmann and Devor, 1978). The sampled activity was predominantly in myelinated fibres, due to technical limitations. A more recent study (Habler et al, 1987) examined C fibres, and demonstrated ongoing activity 11 - 20 months following nerve section, but quantitative data similar to that available for myelinated fibres are not yet available.

The present study showed an accumulation of NA 3 - 7 days after nerve section, and very large amounts of NA were available locally as shown by the pooling of fluorescent material at the distal tip of the neuroma and the large numbers of 5-OH DA labelled dcx seen ultrastructurally. This accumulation may be related to the early peak of adrenergic sensitivity, ongoing activity and mechanosensitivity, which occurs 3 days after nerve section. Scadding (1981) showed that activity due to mechanosensitivity could be evoked in previously silent fibres following the administration of adrenaline. Between 14 and 21 days after section, numbers of sympathetic axons are again beginning to rise, having fallen to a level below normal at 14 days. This rise was steepest at the distal tip where the majority of sprouting may have been occurring. NA was also being manufactured and transported to the distal tip of the nerve following cell body reactions. The abnormal physiological sensitivity of the neuroma which shows a peak at this time may be related to this sympathetic activity. Later following section, the afferent impulse barrage subsides, but remains present at a low level, 5% of recorded fibres being active for up to 250 days after nerve section (Govrin-Lippmann and Devor, 1978).

The results in this thesis have shown that sympathetic sprouting continues for a long period following nerve section, and 6 months after section there is a fine network of very many intermingling fluorescent sprouts in the neuromatous tissue. Devor and Govrin-Lippmann (1983) showed that blockage of axonal transport by colchicine and vinblastine applied locally to the nerve at the time of nerve section, significantly reduced the incidence of spontaneous discharge in neuromas. They suggested that this silencing of ectopic impulse generation was due to a change in the abnormal electrogenicity which would otherwise have developed. Another possible explanation of this effect is that the ectopic impulse generation activity was reduced because of a reduction in the axonal transport of noradrenaline, and so the local NA content of the neuromas was lower. This effect could only partially explain the reduction in ongoing activity, however, because

the ongoing activity which results from the application of exogenous adrenaline was also reduced, and therefore the effect of the colchicine or vinblastine was not merely one of axonal transport block of NA.

The results of the present study show that the NA content and numbers of sympathetic axons vary with time after nerve section. Although physiological experiments in animals have shown ectopic impulse generation in neuromas is enhanced by NA and adrenaline administration (Wall and Gutnick, 1974; Scadding, 1981; Korenmann and Devor, 1981) no direct observations in man which allow conclusions to be drawn about the role of endogenously released catecholamines in producing and/or maintaining ectopic impulse generation in the region of nerve damage. It has been proposed by many authors, including Lewis et al (1931) and Merrington and Nathan (1949) that the spontaneous impulse generation in sensory fibres was the basis for paraesthesiae. More recently, it has been proposed that this ectopic impulse generation is responsible for some of the pains and paraesthesiae which may follow peripheral nerve damage (Wall and Gutnick, 1974; Wall and Devor, 1978; Scadding, 1981). Behavioural experiments in mice and rats have found a positive correlation between pain related behaviour (autotomy) and the presence of an afferent impulse barrage (Wall et al, 1979b; Scadding, 1981). It has been shown that a reduction in this afferent barrage by the administration of drugs, such as guanethidine, reduces this behaviour. This finding reflects the fact that the afferent barrage is sensitive to adrenergic agonists, and so this is a direct link between pain related behaviour, the afferent barrage and the sympathetic nervous system. The beneficial effect of regional sympathetic blockade in man shows that locally released rather than circulating catecholamines must be important in producing and maintaining the pain of peripheral nerve damage in many patients. The results of this thesis show that large amounts of NA are available within the region of nerve damage, such as in neuromas, and that regenerating sympathetic axons are actively sprouting for many months after nerve section.

### Guanethidine

The efficacy of guanethidine as a pain control treatment is assumed to be related to the depletion of NA and sympathetic activity which it produces. The results of this thesis show that the sympathetic axons of damaged peripheral nerve seem to be more susceptible to these



effects than normal peripheral nerve, although the picture is not straightforward.

Normal nerves contralateral to neuromas in animals given guanethidine during the first three postoperative days showed an increased number of fluorescent sympathetic axons when compared with nerves in untreated animals. This may have been a cell body reaction, and because noradrenaline was being depleted from the nerve endings, the cell body reacted by increasing NA synthesis. The fluorescent axons appeared to have a normal morphology, which was confirmed by electron microscopy. There did not appear to be increased numbers of dcv per axon, but more axons in any given plane of section seemed to contain labelled dcv. There was some variation in the numbers of fluorescent axons in the 'normal' nerves of animals treated with guanethidine during the 3 days following nerve section, the lowest figure for the total number of NA axons being 1474, which is slightly less than the highest total from an untreated animal (1586). If the animals were dosed for three days following nerve section and then left to recover for four days prior to killing, then NA levels were towards the lower end of the normal range. There was a significant difference between NA levels in animals with neuromas left to develop for 7 days if they were dosed on days 1 - 4 or 4 - 7, and there was a wide variation in the numbers of sympathetic axons counted. Animals dosed on days 1 - 4 had significantly lower numbers of sympathetic axons when compared to normal nerves, but those dosed on days 4 - 7 were not significantly different from normal. This finding is difficult to explain in terms of the NA-depleting ability of guanethidines. There was a large variability between the counts taken from the three animals dosed on days 4 - 7, one of which had a much higher number of sympathetic axons than the other two. It is probable that larger numbers of animals have to be sampled in order to obtain representative counts because of this inter-animal variation.

It might be expected that no difference would be seen between right 'normal' nerves of animals dosed on days 1 - 3 following nerve section, contralateral to a 3 day neuroma, and animals dosed on days 4 - 7 contralateral to a 7 day neuroma, since both animals effectively were dosed for the last three days prior to killing. But the number of sympathetic axons in the right nerves contralateral to 7 day neuromas were much lower than those in 3 day neuromas. It is possible that this was a central effect resulting from the left nerve being sectioned 3

days before dosing began, although this is unlikely; only 1% of the cell bodies of the sympathetic axons in peripheral nerves lie in the contralateral sympathetic chain, and in the experiments described earlier sectioning the left nerve did not seem to affect the contralateral nerve. The difference between the two sets of figures may merely reflect the variability between counts within sets of animals, but no firm conclusions can be reached on the basis of these small samples.

The dosage regime became more important if longer term neuromas were studied. If the nerves were sectioned and neuromas allowed to develop for three weeks and the animals dosed with guanethidine on days 4 - 9 following section, then much higher levels of noradrenaline were seen in the normal right nerves than in those of animals dosed on days 17 - 21, suggesting that NA levels had recovered following cessation of guanethidine treatment. Numbers of sympathetic axons in the right nerves of rats dosed with guanethidine on days 17 - 21 were significantly lower than normal. Once guanethidine dosage has been stopped, the NA content of the sympathetic axons seems to be able to recover towards normal levels, possibly due a reflex increase in synthesis by the cell body, or possibly due to normal synthesis and transport replenishing the depleted stores once the guanethidine has been metabolised. Counts from animals dosed on days 4 - 9 were significantly higher than normal, if the M15 statistic is compared with normal nerves. This result is not easily explained, although again there was a wide variation between the two animals examined, and it is probably not prudent to make firm conclusions on the basis of the results from two such widely varying counts. The counts from both animals fell within the normal range, but one set of counts was towards the top end of this range.

The dosage schedules used in these experiments were not extensive enough to be able to produce a permanent sympathectomy or permanent damage to the reuptake mechanism. Johnson and O'Brien (1976) treated adult Sprague-Dawley rats with daily injections of guanethidine, at a dose of  $40\text{mgkg}^{-1}$ , for 5 days every week for a total of 5 weeks. Permanent destruction of sympathetic neurones in the peripheral sympathetic nervous system resulted, such that 7 months after cessation of treatment, tyrosine hydroxylase activity was only 14% of the control (untreated) levels, and only 10% of the neurones in the superior cervical ganglion remained. The adrenal medullae were largely

unaffected by even such rigorous treatment.

The picture in the neuromas was quite different, and the effects more striking, and the timing of the dosage was still important. Neuromas which were allowed to develop for three days in animals dosed with guanethidine on days 1 - 3 still showed an accumulation of NA at the distal tip of the nerve, but this was much smaller than that seen in untreated nerves. Ultrastructurally, the tissue appeared to be very similar to that of untreated 3 day old neuromas, with large collections of labelled dcv. However, some axons contained collections of dcv which were not labelled with 5-OH DA, even though they appeared to be morphologically identical to other sympathetic axons. This was probably because the guanethidine had depleted the dense core of NA, and so there was not enough present to be displaced by the 5-OH DA, and so the axon was not labelled. There was a much larger degree of depletion in 7 day neuromas of guanethidine treated animals, than in 3 day neuromas : only 20% of the expected number of sympathetic axons being counted at the distal tip in neuromas from animals dosed on days 1 - 4, and a tiny 2% of the expected number of sympathetic axons at the distal tip of animals dosed on days 4 - 7. There was still a slight accumulation of NA at the distal tip of neuromas from animals dosed on days 1 - 4, but no accumulation in those dosed on days 4 - 7, the most damaged tissue at the distal tip being most heavily depleted by the guanethidine treatment. There was a wide variation in the numbers of sympathetic axons counted in the 7 day neuromas dosed on days 4 - 7, one animal had less than 1/3rd. of the number of sympathetic axons seen in one of the other animals. A similar pattern of NA depletion was seen in the 3 week old neuromas; if the animals were dosed up to the day of killing, then there was a much larger degree of depletion of NA, and this was most evident at the distal tip of the neuroma. In 20 sections of a neuroma from an animal which was dosed on days 17 - 21 after nerve section only 3 fluorescent axons were counted in the most distal 0.5mm of tissue. In contrast to this, in animals dosed on days 4 - 9 after section, at the distal tip numbers were depleted by 1/2, but there was no depletion below the expected numbers of sympathetic axons more than 1.5mm proximally from the tip. The total number of fluorescent axons in the neuroma of one animal dosed on days 4 - 9 following nerve section was 9x that in an animal dosed on days 17 - 21. Therefore the regenerating sympathetic axons 2 - 3 weeks after nerve section are very susceptible to the effects of guanethidine.

327

This complex picture shows that sympathetic axons in normal and damaged peripheral nerve seem to have different susceptibilities to the effects of guanethidine, the more damaged tissue at the distal tip of the neuromas being more sensitive to the depleting effects of guanethidine than more normal proximal tissue. This susceptibility also depends on the degree of degeneration and regeneration going on in the tissue, i.e. the time following section. The degree of depletion caused by the drug is also influenced by the dosage regime, in particular, the time elapsed between the last dose and the killing of the animal. In addition, there was some interanimal variability in response to the drug. For example, the total numbers of axons counted in 7 day old neuromas treated on days 4- 7 varied between 208 - 492. The clinical picture of pain relief response shows a wide variability too, but it is not known whether this variability is linked to the amount of sympathetic depletion in the injured nerves of patients. Very large doses, 30mg/kg, have been used in the experiments described in this thesis. Although similar sized doses are probably used in local therapeutic blocks, 30mg being a standard dose to the occluded circulation in an upper limb, any extrapolation to the clinical situation is obviously difficult. However, the results do highlight the susceptibility of sympathetic axons in neuromas to treatment with guanethidine. It is likely that the therapeutic effect of guanethidine in pain relief is related to its ability to deplete NA in damaged tissue, thereby reducing ectopic impulse generation through adrenergic sensitivity, as discussed earlier in relation to the physiology of neuromas.

### Capsaicin

In a similar way to the manipulation of the sympathetic efferent population with guanethidine, the sensory afferent population can also be altered by treating the experimental animals neonatally with capsaicin (Jancso et al, 1977; Scadding, 1980). This treatment will remove most of the 'contaminating' effect of the unmyelinated afferent fibres and produce a 'pure' population of sympathetic efferent fibres. It was hoped that conclusions could be drawn about the abnormal relationship between sympathetic efferent and sensory afferent fibres in neuromas, following study of a pure population of sympathetic fibres. The preliminary results of this study confirm the known fact that axons are depleted by treatment with capsaicin, although these axons were not directly identifiable as afferent from this study. The

numbers of Schwann cell subunits were depleted by 1/3rd following neonatal treatment with capsaicin in both normal nerves and acute neuromas, which suggests that these subunits may have been composed entirely of afferent sensory fibres. McLachlan and Janig (1983) calculated the number of unmyelinated sensory axons and found that, numerically, they comprised the largest group of axons in the nerves studied (cat gastrocnemius, superficial peroneal and sural nerves). In the superficial peroneal and sural nerves, these axons comprised 52 and 64% of the unmyelinated axons respectively. In the gastrocnemius nerve, which innervates muscle, only 18% of the unmyelinated axons were sensory. The population in the mixed sciatic nerve would be between these two extremes, and probably comprise a large proportion of the unmyelinated axons. Therefore, if all the sensory fibres were removed by capsaicin, the numbers of Schwann cell subunits of unmyelinated fibres in the nerve would be expected to be reduced significantly, and this is the result that was seen in the experiments described in this thesis. It is not possible from the results in this study to conclude anything about the composition of the remaining Schwann cell subunits, since a quantitative analysis of the numbers of axons per subunit was not undertaken, but many very small subunits were seen, suggesting that axons were lost from the remaining subunits. If 11% of the Schwann cell subunits normally contain labelled axons and some of the non-labelled subunits are depleted by capsaicin, then the proportion of labelled subunits would be expected to increase. However, this figure of 11% is likely to have been an unreliable estimate, as discussed earlier, the true figure being much higher, since at least 30% of all unmyelinated axons are probably sympathetic. A very small but non-significant increase was seen, which is likely to be due to the fact that not all of the sympathetic axons in the plane of section contained an identifying dcv, as discussed earlier. Although the number of Schwann cell subunits was also seen to decrease in the neuromas, again there was no increase in the proportion of labelled subunits. Quantitative studies in acute neuromas are a more difficult undertaking because of the more disorganised nature of the tissue, and also due to the difficulties in identifying axons.

The structure of untreated and capsaicin treated neuromas was very similar, despite the depletion of a large number of sensory afferent axons in the treated neuromas. Very large numbers of sprouts were seen in the treated neuromas, the majority of which may have been sympathetic. Fluorescence studies showed that sympathetic axons sprout

very prolifically. If animals were treated neonatally with 6-OH DA or large doses of guanethidine to produce a permanent sympathectomy, it may be possible to determine whether the majority of sprouts in neuromas were sympathetic.

### Autoradiography Studies

It has been proposed that alpha-adrenergic receptors develop on sensory afferent fibres in neuromas, and that the adrenergic sensitivity of the afferent barrage which develops in neuromas is mediated through these receptors. Alpha receptors have not yet been demonstrated directly in neuromas, and this problem was addressed by the experiments in the present study.

The technical difficulties associated with the autoradiographic methods, both with the processing of the tissue and the subsequent quantitative analysis have been discussed in the technical discussion and will not be further described here.

In the central nervous system, good labelling of the substantia gelatinosa in the dorsal horn of the spinal cord was seen, very dense collections of silver grains being seen over this area on both the right and left sides. The changes which were seen in these areas following peripheral nerve section depended on which type of receptors was being studied.

There was generally a decrease in opiate receptor binding density in the left substantia gelatinosa following nerve section although this was not completely consistent and variations in this pattern were seen. This decrease would have been expected in the light of knowledge about the fate of primary afferent neurones following section of their peripheral axons. Jessell et al (1979) showed that there was a decrease in substance P levels of 75 - 80% following sciatic nerve section in rats. They also found a small decrease in opiate receptor binding sites, which was greatest 1 month after nerve section, and concluded that peripheral nerve injury resulted in degeneration of the primary sensory neurones which release substance P as a neurotransmitter.

Para amino clonidine labelling of alpha<sub>2</sub> adrenergic receptors in the substantia gelatinosa has been previously demonstrated, for example by Unnerstall et al, (1984). However the results described in this

thesis showed a change in receptor density following peripheral nerve section, probably with increased numbers of receptors in the dorsal horn on the side of the lesion. If this change in labelling represents the development of  $\alpha_2$  adrenergic receptors on primary afferent fibres, then a large change may have taken place. In order to see an increase in adrenergic receptor labelling when the number of neurones has probably decreased following axotomy, as shown by previous studies (Lieberman, 1971; Grafstein, 1975, and Janig and McLachlan, 1984), a change in the receptor manufacturing capacity of the tissue may have occurred.

It is more difficult to make inferences from the results of autoradiographic studies in the peripheral nerves, because of the presence of some apparently artefactual labelling in the neuromas. However, silver grain densities were always much higher in the neuromas than in normal sciatic nerves and there were some very large increases in silver grain density in the para amino clonidine experiments. If the areas of very high grain density at the distal tip of the tissue were excluded, there seemed to be a more homogeneous area of high grain density, just distal to the more patchy labelling. Anatomically, this area corresponds to the area of greatest sprouting in the tissue. The density of the silver grains falls off further proximally, where less regenerating tissue is present, and this would be expected if the adrenergic receptors in the neuromas were developing on the axolemmae of sprouting afferent fibres, as has been proposed. From the image analysis results, and qualitative appearances, it seems likely that adrenergic receptors are abnormally present in the neuromas. If this is so, it is the first time that adrenergic receptors have been demonstrated in neuromas. There was a similar pattern of labelling with the diprenorphine ligand, but the density of labelling was a great deal lower.

It was not possible to draw conclusions about the exact location of the adrenergic receptors, in particular on which classes of fibres they were being expressed, because the morphology of the tissue was poor. However, since sensory afferent fibres develop abnormal catecholamine sensitivity in neuromas, alpha adrenergic receptors are likely to be expressed on their axonal membranes.

## General Discussion and Conclusions

The experiments in this thesis have investigated changes in the sympathetic nervous system which may follow injury to a peripheral nerve. The experimental injury examined was sciatic nerve section with avulsion of the distal stump in rats. The results of these experiments have shown that the peripheral sympathetic nervous system is highly dynamic in its response to injury, and that large changes ensue following nerve section. The timing of these changes falls broadly into two categories, acute and chronic.

The acute changes, which occurred up to approximately two weeks after nerve section, were large increases in the number of sympathetic axons at the distal end of the cut nerve due to sprouting, and an accumulation of NA proximal to the section point. This accumulation was proposed by Dahlstrom and Fuxe (1964) to follow a block of axonal transport. Accumulation of NA peaked within 7 days following nerve section and then levels of NA dropped, falling to below normal 14 days following nerve section. This cessation of accumulation was probably due to the cell body reaction (Grafstein, 1975).

Chronic changes, which began approximately two weeks following section, included an increase in NA levels, such that by eight weeks after section, the numbers of sympathetic axons had nearly returned to normal. Sprouting of sympathetic axons at the distal tip of the proximal stump seemed to increase, but this was probably due to the reappearance of fluorescent noradrenaline in existing sprouts. The changes were more pronounced at the distal tip of the neuromas (0.5mm), but followed the same pattern throughout the length of nerve examined (Fig. 122). Up to six months after nerve section, sympathetic axons were still sprouting in the new growth distal to the point of section. The neuromatous tissue also became organized into mini-fascicles, taking on the appearance of a chronic neuroma.

These observations may be of relevance to the clinical situation of patients with pain from peripheral nerve damage. Richards (1967) reported that in 98% of patients with causalgia, pain began within 1 month of injury, although in most patients pain begins within 1 week; Tasker and Dostrovsky (1989) report that 80% of patients who were to develop causalgia did so within 7 days of nerve injury, and in some cases, pain is almost immediate in onset. Causalgia may be a very



### Number of fluorescent axons in neuroma vs. Time. 0.5 and 2.5mm from section point

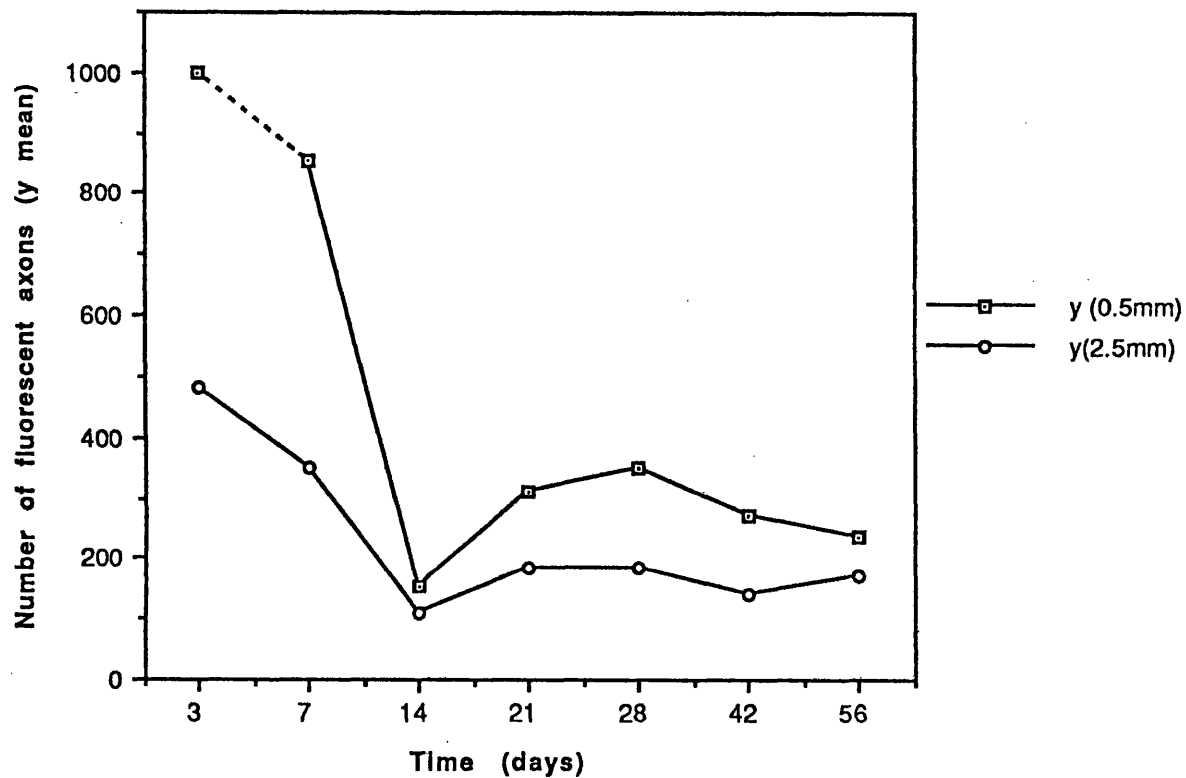


FIGURE 122 Number of fluorescent axons in neuromas vs. Time, for distances 0.5 and 2.5mm proximal to the nerve section point.

severe pain and is at least in part sympathetically maintained in many patients, as judged by the relief which may result following sympathetic block. It has been shown in the present experiments that large amounts of NA were available within the region of nerve damage between 3 and 7 days following nerve section, and that the sympathetic axons were sprouting vigorously. Although neuromas less than three days old were not examined in this thesis, it is possible that the accumulation of NA might begin almost immediately after nerve section since NA vesicles are transported axonally at the rate of  $5\text{mmhour}^{-1}$ .

In addition to the substantial clinical evidence, dating back many years, indicating an interaction in damaged peripheral nerves between sympathetic efferent and sensory afferent fibres, there are now numerous experimental physiological data which confirm the existence of such an interaction and define its characteristics (Introduction, p 31 - 34 ). There is, however, no indication that synaptic contacts develop between these two types of fibre. The long and variable latency to intravenous NA or direct sympathetic stimulation, the duration of its effect and its variability in repeated testing suggests a different kind of interaction (Devor and Janig, 1981; Korenmann and Devor, 1981, and Scadding, 1981). The anatomical substrate has previously been a matter of speculation and the investigations presented here have for the first time attempted to elucidate the problem by differentiating NA in sympathetic axons and sprouts from the sprouts of other fibre types in a mixed peripheral nerve neuroma, by labelling at the ultrastructural level. It has been shown that sympathetic axon sprouts are capable of gaining access beneath the basal laminae of other classes of fibre. It is likely that some of the regenerating units into which sympathetic efferent fibres had entered contained sensory afferent axons, although this was not directly demonstrated. Direct histochemical labelling of both afferent sensory and sympathetic efferent axons may be possible in future studies, following ultrastructural immunocytochemical localization of CGRP or substance P, present in afferent sensory axons.

In addition to the more specialized areas of close contact, where sympathetic axon sprouts had gained access within the basal laminae of other classes of fibre, there were also large amounts of NA available within the region of nerve damage. It is therefore possible that NA diffusing across the gaps between sensory and sympathetic efferent axons could be responsible for stimulating abnormally sensitive sensory

afferent fibres as proposed, on the basis of physiological studies, by Scadding (1982).

The results of the autoradiography studies in this thesis lend credence to this hypothesis; it has been shown that the substantia gelatinosa in the dorsal horn of the spinal cord expresses a higher density of adrenergic receptors on the side of a lesioned peripheral nerve, although they cannot be directly localised to afferent axons. There is evidence that receptors may be transported both peripherally and centrally from their site of synthesis. Young et al (1980) demonstrated axonal and dendritic flow of opiate receptors from the nodose ganglion, and Zarbin et al (1982) have shown that muscarinic cholinergic receptors may be transported anterogradely and retrogradely in the rat vagus nerve. Adrenergic receptors manufactured in the DRG following axotomy could be transported down the axon and inserted into the axolemmae at the sectioned ends of the afferent fibres within the neuroma. Although these receptors have not been localized to afferent fibres within the neuroma, it has been shown that there is probably a higher density of alpha adrenergic receptors within the neuroma than exists in the control normal sciatic nerve. In future research, it may be possible in ultrastructural studies to localize alpha receptors on afferent axons, using autoradiographic and immunocytochemical methods, but there are considerable technical problems. These are primarily the exposure time required for low activity ligands, the diffusion of receptors in emulsion dipped tissue sections, and the tissue artefacts introduced during preparation which may obscure cellular detail.

Studies here in chronic neuromas have shown that sympathetic efferent fibres continue to sprout for many months after nerve section, 6 months being the longest period studied. Causalgia and other types of sympathetically maintained pain may persist for many years. The clinical controversy about the importance of noradrenergic sympathetic efferent activity in pain following peripheral nerve injury continues. The considerable evidence in favour of an influence in the development and continuation of pain has been presented in the introduction. The clinical concept of sympathetically maintained pain is reasonable, although it is certainly not an exclusive idea, in that it does not imply that the sympathetic nervous system is the only factor important in the pathogenesis of pain. The concept does, however, seem to indicate the existence of the sympathetic influence in nerve injury pain in many patients. This applies to both causalgia and other types

of post-traumatic neuralgia. Perhaps the most puzzling clinical observation in relation to this phenomenon is its variability, as judged by the response to sympathetic block. Sympathetic activity is extremely important in some patients, whose pain can be almost completely relieved on occasions and of little or no importance in others with similar types of injury. While there are clearly many factors, both peripheral and central, which contribute to the development of pain after nerve injury, some of the morphological data presented here draw attention to possible explanations for the variability of the importance of sympathetic activity in pain after nerve injury.

There was a degree of variability in the responses of the sympathetic axon population of the rats to nerve section, in both the numbers of sympathetic axons present in the neuromas and also in the morphology. There was also wide variation in the response to guanethidine treatment. The results of experiments in this thesis have shown that injured sympathetic axons which are degenerating or regenerating are more sensitive to the depleting effects of guanethidine than their normal counterparts, and that the degree of NA depletion is variable between animals. These results may have implications for the mechanism of guanethidine as an analgesic: if NA present in the neuromas stimulates the pain producing afferent barrage in sensory afferent fibres, any depletion of this NA, for example by guanethidine, would be expected to result in analgesia. It has also been demonstrated here that the depletion of noradrenaline may outlast the period of guanethidine treatment, although only short term studies have been conducted in this respect. It would be of interest in future experiments to study the effects of guanethidine in older neuromas, especially with regard to the phenomenon of lasting pain relief from a single guanethidine block.

These results could in part explain the variability of pain relief with sympathetic blockade in patients with peripheral nerve injury. Noradrenaline was always depleted to some extent by guanethidine in the animals studied, but whether the NA content of neuromas is related to pain is uncertain.

Only one type of nerve injury has been studied in this thesis, nerve section with distal stump avulsion. From the results of behavioural studies (Wall and Gutnick, 1974; Wall et al, 1979a, b;

Scadding, 1981), it has been concluded that this type of injury is a suitable model for the study of pain from peripheral nerve injury. However, its suitability as a model for the various sensory disorders which accompany peripheral nerve injury has been questioned, in particular whether symptoms such as hyperalgesia and allodynia are adequately reproduced in animals following complete nerve section. Bennett and Xie (1988) have recently developed a model of nerve injury involving the tying of loose ligatures around a peripheral nerve, which seems to result in the generation of hyperalgesia, allodynia and very severe pain. This pain appears to be very acute in onset. This loose ligature model may mimic some clinical situations better than complete nerve section and may be more suitable for future research into the mechanisms of human neuropathic pain.

The techniques which have been developed in the experiments described in this thesis may be suitable for application to this new model and other types of nerve injury. More importantly, they may also be suitable for investigations into the localization of sympathetic axons in human nerve biopsies performed in the treatment of peripheral neuropathy, or the occasional therapeutic resection of nerves such as the digital plantar nerves in Morton's neuralgia, or when proximal stumps of nerves are trimmed at the time of nerve grafting or brachial plexus repair. Such investigations, together with the suggested immunocytochemical methods which have been outlined in this discussion for the localization of sensory afferent fibres, may provide further insight into the abnormal interaction which develops in injured peripheral nerves between afferent sensory and efferent sympathetic axons. It is to be hoped that this may lead to a more rational and effective approach to the treatment of the appalling chronic and intractable pain suffered by many patients with peripheral nerve injury.

## APPENDIX 1

PROCESSING SCHEDULE FOR CONVENTIONAL TRANSMISSION ELECTRON MICROSCOPY**A. Primary Fixation:**

Animals were perfused with 3% glutaraldehyde, buffered with 0.1M sodium cacodylate, via the ascending aorta. Tissue was then excised and immersed in the primary fixative for at least one hour, at 4°C, prior to dissection into pieces of a suitable size for further processing. This procedure was conducted in a fume cupboard.

Alternatively, tissue was immerse fixed in situ with the primary fixative, at 4°C, prior to excision and further processing as detailed above.

**B. Buffer Wash 1:**

The tissue was washed with two x 5 minute changes of 0.1M sodium cacodylate buffer at room temperature.

**C. Secondary Fixation:**

The tissue was immersed in 1% aqueous osmium tetroxide solution for two hours, at room temperature, with agitation. This procedure was conducted in a fume cupboard.

**D. Buffer Wash 2:**

The tissue was washed with two x 5 minute changes of 0.1M sodium cacodylate buffer, in order to remove unbound osmium tetroxide solution.

**E. Dehydration Schedule:**

All the following steps were carried out at room temperature, and the tissue was agitated continuously, up to and including step 5, to ensure maximum penetration of the reagents.

1. Two x 10 minute changes of 70% ethanol.
2. Two x 10 minute changes of 90% ethanol.
3. Four x 15 minute changes of 100% (absolute) ethanol.
4. Two x 15 minute changes of propylene oxide.

**F. Embedding Schedule:**

1. One x 30 minute change of 50:50 propylene oxide:epoxy resin.
2. Overnight immersion in 100% epoxy resin at 4°C.
3. Embedding in fresh 100% epoxy resin in silicone rubber moulds.
4. Polymerization at 60°C for 48 hours.

QUANTITATIVE ANALYSIS OF AUTORADIOGRAPHS**A. Film Counts**

The sheet of developed X-Ray film containing images of the tissue was placed on top of the stage of a dissecting microscope, and illuminated from below with transmitted light. A camera attached to the image analyser was placed above the sheet of film, and the image relayed to the monitor.

The only images which were clear enough to analyse were those of the spinal cord. The substantia gelatinosa was clearly labelled with silver grains in both the diprenorphine and para amino clonidine labelled preparations.

The analysis system used was the Sight Systems image manager. A sampling frame was selected into which the whole of one labelled substantia gelatinosa would fit. The pixel size of this frame was then fixed, and remained constant throughout all measurements on the films. The piece of film was then aligned to give the best fit into the sampling frame and the image of the spinal cord was captured by the analysis system and converted to a binary image. The field detected area covered by the silver grains was then calculated. This procedure was repeated for the other side substantia gelatinosa, and then for an area of tissue which was not labelled, across the midline just below the central canal. These three measurements were taken three times, to try and even out sampling error, and the means of the three measurements taken from the same area calculated.

**B. Slide Counts**

These counts were taken from the coverslips which were attached to the slides. A different programme was used to calculate the field detected area (fda) on these sections because the whole area to be sampled would not now fit into one frame. The slides were mounted on the stage of a microscope to which the camera was attached, with an objective lens magnification of x40. Because the magnification factor on the monitor screen was now much larger, the frame size was also increased, to cover the central area of the screen. This frame size



then remained constant for all counts carried out on the slides.

The whole substantia gelatinosa was now much too large to fit into the frame, so three counts were taken from non-overlapping samples of the central area of the most densely labelled part of the s.g. and the mean of these three counts calculated. The left, right and non substantia gelatinosa areas were measured as before.

Three central areas on the longitudinal sections of normal right sciatic nerve were selected easily, but sampling the peripheral neuromas was more problematical because the labelling was often patchy. Three samples from an area where labelling was as homogenous as possible, towards the distal<sup>al</sup> tip were chosen. The most distal part of the neuroma was often extremely heavily labelled, with probably artefactual labelling forming an outline of the tissue. An area just proximal to this very heavy labelling was therefore chosen for sampling.

The same procedure was repeated for all the pharmacological controls, i.e. tissue which had been reacted with non-tritiated ligands.

STATISTICAL METHODS

These methods were applicable to all analysis of data from the fluorescence studies, including the guanethidine experiments.

By plotting the means vs. standard deviations for each group of rats it became clear that these two variables were related (Fig. 123). In order to stabilize the variance, some sort of transformation was required, so that the variance was not dependent on the mean.

TRANSFORMATION OF DATA

1. The number of sympathetic axons ( $y$ ) counted along a particular rat nerve from 0.5 to 2.5mm when plotted against distance ( $d$ ) gave a curve. If it is assumed that a straight line fitted to this curve will have a particular slope then a series of 'residuals', the differences between the observed and expected values can be calculated. These residuals when plotted as a normal order statistics plot gave a curvilinear plot (Fig. 124).

2. If the data was transformed by a logarithmic transformation ( $\ln$ ), then the normal order statistics plot of residuals based on  $\log$ [number of axons] ( $\log y$ ) gave a straight line, i.e. the residuals were normally distributed (Fig. 125). The plot of standard deviation vs. mean was now scattered and showed no relation (Fig. 126). Thus the variance has been stabilized.

3. The  $\log$ (no. of axons) was then made the dependent variable in a regression against distance for each nerve  $i$  and distance  $j$ , such that:

$$\ln(y_{ij}) = a_i + b_i d_{ij} + e_{ij} \quad \text{where } e_{ij} \text{ is the error of prediction.}$$

From the fitted regression, two parameters were recorded for each nerve,  $i$ :  $b_i$  the slope, and  $M15_i$ , the predicted value of  $\ln(y_{ij})$  at  $d_{ij} = 1.5\text{mm}$ .

The data can therefore now be reduced to two measures for each rat nerve:

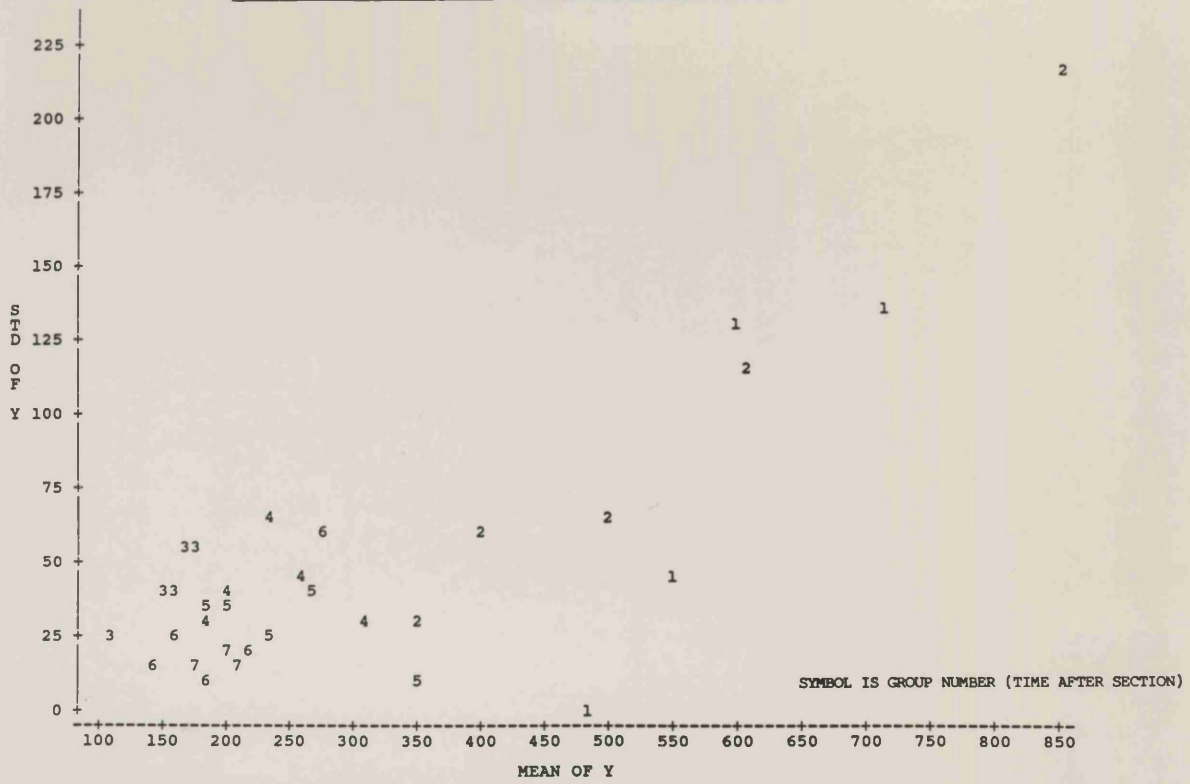
i) a slope ( $b$ )

ii) an expected value at the 1.5mm distance point ( $M15$ ) (Fig. 127)

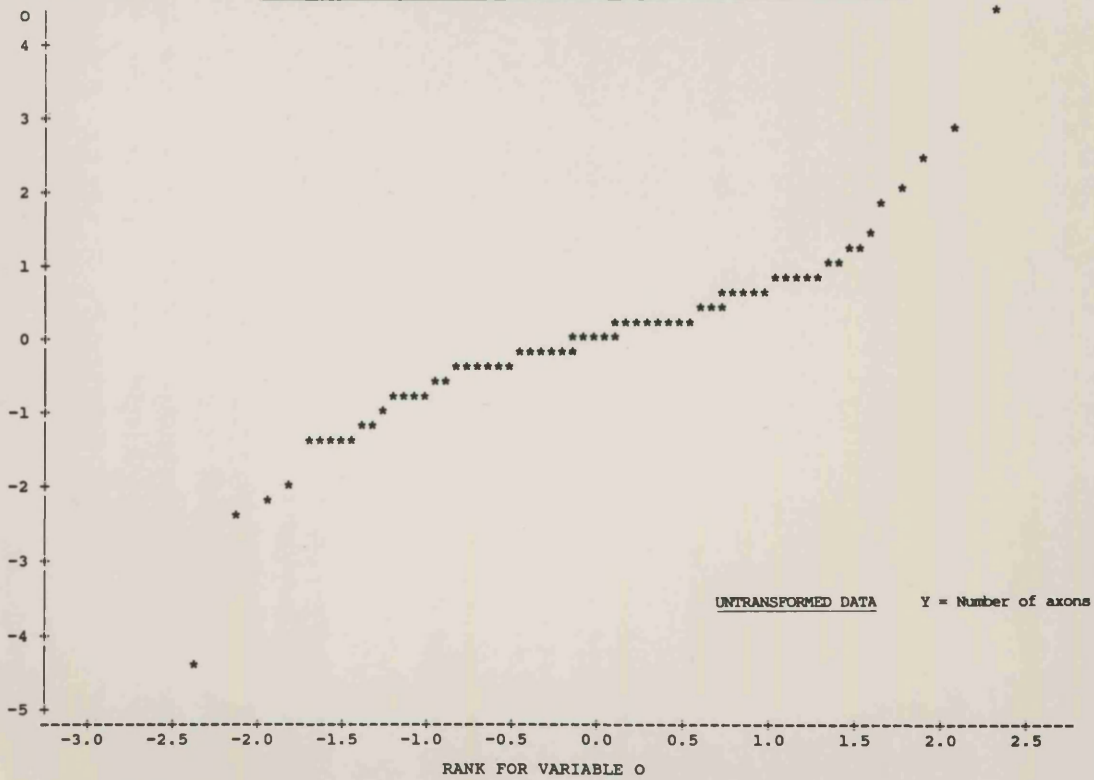
FIGURE 123 Plot of Standard Deviation vs. Mean, based on the dependent variable [number of axons, Y]. There is a relationship, such that the standard deviation is dependent on the mean.  
UNTRANSFORMED DATA.

FIGURE 124 Normal order statistics plot of residuals, observed vs expected values, calculated when straight lines are fitted to plots of [number of axons, Y] vs. distance for neuromas. A curvilinear graph results.  
UNTRANSFORMED DATA.

PLOT OF STD [NO. OF AXONS] VS. MEAN [NO. OF AXONS] FOR NEUROMAS



DEPENDENT VARIABLE Y NORMAL ORDER STATISTICS PLOT OF RESIDUALS (OBSERVED VS. EXPECTED VALUES)



544

**FIGURE 125** Normal order statistics plot of residuals, observed vs expected values, calculated when straight lines are fitted to plots of [ $\text{LOG}_n$  number of axons,  $\text{LOG}_n Y$ ] vs. distance. The normal order statistics plot is now linear, i.e. the residuals are normally distributed.

TRANSFORMED DATA.

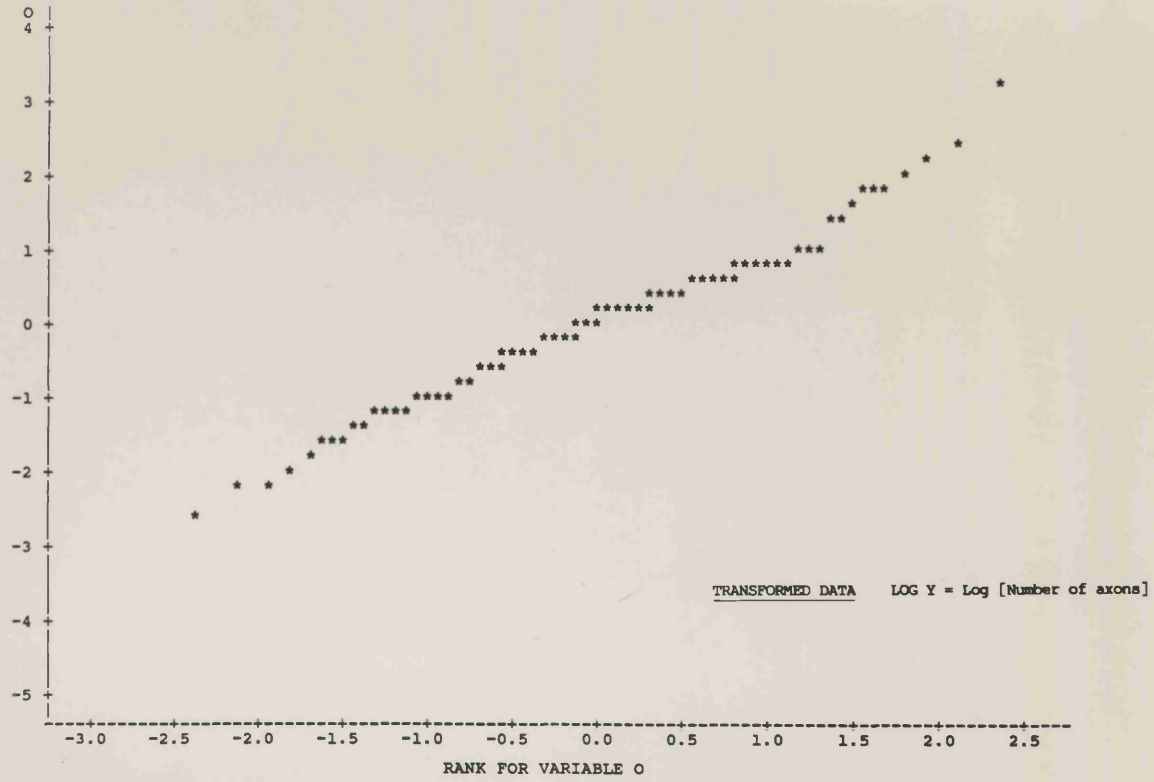
**FIGURE 126** Plot of Standard Deviation vs. Mean, based on the dependent variable [ $\text{LOG}_n$  number of axons,  $\text{LOG}_n Y$ ]. The plot is now much more scattered, and the two variables appear to be unrelated.

TRANSFORMED DATA.

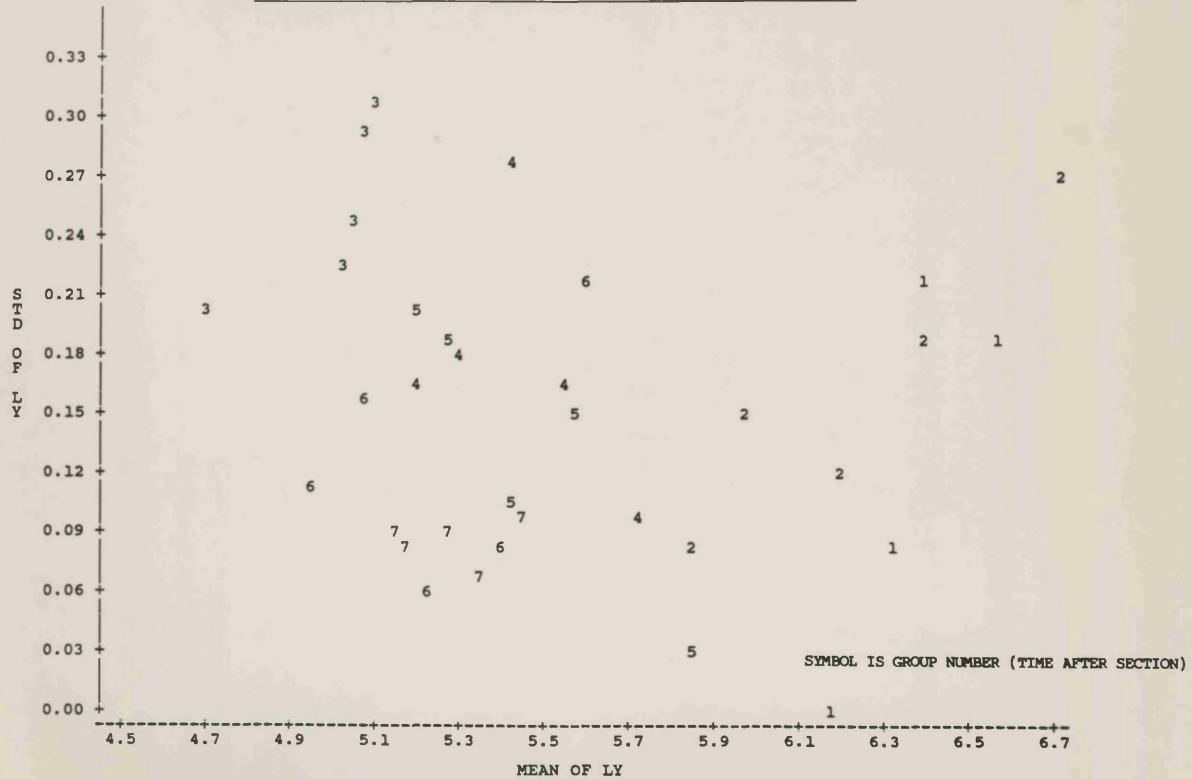
DEPENDENT VARIABLE LOG Y

PLOT OF O+E

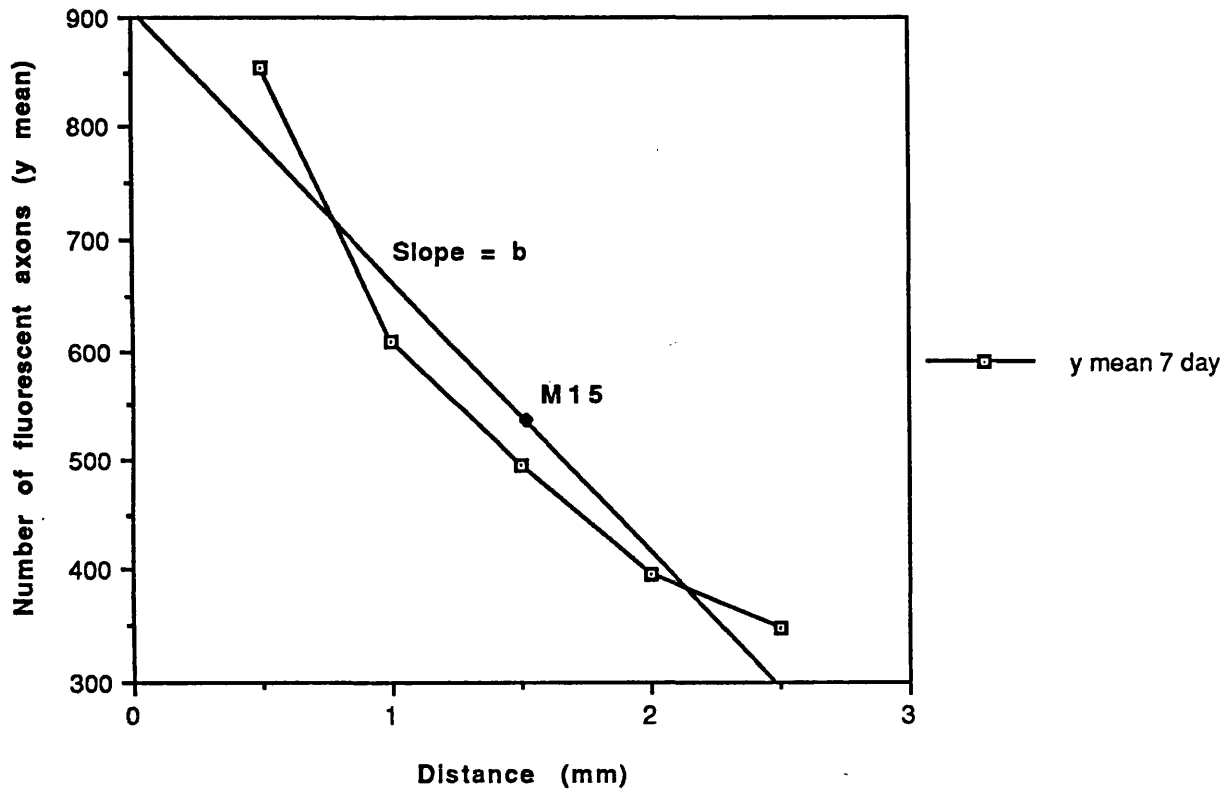
SYMBOL USED IS \*



PLOT OF STD LOG[NO. OF AXONS] VS. MEAN LOG[NO. OF AXONS] FOR NEUROMAS



**Number of fluorescent axons vs. Distance  
Illustrating estimation of  $b$  and  $M15$**



**FIGURE 127** Illustration of the calculation of the summary statistics mean slope,  $b$ , and mean midpoint,  $M15$ .

The value for the slope will give an indication of change along the length of the nerves in that group, i.e. whether the change is positive or negative (more or less sympathetic axons at the distal end) and also an indication of the rate of change of number of axons along those nerves.

The M15 measure reflects the average number of axons.

4. A series of slopes has now been obtained for each group, and the mean slope can be calculated for each group. This can now be used as the summary statistic for that group, as if it were raw data. Each slope also has a midpoint (MI5 - value related to 1.5mm point), and again the mean can be calculated and used as a summary statistic for that group.

5. An analysis of variance was undertaken, to test for differences between the groups. The variances within groups were found to be similar, and so pooled variances were calculated for the b and M15 measures (see below) and F ratios calculated.

F ratio =  $\frac{\text{variance between groups}}{\text{variance within a group}}$  and = 1, if there is no effect of 'groups'

6. The mean values for the b and M15 measures of each group were used for t-tests, in which the means of normal nerves and neuromas were compared and the confidence intervals of the differences in means assessed (Table 2). T-tests comparing guanethidine treated and normal nerves and neuromas were also carried out (Table 6).



STATISTICS USING TRANSFORMED DATA

	n	groups	d.f.	Within groups	
				variance of slopes	variance of M15
Neuromas	23	7	16	0.008926	0.025054
Normal uncut nerves	22	-	21	0.013326	0.06963
Guaneth. treated	24	10	14	0.01606	0.053127
Pooled figures			51	0.012499*	0.049698*
Pooled standard deviation			51	0.1118	0.2293

$$\text{*pooled variance} = \frac{\text{sum of [d.f. x variance]}}{\text{sum of d.f}}$$

Within group variances were all similar, showing that the variation within the groups of rats was fairly constant. These pooled variances were used in all t-tests, according to whether b or M15 was being tested, and the resulting value examined at 51 degrees of freedom.

**F RATIOS:**

Used to determine whether the between group and within group variances were similar, i.e. whether there were differences between groups.

**A. Normal uncut nerves contralateral to neuromas**

F ratio slopes            1.10  
F ratio M15                1.04

**B. Normal control nerves**

F ratio slopes            1.75  
F ratio M15                40.52

**C. Neuromas**

F ratio slopes            13.10  
F ratio M15                33.08

**D. Guanethidine treated nerves**

F ratio slopes normal nerves and neuromas    39.73  
F ratio M15    normal nerves and neuromas    30.36

Quantitative Fluorescence Study

APPENDIX TABLE 1 NORMAL UNCUT NERVES  
(contralateral to neuromas)

Distance from distal nerve tip (mm)	Number of fluorescent axons (y mean)				
	0.5	1.0	1.5	2.0	2.5
(3 day)	216	272	243	246	269
(7 day)	208	208	221	239	223
	289	319	238	227	243
(14 day)	259	294	266	254	203
	173	163	208	187	166
(21 day)	235	304	276	282	229
	161	208	201	173	156
	133	140	165	156	144
	251	263	250	248	217
(28 day)	140	138	169	130	151
	125	141	139	128	136
	180	132	137	134	144
	120	170	170	180	205
	269	336	348	323	288
	125	141	139	128	136
(42 day)	147	134	128	122	136
	129	179	187	186	205
	228	205	198	199	151
	161	230	229	189	178
(56 day)	127	195	186	176	159
	190	225	230	195	220
	139	238	292	300	274
$\bar{x}$	182	211	210	200	192
s.e.	<u>+11.48</u>	<u>+13.82</u>	<u>+11.99</u>	<u>+12.42</u>	<u>+10.33</u>

n = 22

## APPENDIX TABLE 1 (CONTD.)

NORMAL NERVES - (UNOPERATED ANIMALS)

Distance from distal nerve tip(mm)	Number of fluorescent axons (y mean)				
	0.5	1.0	1.5	2.0	2.5
172	163	174	175	178	
150	194	152	168	155	
150	166	152	154	132	
195	158	169	179	155	
225	264	268	267	250	
249	268	250	251	247	
—					
x	190	202	194	199	186
	<u>+16.59</u>	<u>+20.83</u>	<u>+20.95</u>	<u>+19.40</u>	<u>+20.59</u>

n = 6

APPENDIX TABLE 2 - NEUROMAS**1. 3 days post section**

Distance from		Number of fluorescent axons (y mean)			
distal tip (mm) 0.5		1.0	1.5	2.0	2.5
n = 2	-	621	513	523	485
	-	813	695	585	483
	-				
	x -	717	604	554	484
		<u>+96.00</u>	<u>+91.00</u>	<u>+31.00</u>	<u>+0.99</u>

**2. 7 days post section**

	0.5	1.0	1.5	2.0	2.5
n = 3	1038	739	568	466	383
	910	516	453	374	326
	616	571	466	350	337
	-				
	x 855	609	496	397	349
	<u>+124.92</u>	<u>+67.07</u>	<u>+36.36</u>	<u>+35.35</u>	<u>+17.46</u>

**3. 14 days post section**

	0.5	1.0	1.5	2.0	2.5
n = 5	95	150	109	125	109
	146	217	221	260	251
	107	133	156	132	149
	88	150	160	147	159
	121	119	158	162	189
	-				
	x 111	154	161	165	171
	<u>+10.31</u>	<u>+16.83</u>	<u>+17.80</u>	<u>+24.54</u>	<u>+23.66</u>

**4. 21 Days post section**

	0.5	1.0	1.5	2.0	2.5
n = 4	301	279	289	261	225
	317	314	294	188	189
	274	237	191	192	157
	248	215	172	172	164
	-				
	x 285	262	237	203	184
	<u>+10.31</u>	<u>+16.83</u>	<u>+17.80</u>	<u>+24.54</u>	<u>+23.66</u>

APPENDIX TABLE 2 - NEUROMAS (Contd.)**5. 28 Days post section**

	0.5	1.0	1.5	2.0	2.5
n = 3	360	303	326	226	219
	355	225	204	158	146
	338	263	250	208	183
	—				
x	351	264	260	197	183
	<u>+6.66</u>	<u>+22.52</u>	<u>+35.57</u>	<u>+20.34</u>	<u>+21.07</u>

**6. 42 Days post section**

	0.5	1.0	1.5	2.0	2.5
n = 3	214	209	187	139	135
	331	242	196	191	159
	273	210	175	157	129
	—				
x	273	220	186	162	141
	<u>+33.77</u>	<u>+10.84</u>	<u>+6.08</u>	<u>+15.25</u>	<u>+9.17</u>

**7. 56 Days post section**

	0.5	1.0	1.5	2.0	2.5
n = 3	259	225	217	166	181
	234	208	180	172	154
	213	198	198	193	178
	—				
x	235	210	198	177	171
	<u>+13.30</u>	<u>+7.88</u>	<u>+10.68</u>	<u>+8.19</u>	<u>+8.54</u>

## APPENDIX TABLE 3

## GUANETHIDINE TREATED ANIMALS

## Counts of fluorescent axons

A. 'Normal' Nerves

## 1. Contralateral to 3 Day Neuromas, Dosed days 1 - 3

Distance from distal nerve tip (mm)	Counts of fluorescent axons (y mean)				
	0.5	1.0	1.5	2.0	2.5
n = 4	359	403	395	377	324
	298	269	320	302	285
	314	342	324	344	340
	289	370	340	373	353
$\bar{x}$	315	346	345	349	326
	$\pm 15.55$	$\pm 28.54$	$\pm 17.30$	$\pm 17.31$	$\pm 14.75$

## 2. Contralateral to 7 Day Neuromas, Dosed days 1 - 4.

	0.5	1.0	1.5	2.0	2.5
n = 2	144	149	154	176	159
	121	129	133	126	118
$\bar{x}$	133	139	143	151	139
	$\pm 11.50$	$\pm 10.00$	$\pm 10.00$	$\pm 25.00$	$\pm 20.50$

## 3. Contralateral to 7 Day Neuromas, Dosed days 4 - 7.

	0.5	1.0	1.5	2.0	2.5
n = 3	220	189	215	187	218
	161	152	150	158	152
	144	152	162	157	143
$\bar{x}$	175	164	176	167	171
	$\pm 23.03$	$\pm 12.33$	$\pm 19.97$	$\pm 9.84$	$\pm 23.64$

**4. Contralateral to 21 Day Neuromas, Dosed days 4 - 9.**

	0.5	1.0	1.5	2.0	2.5
n = 2	187	246	262	229	231
	291	271	284	284	283
$\bar{x}$	239	259	273	257	257
	<u>+52.00</u>	<u>+12.50</u>	<u>+11.00</u>	<u>+27.50</u>	<u>+26.00</u>

**5. Contralateral to 21 Day Neuromas, Dosed days 17 - 21.**

	0.5	1.0	1.5	2.0	2.5
n = 2	165	177	134	142	145
	142	131	150	134	133
$\bar{x}$	153	154	142	138	139
	<u>+11.50</u>	<u>+23.00</u>	<u>+8.00</u>	<u>+4.00</u>	<u>+6.00</u>

## APPENDIX TABLE 4

## GUANETHIDINE TREATED ANIMALS (NEUROMAS)

B. Neuromas

## 1. 3 Days Dosed days 1 - 3

	0.5	1.0	1.5	2.0	2.5
n = 3	-	369	337	265	303
	-	418	324	270	250
	-	518	418	404	373
	-				
x	-	435	360	313	309
	-	<u>+43.84</u>	<u>+29.41</u>	<u>+45.52</u>	<u>+35.62</u>

## 2. 7 Days Dosed days 1 - 4

	0.5	1.0	1.5	2.0	2.5
n = 2	146	83	76	46	59
	153	110	88	80	84
	-				
x	150	97	82	63	72
	<u>+3.50</u>	<u>+13.50</u>	<u>+6.00</u>	<u>+17.00</u>	<u>+12.50</u>

## 3. 7 Days Dosed days 4 - 7

	0.5	1.0	1.5	2.0	2.5
n = 3	40	75	95	125	156
	11	38	66	114	135
	13	20	37	47	91
	-				
x	21	44	66	95	127
	<u>+9.35</u>	<u>+16.19</u>	<u>+16.74</u>	<u>+24.38</u>	<u>+19.15</u>

## 4. 21 Days Dosed days 4 - 9

	0.5	1.0	1.5	2.0	2.5
n = 2	158	178	181	198	192
	124	110	149	157	182
	-				
x	141	144	165	178	187
	<u>+17.00</u>	<u>+34.00</u>	<u>+16.00</u>	<u>+20.43</u>	<u>+5.00</u>

## 5. 21 Days Dosed days 17 - 21

	0.5	1.0	1.5	2.0	2.5
n = 1	3	11	17	36	41



## REFERENCES

- Ackerman, N.R., Rooks II, W.H., Shott, I., Genant, H., Maloney, P. and West, E. (1979) Effects of naproxen on connective tissue changes in the adjuvant arthritic rat. *Arth. Rheum.* 22: 1365 - 1374.
- Adrian, E.D. (1930) The effects of injury on mammalian nerve fibres. *Proc. Roy. Soc. B.* 106: 596-618.
- Aguayo, A.J., Bray, G.M., Terry, L.C. and Peyronnard, J.M. (1973) Analysis of single normal unmyelinated fibres and their reactions to injury. *Trans. Am. Neurol. Assoc.* 98: 70 - 72.
- Aguayo, A.J., Bray, G.M., Terry, L.C. and Swezey, E. (1976) Three dimensional analysis of unmyelinated fibres in normal and pathologic autonomic nerves. *J. Neuropath. and Exp. Neurol.* 35: 136 - 151.
- Aguayo, A.J., Peyronnard, J.M. and Bray, G.M. (1973) A quantitative ultrastructural study of regeneration from isolated proximal stumps of transected unmyelinated nerves. *J. Neuropath. and Exp. Neurol.* 32: 256 - 270.
- Ahlquist, R.P. (1948) A study of adrenotropic receptors. *Am. J. Physiol.* 153: 586-600.
- Aitken, J.T. (1949) The effect of peripheral connections on the maturation of regenerating nerve fibres. *J. Anat.* 83: 32-43.
- Ainsworth, A., Hall, P., Wall, P.D., Allt, G., Mackenzie, L.M., Gibson, S. and Polak, J.M. (1981) Effects of capsaicin applied locally to adult peripheral nerve and spinal cord. *Pain* 11: 379-388.
- Angeletti, P.U., Levi-Montalcini, R. and Caramia, F. (1971) Analysis of the effect of the antiserum to the nerve growth factor in adult mice. *Brain Res.* 27: 343-355.
- Asbury, A.K., Aldredge, H., Hershberg, R. and Fisher, G.M. (1970) Oculomotor palsy in diabetes mellitus. *Brain* 93: 555 - 556.
- Asbury, A.K. and Fields, H.L. (1984) Pain due to peripheral nerve damage: An hypothesis. *Neurology* 34: 1587-90
- Axelsson, S., Bjorklund, A., Falck, B., Lindvall, O. and Svensson, L.A. (1973) Glyoxylic acid condensation : A new fluorescence method for the demonstration of biogenic monoamines. *Acta Physiol. Scand.* 87: 57-68.
- Bagramova, M.A., Tisova, R.A. and Mantulo, P.M. (1976) Changes in the posterior root potential and excitability of primary afferent terminals on the cat spinal cord evoked by repetitive stimulation of the sympathetic trunk. *Fiziologicheskii Zhurnal I.M. Sechenova* 62: 137 - 140. In Russian. Cited in Loh and Nathan (1978).
- Ballin, R.H.M. and Thomas, P.K. (1969) Changes at the nodes of Ranvier during Wallerian degeneration: An electron microscope study. *Acta Neuropath. Berlin* 14: 237-249.
- Banks, P., Mangnall, D. and Mayor, D. (1969) The redistribution of cytochrome oxidase, noradrenaline and adenosine triphosphate in adrenergic nerves constricted at two points. *J. Physiol. (Lond.)* 200: 745-762.
- Banks, P., Mayor, D., Mitchell, M. and Tomlinson, D. (1971) Studies on the

- translocation of noradrenaline-containing vesicles in post-ganglionic sympathetic neurones in vitro: inhibition of movement by colchicine and vinblastine and evidence for the involvement of axonal microtubules. *J. Physiol.* 216: 625-639.
- Banks, P. and Mayor, D. (1972) Intra-axonal transport in noradrenergic neurones in the sympathetic nervous system. *Biochem. Soc. Symp.* 36: 133-149.
- Banks, P. and Till, R. (1975) A correlation between the effects of antimicrotubule drugs on microtubule assembly and the inhibition of axonal transport in noradrenergic axons. *J. Physiol.* 252(1): 283-294.
- Barnes, R. (1953) The role of sympathectomy in the treatment of causalgia. *J. Bone Joint Surg.* 35B: 172-180.
- Barter, R. and Pearse, A.G.E. (1953) Detection of 5-hydroxytryptamine in mammalian enterochromaffin cells. *Nature* 172: 810.
- Barter, R. and Pearse, A.G.E. (1955) Mammalian enterochromaffin cells as the source of serotonin (5-hydroxytryptamine). *J. Path. Bact.* 69: 25-31.
- Battista, A. and Cravioto, H. (1981) Neuroma formation and prevention by fascicle ligation in the rat. *Neurosurgery* 8: 191-204.
- Bean, B., Aeppli, D. and Balfour, Jr., H.H. (1983) Acyclovir in shingles. *J. Antimicrobiol. Chemother.* 12: 123 - 127.
- Behse, F., Buchtal, F. and Carlsen, F. (1977) Nerve biopsy and conduction studies in diabetic neuropathy. *J. Neurol. Neurosurg. Psychiat.* 40: 1072.
- Bennett, G.J. and Xie, Y.K. (1988) A peripheral mononeuropathy in the rat that produces disorders of pain sensation like those seen in man. *Pain* 33: 87-107.
- Bernstein, J.J. and Pagnanelli, D. (1982) Long term axonal apposition in rat sciatic nerve neuroma. *J. Neurosurg.* 57: 682-684.
- Betcher, A.M., Bean, G. and Casten, D.F. (1953) Continuous procaine block of paravertebral sympathetic ganglions. *J. Am. Med. Ass.* 151: 288-292.
- Bjorklund, A. (1983) Fluorescence histochemistry of biogenic monoamines. Chapter II in: *Handbook of chemical neuroanatomy. Vol. 1: Methods in chemical neuroanatomy.* Bjorklund, A. and Hokfelt, T. (Eds.) Elsevier, Amsterdam. pp 50 - 121.
- Bloom, F.E. and Barnett, R.J. (1966) Fine structural localization of noradrenaline in vesicles of autonomic nerve endings. *Nature* 210: 599 - 601.
- Blinzinger, K. and Kreutzberg, G.W. (1968) Displacement of synaptic terminals from regenerating motoneurons by microglial cells. *Z. Zellforsch. Mikrosk. Anat.* 85: 145 - 157.
- Blumberg, H. and Janig, W. (1981) Changes in unmyelinated fibres including postganglionic fibres of a skin nerve after peripheral neuroma formation. *J. Auton. Nerv. Syst.* 6: 173-183.
- Blumberg, H. and Janig, W. (1982) Activation of fibres via experimentally produced stump neuromas in skin nerves: ephaptic transmission or retrograde sprouting? *Exp. Neurol.* 76: 468-482.
- Blumberg, H. and Janig, W. (1984) Discharge patterns of afferent fibres in a

neuroma. Pain 20: 335-353.

- Blumcke, S. and Niedorf, H.R. (1965) Elektronen mikroskopische Untersuchungen an wachstumsendkolben regenerierenden peripheren nervenfaseren. Virchows Arch. Path.Anat. 340: 93-104. Cited in Morris et al (1972).
- Blumcke, S., Niedorf, H.R. and Rode, J. (1966) Axoplasmic alterations in the proximal and distal stumps of transected nerves. Acta Neuropath. (Berlin) 7: 44-61.
- Bonelli, S., Conoscente, F., Movilia, P.G., Restelli, L., Francucci, B. and Grossi, E. (1983) Regional intravenous guanethidine vs. stellate ganglion block in reflex sympathetic dystrophies; a randomized trial. Pain 16: 297 - 307.
- Bonica, J. J. (1979) In 'Advances in Pain Research and Therapy', Vol. 3. Bonica, J. J., Liebeskind, J.C. and Albe-Fessard, D.G. (Eds.) Raven Press, New York.
- Bowman, W.C. and Rand, M.J. (1982) Textbook of Pharmacology, 2nd Edition. Blackwell Scientific Publications, Oxford.
- Boyle, F.C. and Gillespie, J.S. (1968) The relationship between the accumulation of noradrenaline and the development of fluorescence above a constriction in cat splenic nerves. J. Physiol. (Lond.) 195: 27P-28P.
- Boyle, F.C. and Gillespie, J.S. (1970) Accumulation and loss of noradrenaline central to a constriction on adrenergic nerves. Europ. J. Pharmacol. 12: 77-84.
- Bray, D. (1973) Model for membrane movements in the neural growth cone. Nature 244: 93-95.
- Bray, D. (1979). Mechanical tension produced by nerve cells in tissue culture. J. Cell Sci. 37: 391-410.
- Bray, G.M. and Aguayo, A.J. (1974) Regeneration of peripheral unmyelinated nerves. Fate of axonal sprouts which develop after injury. J. Anat. 117: 517 - 529.
- Bray, G.M., Perkins, S. and Aguayo, A.J. (1977) Interaxonal connections in peripheral nerves of normal newborn rats. Neurosci. Abstr. 3: 101.
- Bray, G.M., Peyronnard, J.M. and Aguayo, A.J. (1972) Reactions of unmyelinated nerve fibres to injury. An ultrastructural study. Brain Res. 42: 297-309.
- Browder, J. and Gallagher, J.P. (1948) Dorsal cordotomy for painful phantom limbs. Annals of Surgery 128: 456 - 469.
- Brown, M.J., Martin, J.R. and Asbury, A.K. (1978) Painful diabetic neuropathy: A morphometric study. Archives of Neurology 33: 164.
- Buck, S.H., Miller, M.S. and Burks, T.F. (1982) Depletion of primary afferent substance P by capsaicin and dihydrocapsaicin without altered thermal sensitivity. Brain Res. 233: 216-220.
- Bunge, M.B. (1973) Fine structure of nerve fibres and growth cones of isolated sympathetic neurons in culture. J. Cell Biol. 56: 713-735.
- Bunge, M.B., Johnson, M.I. and Argiro, V.J. (1982) Certain aspects of growth

cone biology and influences of neuronal age on nerve fibre growth. In: Spinal Cord Reconstruction. Kao, C., Bunge, R. and Reier, P. (Eds.) Raven Press, New York.

- Burchiel, K.J. (1984) Effects of electrical and mechanical stimulation on two foci of spontaneous activity which develop in primary afferent neurons after peripheral axotomy. *Pain* 18: 249 - 265.
- Burgess, P.R. and Perl, E.R. (1973) Cutaneous mechanoreceptors and nociceptors. In: *Handbook of Sensory Physiology*, vol. 2. Somatosensory system. A. Iggo (Ed.) Springer-Verlag. Berlin. pp 29-789.
- Burn, J.H. and Rand, M.J. (1959) Sympathetic postganglionic mechanism. *Nature (Lond.)* 184: 163-165.
- Burnstock, G. and Costa, M. (1975) Adrenergic neurons. Chapman and Hall, London.
- Cajal, S.R.Y. (1928) *Degeneration and Regeneration in the Nervous System*. Oxford University Press. London.
- Cajal, S.R.Y. (1937) *Recollections of my life*. Translated by Craigie, E.H., with Cano, J. American Philosophical Society. Philadelphia.
- Calissano, P., Monaco, G., Castellani, L., Mercanti, D. and Levi, A. (1978) Nerve growth factor potentiates actomyosin adenosinetriphosphatase. *Proc. Natl. Acad. Sci. USA* 75: 2210 - 2214.
- Calvin, W.H. (1979) Some design features of axons and how neuralgias may defeat them. In 'Advances in Pain Research and Therapy'. Vol. 3. Bonica J. J., Liebeskind, J.C. and Albe-Fessard, D.G. (Eds.) Raven Press, New York. pp 297-310.
- Cambridge, D., Davey, M.J. and Massingham, R. (1977) Prazosin, a selective antagonist of post-synaptic alpha-adrenoreceptors. *Br. J. Pharmacol.* 59: 514P.
- Carlen, P.L., Wall, P.D., Nadvorna, H. and Steinbach, T. (1978) Phantom limbs and related phenomena in recent traumatic amputations. *Neurology* 28: 211-217.
- Carter, D.A. and Lisney, S.J.W. (1987) The numbers of unmyelinated and myelinated axons in normal and regenerated rat saphenous nerves. *J. Neurol. Sci.* 80: 163-171.
- Cervero, F. and McRitchie, H.A. (1981) Neonatal capsaicin and thermal nociception - a paradox. *Brain Res.* 215: 414-418.
- Cheah, T.B. and Geffen, L.B. (1973) Effects of axonal injury on noradrenaline, tyrosine hydroxylase and monoamine oxidase levels in sympathetic ganglia. *J. Neurobiol.* 4: 443-452.
- Chudler, E.H. and Dong, W.K. (1983) Neuroma pain model: correlation of motor behaviour and body weight with autotomy in rats. *Pain* 17: 341-351.
- Coderre, T.J., Grimes, R.W. and Melzack, R. (1986a) Autotomy following sciatic and saphenous nerve section, sparing of the medial toes after treatment of the sciatic nerve with capsaicin. *Exp. Neurol.* 91(2): 355-365.
- Coderre, T.J., Grimes, R.W. and Melzack, R. (1986b) Deafferentation and chronic pain in animals: an evaluation suggesting autotomy is related to

pain. Pain 26: 61-84.

- Colpaert, F.C., Donnerer, J. and Lembeck, F. (1983). Effects of capsaicin on inflammation and on the substance P content of nervous tissues in rats with adjuvant arthritis. *Life Sci.* 32 (16): 1827-34.
- Corrodi, H. and Hillarp, N.A. (1963) Fluoreszenz methoden zur histochemischen sichtbarmachung von Monoaminen. 1. Identifizierung der fluoreszierenden Produkte aus Modellversuchen mit 6,7 - Dimethoxyisochinolin-derivten und Formaldehyd. *Helv. Chim. Acta.* 46: 2425-2430. Cited in Bjorklund (1983).
- Corrodi, H. and Hillarp, N.A. (1964) Fluoreszenz methoden zur histochemischen sichtbarmachung von Monoaminen. 2. Identifizierung der fluoreszierenden Produktes aus Dopamin and Formaldehyd. *Helv. Chim. Acta.* 47: 911-918. Cited in Bjorklund (1983).
- Corrodi, H., Hillarp, N.A. and Jonsson, G. (1964) Fluorescence methods for the histochemical demonstration of monoamines. 3. Sodium borohydride reduction of the fluorescent compounds as a specificity test. *J. Histochem. Cytochem.* 12: 582-586.
- Corrodi, H. and Jonsson, G. (1967) The formaldehyde fluorescence method for the histochemical demonstration of biogenic monoamines. A review on the methodology. *J. Histochem. Cytochem.* 15: 65-78.
- Coupland, R.E. and Hopwood, D. (1966) The mechanism of the differential staining reaction for adrenaline and noradrenaline storing granules in tissue fixed in glutaraldehyde. *J.Anat.* 100: 227-243.
- Csillick, B., and Knyihar, E. (1978) Biodynamic plasticity in the Rolando substance. *Progress in Neurobiology*, 10: 203.
- Dahlstrom, A. (1965) Observations on the accumulation of noradrenaline in the proximal/distal parts of peripheral adrenergic nerves after compression. *J.Anat.* 99: 677-689.
- Dahlstrom, A. (1967a) The transport of noradrenaline between two simultaneously performed ligations of the sciatic nerves of the cat and rat. *Acta Physiol. Scand.* 69: 158-166.
- Dahlstrom, A. (1967b) The effect of Reserpine and Tetrabenazine on the accumulation of noradrenaline in the rat sciatic nerve after ligation. *Acta Physiol. Scand.* 69: 167-179.
- Dahlstrom, A. (1968) Effect of colchicine on transport of amine storage granules in sympathetic nerves of rat. *Eur. J. Pharmacol.* 5: 111-113.
- Dahlstrom, A. (1970) The effects of drugs on axonal transport of amine storage granules. In: *New Aspects of storage and release mechanisms of catecholamines.* Bayer Symposium, II: 20-36. Springer-Verlag. Berlin.
- Dahlstrom, A. (1971) Effects of vinblastine and colchicine on monoamine containing neurones of the rat, with special regard to the axoplasmic transport of amine granules. *Acta Neuropathol. Suppl.* V: 226-237.
- Dahlstrom, A. and Fuxe, K. (1964) A method for the demonstration of adrenergic nerve fibres in peripheral nerves. *Zeitschrift fur Zellforschung* 62: 602-607.
- Dahlstrom, A. and Haggendal, J. (1966) Studies on the transport and lifespan of amine storage granules in a peripheral adrenergic neurone system. *Acta Physiol. Scand.* 67: 278-288.

- Dahlstrom, A. and Haggendal, J. (1970). Axonal transport of amine storage granules in sympathetic adrenergic axons. In Costa, E. and Giacobini, E. (Eds). *Biochemistry of Simple Neuronal Models*. Adv. Biochem. Psychopharmacol. Vol. 2: 65-93. Raven Press, New York.
- Dahlstrom, A., Heiwall, P.O., Haggendal, J. and Saunders, N.R. (1975) Effects of antimitotic drugs on the intra-axonal transport of neurotransmitters in rat adrenergic and cholinergic nerves. *Ann. N.Y. Acad. Sci.* 53: 507 - 515.
- Dahlstrom, A., Jonasson, J. and Norberg, K.A. (1969) Monoamine oxidase activity in rat sciatic nerves following constriction. *Europ. J. Pharmacol.* 6: 248-254.
- De La Torre, J.C. and Surgeon, J.W. (1976) A methodological approach to rapid and sensitive monoamine histofluorescence using a modified glyoxylic acid technique: the SPG method. *Histochemistry* 49: 81-93.
- Denmark, A. (1813) An example of symptoms resembling Tic Douleureux produced by a wound in the radial nerve. *Med. Chir. Trans.* 4: 48-52.
- Denny-Brown, D. (1946) Importance of neural fibroblasts in the regeneration of nerves. *Arch. Neurol. Psychiat.* 55: 171-215.
- DeRobertis, E.D.P.(1964) *Histophysiology of synapses and neurosecretion*. Pergamon Press, Oxford.
- De Robertis, E.D.P. and Pellegrino de Iraldi, A. (1961) A plurivesicular component in adrenergic nerve endings. *Anat.Rec.* 139: 299.
- De Santis, M. and Duckworth, J.W. (1982) Properties of primary afferent neurons from muscles which are spontaneously active after a lesion of their peripheral processes. *Exp. Neurol.* 75: 261 - 274.
- Descarries, L. and Droz, B. (1968) Incorporation de noradrenaline 3H (NA) dans le systeme nerveux central du rat adulte: Etude radio-autographique en microscopie electronique. *C.R. Acad.Sci.Paris*, 266: 2480-2482. Cited in Lascar (1980).
- Devor, M. (1984) The pathophysiology of damaged peripheral nerves. In : *Textbook of Pain*. Wall, P.D. and Melzack, R. (Eds.) First Edition. Churchill Livingstone, Edinburgh. pp. 49 - 64.
- Devor, M. (1989) The pathophysiology of damaged peripheral nerves. Chapter 3. In: *Textbook of Pain*. Wall, P.D. and Melzack R. (Eds). Churchill Livingstone, Edinburgh. pp. 63 - 81.
- Devor, M. and Bernstein, J.J. (1982) Abnormal impulse generation in neuromas : electrophysiology and ultrastructure. In: *Abnormal Nerves and Muscles as Impulse Generators*. Culp, W.J. and Ochoa, J. (Eds.) Oxford University Press, Oxford. pp. 363 - 382.
- Devor, M. and Claman, D. (1980) Mapping and plasticity of acid phosphatase afferents in the rat dorsal horn. *Brain Res.* 190: 17-28.
- Devor, M. and Govrin-Lippmann, R. (1983) Axoplasmic transport block reduces ectopic impulse generation in injured peripheral nerves. *Pain* 16: 73-85.
- Devor, M. and Govrin-Lippmann, R. (1985) Spontaneous neural discharge in neuroma C-fibres in rat sciatic nerve. *Neurosci. Lett.* (suppl.) 22: 532

- Devor, M. and Janig, W. (1981) Activity of myelinated afferents ending in a neuroma by stimulation of the sympathetic supply in the rat. *Neurosci. Lett.* 24: 43-47.
- Devor, M. and Raber, P. (1983) Autotomy after nerve injury and its relation to spontaneous discharge originating in nerve and neuromas. *Behav. Neurol. Biol.* 37: 276-283.
- Devor, M. and Wall, P.D. (1981) Plasticity in the spinal cord sensory map following peripheral nerve injury in rats. *J. Neurosci.* 1: 679-684. Devor, M. and Wall, P.D. (1978) Reorganizing of the spinal cord sensory map after peripheral nerve injury. *Nature* 276: 75-76.
- Diamond, J. (1959) The effects of injecting acetyl choline into normal and regenerating nerves. *J. Physiol. (Lond.)* 65:611.
- Doupe, J., Cullen, C.H. and Chance, G.O. (1944) Post-traumatic pain and the causalgic syndrome. *J. Neurol. Psych.* 7: 33-48.
- Dreyfus, P.M., Hakims, S. and Adams, R.D. (1957) Diabetic Ophthalmoplegia. *Arch. Neurol. Psych.* 77: 337 - 49.
- Driessen, J.J., Van der Werken, C., Nicolai, J.P.A. and Crul, J.F. (1983) Clinical effects of regional intravenous guanethidine (Ismelin R) in reflex sympathetic dystrophy. *Acta Anaesthesiologica Scandinavia* 27: 505 - 509.
- Droz, B. (1967) Synthèse et transfert des protéines cellulaires dans les neurones ganglionnaires: étude radioautographique quantitative en microscopie électronique. *J. Micr.* 6: 210 - 228. Cited in Dahlstrom (1970).
- Dyck, P.J. and Lambert, E.H. (1969) Dissociated sensation in amyloidosis. *Arch. Neurol. (Chic.)* 20: 490-507.
- Dyck, P.J., Conn, D.L. and Okazaki, H. (1972) Necrotizing angiopathic neuropathy: three dimensional morphology of fibre degeneration related to sites of occluded vessels. *Mayo Clinic Proceedings* 47: 461.
- Dyck, P.J. and Hopkins, A.P. (1972) Electron microscope observations on degeneration and regeneration of unmyelinated fibres. *Brain* 95: 223-234.
- Dyck, P.J., Lambert, E.N. and O'Brien, P.C. (1976) Pain in peripheral neuropathy related to rate and kind of fibre degeneration. *Neurology (Minneapolis)* 26: 466-471.
- Eames, R.A. and Lange, L.S. (1967) Clinical and pathological study of ischaemic neuropathy. *J. Neurol. Neurosurg. Psychiat.* 30: 215 - 226.
- Edstrom, J.D., Eichner, D. and Edstrom, A. (1962) The ribonucleic acid of axons and myelin sheaths from Mauthner neurons. *Biochim. Biophys. Acta (Amst.)* 61: 178-184.
- Edwall, L. and Scott, D. (1971) Influence of changes in microcirculation on the excitability of the sensory unit in the tooth of the cat. *Acta Physiol. Scand.* 82: 555 - 566.
- Engkvist, O., Wahren, L.K., Wallin, G., Torebjork, E. and Nystrom, B. (1985) Effects of regional intravenous guanethidine block in post-traumatic cold intolerance in hand amputees. *J. Hand Surgery* 10: 145-150.
- Eranko, O. (1952) On the histochemistry of the adrenal medulla of the rat, with special reference to acid phosphate. *Acta Anat.* 16: Suppl. 17.

- Eranko, O. and Harkonen, M. (1965) Effect of axon division on the distribution of noradrenaline and acetylcholinesterase in sympathetic neurons of the rat. *Acta Physiol. Scand.* 63: 411-412.
- Eros, G. (1932) Eine neue Darstellungsmethode der sogenannten 'gelben' argentaffinen Zellen des Magendarmtraktes. *Zentralb. Allg. Path. Path. Anat.* 54: 385-391. Cited in Bjorklund (1983).
- Euler, U.S. von (1959) Autonomic neuroeffector transmission. In: *Handbook of Physiology. Neurophysiology.* Washington, D.C. Am. Physiol. Soc. 1959, Sect. 1. vol.1: 215.
- Euler, U.S. von. (1961) Neurotransmission in the adrenergic nervous system. *Harvey Lecture Series* 55: 43-65.
- Evans, C.A.N. and Saunders, N.R. (1974) An outflow of acetylcholine from normal and regenerating ventral roots of the cat. *J.Physiol.* 240: 15-32.
- Evans, D.H.L. and Murray, J.G. (1954) Regeneration of non-medullated nerve fibres. *J.Anat.* 88: 465 - 480.
- Falck, G., Hillarp, N.A., Thieme, G. and Torp, A. (1962) Fluorescence of catecholamines and related compounds condensed with formaldehyde. *J. Histochem. Cytochem.* 10: 348-354.
- Fields, H.L. (1987) Chapter 6. Painful Dysfunction of the Nervous System. *Pain.* McGraw-Hill, New York. pp. 133 - 169.
- Finch, D.R.A., Macdougall, M., Tibbs, D.J. and Morris, P.J. (1980) Amputation for vascular disease : the experiences of a peripheral vascular unit. *Br. J. Surg.* 67: 233 - 237.
- Fitzgerald, M. (1983) Capsaicin and sensory neurones - a review. *Pain* 15: 109-130.
- Foerster, O., Altenburger, H. and Kroll, F.W. (1929) *Ztsch. f.d.ges. Neurol. u. Psychiat.* 121: 134. Cited in Nathan (1947).
- Friede, R.I. and Bischausen, R. (1980) The fine structure of stumps of transected nerve fibres in subserial sections. *J. Neurol. Sci.* 44: 181-203.
- Friede, R.I. and Martinez, A.J. (1970) Analysis of the process of sheath expansion in swollen nerve fibres. *Brain Res.* 19: 165-182.
- Furness, J.B., Heath, J.R. and Costa, M. (1978) Aqueous aldehyde (FAGLU) methods for the fluorescence histochemical localisation of catecholamines and for ultrastructural studies of central nervous system tissue. *Histochem.* 57: 285-295.
- Furness, J.B. and Iwayama, T. (1972) The arrangement and identification of axons innervating the vas deferens of the guinea pig ileum. *J.Anat.* 113: 179 - 196.
- Gamse, R. (1982) Nociception in mice and rats after capsaicin treatment. *Neuroscience* 7: 576.
- Gamse, R., Holzer, P. and Lembeck, F. (1980) Decrease of substance P in primary afferent neurons and impairment of neurogenic plasma extravasation by capsaicin. *Br. J. Pharmacol.* 68: 207-213.
- Gamse, R., Lackner, D., Gamse, G. and Leeman, S.E. (1981) Effect of capsaicin pretreatment on capsaicin-evoked release of immunoreactive



somatostatin and substance P from primary sensory neurons. *N.S. Arch. Pharmacol.* 316: 38-41.

- Gamse, R., Molnar, A. and Lembeck, F. (1979) Substance P release from spinal cord slices by capsaicin. *Life Sci.* 25: 629-636.
- Gasser, H.S. (1935) The changes produced in the injury discharge of nerve fibres during the period following the propagated disturbance. *J. Physiol.* 85: 15P.
- Geffen, L.B. and Livett, B.G. (1971) Synaptic vesicles in sympathetic neurons. *Physiol. Rev.* 51: 98-157.
- Geffen, L.B. and Ostberg, A. (1969) Distribution of granular vesicles in normal and constricted sympathetic neurones. *J. Physiol.* 204: 583-592.
- Geffen, L.B. and Rush, R.A. (1968) Transport of noradrenaline in sympathetic nerves and the effect of nerve impulses on its contribution to transmitter stores. *J. Neurochem.* 15: 925-930.
- Gilliatt, R.W. and Wilson T.G. (1954) Ischaemic sensory loss in patients with peripheral nerve lesions. *J. Neurol. Neurosurg. Psychiat.* 17 : 104 - 123.
- Govrin-Lippmann, R. and Devor, M. (1978) Ongoing activity in severed nerves: source and variation with time. *Brain Res.* 159: 406-410.
- Grafstein, B. (1971) Role of slow and axonal transport in nerve regeneration. *Acta Neuropathol. Suppl.* V: 144-152.
- Grafstein, B. (1975) The nerve cell body response to axotomy. *Exp. Neurol.* 48: 32-51.
- Grafstein, B. and Murray, M. (1969) Transport of protein in goldfish optic nerve during regeneration. *Exp. Neurol.* 25: 494-508.
- Granit, R., Leksell, L. and Skoglund, C.R. (1944) Fibre interaction in injured or compressed region of nerve. *Brain* 67: 125 - 140.
- Granit, R. and Skoglund, C.R. (1945) Facilitation, inhibition and depression at the 'artificial' synapse formed by the cut end of a mammalian nerve. *J. Physiol.* 103 : 435 - 448.
- Grant, G. and Arvidsson, J. (1975) Transganglionic degeneration in trigeminal primary sensory neurones. *Brain Res.* 95: 265-279.
- Griffith, A. and Lavelle, A. (1971) Developmental protein changes in normal and chromatolytic facial nerve nuclear regions. *Exp. Neurol.* 33: 360-371.
- Grillo, M.A. and Palay, S.L. (1962) In: Breese, S.S. (Ed). Granule-containing vesicles in the Autonomic Nervous System. Fifth International Congress Electron Microscopy, Philadelphia. Academic Press, New York.
- Gutmann, E. and Sanders, F.K. (1943) Recovery of fibre numbers and diameters in the regeneration of peripheral nerves. *J. Physiol.* 101: 489-518.
- Habler, H.J., Janig, W. and Koltzenburg, M. (1987) Activation of unmyelinated afferents in chronically lesioned nerves by adrenaline and excitation of sympathetic efferents in the cat. *Neurosci. Lett.* 82: 35-40.
- Hager, H. and Tafuri, W.L. (1959) *Naturwissenschaften* 46: 332. Cited in Kapeller and Mayor (1967).

---

Heumann, R., Lindholm, D., Bandtlow, C., Meyer, M., Radeke, M.J., Misko, T.P., Shooter, E. and Thoenen, H. (1987). Differential regulation of mRNA encoding nerve growth factor and its receptor in rat sciatic nerve during development, degeneration and regeneration: Role of macrophages. Proc. Natl. Acad. Sci. USA 84: 8735 - 39.

- Haggendal, J. Dahlstrom, A., Bareggi, S. and Larsson, P.A. (1974) Importance of axoplasmic transport for transmitter levels in nerve terminals. In: Dynamics of degeneration and growth in neurons. K. Fuxe, L. Olson, and Y. Zotterman (Eds.) Wenner-Gren Symposium, Pergamon Press Ltd. Oxford.
- Hannington-Kiff, J.G. (1974) Intravenous regional block with guanethidine. *Lancet* 1: 1019-1020.
- Hannington-Kiff, J.G. (1979) Relief of causalgia in limbs by regional intravenous guanethidine. *B.M.J.* 2:367-368.
- Hannington-Kiff, J.G. (1982) Hyperadrenergic-effected limb causalgia: relief by i.v. pharmacologic norepinephrine blockade. *Am. Heart Journal* 103: 152-153.
- Hannington-Kiff, J.G. (1984) Antisymphathetic drugs in limbs. In: Textbook of Pain. P.D. Wall and R. Melzack (Eds). Churchill Livingstone, Edinburgh. pp. 566-573.
- Harkonen, M. (1964) Carboxylic esterases, oxidative enzymes and catecholamines in the superior cervical ganglion of the rat and the effect of pre- and post- ganglionic division. *Acta Physiol. Scand. Suppl.* 237: 1 - 94.
- Harkonen, M. and Kauffman, F.C. (1974) Metabolic alterations in the axotomized superior cervical ganglion of the rat. I. Energy metabolism. *Brain Res.* 65: 127-139.
- Hayes, A.G., Scadding, J.W., Skingle, M. and Tyers, M.B. (1981) Effect of neonatal capsaicin on nociceptive thresholds in the mouse and rat. *J. Pharm. Pharmacol.* 33: 183-185.
- Hayes, A.G. and Tyers, M.B. (1980) Effects of capsaicin on nociceptive heat, pressure and chemical thresholds and on substance P levels in the rat. *Brain Res.* 189: 561-564.
- Henle, J. (1865) Ueber das Gewebe der Nebenniere und der Hypophyse. *Z rat Med.* 24: 143. Cited in Tranzer and Richards (1976).
- Heybach, J.P., Levitt, H.M. and Brodish, A. (1979) Pituitary-adrenal activity, associated with central pain following complete forelimb deafferentations in rats. *Neurosci. Abstr.* 5: 611.
- Hodges, D.L. and McGuire, T.J. (1988) Burning and pain after injury. Is it Causalgia or Reflex Sympathetic Dystrophy? *Postgrad. Medicine* 83(2): 185 - 192.
- Hoffman, P.N., Griffin, J.W. and Price, D.L. (1981) Changes in the axonal transport of the cytoskeleton during development, aging and regeneration. *Soc. Neurosci. Abstr.* 7: 743.
- Hoffman, P.N. and Lasek, R.J. (1980) Axonal transport of the cytoskeleton in regenerating motor neurons: constancy and change. *Brain Res.* 202: 317-333.
- Holzer, P., Jurna, I., Gamse, R. and Lembeck, F. (1979) Nociceptive threshold after neonatal capsaicin treatment. *Eur. J. Pharmacol.* 58: 511-514.
- Hokfelt, T. (1966) The effect of reserpine in intraneuronal vesicles of the rat vas deferens. *Experientia* 22: 56-57.

- Hokfelt, T. and Dahlstrom, A. (1971) Effects of two mitosis inhibitors (Colchicine and Vinblastine) on the distribution and axonal transport of noradrenaline storage particles, studied by fluorescence and electron microscopy. *Z.Zellforsch* 119: 460-482.
- Holmes, W. and Young, J.Z. (1942) Nerve regeneration after immediate and delayed suture. *J.Anat.* 77: 63-96.
- Holtzman, E. and Novikoff, A. (1965) Lysosomes in the rat sciatic nerve following crush. *J. Cell Biol.* 27: 651-669.
- Homans, J. (1940) A hyperaesthetic neurovascular syndrome. *New Eng. J. Med.* 222: 870-874.
- Howe, J.F., Calvin, W.H. and Loeser, J.D. (1976) Impulses reflected from dorsal root ganglia and from focal nerve injuries. *Brain Res.* 116: 1394.
- Howe, J.F., Loeser, J.D. and Calvin, W.H. (1977) Mechanosensitivity of DRG and chronically injured axons: a physiological basis for the radicular pain of nerve root compression. *Pain* 3: 25 - 41.
- Hrdina, P.D. (1986) General principles of receptor binding. Chapter 1. In: *Neuromethods, Vol. 4 - Receptor binding.* Boulton, A.A., Baker, G.B. and Hrdina, P.D. (Eds.). Humana Press, Clifton, New Jersey.
- Hromada, J. (1963) On the nerve supply of the connective tissue of some peripheral nervous system components. *Acta Anatomica* 55: 343.
- Hyndman, O.R. (1939) Post Herpetic Neuralgia in the distribution of the cranial nerves. *Arch. Neurol. Psychiat.* 42: 224 - 232.
- Iggo, A. (1977) Cutaneous and subcutaneous sense organs. *Br. Med. Bull.* 33: 97-102.
- Jaim-Etcheverry, G. and Ziehar, L.M. (1969) Selective demonstration of a type of synaptic vesicle by phosphotungstic acid staining. *J.Cell Biol.* 42:855-860.
- Jansco, N. (1960) Role of the nerve terminals in the mechanism of inflammatory reactions. *Bull. Millard Fillmore Hosp.* 7: 53-77, Buffalo, N.Y.
- Jansco, N. (1968) Desensitization with capsaicin and related acylamides as a tool for studying the function of pain receptors. In: *Pharmacology of Pain*, R.K.S. Lim (Ed.) Pergamon Press, Oxford. pp 33-55.
- Jansco, N. and Jansco-Gabor, A. (1959) Dauerausschaltun der chemischen Schmerzempfindlichkeit durch capsaicin. *Arch. Exp. Path. Pharmak.* 239: 142. Cited in Scadding (1980).
- Jancso, N. and Jancso-Gabor, A. (1980) Effect of capsaicin on morphine analgesia - possible involvement of hypothalamic structures. *N.S. Arch. Pharmacol.* 311: 285 - 288.
- Jansco, G., Kiraly, E. and Jansco-Gabor, A. (1977) Pharmacologically induced selective degeneration of chemosensitive primary sensory neurones. *Nature* 270: 741-743.
- Jansco, G. and Kiraly, E. (1980) Distribution of chemosensitive primary sensory afferents in the central nervous system of the rat. *J. Comp. Neurol.* 190: 781-792
- Jansco, G., Kiraly, E. and Jansco-Gabor, A. (1980) Chemosensitive pain fibres

- and inflammation. *Int.J.Tiss.Reac.* 2: 57-66.
- Janig, W. (1985) Causalgia and Reflex Sympathetic Dystrophy: In which way is the sympathetic nervous system involved? *TINS* 8(11): 471 - 477.
- Janig, W. and McLachlan, E. (1984) On the fate of sympathetic and sensory neurons projecting into a neuroma of the superficial peroneal nerve in the cat. *J. Comp. Neurol.* 225: 302-311.
- Jenq, C.B. and Coggeshall, R.E. (1985) Numbers of regenerating axons in parent and tributary peripheral nerves in the rat. *Brain Res.* 326:27-40.
- Jensen, T. S. and Rasmussen, P. (1989) Phantom pain and related phenomena after amputation. In 'Textbook of Pain', Second Edition. Wall, P.D. and Melzack, R. (Eds.) Churchill Livingstone, Edinburgh. pp 508 -521.
- Jensen, T.S., Krebs, B., Nielsen, J. and Rasmussen, P. (1983) Phantom limb, phantom pain and stump pain in amputees during the first six months following limb amputation. *Pain* 17: 243-256.
- Jensen, T.S., Krebs, B., Nielsen, J. and Rasmussen, P. (1985) Immediate and long term phantom limb pain in amputees : incidence, clinical characteristics and relationship to pre-amputation limb pain. *Pain* 21: 267-278.
- Jessell, T.M., Iversen, L.L. and Cuello, A.C. (1978) Capsaicin induced depletion of substance P from primary sensory neurones. *Brain Res.* 152: 183-188.
- Jessell, T.M., Tsunoo, A., Kanazawa, I. and Otsuka, M. (1979) Substance P: depletion in the dorsal horn of rat spinal cord after section of the peripheral processes of primary sensory neurones. *Brain Res.* 168: 247-259.
- Johnson, E.M. (Jr.) and O'Brien, F. (1976) Evaluation of the permanent sympathectomy produced by the administration of guanethidine to adult rats. *J. Pharmacol. Exp. Ther.* 196: 53-61.
- Jolly (1960) Cited in Gillis, L. (1964) The management of the painful amputation stump and a new theory for the phantom phenomena. *Br.J.Surg.* 51: 87-95.
- Jonsson, G. (1967) Further studies on the specificity of the histochemical fluorescence method for the demonstration of catecholamines. *Acta Histochem.* 26: 379-390.
- Joo, F., Szolcsanyi, J. and Jansco-Gabor, A. (1969) Mitochondrial alterations in the spinal ganglia cells of the rat accompanying the long lasting sensory disturbance induced by capsaicin. *Life Sci.* 8:621-626.
- Juel-Jensen, B.E. (1970) The natural history of shingles : events associated with reactivation of varicella-zoster virus. *J. Roy. Coll. Gen. Pract.* 20: 323 - 327.
- Juel-Jensen, B.E. and MacCallum, F.O. (1972) *Herpes Simplex Varicella and Zoster.* Lippincott, Philadelphia, PA. 194pp.
- Jurecka, W., Ammerer, H.P. and Lassmann, H. (1975). Regeneration of a transected peripheral nerve. An autoradiographic and electron microscopic study. *Acta Neuropath. (Berlin).* 32: 299-312.
- Kallio, K.E. (1950) Permanency of results obtained by sympathetic surgery in the treatment of phantom pain. *Acta Orthopaedica Scandinavica* 19: 391-397

- Kappeller, K. and Mayor, D. (1965) Accumulation of noradrenaline proximal to the site of constriction of sympathetic nerves. *J.Physiol.(Lond.)* 182: 44-45P.
- Kapeller, K. and Mayor, D. (1967) The accumulation of noradrenaline in constricted sympathetic nerves as studied by fluorescence and electron microscopy. *Proc. Roy. Soc. B.* 167: 282-292.
- Kappeller, K. and Mayor, D. (1969) An electron microscopic study of the early changes proximal to a constriction in sympathetic nerves. *Proc.R.Soc.Lond. (Biol.)* 172: 39-51.
- Karlstrom, L. and Dahlstrom, A. (1973) The effect of different types of axonal trauma on the synthesis and transport of amine storage granules in rat sciatic nerves. *J. Neurobiol.* 4: 191-200.
- Kaufmann, S. and Friedmann, S. (1965) Dopamine beta-hydroxylase. *Pharmacol. Rev.* 17: 71-100.
- Kerns, J.M. and Hinsman, E.J. (1974) Neuroglial response to sciatic neurectomy. II Electron microscopy. *J.Comp. Neurol.* 151: 255 - 280.
- King, R.H.M. and Thomas, P.K. (1971) Electron microscope observations on aberrant regeneration of unmyelinated axons in the vagus nerve of the rabbit. *Acta Neuropath. Berl.* 18: 150 - 159.
- Kirk, E.J. (1974) Impulses in dorsal spinal nerve rootlets in cats and rabbits arising from dorsal root ganglia isolated from the periphery. *J.Comp. Neurol.* 155: 165 - 176.
- Kirklín, J.W., Henoweth, A.I. and Murphey, F. (1947) Causalgia : A review of its characteristics, diagnosis and treatment. *Surgery* 21: 321-342.
- Kniyhar, E. and Csillik, B. (1976) Representation of cutaneous afferents by FRAP-active terminals in the rat substantia gelatinosa Rolandi. *Acta Neurol.Scand.* 53: 217-225.
- Kohn, A. (1902) Das chromaffine Gewebe. *Z ges Anat. 3. Ergebn Anat. Entw. Gesch.* 12: 253. Cited in Tranzer and Richards (1976).
- Korsching, S.I., Heumann, R., Davies, A. and Thoenen, H. (1986). *Soc. Neurosci. Abstr.* 12: 1096.
- Krainick, J.U. and Thoden U. (1980) Phantomlimbphänomene bei Amputierten. *Neurochirurgia* 19: 72 - 80. Cited in Krainick et al (1980).
- Krainick, J.U., Thoden, U. and Reichert, T. (1980) Pain reduction in amputees by long term spinal cord stimulation. *J. Neurosurg.* 52: 346-350.
- Krebs, B., Jensen, T.S., Kroner, K., Nielsen, J. and Jorgensen, H.S. (1984) Phantom limb phenomena in amputees 7 years after limb amputation. *Pain Suppl.* 2: S85.
- Kuhar, M.J., De Souza, E.B. and Unnerstall, J.R. (1986) Neurotransmitter receptor mapping by autoradiography and other methods. *Ann. Rev. Neurosci.* 9: 27-59.
- Kwan, S.T. (1935) The treatment of causalgia by thoracic sympathetic

- Kappeller, K. and Mayor, D. (1965) Accumulation of noradrenaline proximal to the site of constriction of sympathetic nerves. *J.Physiol.(Lond.)* 182: 44-45P.
- Kapeller, K. and Mayor, D. (1967) The accumulation of noradrenaline in constricted sympathetic nerves as studied by fluorescence and electron microscopy. *Proc. Roy. Soc. B.* 167: 282-292.
- Kappeller, K. and Mayor, D. (1969) An electron microscopic study of the early changes proximal to a constriction in sympathetic nerves. *Proc.R.Soc.Lond. (Biol.)* 172: 39-51.
- Karlstrom, L. and Dahlstrom, A. (1973) The effect of different types of axonal trauma on the synthesis and transport of amine storage granules in rat sciatic nerves. *J. Neurobiol.* 4: 191-200.
- Kaufmann, S. and Friedmann, S. (1965) Dopamine beta-hydroxylase. *Pharmacol. Rev.* 17: 71-100.
- Kerns, J.M. and Hinsman, E.J. (1974) Neuroglial response to sciatic neurectomy. II Electron microscopy. *J.Comp. Neurol.* 151: 255 - 280.
- King, R.H.M. and Thomas, P.K. (1971) Electron microscope observations on aberrant regeneration of unmyelinated axons in the vagus nerve of the rabbit. *Acta Neuropath. Berl.* 18: 150 - 159.
- Kirk, E.J. (1974) Impulses in dorsal spinal nerve rootlets in cats and rabbits arising from dorsal root ganglia isolated from the periphery. *J.Comp. Neurol.* 155: 165 - 176.
- Kirklin, J.W., Henoweth, A.I. and Murphey, F. (1947) Causalgia : A review of its characteristics, diagnosis and treatment. *Surgery* 21: 321-342.
- Kniyhar, E. and Csillik, B. (1976) Representation of cutaneous afferents by FRAP-active terminals in the rat substantia gelatinosa Rolandi. *Acta Neurol.Scand.* 53: 217-225.
- Kohn, A. (1902) Das chromaffine Gewebe. *Z ges Anat. 3. Ergebn Anat. Entw. Gesch.* 12: 253. Cited in Tranzer and Richards (1976).
- Kopin, I.J. and Silberstein, S.D. (1972) Axons of sympathetic neurons: Transport of enzymes in vivo and properties of axonal sprouts in vitro. *Pharmacol.Rev.* 24: 245-254
- Korenmann, E.M.D. and Devor, M. (1981) Ectopic adrenergic sensitivity in damaged peripheral nerve axons in the rat. *Exp. Neurol.* 72: 63-81.
- Krainick, J.U. and Thoden U. (1976) Schmerzphanomene bei Amputierten. *Neurochirurgia* 19: 72 - 80. Cited in Krainick et al (1980).
- Krainick, J.U., Thoden, U. and Reichert, T. (1980) Pain reduction in amputees by long term spinal cord stimulation. *J. Neurosurg.* 52: 346-350.
- Krebs, B., Jensen, T.S., Kroner, K., Nielsen, J. and Jorgensen, H.S. (1984) Phantom limb phenomena in amputees 7 years after limb amputation. *Pain Suppl.* 2: S85.
- Kuhar, M.J., De Souza, E.B. and Unnerstall, J.R. (1986) Neurotransmitter receptor mapping by autoradiography and other methods. *Ann. Rev. Neurosci.* 9: 27-59.
- Kwan, S.T. (1935) The treatment of causalgia by thoracic sympathetic

ganglionectomy. *Ann. Surg.* 101: 222-227.

- Landon, D.N. (Ed.) (1976) *The Peripheral Nerve*. Chapman and Hall, London.
- Laduron, P. and Belpaire, F. (1968) Transport of noradrenaline and dopamine beta-hydroxylase in sympathetic nerves. *Life Sci.* 7: 1-7.
- Lagercrantz, H. (1976) On the composition and function of the large dense cored vesicles in sympathetic nerves. *Neuroscience* 1: 81-92.
- Lampert, P.W. (1967) A comparative electron microscope study of reactive, degenerating, regenerating and dystrophic axons. *J. Neuropath. Exp. Neurol.* 26: 345-368.
- Lands, A.M., Arnold, A., McAuliff, J.P., Luduena, F.P. and Brown, T.G. (1967) Differentiation of receptor systems activated by sympathomimetic amines. *Nature (Lond.)* 214: 597-598.
- Langer, S.Z. (1974) Presynaptic regulation of catecholamine release. *Biochem. Pharmacol.* 23: 1793-1800.
- Lasek, R.J. (1968) Axoplasmic transport in cat dorsal root ganglion cells: as studied with (3H)-L-leucine. *Brain Res.* 7: 360-377.
- Lassmann, H. and Ammerer, H.P. (1974) Schwann cells and perineurium in neuroma. Some morphological aspects. *Virchows Arch. Abt. B. Zellpath.* 15: 313-321.
- Lawson, S.N. and Nickels, S.M. (1980) The use of morphometric techniques to analyse the effect of neonatal capsaicin treatment on rat dorsal root ganglia and dorsal roots. *J. Physiol. (Lond.)* 303: 12P.
- Lascar, G. (1980) Ultrastructural identification of catecholamine containing vesicles in the ligated sciatic nerve of the rat. Comparison with sympathetic terminals. *Cell Tiss. Res.* 209: 433-454.
- Leger, L. and Audoly, P. (1942) *Traitement du zona par l'infiltration stellaire*. Press Med. 50: 588.
- Leriche, R. (1916) De la causalgie envisagee comme un nervite du sympathique et de son traitement. *Presse Med.* 24: 177-180.
- Leriche, R. (1937) *Chirurgie de la Douleur*. Masson et Cie., Paris.
- Leriche, R. (1939) *La Chirurgie de la Douleur*. Masson et Cie., Paris.
- Letievent, E. (1873) *Traite de sections nerveuses*. J.B. Bailliere et Fils, Paris.
- Levine, J.D., Coderre, T.J., Helms, C. and Basbaum, A.I. (1988) Beta2 Adrenergic mechanisms in experimental arthritis. *Proc. Nat. Acad. Sci. USA* 85: 4553 - 4556.
- Levine, J.D., Dardick, S.J., Roizen, M.F., Helms, C. and Basbaum, A.I. (1986) Contribution of sensory afferents and sympathetic efferents to joint injury in experimental arthritis. *J. Neurosci.* 6 (12): 3423 - 3429.
- Levine, J.D., Moskowitz, M.A. and Basbaum, A.I. (1968) The contribution of neurogenic inflammation in experimental arthritis. *J. Immunol.* 135: 843s - 847s.
- Lever, U.D., Santer, R.M., Lu, K.S. and Presley, R. (1977) Electron probe X-Ray microanalysis of small granulated cells in rat sympathetic ganglia after sequential aldehyde and dichromate treatment.



- J.Histochem.Cytochem. 25(4): 275-279.
- Levi-Montalcini, R. (1976) The nerve growth factor: its role in growth differentiation and function of the sympathetic adrenergic neuron. Prog.Brain Res. 45: 235-258.
- Lewis, T., Pickering, G.W. and Rothschild, P. (1931) Centripetal paralysis arising out of arrested block flow to the limb, including notes on a form of tingling. Heart 16: 1-32.
- Lewis, T. (1936) Vascular disorders of the limbs. Macmillan, London.
- Lewis, T. (1937) The nocifensor system of nerves and its reactions. B.M.J. 431: 491.
- Lhermitte, J. et Nicolas. (1924) Les lésions spinales du zona. La myélite zosterienne. Rev. Neurol. 1: 361 - 364.
- Lieberman, A.R. (1971) The axon reaction: a review of the principal features of perikaryal response to axon injury. Int. Rev. Neurobiol 14: 49-124.
- Lindvall, O. and Bjorklund, A. (1974) The glyoxylic acid fluorescence method for central catecholamine neurons: a detailed account on the methodology. Histochemistry 39: 97-127.
- Lisney, S.J.W. and Diamond, J. (1989) Personal communication in Devor, M.: The pathophysiology of damaged peripheral nerves. In 'Textbook of Pain' Second Edition. Wall, P.D. and Melzack, R. (Eds.) Churchill Livingstone, Edinburgh. pp 63 -81.
- Lisney, S.J.W. and Pover, C.M. (1983) Coupling between fibres involved in sensory nerve neuromata in cats. J.Neurol.Sci. 59(2): 255-64.
- Lison, L. (1936) Histochemie Animale. Gautier Villars, Paris. pp 143 -147. Cited in Tranzer and Richards (1976).
- Livingston, W.K. (1938) Post-traumatic pain syndromes. West. J. Surg. Obstet. Gynaecol. 46: 341-347.
- Livingston, W.K. (1943) Pain Mechanisms: A physiologic interpretation of causalgia and its related states. MacMillan, New York.
- Loeser, J.D. and Ward, A.A. (1967) Some effects of deafferentation on neurons of the cat spinal cord. Arch. Neurol. 17: 629-636.
- Loh, L. and Nathan, P.W. (1978) Painful peripheral states and sympathetic blocks. J. Neurol. Neurosurg. Psychiat. 41: 664-671.
- Loh, L., Nathan, P.W. and Schott, G.D. (1981) Pain due to lesions of the central nervous system removed by sympathetic block. B.M.J. 282: 1026 - 1028.
- Lombard, J.C., Jarlet, M.A. and Daheb, S. (1984) Correlation between deafferentation, self-mutilation, neuronal rhythmical activity and sleep distribution in the rat. Pain suppl. 2: S 445.
- Lourie, H. and King, R.B. (1966). Sensory and neurohistological correlates of cutaneous hyperpathia. Arch. Neurol. 14: 313-320.
- Low, P.A., Schmelzer, J.D., Ward, K.K. and Yao, J.K. (1986) Experimental chronic hypoxic neuropathy: relevance to diabetic neuropathy. Am. J. Physiol. 250: E94 - E99.

- Low, P.A., Schmelzer, J.D., Ward, K.K., Curran, G.L. and Poduslo, J.F. (1988) Effect of hyperbaric oxygenation on normal and chronic streptazotocin induced diabetic peripheral nerves. *Exp. Neurol.* 99: 201 - 212.
- Lubinska, L. (1961) Sedentary and migratory states of Schwann cells. *Exp. Cell Res. Suppl.* 8: 74-90
- Lynn, B. (1975) Somatosensory receptors and their central nervous system connections. *Ann. Rev. Physiol.* 37: 105-127.
- Lynn, B. (1977) Cutaneous hyperalgesia. *Br. Med. Bull.* 33: 103-108.
- Martinez, A.J. and Friede, R.L. (1970) Accumulation of axoplasmic organelles in swollen nerve fibres. *Brain Res.* 19: 183-198.
- Matthews, B. (1976) Effects of stimulation on the response of intradental nerves to chemical stimulation of dentine. In: *Advances in Pain Research and Therapy, Vol. 1.* Bonica, J. J., Liebeskind, J.C. and Albe-Fessard, D.G. (Eds.) Raven Press, New York.
- Matthews, M.R. (1973) An ultrastructural study of axonal changes following constriction of postganglionic branches of the superior cervical ganglion in the rat. *Phil.Trans.B.* 264: 470-508.
- Mayer, M.L., James, M.H., Russell, R.J., Kelly, J.S. and Wise, J.C. (1986) Changes in excitability induced by herpes simplex viruses in rat DRG neurons. *J. Neurosci.* 6(2): 391-402.
- Mayor, D. and Kappeller, K. (1967) Fluorescence microscopy and electron microscopy of adrenergic nerves after constriction at two points. *J. Roy. Microsc. Soc.* 87: 277-294.
- Mclachlan, E.M. and Janig, W. (1983) The cell bodies of origin of sympathetic and sensory axons in some skin and muscle nerves of the cat hind limb. *J. Comp. Neurol.* 214(2): 115-30.
- McQuarrie, I.G., Grafstein, B., Dreyfus, C.F. and Gershon, M.D. (1978) Regeneration of adrenergic axons in rat sciatic nerve: effect of a conditioning lesion. *Brain Res.* 141: 21-34.
- Melzack, R. and Wall, P.D. (1965) Pain mechanisms, a new theory. *Science* 150: 971-979.
- Melzack, R. and Wall, P.D. (1982) *The Challenge of Pain.* Penguin Education, London.
- Meyer, G.A. and Fields, H.L. (1972) Causalgia treated by selective large fibre stimulation of peripheral nerve. *Brain* 95: 163 -168.
- Meyer, R.A., Raja, S.N. and Campbell, J.N. (1985) Neural activity originating from a neuroma in a baboon. *Brain Res.* 325: 255-60.
- Mitchell, S.W. (1867) "On the diseases of Nerves, resulting from injuries", in Flint, A. (Ed): *Contributions relating to the causation and prevention of disease, and to camp diseases.* U.S. Sanitary Commission Memoirs, New York.
- Mitchell, S.W. (1872) *Injuries of nerves and their consequences.* London: Smith Elder. Mitchell, S.W., Morehouse, G.R. and Keen, W.W. (1864) *Gunshot wounds and other injuries of nerves.* J.B. Lippincott, Philadelphia.
- Mobley, W.C. Server, A.C., Ishii, D.N., Riopelle, R.J. and Shooter, E.M. (1977) Nerve Growth Factor. *New Eng.J.Med.* 297: 1096-1104, 1149-1158,

- Moradian, G.P. and Rustioni, A. (1977) Transganglionic degeneration in the dorsal horn and dorsal column nuclei of adult rats. *Anat. Rec.* 187: 660.
- Merrington, W.R. and Nathan, P.W. (1949) A study of post-ischaemic parathesiae. *J. Neurol. Neurosurg. Psychiat.* 12: 1.
- Murray, N. (1973) 3H-Uridine incorporation by regenerating retinal ganglion cells of goldfish. *Exp. Neurol.* 39: 489-497.
- Morris, J.H., Hudson, A.R. and Weddell, G. (1972; A,B,C,D) A study of degeneration and regeneration in the divided rat sciatic nerve based on electron microscopy. *Z. Zellforsch. Mikros. Anat.* 124: 76-203.
- Motsnyi, P.E. and Bagramova, M.A. (1972) Sympathetic influences on presynaptic inhibition of the dorsal spinal cord potential. *Fiziologicheskii Zhurnal I.M. Sechenova*, 58: 697 - 701. In Russian. Cited in Loh and Nathan (1978).
- Nageotte, J. (1932) Sheaths of peripheral nerves. In: *Cytology and Cell Pathology of the Nervous system*. Vol.1. W. Penfield (Ed.) New York. pp 191-239.
- Nagy, J.I., Vincent, S.R., Staines, W.A., Fibiger, H.C., Reisine, T.D. and Yamamura, H.I. (1980) Neurotoxic action of capsaicin on spinal substance P neurones. *Brain Res.* 186: 435-444.
- Nagy, J.I. (1982) Capsaicin's action on the nervous system. *TINS* 5: 362-365.
- Nagy, J.I., Hunt, S.P., Iversen, L.L. and Emson, P.C. (1981) Biochemical and anatomical observations on the degeneration of peptide-containing primary afferent neurons after neonatal capsaicin. *Neuroscience* 6: 1923-1934.
- Nagy, J.I., Buss, U. and Mallory, B. (1986) Autotomy in rats after peripheral nerve section: lack of effect of topical nerve or neonatal capsaicin treatment. *Pain* 24: 75-87.
- Nathan, P.W. (1947) On the pathogenesis of causalgia in peripheral nerve injuries. *Brain* 70: 145-170.
- Nathan, P.W. (1980) Involvement of the sympathetic nervous system in pain. In: *Pain and Society*. Kosterlitz, H.W. and Terenius, L.Y. (Eds.) Weinheim: Verlag Chemie. pp 311- 324.
- Nathan, P.W. and Wall, P.D. (1974) Treatment of post herpetic neuralgia by prolonged electrical stimulation. *B.M.J.* 3(1974): 645 - 647.
- Nemes, Z. (1974) The mechanism of metal binding to glutaraldehyde fixed noradrenaline-storing adrenomedullary granules. *Histochem. J.* 6: 611-620.
- Newrick, P.G., Wilson, A.J., Jakubowski, J. Boulton, A.J.M. and Ward, J.D. (1986) Sural nerve oxygen tension in diabetes. *B.M.J.* 293: 1053 - 1054.
- Nickerson, M. and Collier, B. (1975) In 'The Pharmacological Basis of Therapeutics'. 6th. Edition. Goodman, L.S. and Gilman, A. (Eds.) MacMillan, New York.
- Nissl, F. (1892) Uber die Veränderungen der Ganglionzellen am Facialiskern des kaninchens nach Ausreissung der Nerven. *All. Z. Psychiat. Ihre Grenz.* 48: 197 - 198. Cited in Grafstein (1975).

- Noordenbos, W. (1959) Pain. Elsevier, Amsterdam.
- Nukada, H. (1986) Increased susceptibility to ischaemic damage in streptozotocin-diabetic nerve. *Diabetes* 35: 1058-1061.
- Ochoa, J. (1972) Ultrathin longitudinal sections of single myelinated fibres for electron microscopy. *J. Neurol. Sci.* 17: 103.
- Ochoa, J. (1976) The primary nerve fibre pathology of plantar neuromas. A model of chronic entrapment. *J. Neuropathol. Exp. Neurol.* 35: 370.
- Ochoa, J. (1978) Recognition of unmyelinated fibre disease: morphologic criteria. *Muscle and Nerve* 1: 375.
- Ochs, S. (1971a) Characteristics and a model for fast axoplasmic transport in nerve. *J. Neurobiol.* 2: 331-345.
- Ochs, S. (1971b) The dependence of fast transport in mammalian nerve fibres on metabolism. *Acta Neuropath. Suppl. V*: 86-96.
- Ochs, S. (1982) Axoplasmic transport and its relation to other nerve functions. John Wiley, New York.
- Ohshiro, J., Fujiwara, M. and Osumi, Y. (1978) Axonal transport of noradrenaline and choline acetyl transferase in regenerating sciatic nerve of the rat. *Exp. Neurol.* 62: 159-172.
- Olson, L. and Malmfors, T. (1970) Growth characteristics of adrenergic nerves in the adult rat. *Acta Physiol. Scand.* 80 (Suppl.348): 1-112.
- Owman, C. and Santini, M. (1966) Adrenergic nerves in spinal ganglia of the cat. *Acta Physiol. Scand.* 68: 127-128.
- Pak, T.J., Martin, G.M., Magness, J.L. and Kavanagh, M.D. (1970) Reflex sympathetic dystrophy. *Minn. Med.* 53: 507-512.
- Paravicini, U., Stoeckel, K. and Thoenen, H. (1975) Biological importance of retrograde axonal transport of nerve growth factor in adrenergic neurons. *Brain Res.* 84: 279-291.
- Parkes, C.M. (1973) Factors determining the persistence of phantom pain in the amputee. *J. Psychosomatic Research* 17: 97-108.
- Parry, G.J. and Brown, M.J. (1982) Selective fibre vulnerability in acute ischaemic neuropathy. *Ann. of Neurol.* 11: 147-154.
- Patman, R.D., Thompson, J.E. and Persson, A.V. (1973) Management of post-traumatic pain syndromes. *Ann. Surg.* 177: 780-787.
- Payne, R. (1986) Neuropathic pain syndromes, with special reference to causalgia and reflex sympathetic dystrophy. *Clinical Journal of Pain* 2: 59-73.
- Pearson, C.M. and Wood, F.D. (1959) Studies of polyarthritis and other lesions induced in rats by injection of mycobacterial adjuvant. I. General clinical and pathological characteristics and some modifying factors. *Arth. Rheum.* 2: 440-459.
- Pease, D.C. and Quilliam, T.A. (1957) Electron microscopy of the Pacinian corpuscle. *J. Biophys. Biochem. Cytol.* 3: 331-342.
- Pellegrino de Iraldi, A., Farini Duggan, H. and De Robertis, E.D.P. (1964)

---

Pini, A., Baranowski, R. and Lynn, B. (1990). Long-term reduction in the number of C-fibres following capsaicin treatment of a cutaneous nerve in adult rats. *Eur. J. Neurosci.* 2: 89 - 97.

Adrenergic synaptic vesicles in the anterior hypothalamus of the rat. *Anat. Rec.* 145/4: 521 - 531.

- Pellegrino de Iraldi, A. and De Robertis, E.D.P. (1968) The neurotubular system of the axon and the origin of granulated and non-granulated vesicles in regenerating nerves. *Z.Zellforsch.* 87: 330-344.
- Pellegrino de Iraldi, A. and De Robertis, E.D.P. (1970) Studies on the origin of the granulated and non-granulated vesicles. Bayer Symposium, II, 4-17. Springer-Verlag, Berlin.
- Perroncito, A. (1907) Die regeneration der Nerven. *Bietr. Z.Pathol.Anat. u.z. Allegen. Pathol.* 42:354-446. Cited in Young (1942).
- Peyronnard, J.M., Charron, L., Lavoie, J. and Messier, J.P. (1986) Differences in HRP labelling of sensory motor and sympathetic neurones following chronic axotomy of rat sural nerve. *Brain Res.* 364: 137-150.
- Pictet, A. and Spengler, T. (1911) Uber die Bildung von Isochinol inderivaten durch Einwirkung von methyalal auf Phenyl-athylamin, Phenyl-alanin und Tyrosin. *Ber. Dtsch. Chem. Ges.* 44: 2030-2036. Cited in Bjorklund (1983).
- Potter, L.T. (1967) Role of intraneuronal vesicles in the synthesis, storage, and release of noradrenaline. *Circulation Res. Suppl.* 3, 21: 13-24.
- Purves, D. (1975) Functional and structural changes of mammalian sympathetic neurones following interruption of their axons. *J. Physiol. (Lond.)* 252: 429-463.
- Raff, M.C., Sangalang, V. and Asbury, A.K. (1968) Ischaemic mononeuropathy multiplex associated with diabetes mellitus. *Arch. Neurol.* 18: 487.
- Ranson, S.W. (1906) Retrograde degeneration in the spinal nerves. *J.Comp.Neurol.* 16: 265-293.
- Ranson, S.W. (1912) Degeneration and regeneration of nerve fibres. *J.Comp.Neurol.* 22: 487-545.
- Rasminsky, M. (1978) Ectopic generation of impulses and crosstalk in spinal nerve roots of dystrophic mice. *Ann. Neurol.* 3: 351-357.
- Rasminsky, M. (1980) Ephaptic transmission between single nerve fibres in the spinal nerve roots of dystrophic mice. *J.Physiol.* 305: 151-169.
- Reis, D.J. and Ross, R.A. (1973) Dynamic changes in brain dopamine beta hydroxylase activity during anterograde and retrograde reaction to injury of central noradrenergic neurons. *Brain Res.* 57: 307-326
- Rexed, B. (1942) Uber die Aktivitat der Schwannschen Zellen bei der Nervenregeneration. I. Die uberbruckung neuritloser Nervenlücken. *Z.Mikr.Anat.Forschung.* 51: 177-205.
- Richards, J.G. (1980) Ultrastructural visualization of biogenic monoamines. Chapter III. In: *Handbook of Chemical Neuroanatomy. Vol.1: Methods in Chemical Neuroanatomy.* A.Bjorklund and T.Hokfelt (Eds.) Elsevier, Amsterdam.
- Richards, J.G. and Da Prada, M. (1977) Uranaffin reaction: A new cytochemical technique for the localization of adenine nucleotides in organelles storing biogenic amines. *J.Histochem.Cytochem.* 25: 1322-1336.

- Richards, J.G. and Da Prada, M. (1980) Cytochemical investigations on subcellular organelles storing biogenic amines in peripheral adrenergic neurons. In: Eranko, O., Soinila, S. and Paivarinta, H. (Eds.) *Histochemistry and Cell Biology of Autonomic Neurons, SIF cells and Paraneurons*. Raven Press, New York.
- Richards, J.G. and Tranzer, J.P. (1975) Localization of amine storage sites in the adrenergic cell body. A study of the superior cervical ganglion of the rat by fine structural cytochemistry. *J. Ultrastr. Res.* 53: 204-216.
- Richards, R.L. (1967) Causalgia: A Centennial Review. *Arch. Neurol.* 16: 339-350.
- Richardson, K.C. (1962) The fine structure of autonomic nerve endings in smooth muscle of the rat vas deferens. *Am.J.Anat.* 96: 427-442.
- Rodin, B.E. and Kruger, L. (1984) Deafferentation in animals as a model for the study of pain: an alternative hypothesis. *Brain Res. Rev.* 7: 213-228.
- Roizin, L., Nishikawa, K., Koizumi, J. and Keoseian, S. (1967) The fine structure of the multi-vesicular body and its relationship to the ultracellular constituents of the central nervous system. *J.Neuropathol.Exp.Neurol.* 26: 223-249.
- Romanes, G.J. (1941) The development and significance of the cell columns in the ventral horn of the cervical and upper thoracic spinal cord of the rabbit. *J.Anat.* 76: 112 - 130.
- Romanes G.J. (1946) Motor localization and the effects of nerve injury on the ventral horn cells of the spinal cord. *J.Anat.* 80: 117-131.
- Rose, F.A., Lever, J.D. and Santer, R.M. (1979) Biogenic amine detection in vivo and in vitro: a combined histochemical and X-Ray analytical study. In: Usdin E., Kopin, I.J. and Barchas, J. (Eds.) *Catecholamines, Basic and Clinical Frontiers*. Pergamon Press, Oxford. pp 877-879.
- Ross, J.P. (1932) Causalgia. *St. Barth. Hosp. Rep.* 65: 103-188.
- Rowlingson, J.C. (1983) The sympathetic dystrophies. *International Anaesthesiology Clinics*, 321: 117-129.
- Ruiz, J.A., Kocsis, J.D. and Preston, R.J. (1981) Repetitive firing characteristics of mammalian myelinated axons: an intra-axonal analysis. *Society for Neuroscience Abstracts*, 7: 904-935.
- Russell, L.C. and Burchiel, K.J. (1986) Effect of intrathecal and subepineurial capsaicin on thermal sensitivity and autotomy in rats. *Pain* 25: 109-123.
- Santer, R.M., Lever, J.D. and Davies, T.W. (1978) X-ray microanalysis in biogenic amine detection in the sympathochromaffin system. In: Coupland, R.E. and Forssman, W.G. (Eds.) *Peripheral neuroendocrine interactions*. Springer, Berlin.
- Santini, M. (1966) Adrenergic fibres in the feline Gasserian ganglion. *Life Sci.* 5: 283-287.
- Santini, M. (1968) Noradrenergic fibres in Pacinian corpuscles. *Anat. Rec.* 160: 494.
- Santini, M. (1969) New fibres of sympathetic nature in the inner core of Pacinian corpuscles. *Brain Res.* 16: 535-538.

- Santini, M. (1972) Gasserian and spinal ganglia: a fine structural identification of adrenergic axons closely apposed to ganglion and satellite cells. *J. Cell Biol.* 55: 226a.
- Santini, M. (1976) Towards a theory of sympathetic sensory coupling: the primary sensory neurone as a feedback target of the sympathetic terminal. In: *Sensory functions of the skin in primates*. Zotterman, Y. (Ed.) Pergamon Press, Oxford.
- Santini, M. and Berl, S. (1972) Effects of reserpine and mono-amine oxidase inhibition on the levels of amino acids in sensory ganglia, sympathetic ganglia and spinal cord. *Brain Res.* 47: 167.
- Santini, M., Ibata, Y. and Pappas, G.D. (1971) The fine structure of the sympathetic axons within the Pacinian corpuscle. *Brain Res.* 33: 179-187.
- Scadding, J.W. (1980) The permanent anatomical effects of neonatal capsaicin on somatosensory nerves. *J. Anat.* 131: 473-484.
- Scadding, J.W. (1981) Development of ongoing activity, mechanosensitivity and adrenaline sensitivity in severed peripheral nerve axons. *Exp. Neurol.* 73: 345-364.
- Scadding, J.W. (1982) M.D. Thesis, University of London.
- Scadding, J.W. (1984) Peripheral Neuropathies. In: *Textbook of Pain*. Wall, P.D. and Melzack, R. (Eds.) Churchill Livingstone, Edinburgh. pp 413-425.
- Scadding, J.W. (1989) Peripheral Neuropathies. Chapter 37 in *Textbook of Pain*. Wall, P.D. and Melzack, R. (Eds.) Churchill Livingstone, Edinburgh, pp 522-534.
- Scadding, J.W. and Klenerman, L. (1987) Light and electron microscope observations in Morton's neuralgia. *Pain Suppl.*3: S346.
- Schoenen, J., Budo, C. and Poncelet, G. (1968) Effet de la section du sciatique sur l'activite de l'isoenzyme fluororesistant de la phosphatase acide dans la moelle epiniere du rat. *Comptes Rendus de Societe de Biologie.* 162: 2035. Cited in Wall and Devor (1982).
- Schon, F., Mayer, M.L. and Kelly, J.S. (1987) Pathogenesis of post-herpetic neuralgia. *Lancet* 2 (8555): 366-8.
- Schmitt, F.O. (1968) The molecular biology of neural fibrous proteins. *Neurosci. Res. Progr. Bull.* 6: 119-144.
- Schutzer, S.F. and Gossling, H.R. (1984) The treatment of reflex sympathetic dystrophy syndrome. *J. Bone and Joint Surg.* 66A: 625-629.
- Seltzer, Z. and Devor, M. (1979) Ephaptic transmission in chronically damaged peripheral nerves. *Neurology (Minneap.)* 29: 1061-1064.
- Shaw, R.C. (1933) Sympathetic system and pain phenomena. *Arch. Surg.* 27: 1072-1080.
- Sherman, R.A. and Sherman C.J. (1985) A comparison of phantom sensations among amputees whose amputations were of civilian and military origins. *Pain* 21: 91-97.
- Shumacker, H.B. (1948) Causalgia. III General discussion. *Surgery* 24: 485-504.



- Shumacker, H.B. Jr. (1985) A personal view of causalgia and other reflex sympathetic dystrophies. *Ann. Surg.* 201: 278-289.
- Shumacker, H.B., Spiegel, I.J. and Upjohn, R.H. (1948) Causalgia. *Surg. Gynaec. Obstet.* 86: 452-460
- Sjostrand, J. and Karlsson, J.O. (1970) Axonal transport in central and peripheral axons. *Acta Physiol. Scand. Suppl.* 357: 18.
- Skoglund, C.R. (1942) The response to linearly increasing currents in mammalian motor and sensory nerves. *Acta Physiol. Scand.* 4. Suppl. 12.
- Slessor, A.J. (1948) Causalgia: A review of 22 cases. *Edinburgh Med. J.* 44: 563-571.
- Smith, A.D. and Winkler, H. (1972) Fundamental mechanisms in the release of catecholamines. *Handb.Exp.Pharmacol.* 33: 538- 543.
- Sotelo, C. (1971) The fine structural localization of H-norepinephrine in the substantia nigra and area postrema of the rat. An autoradiographic study. *J.Ultrastr.Res.* 36: 824-841.
- Spencer, P.S. (1971) Light and electron microscopic observations on localized peripheral nerve injury. Ph.D. Thesis, London University.
- Spencer, P.S. (1974) The traumatic neuroma and proximal stump. *Bulletin of the Hospital for Joint Diseases (John Hopkins).* 35: 85-102.
- Spurling, R.G. (1930) Causalgia of the upper extremity. Treatment by dorsal sympathetic ganglionectomy. *Arch. Neurol. Psychiatry* 23: 784-788.
- Stammers, F.A.R. (1932) Some experience with sympathetic ganglionectomy. *Br. J. Surg.* 20: 67-77.
- Starke, K. (1981) Alpha-adrenoreceptor subclassification. *Rev. Physiol. Biochem. Pharmacol.* 88: 199-236.
- Starke, K., Borowski, E. and Endo, T. (1975). Preferential blockade of presynaptic alpha receptors by yohimbine. *Eur.J.Pharmacol.* 34: 385-388.
- Steinbrocker, O. and Argyros, T.G. (1958) The Shoulder-Hand syndrome: Present status as a diagnostic and therapeutic entity. *Med. Clin. North Am.* 42: 1533-1553.
- Sternbach, R.A. (1984) Acute vs. chronic pain. Chapter 1:14 In: *Textbook of Pain.* Wall P.D. and Melzack R. (Eds.) Churchill Livingstone, Edinburgh. pp 173-177.
- Sumner, B.E.H. and Watson, W.E. (1971) Retraction and expansion of the dendritic tree of motor neurones of adult rats induced in vivo. *Nature (London)* 233: 273-275.
- Sunderland, S. (1953) The capacity of regenerating axons to bridge long gaps in nerves. *J.Comp.Neurol.* 99: 481-493.
- Sunderland, S. (1976) Pain mechanisms in causalgia. *J. Neurol. Neurosurg. Psychiat.* 39: 471-480.
- Sunderland, S. (1978) *Nerves and nerve injuries.* E. & S. Livingstone, Edinburgh.
- Sweet, W.H. (1981) Animal models of chronic pain, their possible validation from human experience and posterior rhizotomy and congenital

analgesia. *Pain* 10: 275-295.

- Szolcsanyi, J. (1976) On the specificity of pain-producing and sensory neuron blocking effects of capsaicin. In: Proc. of the 2nd Congress of the Hungarian Pharm. Soc., Akademiai Kiado, Budapest.
- Szolcsanyi, J. and Jansco-Gabor, A. (1975) Relationship between chemical structure and pain-producing potency of pungent agents. *Arzeim - Forsch.* 25: 1877-1881.
- Szolcsanyi, J. and Jansco-Gabor, A. (1976) Sensory effects of capsaicin congeners. II Importance of chemical structure and pungency in desensitizing activity of capsaicin type compounds. *Arzeim-Forsch* 26:33-37.
- Szolcsanyi, J., Jansco-Gabor, A. and Joo, F. (1975) Functional and fine structural characteristics of the sensory neurone blocking effect of capsaicin. *Nauryn - Schmeidebergs Archiv. fur experimentelle Pathologie und Pharmakologie* 287: 157-169.
- Tahmouh, A.J. (1981) Causalgia: redefinition as a clinical pain syndrome. *Pain* 10: 187-197.
- Tasker, R.R. and Dostrovsky, J.O. (1989) Deafferentation and Central Pain. Chapter 9 In: *Textbook of Pain*. Wall, P.D. and Melzack, R. (Eds.) Churchill Livingstone, Edinburgh. pp 154-180.
- Taxi, J. (1959) Etude au microscope electronique de la regenerescence Wallerienne des fibres nerveuses amyeliniques. *C.R.S. Acad. Sci. D.* 248: 2796-2798.
- Tennyson, V.M. (1970) The fine structure of the axon and growth cone of the dorsal root neuroblast of the rabbit embryo. *J.Cell Biol.* 44: 62-79
- Till, R. and Banks, P. (1976) Pharmacological and ultrastructural studies on the electron-dense cores of the vesicles that accumulate in noradrenergic axons constricted in vitro. *Neuroscience* 1: 49-55.
- Thomas, P.K. and Fullerton, P.M. (1963) Nerve fibre size in the carpal tunnel syndrome. *J.Neurol.Neurosurg.Psychiat.* 26: 520-527.
- Thomas, P.K. and Jones, D.G. (1967) The cellular response to nerve injury. 2. Regeneration of the perineurium after nerve section. *J.Anat.* 101: 45-55.
- Thomas, P.K. (1974) Nerve injury. Chapter 3. In: *Essays on the nervous system*. R. Bellairs and E.G. Gray. (Eds.) Clarendon Press, Oxford. pp 44-70.
- Thomas, P.K. (1982) Pain in peripheral neuropathy: clinical and morphological aspects. In: *Abnormal nerves and muscles as impulse generators*. Culp, W.J. and Ochoa, J. (Eds.) Oxford University Press. Oxford.
- Thomas, P.K. and Olsson, Y. (1975) Microscopic anatomy and function of the connective tissue components of peripheral nerve. In: *Peripheral Neuropathy*, Vol. 1. P.J. Dyck, P.K. Thomas and E.H. Lambert. (Eds.) Saunders, Philadelphia.
- Torebjork, H.E. and Hallin, R.G. (1979) Microneurographic studies of peripheral pain mechanisms in man. In: *Advances in Pain Research and Therapy*. Vol 3. J.J. Bonica, J.C. Liebeskind, D.G. Albe-Fessard (Eds.). Raven Press, New York.

- Tranzer, J.P. and Thoenen, H. (1967) Electron microscope localization of 5-OH Dopamine - a new false transmitter. *Experientia (Basel)* 23: 123-124.
- Tranzer, J.P., Thoenen, H., Snipes, R.L. and Richards, J.G. (1969) Recent developments on the ultrastructural aspect of adrenergic nerve endings in various experimental conditions. *Prog. Brain Res.* 31: 33-46.
- Tranzer, J.P. and Richards, J.G. (1976) Ultrastructural cytochemistry of biogenic amines in nervous tissue - methodologic improvements. *J. Histochem. Cytochem.* 24: 1178-1193.
- Tranzer, J.P. and Snipes, R.L. (1968) Fine structural localization of noradrenaline in sympathetic nerve terminals: a critical study on the influence of fixation. *Proc. 4th Europ. Cong. Electr. Microsc.* 519-520.
- Unnerstall, J.R., Kopajtic, T.A. and Kuhar, M.J. (1984) Distribution of alpha2 agonist binding sites in the rat and human central nervous system: analysis of some functional, anatomic correlates of the pharmacologic effects of clonidine and related adrenergic agents. *Brain Res. Rev.* 7: 679-101.
- Van Orden III, L.S., Bloom, F.E., Barnett, R.J. and Giarman, N.J. (1966) Histochemical and functional relationships of catecholamines in adrenergic nerve endings. I. Participation of granular vesicles. *J. Pharmacol. Exp. Ther.* 154: 185-99.
- Walker, A.E. (1942) Relief of pain by mesencephalic tractotomy. *Arch. Neurol. and Psychiat.* 48: 865.
- Wall, P.D. and Devor, M. (1981) The effect of peripheral nerve injury on dorsal root potentials and on transmission of efferent signals into the spinal cord. *Brain Res.* 109(1) 95-111.
- Wall, P.D. and Devor, M. (1982) Consequences of peripheral nerve damage in the spinal cord and intact neighbouring peripheral nerves. Chapter 29. In: *Abnormal nerves and muscles as impulse generators.* W.J. Culp and J. Ochoa (Eds.). Oxford University Press, Oxford. pp 588-606.
- Wall, P.D. and Devor, M. (1983) Sensory afferent impulses originate from dorsal root ganglia as well as from the periphery in normal and nerve injured rats. *Pain* 17: 321-339.
- Wall, P.D., Devor, M., Inbal, R., Scadding, J.W., Schonfield, D., Seltzer, Z and Tomkiewicz, M.M. (1979) Autotomy following peripheral nerve lesions; experimental anaesthesia dolorosa. *Pain* 7: 103-113.
- Wall, P.D. and Gutnick, M. (1974) Ongoing activity in peripheral nerves; the physiology and pharmacology of impulses originating from a neuroma. *Exp. Neurol.* 43: 580-593.
- Wall, P.D., Scadding, J.W. and Tomkiewicz, M.M. (1979) The production and prevention of experimental anaesthesia dolorosa. *Pain* 6: 175-182.
- Wall, P.D. and Sweet, W.H. (1967) Temporary abolition of pain. *Science* 155: 108-109.
- Wall, P.D., Waxman, S. and Basbaum, A.I. (1974) Ongoing activity in peripheral nerve: injury discharge. *Exp. Neurol.* 45: 576-589.
- Wang, J.K., Johnson, K.A. and Itstrup, D.M. (1985) Sympathetic blocks for reflex sympathetic dystrophy. *Pain* 23: 13-17.

- Ward, K.K., Low, P.A., Schmelzer, J.D. and Zochodne, D.W. (1989) Prostacyclin and NA in peripheral nerve of chronic experimental diabetes in rats. *Brain* 112: 197-208.
- Warfield, C.A. (1984) The Sympathetic Dystrophies. *Hospital Practice* 52: C - J.
- Webster, H de F. (1962) Transient focal accumulation of axonal mitochondria during the early stages of Wallerian degeneration. *J.Cell Biol.* 12: 361-383.
- Weisenfeld, Z. and Hallin, R.G. (1980) Stress related pain behaviour in rats with peripheral nerve injury. *Pain* 3: 279-284.
- Weisenfeld, Z. and Lindblom, U. (1980) Behavioural and electrophysiological effects of various types of peripheral nerve lesions in the rat: a comparison of possible models for chronic pain. *Pain* 8: 283-298.
- Weisenfeld-Hallin, Z. (1984) The effects of intrathecal morphine and naltrexone on autotomy in sciatic nerve sectioned rats. *Pain* 18: 267-278.
- Weiss, P. and Hiscoe, H.B. (1948) Experiments on the mechanism of nerve growth. *J. Exp. Zool.* 107: 315.
- Weiss, P.A. (1970) Neuronal dynamics and neuroplasmic flow. In: *The Neurosciences: Second Study Program*, Schmitt, F.O. (Ed.) Rockefeller University Press, New York. pp.840-850.
- Weiss, P. and Pillai, A. (1965) Convection and fate of mitochondria in nerve fibres: axonal flow as a vehicle. *Proc.Nat.Acad.Sci.(Wásh).* 54: 48-56.
- Westrum, I.E., Canfield, R.C. and Black, R.G. (1976) Transganglionic degeneration in the spinal trigeminal nucleus following removal of tooth pulps in adult cats. *Brain Res.* 101: 137-140.
- Wettstein, R. and Sotelo, J.R. (1963) Electron microscope study on the regenerative process of peripheral nerves of mice. *Z. Zellforsch.Mikros.Anat.* 59: 708-730.
- White, J.C. (1930) Diagnostic Novocaine block of the sensory and sympathetic nerves. A method of estimating the results which can be obtained with their permanent interruption. *Amer. J. Surg.* 9: 264-277.
- White, J.C. and Silverstone, B. (1956) Pain and related phenomena. In: *Peripheral Nerve Regeneration*. Ed. by B. Woodhall and G.W. Beebe. V.A. Medical Monograph. U.S. Government Printing Office.
- Williams, P.L. and Wendell-Smith, C.P. (1971) Some additional parametric variations between peripheral nerve fibre populations. *J.Anat.* 109: 505-526.
- Wilson, I. Bamberg, J.R., Mizel, S.B. Grisham, I.M. and Creswell, K.M. (1974) Interaction of drugs with microtubule proteins. *Fed.Proc.* 33: 158-166.
- Wolfe, D.E., Axelrod, J. Potter, I.L.T. and Richardson, K.C. (1962) Localization of tritiated norepinephrine in sympathetic axons by electron-microscope autoradiography. *Science* 138: 440-442.
- Wood, J.G. (1966) Electron microscopic localization of amines in central nervous tissue. *Nature (London)* 209: 1131-1133.
- Wood, J.G. (1975) Use of the analytical electron microscope (AEM) in studies

cytochemical of the central nervous system. *Histochemistry* 41: 233.

- Wood, J.G., Seelig, I.L. and Benjamin, C.P. (1971) Cytochemistry of epinephrine and norepinephrine adrenomedullary cells. *Histochemie* 28: 183-197.
- Wood, J.G. (1974) Positive identification of intracellular biogenic amine reaction product with electron microscope X-Ray analysis. *J. Histochem. Cytochem.* 22: 1060.
- Wood, J.G. and Barrnett, R.J. (1964) Histochemical demonstration of noradrenaline at a fine structural level. *J.Histochem. Cytochem.* 12: 197-209.
- Woods, R.I. (1969) Acrylic aldehyde in sodium dichromate as a fixative for identifying catecholamine storage sites with the electron microscope. *J.Physiol.* 203: 35P.
- Woolf, C.J. and Wall, P.D. (1982) Chronic peripheral nerve section diminishes the primary afferent A-fibre mediated inhibition of rat dorsal horn neurones. *Brain Res.* 242: 77-85.
- Wortis, H., Stein, M.H. and Joliffe, M. (1942) Fibre dissociation in peripheral neuropathy. *Archives of Internal Medicine* 69: 222-237.
- Wynn Parry, C.B. (1988) Update on peripheral nerve injuries. *Int. Disability Studies* 10: 11-20.
- Yaksh, T.L., Farb, D.H., Leeman, S.E. and Jessell, T.M. (1979) Intrathecal capsaicin depletes substance P in the rat spinal cord and produces prolonged thermal analgesia. *Science* 206: 481-483.
- Yamada, K.M., Spooner, B.S. and Wessells, N.K. (1971) Ultrastructure and function of growth cones and axons of cultured nerve cells. *J.Cell Biol.* 49: 614-635.
- Yasumo, W., Nishigori, A. and Yamaguchi, Y. (1984) Facilitatory effects of monoamine on autotomy of rats induced by peripheral nerve section. *Pain Suppl.* 2: 5446.
- Young, J.Z. (1942) The functional repair of nervous tissue. *Physiol. Rev.* 22: 318-374.
- Young, W.S. III, Wamsley, J.K., Zarbin, M.A. and Kuhar, M.J. (1980) Opioid receptors undergo axonal flow. *Science* 210: 76 - 78.
- Zarbin, M.A., Wamsley, J.K. and Kuhar, M.J. (1982) Axonal transport of muscarinic cholinergic receptors in rat vagus nerve : high and low affinity agonist receptors move in opposite directions and differ in nucleotide sensitivity. *J. Neurosci.* 2(7) : 934 - 941.
- Zelena, J., Lubinska, L. and Gutmann, E. (1968) Accumulation of organelles at ends of interrupted axons. *Z. Zellforsch. Mikrosk. Anat.* 91: 200-219.