

Original Article

The Surgical Results in Pure Endoscopic Endonasal Trans-sphenoidal Surgeries in 403 Pituitary Adenomas: An 8-Years of Experience from a Single Neurosurgical Unit

Khalid Mahmood, Muhammad Hassan Raza, Imran Ali, Omair Afzal, Muhammad Ishfaq
Farzana Kausar, Zain Saleh

Department of Neurosurgery, Punjab Institute of Neurosciences, Lahore

ABSTRACT

Objective: Pituitary adenomas have traditionally been approached surgically via the standard transcranial approach for years, but with the success of Endoscopic endonasal trans-sphenoidal approach for these lesion many papers have reported better if not comparable results to the transcranial approach. We aimed to review and report the results in pure endoscopic endonasal trans-sphenoidal surgery done at our unit for pituitary adenomas (PAs) in last 8 years.

Material and Methods: We reviewed 403 consecutive patients who underwent pure endoscopic endonasal trans-sphenoidal surgery for newly diagnosed pituitary adenomas between August 2012 and July 2020 at our neurosurgical unit. Endocrinological, demographic features and outcomes, their complications, and duration of stay in hospital were assessed in these patients who were operated in our neurosurgical Unit. The Mean Follow-up on average was 3.5 months.

Results: 403 consecutive cases were reviewed. Majority of cases were in the 4th decade of life at presentation. 227 (56%) were non-functioning pituitary tumors and 176 (44%) were hormone secreting pituitary adenomas. Thirty-one (7.7%) complications were observed in 28 post-operative patients. The most frequently observed complication was diabetes insipidus (temporary in 19 (5%) and permanent in 3 (0.7%) cases), cerebrospinal fluids leaks (5 cases) (5.7%), Syndrome of inappropriate antidiuretic hormone (1 case) (0.2%), internal carotid injury (1 case) (0.2%), Empty Sella syndrome (1) (0.2%) and post-operative cardiac complication (1 case) (0.2%). The Follow-up on average was 3.5 months.

Conclusions: The pure endoscopic endonasal trans-sphenoidal surgery of pituitary adenomas provides acceptable and reasonable results representing a safe alternative procedure to the traditional Trans-sphenoidal microscopic approach.

Keywords: Endoscopic Endonasal Approach; Pituitary Adenomas; Complication Rates.

Corresponding Author: Muhammad Hassan Raza
Department of Neurosurgery
Punjab Institute of Neurosciences, Lahore
Email: mhraza512@hotmail.com

Date of Submission: 23-11-2020
Date of Revision: 17-12-2020
Date of Online Publishing: 25-12-2020

Date of Print: 30-12-2020

DOI: 10.36552/pjns.v24i4.500

INTRODUCTION

Pituitary adenomas are common benign tumors of the pituitary gland that represent around 10 percent of all intracranial tumors. These tumors

may commonly present with visual deterioration or endocrinological disturbances.¹ Endoscopic endonasal trans-sphenoidal approach has become a cornerstone for the surgical treatment of tumors of the pituitary gland around the globe. Endoscopic endonasal trans-sphenoidal approach is gaining wide acknowledgment as the primary treatment for most pituitary adenomas. The endoscope has revolutionized the treatment of sellar masses including the pituitary tumors due to expanded multi-dimensional view of the surgical field.^{2,3,4,5} The endoscopic endonasal trans-sphenoidal approach to pituitary adenomas provides a better and reasonable alternative as compared to the traditional trans-sphenoidal microscopic approach.^{3,4} Previously these tumors were approached via trans-cranial approach or endonasal microscopic approach.^{6,7,8} Microscopic approach has certain limitations regarding the narrow field of view and issues with depth perception, on the other hand the endoscope provides an unparalleled view of the sellar structures increasing the safety of surgical resection. Giant pituitary tumors pose a challenge to the Endoscopic endonasal trans-sphenoidal approach by pushing the limits of the approach, but favorable outcomes have been reported even in challenging cases.^{9,10}

In our study, we reviewed the data of patients undergoing endoscopic endonasal transsphenoidal excision of pituitary tumors at our neurosurgical unit in the last 8 years, with aim to point out the efficacy, extent of surgical excision and incidence of post-operative complications detailing the results of consecutive 403 cases of pituitary tumors that underwent endoscopic endonasal trans-sphenoidal surgery.

MATERIAL AND METHODS

Study Design

This a retrospective descriptive case series of 403 consecutive cases done during the described 8 years period between August 2012 and July 2020 at our neurosurgical unit. Approval was taken

from office of research affairs. We retrospectively reviewed 403 consecutive cases who underwent endoscopic endonasal trans-sphenoidal surgery for newly diagnosed pituitary adenomas between August 2012 to July 2020 at neurosurgery unit 2, Punjab Institute of Neurosciences, Lahore.

Sample Size

Descriptive case series of 403 consecutive cases.

Inclusion Criteria

All patients requiring surgical excision of pituitary tumors irrespective of age and gender were included.

Exclusion Criteria

Prolactinomas were excluded, which only require medical management. All other endoscopic surgeries performed for Non-pituitary lesions such as Craniopharyngioma, Tuberculum meningiomas, CSF Rhinorrhea, Fungal clearances, Angiofibromas, were not included.

Data Collection

Demographic, endocrinological features and their outcomes, including extent of surgical excision, complications, and duration of hospital stay were observed and assessed in these patients who were operated upon in our unit at the Punjab Institute of Neurosciences.

Data Analysis

Data was statistically analyzed using SPSS 26. Variables were identified. Simple descriptive statistics were used for analysis of demographic variables. Mean and standard deviations were calculated for age, frequencies and percentages were determined for qualitative variables that are gender, post-operative complications, mortality, morbidity and hospital stay.

RESULTS

Collective data of 403 patients who were operated endoscopically for pituitary tumors was included.

Incidence of Age

We distributed patients according to their age into four age groups. 58 (14%) patients were less than 30 years of age. 161 (40%) patients were in 30 to 40 years age group, 107 (27%) patients were in 41 to 50 years age group, 77 (19%) patients were more than 50 years of age. Majority of our patients were in the 4th decade of their life at the time of presentation.

Table 1: Age Range.

Age	Number	Percentage
< 30 years	58	14%
30 – 40 years	161	40%
41 – 50 years	107	27%
> 50 years	77	19%
Total	403	100%

Gender Incidence

There were 218 (54.1%) females and 185 (45.9%) males.

Table 2: Gender Distribution.

Sex	Number	Percentage
Male	185	45.9%
Female	218	54.1%
Total	403	100%

Table 3: Type of Tumor.

Type	Number	Percentage
Hormone producing	176	44%
Non-fundomal	227	56%
Total	403	100%

Clinical Features

After admission, all these patients underwent hormonal assessment (clinical and biochemical) with the help of an endocrinologist. All patients underwent pre-operative visual acuity testing and visual field assessment. Majority of the patients presented with visual field defects. Of the 403 patients reviewed, 176 (44%) had hormone producing tumors that was evident on hormonal assessment of these patients. 227 (56%) patients of our series presented with non-functional tumors with a normal hormonal profile and visual deterioration. Majority of the cases had bitemporal hemianopia during visual field assessment. Computed tomographic scan with functional endoscopic sinus surgery protocol was done routinely to review the endonasal anatomy and confirm the approach. All the patients after getting fitness for general anesthesia and undertaking informed consent underwent G/A. Endoscopic endonasal transsphenoidal binarial approach was employed.

Surgical Approach

Middle turbinectomy was done and naso-septal flap harvested and saved. Mucosa was removed over the keel and bone drilled. Floor of sella was drilled and dura exposed, opened in cruciate fashion. Tumors were debulked initially from lower end and then the upper end. Then the tumor capsule was removed while keeping arachnoid intact.

Extent of Resection

Gross total resection was achieved in 204 (50.6%) cases, near total resection in 146 (36.2%) cases, subtotal resection in 52 (13%) cases and only biopsy was possible in 1 (0.2%) case.

Table 4: Extent of Tumor Resection.

Tumor Resection	Number	Percentage
Gross total	204	50.6%
Near total	146	36.2%
Subtotal	52	13%
Biopsy only	1	0.2%
Total	403	100%

Complications

A total of 31 (7.7%) complications was noted in 28 patients post-operatively. The most frequent complication was diabetes insipidus that was temporary in 19 (5%) cases and 3 (0.7%) patients developed permanent diabetes requiring

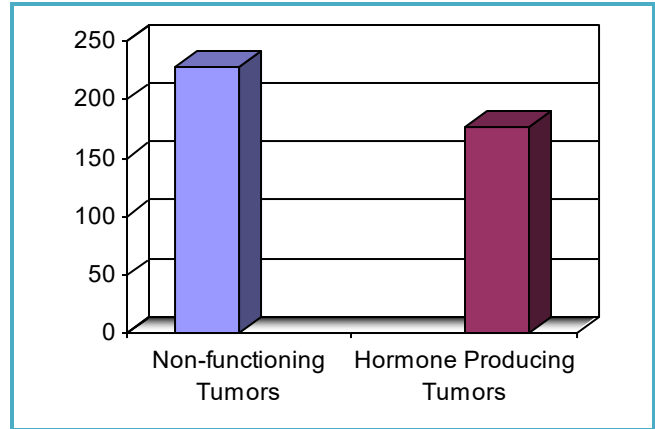


Figure 1: Functional status.

pharmacological therapy. 5 (1.2%) patients developed post-operative CSF rhinorrhea. One (0.2%) patient developed syndrome of inappropriate anti-diuretic hormone. One (0.2%) case had an intraoperative internal carotid injury, one developed an empty Sella syndrome and 1 (0.2%) case had post-operative anesthesia related cardiac complications. A total of 4 (0.9%) patients died from these complications in our series, one (0.2%) from carotid injury, one (0.2%) from cardiac complications and two (9.4%) from meningitis. Patients were followed post-operatively on outdoor basis for periods ranging from 1 to 7 months with an average of 3.5 months. A contrast magnetic resonance imaging was performed at 6 weeks post-op to check the extent of resection.

Table 5: Complications.

Complication	Number	Percentage	Outcome
Dj*			
Temporary	19	5%	19 recovery in 3 months
Permanent	3	0.7%	Permanent 3
CSF Rhinorrhea	5	1.3%	2 dead 3 recovered
SAIDH	1	0.2	Stable the sella
ICA Injury	1	0.2	1 Death
Empty sella syndrome	1	0.2	Partial recovery by with medication repatching
Anesthesia related cardiac arrest	1	0.2	1 Death
Total	31	7.7%	

DI: Diabetes Insipidus

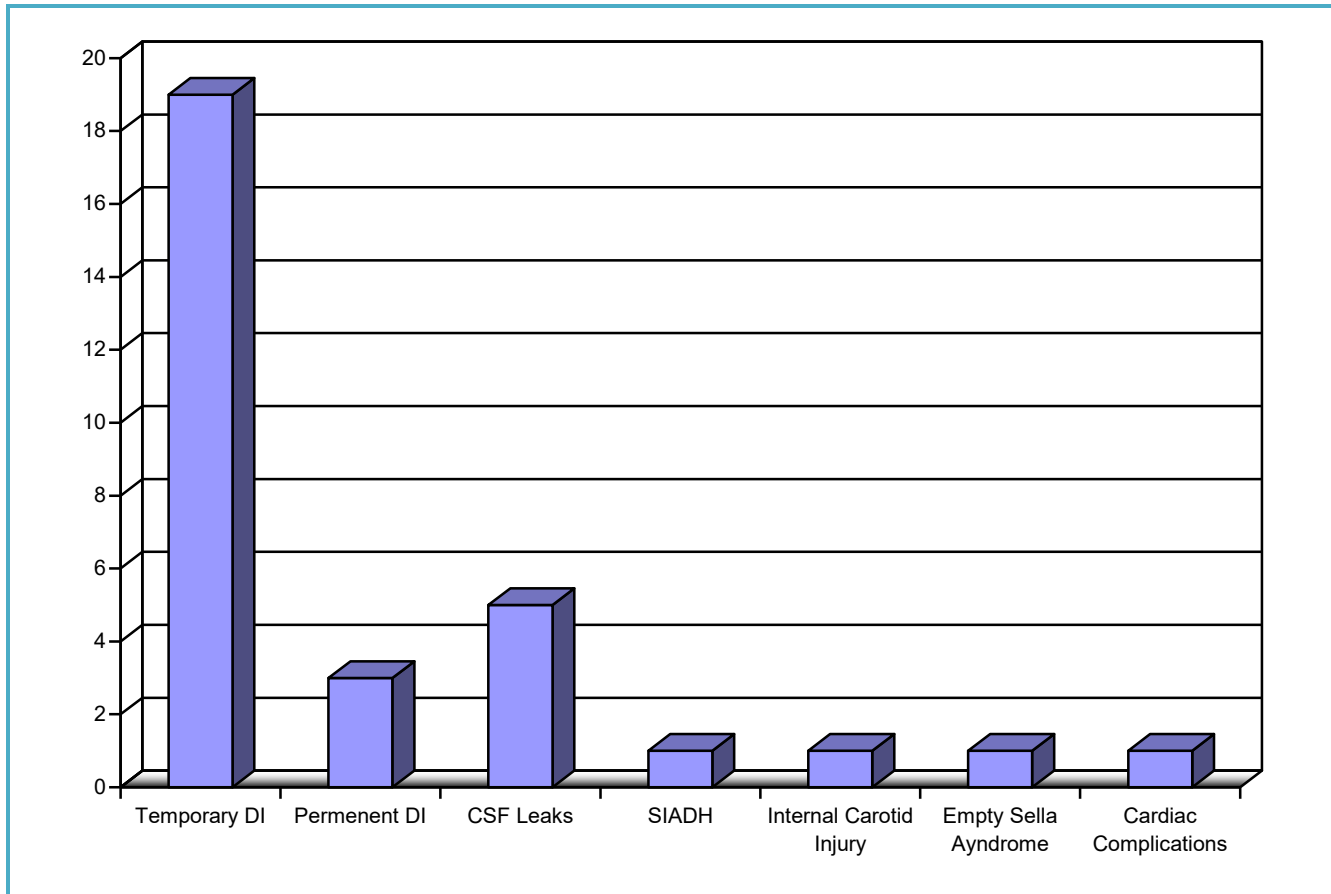


Figure 2: Post-operative complications.

DISCUSSION

Over the years, endoscopic endonasal transsphenoidal surgery has shown application within the treatment of pituitary pathologies. The endoscopic endonasal approach provides enhanced vision and better result with less nasal injuries in comparison to the microsurgical approach. Endoscopic transsphenoidal resection in pituitary adenomas is safe and effective compared to the conventional microscopic approach. The endoscopic transsphenoidal approach provides a panoramic view of the surgical area and enhanced working angle and less nasal cavity injury.^{8,11}

Ours is a busy neurosurgical center where we routinely do endoscopic endonasal trans-sphenoidal surgery due to high patient referral from all over the country. Only in the last year,

our data showed that 81 Endoscopic endonasal trans-sphenoidal surgeries were performed.

In this study, we detail our experience of endonasal endoscopic transsphenoidal excision using a binarial approach in 403 pituitary tumor cases.

In our study, 56% patients had nonfunctioning pituitary adenomas (227 cases) and 44% had hormone secreting adenomas (176 cases). Dixit et al. reported 80% non-secreting and 20% secreting adenomas.¹² While, Wang et al in their series reported 49.5% patients with non-secreting adenomas and 50.5% with secretory adenomas.¹¹

Dixit et al showed that gross total resection was possible in 60% of their cases, while subtotal resection could be achieved in 26.66% of cases and only the partial reduction was possible in 13.66% of their cases.¹² In our series, in 50.6%

cases gross total resection was achieved (204 cases) while near total resection was reported in 36.22% (146 cases), and subtotal resection in 12.90% (52 cases) and only biopsy was possible in 0.25% cases (1 case).

In our series 5.28% patients developed diabetes insipidus that was temporary, and 0.7% patients developed diabetes Insipidus that remained permanent. 1.39% patients had CSF rhinorrhea post-operatively, and one case each developed syndrome of in appropriate anti-diuretic hormone, internal carotid injury, empty sella syndrome and cardiac complications.

Dixit, et al in their series showed 13.33% patients developed diabetes insipidus. 13.33% had CSF rhinorrhea post-operatively, 3.33% had meningitis and one 3.33% had intraventricular hemorrhage and reported 1 death.¹² Wang et al. reported temporary diabetes insipidus in 6.35% and diabetes insipidus that was permanent in 0.69% cases.¹¹ In one study, Nishioka reported CSF rhinorrhea incidence in endoscopic pituitary surgery between 0.7 to 12%.¹³

Four patients died in our series from the above complications. One patient died due to internal carotid injury, one died of cardiac complications and 2 patients died of meningitis post-operatively. Our mortality was at 1.11%. Nishioka reported mortality of less than 1%.¹³ Rocha et al. reported a higher mortality of 7.1% in their series.¹⁴

CONCLUSION

The purely endoscopic endonasal binarial trans-sphenoidal surgery for pituitary adenomas provides reasonable, acceptable results in terms of extent of surgical excision and post-operative complications providing a safe and effective alternative to the trans-sphenoidal microscopic approach and transcranial approach.

REFERENCES

1. Sun G, Cao Y, Jiang N, et al. Binostril endoscopic transsphenoidal neurosurgery for pituitary adenomas: experience with 42 patients. *Oncotarget*. 2017; 8 (40): 69020-69024. doi:10.18632/oncotarget.16976
2. Guiot J, Rougerie J, Fourestier M, Fournier A, Comoy C, Vulmiere J et al. [Intracranial endoscopic explorations]. *Presse Med*. 1963; 71: 1225-8. French.
3. Xue-Fei S, Yong-Fei W, Shi-Qi L, Jing-Song W, Yao Z, Ying M et al. Microsurgical treatment for giant and irregular pituitary adenomas in a series of 54 consecutive patients. *Br J Neurosurg*. 2008; 22 (5): 636-48. doi:10.1080/02688690802346083
4. Berker M, Hazer DB, Yücel T, Gürlek A, Cila A, Aldur M, et al. Complications of endoscopic surgery of the pituitary adenomas: analysis of 570 patients and review of the literature. *Pituitary*, 2012; 15 (3): 288-300. doi:10.1007/s11102-011-0368-2
5. Santos RP, Zymberg ST, Abucham Filho JZ, Gregório LC, Weckx LLM. Endoscopic transnasal approach to sellar tumors. *Rev Bras Otorrinolaringol*. 2007; 73 (4): 463-75. doi:10.1590/S0034-72992007000400005
6. Komotar RJ, Starke RM, Raper DM, Anand VK, Schwartz TH. Endoscopic endonasal compared with microscopic transsphenoidal and open transcranial resection of giant pituitary adenomas. *Pituitary*, 2012; 15 (2): 150-9. doi:10.1007/s11102-011-0359-3
7. Cecenarro LA, Rodrigo Fanton ET, Estario P, Papalini RF, Estario ME. Pituitary tumors: 10 years of experience. *Rev FacCien Med Univ Nac Cordoba*. 2015; 72: 32-38.
8. Singh H, Essayed WI, Cohen-Gadol A, Zada G and Schwartz TH. Resection of pituitary tumors: endoscopic versus microscopic. *J Neurooncol*. 2016; 130: 309.
9. Constantino, Edson & Leal, Rafael & Ferreira, Christian & Acioly, Marcus & Landeiro, José. Surgical outcomes of the endoscopic endonasal transsphenoidal approach for large and giant pituitary adenomas: Institutional experience with special attention to approach-related complications. *Arquivos de Neuro-Psiquiatria*. 2016; 74: 388-395. 10.1590/0004-282X20160042.

10. Cappabianca P, Cavallo LM, de Divitiis O, de Angelis M, Chiaramonte C, Solari D. Endoscopic Endonasal Extended Approaches for the Management of Large Pituitary Adenomas. *Neurosurg Clin N Am.* 2015; 26: 323-331.
11. Wang F, Zhou T, Wei S, Meng X, Zhang J, Hou Y and Sun G. Endoscopic endonasal transsphenoidal surgery of 1,166 pituitary adenomas. *Surgical Endoscopy*, 2015; 29 (6): 1270–1280.
12. Dixit, Sourabh & Samanta, Nirmalya & Saha, Suniti & Roy, Kaushik & Ghosh, Partha & Bachchan, Abta. A study assessing the outcome of endoscopic endonasal transsphenoidal excision of pituitary adenoma at a tertiary care institutions- An Initial experience of 30 cases. *Asian Journal of Medical Sciences*, 2018; 10: 53-60. Doi:10.3126/ajms.v10i1.21021.
13. Nishioka H. Recent Evolution of Endoscopic Endonasal Surgery for Treatment of Pituitary Adenomas. *Neurologia Medico Chirurgica.* 2017; 57 (4): 151–158.
14. Rocha CE, Rafael L, Cândido FC, André AM and Alberto LJ. Surgical outcomes of the endoscopic endonasal transsphenoidal approach for large and giant pituitary adenomas: institutional experience with special attention to approach-related complications. *Arq Neuro-Psiquiatr.* [Internet]. 2016 May [cited 2018 Sep 28]; 74 (5): 388-395.

Additional Information

Disclosures: Authors report no conflict of interest.

Ethical Review Board Approval: The study was conformed to the ethical review board requirements.

Human Subjects: Consent was obtained by all patients/participants in this study.

Conflicts of Interest:

In compliance with the ICMJE uniform disclosure form, all authors declare the following:

Financial Relationships: All authors have declared that they have no financial relationships at present or within the previous three years with any organizations that might have an interest in the submitted work.

Other Relationships: All authors have declared that there are no other relationships or activities that could appear to have influenced the submitted work.

AUTHORS CONTRIBUTIONS

Sr.#	Author's Full Name	Intellectual Contribution to Paper in Terms of:
1.	Khalid Mahmood	1. Study design and methodology.
2.	Muhammad Hassan Raza	2. Paper writing, referencing, and data calculations.
3.	Imran Ali	3. Data collection and calculations.
4.	Omair Afzal	4. Analysis of data and interpretation of results.
5.	Muhammad Ishfaq	5. Literature review and manuscript writing.
6.	Farzana Kausar	6. Analysis of data and quality insurer.
7.	Zain Saleh	7. Analysis of data and paper writing.