



Received: 2006.09.14
Accepted: 2007.02.12
Published: 2007.04.27

Intraluminal pulsed dose rate (PDR) brachytherapy and trans-hepatic technique in treatment of locally advanced bile duct cancer – preliminary assessment

Janusz Skowronek^{1ABCDEF}, Aleksander Sowier^{2BDE}, Paweł Skrzywanek^{3BDE}

¹ Department of Brachytherapy, Greatpoland Cancer Center, Poznań, Poland

² NZOZ Olympus, Łódź, Poland

³ 1st Surgical Clinic, University of Medical Sciences, Poznań, Poland

Authors' Contribution:

- A** Study Design
- B** Data Collection
- C** Statistical Analysis
- D** Data Interpretation
- E** Manuscript Preparation
- F** Literature Search
- G** Funds Collection

Summary

Background

Treatment options for bile duct cancer remain limited due to the large number of patients with advanced disease at the time of diagnosis. Radical surgery is possible in less than 10–15% of these cases. Unresectable bile duct cancers are very difficult to treat with external beam therapy alone due to the proximity of adjacent normal organs and the high doses required to effectively irradiate these neoplasms. Indications for brachytherapy include all malignant strictures of the bile duct which can be cannulated. Patients should be fit enough for the procedure and should have been reviewed to confirm that they are not suitable for resection. Combined treatment is possible in patients who are in good condition; it is usual to combine bile duct brachytherapy (BT) with external beam radiation therapy (EBRT).

Aim

To assess the feasibility of intraluminal palliative pulsed dose rate brachytherapy (PDR-BT) in the treatment of locally advanced bile duct cancer.

Materials/Methods

Seventeen patients with advanced inoperable bile duct cancer were treated between May 2002 and December 2005 in Greatpoland Cancer Centre. Patients were disqualified from surgery or radical external beam radiation therapy (EBRT). Thirteen patients were treated exclusively with PDR brachytherapy, 4 patients were qualified for combined treatment: PDR brachytherapy and palliative EBRT. Percutaneous trans-hepatic technique was used to implant a catheter into the bile duct. All patients received 25 pulses of 0.8Gy hourly to the total dose of 20Gy. In 4 cases PDR was repeated after one week. Target Volume encompassed tumour visualized at cholangiography and a one or two cm margin taken proximally and distally. Dose was prescribed at 10mm from the source axis. For palliative EBRT 15MV photons were used.

Results

In all 17 cases trans-hepatic technique allowed insertion of the BT catheter into the bile duct and safe application of PDR-BT. In 13/17 (76.5%) cases improvement in jaundice was noted at the first check-up after 4 weeks. Median overall survival time (OS) was 10 months, longest survival time was 36 months, shortest was 2 months. Acute and late complications were not observed.

Conclusions

1. It was established that the use of pulsed dose rate brachytherapy was feasible and had a low early complication rate. A new percutaneous trans-hepatic technique

allowed whole treatment (insertion of catheter, PDR brachytherapy) to be performed in one day. 2. In most cases a satisfactory palliative effect was achieved.

Key words bile duct cancer • palliative • PDR brachytherapy • radiotherapy

Full-text PDF: <http://www.rpor.pl/pdf.php?MAN=10308>

Word count: 3469

Tables: 2

Figures: –

References: 34

Author's address: Janusz Skowronek, Department of Brachytherapy, Greatpoland Cancer Center, Garbary 15 Str., 61-866 Poznań, Poland, e-mail: janusz.skowronek@wco.pl

BACKGROUND

Treatment options for bile duct cancer remain limited due to the large number of patients with advanced disease at the time of diagnosis. Radical surgery is possible in less than 10–15% of these cases [1–4]. Unresectable bile duct cancers are very difficult to treat with external beam therapy alone due to the proximity of adjacent normal organs and high doses required to effectively irradiate these neoplasms [1,5].

Bile duct carcinoma is rare. It accounts for approximately 200 new cases annually in Poland; it makes up less than 4% of gastrointestinal malignancies. The majority of bile duct carcinomas involve the hepatic duct bifurcation, the common hepatic duct, the cystic duct, and the ampulla. The tumour can spread along the sinusoids and neoplastic destruction of normal cholangioles leads to the retention of bile around the margin of the tumour. Tumour emboli in the portal and hepatic veins are common and vascular invasion can occur in up to 90% of cases. The tumour may also metastasize to the lungs, peritoneum and intra-peritoneal organs. The majority of tumours are low-grade cholangiocarcinomas. Patients commonly present with obstructive jaundice. The most important diagnostic procedure is cholangiography. Staging requires ultrasound and CT scans. The only curative treatment is radical surgical excision. However, because of the propensity of cholangiocarcinomas to invade the hepatic artery, portal vein and other vital structures this is only feasible in 10 to 20% of cases and is associated with an operative mortality of 5 to 10% [2,6,7]. Effective palliation is achieved by biliary decompression. This is carried out either surgically by using bypass procedures such as hepaticojejunostomy or nonoperatively by en-

doscopic or percutaneous insertion of biliary endoprotheses [1,8,9].

Indications for brachytherapy include all malignant strictures of the bile duct which can be cannulated. Patients should be fit enough for the procedure and should have been reviewed to confirm that they are not suitable for resection. Combined treatment is possible in patients who are in reasonably good condition; it is usual to combine bile duct brachytherapy (BT) with external beam radiation therapy (EBRT) [5,10–15].

AIM

The purpose of this study was to assess the feasibility of intraluminal PDR brachytherapy (PDR-BT) and trans-hepatic technique of catheter insertion in the treatment of locally advanced bile duct cancer. We decided to irradiate these patients due to the clinical presence of a tumour and due to increase of jaundice. We chose PDR-BT instead of HDR-BT because of the short one-day treatment time which was accepted by the patients and the growing interest in using PDR-BT in treatment of different cancers. In view of the short time of observation and small group of patients we present the preliminary results.

MATERIALS AND METHODS

Patients

Seventeen patients with advanced bile duct cancer were treated using PDR brachytherapy between May 2002 and December 2005 in Greatpoland Cancer Centre. In all cases trans-hepatic technique was used. There were 10 women and 7 men, at median age of 59.8 years, range from 40 to 81. Six patients underwent surgical procedures

Table 1. Patients' characteristics.

Characteristic		Number, rate
Age:	Median	59.8
	Range	40–81
Gender:	Male	7 (41.2%)
	Female	10 (58.8%)
Tumour site:	Perihilar and CHD	12 (70.6%)
	CBD	3
	Diffuse*	2
Pathologic type:	Adenocarcinoma	8
	Cholangiocarcinoma	1
	Carcinoma solidum adenogenes	1
	Lack of diagnosis	7 (41.2%)
Primary/recurrent tumour		11/6
Previous surgery		6

CHD – common hepatic duct; CBD – common bile duct.

* Included patients with >2 sites of extrahepatic biliary ducts.

(prior cholecystectomy) before being referred for brachytherapy. In four a palliative surgical procedure such as biliodigestive anastomosis had been performed. In twelve patients a stent or endoprosthesis was placed. All patients referred for brachytherapy were regarded by surgeons as no further operable. All of them had been symptomatic with jaundice, eleven suffered from pain in the upper abdomen, seven from anorexia and nausea and in fifteen patients rapid weight loss (up to 15 kg in 2–3 months) had occurred. Histological confirmation of *adenocarcinoma* was obtained in 10 cases: in 8 cases *adenocarcinoma*, in 1 case *cholangiocarcinoma* and in 1 case *carcinoma solidum adenogenes* were diagnosed. In the remaining cases we did not obtain histological material for diagnosis. The diagnosis of cancer was established by radiographic, endoscopic and other clinical evidence. Most of the tumours were located in the perihilar and common hepatic duct (CHD) – 12/17 (70.6%). Summarized clinical data are presented in Table 1.

Method of treatment

Brachytherapy was started on the same day after insertion of the intraductal catheter. Cholangiography was performed to compare current status with earlier X-ray films. Treatment planning was based on radiography taken with the applicator in place and the cholangiogram showing the malignant stenosis (Figures 1, 2). Cases with stents inserted previously are present-

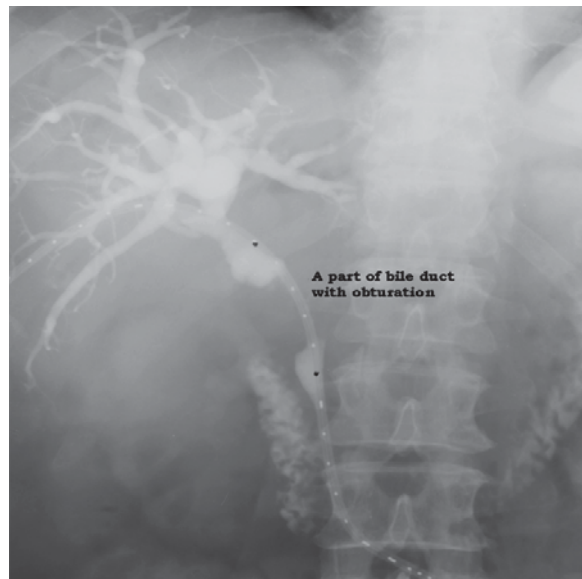


Figure 1. Bile duct cancer, bile ducts visible after cholangiography, obturated part visible as a break, 5 French brachytherapy catheter with radio-opaque wire inside, irradiated length 5cm (between black points).

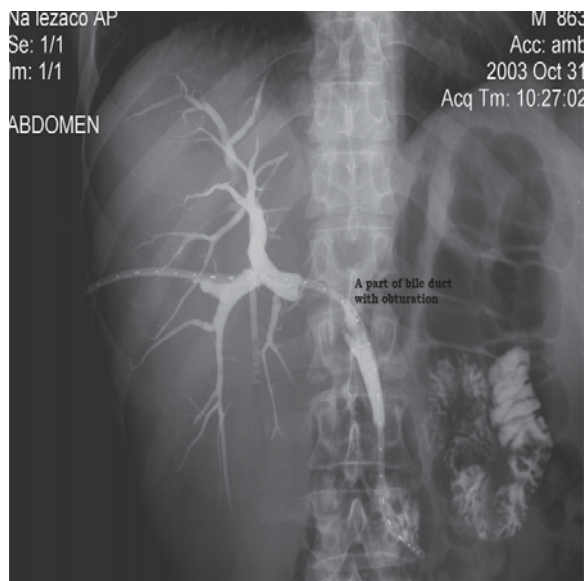


Figure 2. A different patient than in Figure 1, bile duct cancer, bile ducts visible after cholangiography, obturated part visible as a break, 5 French brachytherapy catheter with radio-opaque wire inside, irradiated length 6cm (4cm of obturation and a margin of 1cm distally and proximally).

ed in Figures 3 and 4. The radio-opaque wire had markers at intervals which indicated the placement of the radioactive source. An X-ray unit, the IBU (Integrated Brachytherapy Unit), was used for 3D planning. Target Volume encompassed tumour visualized at cholangiography and a 1 or 2cm margin taken proximally and distally. The

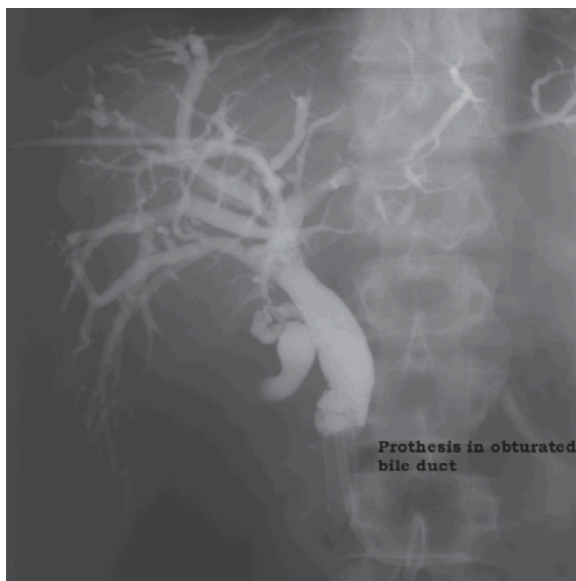

Figure 3. Bile duct cancer with recurrence after insertion of prosthesis, bile ducts visible after cholangiography, obturated part visible as a break

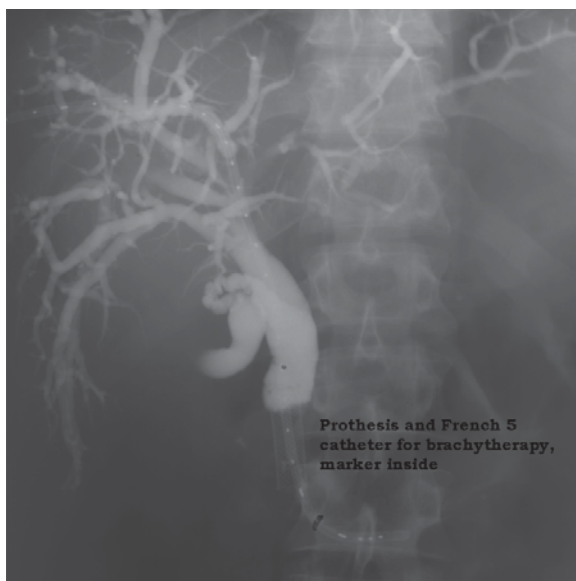


Figure 4. Bile duct cancer with recurrence after insertion of prosthesis, bile ducts visible after cholangiography, obturated part visible as a break, French 5 brachytherapy catheter with radio-opaque wire inside, irradiated length 5cm (3cm of obturation and a margin of 1 cm distally and proximally).

radiation dose was prescribed at 10mm from the source axis. The length of the reference isodose encompassed the planning target length as closely as possible. PLATO brachytherapy planning system was used. Treatment plan for EBRT was prepared with 3-dimensional treatment planning system (CadPlan®); 15MV photons were used. For PDR brachytherapy a microSelectron

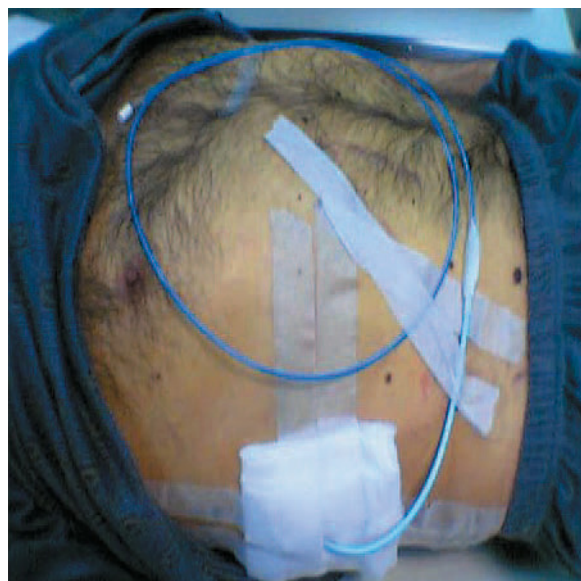

Figure 5. Photo of a patient with a 10F catheter inserted using trans-hepatic technique in the bile ducts, a 5 French catheter for brachytherapy (dark blue colour) inside.

PDR (Nucletron®) unit was used, with radioactive source ^{192}Ir Iridium, with 1Ci (Curie) nominal activity. A 5 French intraluminal catheter was attached to a remote afterloading machine which was given pulses of PDR-BT.

Thirteen patients were treated exclusively with PDR brachytherapy. PDR brachytherapy was chosen as the method of treatment because of the relatively good performance status of all patients and for shortening of the overall treatment time [16]. They received one fraction of 25 pulses, 0.8Gy hourly up to 20Gy total dose. Four patients received two PDR fractions of 20Gy with a 1-week interval because of rapid regression of jaundice and satisfied relief of pain. Four patients with reasonably good performance status and with relative large tumour thickness were qualified for combined palliative treatment (PDR brachytherapy and external beam radiation therapy). A dose of 40Gy was delivered to a volume which encompassed the porta hepatis, the common bile duct and regional nodes.

Trans-hepatic technique

There are two techniques commonly used in brachytherapy treatment of advanced bile duct carcinoma nowadays. The first is trans-duodenal endoscopic technique, the second trans-hepatic technique. Percutaneous trans-hepatic technique allows the passage of a catheter through the stricture. A transhepatic cholangiogram is initially

performed under fluoroscopic control; in patients who have undergone a surgical procedure, the cholangiogram can be performed through the T-tube. After the site of obstruction is identified, a flexible catheter is inserted into the biliary tree to an appropriate depth, under fluoroscopic control. To avoid the catheter changing procedure, we used a 10 French catheter, which could also be used as a conduit to place the brachytherapy catheter, thus facilitating the procedure for both team and patient (Figure 5). A dual-lumen catheter or two separate catheters can be inserted in another technique, one for lodging the radioactive sources and the other for bile drainage. Special care must be taken to maintain biliary drainage. Otherwise, the patient will develop pain and fever as a result of obstructive cholangitis. The catheter is sutured to the skin.

RESULTS

All patients had an unfavourable prognosis. In all 17 cases trans-hepatic technique allowed correct insertion of a BT catheter and safe use of PDR-BT. Complications connected with the technique were not observed. In 13/17 cases (76.5%) improvement (complete or partial remission) in grade of jaundice was assessed within 4 weeks after brachytherapy. In two cases we noted lack of remission, in two other cases deterioration. Decline in performance status was observed during the course of brachytherapy in one patient with metastasis in the liver, which did not end the treatment, and in a second when 4 weeks after the end of treatment we noted massive progression in the liver. Median overall survival time (OS) was out 10 months, longest survival time 36 months, and the shortest 2 months. These results refer to 11 patients who were under regular observation in the Brachytherapy Department. Acute and late complications were not observed. Due to the small number of patients in this pilot study, these results do not reach the level of significance.

DISCUSSION

The vast majority of bile duct tumours are diagnosed late, with upper abdominal discomfort, general malaise, fever, anorexia and jaundice. Tumours of the bile duct are much less common than hepatocellular carcinoma and the aetiology is unknown. Prognosis is poor and related to the extent of spread within the liver and regional lymph nodes and to the site of tumour [1]. Most bile duct cancer patients are treated palliatively.

The role of radiotherapy in this disease has long been debated. Since the majority of patients die from uncontrolled locoregional disease, postoperative adjuvant radiotherapy has been used at several centres [4,5,17-19]. Until the mid-1970s *cholangiocarcinoma* was considered to be radioresistant. There were several reasons for this. Firstly, cholangiocarcinomas were considered intrinsically radioresistant. Secondly, the technical problem of delivering radical radiation without damaging the intestine or liver was formidable. Before the advent of radiological techniques for decompression of the obstructed biliary tract most patients were in poor general condition and treatment was not attempted. However, during the second half of the 1970s a few published reports indicated that radiotherapy could provide useful palliation and possibly improve survival for patients with *cholangiocarcinoma*. Several reports then indicated that radiotherapy could provide useful palliation [12,17]. In some cases external beam radiotherapy (EBRT) was thought to have contributed to prolongation of survival [14,19,20]. Kopelson et al. reported that obstructive jaundice was relieved in 7 of 8 patients treated for extrahepatic bile duct cancer with EBRT [17]. Hanna and Rider retrospectively reviewed 17 patients treated at the Princess Margaret Hospital, Toronto [14]. Fourteen patients who received radiotherapy had a mean survival of 12.3 months compared with 1.1 months for those who did not.

In the 1980s, intraluminal brachytherapy for *cholangiocarcinoma* was introduced and inspired considerable enthusiasm. Since most *cholangiocarcinomas* remain localised until a relatively late stage in their natural history, the ability to give a high radiation dose to the tumour without jeopardising adjacent radiosensitive structures was attractive. The ease with which a radioactive source could be placed via transhepatic catheters was a further spur to developing the technique. The increasing use of percutaneous transhepatic catheters by interventional radiologists provided a means by which brachytherapy could be given. A ^{192}Ir wire could be inserted through these catheters. Such treatment has also been given by insertion of a ^{192}Ir wire through an endoscopically placed nasobiliary catheter [21]. Several centres have reported their results using intraluminal brachytherapy alone or in combination with EBRT [5,11,15,18,22-24]. It was difficult to separate the effect of biliary decompression on survival from that of radiotherapy. The median survival for this procedure is 10 to 12 months and

approximately 15% of patients survive for 2 years or more. Late effects of treatment are often difficult to distinguish from symptoms due to recurrence or blockage of the biliary drain. Blockage of the stent or biliary drain is fairly common and it may need to be replaced every 3 to 4 months. Others have reported improvement in survival using this technique.

In 1984 a protocol for treating advanced cholangiocarcinoma using both EBRT and BT was introduced at Hammersmith Hospital [25]. An accelerated split course of EBRT was used. This allowed a reduction in overall treatment time (4 compared with 5 weeks for conventional fractionation) without concomitant reduction in total radiation dose. Reduction of overall treatment time diminishes the opportunity for tumour cell repopulation during treatment, and therefore increases the probability of tumour control for a given dose. The fraction size used in the accelerated EBRT regimen reported here was either 2.25Gy (pre 1989) or 2.75Gy. The latter was less well tolerated with fewer patients completing the prescribed course of treatment. Large fraction sizes were associated with late radiation morbidity. Karani et al. treated 30 patients with hilar cholangiocarcinoma by BT alone. Mean survival time was 16.8 months and this compared favourably with a mean survival of 8.5 months for patients treated by palliative surgery or stenting only at the same institution [26]. Fields et al. [5] found that eight patients receiving BT in addition to EBRT had a median survival of 15 months compared to 7 months for those receiving EBRT only. Seven patients were treated at Stanford University Medical Center using a combination of EBRT (50.0Gy) and BT (31.0Gy to 60.0Gy) [11]. The mean survival was 15.4 months. Fritz et al. [10] reported the treatment of 30 patients with extrahepatic bile duct cancers using EBRT (30.0 to 45.0Gy) and BT (20.0 to 45.0Gy). The median survival was 10 months. Mahe et al. [22] treated 51 patients; 25 received EBRT, 8 BT and 17 both EBRT and BT. Median survival for the whole group was 12 months. Radiotherapy was associated with significant prolongation of survival in patients undergoing palliative stenting; actuarial 1-year survival of those receiving radiotherapy was 38% compared to 9% in those in whom radiotherapy was not given. In none of these series were patients randomised to receive radiotherapy or not, so the real efficacy of treatment is difficult to estimate. Shin et al. [27] treated 31 patients with inoperable carcinoma of the extrahepatic bile ducts with a combination

of EBRT and BT. Although locoregional recurrence was the most common pattern of failure in both groups, no statistically significant difference was found in the recurrence rates between those who did and did not receive BT (53% for Group 1 vs. 36% for Group 2; $p > 0.05$). However, a prolongation of the median time to tumour recurrence was observed in Group 2 patients (5 months for Group 1 vs. 9 months for Group 2; $p = 0.06$). With a median follow-up of 12 months, the overall actuarial 2-year survival rate for Group 2 patients was significantly better than that for Group 1 patients (0% for Group 1 vs. 21% for Group 2; $p = 0.015$). Schleicher et al. [28] treated 30 patients for extrahepatic proximal bile duct cancer with a schedule consisting of EBRT (median dose 30Gy) and a HDR-BT boost (median dose 40Gy) delivered in four or five fractions. 15 patients in the brachytherapy and nine patients in the non-brachytherapy group received additional low-dose chemotherapy with 5-fluorouracil. The brachytherapy boost dose improved the effect of EBRT by increasing survival from a median of 3.9 months in the non-brachytherapy group to 9.1 months in the brachytherapy group. The effect was obvious in patients receiving a brachytherapy dose above 30Gy, and in those without jaundice at the beginning of radiotherapy ($p < 0.05$). Takamura A. et al. [29] treated 93 patients with unresectable extrahepatic bile duct carcinoma with definitive radiotherapy. The dose of external beam radiotherapy was 50Gy in 25 fractions. Low-dose-rate ^{192}Ir was delivered at a dose of 27–50Gy (mean 39.2). An expandable metallic endoprosthesis was used to establish an internal bile passage. The median survival was 12 months, with a 1-, 3-, and 5-year actuarial survival rate of 50%, 10%, and 4%, respectively. Tumour length, hepatic invasion and distant metastasis significantly affected survival.

Summarized data from published literature are presented in Table 2.

Gastrointestinal bleeding is a complication that others have reported. Johnson et al. [11] found that of 11 patients treated for a variety of malignant causes of biliary obstruction by EBRT and BT, three developed upper gastrointestinal bleeding from duodenitis or frank duodenal ulceration at 4 weeks, 4 months and 7.5 months. The risk of gastrointestinal bleeding may be dose dependent. Fritz et al. [10] found that the frequency of radiogenic ulcers was 23% in patients receiving BT doses of 37.5 to 40.0Gy and 7.6% in those receiving 20.0Gy. Buskirk et al. [3] found 4 of 20

Table 2. Results of combined EBRT and BT - literature review. Regarding the outcome with different treatment schedules, the very inhomogeneous patient groups should be taken into account.

Author	Number of patients	EBRT, dose (Gy)	BT, number of fractions, fraction dose, method	Results of treatment	Statistical analysis
Shin et al. [27]	27	36–55 (median 50.4)	1. No 2. 3×5Gy HDR	1. RR – 53% 2. RR – 36% 1. MDC – 5 months 2. MDC – 9 months 1. OS (2 y) – 0% 2. OS (2 y) – 21%	RR – p>0.05 MDC – p=0.06 OS – p=0.015
Schleicher et al. [28]	30	median 30	1. No 2. median 40Gy, 4–5 fractions, HDR	1. OS – 3.9 months 2. OS – 9.1 months	OS – p<0.05
Eschelmann et al. [30]	11	25–56	15–31Gy LDR	MS – 22.6 months	n.d.
Kamada et al. [31]	145	1. 40–50 2. 40–50	1. No 2. 25Gy LDR	1. MS – 4.3 months 2. MS – 9.3 months	n.d.
Gonzalez Gonzalez et al. [32]	38	1. 44–68 2. 33–47	1. No 2. 22–25Gy LDR	1. MS – 10.5 months 2. MS – 10.5 months	n.s.
Takamura et al. [29]	93	50	27–50Gy (median 39.2) LDR	MS – 12 months	n.d.

In papers of Shin [27], Schleicher [28], Kamada [31] and Gonzalez Gonzalez [32] two different groups are compared.

EBRT – external beam radiotherapy; BT – brachytherapy; HDR – high dose rate brachytherapy; LDR – low dose rate brachytherapy; RR – recurrence rate; MDC – median time to tumour recurrence; OS – overall survival; MS – median survival; n.d. – no data; n.s. – not significant.

patients receiving radiotherapy for either gall bladder cancer or *cholangiocarcinoma* developed gastrointestinal bleeding. Three had received doses of greater than 55.0Gy to the stomach or duodenum. Intestinal obstruction following radiotherapy for *cholangiocarcinoma* has also been reported [33].

These studies were neither randomised nor controlled, and it has not been possible to make a definitive statement about the efficacy of this technique. The contribution of BT to survival in *cholangiocarcinoma* is still uncertain. A randomised controlled trial would require large numbers of patients to demonstrate what is likely to be a subtle effect.

It would be difficult to accrue sufficient numbers because *cholangiocarcinoma* is rare and many patients are treated surgically or are deemed unsuitable for radiotherapy for a variety of reasons. Even those patients who are referred for radiotherapy are a heterogeneous group, having received a variety of different treatments before attendance at the oncology clinic. One potential benefit of BT is that it may prevent encroachment of the tumour into the stent and so the ne-

cessity for frequent stent replacements. However, stent occlusion itself has become less of a problem since the introduction of self-expanding metal stents [9].

The efficacy of BT is still uncertain and controlled, prospective studies are required to address this aspect of radiotherapeutic management of *cholangiocarcinoma*. To test whether the results of radiotherapy for *cholangiocarcinoma* can be improved by the use of synchronous chemotherapy our current protocol consists of combined chemotherapy (5-fluorouracil) and EBRT. This is a strategy that has recently been reported as being well tolerated in a Phase I Eastern Cooperative Oncology Group trial [34].

In our opinion indications for brachytherapy should include all malignant strictures of the bile duct which can be cannulated. Patients should be fit enough for the procedure and should have been reviewed to confirm that they are not suitable for resection or sole radical external beam radiation therapy. In patients who are in reasonably good condition, it is usual to combine bile duct brachytherapy with external beam radiation. Thirty to 40 Gy are delivered to a volume

which encompasses the porta hepatis, the common bile duct and regional nodes. Evaluation for this therapy should be made carefully and individually. HDR brachytherapy allow irradiation on an out-patient basis, which makes treatment more accessible. In turn of relatively good prognosis PDR (LDR) brachytherapy should be taken into consideration. For LDR or PDR irradiation a dose of 15 to 20Gy can be given at 1 cm from the centre of the source axis at a dose rate of 0.6 to 0.8Gy/hr. This is combined with the prior external beam radiation. For HDR brachytherapy, 5Gy per fraction is prescribed at 1 cm from the centre of the catheter and can be given once or twice daily with a minimum of 6 hours between treatments. A total dose of 20Gy in 4 fractions over 2 or 4 days can be given if combined with external beam radiation. If the patient is being treated by brachytherapy alone, 30Gy in 6 fractions over 3 or 6 days may be given [1].

We did not find any other reports on using PDR-BT in treatment of advanced bile duct cancer. Our decision to use this technique was based on earlier results of LDR brachytherapy. Pulsed dose rate (PDR) treatment is a new brachytherapy modality that combines the physical advantages of high-dose-rate (HDR) technology (isodose optimization, planning flexibility, radiation safety) with the radiobiological advantages of low-dose-rate (LDR) brachytherapy (repair advantages) [6]. PDR-BT uses a single stepping source of 15–37GBq (0.5–1Ci) of ¹⁹²Iridium. This produces treatment dose rates of up to about 3Gy per hour which can be delivered (pulsed) each hour, 24 pulses per day. PDR-BT consists of using a stronger radiation source than for LDR brachytherapy and gives a series of short exposures of 10 to 30 minutes in every hour to approximately the same overall total dose as with LDR. Although low-dose-rate (LDR) BT and high-dose-rate (HDR) BT have been applied successfully for a long time in the treatment of bile duct cancer, recent interest in PDR brachytherapy has gradually expanded its application to the management of breast and head and neck cancer, as well as bile duct cancer. From a therapeutic viewpoint, it seems likely that PDR-BT is a safe modality for the treatment of bile duct cancer. Although this study has an inherent flaw because of the retrospective analysis and an insufficient number of patients, our observations do suggest that an approach using PDR-BT has good treatment outcome in patients with inoperable carcinoma of the extrahepatic bile ducts.

CONCLUSIONS

We found that PDR-BT for *cholangiocarcinoma* was feasible. A new percutaneous trans-hepatic technique allowed whole treatment (insertion of catheter, planning, PDR brachytherapy) to be performed in one day. Until recently, however, no conclusive data were available regarding the optimal numbers and size of the fractionation and the total radiation dose in BT for malignant bile duct cancer. This is why we decided to use similar doses as in LDR brachytherapy. We consider the achieved palliative effect satisfactory. We consider that in patients disqualified for radical treatment one-day PDR-BT makes it possible to achieve a palliative effect which earlier only in some cases was achieved pharmacologically. We think that especially in a group of patients with recurrence in stents PDR-BT is a reasonable alternative. Although our technique provided encouraging results with minimal side effects, additional investigation is needed to determine the appropriate time-dose fractionation scheme through systematic clinical trials.

REFERENCES:

1. Gerbaulet A, Potter R, Mazeron J-J (eds): The GEC ESTRO Handbook of Brachytherapy. Bruksela, ESTRO, 2002
2. Baer HU, Stain SC, Dennison AR et al: Improvements in survival by aggressive resections of hilar cholangiocarcinoma. *Ann Surg*, 1993; 217: 20–7
3. Buskirk SJ, Gunderson LL, Adson MA et al: Analysis of failure following curative irradiation of gallbladder and extrahepatic bile duct carcinoma. *Int J Radiat Oncol Biol Phys*, 1984; 10: 2013–23
4. Cameron JL, Pitt HA, Zinner MJ et al: Management of proximal cholangiocarcinomas by surgical resection and radiotherapy. *Am J Surg*, 1990; 159: 91–7
5. Fields JN, Emami B: Carcinoma of the extrahepatic biliary system – results of primary and adjuvant radiotherapy. *Int J Radiat Oncol Biol Phys*, 1987; 13: 331–8
6. Hadjis NS, Blenkharn JI, Alexander N et al: Outcome of radical surgery in hilar cholangiocarcinoma. *Surgery*, 1990; 107: 597–604
7. Nagorney DM, Donohue JH, Faruell MB et al: Outcomes after curative resections of cholangiocarcinoma. *Arch Surg*, 1993; 128: 871–9
8. Adam A, Chetty N, Roddie M et al: Self-expandable stainless steel endoprostheses for treatment of malignant bile duct obstruction. *Am J Radiol*, 1991; 156: 321–5
9. Davids RHE, Groen AK, Rauws EAJ et al: Randomised trial of self-expanding metal stents

- versus polyethylene stents for distal malignant biliary obstruction. *Lancet*, 1992; 340: 1488-92
10. Fritz E, Brambs HJ, Schraube E et al: Combined external beam radiotherapy and intraluminal high dose rate brachytherapy on bile duct carcinomas. *Int J Radiat Oncol Biol Phys*, 1994; 29: 855-61
 11. Johnson DW, Safai C, Goffinet DR: Malignant obstructive jaundice: treatment with external-beam and intracavitary radiotherapy. *Int J Radiat Oncol Biol Phys*, 1985; 11: 411-6
 12. Fogel TD, Weissberg JB: The role of radiation therapy in carcinoma of the extrahepatic bile ducts. *Int J Radiat Oncol Biol Phys*, 1984; 10: 2251-8
 13. Gonzfilez DG, Gerard JR, Maners AW et al: Results of radiation therapy in carcinoma of the proximal bile duct (Klatskin tumor). *Sere Liver Dis*, 1990; 10: 131-41
 14. Hanna SS, Rider WD: Carcinoma of the gallbladder or extrahepatic bile ducts: the role of radiotherapy. *Can Med Assoc J*, 1978; 118: 59-61
 15. Hayes JK, Sapozink MD, Miller FJ: Definitive radiation therapy in bile duct carcinoma. *Int J Radiat Oncol Biol Phys*, 1988; 15: 735-44
 16. Skowronek J, Piotrowski T, Zwierzchowski G: PDR brachytherapy - describing of a method and a review of clinical applications. *Rep Pract Oncol Radiother*, 2001; 4: 197-202
 17. Kopelson G, Harisiadis L, Tretter R, Chang CH: The role of radiation therapy in cancer of the extra-hepatic biliary system: an analysis of 13 patients and a review of the literature of the effectiveness of surgery, chemotherapy and radiotherapy. *Int J Radiat Oncol Biol Phys*, 1977; 2: 883-94
 18. Minsky BD, Wesson MF, Armstrong JG et al: Combined modality therapy of extrahepatic biliary system cancer. *Int J Radiat Oncol Biol Phys*, 1990; 18: 1157-63
 19. Verbeek EC, Van Leeuwen DJ, Van Der Heyde MN, Gonzalez GD: Does additive radiotherapy after hilar resection improve survival of cholangiocarcinoma? An analysis in sixty four patients. *Ann Chirurgie*, 1991; 45: 350-4
 20. Pilepich MJ, Lambert RM: Radiotherapy of carcinomas of the extrahepatic biliary system. *Radiology*, 1978; 127: 767-70
 21. Levitt MD, Laurence BH, Cameron F, Klemp EFB: Transpapillary iridium-192 wire in the treatment of malignant bile duct obstruction. *Gut*, 1988; 29: 149-52
 22. Mahe M, Romestaing R, Talon B et al: Radiation therapy in extrahepatic bile duct carcinoma. *Radiother Oncol*, 1991; 21: 121-27
 23. Molt R, Hopfan S, Watson RC et al: Intraluminal radiation therapy in the management of malignant biliary obstruction. *Cancer*, 1986; 57: 536-44
 24. Mornex F, Ardiet JM, Bret E, Gerard JE: Radiotherapy of high bile duct carcinoma using intracatheter iridium 192 wire. *Cancer*, 1984; 54: 2069-73
 25. Peters LJ, Ang KK: Accelerated fractionation. In: Withers HR, Peters LJ (eds). *Innovations in Radiation Oncology*. Berlin, Springer Verlag; 231-8
 26. Karani J, Fletcher M, Brinkley D et al: Internal biliary drainage and local radiotherapy with iridium-192 wire in treatment of hilar cholangiocarcinoma. *Clin Radiol*, 1985; 36: 603-6
 27. Shin HS, Seong J, Kim WC et al. Combination of external beam irradiation and high-dose-rate intraluminal brachytherapy for inoperable carcinoma of the extrahepatic bile ducts. *Int J Radiat Oncol Biol Phys*, 2003; 57: 105-12
 28. Schleicher UM, Staatz G, Alzen G, Andreopoulos D: Combined External Beam and Intraluminal Radiotherapy for Irresectable Klatskin Tumors. *Strahlenther Onkol*, 2002; 178: 682-7
 29. Takamura A, Saito H, Kamada T et al: Intraluminal low-dose-rate ¹⁹²Ir brachytherapy combined with external beam radiotherapy and biliary stenting for unresectable extrahepatic bile duct carcinoma. *Int J Radiat Oncol Biol Phys*, 2003; 57: 1357-65
 30. Eschelmann DJ, Shapiro MJ, Bonn J et al: Malignant biliary duct obstruction: long-term experience with Gianturco stents and combined-modality radiation therapy. *Radiology*, 1996; 200: 717-24
 31. Kamada T, Saitou H, Takamura A et al: The role of radiotherapy in the management of extrahepatic bile duct cancer: an analysis of 145 consecutive patients treated with intraluminal and/or external beam radiotherapy. *Int J Radiat Oncol Biol Phys*, 1996; 34: 767-74
 32. Gonzalez Gonzalez D, Gouma DJ, Rauws EAJ et al: Role of radiotherapy, in particular intraluminal brachytherapy, in the treatment of proximal bile duct carcinoma. *Ann Oncol*, 1999; 10: 215-20
 33. Mogavero GT, Jones B, Cameron JL, Coleman J: Gastric and duodenal obstruction in patients with cholangiocarcinoma in the porta hepatis: increased prevalence after radiation therapy. *Am Radiol*, 1992; 159: 1001-3
 34. Whittington R, Neuberg D, Tester WJ et al: Protracted intravenous fluorouracil infusion with radiation therapy in the management of localized pancreaticobiliary carcinoma: a Phase I Eastern Cooperative Oncology Group Trial. *J Clin Oncol*, 1995; 13: 227-32