

This is a provisional PDF only. Copyedited and fully formatted version will be made available soon.



ISSN: 0015-5659

e-ISSN: 1644-3284

Two cases of combined anatomical variations: maxillofacial trunk, vertebral, posterior communicating and anterior cerebral atresia, linguofacial and labiomental trunks

Authors: M. C. Rusu, A. M. Jianu, M. D. Monea, A. C. Ilie

DOI: 10.5603/FM.a2021.0007

Article type: Case report

Submitted: 2020-11-28

Accepted: 2021-01-08

Published online: 2021-01-29

This article has been peer reviewed and published immediately upon acceptance. It is an open access article, which means that it can be downloaded, printed, and distributed freely, provided the work is properly cited. Articles in "Folia Morphologica" are listed in PubMed.

Two cases of combined anatomical variations: maxillofacial trunk, vertebral, posterior communicating and anterior cerebral atresia, linguofacial and labiomental trunks

M.C. Rusu et al., The maxillofacial trunk

M.C. Rusu¹, A.M. Jianu², M.D. Monea², A.C. Ilie³

¹Division of Anatomy, Faculty of Dental Medicine, “Carol Davila” University of Medicine and Pharmacy, Bucharest, Romania

²Department of Anatomy, Faculty of Medicine, “Victor Babeş” University of Medicine and Pharmacy, Timișoara, Romania

³Department of Functional Sciences, Discipline of Public Health, Faculty of Medicine, “Victor Babes” University of Medicine and Pharmacy, Timisoara, Romania

Address for correspondence: M.C. Rusu, MD, PhD (Med.), PhD (Biol.), Dr. Hab., Prof., Division of Anatomy, Faculty of Dental Medicine, “Carol Davila” University of Medicine and Pharmacy, 8 Eroilor Sanitari Blvd., RO-76241, Bucharest, Romania, , tel: +40722363705
e-mail: mugurel.rusu@umfcd.ro

ABSTRACT

Background: Commonly, arterial anatomic variants are reported as single entities. However, different such variants can occur in a single patient.

Materials and methods: During a retrospective study of computed tomography angiograms of 52 adult patients, two cases were found with unilateral maxillofacial trunks. In each case different other anatomic variants were documented.

Results: The maxillofacial trunk in the first case was associated with bilateral posterior kinks of the internal carotid artery which passed beyond the transverse processes of the atlas vertebra and indented and displaced the internal jugular veins. Common carotid origins of the superior thyroid arteries were found, as well as a high origin of the contralateral facial artery. In the second case a plethora of variants were associated with a unilateral maxillofacial trunk: (1) direct occipital-vertebral arterial anastomosis; (2) ipsilateral atresia of the distal vertebral

artery and of the A1 segment of the anterior cerebral artery; (3) bilateral atresia of posterior communicating arteries; (4) linguofacial and labiomenal trunks; (5) terminal trifurcation of the external carotid artery.

Conclusions: The arterial anatomical variants of the head and neck should be carefully documented prior to specific surgical and interventional procedures, as well as for understanding the compensatory anatomical pathways of circulatory insufficiencies.

Key words: vertebral artery, carotid artery, circle of Willis, maxillary artery, facial artery

INTRODUCTION

The external (ECA) and the internal (ICA) carotid arteries are the terminal branches of the common carotid artery (CCA), leaving it in the carotid triangle of neck [32], typically at the level of the upper border of the thyroid cartilage.

The ECA further sends off its collateral branches: the superior thyroid artery (StA), lingual artery (LA), facial artery (FA), ascending pharyngeal artery (APA), occipital artery (OA) and posterior auricular artery (PAA). Commonly, the ECA divides terminally into the maxillary (MA) and superficial temporal (STA) arteries. Rarely, the ECA could trifurcate terminally, the third added branch being either the middle meningeal artery (MMA), or the transverse facial artery (TFA) [31].

Different common trunks could result after the fusion of the ECA branches, such as the thyrolingual, linguofacial and thyrolinguofacial trunks [4,20]. The maxillofacial trunk (MFT) is an extraordinary arterial variation in man [28]. Although few authors were quoted by Pretterklieber et al for listing this last arterial variation, they did not provide supportive evidence [4,15]. In the online “Illustrated Encyclopedia of Human Anatomic Variation” Bergman, Afifi and Miyauchi documented that the origin of the MA is constant and very rarely it leaves the FA to course upwards into the infratemporal fossa [3].

The posterior cerebral circulation is supplied by the vertebrobasilar system of arteries. The vertebral arteries (VAs) commonly join in the posterior cranial fossa to form the basilar artery (BA). This later supplies the circle of Willis, as the ICAs also do. Cerebral insufficiencies could result if anatomical variant lead to an incomplete circle of Willis, but they could be compensated by ECA-to-VA anastomoses.

It was therefore aimed at documenting a retrospective lot of CT angiograms for the MFT variant and whether, or not, other anatomic variations are associated with it.

MATERIALS AND METHODS

The anatomic variations reported here were found during a retrospective study of computer tomography angiograms from 52 adult patients, a 68 y.o. female patient (Case #1) and a 57 y.o. male one (Case #2). For the computed tomographic studies an iodine radiocontrast agent (Ultravist 370 mg/ml) was injected in the brachial vein, followed by 20 ml saline medium. The computed tomography was performed with a 32-slice scanner (Siemens Multislice Perspective Scanner), using a 0.6 mm collimation and reconstruction of 0.75 mm thickness with 50% overlap for multiplanar, MIP, and 3D volume rendering technique [31]. The arterial variants were documented with the Horos software. The research was conducted ethically in accordance with The Code of Ethics of the World Medical Association (Declaration of Helsinki). Informed consent for anonymous use of the data with scientific purposes was signed by patients. The manuscript was tacitly approved by the responsible authorities where the work was carried out.

RESULTS

Two of the 52 cases (3.8%) presented each the exceptionally rare arterial variation – unilateral MFT. Moreover, in each case different other rare variations were found and are listed in Table 1.

Case #1 – Left maxillofacial trunk

In this first case, the right CCA bifurcation was posterior to the tip of the greater horn of the hyoid bone, at 1.28 cm deep to the gonial angle (fig.1), at the level of the 3rd cervical vertebra. Prior to its bifurcation the CCA was sending off the StA, which originated above the greater horn of the hyoid bone and coursed inferiorly, over that bone. Immediately as the respective ECA left the carotid bifurcation it gave off from its anterior side the LA of which initial segment was coiled and continued inferiorly towards the greater horn. Above the origin of the LA, at the level of the 2nd cervical vertebra, three major vessels had parapharyngeal posterior kinks, folded into each other: the ECA, ICA and the internal jugular vein (IJV)

(fig.1). These kinks were at 1.78 cm postero-medial to the mandibular ramus, and the kinks of the ICA and IJV were posterior to the frontal plane of the transverse processes of the axis vertebra. From the ECA's posterior kink left a posterior branch – the OA, and an anterior one – the FA. The FA originated at 2.18 cm postero-infero-medially to the mandibular foramen. Then, the FA turned laterally in front of the styloglossus muscle and further descended infero-laterally between the styloglossus and the medial pterygoid to reach the inferior border of the mandible. In that course the FA was placed between the parotid and submandibular glands. Above the anterior loop of the FA was an anterior loop of the ECA which turned laterally also in front of the styloglossus and gave off the PAA. After the PAA emerged the medial side of the ECA it ascended on its inner side. The ECA continued in the retromandibular fossa and bifurcated terminally postero-medial to the mandibular neck into the STA and MA. The MA coursed into the infratemporal fossa deep to the inferior head of the lateral pterygoid muscle.

On the left side (figs.2 and 3) the CCA bifurcated postero-superiorly to the tip of the respective greater horn of the hyoid bone, at the level of the 3rd cervical vertebra. The StA left the anterior side of the CCA, prior to its bifurcation. At 35 mm distally from its origin, the left ECA sent off a posterior branch – the OA, a medial one – the APA, and an anterior one – the LA. Then the ECA continued vertically for another 59 mm, being located antero-medially to a large posterior kink of the ICA which, in turn, was folded into the medial side of the IJV to get posterior to the frontal plane through the transverse process of the 2nd cervical vertebra. The left ECA divided terminally into the STA and MFT at 1.47 cm deep to the gonial angle. The STA initially looped anteriorly in the parapharyngeal space, then it continued posteriorly and passed behind the *os stylo-hiale* to enter the parotid space. At that level the STA gave off the PAA.

The MFT looped anteriorly and then reached laterally the medial pterygoid muscle to bifurcate into an ascending branch – the MA, and a descending one – the FA. The MA ascended posterior to the medial pterygoid muscle, on the medial side of the posterior mandibular border. Above the medial pterygoid muscle the MA reached the inferior head of the lateral pterygoid muscle and continued deep to it with a normal course.

Case #2 – Right maxillofacial trunk

In the second case reported here there were found different unilateral combinations of anatomic variants.

On the left side the CCA had a high terminal bifurcation, which was at mid distance between the greater horn of the hyoid bone and the angle of mandible, at the level of the C3-C4 disc. From that bifurcation left off the StA. From the ECA first left the APA. Then the ECA sent off an anterior linguofacial trunk and the posteriorly directed OA, and continued deep to the gonial angle where it gave off the PAA. Then it passed beneath the tip of the styloid process with a medio-lateral course, to continue lateral to it till it reached the postero-lateral side of the neck of mandible (fig.4). Here it trifurcated terminally into the STA, MA and TFA (fig. 4). The OA continued towards the occipital region where it sent off the descending branch. That branch further continued with a thinned and kinked anastomotic arch which joined the left VA into the intervertebral space between the transverse processes of the 2nd and 3rd cervical vertebrae (fig. 4). The VA was further observed in the posterior cranial fossa and was noticed the aplasia of its distal segment (fig.5). The left VA was not contributing to the BA. Instead, it continued as left posterior inferior cerebellar artery (fig. 5). When the circle of Willis was carefully observed it was also noticed the aplasia of the A1 precommunicating segment of the left anterior cerebral artery (ACA) (fig. 5). The posterior communicating arteries were also absent. Therefore, the respective circle of Willis appeared incompetent.

On the right side the CCA had also a high terminal bifurcation, at the level of the C3-C4 disc. Such as on the opposite side the StA left the CCA bifurcation. Then, from the right ECA were leaving the LA and the OA (fig.6). The LA's initial segment was coiled medially to the initial segments of the ECA and ICA. Then, the ECA divided terminally immediately beneath the gonial angle into an anterior MFT and the STA (fig. 7).

On that side was found an *os cerato-hyale* located beneath the tip of the styloid process (fig. 6). The STA crossed posteriorly that *os cerato-hyale* and continued laterally posterior to the mandibular ramus, crossing it at 1.13 cm above the gonial angle. It sent off the PAA and ascended laterally to the posterior border of the mandibular ramus (fig. 7), behind the masseter muscle, with the superficial temporal vein on its lateral side. The STA gave off the TFA which ascended on masseter at the level of the mandibular notch and coronoid process. The STA continued laterally to the neck of mandible, covered by the superficial part of the parotid gland. It further ascended over the temporomandibular joint and posterior zygomatic root in the temporal region. The STA divided terminally at pterion into the frontal and parietal branches.

The respective right MFT trifurcated at the tip of the *os cerato-hyale* into inferior, middle and superior branches (fig.6). The inferior one was a glandular submandibular artery. The middle one was an ascending MA. The superior one was the FA. The FA initially descended below the inferior border of the mandible then it continued laterally to the body of mandible where it sent off a labiomental trunk (fig.8). The MA had an initial ascending course, first being posterior to the medial pterygoid muscle, then passing through it to reach the *sulcus colli* postero-superior to the mandibular foramen, at the inferior border of the lateral pterygoid muscle. From this level it continued superficially to the lateral pterygoid with a normal antero-superior course, intermingling with veins of the pterygoid plexus (fig.7).

When the right ICA was observed above the skull base (fig. 5) was noticed that the A1 segment of the right ACA was sending the A2 segments of both ACAs. The left pericallosal artery was leaving the A2 segment of the left ACA immediately after this latter originated from the A1 segment of the opposite ACA.

DISCUSSION

The embryonic maxillofacial trunk

During embryogenesis of the pharyngeal system six paired aortic arches develop bilaterally between primitive ventral and dorsal aortae [21]. The dorsal remnants of the first embryonic aortic arch coalesce with the hyoid artery which emerges the second aortic arch to form the hyostapedial artery [31]. From that latter emerge the primitive supraorbital artery and the embryonic maxillofacial trunk [31]. This embryonic trunk will give rise to infraorbital and mandibular branches and ultimately connects to the ECA, which is a derivative of the ventral aortic system [21,31]. Commonly, the embryonic maxillofacial trunk becomes the definitive MA [25]. The primitive FA arises from the ECA and it could be speculated here that if the ECA origin of the FA glides cranially on the primitive maxillofacial trunk, the adult MFT would result. On other hand, if the primitive maxillofacial trunk, which is a dorsal aortic derivative, fuses with the FA bud, and not with the primitive ECA, it could also result the adult MFT. Nevertheless, if the initial segment of the definitive MA fails to insert on the ECA, it could be replaced by the ascending palatine artery from the FA, as documented in [28].

The maxillofacial trunk in human adult

The adult MFT appears as the common trunk of ECA origin of the MA and FA. This is different of the embryonic maxillofacial trunk which is the primordium of the definitive MA. Quain (1844), quoted in [28], was seemingly the first who reported an adult MFT, which was found once in 302 cases [29].

Pretterklieber et al reported a case with bilateral MFTs which were dissected in an 88 y.o. adult male. The MA had, such as in the two cases reported here, two parts: an ascending one, followed by a pterygoid one. Dissections allowed the observation that the ascending part of the MFT-emerged MA ran straight upwards, covered by the posterior margin of the mandibular ramus and by the medial pterygoid muscle; further, the MA pierced that muscle between a tendinous dorsal and a fleshy ventral portion, to continue within the infratemporal fossa. On both sides the pterygoid part of the variant MA coursed deep to the inferior head of the lateral pterygoid muscle. In the present study, while in Case #1 the MA ran deep to the lateral pterygoid muscle, in case #2 it was superficial to the respective muscle.

Different from humans, the MFT is a common phylogenetic trait and is a common finding in lagomorphs with extremely enlarged medial pterygoid and masseter muscles [28]. Therefore, a MFT in man should not be regarded as an atavism but as an ontogenetic adaptation of the arterial anatomy to enlarged masseter and medial pterygoid muscles [28].

The linguofacial trunk

The linguofacial trunk is a well-known possibility of variation in which the LA and FA could emerge from the ECA [12]. The incidence of the linguofacial trunk has been reported being 7% [2], 7.5% [26], 10% [5], 18% [20], 20% [7,40], or 21% [24].

The labiomentental trunk

The anatomy of the FA was recently reviewed, being documented that the inferior labial a. it either branches at the cheilion and courses long the vermilion border of the inferior lip, or it branches below the cheilion and courses along the labiomentental crease as an horizontal labiomentental artery [17], such as in the Case #2 reported here. The inferior labial artery and the horizontal labiomentental artery are the main arteries used in the lower lip pedicle [18].

Kinked internal carotid arteries

As Paulsen et al documented, in most descriptions the cervical part of the ICA runs a straight course to the base of skull [27]. However, in 12/282 preparations (4.2%) kinks of the ICA were found [27]. These were documented for their relation with the pharyngeal wall, being found that in female patients the ICA kinks come in relation with the pharyngeal wall in 3.33% of cases [27]. Details on the uni- or bilateral evidence of such kinked ICAs were blurred by the material and methods that were used [27]. In Case #1 were found bilaterally symmetrical antero-posterior kinks of the ICAs which were extended posterior to a frontal plane through the transverse processes of the atlas vertebra. Moreover, they were either indenting medially, or displacing posteriorly the adjacent IJV. Such morphological variant brings the ICA and the IJV posterior to the vertebral vessels, this being important in spine and back surgery. As kinking of an artery is the angulation of arterial segments, it is often associated with stenosis [39]. A kinked ICA could be clinically significant and cause cerebral infarction [39]. Few reports detailed previously the IJV extrinsic compression caused by ICA compression [19]. The IJV stenosis is characterized by a series of non-specific symptoms determined by blood flow obstruction [19].

Incompetent circle of Willis

As in Case #2 the A1 segment of the left anterior cerebral artery, as well as both, left and right, posterior communicating arteries were also absent, the circle of Willis was regarded as an incompetent one. To that unfavourable anatomical disposition was added the distal aplasia of the left VA (fig.9).

Aplasia of the A1 segment of the anterior cerebral artery and bilateral aplasia of the posterior communicating artery

The aplasia of the A1 segment of the left anterior cerebral artery was found in Case #2. Thus both distal parts of the anterior cerebral arteries were supplied from the contralateral ICA. This is a rare finding, but the most frequently observed variation of the anterior cerebral artery [37]. Lippert and Pabst indicated this variant to occur in 10% of cases [20], Carels et al found it in 10.5% [6], but Uchino et al (2006) observed it in just 5.6% of cases [37].

Lippert and Pabst also indicated an incidence of 10% of the bilateral aplasia or hypoplasia of both posterior communicating arteries [20]. The bilateral posterior

communicating artery atresia was listed as a variation in the configuration of the circle of Willis by Jinkins [14]. The unilateral aplasia of the posterior communicating artery was found in 3.5% of cases [9]. Alpers et al reported a prevalence of 0.6% of the unilateral absence of the posterior communicating artery [1]. Saeki and Rhoton [33] credited Alpers et al for the incidence of the absent posterior communicating but in “Bergman’s Comprehensive Encyclopedia of Human Anatomic Variation” this anatomic variation was attributed to Saeki and Rhoton [4]. As it appears, in Bergman’s Encyclopedia the possible bilateral absence of the posterior communicating arteries was not documented.

Distal aplasia of the vertebral artery

Interestingly, on the side with the occipital-vertebral anastomotic channel (Case #2) the distal part of that left VA was aplastic, thus it was not contributing to the formation of the BA, but it ended supplying the posterior inferior cerebellar artery. Such an unilateral aplastic distal VA was reported with a incidence of 4.6% in asymptomatic persons by use of magnetic resonance imaging, while it has been reported as 0.2% of cases after use of cerebral angiography [23].

The occipital-vertebral arterial anastomosis

In the 4-5 mm embryos a pair of neural arteries supply the hindbrain and anastomose with the ICA system through trigeminal, otic, hypoglossal and proatlantal arteries [8]. These are ventro-dorsal anastomotic arteries or cervical somatic arteries [16]. The proatlantal (cervical somatic) arteries persist until the VAs develop [8]. Two types of proatlantal arteries are described: Type 1, when the proatlantal artery arises from the ICA and courses above the atlas vertebra to enter the foramen magnum and join the VA, and Type 2, which leaves the ECA and joins the VA outside the skull [8]. Different possibilities of regression of the proatlantal arteries determine the variation of the OA origin, either from the ECA, or from the ICA, or from the VA [16,36,38].

In the present study was found, among other variations, an anastomotic channel between the descending branch of the OA and the VA in the 3rd intervertebral space (C2-C3 space). This should not be unusual, as in the anatomical and neuroradiological literature is admitted that the OA and VA are anastomosed, usually by muscular anastomotic channels [16].

According to Lasjaunias et al, from the ascending (cervico-occipital) portion of the OA two posterior muscular branches arise and project in the 2nd and 3rd intervertebral spaces, respectively [16]. The branch of the 2nd space anastomoses with the VA by an anastomotic channel of the 2nd space [16]. Further, from the horizontal (occipital) portion of the OA arise: (a) a direct anastomotic channel of 1st space, which anastomoses with the VA in that atlantooccipital space and (b) a posterior arch (descending branch) that anastomoses with the anastomotic channel of the 2nd space.

Therefore, the anastomotic channel that was found here uniting the descending branch of the OA with the VA in the 3rd space appears as a novel finding to be added to the morphological pattern that was suggested by Lasjaunias et al (fig.9).

If the occipital-vertebral anastomotic channel of the 3rd intervertebral space is regarded as a part of a general arterial picture (fig.10) it appears that it could play a certain role in supplying the ipsilateral middle cerebral artery with blood from the VA, thus it compensates the ipsilateral absent posterior communicating artery. However, on the opposite side the arterial anatomy indicates that the VA supplies both posterior cerebral arteries and the ICA supplies the ipsilateral middle and anterior cerebral arteries, as well as the contralateral anterior cerebral one.

Richter found in 25/30 cases segmental branches from the VA to the muscles of the neck [30], which supports the theory of Lasjaunias et al. Richter observed filling of the OA that occurred once during vertebral angiography [30]. Additionally he observed in two cases of ICA thrombosis the possibility of a compensatory occipital-vertebral flow [30]. In such a case with ICA thrombosis, Richter found multiple small occipital-vertebral connections [10]. Schechter observed in a retrospective study of 1000 cerebral angiograms just 8 cases with occipital-vertebral anastomosis [34]. This author demonstrated on angiograms small anastomotic pathways linking the vertebral system with the descending branch of the OA and discussed they can function in either direction, carotid-to-vertebral or vertebral-to-carotid [34]. Occipital-vertebral anastomoses built-up by muscular branches of the 2nd and 3rd intervertebral space ensured an ipsilateral ECA supply of the cerebral circulation in a case with occluded ICA [13]. The anastomotic channel of the 3rd space was also tortuous, such as in the present report.

Anastomoses of the carotid and vertebrobasilar systems exist or become apparent in different pathological conditions (occlusions, arteriovenous malformations) [13]. The

possibility for the occipital-vertebral anastomoses being constitutive was supported by a series of four cases with such direct anastomoses in the 1st (atlantooccipital space), when just two of these were associated with VA occlusion, the other two being not related neither to ECA, nor to VA occlusion [35]. Rarely, the occipital-vertebral anastomosis is symptomatic (syncope, vertebrobasilar insufficiency) due to a vertebral steal phenomenon through the anastomotic channel [11]. The occipital-vertebral anastomoses are infrequently visualized on angiographies, although they are not uncommon [22]. In the 2nd case reported here the occipital-vertebral anastomosis was seemingly of benefit to compensate the aplasia of different arterial suppliers of the circle of Willis.

List of Abbreviations

ACA – anterior cerebral artery

APA – ascending pharyngeal artery

BA – basilar artery

CCA – common carotid artery

ECA – external carotid artery

FA – facial artery

ICA – internal carotid artery

IJV – internal jugular vein

LA – lingual artery

MA – maxillary artery

MFT – maxillofacial trunk

MMA – middle meningeal artery

OA – occipital artery

PAA – posterior auricular artery

STA – superficial temporal artery

StA – superior thyroid artery

TFA – transverse facial artery

VA – vertebral artery

References

1. Alpers BJ, Berry RG, Paddison RM (1959) Anatomical studies of the circle of willis in normal brain. *AMA Arch Neurol Psychiatry*, 81:409-418.
doi:10.1001/archneurpsyc.1959.02340160007002,
<https://www.ncbi.nlm.nih.gov/pubmed/13636509>
2. Anangwe D, Saidi H, Ogeng'o J, Awori KO (2008) Anatomical variations of the carotid arteries in adult kenyans. *East Afr Med J*, 85:244-247. doi:10.4314/eamj.v85i5.9619,
<https://www.ncbi.nlm.nih.gov/pubmed/18814535>
3. Illustrated encyclopedia of human anatomic variation: Opus ii: Cardiovascular system: Arteries: Head, neck, and thorax. Maxillary artery. 2013. at
<https://www.anatomyatlases.org/AnatomicVariants/Cardiovascular/Text/Arteries/Maxillary.shtml>.)
4. Bergman RA, Tubbs RS, Shoja MM, Loukas M. Bergman's comprehensive encyclopedia of human anatomic variation. Hoboken, New Jersey: John Wiley & Sons; 2016.
5. Cappabianca S, Scuotto A, Iaselli F, Pignatelli di Spinazzola N, Urraro F, Sarti G, Montemarano M, Grassi R, Rotondo A (2012) Computed tomography and magnetic resonance angiography in the evaluation of aberrant origin of the external carotid artery branches. *Surg Radiol Anat*, 34:393-399. doi:10.1007/s00276-011-0926-3,
<https://www.ncbi.nlm.nih.gov/pubmed/22215429>
6. Carels K, Cornelissen SA, Robben D, Coudyzer W, Demaerel P, Wilms G (2018) Smaller caliber of the internal carotid artery in patients with ipsilateral aplasia of the a1 segment of the anterior cerebral artery: A study with cta. *Acta Neurol Belg*, 118:297-302. doi:10.1007/s13760-018-0935-7, <http://www.ncbi.nlm.nih.gov/pubmed/29721852>
7. Devadas D, Pillay M, Sukumaran TT (2018) A cadaveric study on variations in branching pattern of external carotid artery. *Anat Cell Biol*, 51:225-231. doi:10.5115/acb.2018.51.4.225, <https://www.ncbi.nlm.nih.gov/pubmed/30637155>
8. Gumus T, Onal B, Ilgit ET (2004) Bilateral persistence of type 1 proatlantal arteries: Report of a case and review of the literature. *AJNR Am J Neuroradiol*, 25:1622-1624.
<https://www.ncbi.nlm.nih.gov/pubmed/15502152>
9. Gunnal SA, Farooqui MS, Wabale RN (2018) Anatomical variability of the posterior communicating artery. *Asian J Neurosurg*, 13:363-369. doi:10.4103/ajns.AJNS_152_16,
<https://www.ncbi.nlm.nih.gov/pubmed/29682035>

10. Hackett ER, Wilson CB (1968) Congenital external carotid-vertebral anastomosis. A case report. *Am J Roentgenol Radium Ther Nucl Med*, 104:86-89. doi:10.2214/ajr.104.1.86, <https://www.ncbi.nlm.nih.gov/pubmed/5672781>
11. Harada J, Kuwayama N, Nishijima M, Okamoto S, Kubo M, Endo S (2000) Symptomatic occipital-vertebral anastomosis - a case report. *Interv Neuroradiol*, 6:317-320. doi:10.1177/159101990000600406, <https://www.ncbi.nlm.nih.gov/pubmed/20667210>
12. Herrera-Nunez M, Menchaca-Gutierrez JL, Pinales-Razo R, Elizondo-Riojas G, Quiroga-Garza A, Fernandez-Rodarte BA, Elizondo-Omana RE, Guzman-Lopez S (2020) Origin variations of the superior thyroid, lingual, and facial arteries: A computed tomography angiography study. *Surg Radiol Anat*, 42:1085-1093. doi:10.1007/s00276-020-02507-6, <https://www.ncbi.nlm.nih.gov/pubmed/32488410>
13. Holodny AI (2005) Supply of the unilateral circulation of the brain by an occipital artery anastomosis--a case report. *Angiology*, 56:93-95. doi:10.1177/000331970505600113, <https://www.ncbi.nlm.nih.gov/pubmed/15678262>
14. Jinkins JR. *Atlas of neuroradiologic embryology, anatomy, and variants*. Philadelphia: Lippincott Williams & Wilkins; 2000.
15. Krmpotić-Nemanić J (1978) Anatomie, variationen und mißbildungen der gefäße im kopf-und halsbereich (erläuterungen zum referat). *Arch Otorhinolaryngol*, 219:285-305.
16. Lasjaunias P, Theron J, Moret J (1978) The occipital artery. Anatomy--normal arteriographic aspects--embryological significance. *Neuroradiology*, 15:31-37. doi:10.1007/BF00327443, <https://www.ncbi.nlm.nih.gov/pubmed/643171>
17. Lee HJ, Won SY, O J, Hu KS, Mun SY, Yang HM, Kim HJ (2018) The facial artery: A comprehensive anatomical review. *Clin Anat*, 31:99-108. doi:10.1002/ca.23007, <https://www.ncbi.nlm.nih.gov/pubmed/29086435>
18. Lee SH, Lee HJ, Kim YS, Kim HJ, Hu KS (2015) What is the difference between the inferior labial artery and the horizontal labiomental artery? *Surg Radiol Anat*, 37:947-953. doi:10.1007/s00276-015-1447-2, <https://www.ncbi.nlm.nih.gov/pubmed/25724940>
19. Li M, Su C, Fan C, Chan CC, Bai C, Meng R (2019) Internal jugular vein stenosis induced by tortuous internal carotid artery compression: Two case reports and literature review. *J Int Med Res*, 47:3926-3933. doi:10.1177/0300060519860678, <https://www.ncbi.nlm.nih.gov/pubmed/31304848>
20. Lippert H, Pabst R. *Arterial variations in man: Classification and frequency*: Springer; 1985.

21. McEachen JC, Obrzut M, Bokhari SJ (2009) A rare combination of carotid artery congenital abnormalities: Understanding the embryology and clinical associations. *Emerg Radiol*, 16:411-414. doi:10.1007/s10140-008-0756-8, <https://www.ncbi.nlm.nih.gov/pubmed/18682997>
22. Miyachi S, Negoro M, Sugita K (1989) The occipital-vertebral anastomosis as a collateral pathway: Hemodynamic patterns--case report. *Surg Neurol*, 32:350-355. doi:10.1016/0090-3019(89)90138-9, <https://www.ncbi.nlm.nih.gov/pubmed/2683165>
23. Morimoto K, Nagahata M, Ono S, Miura H, Tsushima F, Seino H, Kakehata S, Basaki K, Uno S, Abe Y (2009) Incidence of unilateral distal vertebral artery aplasia: Evaluation by combining basiparallel anatomic scanning-magnetic resonance imaging (bpas-mri) and magnetic resonance angiography. *Jpn J Radiol*, 27:151-155. doi:10.1007/s11604-008-0313-0, <https://www.ncbi.nlm.nih.gov/pubmed/19412683>
24. Natsis K, Raikos A, Foundos I, Noussios G, Lazaridis N, Njau SN (2011) Superior thyroid artery origin in caucasian greeks: A new classification proposal and review of the literature. *Clin Anat*, 24:699-705. doi:10.1002/ca.21181, <https://www.ncbi.nlm.nih.gov/pubmed/21438023>
25. Osborn AG. *Diagnostic cerebral angiography*. 2nd ed. Philadelphia, PA: Lippincott Williams & Wilkins; 1999.
26. Ozgur Z, Govsa F, Ozgur T (2008) Assessment of origin characteristics of the front branches of the external carotid artery. *J Craniofac Surg*, 19:1159-1166. doi:10.1097/SCS.0b013e3180690252, <http://www.ncbi.nlm.nih.gov/pubmed/18650752>
27. Paulsen F, Tillmann B, Christofides C, Richter W, Koebke J (2000) Curving and looping of the internal carotid artery in relation to the pharynx: Frequency, embryology and clinical implications. *J Anat*, 197 Pt 3:373-381. doi:10.1046/j.1469-7580.2000.19730373.x, <https://www.ncbi.nlm.nih.gov/pubmed/11117624>
28. Pretterklieber ML, Krammer EB, Mayr R (1991) A bilateral maxillofacial trunk in man: An extraordinary anomaly of the carotid system of arteries. *Acta Anat (Basel)*, 141:206-211. doi:10.1159/000147123, <https://www.ncbi.nlm.nih.gov/pubmed/1755281>
29. Quain R. *The anatomy of the arteries of the human body*. London: Taylor and Walton; 1844.
30. Richter HR (1953) Collaterals between the external carotid artery and the vertebral artery in cases of thrombosis of the internal carotid artery. *Acta radiol*, 40:108-112. doi:10.3109/00016925309176574, <https://www.ncbi.nlm.nih.gov/pubmed/13114009>

31. Rusu MC, Maru N, Radoi PM, Dinca D (2019) Trifurcated external carotid artery and complete gamma-loop of its maxillary branch. *Surg Radiol Anat*, 41:231-234. doi:10.1007/s00276-018-2142-x, <http://www.ncbi.nlm.nih.gov/pubmed/30483866>
32. Rusu MC, Vasilescu A, Nimigean V (2006) A rare anatomic variant: The lateral position of the external carotid artery. *Int J Oral Maxillofac Surg*, 35:1066-1067. doi:10.1016/j.ijom.2006.04.001, <http://www.ncbi.nlm.nih.gov/pubmed/16828540>
33. Saeki N, Rhoton AL, Jr. (1977) Microsurgical anatomy of the upper basilar artery and the posterior circle of willis. *J Neurosurg*, 46:563-578. doi:10.3171/jns.1977.46.5.0563, <https://www.ncbi.nlm.nih.gov/pubmed/845644>
34. Schechter MM (1964) The occipital-vertebral anastomosis. *J Neurosurg*, 21:758-762. doi:10.3171/jns.1964.21.9.0758, <https://www.ncbi.nlm.nih.gov/pubmed/14210007>
35. Suzuki S, Kuwabara Y, Karasawa S (1980) [the developmental mechanism of occipital-vertebral anastomosis (author's transl)]. *No To Shinkei*, 32:69-79. <https://www.ncbi.nlm.nih.gov/pubmed/7356852>
36. Tanaka Y, Hara H, Momose G, Kobayashi S, Kobayashi S, Sugita K (1983) Proatlantal intersegmental artery and trigeminal artery associated with an aneurysm. Case report. *J Neurosurg*, 59:520-523. doi:10.3171/jns.1983.59.3.0520, <https://www.ncbi.nlm.nih.gov/pubmed/6886766>
37. Uchino A, Nomiya K, Takase Y, Kudo S (2006) Anterior cerebral artery variations detected by mr angiography. *Neuroradiology*, 48:647-652. doi:10.1007/s00234-006-0110-3, <https://www.ncbi.nlm.nih.gov/pubmed/16786350>
38. Uchino A, Saito N, Mizukoshi W, Okada Y (2011) Anomalous origin of the occipital artery diagnosed by magnetic resonance angiography. *Neuroradiology*, 53:853-857. doi:10.1007/s00234-010-0825-z, <https://www.ncbi.nlm.nih.gov/pubmed/21174081>
39. Vannix RS, Joergenson EJ, Carter R (1977) Kinking of the internal carotid artery. Clinical significance and surgical management. *Am J Surg*, 134:82-89. doi:10.1016/0002-9610(77)90288-4, <https://www.ncbi.nlm.nih.gov/pubmed/879413>
40. Zumre O, Salbacak A, Cicekcibasi AE, Tuncer I, Seker M (2005) Investigation of the bifurcation level of the common carotid artery and variations of the branches of the external carotid artery in human fetuses. *Ann Anat*, 187:361-369. doi:10.1016/j.aanat.2005.03.007, <https://www.ncbi.nlm.nih.gov/pubmed/16163849>

Table 1. Anatomic variations encountered in the 2/52 cases found with maxillofacial trunks. U – unilateral; B – bilateral; ICA – internal carotid a.; IJV – internal jugular vein; StA – superior thyroid a.; CCA – common carotid a.; CB – common carotid a.bifurcation; ECA – external carotid a.; VA – vertebral a.; ACA – anterior cerebral a.; STA – superficial temporal a.

Anatomic variation	Case #1	Case #2
maxillofacial trunk	U	U
ICA folded into the IJV	B	-
CCA origin of the StA	B	-
<i>os stylo-hyale</i>	B	-
high origin (C2) of the facial a.	U	-
CB origin of the StA	-	B
<i>os cerato-hyale</i>	-	B
occipital-to-vertebral arterial anastomosis	-	U
terminal trifurcation of the ECA	-	U
aberrant course of the STA		
aplasia of the distal segment of the VA	-	U
aplasia of the A1 segment of the ACA	-	U
aplasia of the posterior communicating artery	-	B
linguofacial trunk	-	U
labiomental trunk	-	U

Figure 1. Three dimensional volume renderization, infero-medial view, right side (case #1). 1.superficial temporal a.; 2.middle meningeal a.; 3.maxillary a.; 4.os stylo-hyale; 5.posterior auricular a.; 6.facial a.; 7.external carotid a.; 8.occipital a.; 9.posterior kink of the internal carotid a.; 10.coiled lingual a.; 11.origin of the superior thyroid a.; 12.greater horn of the hyoid bone; 13.common carotid a.; 14.internal jugular v.

Figure 2. Three dimensional volume renderization, postero-infero-lateral view, left side. The maxillofacial trunk (case #1). 1.maxillary a.; 2.facial a.; 3.lingual a.; 4.greater horn of the hyoid bone; 5.superficial temporal a.; 6.middle meningeal a.; 7.os tympano-hyale; 8.posterior

auricular a.; 9.occipital a.; 10.atlas vertebra; 11.vertbral a.; 12.posterior kink of the internal carotid a.; 13.maxillofacial trunk; 14.internal jugular v.; 15.os stylo-hyale.

Figure 3. Three dimensional volume renderization, infero-medial view, left side. The maxillofacial trunk (case #1). 1.middle meningeal a.; 2.superficial temporal a.; 3. os stylo-hyale; 4.posterior auricular a.; 5.ascending pharyngeal a.; 6.internal jugular v.; 7.posterior kink of the internal carotid a.; 8.tip of the greater horn of the hyoid bone; 9.origin of the superior thyroid a.; 10.common carotid a.; 11.maxillary a.; 12.lingual a.; 13.maxillofacial trunk; 14.facial a.

Figure 4. Three dimensional volume renderization, infero-lateral view, left side (case #2). The occipital-to-vertebral anastomosis. Terminally trifurcated external carotid artery. Linguofacial arterial trunk. 1. transverse facial a.; 2.internal carotid a.; 3.occipital a.; 4.linguofacial trunk; 5.facial a.; 6.external carotid a.; 7.lingual a.; 8.superior thyroid a.; 9.superficial temporal a.; 10.styloid process; 11.internal jugular v.; 12.descending branch of the occipital a.; 13. occipital-to-vertebral arterial anastomosis; 14.vertbral a.; 15.maxillary a.

Figure 5. Three dimensional volume renderization, superior view of the skull base (case #2). Aplasia of the A1 segment of the left cerebral artery. Aplasia of the left distal vertebral artery. 1.left pericallosal a.; 2.left anterior cerebral a.; 3.left internal carotid a.; 4.left middle cerebral a.; 5.dorsum sellae; 6.left posterior cerebral a.; 7.left superior cerebellar a.; 8.basilar a.; 9.left posterior inferior cerebellar a.; 10.left vertebral a.; 11.right anterior cerebral a.; 12.right internal carotid a.; 13.A1 segment of the right anterior cerebral a.; 14.right middle cerebral a.; 15.right posterior inferior cerebellar a.; 16.right vertebral a.

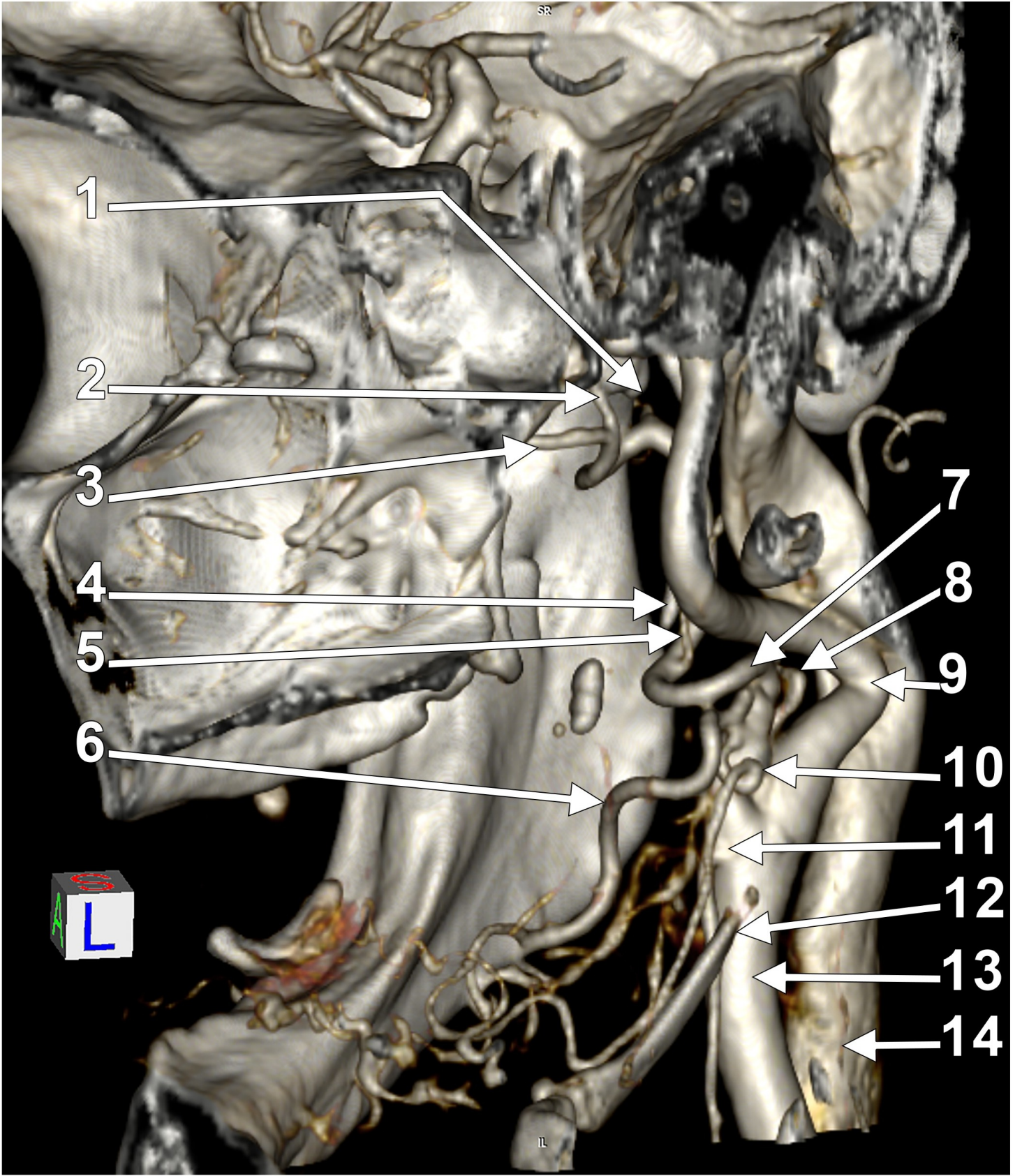
Figure 6. Three dimensional volume renderization, anterior view, right side. Origin of the maxillofacial trunk (case #2). 1.coronoid process; 2.superficial temporal artery; 3.maxillary a.; 4.facial a.; 5.submandibular a.; 6.maxillofacial trunk; 7.common carotid a.; 8.pterygoid plexus; 9.internal carotid a.; 10. styloid process; 11.internal jugular vein; 12.pharyngeal plexus; 13. os cerato-hyale; 14.vertbral a.; 15.lingual a.; 16.superior thyroid a.; 17.greater horn of the hyoid bone.

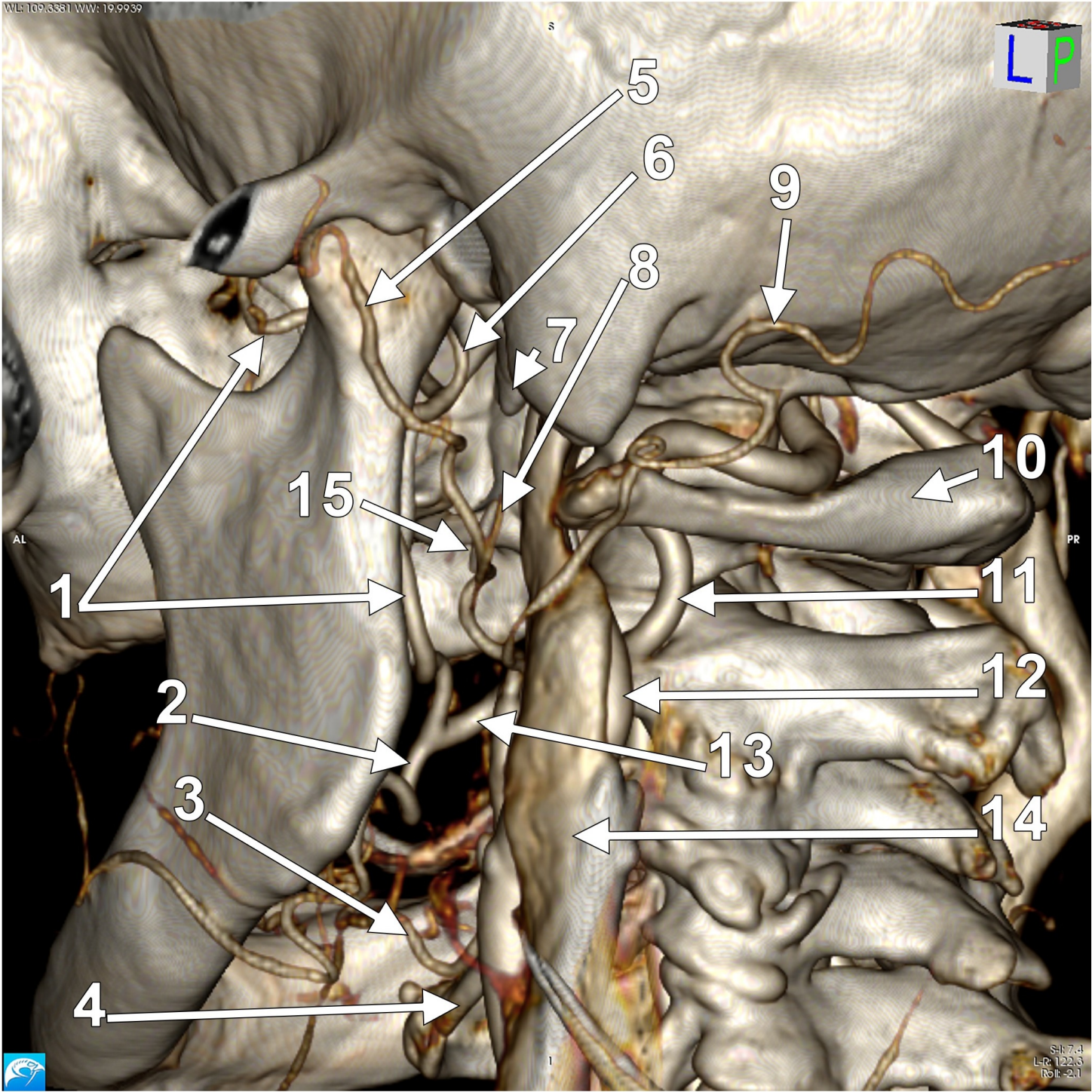
Figure 7. Three dimensional volume renderization, postero-infero-lateral view, right side. Origin of the maxillofacial trunk (case #2). 1.internal carotid a.; 2.styloid process; 3.posterior auricular a.; 4.occipital a.; 5.vertrebral a.; 6.internal jugular vein; 7.transverse facial a.; 8.superficial temporal a.; 9.maxillofacial trunk; 10.facial a.; 11.lingual a.

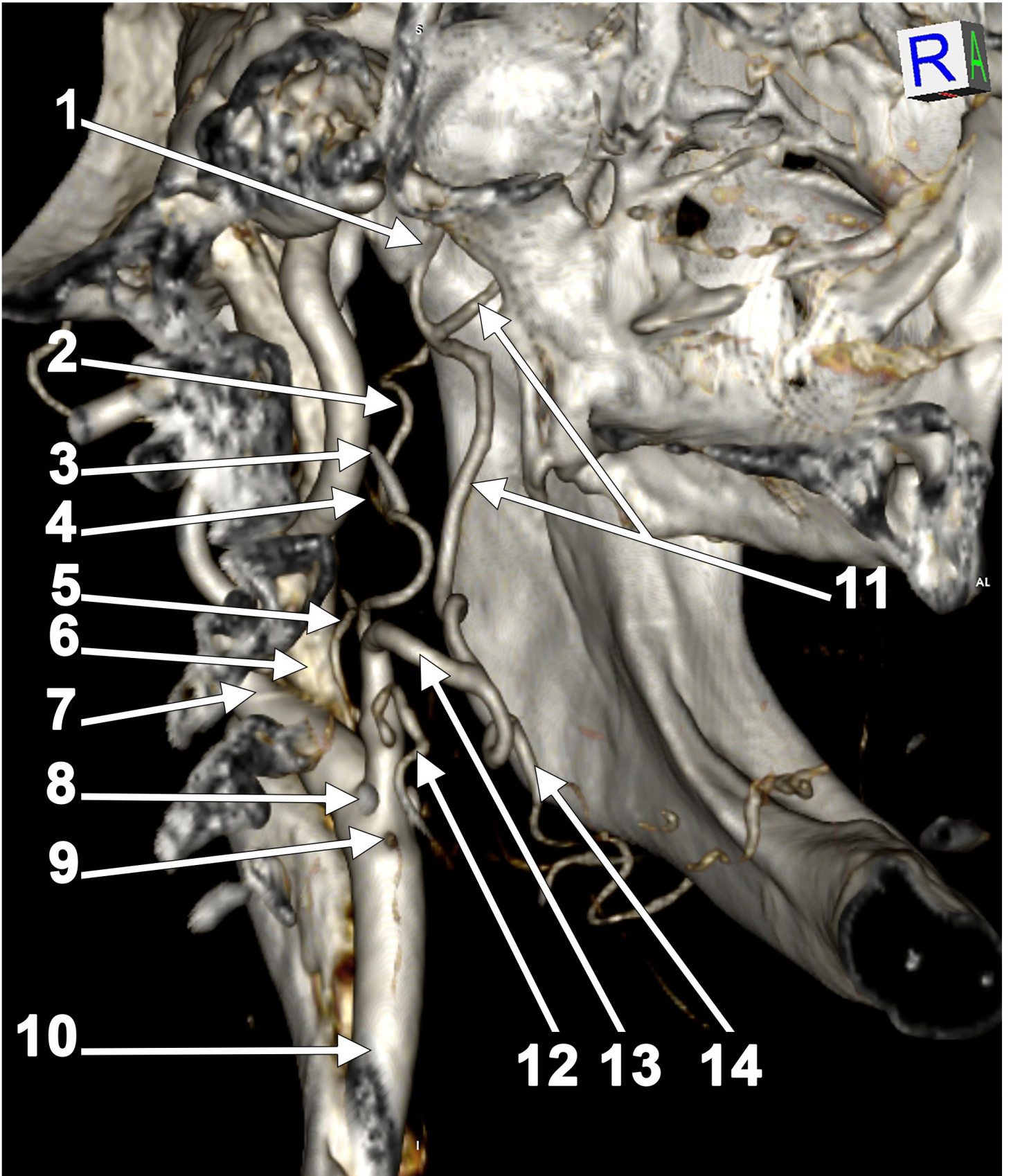
Figure 8. Three dimensional volume renderization, infero-lateral view, right side (case #2). The labiomental trunk. 1.superficial temporal a.; 2.superficial temporal v.; 3.occipital a.; 4.internal jugular v.; 5.facial a.; 6.transverse facial a.; 7.facial v.; 8.labiomental trunk.

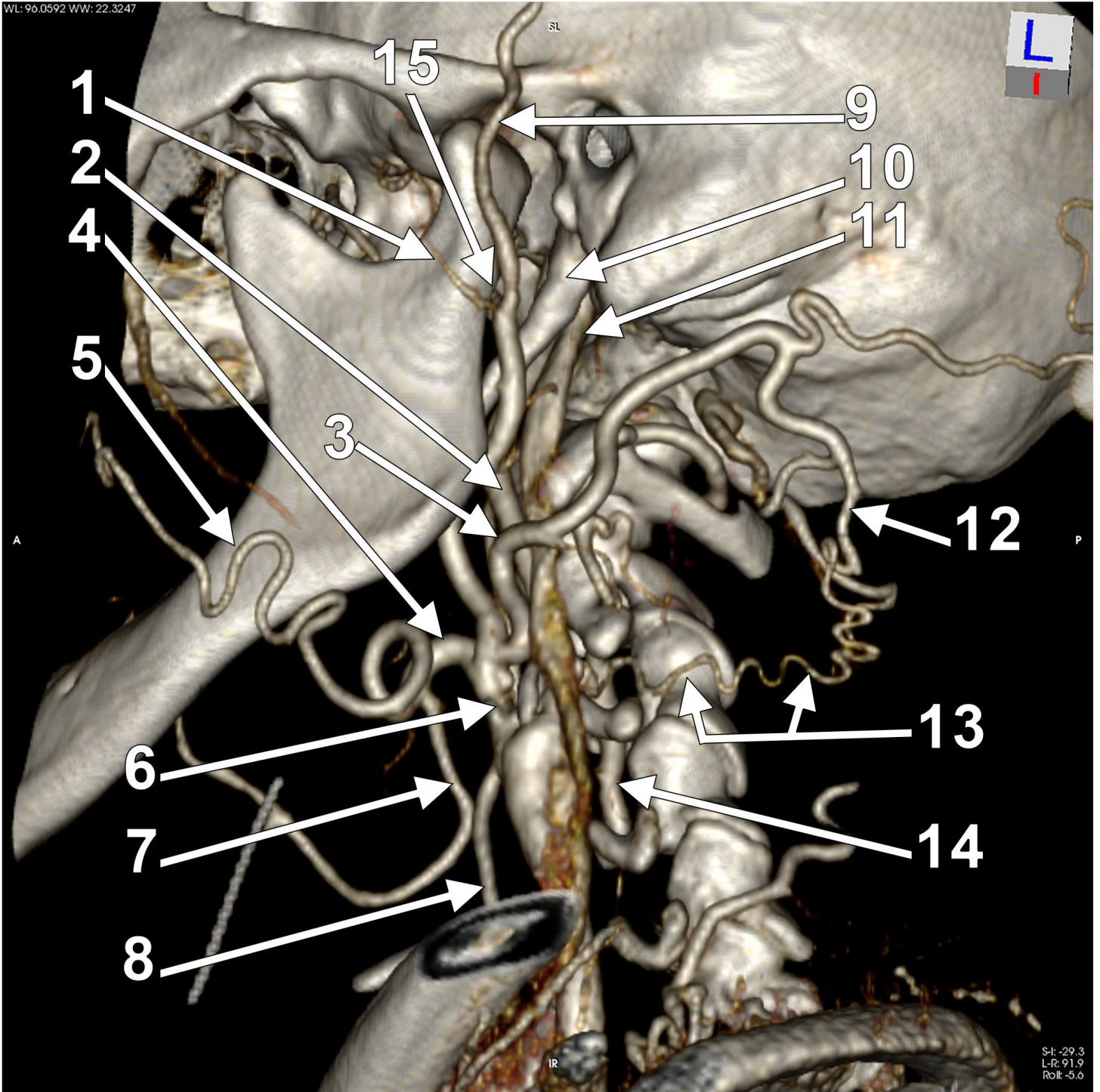
Figure 9. Drawing of a left lateral view updating the occipital-vertebral anastomotic pattern of Lasjaunias et al. 1.occipital a.; 2.vertrebral a.; 3.posterior muscular branch of the 2nd intervertebral space; 4. posterior muscular branch of the 3rd intervertebral space; 5.anastomotic channel of the 1st (atlantooccipital) space; 6.anastomotic channel of the 2nd space; 7.posterior arch of Lasjaunias; 8.descending branch of the occipital a. (Nomina Anatomica); 9.anastomotic channel of the 3rd space (Case #2).

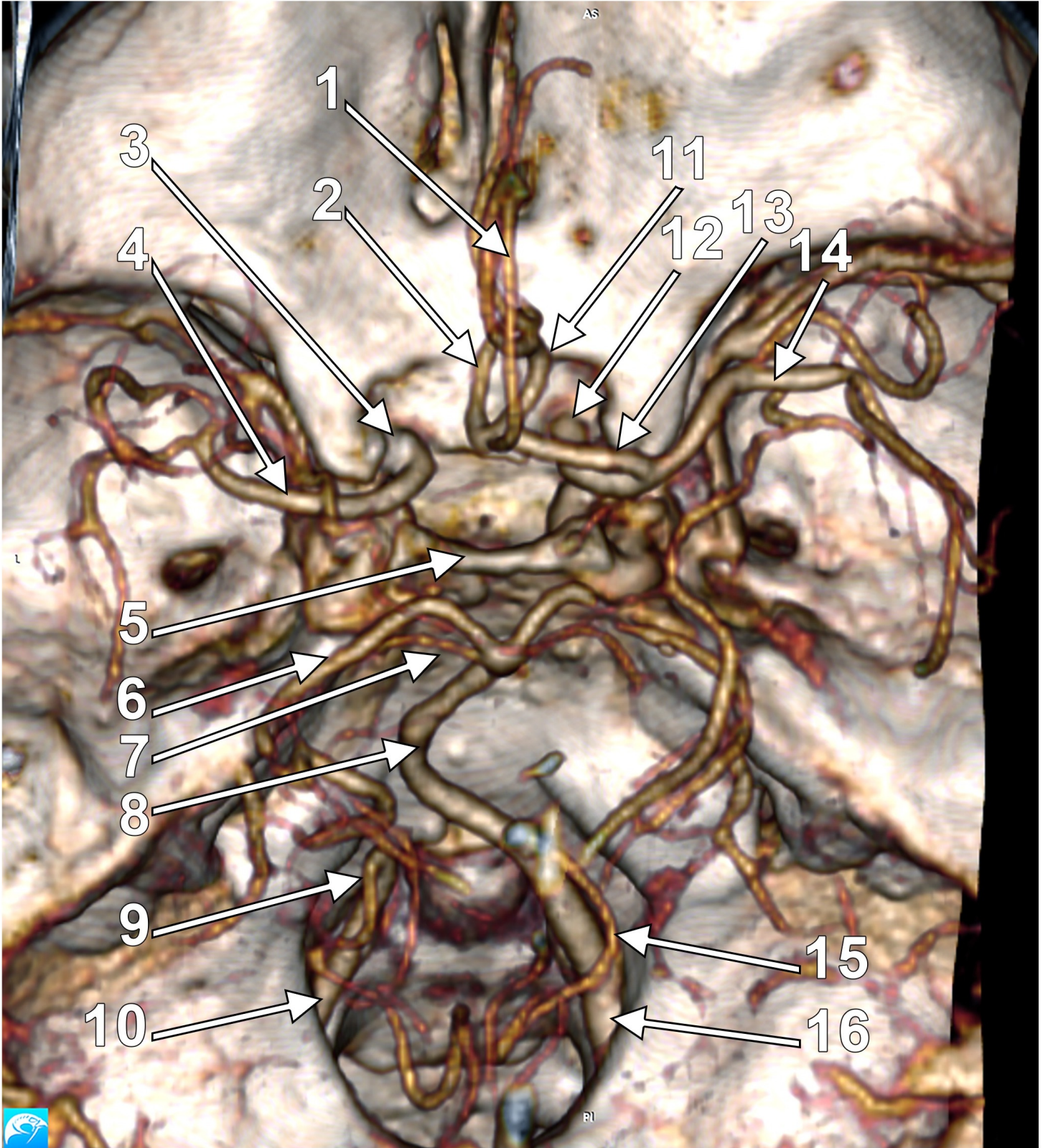
Figure 10. Diagram of the arterial variation (superior view) in Case #2. The ipsilateral vertebral-to-middle cerebral artery pathway is indicated with arrows. 1.left common carotid a.; 2.left; 3.left internal carotid a.; 4.left occipital a.; 5. occipital-vertebral anastomotic channel of the 3rd intervertebral space; 6.left vertebral a.; 7.right vertebral a.; 8.posterior inferior cerebellar arteries; 9.basilar a.; 10.right posterior cerebral a.; 11.left posterior cerebral a.; 12.left middle cerebral a.; 13.right middle cerebral a.; 14.right anterior cerebral a.; 15.left anterior cerebral a. Thin lines indicate the aplastic arteries: (a) distal left vertebral a.; (b, b') posterior communicating arteries; (c) left A1 segment of the anterior cerebral a.

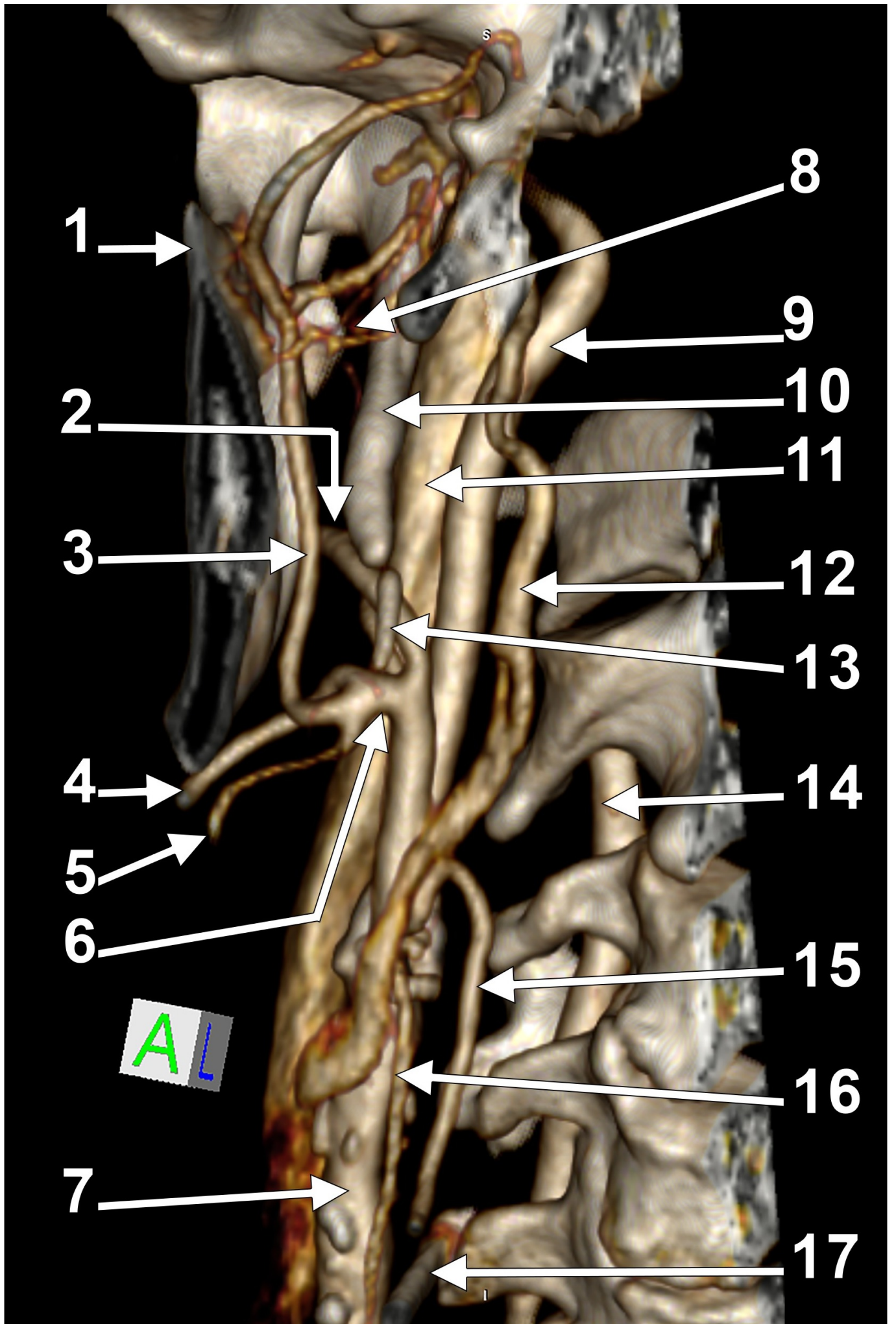


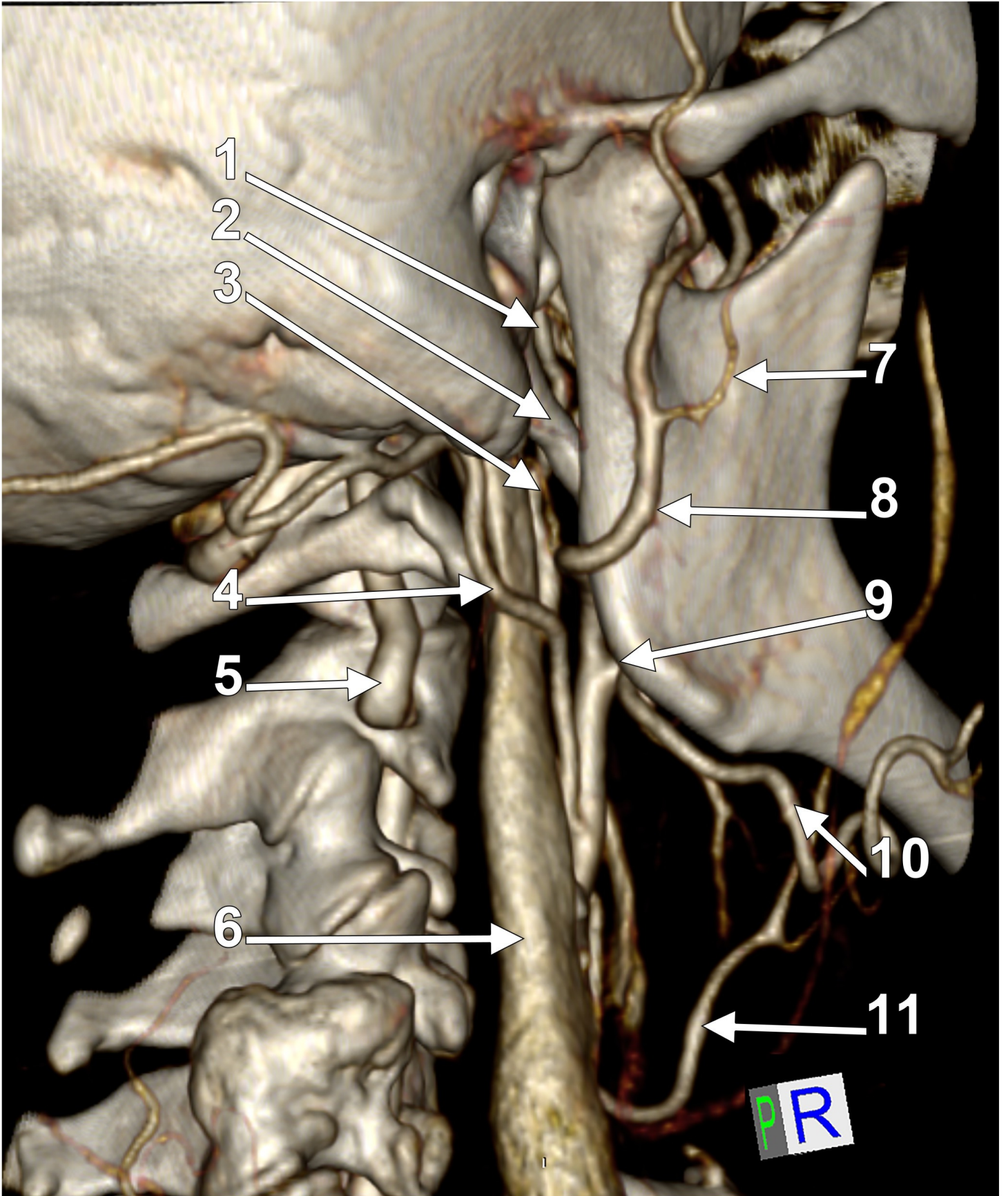












WL: 77.5311 WW: 23.1642

